

[Click here to view linked References](#)

Morphometric features on enhanced-depth imaging optical coherence tomography scans in idiopathic posterior uveitis or panuveitis

Rashi Arora^{1*}

Rupesh Agrawal^{2,3,4*}

Pearse A. Keane^{2,3}

Aniruddha Agarwal,⁵

Carlos Pavesio^{2,3}

¹Salisbury District Hospital, Salisbury, London, United Kingdom

²Moorfields Eye Hospital, NHS Foundation Trust, London, United Kingdom

³Institute of Ophthalmology, University College London, London, United Kingdom

⁴National Healthcare Group Eye Institute, Tan Tock Seng Hospital, Singapore.

⁵Advanced Eye Center, Post Graduate Institute of Medical Education and Research (PGIMER), Chandigarh, India

Corresponding author:

Dr. Rupesh Agrawal

National Healthcare Group Eye Institute,

Tan Tock Seng Hospital,

Singapore

Email: Rupesh_agrawal@ttsh.com.sg

Running title: **Morphological changes in uveitis**

*** Joint first authors**

Abstract:

Purpose: Enhanced Depth Imaging (EDI) optical coherence tomography (OCT) ~~is emerging~~has emerged as a novel tool for qualitative and quantitative choroidal assessment in posterior uveitis. The objective of this study was to investigate the role of EDI-OCT to assess the choroidal and retinal changes in posterior uveitis.

Methods: In this retrospective study, EDI-OCT scans of patients with idiopathic posterior uveitis or panuveitis were reviewed. Morphological features from retina and choroid from the OCT scans were assessed and ~~reviewed with apparently compared to the~~ fellow normal eyes. Follow-up assessment was performed and longitudinally at six-month follow-up.

Results: 19 patients with idiopathic posterior or panuveitis were included in the study. Choroidal examination using EDI-OCT scans showed areas of focal hypo-reflective and discrete hyper-reflective foci in one-third ~~of the~~ patients. Macular edema, disruption of the ellipsoid zone (generalised and discrete), outer retinal hyper-reflective foci, intra-retinal and sub-retinal fluid were ~~features of the retinal assessment~~observed.

Conclusions: The index study reports qualitative OCT-derived parameters as possible tools in monitoring disease progression in uveitis.

Key words:

Enhanced depth imaging (EDI-OCT);

Heterogeneous uveitis;

Hyperreflective foci;

Hyporefective foci;

Intraretinal fluid;

Subretinal fluid

Conflict of Interest:

Nil

Funding:

Nil

Ethical approval:

Obtained, stated in the manuscript.

INTRODUCTION

Uveitis often presents as a diagnostic and therapeutic challenge and can present with sight-threatening manifestations [1]. Although anterior uveitis is more common, posterior and panuveitis ~~that can occur~~that occurs in 10-15% patients, may be associated with a higher visual morbidity [2-4]. There are limited objective measures available to assess and monitor the posterior segment involvement in uveitis making the diagnosis and management a challenging task.

The imaging modalities currently ~~used~~employed in the diagnosis and follow-up of uveitis include fluorescein angiography (FFA) and indocyanine green angiography (ICGA) [5], optical coherence tomography (OCT) [6], wide-field retinal imaging [7], and fundus autofluorescence [8], among others. Angiography can ~~suggest help in the assessment of~~ disease activity. ~~Angiographic, and the~~ leakage and staining ~~identified in this test~~ are useful in monitoring the disease changes that occur at the subclinical level ~~or ultrastructural levels~~. However, such changes may not be always ~~visible~~detectable. This represents an inherent limitation of the technique of angiography, apart from its invasive nature.

With the advent of OCT and autofluorescence imaging, ~~more~~ in-depth analysis of the vitreous, retina, and choroid is possible non-invasively [9]. OCT can provide real-time optical histological cross-sections of the retina, retinal pigment epithelium (RPE) and the choroid. When compared to FFA, OCT was found to have 89% sensitivity for diagnosing CME [10]. OCT is also very useful in studying the vitreoretinal interface and identifying vitreo-foveal traction in uveitic eyes [11]. In patients with Vogt–Koyanagi–Harada (VKH) disease and sympathetic ophthalmia, OCT is very useful in monitoring serous retinal detachments. During the early stage

of VKH disease, the RPE may be elevated because of underlying choroidal granulomas, thus producing choroidal striations [12].

It is difficult to visualise the choroid and this is the fundamental reason for our limited understanding of the pathological changes that occur in posterior uveitis or panuveitis. Enhanced depth imaging (EDI) OCT provides detailed ~~objective~~ *in vivo* visualization of the choroid and can be used to characterize uveitic entities involving the posterior segment ~~posterior segment inflammatory disorders~~, monitor the disease activity, and evaluate the efficacy of treatment. For instance, the presence of suprachoroidal fluid on EDI-OCT appears to correlate with the subjective complaints of photopsias in patients with Birdshot ~~retinochoroidopathy~~ chorioretinopathy [13]. Similarly, thinning of the sub-foveal choroidal tissue has been observed in patients with Behçet's Disease [14].

The primary objective of this pilot study was to assess the morphological changes on EDI-OCT in the retina and choroid as a possible surrogate marker of disease activity and as a monitoring tool in patients with varying forms of posterior or panuveitis.

MATERIALS AND METHODS:

A retrospective analysis of EDI-OCT images and clinical data of all the patients with posterior uveitis and panuveitis who had follow-up EDI-OCT scans was performed. The study was approved by the Hospital ethics committee (ROAD 14/002), and complied with the tenets set forth in the declaration of Helsinki.

The inclusion criteria are ~~enlisted~~ provided in **Table 1**. ~~We~~ The study included all the patients who received a clinical diagnosis of idiopathic posterior uveitis or

panuveitis for the first time (incident cases), and who had been ~~followed~~ ~~with~~ ~~monitored~~ ~~using~~ EDI-OCT since the first visit for a follow-up period of at least 6 months. ~~The named uveitic entities like~~ Specific uveitic entities such as sarcoidosis, ~~Vogt-Koyanagi-Harada (VKH)~~ disease and posterior scleritis, among others, were not included in this ~~heterogeneous~~ heterogeneous study group of patients with idiopathic posterior uveitis or panuveitis. The following information was retrieved from the clinical records: demographics, ophthalmic examination with best-corrected visual acuity (BCVA) in LogMAR (logarithm of the minimum angle of resolution) units at baseline and follow-up visits, clinician's assessment of disease activity, morphological and etiological diagnosis, systemic and local therapy, duration of treatment, baseline and follow-up EDI-OCT scans, and any other ancillary investigations. All the patients had tailored laboratory investigations, including tests for syphilis and tuberculosis. Based on the results of the laboratory tests (syphilis, tuberculosis, polymerase chain reaction (PCR) in selected cases), imaging (chest X-ray, ocular imaging) and notes from the uveitis specialist, ~~we recorded the cases as idiopathic~~ the diagnosis of idiopathic disease was established. Patients with significant media haze precluding good quality scans (image quality worse than 25 dB) and those who did not ~~had~~ have follow-up EDI-OCT scans were excluded from the study.

Image acquisition: OCT images were obtained using Spectralis OCT (Spectralis; Heidelberg Engineering GmbH; Heidelberg, Germany). All the images were obtained using the EDI protocols first described by Spaide et al [9]. In brief, the OCT device was positioned in close proximity to the patient's eye in order to acquire an inverted image, with 7 equally-spaced OCT B-scan sections obtained in a 20° x 15° horizontal raster pattern. Each image was obtained after averaging 100 scans and using the

eye tracking system in order to maximize the signal-to-noise (SNR) ratio. No image manipulation prior to image acquisition was done.

Qualitative features were assessed on all the EDI-OCT scans at baseline and ~~at six-~~ month follow-up for ~~number of various~~ abnormal retinal and choroidal morphological parameters ~~characterising posterior uveitis~~ by one trained author (RA). A standard form, similar to the one used in our previous study, was used to grade each image ~~set as~~ ('visible', 'questionable', 'not visible', or 'cannot grade') [15].

RESULTS:

19 eyes ~~from~~ (19 patients) with idiopathic posterior or panuveitis were included as study eyes. ~~with 19~~ Nineteen fellow eyes of these patients served as the control group. The mean age was 51.2 years (range: 29 to 76) with 10 (52.63%) males. The mean BCVA at presentation was 0.28 LogMAR (range: -0.08 to 1.78, Snellen equivalent 20/40). All patients were either emmetropic (n=16 (84.21%)) or had less than 3D (Diopters) (n=3) (15%) of myopia. Epiretinal membrane was observed in 3 patients (15%), and cystoid macular edema in 4 (20%). BCVA in these eyes was significantly worse compared to the other eyes (p=0.006). No significant correlations were observed between any of the other morphometric features of the retina/ choroid on EDI-OCT scans and LogMAR BCVA or disease activity (vitreous cellularity) (p=0.15).

Qualitative changes: Qualitative changes ~~were described~~ observed using EDI-OCT images are described in **Table 2**. The characteristics observed on EDI-OCT were **retinal** (epiretinal membrane, generalized thinning or loss of architecture, focal disruption of inner segment (IS)/ outer segment (OS) junction or Ellipsoid zone,

discrete outer retinal hyperreflective foci, generalized loss of Ellipsoid zone, intraretinal cystoid spaces, subretinal fluid, cystoid macular edema (CME)) and **choroidal** (thinning or absence of Sattler's layer, generalized thinning, discrete hyper-reflective foci, focal hypo-reflective spots, suprachoroidal hypo-reflective space, generalized thickness). None of the se characteristic features were observed in the apparently fellow normal eyes. CME was a frequent finding in patients with posterior uveitis and panuveitis (**Figure 1**). The fluid can be subretinal as in (**Figure 2A and B**) or intra-retinal as in (**Figure 3**). Other retinal changes noted included discrete outer retinal hyper-reflective foci (**Figure 4**) and loss of Ellipsoid zone, which can be generalised (**Figure 5**) or discrete (**Figure 6**). Epiretinal membrane was also seen as a sequelae as in (**Figure 7**)—5.

The choroid can be grossly thickened in posterior/panuveitis as in (**Figure 8**) or can show generalised thinning as in (**Figure 9A and B**). Other choroidal features observed noted include were focal choroidal hypo-reflective spots (**Figure 9**) and discrete hyper-reflective spots (**Figure 10**). The follow-up features on EDI-OCT scans were recorded at six-month follow-up are elucidated in (**Table 2**).

DISCUSSION:

In the exploratory index study, we investigated qualitative changes in the retina and choroid in patients with various forms of posterior or panuveitis using custom OCT scanning protocols to allow enhanced structural characterization of the retina and choroid. With significant advances in technology, we are now able to obtain tomographic images of the retina and the choroid *in vivo*. OCT is able to resolve three highly reflecting layers, believed to correspond to the vitreous/retina, inner/outer photoreceptor segments, and RPE/choriocapillaris interfaces [16]. Our

understanding of vitreo-retinal interface, retinal architecture and choroidal morphology and its dynamics in different disease processes is evolving with the increasing amount of literature.

We assessed the structural changes in the choroid and retina based on the algorithm used by Keane et al [15] in patients with extramacular EDI-OCT scans. The authors have described the structural changes in the retina and choroid using extramacular EDI-OCT scans in patients with Birdshot retinochoroidopathy. Mahendradas et al have published qualitative features in uveitis using combined-depth imaging. Their study demonstrated structures seen in the conventional, EDI and CDI techniques in the posterior segment pathologies of various uveitis entities [17].

ICGA remains the gold standard investigation for imaging choroidal pathology and vascularity. However, due to its invasive nature, it is less preferred by uveitis specialists for imaging the posterior uveitis as a follow-up tool [18]. ICGA demonstrates hypofluorescent lesions in all types of posterior uveitis, and specific features on ICGA angiography signs have been demonstrated-described in different patterns of uveitis. However, there is no cross-sectional analysis of these ICGA angiography images, and the mechanism and quantification for of these hypofluorescent lesions is still under investigation [19]. OCT has been universally adopted by ophthalmologists as an essential tool in management and follow-up of uveitis [20-24]. Various attempts have been made to look-at-describe the detailed retinal, vitreoretinal and choroidal features using the advancements in this non-invasive modality [6,15,25,17]. The technology of EDI-OCT scan has revolutionised the method of assessment of choroidal characteristics in patients with retinal diseases and uveitis [9,21,26-31]. Imaging the choroid using OCT was challenging a

few years ago due to the attenuation of light signals by retinal pigment epithelium (RPE). Repositioning the OCT closer to the eye results in formation of an inverted mirror image with the choroid moving closer to the zero delay line replacing vitreous and giving a very high resolution image of the choroid on EDI-OCT scans [9]. During acquisition of OCT scans, the objects nearer the zero delay are imaged at the top of the screen and deeper objects are imaged further down on the screen. Images placed near the top of the display have greater detail than those lower in the display. Thus, it is imperative to remember that EDI-OCT has certain inherent limitations in imaging the inner retinal layers compared to the non-EDI mode. Changes towards the vitreous side, such as vitreoretinal interface abnormalities (ERM, vitreomacular tractions), vitreous inflammation, posterior vitreous pockets, and cystoid macular edema may be better imaged using the conventional non-EDI mode compared to the EDI-OCT.

Three patterns of macular edema are described in uveitis, namely focal, diffuse or cystoid [32]. The earlier the detection and treatment of macular edema, the more favourable the visual prognosis is for the patient as visual acuity improvement is more commonly seen in patients with macular edema of less than 6 months' duration [6].

Morphologically, two types of vitreous traction can develop in VMT: an incomplete V-shaped posterior vitreous detachment that leads to foveal retinal detachment, the surgical outcome of which is favourable, and partial posterior vitreous detachment temporal to the fovea in which prominent CME develops and which may result in a macular hole or macular atrophy postoperatively [33].

Epiretinal membrane is a common complication of uveitis that is associated with patient age, intermediate uveitis, posterior uveitis, panuveitis, male sex, and previous cataract surgery. In uveitis, OCT is more sensitive than fundus photography for identification of epiretinal membranes [34].

In the current study, we were able to demonstrate the focal and generalised loss of Ellipsoid zone in the retina in addition to the other known structural changes in posterior uveitis. We were also able to demonstrate the thinning of Sattler layer and generalised thinning of choroid in this heterogeneous group of posterior uveitis.

Discrete hyper-reflective foci, focal hypo-reflective spots ~~were~~ seen in 1/3rd of the patients both at baseline and follow-up. One quarter of the patients demonstrated generalised thickened choroid. There was no significant correlation of these characteristic features with disease activity and visual acuity.

Limitations of the study: The study was inherently limited due to its retrospective nature, and the small sample size. ~~The EDI-OCT images of posterior uveitis were obtained at different baseline levels and it was not essentially at the stage where there was no treatment instituted in the patients.~~ A good correlation of these features with visual acuity and disease activity could not be established due to limited number of eyes. Inter-rater agreement and inter-session agreement was not performed in this series to validate the results.

Conclusion: EDI-OCT is a useful tool in the further management of patients with posterior uveitis. The study highlights various qualitative parameters ~~as the possible tool~~ useful in monitoring the disease progression in posterior uveitis and can be explored further using a well-designed prospective study. Ophthalmologists should

be aware of the variety of retinal as well as choroidal morphological characteristics that can present on OCT in posterior uveitis.

Acknowledgement:

“The research was partially funded by the National Institute for Health Research (NIHR) Biomedical Research Centre at Moorfields Eye Hospital NHS Foundation Trust and UCL Institute of Ophthalmology”

Figure Legends

Figure 1: Optical Coherence Tomography (OCT) of a patient with active posterior uveitis shows presence of uveitic macular edema with cystoid spaces. **No specific diagnosis was made in this case with macular edema.**

Figure 2: (A) Optical Coherence tomography (OCT) scan of a patient with idiopathic posterior uveitis shows characteristic pockets of subretinal fluid. (B) OCT scan of another patient with idiopathic posterior uveitis demonstrates presence of outer retinal undulations and pockets of subretinal fluid.

Figure 3: Macular optical coherence tomography (OCT) scan of a patient with idiopathic panuveitis shows presence of intraretinal cystoid spaces.

Figure 4: Optical Coherence Tomography (OCT) of a patient with idiopathic panuveitis shows presence of discrete hyper-reflective foci in the outer retinal layers.

Figure 5: Raster scan of optical coherence tomography through a lesion of idiopathic posterior uveitis shows generalized loss of photoreceptor inner segment/outer segment junction (IS-OS junction) or Ellipsoid zone.

Figure 6 A-B: Optical Coherence tomography scan of a patient with idiopathic posterior uveitis shows presence of a choroiditis lesion associated with focal disruption of photoreceptor inner segment/outer segment junction (IS-OS junction) or Ellipsoid zone (A). Another raster scan demonstrates presence of an extramacular lesion associated with disruption of IS-OS junction or Ellipsoid zone (B).

Figure 7: Optical Coherence Tomography (OCT) demonstrates presence of a distinct hyper-reflective band in the inner retina suggestive of a thick epiretinal membrane.

Figure 8: Optical Coherence tomography (OCT) scan of a patient with active idiopathic panuveitis demonstrates generalized thickening of the choroid.

Figure 9 A-B: Optical Coherence tomography scan of a patient with idiopathic posterior uveitis demonstrates various morphological features identified in the choroidal layers. (A) There is presence of generalized choroidal thinning. Suprachoroidal space can be seen clearly beneath the large choroidal vessels. In addition, there is presence of focal hyporeflective spots in the choroid. (B) Another raster scan demonstrates presence of suprachoroidal space, generalized choroidal thinning and hyporeflective spots in the choroid.

Figure 10: Enhanced-depth imaging optical coherence tomography of a patient with idiopathic posterior uveitis demonstrates presence of discrete foci of hyper-reflective spots in the choroid.

Table 1: Inclusion Criteria

Criteria
Age >18years
Newly diagnosed Unilateral Posterior Uveitis or Panuveitis
No other co-existing retinal pathology like Diabetic Retinopathy, AMD, Vein Occlusion
Fellow eye with Normal Fundus Examination
Baseline and Follow-up on EDI-OCT available
Image quality good
Patient co-operative for slit lamp assessment and OCT examination
Exclusion of posterior scleritis, uveal reactive lymphoid hyperplasia or lymphoma.

Table 2: Qualitative changes on the Spectralis OCT in heterogeneous posterior or panuveitis:-

	Participants, No (%)	
	Baseline	Follow up
Retinal Morphologic Parameter		
Epiretinal membrane	3(15%)	3(15%)
Generalised thinning/ loss of architecture	2(10%)	4(20%)
Focal disruption of IS/OS junction or Ellipsoid zone	6(30%)	7(35%)
Discrete outer retinal hyperreflective foci	8(40%)	8(40%)
Generalised loss of IS/OS junction or Ellipsoid zone	2(10%)	2(10%)
Intraretinal cystoid spaces	4(20%)	4(20%)
Subretinal fluid	0(0%)	0(0%)
CMO	4(20%)	4(20%)
Choroidal Morphologic Parameter		
Thinning/ absence of Sattler Layer	2(10%)	3(15%)
Generalised thinning	3(15%)	4(20%)
Discrete hyperreflective foci	7(35%)	7(35%)
Focal hyporefective spots	6(30%)	6(30%)
Suprachoroidal hyporefective space	3 (15%)	2 (10%)
Generalised thickness	5(25%)	4(20%)

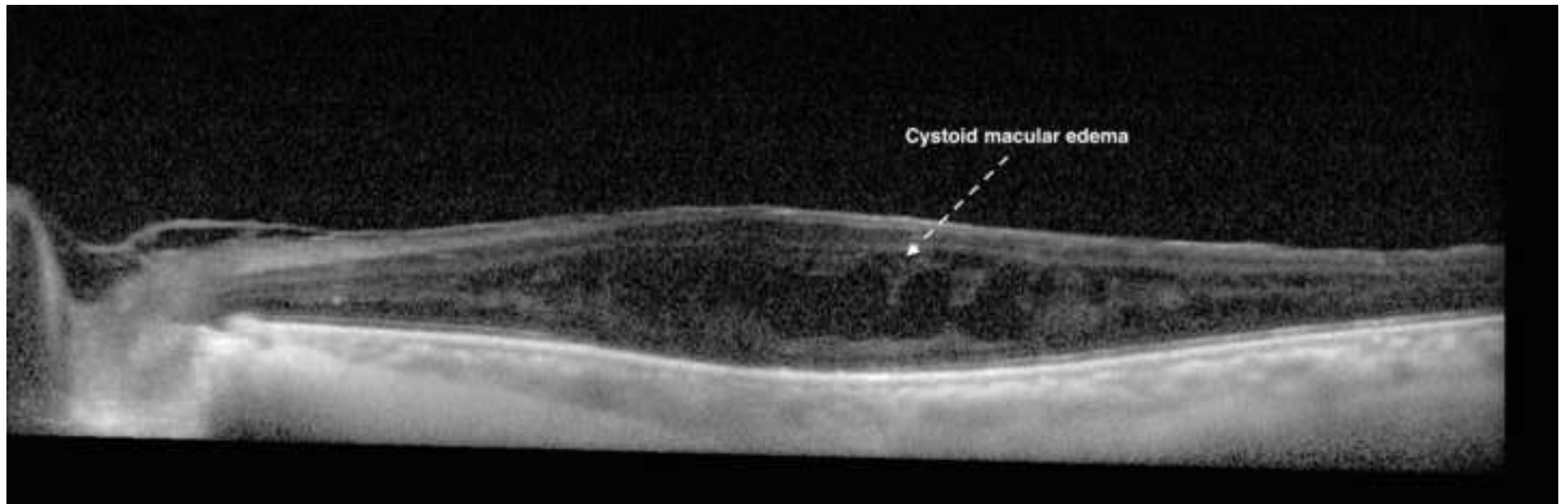
Fellow eyes (control group): None of the retinal or choroidal changes on EDI OCT scans as described above were observed in the fellow eyes.

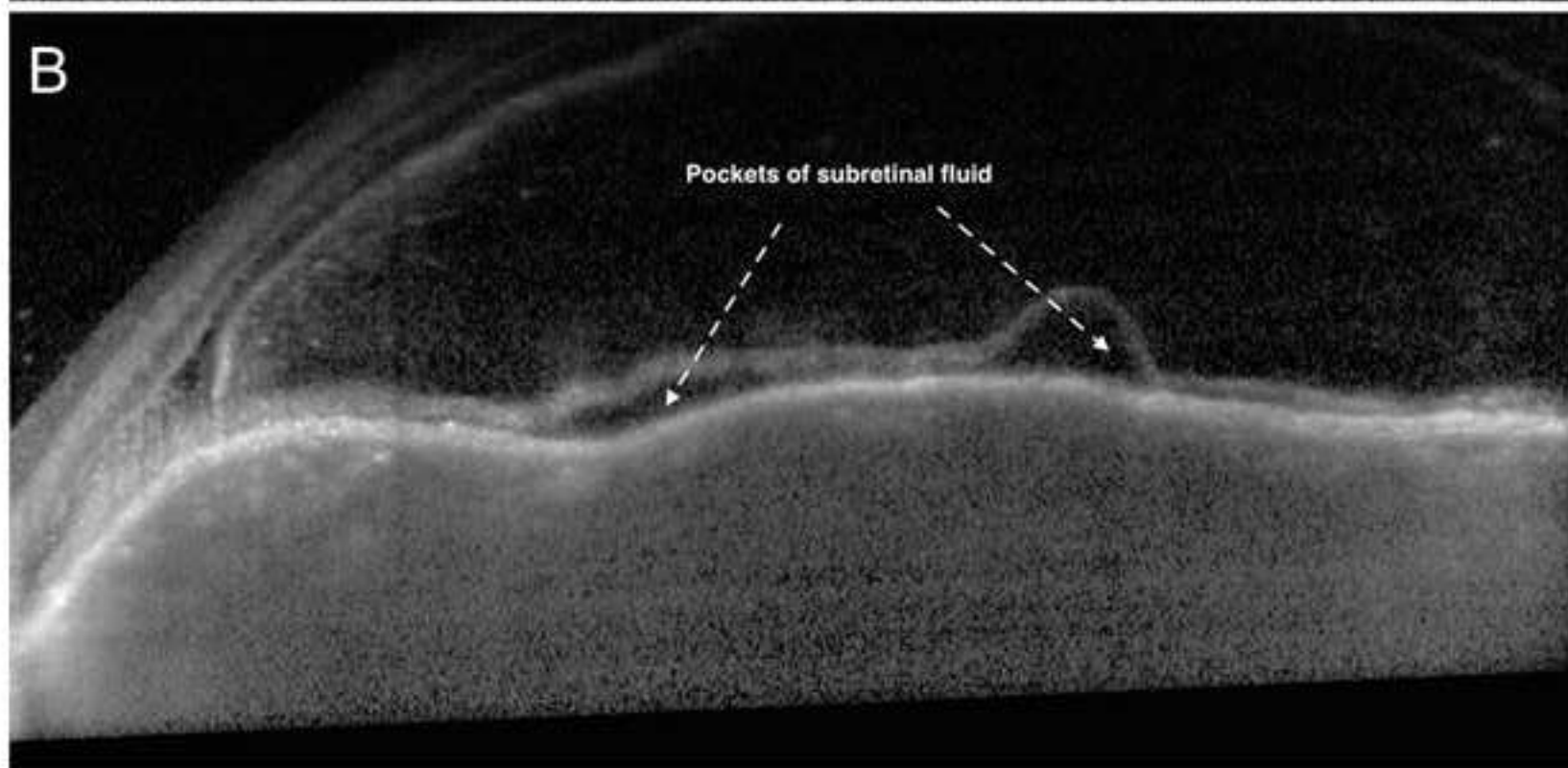
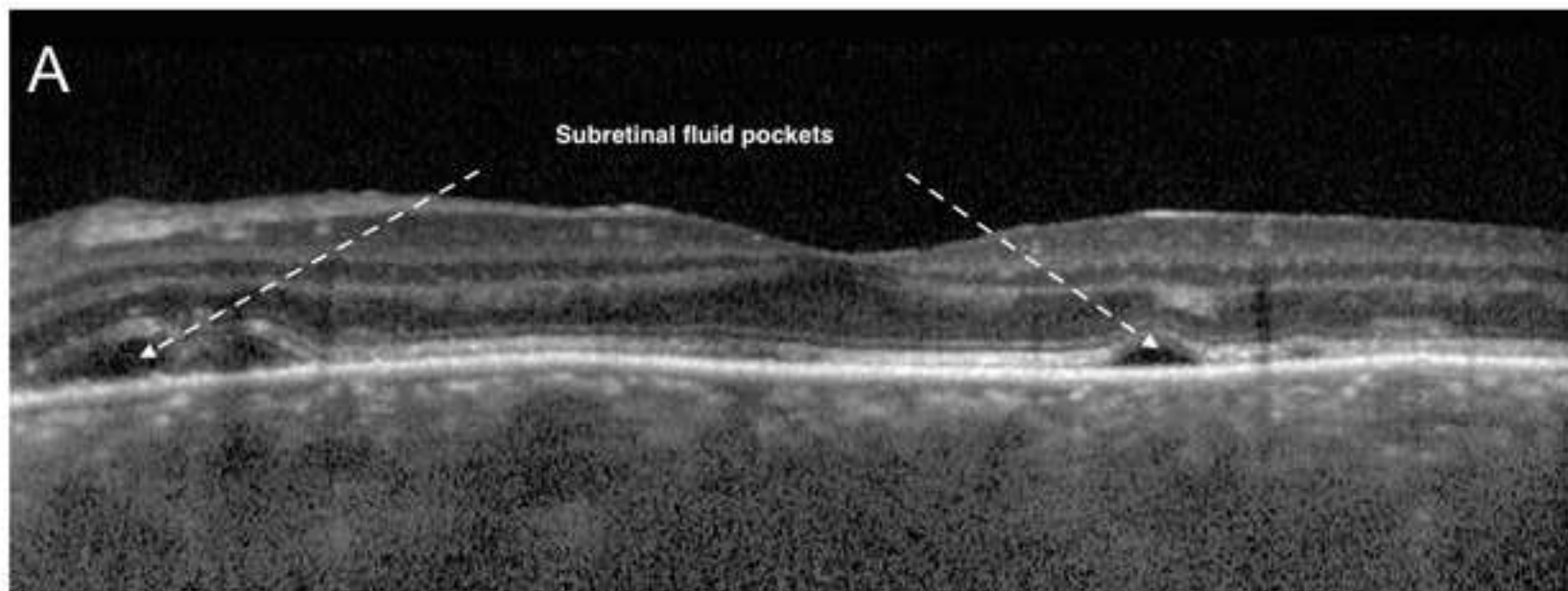
References

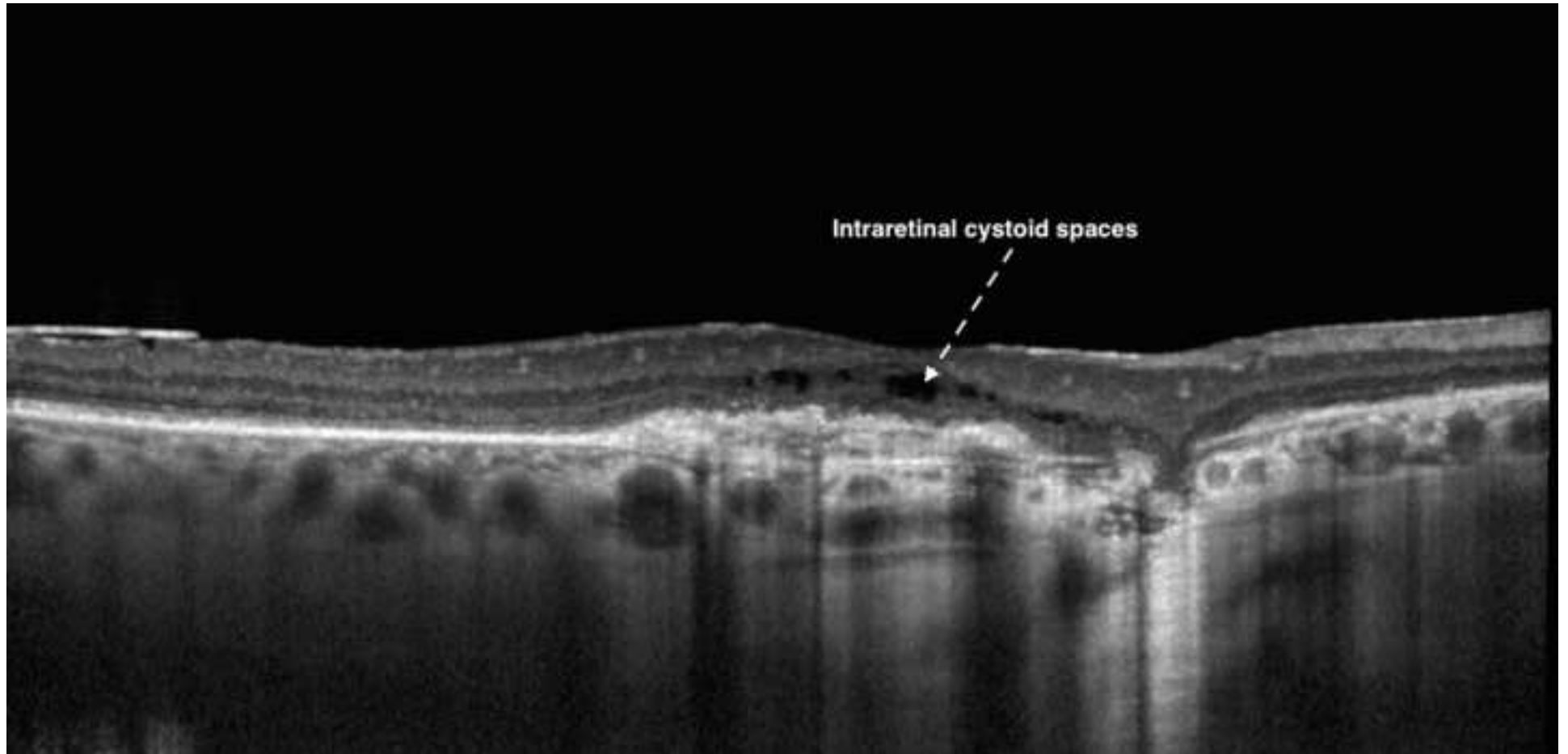
1. Forrester JV (2007) Intermediate and posterior uveitis. *Chemical immunology and allergy* 92:228-243. doi:10.1159/000099274
2. Henderly DE, Genstler AJ, Smith RE, Rao NA (1987) Changing patterns of uveitis. *American journal of ophthalmology* 103 (2):131-136
3. Pivetti-Pezzi P, Accorinti M, La Cava M, Colabelli Gisoldi RA, Abdulaziz MA (1996) Endogenous uveitis: an analysis of 1,417 cases. *Ophthalmologica Journal international d'ophtalmologie International journal of ophthalmology Zeitschrift fur Augenheilkunde* 210 (4):234-238
4. Baarsma GS (1992) The epidemiology and genetics of endogenous uveitis: a review. *Current eye research* 11 Suppl:1-9
5. Agrawal RV, Biswas J, Gunasekaran D (2013) Indocyanine green angiography in posterior uveitis. *Indian journal of ophthalmology* 61 (4):148-159. doi:10.4103/0301-4738.112159
6. Gallagher MJ, Yilmaz T, Cervantes-Castaneda RA, Foster CS (2007) The characteristic features of optical coherence tomography in posterior uveitis. *The British Journal of Ophthalmology* 91 (12):1680-1685. doi:10.1136/bjo.2007.124099
7. Campbell JP, Leder HA, Sepah YJ, Gan T, Dunn JP, Hatfeg E, Cho B, Ibrahim M, Bittencourt M, Channa R, Do DV, Nguyen QD (2012) Wide-field retinal imaging in the management of noninfectious posterior uveitis. *American journal of ophthalmology* 154 (5):908-911 e902. doi:10.1016/j.ajo.2012.05.019
8. Durrani K, Foster CS (2012) Fundus autofluorescence imaging in posterior uveitis. *Seminars in ophthalmology* 27 (5-6):228-235. doi:10.3109/08820538.2012.711414
9. Spaide RF, Koizumi H, Pozzoni MC (2008) Enhanced depth imaging spectral-domain optical coherence tomography. *American journal of ophthalmology* 146 (4):496-500. doi:10.1016/j.ajo.2008.05.032
10. Antcliff RJ, Stanford MR, Chauhan DS, Graham EM, Spalton DJ, Shilling JS, Ffytche TJ, Marshall J (2000) Comparison between optical coherence tomography and fundus fluorescein angiography for the detection of cystoid macular edema in patients with uveitis. *Ophthalmology* 107 (3):593-599
11. Gupta V, Gupta P, Singh R, Dogra MR, Gupta A (2008) Spectral-domain Cirrus high-definition optical coherence tomography is better than time-domain Stratus optical coherence tomography for evaluation of macular pathologic features in uveitis. *American journal of ophthalmology* 145 (6):1018-1022. doi:10.1016/j.ajo.2008.01.021
12. Gupta V, Gupta A, Gupta P, Sharma A (2009) Spectral-domain cirrus optical coherence tomography of choroidal striations seen in the acute stage of Vogt-Koyanagi-Harada disease. *American journal of ophthalmology* 147 (1):148-153 e142. doi:10.1016/j.ajo.2008.07.028
13. Birnbaum AD, Fawzi AA, Rademaker A, Goldstein DA (2014) Correlation between clinical signs and optical coherence tomography with enhanced depth imaging findings in patients with birdshot chorioretinopathy. *JAMA ophthalmology* 132 (8):929-935. doi:10.1001/jamaophthalmol.2014.877
14. Coskun E, Gurler B, Pehlivan Y, Kisacik B, Okumus S, Yayuspayi R, Ozcan E, Onat AM (2013) Enhanced depth imaging optical coherence tomography findings in Behcet disease. *Ocular immunology and inflammation* 21 (6):440-445. doi:10.3109/09273948.2013.817591
15. Keane PA, Allie M, Turner SJ, Southworth HS, Sadda SR, Murray PI, Denniston AK (2013) Characterization of birdshot chorioretinopathy using extramacular enhanced depth optical coherence tomography. *JAMA ophthalmology* 131 (3):341-350. doi:10.1001/jamaophthalmol.2013.1724
16. Pons ME, Garcia-Valenzuela E (2005) Redefining the limit of the outer retina in optical coherence tomography scans. *Ophthalmology* 112 (6):1079-1085. doi:10.1016/j.ophtha.2004.11.061

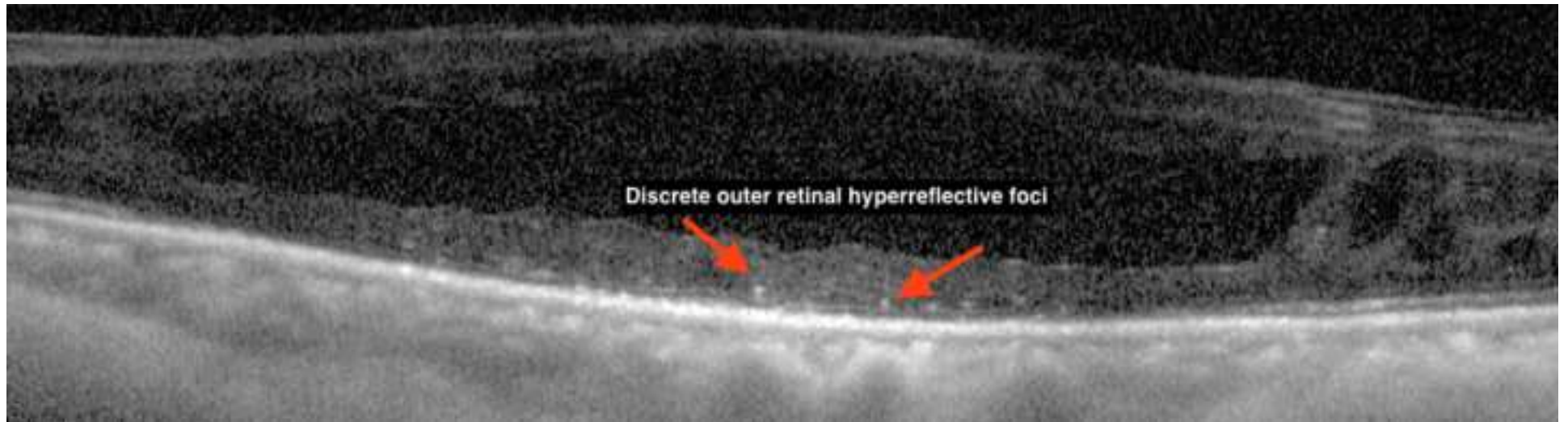
17. Mahendradas P, Madhu S, Kawali A, Govindaraj I, Gowda PB, Vinekar A, Shetty N, Shetty R, Shetty BK (2014) Combined depth imaging of choroid in uveitis. *Journal of ophthalmic inflammation and infection* 4 (1):18. doi:10.1186/s12348-014-0018-8
18. Howe LJ, Tufail A (2004) ICG angiography and uveitis. *Ocular immunology and inflammation* 12 (1):1-5
19. Herbort CP, LeHoang P, Guex-Crosier Y (1998) Schematic interpretation of indocyanine green angiography in posterior uveitis using a standard angiographic protocol. *Ophthalmology* 105 (3):432-440. doi:10.1016/s0161-6420(98)93024-x
20. Hunter RS, Skondra D, Papaliadis G, Sobrin L (2012) Role of OCT in the diagnosis and management of macular edema from uveitis. *Seminars in ophthalmology* 27 (5-6):236-241. doi:10.3109/08820538.2012.708813
21. Onal S, Tugal-Tutkun I, Neri P, C PH (2014) Optical coherence tomography imaging in uveitis. *International ophthalmology* 34 (2):401-435. doi:10.1007/s10792-013-9822-7
22. Pakzad-Vaezi K, Or C, Yeh S, Forooghian F (2014) Optical coherence tomography in the diagnosis and management of uveitis. *Canadian journal of ophthalmology Journal canadien d'ophtalmologie* 49 (1):18-29. doi:10.1016/j.jcjo.2013.10.005
23. Atas M, Yuvaci I, Demircan S, Guler E, Altunel O, Pangal E, Goktas A, Sutbeyaz S, Zararsiz G (2014) Evaluation of the Macular, Peripapillary Nerve Fiber Layer and Choroid Thickness Changes in Behcet's Disease with Spectral-Domain OCT. *Journal of ophthalmology* 2014:865394. doi:10.1155/2014/865394
24. Gehl Z, Kulcsar K, Kiss HJ, Nemeth J, Maneschg OA, Resch MD (2014) Retinal and choroidal thickness measurements using spectral domain optical coherence tomography in anterior and intermediate uveitis. *BMC ophthalmology* 14:103. doi:10.1186/1471-2415-14-103
25. Karampelas M, Sim DA, Keane PA, Zarranz-Ventura J, Patel PJ, Tufail A, Westcott M, Lee R, Pavesio CE (2013) Choroidal assessment in idiopathic panuveitis using optical coherence tomography. *Graefes' archive for clinical and experimental ophthalmology = Albrecht von Graefes Archiv fur klinische und experimentelle Ophthalmologie* 251 (8):2029-2036. doi:10.1007/s00417-013-2330-7
26. Mrejen S, Spaide RF (2012) Imaging the choroid in uveitis. *International ophthalmology clinics* 52 (4):67-81. doi:10.1097/IIO.0b013e318265f676
27. Spaide RF, Goldberg N, Freund KB (2013) Redefining multifocal choroiditis and panuveitis and punctate inner choroidopathy through multimodal imaging. *Retina (Philadelphia, Pa)* 33 (7):1315-1324. doi:10.1097/IAE.0b013e318286cc77
28. Sonoda S, Sakamoto T, Yamashita T, Shirasawa M, Uchino E, Terasaki H, Tomita M (2014) Choroidal structure in normal eyes and after photodynamic therapy determined by binarization of optical coherence tomographic images. *Investigative ophthalmology & visual science* 55 (6):3893-3899. doi:10.1167/iops.14-14447
29. Cui Y, Wang G, Li Y, Wang Y, Wang X, Bi H (2014) Optical coherence tomography and histopathology of macular uveitis. *Optometry and vision science : official publication of the American Academy of Optometry* 91 (11):1335-1342. doi:10.1097/OPX.0000000000000399
30. Ishikawa S, Taguchi M, Muraoka T, Sakurai Y, Kanda T, Takeuchi M (2014) Changes in subfoveal choroidal thickness associated with uveitis activity in patients with Behcet's disease. *The British journal of ophthalmology* 98 (11):1508-1513. doi:10.1136/bjophthalmol-2014-305333
31. Behdad B, Rahmani S, Montahaei T, Soheilian R, Soheilian M (2015) Enhanced depth imaging OCT (EDI-OCT) findings in acute phase of sympathetic ophthalmia. *International ophthalmology* 35 (3):433-439. doi:10.1007/s10792-015-0058-6
32. Markomichelakis NN, Halkiadakis I, Pantelia E, Peponis V, Patelis A, Theodossiadi P, Theodossiadi G (2004) Patterns of macular edema in patients with uveitis: qualitative and quantitative assessment using optical coherence tomography. *Ophthalmology* 111 (5):946-953. doi:10.1016/j.ophtha.2003.08.037

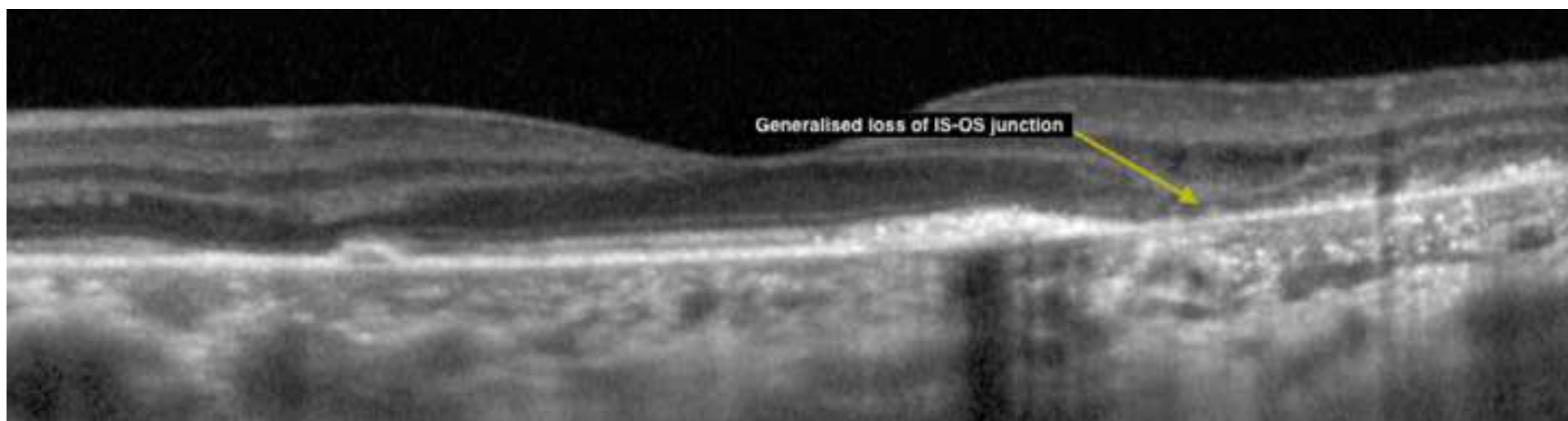
33. Yamada N, Kishi S (2005) Tomographic features and surgical outcomes of vitreomacular traction syndrome. *American journal of ophthalmology* 139 (1):112-117. doi:10.1016/j.ajo.2004.08.055
34. Nicholson BP, Zhou M, Rostamizadeh M, Mehta P, Agron E, Wong W, Wiley H, Nussenblatt R, Sen HN (2014) Epidemiology of epiretinal membrane in a large cohort of patients with uveitis. *Ophthalmology* 121 (12):2393-2398. doi:10.1016/j.ophtha.2014.06.015

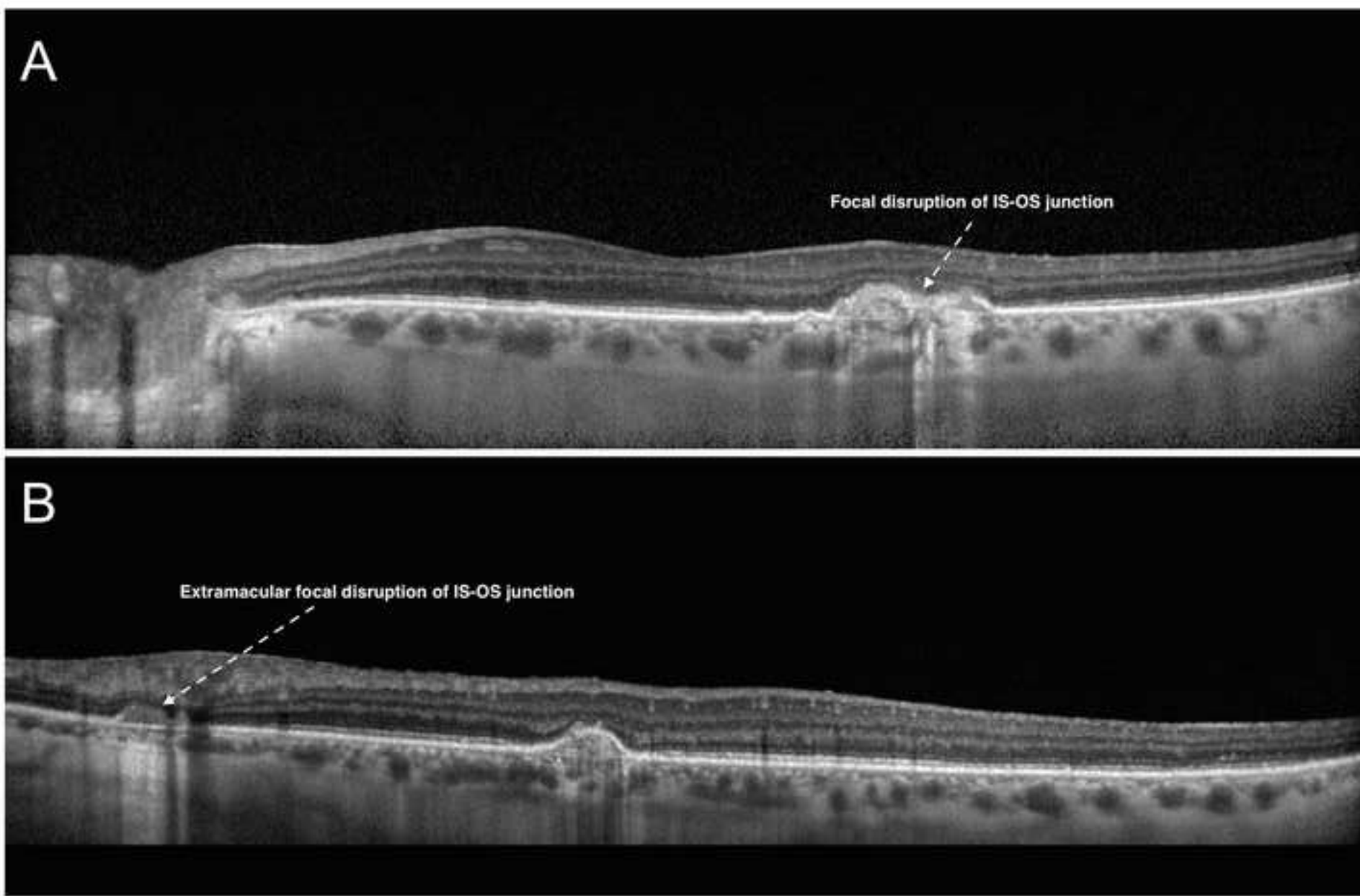


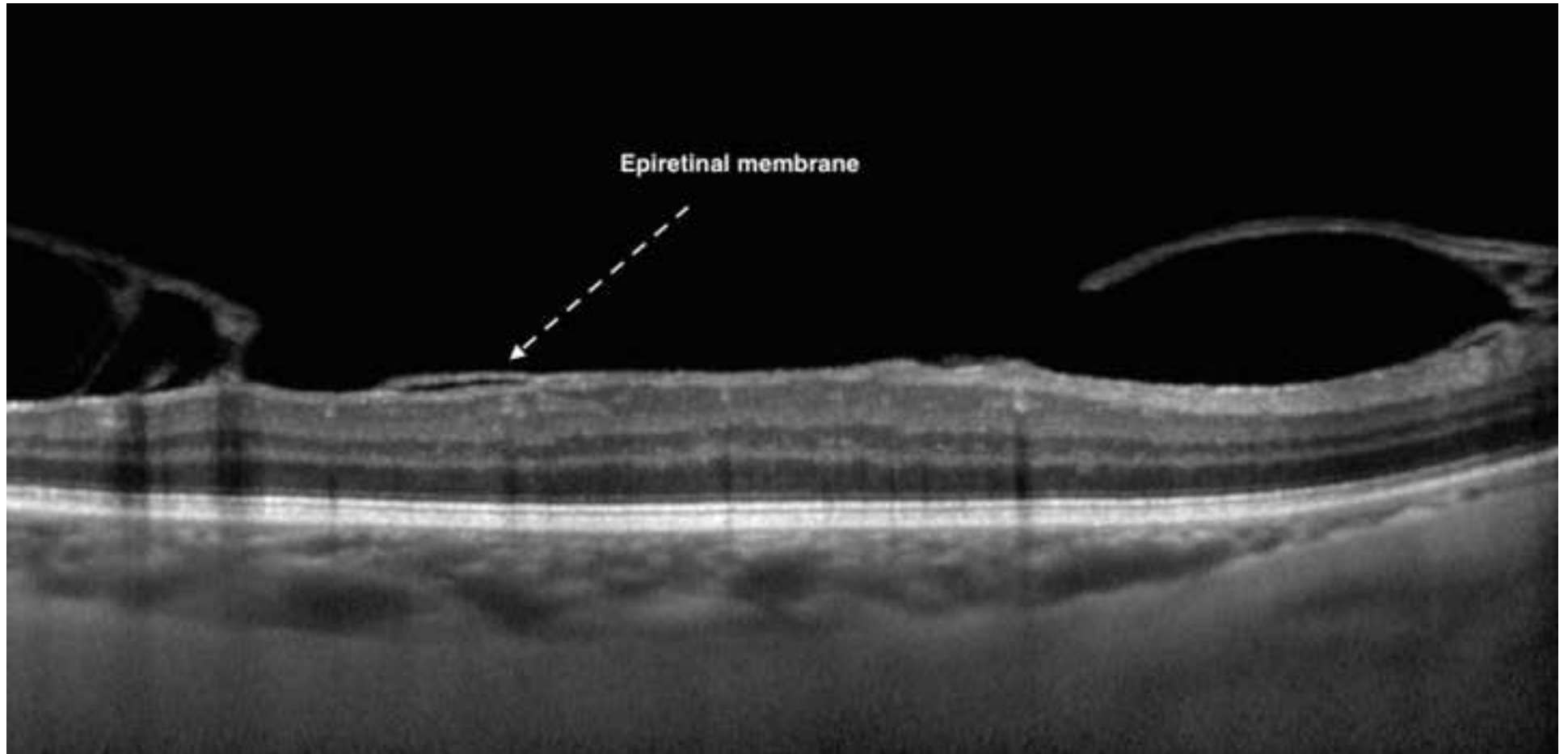


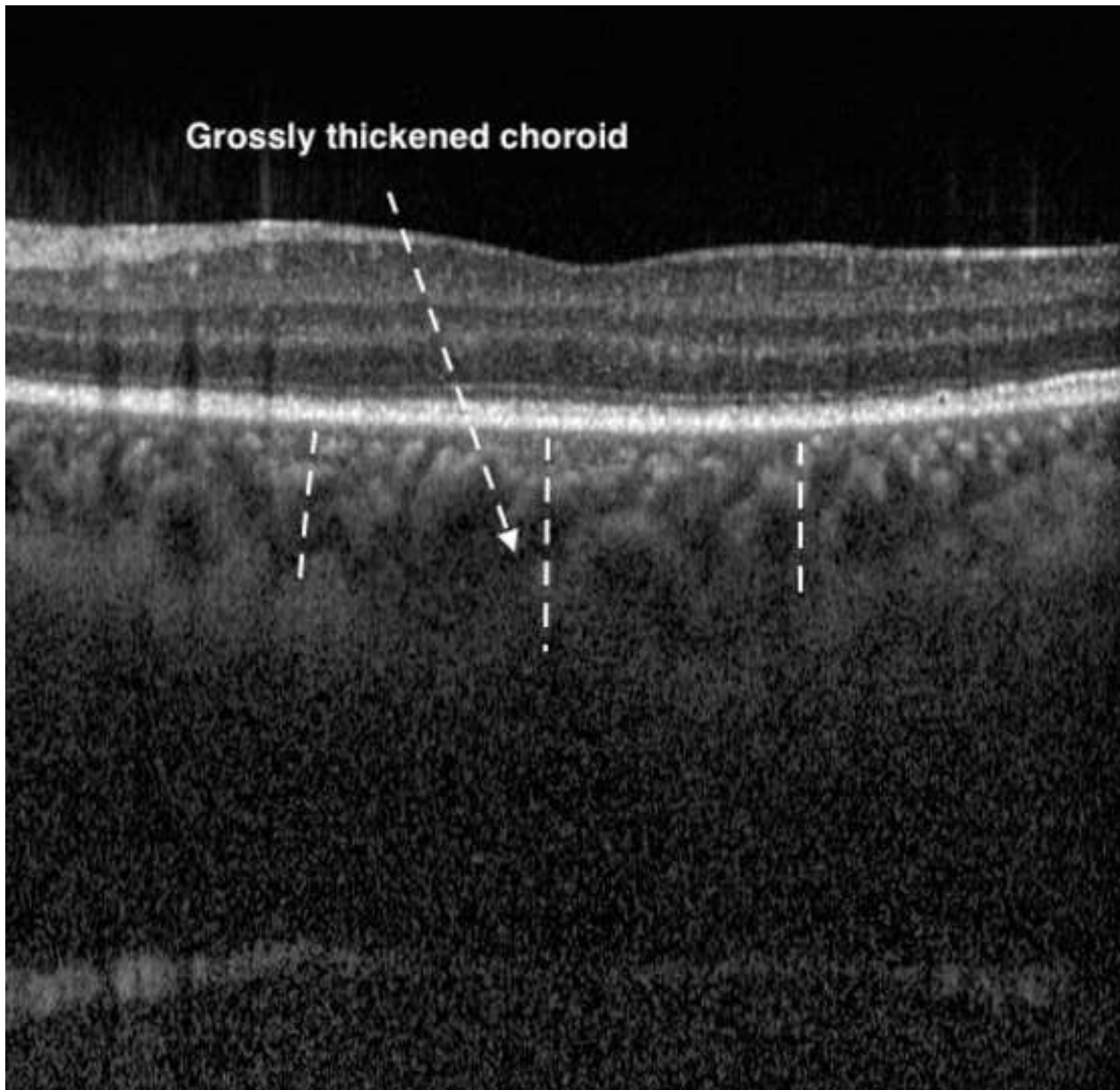


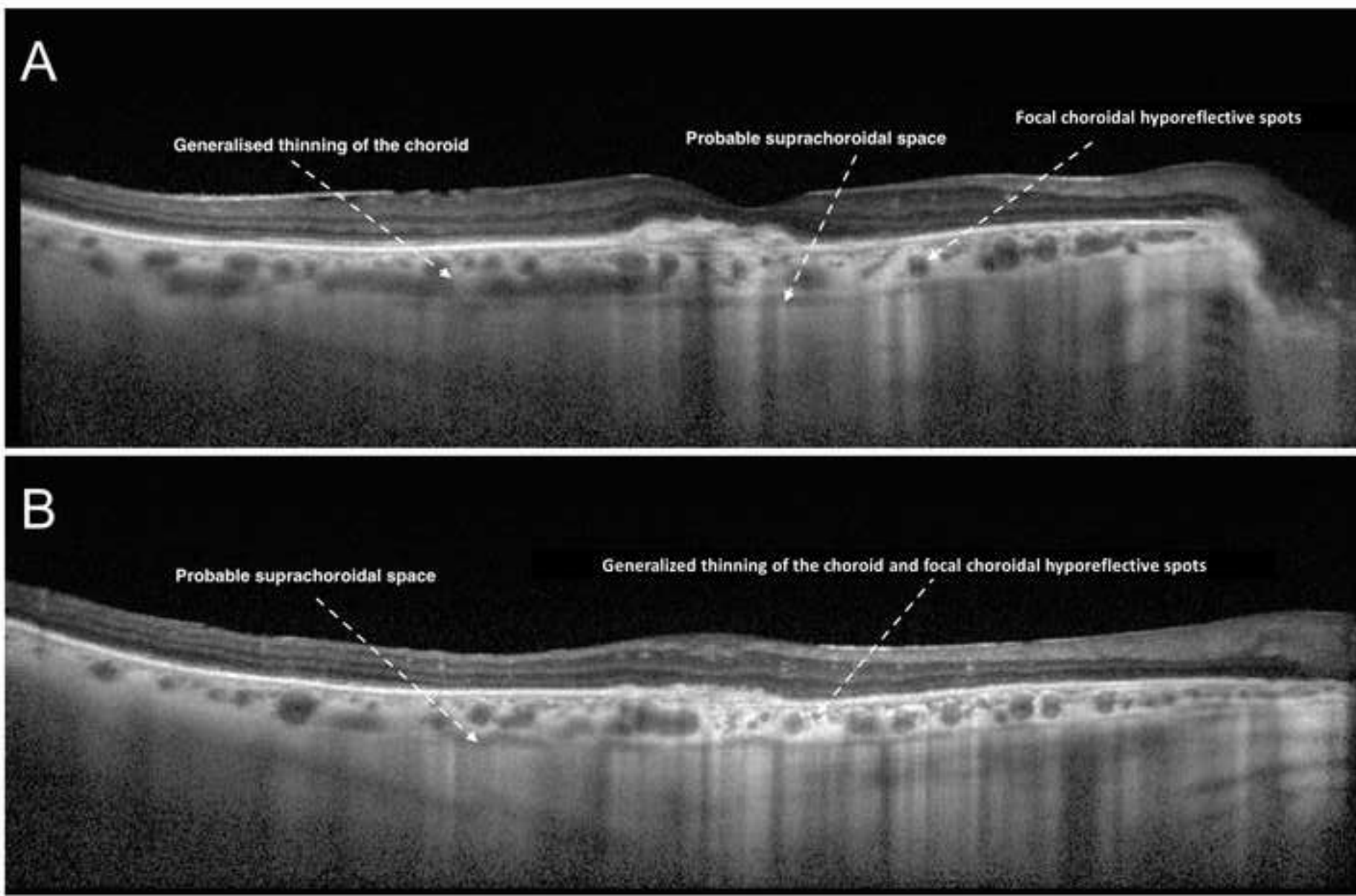


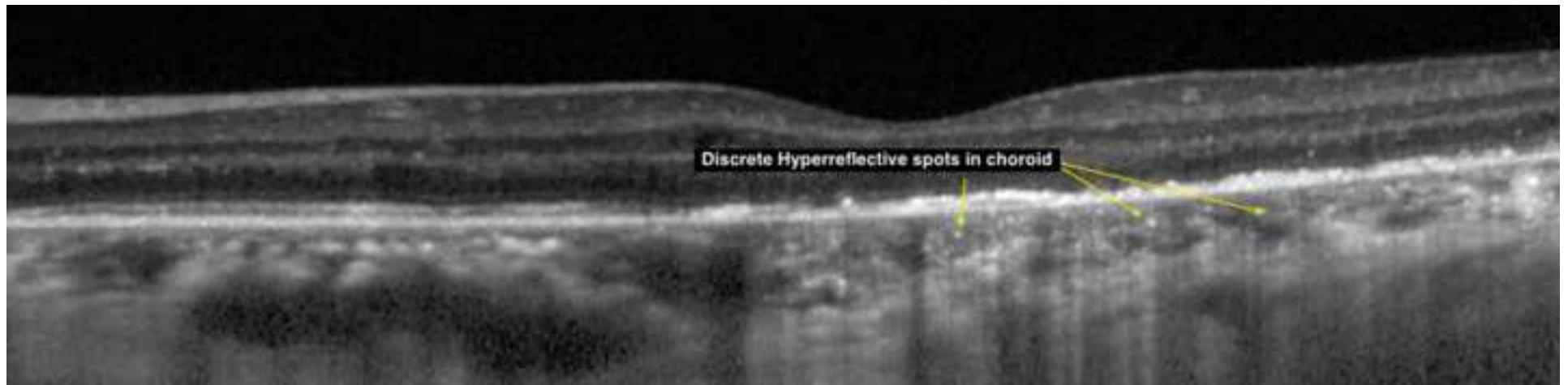













Click here to access/download

Supplementary Material

MORPHOMETRIC CHANGES IN CHOROID IN
UVEITIS.xlsx

