

Diagnostic accuracy of MRI and additional [¹⁸F]FDG-PET for behavioral variant frontotemporal dementia in patients with a late onset frontal lobe syndrome

Vijverberg EGB MD^{1,2}, Wattjes MP MD, PhD³, Dols A MD, PhD⁴, Krudop WA MD¹, Möller C MSc^{1,5}, Peters A MSc¹, Kerssens CJ MD⁴, Gossink F MD⁴, Prins ND MD, PhD¹, Stek ML MD, PhD⁴, Scheltens P MD, PhD¹, van Berckel BNM MD, PhD⁶, Barkhof F MD, PhD³, Pijnenburg YAL MD, PhD¹

¹ Alzheimer Centre and Department of Neurology, Neuroscience Campus Amsterdam, VU University Medical Centre, Amsterdam, The Netherlands

² Department of Neurology, Haga Ziekenhuis, The Hague, The Netherlands

³ Department of Radiology & Nuclear Medicine, VU University Medical Centre, Amsterdam

⁴ The Netherlands Department of Old Age Psychiatry, GGZ InGeest, Amsterdam, The Netherlands

⁵ Leiden Institute for Brain and Cognition (LIBC), Institute of Psychology, Leiden University

⁶ Department of Nuclear Medicine & PET research, VU University Medical Centre, Amsterdam, The Netherlands

Corresponding author:

Everard.G.B. Vijverberg, MD

Alzheimer Centre and Department of Neurology

VU University Medical Center

P.O. Box 7057

1007 MB, Amsterdam,

The Netherlands. E.Vijverberg@vumc.nl

Telephone: +31204440183

Fax: +3120444852

e-mail: E.Vijverberg@vumc.nl

Figures and tables

1 figure

3 tables

Word count abstract: 349

Total word count text: 3048

References: 50

Authors' contributions

Vijverberg had full access to all of the data in the study and takes responsibility for the integrity of the data and the accuracy of the data analysis. *Study concept and design:* Vijverberg, Dols, Barkhof and Pijnenburg; *Acquisition of data:* Vijverberg, Krudop, Gossink, Peters, Möller, Wattjes, Barkhof, van Berckel *Analysis and interpretation of data:* Vijverberg, Wattjes, van Berckel, Barkhof and Pijnenburg ; *Drafting of the manuscript:* Vijverberg and Pijnenburg; *Critical revision of the manuscript for important intellectual content:* Wattjes, Dols, , Krudop, Möller, Peters, Kerssens, Gossink, Prins, Stek, Scheltens, van Berckel, Barkhof, Pijnenburg; *Statistical analysis:* Vijverberg; *Obtained funding:* Scheltens, Pijnenburg; *Administrative, technical and material support:* Pijnenburg; *Study supervision:* Pijnenburg.

Disclosures

Everard G.B. Vijverberg reports no disclosures.

Dr. Mike P. Wattjes

Dr. Anniemiek Dols

Welmoed A. Krudop

Dr. Christiane C. Möller

Anne Peters

C J. Kerssens

Flora Gossink

Dr. Niels D. Prins

Prof. Dr. Max L. Stek

Prof. Dr. Philip Scheltens serves/has served on the advisory boards of Genentech, Novartis, Roche, Danone, Nutricia, Lilly, and Lundbeck. He has been a speaker at symposia organized by Lundbeck, Merz, Danone, Novartis, Roche, GE, and Genentech. For all his activities he receives no personal compensation.

Prof. Dr. van Berckel

Prof. Dr. Frederik Barkhof serves/has served on the advisory boards of Bayer-Schering Pharma, Sanofi-Aventis, Biogen Idec, UCB, Merck-Serono, Novartis, and Roche. He received

funding from the Dutch MS Society and has been a speaker at symposia organized by the Serono Symposia Foundation.

Dr. Yolande A.L. Pijnenburg received a personal fellowship form the Dutch brain foundation.

Abstract

Importance: Neuroimaging has recently been incorporated in the clinical diagnostic criteria for behavioral variant frontotemporal dementia (bvFTD). Although neuroimaging has a reasonable accuracy to differentiate bvFTD from other neurodegenerative disorders, its value for the differentiation of bvFTD among subjects with an acquired frontal lobe syndrome is unknown.

Objective: to determine the diagnostic accuracy of MRI, additional [¹⁸F]FDG-PET, and their combination for bvFTD.

Design: The late-onset frontal lobe syndrome (LOF) study is a prospective cohort study with a symptom based inclusion and 2 years of clinical, radiological and neuropsychological follow-up. Radiological reviewers were blinded to the clinical diagnosis.

Setting: multi-center, memory clinics

Participants: Participants were aged 45-75 years. Out of 137 patients included at baseline, a follow-up diagnosis was available in 116. At baseline 111 patients had a brain MRI scan and 74 patients underwent additional [¹⁸F]FDG-PET. They were classified as having probable/definite bvFTD or a non-bvFTD diagnosis after 2 years of follow-up.

Main Outcome and Measure: MRIs and [¹⁸F]FDG-PET scans were visually rated on frontal and/or anterior temporal changes at baseline, and were classified to be consistent with FTD or not. The follow-up diagnosis was used as the gold standard to calculate sensitivity and specificity for baseline neuroimaging.

Results: 27 patients had *probable/definite* bvFTD and 84 patients had a non-bvFTD diagnosis (psychiatric diagnosis or other neurological disorders). MRI had a sensitivity of 70% (95% CI 52-85%) with a specificity of 93% (95% CI 86-97%). [¹⁸F]FDG-PET had a sensitivity of 90% (95% CI 66-100%) with a specificity of 68% (95% CI 56-79%). The sensitivity of combined neuroimaging was 96% (95% CI 85-100%) with a specificity of 73% (95% CI 63-81%). In 75% of the genetic FTD cases, MRI lacked typical frontotemporal atrophy. 40% of cases with a false positive [¹⁸F]FDG-PET scan had a psychiatric diagnosis.

Conclusions and Relevance: A good diagnostic accuracy was found for MRI and additional [¹⁸F]FDG-PET for bvFTD in a late-onset frontal lobe syndrome cohort. Caution with the interpretation of neuroimaging results should especially be taken in cases with a genetic

background and in cases with a psychiatric differential diagnosis where [¹⁸F]FDG-PET is the only abnormal investigation.

Introduction

In clinical practice, behavioral variant frontotemporal dementia (bvFTD) has a broad and heterogeneous differential diagnosis including both neurodegenerative diseases and psychiatric disorders. Identifying the specific cause of a late-onset frontal lobe syndrome represents a major challenge¹⁻³ and will be increasingly important when disease-specific treatments become available.

As described in the international consensus criteria for bvFTD (FTDC), the presence of frontotemporal abnormalities on neuroimaging is considered as a biomarker for bvFTD, and is mandatory for the diagnosis *probable* bvFTD⁴. However, the diagnostic accuracy of magnetic resonance imaging (MRI) and ([¹⁸F]-fluorodeoxyglucose-positron emission tomography ([¹⁸F]FDG-PET) for bvFTD varies across different studies⁵⁻⁹. Generally, these studies have measured the diagnostic accuracy of frontotemporal changes on neuroimaging for bvFTD among cohorts of patients with neurodegenerative disorders.

Several studies have reported changes in frontotemporal regions on MRI and [¹⁸F]FDG-PET-scan in mood disorders and schizophrenia, psychiatric disorders that may also present with a frontal lobe syndrome¹⁰⁻¹⁴. This might affect the diagnostic accuracy of neuroimaging for bvFTD. In other words, the value of neuroimaging for the differentiation of bvFTD among subjects with an acquired frontal lobe syndrome is unknown.

Therefore, the aim of this study was to measure the diagnostic accuracy of MRI and additional [¹⁸F]FDG-PET for bvFTD in a large and clinically relevant cohort, consisting of subjects with a late-onset frontal lobe syndrome¹⁵.

Methods

Patients

We selected patients of the Late Onset Frontal lobe (LOF) study, which is a multi-center observational and prospective follow-up study¹⁶. In the LOF study 137 patients were prospectively included with a presentation of behavioral changes consisting of apathy, disinhibition, and/or compulsive/stereotypical behavior emerging between 45 and 75 years of age. The patients had been referred to the VUMC Alzheimer Center and the Department of Old Age Psychiatry of the GGZInGeest, Amsterdam, the Netherlands, between April 2011 and June 2013¹⁷. Patients were included in the study when behavioral complaints dominated the presentation and when they had a score of ≥ 11 on the Frontal Behavioural Inventory (FBI)¹⁸ or a score of ≥ 10 on the Stereotypy Rating Inventory (SRI)¹⁹. All patients underwent full neurological and psychiatric examination at baseline and at two-year-follow-up. Cognitive screening tests included the Mini Mental State Examination (MMSE)²⁰ and the Frontal Assessment Battery (FAB)²¹. Additional information of the assessment is described in the LOF study design¹⁶. The local institutional review board approved this study and a written informed consent was obtained from all participants.

Neuroimaging

All patients underwent a brain MR (3T Signa HDxt whole-body MRI system GE Medical Systems Milwaukee, WI, USA) using an 8-channel head coil with foam padding to restrict head motion. Image acquisition included an established standard MRI protocol for memory clinic patients [17]. A sagittal 3D heavily T1-weighted gradient-echo sequence with coronal reformats, a sagittal 3D T2-weighted fluid-attenuated inversion-recovery (FLAIR) fast spin-echo with axial reformats, a transverse T2-weighted fast spin-echo, a transverse T2* susceptibility sequence, and diffusion weighted imaging/EPI. All sequences were performed using 3mm slices/reformats with 1 mm in-plane resolution and provided whole brain coverage¹⁷. An experienced neuroradiologist (FB or MPW), unblinded for the study design but blinded to the patients' symptoms and medical history, evaluated the images with respect to global cortical atrophy (GCA), medial temporal lobe atrophy (MTA), and white matter hyperintensities (Fazekas) according to established and validated visual rating scales²²⁻²⁴. In

addition, they classified the imaging findings based on frontal and/or anterior temporal atrophy on MRI to be consistent with FTD or not.

In case of normal MRI findings or doubt on the interpretation of the abnormalities being explanatory for the behavioral changes, an [¹⁸F]FDG-PET-scan was made. [¹⁸F]FDG-PET-scans were made on an ECAT EXACT HR+ scanner (Siemens/CTI, Knoxville, USA). 185 MBq [¹⁸F]FDG was injected after subjects rested for ten minutes with minimal noise and eyes closed in a dimly lit room. PET scans were acquired 45 minutes after injection during fifteen minutes (3 frames of 5 minutes). [¹⁸F]FDG-PET-scans were assessed visually and interpreted by an experienced nuclear medicine physician (BB) on frontal and/or anterior temporal hypometabolism based on the summed images of all the frames, unblinded for the study design and blinded to the patients' symptoms, complaints and medical history.

Diagnostic procedure

A consensus diagnosis between the neurologist and the psychiatrist was made based upon the relevant clinical information and additional investigations, including results of CSF biomarkers, MRI and [¹⁸F]FDG-PET at baseline. All patients with a positive family history for early-onset dementia were referred for clinical genetic counseling. If deemed appropriate, genetic screening included the MAPT, GRN, PSEN1, and APP genes. In all subjects of whom DNA was available (n=137) C9orf repeat expansion was tested. After two years of follow-up, neuropsychiatric examination, neuropsychological examination and the brain MRI were repeated, followed by establishment of the final multidisciplinary diagnosis. Based on the follow-up diagnosis, patients were divided into two groups: having bvFTD (defined as *probable* and *definite* bvFTD) or not having bvFTD (non-bvFTD). All *probable* bvFTD patients at follow-up had neuroimaging consistent with FTD. Subsequently the sensitivity and specificity of the baseline MRI and additional [¹⁸F]FDG-PET were calculated, using the follow-up diagnosis as the gold standard. From the original LOF cohort of 137 cases, a total of 26 patients were excluded. Three patients were excluded from the final analysis with a two-year follow-up diagnosis of *possible* bvFTD, whereas three patients died without post mortem verification or a clear clinical diagnosis. Fifteen patients were lost to follow-up, whereby most

of these participants withdrew from the study. Five cases were excluded based on insufficient quality of their baseline MRI that had been performed elsewhere.

Statistical analysis

Data analysis was performed using IBM SPSS statistics version 20.0 (IBM SPSS Statistics, Armonk, NY). Independent samples t-test for continuous measures, Chi-square tests for categorical variables and Mann-Whitney *U* test for variables that are not normally distributed were performed to compare age, gender, duration of onset symptoms at presentation, education in years, MMSE, FAB, FBI and SRI between the 2 groups. MRI visual rating scores comparison was done with the Chi-square test for trend. Sensitivities and specificities for the MRI scans of the brain and [¹⁸F]FDG-PET-scans were calculated with cross tables with 95% confidence interval. The statistical significance was set to p-value <0.05.

Results

Clinical and demographical characteristics

The two-year-follow-up multidisciplinary diagnoses consisted of *probable/definite* bvFTD in 27 patients (24%) and non-bvFTD in 84 patients. Of the 27 patients in *probable/definite* bvFTD group, 4 patients were diagnosed with *definite* bvFTD consisting of two C9orf72 hexanucleotide repeat expansion, one progranulin mutation and a histopathological-confirmed tauopathy. The non-bvFTD group consisted of patients diagnosed with other types of dementia (n=28, 25%), psychiatric disorders (n=44, 40%) and other neurological diseases (n=12, 11%). The most common neurodegenerative diagnoses were Alzheimer's disease (n=7), vascular cognitive impairment (n=6), progressive supranuclear palsy (n=4) and dementia with Lewy bodies (n=4). The most common psychiatric diagnoses were major depression (n=11) and bipolar disorder (n=6). Other neurological disorders were Parkinson's disease (n=2), multiple sclerosis (n=2), histopathologically-confirmed limbic encephalitis (n=1) and post-anoxic encephalopathy (n=1). Their clinical and demographical characteristics are shown in table 1. The patients with bvFTD diagnosis after two-year-follow-up were more often male and presented more often with stereotypical symptoms than the non-bvFTD group.

Procedure neuroimaging

The included 111 cases all underwent an MRI scan at baseline and 74 cases underwent additional [¹⁸F]FDG-PET-scan. Of the 74 cases with a additional [¹⁸F]FDG-PET-scan, nine cases had MRI scans with borderline abnormalities consistent with bvFTD, whereas 64 were considered as inconclusive (no abnormalities). Of the 37 patients without an [¹⁸F]FDG-PET-scan, sixteen MRI scans showed abnormalities consistent with bvFTD, and in nineteen cases the MRI findings were inconclusive, however the patient refused or there were technical problems with the [¹⁸F]FDG-PET-scanner. In two patients the MRI scan showed findings suggestive of an alternative clinical diagnosis (Multiple sclerosis and vascular cognitive impairment (VCI)).

Neuroimaging for probable/definite bvFTD

Of the 27 patients with a diagnosis of probable/definite bvFTD at two-year-follow-up, 19 patients had MRI features consistent with bvFTD at baseline and ten patients revealed frontotemporal hypometabolism on the additional [¹⁸F]FDG-PET-scan at baseline. Of these ten patients, eight patients showed no clear abnormalities on MRI at baseline and these were considered as inconclusive. Two out of the 27 patients with probable/definite bvFTD at two-year-follow-up had abnormalities consistent with bvFTD on MRI and on [¹⁸F]FDG-PET at baseline. The MRI visual ratings scores at baseline are described in table 2, showing a significantly higher MTA and GCA scores in bvFTD compared to the non-FTD group. Overall, predominant of changes on MRI and the additional [¹⁸F]FDG-PET on the right side of the brain were found and more often in the temporal lobe than in the frontal lobe.

Sensitivity and specificity of MRI and additional [¹⁸F]FDG-PET-scan

The sensitivity of frontotemporal atrophy on the baseline MRI for bvFTD was 70% (95% CI 52-85%) and the specificity was 93% (95% CI 86-97%). This yielded positive and negative predictive values of 76% (95% CI 57-90%) and 91% (95% CI 84-96%). The sensitivity for the additional [¹⁸F]FDG-PET-scan at baseline was 90% (95% CI 66-100%) and the specificity 68% (95% CI 56-79%). This yielded positive and negative predictive values of 33% (95% CI 18-51%) and 98% (95% CI 90-100%). The sensitivity of combined neuroimaging in bvFTD, MRI and additional [¹⁸F]FDG-PET-scan together, was 96% (95% CI 85-100%) and the specificity was 73% (95% CI 63-81%). The positive and negative predictive values of neuroimaging in a frontal lobe syndrome cohort for bvFTD were 53% (95% CI 40-67%) and 98% (95% CI 93-100%).

False negative cases

Eight patients showed no frontotemporal atrophy on the MRI at baseline, but were diagnosed with probable/definite bvFTD at two-year-follow-up. Among these patients, 3 patients were diagnosed with *definite* bvFTD; the first patient had a progranulin mutation with asymmetric atrophy in the right temporoparietal region on the MRI, reported as more consistent with AD. Another patient with a C9orf72 hexanucleotide repeat showed mild hippocampus atrophy only

on the left side (MTA grade 1) and no global atrophy (See figure 1C). The third patient with autopsy-based *definite* bvFTD, had generalized frontoparietal atrophy (GCA grade 1) and asymmetric atrophy of the temporal lobe right more than left, reported also more consistent with AD. In three patients (75%) with *probable* bvFTD, the neuroradiologist reported that the MRI was more consistent with another type of dementia (AD or VCI). For [¹⁸F]FDG-PET, one patient diagnosed with *probable* bvFTD had no hypometabolism on the [¹⁸F]FDG-PET-scan at baseline.

False-positive cases

Six patients of the non-FTD group demonstrated frontotemporal atrophy on the baseline MRI. These patients had bipolar disorder (n=2), Parkinson's disease (n=1), post-anoxic encephalopathy (n=1), semantic dementia (SD) (n=1) and behavioral changes due to relational problems. This group had predominantly low visual rating scores at baseline in the frontal and temporal regions; a description is shown in table 2. Twenty patients with frontal, anterior temporal or frontotemporal hypometabolism on the baseline [¹⁸F]FDG-PET-scan were diagnosed with a different disorder than probable/definite bvFTD. This group consisted of twelve patients with a psychiatric disorder; the most common alternative diagnosis was major depressive disorder (n=4) (MDD) (see figure 1A). These patients with psychiatric disorders had mainly decreased uptake in the frontal and temporal lobe, mostly bilaterally. Some patients also showed parietal hypometabolism mainly on the right side. Six patients were diagnosed with dementia other than bvFTD, including patients with Alzheimer disease (n=1), semantic dementia (SD) (n=3), progressive supranuclear palsy (PSP) (n=1) and cortical basal syndrome (CBS) (n=1). In this group the [¹⁸F]FDG-PET-scans showed mainly bilateral frontotemporal hypometabolism. Diagnoses at two-year-follow-up for patients with positive neuroimaging consistent with findings in bvFTD are presented in table 3.

Discussion

We found a sensitivity of frontotemporal changes on MRI for bvFTD of 70% with a specificity of 93%. The additional [¹⁸F]FDG-PET, when the MRI was inconclusive, had a sensitivity of 90% at the cost of a lower specificity of 68%. The combination of MRI and [¹⁸F]FDG-PET-scan, had a sensitivity of 96% and a specificity of 73%.

The current study found a moderate sensitivity for frontotemporal changes on MRI for bvFTD. This finding is predominately driven by the absence of structural abnormalities on baseline MRI in patients with *probable* bvFTD²⁵. Moreover, 3 cases with a known pathogenic mutation had atypical findings on MRI.^{26,27} In a previous study including post-mortem confirmed FTD cases, it was found that only 50% of the patients with FTD had abnormalities on the MRI at presentation^{6,8}. One study among patients with a C9orf72 hexanucleotide repeat expansion reported a very low sensitivity of 13% for frontotemporal changes on MRI²⁸. Our results seem to be more consistent with a sensitivity of 72% of MRI in a different cohort of patients carrying a C9orf72 hexanucleotide repeat expansion²⁹ and a sensitivity of 75% in clinically defined bvFTD³⁰. Overall, the sensitivity for MRI abnormalities varies and is moderate in different studies. Our findings suggest that the current clinical consensus criteria for bvFTD might be modified, and include the atrophy patterns described in known pathogenic mutations. Furthermore, the absence of atrophy on MRI in the early stage of bvFTD supports the search for specific biomarkers for bvFTD.

In contrast, we found a high specificity of MRI for bvFTD, indicating that frontotemporal atrophy on MRI is suggestive of a neurodegenerative cause. Moreover, this result is consistent with the visual rating scores of global cortical atrophy and especially hippocampal atrophy in this study, which were significantly higher in the true-positive group and false-negative group compared to the non-FTD group. In addition, the current findings also seem in line with previous studies that found higher MTA scores in FTD³¹⁻³³. Taken together, MTA and GCA scores appear to be a good indicator for bvFTD in a late-onset frontal lobe syndrome. However, these visual rating scores are identical to patients with AD, and must be ruled out with additional investigations such as amyloid PET imaging^{34,35} or CSF biomarkers³⁶.

Frontotemporal changes on [¹⁸F]FDG-PET had a high sensitivity for bvFTD, which is similar in previous studies^{5,37}. An explaining for these results might be the early synaptic dysfunction in the frontal and temporal regions in FTD³⁸, which is measured by [¹⁸F]FDG-PET³⁹. In contrast, other studies found lower sensitivities for [¹⁸F]FDG-PET in patients with a C9orf72 hexanucleotide repeat expansion^{28,29}. This might be due to the atypical slow progression of this phenotype of bvFTD⁴⁰. In addition, we found that a group of bvFTD patients without MRI changes had metabolism changes on the [¹⁸F]FDG-PET-scan. This finding is an argument for the suggestion that absence of sufficient atrophy could be an early stage of the disease. Therefore, [¹⁸F]FDG-PET seems a sensitive marker for early detection of bvFTD.

However, in our clinically representative cohort of patients presenting with behavioral changes, we found that the specificity of [¹⁸F]FDG-PET was relatively low due to false positive scans in psychiatric cases and cases with various other types of dementia. Moreover, 40% of the false positively rated scans were of patients with psychiatric disorders. This also may be explained by the synaptic dysfunction in psychiatric disorders in similar anatomic regions as FTD^{12,14,41-43}. Our findings indicate that the interpretation of frontotemporal hypometabolism on [¹⁸F]FDG-PET should always be accompanied by a thorough clinical evaluation, such as a psychiatric and neurological examination.

Another finding of the present study was the high sensitivity and a suboptimal specificity for the combination of MRI and additional [¹⁸F]FDG-PET-scan. The combined neuroimaging causes an increase in the diagnostic accuracy for bvFTD compared with the both individual imaging technics. Conclusively, these results support the notion of clinical practice to perform MRI investigation first in patients with a frontal lobe syndrome and clinically bvFTD, and if inconclusive for bvFTD, to perform a additional [¹⁸F]FDG-PET-scan. Moreover, coverage by Centers for Medicare en Medicaid Services (CMS) for [¹⁸F]FDG-PET for dementia requires diagnostic structural imaging first.

It could be discussed that in the present study SD (n=3), PSP (n=1) and CBS (n=1) patients were among the false positive rated scans on MRI and [¹⁸F]FDG-PET-scan, and this could indicate an incorrect evaluation of the images. However, this is not the case, since our study design asked the neuroradiologist for FTD specific abnormalities and not for the differentiation between bvFTD, SD, PSP or CBS. Moreover, these disorders are all part of the spectrum FTLD and share the same anatomical regions^{44,45}. Although, SD is associated with bilateral temporal changes, CBS with asymmetric changes and PSP with changes of the midbrain and frontal lobes, it is still difficult to differentiate between these disorders on neuroimaging⁴⁶⁻⁴⁸. From a clinical perspective, we might therefore have underestimated the specificity of MRI and [¹⁸F]FDG-PET-scan. Even when including these patients as FTD cases, specificity of MRI would not have surpassed 93% and for the [¹⁸F]FDG-PET-scan 74%.

Considerable strengths of our study are the large and clinically well-phenotyped cohort and its study design. Patients were included based on their symptoms, thereby closely resembling daily practice in neuropsychiatric clinics. Another important strength is the blinding of the neuroimaging raters, although they were aware of the study design. Thus, we have attempted to avoid over-interpretation of the neuroimaging investigations.

A limitation of this study is the rather limited number of cases with a definite FTD diagnosis based on autopsy and genetic testing. For the gold standard definition, we had to rely on the clinical consensus diagnosis and additional investigations at two-year-follow-up. Furthermore, it is important to bear in mind that there was a selection bias for the [¹⁸F]FDG-PET-scan, due to cases with a clear abnormal MRI who did not have [¹⁸F]FDG-PET. As a consequence, the sensitivity [¹⁸F]FDG-PET-scan may have been underestimated. Another source of uncertainty is the reliability of visual rating of the MRI and [¹⁸F]FDG-PET, in combination with the lacking data on interrater variability and interrater agreement of the assessment of the neuroimaging. This limits the accuracy of the present results to a certain degree and it gives a possible explanation of the finding that the correctly assessed scans in our study were with vast atrophy and high visual rating grades and the false positive scans showed less atrophy and lower visual rating grades.

Our study shows that atypical MRI atrophy patterns should not preclude genetic testing in case of suspected bvFTD. On the other hand, overinclusive bvFTD diagnosis of subjects with [¹⁸F]FDG-PET abnormalities in psychiatric disorders should be avoided by thorough psychiatric examination. Therefore, genetic testing and long-term follow-up, by a neurologist and psychiatrist, are of high relevance in the diagnosis of bvFTD. Nevertheless, the search for additional and disease specific biomarkers might further increase the diagnostic specificity of bvFTD.

Acknowledgements

E.G.B. Vijverberg had full access to all of the data in the study and takes responsibility for the integrity of the data and the accuracy of the data analysis. *Financial disclosures:* Dr. Yolande A.L. Pijnenburg received a personal fellowship from the Dutch brain foundation. Prof. Dr. Philip Scheltens serves/has served on the advisory boards of Genentech, Novartis, Roche, Danone, Nutricia, Lilly, and Lundbeck. He has been a speaker at symposia organized by Lundbeck, Merz, Danone, Novartis, Roche, GE, and Genentech. For all his activities he receives no personal compensation. Prof. Dr. Frederik Barkhof serves/has served on the advisory boards of Bayer-Schering Pharma, Sanofi-Aventis, Biogen Idec, UCB, Merck-Serono, Novartis, and Roche. He received funding from the Dutch MS Society and has been a speaker at symposia organized by the Serono Symposia Foundation. All other co-authors report no disclosures. *Funding/support:* E.G.B. Vijverberg is supported by the VUmc Alzheimer center. The Alzheimer Centre receives unrestricted funding from various sources through the VUmc Fonds. *Role of the sponsor:* The funding sources had no role in design and conduct of the study, data collection, data analysis, data interpretation, or in writing or approval of this report.

References:

1. Gossink FT, Dols A, Kerssens CJ, et al. Psychiatric diagnoses underlying the phenocopy syndrome of behavioural variant frontotemporal dementia. *Journal of Neurology, Neurosurgery & Psychiatry*. January 2015:1-6. doi:10.1136/jnnp-2014-308284.
2. Ducharme S, Price BH, Larvie M, Dougherty DD, Dickerson BC. Clinical Approach to the Differential Diagnosis Between Behavioral Variant Frontotemporal Dementia and Primary Psychiatric Disorders. *Am J Psychiatry*. 2015;172(9):827-837.
3. Woolley JD, Khan BK, Murthy NK, Miller BL, Rankin KP. The Diagnostic Challenge of Psychiatric Symptoms in Neurodegenerative Disease. *J Clin Psychiatry*. 2011;72(02):126-133.
4. Rascovsky K, Hodges JR, Knopman D, et al. Sensitivity of revised diagnostic criteria for the behavioural variant of frontotemporal dementia. *Brain*. 2011;134(Pt 9):2456-2477.
5. Mendez MF, Shapira JS, McMurtray A, Licht E, Miller BL. Accuracy of the clinical evaluation for frontotemporal dementia. *Arch Neurol*. 2007;64(6):830-835.
6. Pijnenburg YAL, Mulder JL, Van Swieten JC, et al. Diagnostic Accuracy of Consensus Diagnostic Criteria for Frontotemporal Dementia in a Memory Clinic Population. *Dement Geriatr Cogn Disord*. 2008;25(2):157-164.
7. Kipps CM, Davies RR, Mitchell J, Kril JJ, Halliday GM, Hodges JR. Clinical Significance of Lobar Atrophy in Frontotemporal Dementia: Application of an MRI Visual Rating Scale. *Dement Geriatr Cogn Disord*. 2007;23(5):334-342.
8. Knopman DS, Boeve BF, Parisi JE, et al. Antemortem diagnosis of frontotemporal lobar degeneration. *Ann Neurol*. 2005;57(4):480-488.
9. Kerklaan BJ, van Berckel BNM, Herholz K, et al. The Added Value of 18-Fluorodeoxyglucose-Positron Emission Tomography in the Diagnosis of the Behavioral Variant of Frontotemporal Dementia. *American Journal of Alzheimer's Disease and Other Dementias*. 2014;29(7):607-613.
10. Canu E, Kostić M, Agosta F, et al. Brain structural abnormalities in patients with major depression with or without generalized anxiety disorder comorbidity. *Journal of Neurology*. April 2015:1-11.
11. Houenou J, Frommberger J, Carde S, et al. Neuroimaging-based markers of bipolar disorder: Evidence from two meta-analyses. *Journal of Affective Disorders*. 2011;132(3):344-355.
12. Su L, Cai Y, Xu Y, Dutt A, Shi S, Bramon E. Cerebral metabolism in major depressive disorder: a voxel-based meta-analysis of positron emission tomography studies. November 2014:1-7.
13. Olabi B, Ellison-Wright I, McIntosh AM, Wood SJ, Bullmore E, Lawrie SM. Are There Progressive Brain Changes in Schizophrenia? A Meta-Analysis of Structural Magnetic Resonance Imaging Studies. *Biological Psychiatry*. 2011;70(1):88-96.
14. Ellison-Wright I, Bullmore E. Anatomy of bipolar disorder and schizophrenia: A meta-analysis. *Schizophrenia Research*. 2010;117(1):1-12.
15. Krudop WA, Kerssens CJ, Dols A, et al. Identifying bvFTD Within the Wide Spectrum

- of Late Onset Frontal Lobe Syndrome: A Clinical Approach. *Am J Geriatr Psychiatry*. 2015;23(10):1056-1066.
16. Krudop WA, Kerssens CJ, Dols A, et al. Building a New Paradigm for the Early Recognition of Behavioral Variant Frontotemporal Dementia: Late Onset Frontal Lobe Syndrome Study. *The American Journal of Geriatric Psychiatry*. June 2013:1-6.
 17. van der Flier WM, Pijnenburg YAL, Prins N, et al. Optimizing patient care and research: the Amsterdam Dementia Cohort. *J Alzheimers Dis*. 2014;41(1):313-327.
 18. Kertesz A, Davidson W, Fox H. Frontal behavioral inventory: diagnostic criteria for frontal lobe dementia. *Can J Neurol Sci*. Feb 1997;24(1):29-36.
 19. Shigenobu K, Ikeda M, Fukuhara R, et al. The Stereotypy Rating Inventory for frontotemporal lobar degeneration. *Psychiatry Research*. 2002;110(2):175-187.
 20. Folstein MF, Folstein SE, McHugh PR. "Mini-mental state": a practical method for grading the cognitive state of patients for the clinician. *J Psychiatr Res*. 1975.
 21. Dubois B, Slachevsky A, Litvan I, Pillon B. The FAB: a Frontal Assessment Battery at bedside. *Neurology*. 2000;55(11):1621-1626.
 22. Scheltens P, Launer LJ, Barkhof F, Weinstein HC, van Gool WA. Visual assessment of medial temporal lobe atrophy on magnetic resonance imaging: interobserver reliability. *Journal of Neurology*. 1995;242(9):557-560.
 23. Koedam ELGE, Lehmann M, van der Flier WM, et al. Visual assessment of posterior atrophy development of a MRI rating scale. *Eur Radiol*. 2011;21(12):2618-2625.
 24. Fazekas F, Chawluk JB, Alavi A, Hurtig HI, Zimmerman RA. MR signal abnormalities at 1.5 T in Alzheimer's dementia and normal aging. *AJR Am J Roentgenol*. 1987;149(2):351-356.
 25. Gregory CA, Serra-Mestres J, Hodges JR. Early diagnosis of the frontal variant of frontotemporal dementia: how sensitive are standard neuroimaging and neuropsychologic tests? *Neuropsychiatry Neuropsychol Behav Neurol*. 1999;12(2):128-135.
 26. Beck J, Rohrer JD, Campbell T, et al. A distinct clinical, neuropsychological and radiological phenotype is associated with progranulin gene mutations in a large UK series. *Brain*. 2008;131(Pt 3):706-720.
 27. Whitwell JL, Boeve BF, Weigand SD, et al. Brain atrophy over time in genetic and sporadic frontotemporal dementia: a study of 198 serial magnetic resonance images. *Eur J Neurol*. 2015;22(5):745-752.
 28. Devenney E, Hornberger M, Irish M, et al. Frontotemporal dementia associated with the C9ORF72 mutation: a unique clinical profile. *JAMA Neurol*. 2014;71(3):331-339.
 29. Solje E, Aaltokallio H, Koivumaa-Honkanen H, et al. The Phenotype of the C9ORF72 Expansion Carriers According to Revised Criteria for bvFTD. Dermaut B, ed. *PLoS ONE*. 2015;10(7):e0131817-e0131819.
 30. Kipps CM, Davies RR, Mitchell J, Kril JJ, Halliday GM, Hodges JR. Clinical Significance of Lobar Atrophy in Frontotemporal Dementia: Application of an MRI Visual Rating Scale. *Dement Geriatr Cogn Disord*. 2007;23(5):334-342.
 31. van de Pol LA, Hensel A, van der Flier WM, et al. Hippocampal atrophy on MRI in frontotemporal lobar degeneration and Alzheimer's disease. *Journal of Neurology*,

- Neurosurgery & Psychiatry*. 2006;77(4):439-442.
32. Frisoni GB, Laakso MP, Beltramello A, et al. Hippocampal and entorhinal cortex atrophy in frontotemporal dementia and Alzheimer's disease. *Neurology*. 1999;52(1):91-91.
 33. Galton CJ, Gomez-Anson B, Antoun N. Temporal lobe rating scale: application to Alzheimer's disease and frontotemporal dementia. *Journal of Neurology*. 2001.
 34. Kobylecki C, Langheinrich T, Hinz R, et al. 18F-Florbetapir PET in Patients with Frontotemporal Dementia and Alzheimer Disease. *Journal of Nuclear Medicine*. 2015;56(3):386-391.
 35. Rabinovici GD, Furst AJ, O'Neil JP, et al. 11C-PIB PET imaging in Alzheimer disease and frontotemporal lobar degeneration. *Neurology*. 2007;68(15):1205-1212.
 36. Schoonenboom NSM, Reesink FE, Verwey NA, et al. Cerebrospinal fluid markers for differential dementia diagnosis in a large memory clinic cohort. *Neurology*. 2012;78(1):47-54.
 37. Foster NL, Heidebrink JL, Clark CM, et al. FDG-PET improves accuracy in distinguishing frontotemporal dementia and Alzheimer's disease. *Brain*. 2007;130(10):2616-2635.
 38. Lipton AM, Cullum CM, Satumtira S, et al. Contribution of asymmetric synapse loss to lateralizing clinical deficits in frontotemporal dementias. *Arch Neurol*. 2001;58(8):1233-1239.
 39. Kadekaro M, Crane AM, Sokoloff L. Differential effects of electrical stimulation of sciatic nerve on metabolic activity in spinal cord and dorsal root ganglion in the rat. *Proc Natl Acad Sci USA*. 1985;82(17):6010-6013.
 40. Khan BK, Yokoyama JS, Takada LT, et al. Atypical, slowly progressive behavioural variant frontotemporal dementia associated with C9ORF72 hexanucleotide expansion. *Journal of Neurology, Neurosurgery & Psychiatry*. 2012;83(4):358-364.
 41. Sapara A, Cooke M, Fannon D, et al. Prefrontal cortex and insight in schizophrenia: a volumetric MRI study. *Schizophrenia Research*. 2007;89(1-3):22-34.
 42. Lim CS, Baldessarini RJ, Vieta E, Yucel M, Bora E, Sim K. Longitudinal neuroimaging and neuropsychological changes in bipolar disorder patients: Review of the evidence. *Neuroscience and Biobehavioral Reviews*. 2013;37(3):418-435.
 43. Schöll M, Damián A, Engler H. Fluorodeoxyglucose PET in Neurology and Psychiatry. *PET Clin*. 2014;9(4):371–90–v. doi:10.1016/j.cpet.2014.07.005.
 44. Cairns NJ, Bigio EH, Mackenzie IRA, et al. Neuropathologic diagnostic and nosologic criteria for frontotemporal lobar degeneration: consensus of the Consortium for Frontotemporal Lobar Degeneration. *Acta Neuropathol*. 2007;114(1):5-22.
 45. Mackenzie IRA, Neumann M, Bigio EH, et al. Nomenclature and nosology for neuropathologic subtypes of frontotemporal lobar degeneration: an update. *Acta Neuropathol*. 2009;119(1):1-4.
 46. Rosen HJ, Gorno-Tempini ML, Goldman WP, et al. Patterns of brain atrophy in frontotemporal dementia and semantic dementia. *Neurology*. 2002;58(2):198-208.
 47. Whitwell JL, Jack CR Jr, Parisi JE, et al. Midbrain atrophy is not a biomarker of progressive supranuclear palsy pathology. *Eur J Neurol*. 2013;20(10):1417-1422.

48. Whitwell JL, Jack CR, Boeve BF, et al. Imaging correlates of pathology in corticobasal syndrome. *Neurology*. 2010;75(21):1879-1887.
49. Bruns MB, Josephs KA. Neuropsychiatry of corticobasal degeneration and progressive supranuclear palsy. *Int Rev Psychiatry*. 2013;25(2):197-209.
50. Snowden JS, Bathgate D, Varma A, Blackshaw A, Gibbons ZC, Neary D. Distinct behavioural profiles in frontotemporal dementia and semantic dementia. *Journal of Neurology, Neurosurgery & Psychiatry*. 2001;70(3):323-332.

Figures and tables

Figure title and legend

Figure 1. Four coronal T1 MRI slices and voxel-based [18F]FDG-PET images

*Example of (A) Major Depression Disorder with true negative MR and false positive [18F]FDG-PET (B) Bipolar Disorder with false positive MR and [18F]FDG-PET (C) Definite bvFTD due to C9orf72 hexanucleotide repeat expansion with false negative MR and true positive [18F]FDG-PET (D) Probable bvFTD with true positive MR and [18F]FDG-PET.

Table 1. Clinical and demographical characteristics

Characteristics	FTD (n=27)	Non-FTD (n = 84)	P- Value
Men, n (%)	16 (59)	68(81)	0.02 ^a
Age, mean (SD), y	62.9 (6.7)	61.2 (6.6)	0.23
Duration of symptoms at presentation, mean (SD),y	5.4(5.1)	3.7(3.9)	0.14
Education, mean (SD), y	10.4(2.5)	10.2(2.6) (n=69)	0.69
MMSE, mean (SD)	26.1(2.6)	26.4(2.7)	0.71
FAB, mean (SD)	14.4(4.0)	14.9(2.9)	0.81
FBI, mean (SD)	26.3(10.4)	24.1(9.5)	0.31
SRI, mean (SD)	15.6.(10.8)	5.6(7.6)	<0.001 ^b

Abbreviations: FTD, frontotemporal dementia; FAB, Frontal Assessment Battery; FBI, Frontal

Behavioral Inventory; MMSE, Mini-Mental State Examination; SRI, Stereotypy Rating

Inventory. Significant at $p < 0.05$. independent t-tests, unless otherwise stated. ^a: Chi-square

test. ^b: Mann-Whitney test

Table 2. MRI Visual ratings scores at baseline.

MRI Visual rating scores	FTD (n=27)		Non-FTD (n=84)		P-value
	True positive (n=19)	False negative (n=8)	True negative (n=78)	False positive (n=6)	
GCA, mean (SD)	1.16 (0.83)	0.88(0.35)	0.40(0.57)	0.83(0.75)	<0.001 ^a
Right, MTA, mean (SD)	2.42(1.54)	1.25(0.89)	0.58(0.73)	0.33(0.52)	<0.001 ^a
Left, MTA , mean (SD)	1.95(1.3)	0.88(0.64)	0.53(0.73)	0.17(0.41)	<0.001 ^a
Fazekas, mean (SD)	0.89(0.66)	0.50(0.76)	0.56(0.77)	0.50(0.84)	0.13

Abbreviations: GCA, global cortical atrophy; MTA, medial temporal lobe atrophy. Chi-test. ^a

Significant <0.001 FTD vs Non-FTD.

Table 3. Diagnoses of patients after two-year-follow-up with neuroimaging findings consistent with bvFTD pattern at baseline.

MRI scans (N=25)		Frequency (n)
True positive	<i>Probable bvFTD</i>	18
	<i>Definite bvFTD (C9orf72)</i>	1
False positive	Semantic Dementia	1
	Post-anoxic-encephalopathy	1
	Parkinson's Disease Dementia	1
	Bipolar Disorder	2
	Relationship problems	1
[18F]FDG-PET-scans (n=30)		Frequency (n)
True positive	<i>Probable bvFTD</i>	8
	<i>Definite bvFTD</i>	2
False positive	Alzheimer's disease	1
	Dementia others	5
	<i>Progressive Supranuclear Palsy</i>	1
	<i>Corticobasal Degeneration</i>	1
	<i>Semantic Dementia</i>	3
	Subjective cognitive decline	1
	Vascular cognitive Impairment	1
	Psychiatric disorders	12
	<i>Schizophrenia</i>	1
	<i>Major depression</i>	4
	<i>Bipolar Disorder</i>	1
	<i>Personality disorder</i>	1
<i>Other psychiatric disorders</i>	5	

Figure 1.

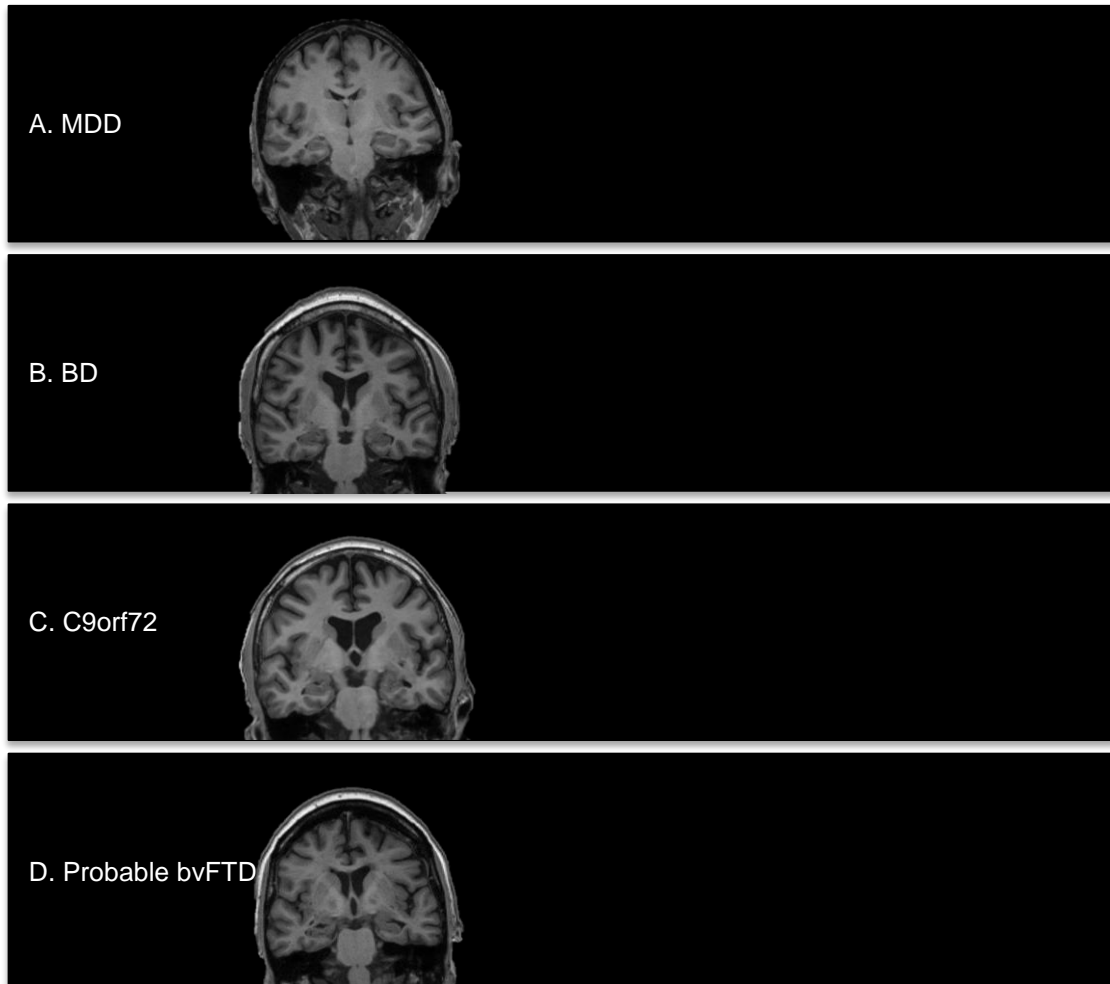


Fig. 1 Four coronal T1 MRI slices and voxel-based [18F]FDG-PET images (A) MDD with true negative MR and false positive [18F]FDG-PET (B) BD with false positive MR and [18F]FDG-PET (C) Definite bvFTD due to C9orf72 hexanucleotide repeat with false negative MR and true positive [18F]FDG-PET (D) Probable bvFTD with true positive MR and [18F]FDG-PET.

