

## **Atrophy, hypometabolism and clinical trajectories in amyloid negative probable AD patients**

Gaël Chételat,<sup>1,2,3,4</sup> Rik Ossenkoppele,<sup>\*,5,6</sup> Victor L Villemagne,<sup>\*,7</sup> Audrey Perrotin,<sup>\*,1,2,3,4</sup> Brigitte Landeau,<sup>1,2,3,4</sup> Florence Mézenge,<sup>1,2,3,4</sup> William J. Jagust,<sup>8</sup> Vincent Dore,<sup>7</sup> Bruce L. Miller,<sup>9</sup> Stéphanie Egret,<sup>1,2,3,4</sup> William W. Seeley,<sup>9</sup> Wiesje M van der Flier,<sup>6,10</sup> Renaud La Joie,<sup>1,2,3,4</sup> David Ames,<sup>11</sup> Bart NM van Berckel,<sup>6</sup> Philip Scheltens,<sup>5</sup> Frederik Barkhof,<sup>6</sup> Christopher C Rowe,<sup>7</sup> Colin Masters,<sup>12</sup> Vincent de La Sayette,<sup>1,2,3,4,13</sup> Femke Bouwman,<sup>\*,5</sup> Gil D Rabinovici,<sup>\*,8,9</sup>

\* contributed equally to this work

<sup>1</sup> INSERM, U1077, Caen, France

<sup>2</sup> Université de Caen Basse-Normandie UMR-S1077, Caen, France

<sup>3</sup> Ecole Pratique des Hautes Etudes, UMR-S1077, Caen, France

<sup>4</sup> CHU de Caen, U1077, Caen, France

<sup>5</sup> VU University Medical Center, Amsterdam, the Netherlands, Neuroscience Campus  
Amsterdam, Department of Neurology & Alzheimer Center

<sup>6</sup> VU University Medical Center, Amsterdam, the Netherlands, Department of Radiology &  
Nuclear Medicine

<sup>7</sup> Department of Nuclear Medicine and Centre for PET, Austin Health, Melbourne, VIC,  
Australia

<sup>8</sup> Helen Wills Neuroscience Institute, University of California, Berkeley, Berkeley CA, USA;  
Lawrence Berkeley National Laboratory, Berkeley, California, USA

<sup>9</sup> Department of Neurology, Memory and Aging Center, University of California San  
Francisco, San Francisco, CA, USA

<sup>10</sup> VU University Medical Center, Amsterdam, department of Epidemiology & Biostatistics

<sup>11</sup> Academic Unit for Psychiatry of Old Age, St. Vincent's Health, Department of Psychiatry,  
The University of Melbourne, Kew, Victoria, Australia; National Ageing Research Institute,  
Parkville, Victoria, Australia

<sup>12</sup> Cooperative Research Centre for Mental Health, Carlton, VIC 3053 Australia ; Mental  
Health Research Institute, The University of Melbourne, Parkville, VIC 3052 Australia ;  
Centre for Neuroscience, The University of Melbourne, Parkville, VIC 3010 Australia.

<sup>13</sup> CHU de Caen, Service de Neurologie, Caen, France

Corresponding author: Gaël Chételat, Unité U1077, GIP CYCERON, Bd Henri Becquerel – BP  
5229, 14074 Caen Cedex, France. Telephone: (+33) 231470173. Fax: (+33) 2 3147 0275.  
Email: chetelat@cyceron.fr

## Abstract

About 15% of patients clinically diagnosed with Alzheimer's disease do not show high tracer retention on amyloid PET. The present study investigates the clinical and demographic features, patterns of brain atrophy and hypometabolism and longitudinal clinical trajectories of these patients, with a particular emphasis on the AD-mimic typical amnestic subgroup. 38 amyloid PET-negative patients carrying a pre-PET diagnosis of AD ( $A\beta$ neg-AD) from 4 centers (Amsterdam, Melbourne, San Francisco and Caen) were included in this study (11/27 females/males; mean age= $67\pm 9$ ). Detailed clinical histories, including the clinical diagnoses before and after the PET scan and at follow-up ( $>2$  years), were collected. Patients were classified according to their pre-PET clinical phenotype as amnestic (memory predominant), non-amnestic (predominant language, visuospatial or frontal symptoms), or non-specific (diffuse cognitive deficits). Demographic, clinical, neuropsychological, MRI and FDG-PET data obtained at the time of the amyloid-PET scan were compared between  $A\beta$ neg-AD subgroups, 27  $A\beta$ -positive AD cases with a typical amnestic clinical presentation ( $A\beta$ pos-AD; 14/13 females/males; mean age= $71\pm 10$ ) and 29  $A\beta$ -negative cognitively healthy controls ( $A\beta$ neg-HC; 15/14 females/males; mean age= $69\pm 12$ ) matched for age, gender and education. There were 19 amnestic, 13 non-amnestic, and 7 non-specific  $A\beta$ neg cases.  $A\beta$ neg-AD subgroups did not differ in age, gender, education or APOE4 proportion. After the PET scan, clinicians altered the diagnosis in 68% of  $A\beta$ neg-AD cases including 44% of amnestic versus 94% of non-amnestic and non-specific cases. Amnestic  $A\beta$ neg-AD were most often reclassified as frontotemporal dementia, non-amnestic as frontotemporal dementia or corticobasal degeneration, and non-specific as dementia with Lewy bodies. The longer-term clinical follow-up was consistent with the post-PET diagnosis in most cases (89%), including in amnestic  $A\beta$ neg-AD whose post-PET diagnosis remained AD. While the non-amnestic and non-specific  $A\beta$ neg-AD usually showed patterns of atrophy and hypometabolism suggestive of another

degenerative disorder, the amnesic A $\beta$ neg-AD had subtle atrophy and hypometabolism, restricted to the retrosplenium – posterior cingulate – posterior hippocampus junction. A $\beta$ neg-AD patients have heterogeneous clinical presentations and likely represent a mixed population of initially misdiagnosed, mostly neurodegenerative, conditions. The clinical, cognitive, MRI and FDG profiles aided to find an alternative post-PET diagnosis in most non-amnesic cases. In the largest and most intriguing subgroup of amnesic A $\beta$ neg-AD however, the patients mimic typical AD in their clinical presentation and follow-up, so that an alternative diagnosis was not made in more than half of the cases – highlighting the need for a clinical framework and terminology to define these patients, who may have underlying limbic-predominant, non-A $\beta$ -driven pathologies.

## 1. Introduction

$\beta$ -Amyloid ( $A\beta$ ) deposition is one of the neuropathological hallmarks of Alzheimer's disease (AD) (Hyman *et al.*, 2012). For more than a decade, it has been possible to visualize these lesions *in vivo* with positron emission tomography (PET) radiotracers that bind to fibrillar  $A\beta$  plaques (Klunk *et al.*, 2004). Most patients with a clinical diagnosis of probable AD have a positive  $A\beta$  scan ( $A\beta$ pos-AD). However, a significant proportion, about 15% (ranging from 2 to 32%) of patients across clinical series, have a negative  $A\beta$  scan ( $A\beta$ neg-AD) (Doraiswamy *et al.*, 2012; Jagust *et al.*, 2010; Ossenkoppele *et al.*, 2013; Ossenkoppele, Jansen, *et al.*, 2015; Rowe *et al.*, 2010; Sperling *et al.*, 2014; Vandenberghe *et al.*, 2010). Very few such cases have come to autopsy so that their etiology remains largely unknown. Some of the  $A\beta$ neg-AD might correspond to false negatives due to technical issues or scan misinterpretation, or a lack of sensitivity of  $A\beta$  ligands in cases with low  $A\beta$  burden or atypical  $A\beta$  forms (Cairns *et al.*, 2009; Johnson *et al.*, 2013; Rosen *et al.*, 2010; Schöll *et al.*, 2012). The majority of  $A\beta$ neg-AD cases probably reflect clinical misdiagnosis, as the accuracy of the clinical diagnosis of probable AD at expert centers is approximately 70% when compared to the cause of dementia as determined at autopsy (Beach *et al.*, 2012). Clinical series have shown that clinicians change their diagnosis after disclosure of PET results from AD to a non- $A\beta$  neurodegenerative or non-degenerative condition in a significant portion of  $A\beta$ neg-AD cases, especially when prior diagnostic certainty was low (Ossenkoppele *et al.*, 2013; Sánchez-Juan *et al.*, 2014). This is particularly the case for patients who present with an atypical (non-amnesic) clinical phenotype (e.g. behavioural-predominant or language deficits). However, clinicians may not revise their diagnosis when faced with a progressive amnesic disorder suggestive of "typical" AD, and identifying the etiologies of these intriguing cases is particularly challenging. In-depth description of the atrophy and hypometabolism pattern and longitudinal clinical trajectories of these patients would further our understanding of their possible underlying pathology, which is crucial to

improve both the clinical diagnosis of AD and AD-like dementia and the understanding of the pathological mechanisms leading to AD symptoms.

In the present study, we gathered detailed clinical and neuroimaging data on A $\beta$ neg-AD cases from different samples to further characterize this population compared to A $\beta$ pos-AD and A $\beta$  negative healthy controls (A $\beta$ neg-HC). Patients were split in subgroups according to their baseline clinical presentation with the two following main objectives: i) to determine the most plausible alternative diagnosis per subgroup based on all available information (clinician judgment based on clinical, neuropsychological, CSF, neuroimaging data and follow-up clinical information); and ii) in the AD-mimic typical amnesic subgroup, especially those without an alternative diagnosis, to provide a comprehensive description of their neuroimaging (atrophy and hypometabolism) profile as a key to the possible etiologies.

## **2. Methods**

### **2.1. Participants**

A $\beta$ neg-AD cases were identified by database searches in four A $\beta$  PET research centers. In two centers recruitment for A $\beta$  PET was derived from observational research studies of typical amnesic AD (Caen, France: CAEN and Melbourne, Australia: MEL), whereas in the other two recruitment centered around clinical populations with more diverse clinical profiles (Amsterdam, The Netherlands: AMS and San Francisco, United States: SF). Individuals were eligible for inclusion in this study if they had i) a pre-PET clinical diagnosis of probable AD according to international consensus NINCDS-ADRDA criteria (McKhann *et al.*, 1984) without taking into account imaging data; ii) an A $\beta$ -PET scan that was classified as negative by local readers (VLV, CCR, WJJ, VLS, GDR, BVB); and iii) a structural MRI scan (used for MRI and FDG-PET data processing).

All A $\beta$ -PET scans (PIB or florbetapir standardized uptake value [SUV] images; see Supplementary Table S2) from the four centers were re-reviewed by a single reader blinded to all clinical information (GDR). Ambiguous cases (i.e. high degree of uncertainty or discordance across readers) were excluded, since the goal of this study was to characterize the clearly negative (compared to the clearly positive) AD cases, and not to deal with the issue of intermediate/ambiguous A $\beta$  scans. Out of the 46 A $\beta$ neg-AD cases pre-selected by the centers (representing 9%-21% of all AD cases with an A $\beta$  PET scan in those centers), 38 cases were finally included in the present study (**Table 1**; 3 from CAEN, 6 from MEL, 18 from AMS and 11 from SF). Among the 8 cases that were excluded, 6 had ambiguous or positive A $\beta$ -PET reading on re-review, 1 had an ambiguous pre-PET diagnosis and 1 was too severely impaired. For comparison, A $\beta$ -positive AD cases (A $\beta$ pos-AD) and A $\beta$ neg-HC from each center were selected. The A $\beta$ pos-AD cases were eligible if they had a pre-PET clinical diagnosis of probable AD according to the NINCDS-ADRDA criteria (McKhann *et al.*, 1984) with a typical amnesic clinical presentation, a structural MRI scan and an A $\beta$ -PET scan that was classified as positive by the local reader. The A $\beta$ neg-HC were volunteers recruited through newspaper advertisements as described elsewhere (Mevel *et al.*, 2013; Mormino *et al.*, 2009; Ossenkoppele *et al.*, 2012; Villemagne *et al.*, 2011), who performed within normal limits on screening cognitive tests assessing memory, attention, language, visuo-spatial and executive functions. The same reader as for the A $\beta$ neg-AD (GDR) performed a blinded review of all A $\beta$ pos-AD and A $\beta$ neg-HC cases and all cases with an ambiguous A $\beta$  PET scan were excluded. The A $\beta$ pos-AD and A $\beta$ neg-HC cases were selected so that the groups were matched to the A $\beta$ neg-AD group for age and education (and MMSE for AD). In total, 27 A $\beta$ pos-AD and 29 A $\beta$ neg-HC cases were included in the study. All participants included in this study underwent standard dementia screening that included medical history, informant-based history, physical and neurologic examinations, screening laboratory tests, MRI and neuropsychological testing. Pre-

PET clinical diagnosis was established by consensus in a multidisciplinary team. The demographic characteristics of the groups are indicated in [Table 1](#). All participants or their surrogates provided informed consent to participate in research, and the local ethics committee in each centre approved for all protocols.

## **2.2. Data collection**

To optimize data collection, AP or GC performed site visits at each of the centers following a pre-specified procedure. Before the visit, each centre prepared a list of cases (A $\beta$ neg-AD, A $\beta$ pos-AD and A $\beta$ neg-HC) with their corresponding demographic, ApoE genotype and neuropsychological data, results of CSF analyses when available, and a file summarizing available neuroimaging data (structural MRI, FDG-PET, A $\beta$ -PET).

The procedure for the site visit included:

- i) Reviewing the clinical history with one of the local site investigators (who was informed about each case being A $\beta$ neg-AD, A $\beta$ pos-AD or A $\beta$ neg-HC) based on the information available in the clinical report. When information was unclear or missing, the attending clinician of the patient (if different from the site investigator) was further interviewed. The systematically recorded clinical information included: presenting cognitive complaints, date of the first visit, reports from the clinical and neuropsychological assessment, whether the patient had a typical amnesic or non-amnesic presentation, the differential diagnosis (if any), change of diagnosis after disclosing results of the PET scan, clinical follow-up and results of post-mortem analyses if available;
- ii) Checking that all neuroimaging data were available and de-identified;
- iii) Copying the neuroimaging data and performing a first pass quality control;
- iv) Getting information and explanation on the neuropsychological tests and scores.



All A $\beta$ neg-AD patients were then classified according to their clinical phenotype in the last assessment prior to the PET scan. The clinical phenotype was determined by the clinician based on clinical and neuropsychological information. They were classified as i) “amnesic” A $\beta$ neg-AD if they had predominant episodic memory deficits, with various involvement of other cognitive domains; ii) “non-amnesic” A $\beta$ neg-AD if their predominant deficit was in another cognitive domain than memory – i.e. if they had predominant language, visuospatial or frontal symptoms, while memory deficits, if present, were less prominent, or iii) “non-specific” A $\beta$ neg-AD if they had a diffuse pattern of cognitive impairment (i.e. they did not present with a predominant deficit in one specific area of cognition).

### **2.2.1. Neuropsychological scores**

To quantify and compare subgroup’s performances, the same or an equivalent test was selected within each center for each of the following cognitive functions: verbal episodic memory (immediate and delayed recall), visual episodic memory, executive functions, visuo-spatial function and semantic memory. The tests and scores selected for each centre are indicated in the Supplementary Material (Table S1). Each score was z-score transformed based on a control database from each corresponding centre.

### **2.2.2. Neuroimaging data**

The scanner types and acquisition protocols for each site are indicated in Supplementary Materials. For voxel-wise analyses, MRI and FDG-PET data were processed and analyzed using SPM5 software (Statistical Parametric Mapping, Wellcome Trust Centre for Neuroimaging, London, UK). T1-weighted MRI images were segmented, spatially normalized to the MNI space, modulated to correct for nonlinear warping effects using the VBM5.1 toolbox and smoothed using a 12 mm full-width at half-maximum (FWHM) Gaussian kernel. FDG-PET images were co-registered onto corresponding MRI, normalized using the deformation parameters defined from the VBM procedure performed on the corresponding MRI, scaled

using the mean PET value of the cerebellar gray matter and smoothed using a 12 mm FWHM Gaussian kernel.

Each scan was subject to a careful quality check both before and after preprocessing by three neuroimaging experts with more than 10 years of experience in neuroimaging data processing and analyses (FM, BL and GC). MRI data were considered for further analyses if the raw image and the results of the normalization and the segmentation processes were considered to be reliable. For FDG PET data, the selection was based on the quality of the raw PET images and the success of the co-registration (of the PET image onto the corresponding MRI) and the normalization (of the MRI) processes. The selection of images for voxel-wise analyses was based on a consensus agreement from the three experts on the criteria defined above based on qualitative assessment. Note that PET data were not corrected for atrophy as this would rather exacerbate differences due to the different MRI scanners.

79 MRI scans (n= 32 A $\beta$ neg-AD, 24 A $\beta$ neg-HC and 23 A $\beta$ pos-AD) and 72 FDG-PET scans (n= 32 A $\beta$ neg-AD, 19 A $\beta$ neg-HC and 21 A $\beta$ pos-AD) were included in the corresponding voxel-wise analyses. The demographic and clinical characteristics of the respective samples are indicated in Supplementary material; there was no significant difference in the characteristics of the MRI and FDG subsamples compared to those of the main sample.

### **2.2.3. Cerebrospinal Fluid (CSF)**

CSF sampling was obtained in a proportion of the A $\beta$ neg-AD (18/38) from AMS and SF. In AMS, CSF was collected in 10 mL polypropylene tubes. Within 2h after collection, the CSF was centrifuged at 1800g for 10 min at 4°C and transferred into a second polypropylene tube, and stored at -20°C. Within 2 months after lumbar puncture, analysis of A $\beta$ - $\beta$  1-42 (A $\beta$ 1-42), total tau (tau) and tau phosphorylated at threonine-181 (ptau) was performed using sandwich ELISAs (Innotest  $\beta$ -A $\beta$ (1-42), Innotest hTAU-Ag and Innotest Phosphotau(181P); Innogenetics, Gent, Belgium). A $\beta$  1-42 was considered abnormal <550 pg/ml, total tau > 374

pg/ml and ptau > 52 pg/ml or when the ratio of total tau/A $\beta$  1-42 was > 0,52 (Duits *et al.*, 2014). Analyses were done by operators who were blinded to all clinical information. CSF collection and processing in SF followed the Alzheimer's Disease Neuroimaging Initiative (ADNI) protocol (Shaw *et al.*, 2009). Samples were frozen on dry ice and shipped overnight to the ADNI Biomarker Core laboratory at the University of Pennsylvania Medical Center. A $\beta$ <sub>1-42</sub>, tau (total), and p-tau<sub>181p</sub> were measured using the multiplex xMAP Luminex platform (Luminex Corp, Austin, TX) with Innogenetics (INNO-BIA AlzBio3; Ghent, Belgium). Thresholds for CSF biomarkers and biomarker ratios were adopted from the autopsy-proven study by Shaw *et al.* (Shaw *et al.*, 2009).

### **2.3. Statistical analyses**

Demographic, clinical and neuropsychological data were compared between groups using ANOVAs and post-hoc two-by-two group comparisons. Chi-square tests were performed for categorical variables (gender and ApoE4). MRI and FDG-PET images were compared voxel-wise between groups using the full factorial design in SPM5. Results are displayed at a threshold of uncorrected  $p$  ( $p_{unc}$ ) < 0.001 (cluster extent  $k$  > 10 voxels) unless specified otherwise. Results described below are presented with all models performed without covariates. This appears as the best option given that the groups were matched to avoid reducing the degrees of freedom and associated statistical power in our analyses. Yet, to ensure that none of our findings were merely reflecting the effects of a covariate, all analyses were repeated including age, gender or centre as a covariate.

## **3. Results**

### **3.1. Demographic and clinical data**

The A $\beta$ pos-AD, A $\beta$ neg-AD, and A $\beta$ neg-HC did not differ in age, gender or education (**Table 1**). The proportion of APOE4 carriers was significantly higher in A $\beta$ pos-AD compared to both controls and A $\beta$ neg-AD but was not different between the controls and A $\beta$ neg-AD.

**Table 1:** Demographic and clinical characteristics of the samples

	A $\beta$ neg-AD (n=38)	A $\beta$ pos-AD (n=27)	A $\beta$ neg-HC (n=29)	Group effect
Age	67.4 $\pm$ 9.1	70.6 $\pm$ 9.8	69.3 $\pm$ 11.7	0.4
Gender (M:F)	27 : 11	13 : 14	14 : 15	0.09
Education	12.1 $\pm$ 4.1	13.1 $\pm$ 3.3	13.5 $\pm$ 4.0	0.4
MMSE	23.0 $\pm$ 4.4	23.5 $\pm$ 3.3	29.0 $\pm$ 1.0*	<0.001
APOE4 <sup>1</sup>	4/32 (12%)	17/22 (77%)**	3/28 (11%)	<0.001

\*: significant difference from both other groups in post-hoc tests ( $p < 0.001$ ); \*\*: significant difference from both other groups in 2x2 Chi-square ( $p < 0.001$ ). <sup>1</sup>indicated is number of APOE4 cases / number of cases with APOE genotyping (proportion).

Among A $\beta$ neg-AD patients, there were 19 amnestic, 13 non-amnestic, and 7 non-specific cases. A $\beta$ neg-AD subgroups did not differ in age, gender, education or ApoE4 proportion. There was a trend for a group effect on MMSE ( $p = 0.08$ ) and post-hoc analyses showed that non-specific A $\beta$ neg-AD had slightly lower MMSE than amnestic A $\beta$ neg-AD (**Table 2**). Comparisons of the neuropsychological scores between these subgroups were consistent with their classification, showing overall more severe episodic memory deficits in A $\beta$ pos-AD and amnestic A $\beta$ neg-AD, while non-amnestic A $\beta$ neg-AD had lower performance on non-memory tasks (see details in Supplemental data text and Figure S1).

**Table 2:** Demographic and clinical characteristics in A $\beta$ neg-AD subgroups

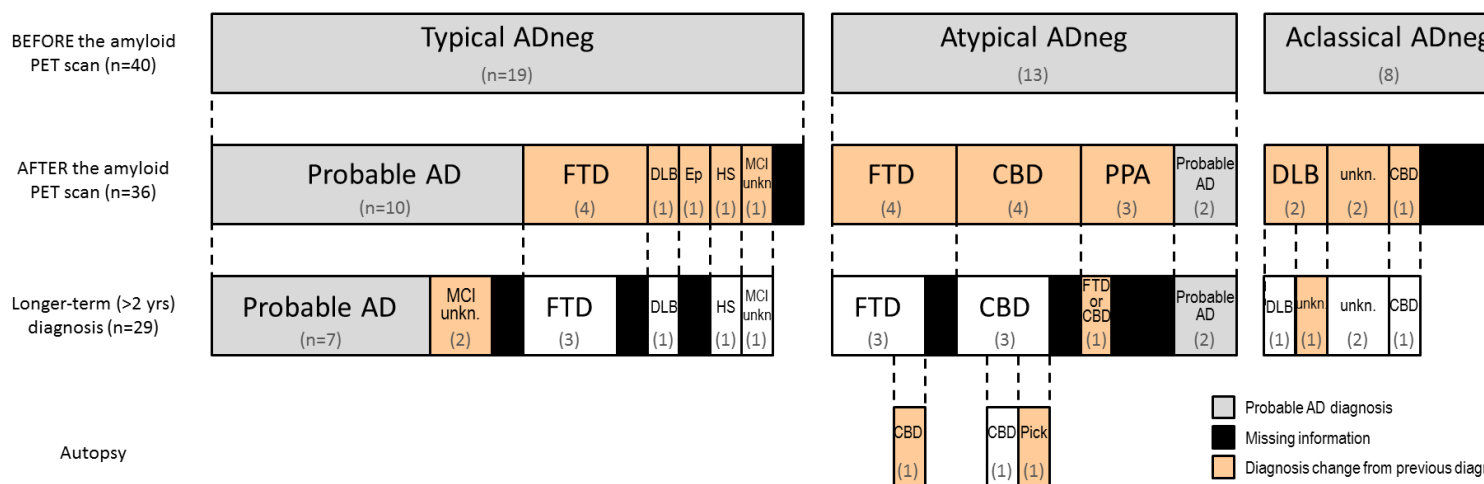
	Amnestic A $\beta$ neg-AD (n=19)	Non-amnestic A $\beta$ neg-AD (n=12)	Non-specific A $\beta$ neg-AD (n=7)	Group effect (p value)
Age	68.6 $\pm$ 11	64.8 $\pm$ 5.7	68.3 $\pm$ 8.2	0.5
Gender (M:F)	12 : 7	9 : 3	6 : 1	0.5
Education	11.9 $\pm$ 4.5	12.6 $\pm$ 3.6	10.5 $\pm$ 2.1	0.8
MMSE	24.5 $\pm$ 2.6	21.0 $\pm$ 5.9*	22.6 $\pm$ 4.8	0.08
APOE4 <sup>1</sup>	4/17 (24%)	0/11 (0%)	0/6 (0%)	0.1

\*: post-hoc Fisher LSD difference from amnestic A $\beta$ neg-AD  $p=0.04$ . <sup>1</sup>indicated is number of APOE4 cases / number of cases with APOE genotyping (proportion).

After A $\beta$  PET, the clinicians altered the diagnosis in 23 of 34 (68%; missing information in 4 cases) A $\beta$ neg-AD cases (**Figure 1**). Post-A $\beta$  PET diagnoses included behavioral and/or language variants of frontotemporal dementia (FTD, n=11), corticobasal degeneration (CBD, n=5), dementia with Lewy bodies (DLB, n=3), epilepsy/depression (n=1), hippocampal sclerosis (n=1) and unknown (n=2, see **Figure 1**). The FTD diagnoses included non-fluent variant of primary progressive aphasia (n=3), behavioural variant of FTD (n=2), semantic dementia (n=1), mixed language and behavioral FTD (n=2), unspecified variant (n=2) and atypical FTD (n=1).

When considering A $\beta$ neg-AD subgroups (**Figure 1**), clinicians did not change their clinical diagnosis in 56% of amnestic A $\beta$ neg-AD patients, but nearly always changed the diagnosis in non-amnestic and non-specific cases (94%; significantly different from the percentage in amnestic A $\beta$ neg-AD; chi-square  $p=0.002$ ). Amnestic A $\beta$ neg-AD cases were most often reclassified as FTD, non-amnestic as FTD or CBD, and non-specific as DLB.

Among the patients who had longer-term (>2 years) follow-up (n=27, 80%), the post-PET diagnosis was supported and remained unchanged in most cases (n=24; 89%). Three non-amnesic A $\beta$ neg-AD patients were followed to death and underwent brain autopsy at the UCSF Neurodegenerative Disease Brain Bank following previously published protocols (Ossenkoppele, Pijnenburg, *et al.*, 2015). The post-mortem diagnoses were corticobasal degeneration (2) and Pick's disease, pathological variants of frontotemporal lobar degeneration (Mackenzie *et al.*, 2010). The two former cases had no amyloid at all (Thal stage 0, CERAD absent) and the later case showed sparse diffuse plaques without neuritic plaque (Thal stage 1, CERAD absent).



**Figure 1:** Clinical diagnosis at baseline (in the last assessment prior to the A $\beta$ -PET scan; 1<sup>st</sup> line), once the clinicians knew the results of the PET scan (2<sup>nd</sup> line), and after a >2 years clinical follow-up (3<sup>rd</sup> line). The neuropathological diagnosis is also indicated in three patients who died and underwent autopsy (4<sup>th</sup> line). AD: Alzheimer's disease; CBD: corticobasal degeneration; CBD: corticobasal degeneration; DLB: dementia with Lewy Body; Ep: Epilepsy-depression; FTD: frontotemporal dementia; HS: hippocampal sclerosis; MCI unkn: MCI with unknown etiology; Prb: probable; unkn.: unknown disease.

### 3.2. CSF biomarkers

The results of CSF AD biomarkers in A $\beta$ neg-AD are indicated in **Table 3**. CSF A $\beta$ <sub>42</sub> results in A $\beta$ neg-AD patients were usually in the normal range, concordant with the negative A $\beta$  PET. However, CSF total Tau or p-Tau levels were abnormal in more than half the cases. Only one patient had a CSF profile strongly suggestive of underlying AD, with low A $\beta$ <sub>42</sub> and high Tau/p-Tau. The results of A $\beta$ neg-AD subgroups should be considered with caution because of the small sample sizes. They indicate that amnesic A $\beta$ neg-AD had either i) normal CSF results (45%) or ii) normal CSF A $\beta$ <sub>42</sub> with increased CSF total Tau or p-Tau levels (55%). Non-amnesic A $\beta$ neg-AD presented with any combination of normal or abnormal A $\beta$ <sub>42</sub> or Tau/p-Tau levels; they notably included all A $\beta$ neg-AD cases with decreased A $\beta$ <sub>42</sub>. CSF results were obtained in only 3 non-specific A $\beta$ neg-AD and 2 had increased Tau or p-Tau levels with normal A $\beta$ <sub>42</sub>.

**Table 3:** CSF profile per A $\beta$ neg-AD subgroup: number of cases (percentage)

	N total	A $\beta$ <sub>42</sub> normal, Tau/p-Tau normal	A $\beta$ <sub>42</sub> low, Tau/p-Tau normal	A $\beta$ <sub>42</sub> normal, Tau/p-Tau high	A $\beta$ <sub>42</sub> low, Tau/p-Tau high
All	18	7 (39%)	1 (5.5%)	9 (50%)	1 (5.5%)
Amnesic A $\beta$ neg-AD	9	4	-	5	-
Non-amnesic A $\beta$ neg-AD	7	2	1	2	1
Non-specific A $\beta$ neg- AD	3	1	-	2	-

### 3.3. Neuroimaging

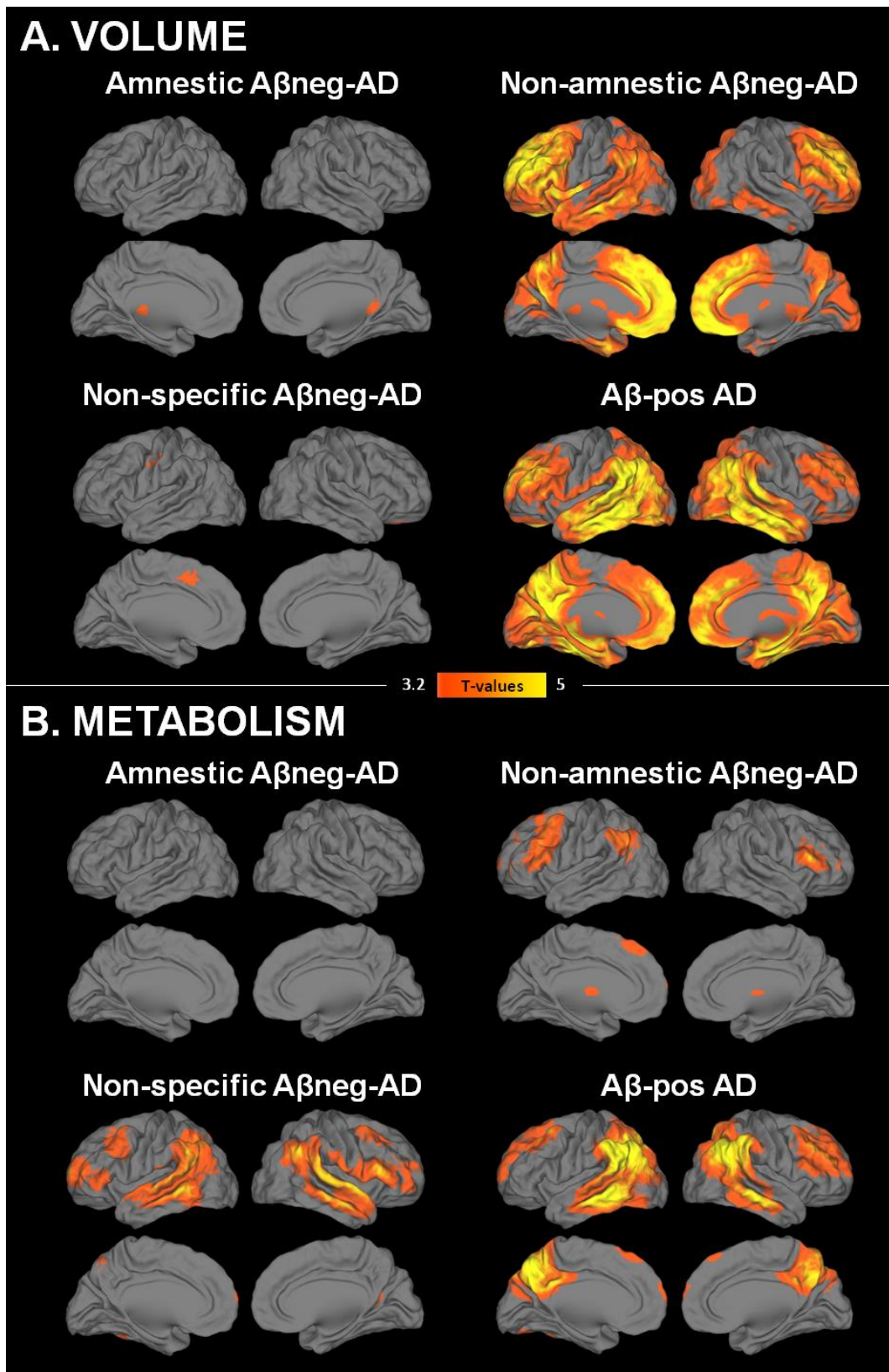
The neuroimaging findings in the total A $\beta$ neg-AD group, compared to A $\beta$ pos-AD and A $\beta$ neg-HC, are described in the Supplemental data (text and Figure S2). The neuroimaging findings for the different A $\beta$ neg-AD subgroups are shown in [Figure 2](#).

Compared to A $\beta$ neg-HC, significant atrophy in amnesic A $\beta$ neg-AD was restricted to small clusters in the right and left retrosplenium (not surviving family-wise correction for multiple comparisons at pFWE<0.05). With a more permissive threshold (p<sub>unc</sub><0.005), atrophy was also found in the hippocampus (anterior and posterior portions), ventral posterior cingulate cortex and orbito-frontal and dorsomedial prefrontal cortex. There was no area of significant hypometabolism in amnesic A $\beta$ neg-AD compared to A $\beta$ neg-HC; even at a more permissive threshold (p<sub>unc</sub><0.005), only very small clusters in the medial prefrontal, right middle temporal and posterior cingulate cortex were observed. As expected, both atrophy and hypometabolism were significantly less pronounced in amnesic A $\beta$ neg-AD compared to A $\beta$ pos-AD, in the temporo-parietal cortex (surviving at pFWE<0.05 in the left side) and precuneus.

In non-amnesic A $\beta$ neg-AD, asymmetric atrophy was found in left greater than right prefrontal, temporal, temporoparietal and temporo-occipital cortex, temporal pole, insula, posterior cingulate and precuneus, amygdala and parahippocampal gyrus. The hippocampus was mostly preserved (except a small portion in the posterior end of the right hippocampus). Large portions of the prefrontal cortex and small clusters in the left temporal lobe survived multiple comparisons correction (pFWE<0.05). Significant hypometabolism was found in left greater than right dorsal (mainly lateral) prefrontal cortex and left angular gyrus (both surviving at pFWE<0.05). Compared to A $\beta$ pos-AD, non-amnesic A $\beta$ neg-AD showed greater atrophy especially in frontal and insular regions and caudate nucleus, but they also had small clusters of less significant atrophy in posterior temporal cortex. No significant difference was found in hypometabolism between non-amnesic A $\beta$ neg-AD and A $\beta$ pos-AD.



Compared to  $A\beta$ neg-HC, the non-specific  $A\beta$ neg-AD showed restricted areas of atrophy in the orbital and dorsomedial frontal cortex (not surviving at  $pFWE < 0.05$ ), and significant hypometabolism predominantly in the temporal neocortex (surviving at  $pFWE < 0.05$ ) extending to the temporoparietal junction, and the prefrontal cortex (mainly bilateral). Compared to  $A\beta$ pos-AD, atrophy was slightly less pronounced in non-specific  $A\beta$ neg-AD while hypometabolism was more pronounced in the left insula and bilateral lingual cortex.



**Figure 2:** Profiles of atrophy (A) and hypometabolism (B) in the three A $\beta$ neg-AD subgroups and in the A $\beta$ pos-AD compared to the A $\beta$ neg-HC. The threshold was set at  $p_{unc} < 0.001$ ,  $k > 10$ .

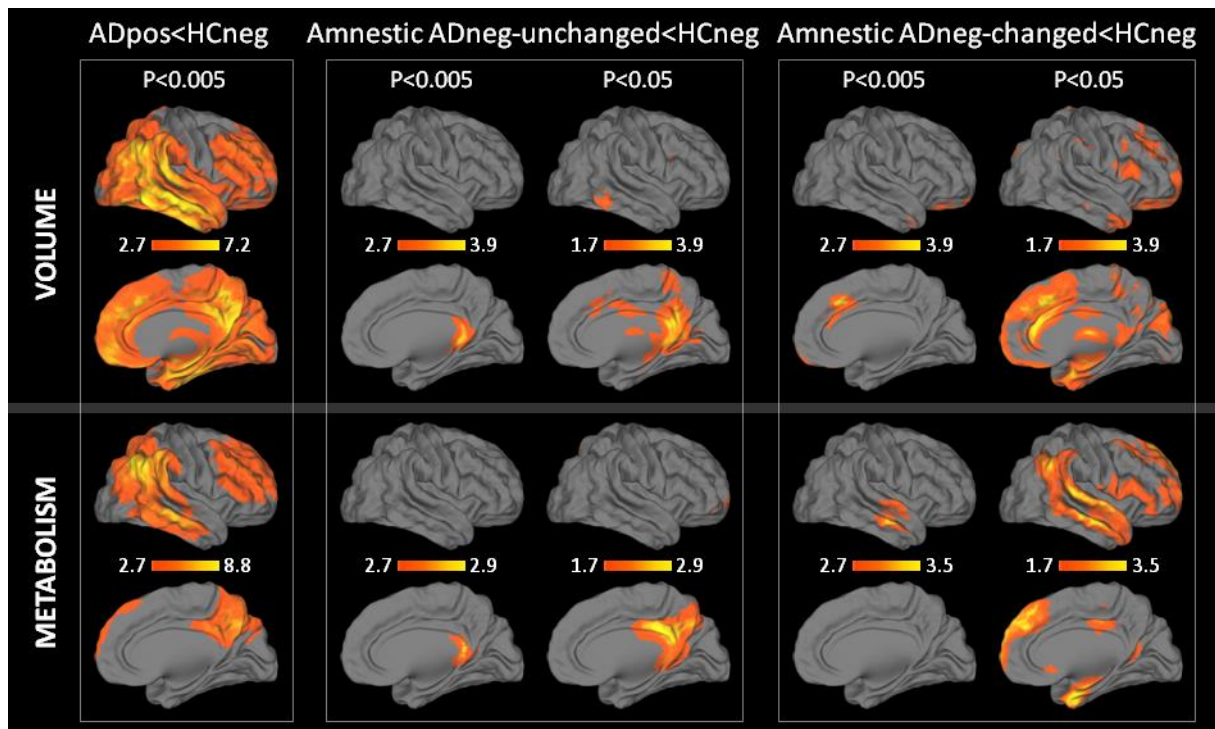
### 3.4. Additional analyses in the amnesic A $\beta$ neg-AD subgroup

To further understand what distinguished amnesic A $\beta$ neg-AD from A $\beta$ pos-AD cases, we split A $\beta$ neg-AD according to their post-PET diagnosis, i.e. whether or not the diagnosis changed after the clinician knew the results of the A $\beta$ -PET scan. The diagnosis did not change in 10 amnesic A $\beta$ neg-AD (i.e. A $\beta$ neg-AD-unchanged) (**Figure 1**). Within this subgroup, longer term (> 2 years) follow-up was available in all but one patient, and the diagnosis remained probable AD in 7/9 cases while diagnosis changed to unspecified MCI in the two remaining cases because their functional impairment was in the gray zone between MCI and dementia and they did not deteriorate during the follow-up. The 8 amnesic A $\beta$ neg-AD cases with a post-PET change in diagnosis were called amnesic A $\beta$ neg-AD-changed. Longer term (> 2 years) follow-up was available in 6 out of these 8 patients and the clinical diagnosis remained the same as the post-PET diagnosis in all cases.

The neuroimaging findings of the amnesic A $\beta$ neg-AD subgroups are shown in **Figure 3**. Because of the limited size of the subsamples, all results are shown and described at  $p_{unc} < 0.005$  (and  $p_{unc} < 0.05$  when specified) with cluster extend  $k > 50$  voxels. The amnesic A $\beta$ neg-AD-unchanged showed significant atrophy and hypometabolism compared to A $\beta$ neg-HC in the same region of the retrosplenial cortex encroaching the posterior hippocampus as amnesic A $\beta$ neg-AD. Interestingly, even at an exploratory threshold of  $p_{unc} < 0.05$ , atrophy and hypometabolism remained mainly constrained to the posterior hippocampus, posterior cingulate and precuneus.

The amnesic A $\beta$ neg-AD-changed group had significantly more atrophy compared to A $\beta$ neg-HC in the medial orbitofrontal cortex, dorso-medial frontal cortex (superior frontal gyrus), thalamus, amygdala, and parahippocampal gyrus. Significant hypometabolism was observed in the middle and superior temporal gyri.

Individual profiles of atrophy and hypometabolism were also assessed as illustrated in Supplemental material (Figure S3). They showed that three different scenarios could be found amongst the amnesic A $\beta$ neg-AD. About half of the cases presented with very slight and similar profiles of atrophy and hypometabolism restricted to the posterior hippocampus, retrosplenium and/or posterior cingulate cortex (representative examples in Figure S3B and S3C). In these cases, the clinical follow-up did not allow to identify an alternative diagnosis to probable AD. About one third of the cases had a profile of atrophy and hypometabolism consistent with another degenerative disease (representative example in Figure S3F); the clinicians changed the diagnosis based on this information and in all cases the longer-term clinical evolution was consistent with the new diagnosis. Finally, a small proportion of the amnesic A $\beta$ neg-AD cases (n=4, 22%) had a clinical progression that was not consistent with a neurodegenerative disease in that they were relatively stable or declined very slowly. Interestingly, the profiles of atrophy and hypometabolism were different in these later cases compared to both previous scenarios, in that they had either no atrophy and no hypometabolism, or very discrepant profiles with pronounced and extended atrophy and almost no hypometabolism (Figure S3D and S3E). It seems relevant to identify these cases as their clinical outcome is different and they likely do not have a neurodegenerative disease.



**Figure 3:** Profiles of atrophy (upper row) and hypometabolism (lower row) in  $A\beta$ pos-AD (left), amnestic  $A\beta$ neg-AD-unchanged (middle) and amnestic  $A\beta$ neg-AD changed (right), compared to  $A\beta$ neg-HC. The results are displayed at  $p_{unc}<0.005$  and  $p_{unc}<0.05$ ,  $k>50$ ; scale is in T-values.

## 4. Discussion

In this multicenter study we assessed the clinical, neuropsychological and neuroimaging features of patients clinically diagnosed with Alzheimer's disease who had an amyloid-negative PET scan. We found  $A\beta$ neg-AD patients to have heterogeneous clinical presentations and outcomes. 50% had a clinical phenotype typical of AD with memory predominant deficits (amnestic  $A\beta$ neg-AD), 32% showed an atypical presentation with predominant deficits in a non-memory domain (non-amnestic  $A\beta$ neg-AD), while the remaining 18% had a non-specific neurobehavioral phenotype (non-specific  $A\beta$ neg-AD). After disclosure of PET scan results, the diagnosis was changed in two-thirds of all cases, including 44% of amnestic- $A\beta$ neg-AD cases versus all but one (94%) of non-amnestic and non-specific cases. The alternative diagnosis was

another degenerative condition in a majority of cases (56% of all A $\beta$ neg-AD cases, 87% of the non-amnesic and non-specific A $\beta$ neg-AD cases), which reflects the overlap in clinical expression between the different degenerative diseases. The most frequent alternative diagnoses were FTD (48% of the cases for which the diagnosis was changed), CBD (22%) and DLB (13%).

In the national Alzheimer's coordinating center (NACC) autopsy database, a mismatch between the clinical and neuropathological diagnoses of AD was found in 17% of the 526 subjects diagnosed as clinically probable AD (Beach *et al.*, 2012), and in 25% of patients diagnosed with possible or probable AD in a follow-up study (Monsell *et al.*, 2015). The proportion of A $\beta$ neg-AD cases in the four centers in the present study (9 to 21%) is comparable to these postmortem studies, and to the rate of clinically diagnosed AD patients with negative A $\beta$  PET reported in the literature (Doraiswamy *et al.*, 2012; Jagust *et al.*, 2010; Ossenkoppele, Jansen, *et al.*, 2015; Salloway *et al.*, 2014; Vandenberghe *et al.*, 2010).

The most frequent primary neuropathological diagnoses for the cases not meeting the neuropathological threshold for AD in Beach *et al.* (2012) were AD nevertheless (19%), FTD (17%; amongst which 7/15 had ubiquitin or TDP-43 positive inclusions and 3/15 had tauopathies), tangle-only dementia or argyrophilic grain disease (17%), cerebrovascular disease (11%), DLB (10%), hippocampal sclerosis (9%) and CBD (2%). The alternative clinical diagnoses in the present study were mostly similar, with differences likely reflecting the differences in the study design (e.g. postmortem versus clinical diagnoses, availability of both plaque and tangle data at autopsy versus A $\beta$  biomarker only in the present study).

A proportion of A $\beta$ neg-AD might reflect false negative A $\beta$  scans. However, the fact that A $\beta$ neg-AD showed different profiles of hypometabolism and atrophy as compared to A $\beta$ pos-AD makes this an unlikely explanation in the majority of cases in this study. Moreover, most A $\beta$ neg-AD had a normal CSF level of A $\beta$ 42, consistent with previous reports (Shimada *et al.*,

2011; Takeuchi *et al.*, 2012), and studies showing high agreement between amyloid PET and CSF A $\beta$  results. (e.g. (Palmqvist *et al.*, 2014; Zwan *et al.*, 2014)). Only two patients had low CSF A $\beta_{42}$ , suggesting that false negative A $\beta$  PET may occur infrequently at least in our cohort, although postmortem confirmation would be needed. A few cases (especially those with an AD-typical phenotype and clinical evolution, or low CSF A $\beta$ ) might yet have low levels (Cairns *et al.*, 2009; Leinonen *et al.*, 2008) or an atypical form (Schöll *et al.*, 2009) of A $\beta$ , that would not be detected with A $\beta$  PET. As regard to CSF Tau and p-Tau, the high levels found in about half of the cases indicates that neurodegeneration and/or neurofibrillary tangles are likely present in at least 50% of A $\beta$ neg-AD in our study (Blennow *et al.*, 2010).

A $\beta$ neg-AD patients were characterized by a low prevalence of APOE4 (12% against 77% in the A $\beta$ pos-AD), consistent with previous reports (Serrano-Pozo *et al.*, 2014; Shimada *et al.*, 2011; Takeuchi *et al.*, 2012) and with the fact that APOE4 is strongly associated with A $\beta$  deposition (Fouquet *et al.*, 2014). In Monsell *et al.* (2015), minimal plaques were found postmortem in 13% of APOE4 carriers versus 37% of non-carriers in patients with a clinical diagnosis of possible or probable AD. In a recent clinical trial of anti-A $\beta$  immunotherapy, the prevalence of A $\beta$  PET-negativity in patients clinically diagnosed with mild-moderate AD dementia was 6.5% in ApoE4 carriers versus 36% in non-carriers (Liu *et al.*, 2015; Salloway *et al.*, 2014).

#### **4.1. Amnestic A $\beta$ neg-AD**

The largest subgroup of A $\beta$ neg-AD patients presented with a progressive amnestic disorder consistent with typical AD, and performed most similarly to A $\beta$ pos-AD on cognitive tests. The clinical follow up suggests that in most cases this condition is not benign: only 3/15 patients with longer-term clinical follow-up were reclassified as MCI as their cognition remained stable, while the others showed clinical progression consistent with ongoing neurodegeneration and dementia (i.e. probable AD in 7, FTD in 3, hippocampal sclerosis and DLB in 1 each). Within

this group, patients whose diagnosis changed after the A $\beta$  PET scan (44%) were most often reclassified as FTD (in 50% of the cases), and their neuroimaging profiles consistently showed predominant fronto-temporal alterations. However the diagnosis remained unchanged in 56% of cases. In the A $\beta$ neg-AD-unchanged group, atrophy and hypometabolism were restricted to the hippocampus, retrosplenial and PCC areas. These regions are known to be highly connected and involved in episodic memory (see e.g. (Ranganath and Ritchey, 2012)), which is consistent with the predominant episodic memory deficits of these patients. These patients seem likely to harbour a variety of limbic-predominant pathologies affecting the medial temporal lobe. One likely cause may be tangle-predominant dementia. Along the line of the recently termed primary age-related tauopathy (PART), patients with a clinical diagnosis of AD and neurofibrillary tangles but lacking A $\beta$  plaques have been described in many cohorts (Crary *et al.*, 2014). Amongst clinically diagnosed AD cases with no or sparse neuritic plaques from autopsy (excluding the cases with a non-AD pathological diagnosis in Serrano-Pozo *et al.*, 2014), 40 to 45% had substantial neurofibrillary degeneration (Braak stages  $\geq$  III) (Monsell *et al.*, 2015; Serrano-Pozo *et al.*, 2014). On the other hand, more than half of A $\beta$ -negative patients thus had Braak stages 0/I/II of neurofibrillary tangles, which is insufficient to account for their mild-to-moderate dementia. Additional neuropathologies that specifically target the medial temporal lobe and hippocampal circuit include hippocampal sclerosis (with or without TDP-43 positive inclusions (Nag *et al.*, 2015)) and argyrophillic grain disease, a primary tauopathy with inclusions that are morphologically and biochemically distinct from neurofibrillary tangles (Grinberg *et al.*, 2013). Cerebrovascular disease and dementia with Lewy bodies can also mimic typical AD clinically, though are more often associated with a non-amnesic predominant clinical phenotype. Notably, Serrano-Pozo and colleagues found essentially no difference in the frequency and severity of concurrent vascular and Lewy body pathologies at autopsy in low versus high amyloid brains of patients diagnosed clinically with AD. White matter lesions were



not assessed in the present study because of the lack of homogeneous data / information across centers. However, clinicians had access to the clinical MRIs and did not make the diagnosis of vascular dementia or vascular MCI despite the negative amyloid scans. Emerging tau-specific PET ligands may shed further light on the underlying pathology in these patients (Villemagne *et al.*, 2015).

It is particularly striking that amnesic A $\beta$ neg-AD-unchanged were comparable to A $\beta$ pos-AD in their clinical presentation and trajectories, while they had significantly less atrophy and hypometabolism in extended neocortical brain areas. It is possible that these patients have another pathological process, which is not measured here but contributes to their clinical profile and evolution. One can speculate that there is a causal relationship between the lack of amyloid deposition and the lack of atrophy/hypometabolism beyond the hippocampo-posterior cingulate cortex area in A $\beta$ neg-AD patients. Thus, A $\beta$  may facilitate the spread of pathologies (e.g. tau in AD) and related neurodegeneration from the initial site of infection to distant connected brain regions (i.e. temporo-parietal, precuneus and frontal areas in AD). On the same line, as A $\beta$ neg-AD tend to show very similar patterns of atrophy and hypometabolism, our results raise the question of the role of A $\beta$  in the mismatch between atrophy and hypometabolism patterns typically found in AD (Chételat *et al.*, 2008; La Joie *et al.*, 2012).

#### **4.2. Non-amnesic and non-specific A $\beta$ neg-AD**

A second group of A $\beta$ neg-AD patients was characterized by non-amnesic predominant clinical presentations. These patients showed relatively greater impairment in non-memory domains compared to A $\beta$ pos-AD and amnesic A $\beta$ neg-AD. Predominant deficits in language, executive functions/behavior and visuospatial function characterize ~15% of AD patients presenting to academic dementia centers (Snowden *et al.*, 2007) and even more in early-onset AD (Mendez

*et al.*, 2012). While these presentations are now recognized as AD phenotypes and are included in newly proposed AD diagnostic criteria (Dubois *et al.*, 2014; McKhann *et al.*, 2011), these patients also show significant clinical overlap with FTD-spectrum disorders (Alladi *et al.*, 2007; Ossenkoppele, Pijnenburg, *et al.*, 2015). In these cases clinicians changed their clinical diagnosis to FTD-spectrum syndromes (such as behavioral variant FTD, non-fluent variant primary progressive aphasia or CBD), and the topography of atrophy and hypometabolism was consistent with the alterations typically found in FTD (Diehl *et al.*, 2004; Rabinovici *et al.*, 2007), CBD (Lee *et al.*, 2011), and primary progressive aphasia (Gorno-Tempini *et al.*, 2011; Nestor *et al.*, 2003; Rabinovici *et al.*, 2008). These diagnoses remained stable over time.

The third (and smallest) subtype of A $\beta$ neg-AD presented with non-specific clinical symptoms and cognitive deficits. In these patients, AD may have represented a “default” diagnosis for a condition felt to be neurodegenerative in origin, but failing to conform a clearly described cognitive-behavioral syndrome. This group did not show a clear “signature” in the post-PET diagnoses (including DLB, CBD, and unknown dementia), clinical evolution, cognitive testing or MRI/FDG patterns, reflecting its heterogeneity as well as small numbers. In addition to cognitive deficits, these patients often have one or more of the following: global slowing (2 cases), parkinsonism (1 case), depression (1 case), vascular lesions (2 cases), hallucinations (2 cases) and cognitive fluctuations (2 cases), representing a mix of core DLB features, as well as potential non-degenerative comorbidities that might impact cognition. Indeed, in two cases cognition was stable or even improved at follow-up, suggesting that some non-specific patients, despite meeting criteria for dementia at one point, may not have an underlying neurodegenerative disease. This subtype illustrates the utility of A $\beta$  PET for “ruling-out” AD in patients with non-specific presentations, and potentially identifying treatable non-degenerative etiologies in a subset.

### **4.3. Limitations**

The lack of autopsy data (except in three cases) is a limitation of the present study as postmortem analysis would be the gold standard for identifying the etiology of A $\beta$ neg-AD cases. Note that 19% of the cases not meeting full neuropathological criteria for AD in Beach et al. (2012) were nevertheless diagnosed with AD as the primary cause of dementia, illustrating that histopathological analyses does not always provide a clear answer; in some cases, the pathological processes underlying their dementia might not be identified using current techniques.

Another limitation is the lack of standard cognitive tests and the fact that we compared retrospectively data from different centers that sometimes used different cognitive tests. Similarly, only clinical follow-up was available in the present study. Future prospective, longitudinal studies including an A $\beta$ neg-AD sample tested using a standardized neuropsychological battery will be needed to further assess whether subtle difference in the nature, degree or evolution of cognitive (including episodic memory) deficits are present.

#### **4.4. Conclusion**

This study shows that A $\beta$ neg-AD is neither a rare nor a benign condition. The clinical evolution suggests an underlying neurodegenerative disease in most patients, including those with a typical amnesic presentation or the less typical non-amnesic cases. In the latter, who likely reflect misdiagnosis, A $\beta$  PET imaging proved to be useful to rule-out AD, as shown in previous studies on the clinical impact of amyloid PET imaging. The individual profiles of atrophy and hypometabolism help, not only to find an alternative diagnosis in those cases, but also to detect the cases that might not have a neurodegenerative disease and remain relatively stable clinically. In the amnesic A $\beta$ neg-AD cases however, an alternative diagnosis could not be found in slightly more than half of the cases: they have no amyloid and showed atrophy and hypometabolism restricted to the retrosplenial cortex, but they mimic AD in their clinical presentation as well as in their clinical trajectory. Based on the current neuropathological

definition of AD they should not be called AD, but there is a need for a clinical framework and terminology for the classification of these patients. They likely represent a mixed population of limbic-predominant AD-mimics (e.g. tangle-only dementia but also hippocampal sclerosis with TDP-43 inclusions, or argyrophilic grain disease) or other non-A $\beta$ -driven pathologies. Further in-vivo exploration (including Tau-PET imaging) and extensive longitudinal assessment with autopsy data are needed to expand on our understanding of these intriguing clinical cases.

### **Funding:**

This study was supported by the Fondation Plan Alzheimer, Programme Hospitalier de Recherche Clinique, Agence Nationale de la Recherche, Région Basse Normandie, Institut National de la Santé et de la Recherche Médicale, NIA P01-AG1972403 (BLM), and ADRC P50-AG023501 (BLM and GDR), Alzheimer's Association (GDR), State of California DHS 04-33516 (BLM), John Douglas French Alzheimer's Foundation (BLM and GDR), Avid Radiopharmaceuticals (GDR), NHMRC project grant 1071430 (VLV and CCR) and Senior Research Fellowship (VLV).

### **Acknowledgements**

Authors are grateful to J. Mutlu, C. Tomadesso, R. de Florès, J. Gonneaud, G. Poisnel, S. Egret, C. Lebouleux, A. Manrique, M-C. Onfroy, L. Barré, A. Abbas, A. Quillard, for their help with recruitment, cognitive testing and imaging examinations. We thank J. Vogel, P. Ghosh, B. Cohn-Sheehy, for their help with data collection.

### **Tables and Figures**

Included in the text for the sake of proof reading

## References

- Alladi S, Xuereb J, Bak T, Nestor P, Knibb J, Patterson K, et al. Focal cortical presentations of Alzheimer's disease. *Brain* 2007; 130: 2636–2645.
- Beach TG, Monsell SE, Phillips LE, Kukull W. Accuracy of the Clinical Diagnosis of Alzheimer Disease at National Institute on Aging Alzheimer Disease Centers, 2005–2010: *J. Neuropathol. Exp. Neurol.* 2012; 71: 266–273.
- Blennow K, Hampel H, Weiner M, Zetterberg H. Cerebrospinal fluid and plasma biomarkers in Alzheimer disease. *Nat. Rev. Neurol.* 2010; 6: 131–144.
- Cairns NJ, Ikonomic MD, Benzinger T, Storandt M, Fagan AM, Shah AR, et al. Absence of Pittsburgh compound B detection of cerebral amyloid beta in a patient with clinical, cognitive, and cerebrospinal fluid markers of Alzheimer disease: a case report. *Arch. Neurol.* 2009; 66: 1557–1562.
- Chételat G, Desgranges B, Landeau B, Mézenge F, Poline JB, de la Sayette V, et al. Direct voxel-based comparison between grey matter hypometabolism and atrophy in Alzheimer's disease. *Brain* 2008; 131: 60–71.
- Crary JF, Trojanowski JQ, Schneider JA, Abisambra JF, Abner EL, Alafuzoff I, et al. Primary age-related tauopathy (PART): a common pathology associated with human aging. *Acta Neuropathol. (Berl.)* 2014; 128: 755–766.
- Diehl J, Grimmer T, Drzezga A, Riemenschneider M, Förstl H, Kurz A. Cerebral metabolic patterns at early stages of frontotemporal dementia and semantic dementia. A PET study. *Neurobiol. Aging* 2004; 25: 1051–1056.
- Doraiswamy PM, Sperling RA, Coleman RE, Johnson KA, Reiman EM, Davis MD, et al. Amyloid- $\beta$  assessed by florbetapir F 18 PET and 18-month cognitive decline: a multicenter study. *Neurology* 2012; 79: 1636–1644.
- Dubois B, Feldman HH, Jacova C, Hampel H, Molinuevo JL, Blennow K, et al. Advancing research diagnostic criteria for Alzheimer's disease: the IWG-2 criteria. *Lancet Neurol.* 2014; 13: 614–629.
- Duits FH, Teunissen CE, Bouwman FH, Visser P-J, Mattsson N, Zetterberg H, et al. The cerebrospinal fluid 'Alzheimer profile': easily said, but what does it mean? *Alzheimers Dement.* 2014; 10: 713–723.e2.
- Fouquet M, Besson FL, Gonneaud J, La Joie R, Chételat G. Imaging brain effects of APOE4 in cognitively normal individuals across the lifespan. *Neuropsychol. Rev.* 2014; 24: 290–299.
- Gorno-Tempini ML, Hillis AE, Weintraub S, Kertesz A, Mendez M, Cappa SF, et al. Classification of primary progressive aphasia and its variants. *Neurology* 2011; 76: 1006–1014.
- Grinberg LT, Wang X, Wang C, Sohn PD, Theofilas P, Sidhu M, et al. Argyrophilic grain disease differs from other tauopathies by lacking tau acetylation. *Acta Neuropathol. (Berl.)* 2013; 125: 581–593.
- Hyman BT, Phelps CH, Beach TG, Bigio EH, Cairns NJ, Carrillo MC, et al. National Institute on Aging–Alzheimer's Association guidelines for the neuropathologic assessment of Alzheimer's disease. *Alzheimers Dement.* 2012; 8: 1–13.
- Jagust WJ, Bandy D, Chen K, Foster NL, Landau SM, Mathis CA, et al. The Alzheimer's Disease Neuroimaging Initiative positron emission tomography core. *Alzheimers Dement.* 2010; 6: 221–229.

Johnson KA, Minoshima S, Bohnen NI, Donohoe KJ, Foster NL, Herscovitch P, et al. Update on appropriate use criteria for amyloid PET imaging: dementia experts, mild cognitive impairment, and education. *Amyloid Imaging Task Force of the Alzheimer's Association and Society for Nuclear Medicine and Molecular Imaging. Alzheimers Dement.* 2013; 9: e106–109.

Klunk WE, Engler H, Nordberg A, Wang Y, Blomqvist G, Holt DP, et al. Imaging brain amyloid in Alzheimer's disease with Pittsburgh Compound-B. *Ann. Neurol.* 2004; 55: 306–319.

La Joie R, Perrotin A, Barré L, Hommet C, Mézence F, Ibazizene M, et al. Region-specific hierarchy between atrophy, hypometabolism, and  $\beta$ -amyloid (A $\beta$ ) load in Alzheimer's disease dementia. *J. Neurosci.* 2012; 32: 16265–16273.

Lee SE, Rabinovici GD, Mayo MC, Wilson SM, Seeley WW, DeArmond SJ, et al. Clinicopathological correlations in corticobasal degeneration. *Ann. Neurol.* 2011; 70: 327–340.

Leinonen V, Alafuzoff I, Aalto S, Suotunen T, Savolainen S, Någren K, et al. Assessment of beta-amyloid in a frontal cortical brain biopsy specimen and by positron emission tomography with carbon 11-labeled Pittsburgh Compound B. *Arch. Neurol.* 2008; 65: 1304–1309.

Liu E, Schmidt ME, Margolin R, Sperling R, Koeppe R, Mason NS, et al. Amyloid- $\beta$  11C-PiB-PET imaging results from 2 randomized bapineuzumab phase 3 AD trials. *Neurology* 2015; 85: 692–700.

Mackenzie IRA, Neumann M, Bigio EH, Cairns NJ, Alafuzoff I, Kril J, et al. Nomenclature and nosology for neuropathologic subtypes of frontotemporal lobar degeneration: an update. *Acta Neuropathol. (Berl.)* 2010; 119: 1–4.

McKhann G, Drachman D, Folstein M, Katzman R, Price D, Stadlan EM. Clinical diagnosis of Alzheimer's disease: report of the NINCDS-ADRDA Work Group under the auspices of Department of Health and Human Services Task Force on Alzheimer's Disease. *Neurology* 1984; 34: 939–944.

McKhann GM, Knopman DS, Chertkow H, Hyman BT, Jack CR Jr, Kawas CH, et al. The diagnosis of dementia due to Alzheimer's disease: recommendations from the National Institute on Aging-Alzheimer's Association workgroups on diagnostic guidelines for Alzheimer's disease. *Alzheimers Dement.* 2011; 7: 263–269.

Mendez MF, Lee AS, Joshi A, Shapira JS. Nonamnestic presentations of early-onset Alzheimer's disease. *Am. J. Alzheimers Dis. Other Demen.* 2012; 27: 413–420.

Mevel K, Landeau B, Fouquet M, La Joie R, Villain N, Mézence F, et al. Age effect on the default mode network, inner thoughts, and cognitive abilities. *Neurobiol. Aging* 2013; 34: 1292–1301.

Monsell SE, Kukull WA, Roher AE, Maarouf CL, Serrano G, Beach TG, et al. Characterizing Apolipoprotein E  $\epsilon$ 4 Carriers and Noncarriers With the Clinical Diagnosis of Mild to Moderate Alzheimer Dementia and Minimal  $\beta$ -Amyloid Peptide Plaques. *JAMA Neurol.* 2015

Mormino EC, Kluth JT, Madison CM, Rabinovici GD, Baker SL, Miller BL, et al. Episodic memory loss is related to hippocampal-mediated beta-amyloid deposition in elderly subjects. *Brain* 2009; 132: 1310–1323.

Nag S, Yu L, Capuano AW, Wilson RS, Leurgans SE, Bennett DA, et al. Hippocampal sclerosis and TDP-43 pathology in aging and Alzheimer disease. *Ann. Neurol.* 2015; 77: 942–952.

Nestor PJ, Caine D, Fryer TD, Clarke J, Hodges JR. The topography of metabolic deficits in posterior cortical atrophy (the visual variant of Alzheimer's disease) with FDG-PET. *J. Neurol. Neurosurg. Psychiatry* 2003; 74: 1521–1529.

Ossenkoppele R, Jansen WJ, Rabinovici GD, Knol DL, van der Flier WM, van Berckel BNM, et al. Prevalence of amyloid PET positivity in dementia syndromes: a meta-analysis. *JAMA* 2015; 313: 1939–1949.

Ossenkoppele R, Pijnenburg YAL, Perry DC, Cohn-Sheehy BI, Scheltens NME, Vogel JW, et al. The behavioural/dysexecutive variant of Alzheimer's disease: clinical, neuroimaging and pathological features. *Brain* 2015; 138: 2732–2749.

Ossenkoppele R, Prins ND, Pijnenburg YAL, Lemstra AW, van der Flier WM, Adriaanse SF, et al. Impact of molecular imaging on the diagnostic process in a memory clinic. *Alzheimers Dement.* 2013; 9: 414–421.

Ossenkoppele R, Zwan MD, Tolboom N, van Assema DME, Adriaanse SF, Kloet RW, et al. Amyloid burden and metabolic function in early-onset Alzheimer's disease: parietal lobe involvement. *Brain* 2012; 135: 2115–2125.

Palmqvist S, Zetterberg H, Blennow K, Vestberg S, Andreasson U, Brooks DJ, et al. Accuracy of brain amyloid detection in clinical practice using cerebrospinal fluid  $\beta$ -amyloid 42: a cross-validation study against amyloid positron emission tomography. *JAMA Neurol.* 2014; 71: 1282–1289.

Rabinovici GD, Jagust WJ, Furst AJ, Ogar JM, Racine CA, Mormino EC, et al. Abeta amyloid and glucose metabolism in three variants of primary progressive aphasia. *Ann. Neurol.* 2008; 64: 388–401.

Rabinovici GD, Seeley WW, Kim EJ, Gorno-Tempini ML, Rascovsky K, Pagliaro TA, et al. Distinct MRI atrophy patterns in autopsy-proven Alzheimer's disease and frontotemporal lobar degeneration. *Am. J. Alzheimers Dis. Other Dement.* 2007; 22: 474–488.

Ranganath C, Ritchey M. Two cortical systems for memory-guided behaviour. *Nat. Rev. Neurosci.* 2012; 13: 713–726.

Rosen RF, Ciliax BJ, Wingo TS, Gearing M, Dooyema J, Lah JJ, et al. Deficient high-affinity binding of Pittsburgh compound B in a case of Alzheimer's disease. *Acta Neuropathol. (Berl.)* 2010; 119: 221–233.

Rowe CC, Ellis KA, Rimajova M, Bourgeat P, Pike KE, Jones G, et al. Amyloid imaging results from the Australian Imaging, Biomarkers and Lifestyle (AIBL) study of aging. *Neurobiol. Aging* 2010; 31: 1275–1283.

Salloway S, Sperling R, Fox NC, Blennow K, Klunk W, Raskind M, et al. Two phase 3 trials of bapineuzumab in mild-to-moderate Alzheimer's disease. *N. Engl. J. Med.* 2014; 370: 322–333.

Sánchez-Juan P, Ghosh PM, Hagen J, Gesierich B, Henry M, Grinberg LT, et al. Practical utility of amyloid and FDG-PET in an academic dementia center. *Neurology* 2014; 82: 230–238.

Schöll M, Almkvist O, Axelman K, Stefanova E, Wall A, Westman E, et al. Glucose metabolism and PIB binding in carriers of a His163Tyr presenilin 1 mutation. *Neurobiol. Aging* 2011; 32: 1388–1399.

Schöll M, Wall A, Thordardottir S, Ferreira D, Bogdanovic N, Långström B, et al. Low PiB PET retention in presence of pathologic CSF biomarkers in Arctic APP mutation carriers. *Neurology* 2012; 79: 229–236.

Serrano-Pozo A, Qian J, Monsell SE, Blacker D, Gómez-Isla T, Betensky RA, et al. Mild to moderate Alzheimer dementia with insufficient neuropathological changes. *Ann. Neurol.* 2014; 75: 597–601.

Shaw LM, Vanderstichele H, Knapik-Czajka M, Clark CM, Aisen PS, Petersen RC, et al. Cerebrospinal fluid biomarker signature in Alzheimer's disease neuroimaging initiative subjects. *Ann. Neurol.* 2009; 65: 403–413.

Shimada H, Ataka S, Takeuchi J, Mori H, Wada Y, Watanabe Y, et al. Pittsburgh compound B-negative dementia: a possibility of misdiagnosis of patients with non-alzheimer disease-type dementia as having AD. *J. Geriatr. Psychiatry Neurol.* 2011; 24: 123–126.

Snowden JS, Stopford CL, Julien CL, Thompson JC, Davidson Y, Gibbons L, et al. Cognitive phenotypes in Alzheimer's disease and genetic risk. *Cortex J. Devoted Study Nerv. Syst. Behav.* 2007; 43: 835–845.

Sperling R, Mormino E, Johnson K. The evolution of preclinical Alzheimer's disease: implications for prevention trials. *Neuron* 2014; 84: 608–622.

Takeuchi J, Shimada H, Ataka S, Kawabe J, Mori H, Mizuno K, et al. Clinical features of Pittsburgh compound-B-negative dementia. *Dement. Geriatr. Cogn. Disord.* 2012; 34: 112–120.

Vandenberghe R, Van Laere K, Ivanoiu A, Salmon E, Bastin C, Triau E, et al. 18F-flutemetamol amyloid imaging in Alzheimer disease and mild cognitive impairment: a phase 2 trial. *Ann. Neurol.* 2010; 68: 319–329.

Villemagne VL, Fodero-Tavoletti MT, Masters CL, Rowe CC. Tau imaging: early progress and future directions. *Lancet Neurol.* 2015; 14: 114–124.

Villemagne VL, Pike KE, Chételat G, Ellis KA, Mulligan RS, Bourgeat P, et al. Longitudinal assessment of A $\beta$  and cognition in aging and Alzheimer disease. *Ann. Neurol.* 2011; 69: 181–192.

Zwan M, van Harten A, Ossenkoppele R, Bouwman F, Teunissen C, Adriaanse S, et al. Concordance between cerebrospinal fluid biomarkers and [11C]PIB PET in a memory clinic cohort. *J. Alzheimers Dis.* 2014; 41: 801–807.