

The Annals of Thoracic Surgery

Classification of ventricular septal defects for the Eleventh Iteration of the International Classification of Diseases - striving for consensus: A report from the International Society for Nomenclature of Paediatric and Congenital Heart Disease --Manuscript Draft--

Manuscript Number:	ANNALS-18-01287R1
Article Type:	Report
Corresponding Author:	Leo Lopez, MD Nicklaus Children's Hospital Miami, FL UNITED STATES
First Author:	Leo Lopez, MD
Order of Authors:	Leo Lopez, MD Lucile Houyel, MD Steven D. Colan, MD Robert H. Anderson, BSc, MD, FRCPath, FRCS Ed (Hon) Marie J. Béland, MDCM Vera D. Aiello, MD, PhD Frederique Bailliard, MD, MS Meryl S. Cohen, MD Jeffrey P. Jacobs, MD Hiromi Kurosawa, MD Stephen P. Sanders, MD Henry L. Walters III, MD Paul M. Weinberg, MD Jeffrey R. Boris, MD Andrew C. Cook, PhD Adrian Crucean, MD, MS, PhD Allen D. Everett, MD J. William Gaynor, MD Jorge Giroud, MD Kristine J. Guleserian, MD Marina L. Hughes, DPhil, MRCP, FRACP Amy L. Juraszek, MD Otto N. Krogmann, MD Bohdan J. Maruszewski, MD, PhD James D. St. Louis, MD Stephen P. Seslar, MD, PhD Diane E. Spicer, BS, PA Shubhika Srivastava, MBBS Giovanni Stellin, MD

	Christo I. Tchervenkov, MD
	Lianyi Wang, MD
	Rodney C.G. Franklin, MD

Title: Classification of ventricular septal defects for the Eleventh Iteration of the International Classification of Diseases – striving for consensus: A report from the International Society for Nomenclature of Paediatric and Congenital Heart Disease

Running Head: Classification of ventricular septal defects – striving for consensus

Authors: Leo Lopez, MD,¹ Lucile Houyel, MD,² Steven D. Colan, MD,³ Robert H. Anderson, BSc, MD, FRCPath, FRCS Ed (Hon),⁴ Marie J. Béland, MDCM,⁵ Vera D. Aiello, MD, PhD,⁶ Frederique Bailliard, MD, MS,⁷ Meryl S. Cohen, MD,⁸ Jeffrey P. Jacobs, MD,⁹ Hiromi Kurosawa, MD,¹⁰ Stephen P. Sanders, MD,³ Henry L. Walters III, MD,¹¹ Paul M. Weinberg, MD,⁸ Jeffrey R. Boris, MD,⁸ Andrew C. Cook, PhD,¹² Adrian Crucean, MD, MS, PhD,¹³ Allen D. Everett, MD,¹⁴ J. William Gaynor, MD,⁸ Jorge Giroud, MD,⁹ Kristine J. Guleserian, MD,¹ Marina L. Hughes, DPhil, MRCP, FRACP,¹⁵ Amy L. Juraszek, MD,¹⁶ Otto N. Krogmann, MD,¹⁷ Bohdan J. Maruszewski, MD, PhD,¹⁸ James D. St. Louis, MD,¹⁹ Stephen P. Seslar, MD, PhD,²⁰ Diane E. Spicer, BS, PA,²¹ Shubhika Srivastava, MBBS,²² Giovanni Stellin, MD,²³ Christo I. Tchervenkov, MD,²⁴ Lianyi Wang, MD,²⁵ Rodney C. G. Franklin, MD²⁶

Institutions and Affiliations: ¹Heart Program, Nicklaus Children's Hospital, Miami, Florida, USA;

²Department of Congenital Cardiac Surgery, Marie-Lannelongue Hospital, Le Plessis-Robinson, France;

³Department of Cardiology, Boston Children's Hospital, Boston, Massachusetts, USA; ⁴Institute of Genetic Medicine, Newcastle University, Newcastle-upon-Tyne, UK; ⁵Division of Paediatric Cardiology, Montreal Children's Hospital, McGill University Health Centre, Montréal, Québec, Canada; ⁶Heart Institute (InCor), University of São Paulo School of Medicine, São Paulo, Brazil; ⁷Bailliard Henry Pediatric Cardiology, Raleigh, North Carolina, USA; ⁸Cardiac Center, Children's Hospital of Philadelphia, Philadelphia, Pennsylvania, USA; ⁹Heart Institute, Johns Hopkins All Children's Hospital, St Petersburg, Florida, USA; ¹⁰Cardiovascular Surgery, Tokyo Women's Medical University, Tokyo, Japan; ¹¹Children's Hospital of Michigan, Wayne State University School of Medicine, Detroit, Michigan, USA; ¹²Research Department of Children's Cardiovascular Disease, UCL Institute of Cardiovascular Science, London, UK; ¹³Birmingham Women's and Children's Foundation Trust Hospital, University of Birmingham, Birmingham, UK; ¹⁴Division of Pediatric Cardiology, Johns

Hopkins Hospital, Baltimore, Maryland, USA; ¹⁵Great Ormond Street Hospital for Children, London, UK; ¹⁶University of Florida College of Medicine Jacksonville, Jacksonville, Florida, USA; ¹⁷Paediatric Cardiology – Congenital Heart Disease, Heart Center Duisburg, Duisburg, Germany; ¹⁸Department for Paediatric and Congenital Heart Surgery, Children’s Memorial Health Institute, Warsaw, Poland; ¹⁹Department of Surgery, University of Missouri Kansas City School of Medicine, Kansas City, Missouri, USA; ²⁰Department of Pediatrics, Division of Pediatric Cardiology, Seattle Children’s Hospital, University of Washington, Seattle, Washington, USA; ²¹Department of Pediatric Cardiology, Congenital Heart Center, University of Florida, Gainesville, Florida, USA; ²²Icahn School of Medicine, Children’s Heart Center, Mount Sinai Hospital, New York, New York, USA; ²³Department of Cardiothoracic and Vascular Sciences, Pediatric and Congenital Cardiac Surgical Unit, University of Padova, Padova, Italy; ²⁴Division of Cardiovascular Surgery, Montreal Children’s Hospital, McGill University Health Centre, Montréal, Québec, Canada; ²⁵Heart Centre, First Hospital of Tsinghua University, Beijing, China; ²⁶Paediatric Cardiology Department, Royal Brompton & Harefield NHS Trust, London, UK

Meeting Presentation: 7th World Congress of Paediatric Cardiology and Cardiac Surgery, Barcelona, Spain; July 2017

Classifications: Congenital heart disease, cardiac/pathologic anatomy, pediatric, shunts

Word Count: 7172 words

Corresponding Author: Leo Lopez, MD
Nicklaus Children’s Hospital – Pediatric Cardiology
3100 SW 62nd Avenue, Ambulatory Building, 2nd Floor
Miami, Florida 33155-3009
786-624-5365
leolopezmd@gmail.com

Abstract

The definition and classification of ventricular septal defects have been fraught with controversy. The International Society for Nomenclature of Paediatric and Congenital Heart Disease is a group of international specialists in pediatric cardiology, cardiac surgery, cardiac morphology, and cardiac pathology that has met annually for the past nine years in an effort to unify by consensus the divergent approaches to describe ventricular septal defects. These efforts have culminated in acceptance of the classification system by the World Health Organization into the 11th Iteration of the International Classification of Diseases (ICD-11). The scheme to categorize a ventricular septal defect utilizes both its location and the structures along its borders, thereby bridging the two most popular and disparate classification approaches and providing a common language for describing each phenotype. Although the first-order terms are based on the geographic categories of central perimembranous, inlet, trabecular muscular, and outlet defects, inlet and outlet defects are further characterized by descriptors that incorporate the borders of the defect, namely the perimembranous, muscular, and juxta-arterial types. The Society recognizes that it is equally valid to classify these defects by geography or borders, so the emphasis in this system is on the second-order terms that incorporate both geography and borders to describe each phenotype. The unified terminology should help the medical community describe with better precision all types of ventricular septal defects.

Introduction

The International Society for Nomenclature of Paediatric and Congenital Heart Disease (ISNPCHD) has defined a ventricular septal defect (VSD) as *a congenital cardiac malformation in which there is a hole or pathway between the ventricular chambers* [1]. It is known as a VSD in English and German and literally translated as an interventricular communication in Spanish, French, and Portuguese. It can occur in isolation or as an integral component of complex lesions like tetralogy of Fallot, transposition, common arterial trunk, or functionally univentricular heart. Even though it is the most common congenital cardiac malformation, there is no consensus on how to describe and categorize these lesions [2]. In fact, some have suggested that the terms VSD and interventricular communication are not equal [3]. The lack of consensus occurs primarily because of three scenarios: there may be different opinions about intrinsic anatomy; there may be agreement about anatomy, but different authors have used the same term differently; or there may be different terms for the same anatomic entity. The need for consensus is well recognized, since VSDs, even in isolation, can show bewildering morphologic heterogeneity, resulting in variable definitions in the literature [4-11].

In an effort to unify divergent approaches to the description and categorization of VSDs, the ISNPCHD has proposed a classification system that utilizes the terms with their linked 6 digit codes from the International Paediatric and Congenital Cardiac Code (IPCCC) to pave the way towards consensus (Table 1). This system, which includes definitions, synonyms, and commentaries, has been accepted by the World Health Organization and incorporated into the Foundation layer of the eleventh iteration of the International Classification of Diseases (ICD-11) [1, 12]. In order to clarify the definition of a VSD and highlight the controversies related to classification, the ISNPCHD has provided the following commentary in ICD-11 [1]:

The definitions offered for a VSD, in its various forms, will be used most frequently in the setting of patients who do not have abnormalities of either atrioventricular (AV) or ventriculo-arterial (VA) connections. The definitions themselves, however, are equally applicable for the description and categorization of holes or pathways between the ventricles when the segmental connections between the cardiac components are abnormal. The key to understanding the definitions is to appreciate that the hole or pathway between the ventricles is defined both on the basis of its geographic location within the ventricular septum and its margins as seen from the aspect of the morphologically right ventricle (RV).

The ISNPCHD is a group of committed volunteers whose primary goal since 2002 has been to develop a naming system for pediatric and congenital heart disease (CHD) with the following characteristics: the system is comprehensive, internally consistent, and sensitive to previous work in the field, and it strives to overcome the challenges in communication related to competing nomenclature systems [13-16]. For obvious reasons, this issue has become particularly acute with the escalating reliance on multicenter data sharing as a means of tracking outcomes and responses to therapies.

Thus, the definition of a VSD provides the epitome of the challenges facing efforts to create a common language for CHD [17-21]. The diversity of entrenched systems at centers caring for children with CHD is significant, as is the resistance to change. This has been the most challenging topic faced by the ISNPCHD, and this document chronicles the multi-year effort to achieve consensus, requiring compromise from all participants. The terms attempt to incorporate the views of cardiologists, surgeons, morphologists, and pathologists from programs employing the full spectrum of nomenclature systems. There is no intent to declare one terminology as correct and another as incorrect. Instead, the objective is to construct a workable system with the least ambiguity that can be achieved.

Several guiding principles have evolved during our deliberations and are worth emphasizing:

- The primary goal of the ISNPCHD is to provide a rich and unambiguous classification system for use in multicenter data consolidation initiatives, such as the World Health Organization’s ICD and the databases of the Society of Thoracic Surgeons and Association for European Paediatric and Congenital Cardiology. It is not anticipated that programs will necessarily convert to the ISNPCHD system, although it is likely that an evolution in this direction will take place over time since this system facilitates multicenter data sharing.
- Ultimately, the anatomic names are simply words used as a means of communication. They have no prima facie “scientific” correctness or incorrectness. Their correctness is based on whether they facilitate communication and whether they achieve acceptance among cardiologists, surgeons, and morphologists.
- Nomenclature is often divorced from etymology and cannot be judged right or wrong based on whether it accurately reflects the original meaning of the word. A familiar example is the term “gradient”, which etymologically means a change per unit distance, a slope value. In contrast, it is used in cardiology to designate the absolute pressure difference between two anatomic locations. This divergence between etymology and use has not impaired understanding.
- Basing nomenclature on the continuously evolving understanding of embryology has been challenging. Endocardial cushion defect and bulboventricular foramen, for example, have been problematic terms in this regard and are no longer considered as accurate descriptions of their respective phenotypes. For a discussion of the embryologic development of the ventricular septum, please see the Supplemental Appendix.
- The nomenclature requires a hierarchical system that captures the anatomic and physiologic findings at both low and high specificity, reflecting the wide range of granularity that is clinically achieved in the variable settings wherein clinical care is delivered.

Classification: Geography versus Borders

Historically, the classification of VSDs has been fraught with controversy. Most systems for classification utilize either the geographic approach, which focuses on the defect location within the septum from the RV perspective, or the borders approach, which focuses on the anatomic structures adjacent to and surrounding the defect. The geographic approach helps to determine the surgical incision site (through the right atrium, RV, or pulmonary artery), whereas the borders approach helps to anticipate the location of the conduction pathway (which is not easily visible) to avoid heart block during intervention [22].

Early reports based on pathologic specimens to promote the geographic approach divided VSDs into defects at or distant from the ventricular outflow tracts, with the former more common than the latter [4]. Others used the location relative to the supraventricular crest with terms like “infracristal” or “supracristal.” Subsequent echocardiographic reports classified defects by specified areas of the RV septum as inlet, membranous, muscular, and outlet VSDs, with the last term involving the area between the limbs of the septal band (septomarginal trabeculation) [6]. Within the geographic framework, inlet defects were occasionally associated with a straddling tricuspid valve and malalignment between the atrial and ventricular septum, and outlet defects were frequently associated with malalignment between the outlet septum (conal septum) and the remainder of the ventricular septum. Further refinement of this classification system equated inlet defects to VSDs of the AV canal type and outlet defects to conal septal or infundibular VSDs [7, 8]. In addition, conoventricular defects encompassed membranous VSDs as well as those involving malalignment of the muscular outlet septum.

Proponents of the borders approach focused on the relationship of VSDs to the AV valves, membranous septum, muscular ventricular septum, and arterial valves, highlighting the areas of fibrous continuity between the AV and arterial valves [5, 9]. In hearts with concordant VA connections, perimembranous defects were defined by their location in the area of fibrous continuity between the tricuspid and aortic valves, representing the postero-inferior border of the defect. These defects opened towards the RV inlet

or outlet. The term conoventricular defect was used instead of perimembranous or membranous defect in one report, defining its location between the limbs of the septal band, often in association with abnormalities of the outlet septum [9]. Muscular defects had a completely muscular border located anywhere in the muscular ventricular septum. Subarterial or juxta-arterial defects were defined by an absent or fibrous outlet septum, localizing them in the area of fibrous continuity between the aortic and pulmonary valves.

More recently, the Society of Thoracic Surgeons utilized a hybrid classification system involving both borders and geography for its international database project, incorporating commonly used synonyms: type 1 (subarterial, supracristal, conal septal, infundibular), type 2 (perimembranous, paramembranous, conoventricular), type 3 (inlet, AV canal type), and type 4 (muscular) [7, 10].

Within this context, the ISNPCHD has proposed a classification scheme that begins with geography but also highlights the importance of borders to facilitate the understanding of each lesion. This system uses the terms central perimembranous, inlet, trabecular muscular, and outlet VSDs (Table 1). A similarly reasonable approach might begin with borders, using the terms perimembranous, muscular, and juxta-arterial as described above, while highlighting the geographic extent of each type of defect. Although the two approaches may seem incongruent and disparate, the individual second-order lesions listed under each first-order category can be found in both classification systems, with names that are identical or nearly identical, emphasizing the interdependence of geography and borders. Therefore, the ISNPCHD classification system includes synonyms (listed as parenthetical terms in this document) for the second-order terms used to describe the same phenotype, underscoring the validity of both approaches. In addition, it is important to recognize that two or more defect types can co-exist in the same heart as a single confluent VSD. For example, some hearts have confluent inlet and outlet VSDs as seen in patients with tetralogy of Fallot and AV septal defect (AV canal defect).

Normal Ventricular Septal Anatomy

To fully appreciate the geography and borders of VSDs, one must understand the landmarks of a normal ventricular septum from the RV perspective (Figure 1): the membranous septum with the AV conduction pathway traversing its postero-inferior margin; the septal band (septomarginal trabeculation) with its postero-inferior and anterosuperior limbs; the medial papillary muscle (papillary muscle of the conus) which is usually located on the postero-inferior limb of the septal band and supports the anteroseptal commissure of the tricuspid valve; and the subpulmonary muscular sleeve (subpulmonary infundibulum) separating the tricuspid and pulmonary valves (not delineated in Figure 1). All of these morphologic structures can vary significantly in normal hearts. An important structure in the setting of outlet defects is the outlet septum (conal septum); its presence in normal hearts is still controversial at this time [23].

Central Perimembranous Defects

Central perimembranous defects (perimembranous central defects) are located at the center of the base of the ventricular mass in the space usually occupied by the interventricular part of the membranous septum. This defect elicits the most controversy with regard to location and name, primarily because the term “perimembranous” involves borders and not geography. It refers specifically to the fibrous nature of the postero-inferior rim of the defect, and it is used to complement the geographic definition. One margin of these VSDs usually involves the area of fibrous continuity between an AV valve and an arterial (semilunar) valve. In hearts with concordant VA connections, this is where the tricuspid and aortic valves are in fibrous continuity. It is feasible that some central perimembranous defects are in continuity exclusively between the leaflets of the AV valves without involving an arterial valve. It may also be possible for a defect that is central perimembranous in location to have completely muscular borders, and some have considered this to be a “central muscular” defect. Because there is still no consensus on the characteristics of this anatomic entity, the “central muscular” defect is not currently included in ICD-11.

Central perimembranous defects are usually located at the anteroseptal commissure behind the septal leaflet of the tricuspid valve and below the commissure between the right and non-coronary leaflets of the aortic valve. The aortic valve may prolapse through the defect into the RV, with associated distortion often resulting in aortic regurgitation. These defects are located below and behind the postero-inferior limb of the septal band, in contrast to outlet defects that open into the RV between the two limbs of the septal band [11]. The postero-inferior limb does not extend to the ventriculo-infundibular fold, thereby usually allowing for fibrous continuity between the tricuspid and aortic valves at the postero-inferior rim of the defect. As a result, the AV conduction system is vulnerable to injury as it passes through the apex of the triangle of Koch into muscle just below this postero-inferior fibrous rim (Figure 2).

Common synonyms for central perimembranous defects include membranous, perimembranous, paramembranous [8], conoventricular without conal septal malalignment, and type 2 VSDs [10]; less frequently used terms include infracristal and subaortic VSDs. The ISNPCHD has created this new term because of the conflicting and overlapping usage of these prior terms, frequently resulting in misinterpretation. The motivation for this approach is similar to the motivation for the recommendation by the Society of Thoracic Surgeons [10] to use neutral and abstract terms (types 1 to 4) to describe VSDs as described earlier by Wells and Lindesmith [7].

Perimembranous defects with inlet extension have been classified as perimembranous inlet defects [5] and perimembranous defects with anterior outlet extension, as well as conoventricular defects with malaligned outlet septum, are generally classified as outlet defects. The ISNPCHD provides the following commentary to address these issues [1]:

Although best used to describe the perimembranous defect that opens centrally at the base of the RV, this term might be used to code perimembranous defects with inlet or outlet extension. It is

recommended, however, that the more precise terms be used whenever possible for coding the latter lesions. This code is used by some as synonymous with the perimembranous, conoventricular, Type II, or the paramembranous defects. It should not be used to code an inlet VSD, or the so-called AV canal VSD. More specific terms exist for coding these entities. It is used by some to describe an isolated perimembranous VSD without extension, although it is unlikely that perimembranous defects exist in the absence of deficiency of their muscular perimeter. The conoventricular VSD with malalignment should be coded as an outlet defect, as should the perimembranous defect opening to the outlet of the RV. [Most] perimembranous defects, nonetheless, have part of their margins made up of fibrous continuity either between the leaflets of an AV and an arterial valve or, in the setting of double outlet RV or overriding of the tricuspid valve, by fibrous continuity between the leaflets of the mitral and tricuspid valves. Such defects can also extend to become doubly committed and juxta-arterial (conal septal hypoplasia) when there is also fibrous continuity between the leaflets of the arterial valves or when there is a common arterial valve. Specific codes exist for these variants, which ideally should not be coded using this term.

When there is only minor inlet or outlet extension, differentiation of the central defect from the inlet or outlet defect may be difficult by noninvasive imaging. In these instances, direct visual inspection during surgery or morphological evaluation may be the only way to distinguish one from the other.

Inlet Defects

Inlet defects open into the RV inlet and extend along the septal leaflet of the tricuspid valve. They are located below the medial papillary muscle, postero-inferior limb of the septal band, and anteroseptal commissure of the tricuspid valve. Defects with distinct and separate right and left AV junctions (distinct tricuspid and mitral valves) are included here, whereas AV septal defect variants involving a common AV

junction without significant atrial shunting and with exclusive ventricular shunting should be considered as the interventricular component of an AV septal defect and not labeled as “inlet VSDs without a common AV junction” [24, 25]. Other terms used for an inlet defect include AV canal-type defect [8], perimembranous defect with posterior inlet extension, and type 3 defect [10].

Inlet perimembranous defects (perimembranous inlet defects or perimembranous defects with postero-inferior inlet extension) are bordered anterosuperiorly by the area of fibrous continuity between the leaflets of an AV valve and an arterial valve. Because the conduction system courses along its postero-inferior rim, surgical closure must involve sutures along the annulus of the septal leaflet of the tricuspid valve away from the postero-inferior border to avoid heart block (Figure 3) [22, 24]. Inlet muscular defects (muscular inlet defects) are in a similar location, but they have exclusively muscular borders and are not continuous with AV valvar tissue (Figure 4). Unlike inlet perimembranous defects, the conduction system courses near but not along the superior border of an inlet muscular defect [22, 24].

Inlet perimembranous defects are further subdivided into those with alignment of the atrial septum and postero-inferior part of the muscular ventricular septum and those with malalignment. The former involves the area of fibrous continuity between the tricuspid and mitral valves, while the latter is always associated with a straddling and/or overriding tricuspid valve or with supero-inferior ventricles with orthogonally related atrial septum and ventricular septum. When there is malalignment, the conduction axis arises from an anomalous AV node located inferiorly and to the right where the muscular ventricular septum joins the right AV groove (Figure 5) [24].

Trabecular Muscular Defects

Trabecular muscular defects have exclusively muscular borders and are located within the apical muscular component of the ventricular septum (Figure 5A). They are not synonymous with type 4 VSDs,

since this classification also includes inlet muscular and outlet muscular defects that are now classified as inlet or outlet defects (Figure 5B) [7, 10]. Many trabecular muscular defects close spontaneously without intervention. Some are complex with multiple entrances and exits on both sides of the ventricular septum, and these are coded differently than the entity of multiple VSDs from different geographic categories. Trabecular muscular defects are the least controversial with regard to nomenclature, though there does still exist some differing approaches related to muscular defects at the RV inlet and outlet (Figure 4A). Inlet muscular defects are actually in the apical trabecular muscular septum, but they open into the RV inlet (Figure 4B). In contrast, outlet muscular defects open into the RV outlet and are formed because of failed fusion between the muscularized proximal outflow cushions and the apical trabecular muscular septum. The ISNPCHD provides the following commentary regarding this issue [1]:

Defects within the muscular part of the ventricular septum that open to the inlet or the outlet of the RV [have been] considered to be within the apical part of the ventricular septum. However, these codes specifying defects within the trabecular part of the ventricular septum should not be used to code the inlet or outlet muscular defects as more specific geographical codes have been created for these latter variants.

These VSDs are further classified by their geographic location within the trabecular muscular septum (Figure 6). The most commonly used sub-classification involves the terms midseptal, apical, postero-inferior, and anterosuperior. This approach requires a complete understanding of the spatial landmarks designating anterior, posterior, inferior, and superior locations within the trabecular muscular septum, particularly in terms of the relationship of the defect to the AV valves, moderator band, subarterial infundibulum, and arterial valves. For example, apical muscular defects are distal to the moderator band, whereas anterosuperior, midseptal, and postero-inferior defects are proximal to the moderator band. Anterosuperior muscular defects are anterior to the septal band and its limbs compared to the other trabecular muscular defects. Midseptal muscular defects are distinguished from central perimembranous

defects, since the former are embedded within the middle of the apical muscular septum (Figure 6A), while the latter open in the central part of the base of the ventricular mass (Figure 2). The distinction between a postero-inferior muscular defect (Figure 6B) and an inlet muscular defect (Figure 4B) can be difficult and somewhat arbitrary, often determined by the distance of the defect from the hinge of the septal leaflet of the tricuspid valve. In addition, the postero-inferior muscular defects are often adjacent to the diaphragmatic part of the RV, precluding transcatheter device closure because of the right angle between the septum and RV free wall and the absence of a postero-inferior muscular rim.

Outlet Defects

Outlet defects open into the RV outlet between the limbs of the septal band. They may or may not be associated with malalignment between the outlet septum and the apical part of the muscular septum [11]. They can be further subdivided into outlet perimembranous defects (perimembranous outlet defects), outlet muscular defects (muscular outlet defects), and doubly-committed juxta-arterial defects with a muscular or fibrous postero-inferior rim. Many systems for classifying outlet defects have included only those defects with hypoplastic or absent muscular outlet septum, using nomenclature like infundibular, subarterial, doubly committed subarterial, conal septal [8], intraconal, type 1 [10], subpulmonary, and supracristal VSDs. However, defects with a malaligned outlet septum are also included in this category.

Outlet perimembranous defects are usually associated with a malaligned outlet septum (Figure 7). As with central and inlet perimembranous defects, these defects usually involve discontinuity between the postero-inferior limb of the septal band and the ventriculo-infundibular fold, allowing for fibrous continuity between the tricuspid and aortic valves. Once again, the AV conduction system is vulnerable as it courses along the postero-inferior rim of the defect. Outlet perimembranous defects are also distinguished from central perimembranous defects since the former are usually adjacent to the anterior leaflet and the latter are usually adjacent to the septal leaflet of the tricuspid valve [11]. In outlet muscular

defects and juxta-arterial defects with a muscular postero-inferior rim, the conduction pathway travels underneath the postero-inferior limb of the septal band (Figures 4A and 8A), thereby becoming a left-sided structure that is remote from the postero-inferior defect border. Surgical closure utilizing the postero-inferior limb as it approaches the membranous septum, therefore, should not result in disruption of the conduction axis [22].

When the muscular outlet septum is hypoplastic and aligned with the apical part of the muscular septum, the outlet defect thus formed usually has exclusively muscular borders without fibrous continuity between the leaflets of the aortic and pulmonary valves. These defects are considered outlet muscular defects without malalignment. They are not in fibrous continuity with the AV septum and are located away from the AV conduction pathway and above the postero-inferior limb of the septal band.

When the muscular outlet septum is absent (when there is a purely fibrous outlet septum), the cranial border of the defect is the area of fibrous continuity between the pulmonary and aortic valves (Figure 8), highlighting the partial deficiency of the free-standing subpulmonary infundibulum. These lesions are also described as doubly committed juxta-arterial defects, and the fibrous outlet septum can be aligned or malaligned relative to the apical part of the muscular septum. The right and non-coronary leaflets of the aortic valve can prolapse into these defects, with associated aortic valvar distortion and aortic regurgitation. In the setting of concordant VA connections, these defects can extend postero-inferiorly into the area of fibrous continuity between the tricuspid and aortic valves, resulting in a doubly committed juxta-arterial defect without malalignment and with a fibrous postero-inferior rim (perimembranous extension).

When the outlet septum is located outside the plane of the limbs of the septal band, there is malalignment between the outlet septum and the rest of the muscular ventricular septum. Some have utilized a separate and distinct category for these lesions, labeling them as malalignment defects. Outlet defects can involve

anterior or posterior malalignment of the outlet septum. Anterior malalignment is associated with overriding of the arterial valve that is supported predominantly by the left ventricle, and posterior malalignment is associated with left ventricular outflow tract obstruction. Outlet defects with a malaligned outlet septum usually occur with other CHDs. For example, the anterior malalignment with concordant VA connections seen in tetralogy of Fallot is associated with obstruction along the subpulmonary region. Extreme anterior malalignment results in the tetralogy of Fallot variant with pulmonary atresia. In contrast, posterior malalignment with concordant VA connections is usually associated with subaortic stenosis and aortic arch obstruction or interruption. In patients with discordant VA connections (transposition of the great arteries), anterior malalignment is associated with subaortic stenosis and a hypoplastic aortic arch, and posterior malalignment is associated with subpulmonary stenosis. Outlet defects with malalignment, particularly in the setting of tetralogy of Fallot, can also be confluent with the ventricular component of an AV septal defect, resulting in the co-existence of both lesions in the same heart.

Summary

The scheme proposed by the ISNPCHD classifies VSDs as central perimembranous, inlet, trabecular muscular, and outlet defects, using a geographic approach as the starting point of classification while highlighting the importance of describing the borders to facilitate better understanding (Table 2). In hearts with concordant VA connections, central perimembranous defects are usually adjacent to the area of fibrous continuity between the septal leaflet of the tricuspid valve and the aortic valve, and they are located below and behind the postero-inferior limb of the septal band. Inlet defects open into the RV inlet below the postero-inferior limb of the septal band and the medial papillary muscle, while outlet defects open into the RV outlet between the two limbs of the septal band. Inlet defects can be associated with malalignment of the atrial septum and ventricular septum, typically with a straddling tricuspid valve. In contrast, outlet defects are often associated with malalignment of the muscular or fibrous outlet septum

relative to the limbs of the septal band. The conduction pathway is located along the postero-inferior border of all perimembranous defects and juxta-arterial defects with a fibrous postero-inferior rim, whereas it is remote from the inferior border of all other defects. Trabecular muscular defects are embedded within the apical muscular ventricular septum and can occupy any of its geographic components. All VSDs can occur in isolation, as confluent combinations of two or more types, or as integral components of other CHDs. In fact, single defects representing confluence of two or more types (such as confluent inlet and outlet defects) will likely be a component of the next version of the ISNPCHD ICD-11 classification system. The ISNPCHD acknowledges that it is equally valid to classify VSDs based primarily on geography or borders with synonymous terminology to describe the individual phenotypes. By using an approach that incorporates both the geographic location of a VSD and its borders, the ISNPCHD system is an attempt to improve the understanding of the anatomy of holes between the ventricles and to harmonize the disparate approaches that have evolved on the basis of pathology and noninvasive imaging. In addition, this approach should encourage anyone who cares for children with VSDs to be as descriptive as possible, using the specified terminology after review and acceptance by all members of the local health care team.

Conclusion

This report is a culmination of work done by the ISNPCHD to classify VSDs, and it represents years of meetings and debates by the members of the Society. It is meant to be an organic and continuously evolving classification system that will likely change with field testing and advances in scientific knowledge. The terms attributed herein to the various types of VSDs have been accepted by the World Health Organization for incorporation into the ICD-11. They provide the medical community with a standardized way to name these lesions, enhancing national and international quality assurance and improvement efforts as well as multicenter research for individuals with CHDs.

References

1. Franklin RCG, Béland MJ, Colan SD, Walters HL, Aiello VD, Anderson RH, et al. Nomenclature for congenital and paediatric cardiac disease: the International Paediatric and Congenital Cardiac Code (IPCCC) and the Eleventh Iteration of the International Classification of Diseases (ICD-11). *Cardiol Young*. 2017;27(10):1872-938.
2. Bailliard F, Spicer DE, Mohun TJ, Henry GW, Anderson RH. The problems that exist when considering the anatomic variability between the channels that permit interventricular shunting. *Cardiol Young*. 2015;25(1):15-28.
3. Anderson RH, Spicer DE, Giroud JM, Mohun TJ. Tetralogy of Fallot: nosological, morphological, and morphogenetic considerations. *Cardiol Young*. 2013;23(6):858-66.
4. Becu LM, Burchell HB, Dushane JW, Edwards JE, Fontana RS, Kirklin JW. Anatomic and pathologic studies in ventricular septal defect. *Circulation*. 1956;14(3):349-64.
5. Soto B, Becker AE, Moulaert AJ, Lie JT, Anderson RH. Classification of ventricular septal defects. *Br Heart J*. 1980;43(3):332-43.
6. Hagler DJ, Edwards WD, Seward JB, Tajik AJ. Standardized nomenclature of the ventricular septum and ventricular septal defects, with applications for two-dimensional echocardiography. *Mayo Clin Proc*. 1985;60(11):741-52.
7. Wells WJ, Lindesmith GG. Ventricular septal defect. In: Arcineagas E, editor. *Pediatric Cardiac Surgery*. Chicago, IL: Year Book Medical; 1985. p. 141-53.
8. Van Praagh R, Geva T, Kreutzer J. Ventricular septal defects: how shall we describe, name and classify them? *J Am Coll Cardiol*. 1989;14(5):1298-9.
9. Soto B, Ceballos R, Kirklin JW. Ventricular septal defects: a surgical viewpoint. *J Am Coll Cardiol*. 1989;14(5):1291-7.
10. Jacobs JP, Burke RP, Quintessenza JA, Mavroudis C. Congenital Heart Surgery Nomenclature and Database Project: ventricular septal defect. *Ann Thorac Surg*. 2000;69(4 Suppl):S25-35.

11. Mostefa-Kara M, Bonnet D, Belli E, Fadel E, Houyel L. Anatomy of the ventricular septal defect in outflow tract defects: similarities and differences. *J Thorac Cardiovasc Surg.* 2015;149(3):682-8 e1.
12. WHO WHO. ICD-11 Beta Draft [<https://icd.who.int/dev11/f/en#/>].
13. Franklin RC, Jacobs JP, Tchervenkov CI, Béland MJ. Bidirectional crossmap of the Short Lists of the European Paediatric Cardiac Code and the International Congenital Heart Surgery Nomenclature and Database Project. *Cardiol Young.* 2002;12(5):431-5.
14. Béland MJ, Jacobs JP, Tchervenkov CI, Franklin RCG, Report from the Executive of The International Working Group for Mapping and Coding of Nomenclatures for Paediatric and Congenital Heart Disease. *Cardiol Young.* 2002;12(5):425-30.
15. Béland MJ, Franklin RC, Jacobs JP, Tchervenkov CI, Aiello VD, Colan SD, et al. Update from the International Working Group for Mapping and Coding of Nomenclatures for Paediatric and Congenital Heart Disease. *Cardiol Young.* 2004;14(2):225-9.
16. Jacobs JP, Maruszewski B, Tchervenkov CI, Lacour-Gayet FG, Jacobs ML, Clarke DR, et al. The current status and future directions of efforts to create a global database for the outcomes of therapy for congenital heart disease. *Cardiol Young.* 2005;15 Suppl 1:190-7.
17. Jacobs JP, Franklin RC, Jacobs ML, Colan SD, Tchervenkov CI, Maruszewski B, et al. Classification of the functionally univentricular heart: unity from mapped codes. *Cardiol Young.* 2006;16 Suppl 1:9-21.
18. Tchervenkov CI, Jacobs JP, Weinberg PM, Aiello VD, Béland MJ, Colan SD, et al. The nomenclature, definition and classification of hypoplastic left heart syndrome. *Cardiol Young.* 2006;16(4):339-68.
19. Jacobs JP, Franklin RC, Wilkinson JL, Cochrane AD, Karl TR, Aiello VD, et al. The nomenclature, definition and classification of discordant atrioventricular connections. *Cardiol Young.* 2006;16 Suppl 3:72-84.
20. Jacobs JP, Anderson RH, Weinberg PM, Walters HL III, Tchervenkov CI, Del Duca D, et al. The nomenclature, definition and classification of cardiac structures in the setting of heterotaxy. *Cardiol Young.* 2007;17 Suppl 2:1-28.

21. Franklin RC, Jacobs JP, Krogmann ON, Béland MJ, Aiello VD, Colan SD, et al. Nomenclature for congenital and paediatric cardiac disease: historical perspectives and The International Pediatric and Congenital Cardiac Code. *Cardiol Young*. 2008;18 Suppl 2:70-80.
22. Kurosawa H, Becker AE. Atrioventricular conduction in congenital heart disease : surgical anatomy. Tokyo ; New York: Springer-Verlag; 1987. xii, 272 p. p.
23. Anderson RH, Spicer DE, Yoo SJ, Jacobs JP, Aiello VD. Innovation and the role of the cardiac morphologist. *Cardiol Young*. 2009;19 Suppl 2:11-25.
24. Spicer DE, Anderson RH, Backer CL. Clarifying the surgical morphology of inlet ventricular septal defects. *Ann Thorac Surg*. 2013;95(1):236-41.
25. LaCorte MA, Cooper RS, Kauffman SL, Schiller MS, Golinko RJ, Griep RB. Atrioventricular canal ventricular septal defect with cleft mitral valve. Angiographic and echocardiographic features. *Pediatr Cardiol*. 1982;2(4):289-95.

Table 1: ISNPCHD Classification Scheme for VSD (IPCCC 07.10.00) as Incorporated in ICD-11

1. Perimembranous central VSD (07.10.01)
2. Inlet VSD without a common AV junction (07.14.05) *
 - a. Inlet perimembranous VSD without AV septal malalignment and without a common AV junction (07.10.02)
 - b. Inlet perimembranous VSD with AV septal malalignment and without a common AV junction (07.14.06)
 - c. Inlet muscular VSD (07.11.02)
3. Trabecular muscular VSD (07.11.01)
 - a. Trabecular muscular VSD: midseptal (07.11.04)
 - b. Trabecular muscular VSD: apical (07.11.03)
 - c. Trabecular muscular VSD: postero-inferior (07.11.12)
 - d. Trabecular muscular VSD: anterosuperior (07.11.07)
 - e. Trabecular muscular VSD: multiple (“Swiss cheese” septum) (07.11.05)
4. Outlet VSD (07.12.00)
 - a. Outlet VSD without malalignment (07.12.09)
 - i. Outlet muscular VSD without malalignment (07.11.06)
 - ii. Doubly committed juxta-arterial VSD without malalignment (07.12.01)
 1. Doubly committed juxta-arterial VSD without malalignment and with a muscular postero-inferior rim (07.12.02)
 2. Doubly committed juxta-arterial VSD without malalignment and with a fibrous postero-inferior rim (perimembranous extension) (07.12.03)
 - b. Outlet VSD with anteriorly malaligned outlet septum (07.10.17)
 - i. Outlet muscular VSD with anteriorly malaligned outlet septum (07.11.15)
 - ii. Outlet perimembranous VSD with anteriorly malaligned outlet septum (07.10.04)

- iii. Doubly committed juxta-arterial VSD with anteriorly malaligned fibrous outlet septum (07.12.12)
 - 1. Doubly committed juxta-arterial VSD with anteriorly malaligned fibrous outlet septum and a muscular postero-inferior rim ((07.12.07)
 - 2. Doubly committed juxta-arterial VSD with anteriorly malaligned fibrous outlet septum and a fibrous postero-inferior rim (perimembranous extension) (07.12.05)
- c. Outlet VSD with posteriorly malaligned outlet septum (07.10.18)
 - i. Outlet muscular VSD with posteriorly malaligned outlet septum (07.11.16)
 - ii. Outlet perimembranous VSD with posteriorly malaligned outlet septum (07.10.19)
 - iii. Doubly committed juxta-arterial VSD with posteriorly malaligned fibrous outlet septum (07.12.13)
 - 1. Doubly committed juxta-arterial VSD with posteriorly malaligned fibrous outlet septum and a muscular postero-inferior rim (07.12.08)
 - 2. Doubly committed juxta-arterial VSD with posteriorly malaligned fibrous outlet septum and a fibrous postero-inferior rim (perimembranous extension) (07.12.06)

* The interventricular communication associated with a common AV junction (VSD component of an AV septal or AV canal defect) should be considered in the common AV junction section of the IPCC or the ICD-11 for coding purposes.

Table 2: Characteristic Anatomic Features of VSD Types with Concordant VA Connections

1. Central perimembranous defect
 - a. Opens into central part of base of ventricular mass adjacent to interventricular component of membranous septum
 - b. Covered by open septal leaflet of tricuspid valve
 - c. In area of anteroseptal commissure of tricuspid valve
 - d. Below commissure between right and non-coronary leaflets of aortic valve
 - e. Below and behind posterior limb of septal band and medial papillary muscle
 - f. Conduction system along postero-inferior rim of defect
2. Inlet defect
 - a. Can be a muscular defect or a perimembranous defect with or without AV septal alignment
 - b. Opens into inlet component of RV
 - c. Extends behind septal leaflet of tricuspid valve
 - d. Below anteroseptal commissure of tricuspid valve
 - e. Below posterior limb of septal band and papillary muscle of conus
 - f. Without and with malalignment between atrial septum and ventricular septum
 - g. Inlet perimembranous defect: conduction system along postero-inferior rim of defect
 - h. Inlet muscular defect: conduction system away from rims of defect
3. Trabecular muscular defect
 - a. Extends through the septum, thereby opening within the apical component of muscular ventricular septum
 - b. Exclusively muscular borders
 - c. Conduction system away from rims of defect
4. Outlet defect
 - a. Can be a perimembranous, muscular, or juxta-arterial defect

- b. Opens into outlet component of RV
- c. Behind or near anterior leaflet of tricuspid valve
- d. Above anteroseptal commissure of tricuspid valve
- e. Between limbs of septal band
- f. Without or with malalignment between muscular outlet septum and apical part of muscular septum
- g. Outlet perimembranous defect and juxta-arterial defect with fibrous postero-inferior rim: conduction system along postero-inferior rim of defect
- h. Outlet muscular defect and juxta-arterial defect with muscular postero-inferior rim: conduction system away from rims of defect

Figure Legends

Figure 1. Illustration of the normal ventricular septum as viewed from the right side after dissection of the parietal ventricular wall. The circular structure above and behind the anterosuperior aspect of the septal leaflet of the tricuspid valve (yellow valvar structure) is the membranous septum with the AV conduction pathway in green traversing its postero-inferior margin; the light-yellow portion of the circle represents its AV component, and the light blue portion represents its interventricular component. The septal band is the prominent muscle bar coursing from the apex to the base and bifurcating into the postero-inferior and anterosuperior limbs.

Figure 2. A) Illustration of a central perimembranous defect. The hole is behind the septal leaflet of the tricuspid valve, below the right and/or non-coronary leaflets of the aortic valve, and below the postero-inferior limb of the septal band. Notice the conduction pathway in green coursing along the postero-inferior rim. B) Pathology specimen of a central perimembranous defect below the medial papillary muscle and postero-inferior limb of the septal band.

Figure 3. A) Illustration of an inlet perimembranous defect with aligned atrial septum and ventricular septum. Notice the abnormally inferior AV node and conduction pathway coursing along the postero-inferior rim (dotted line). B) Pathology specimen of an inlet perimembranous defect opening into the RV inlet below the anteroseptal commissure of the tricuspid valve; the defect extends along and is mostly covered by the septal leaflet of the tricuspid valve.

Figure 4. A) Illustration of an inlet muscular defect which opens into the RV inlet and has exclusively muscular borders. Notice that the AV conduction pathway is located near but not at the superior border. This illustration also depicts an outlet muscular defect; inlet and outlet muscular defects are not coded as trabecular muscular defects. B) Pathology specimen of an inlet muscular defect with exclusively muscular borders opening into the RV inlet.

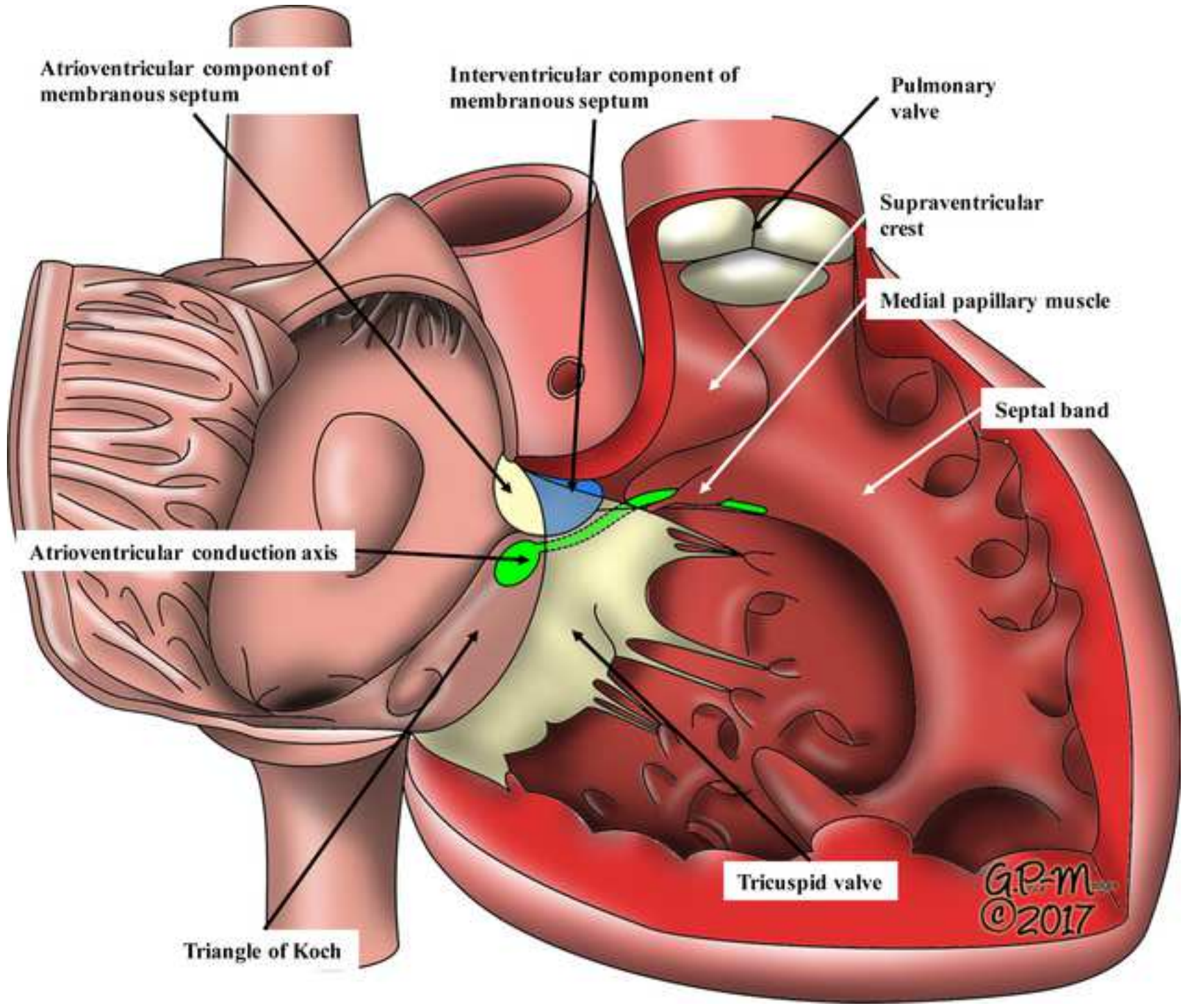
Figure 5. A) Illustration of an inlet perimembranous defect with malalignment of the atrial septum and postero-inferior part of the ventricular septum. The tricuspid valve straddles the defect with attachments to the left ventricle. Notice the abnormally inferior AV node and conduction pathway coursing along the

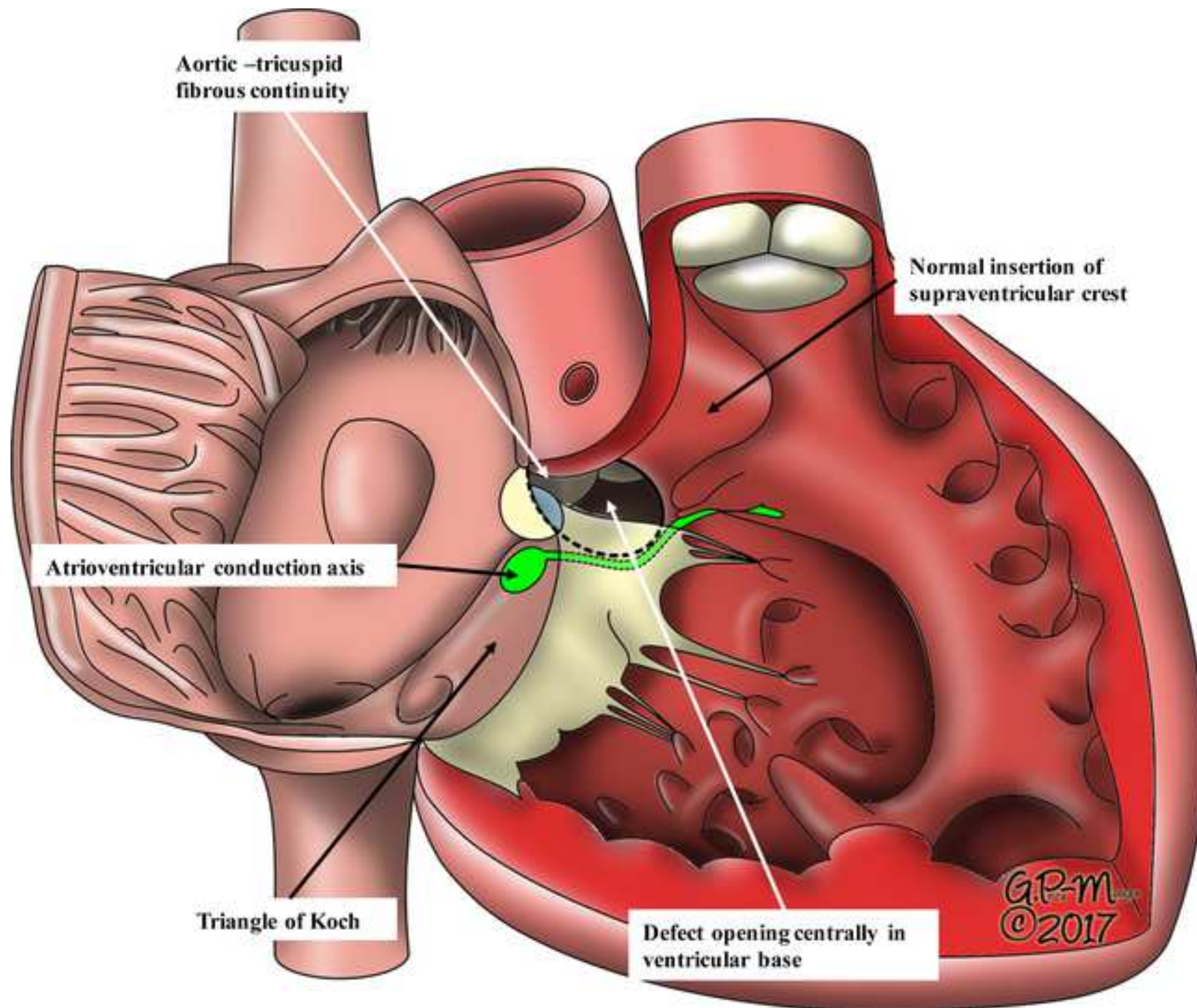
postero-inferior rim. B) Pathology specimen of an inlet perimembranous defect with AV septal malalignment and a straddling tricuspid valve.

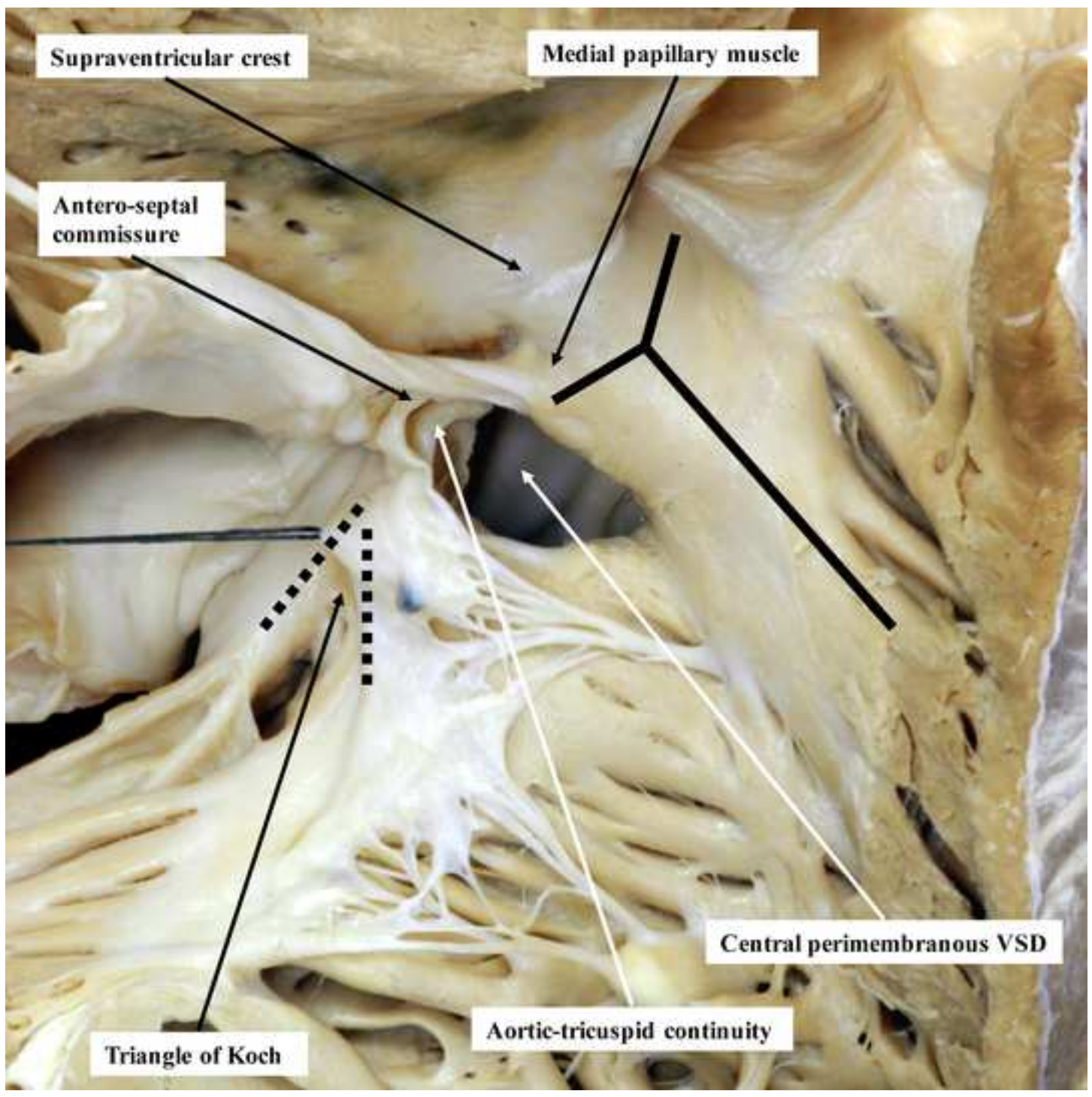
Figure 6. A) Illustration of trabecular muscular defects located in the midseptal, postero-inferior, apical, and anterosuperior aspects of the muscular trabecular septum. B) Pathology specimen of a large postero-inferior muscular trabecular defect with the inferior margin at the diaphragmatic wall of the ventricle.

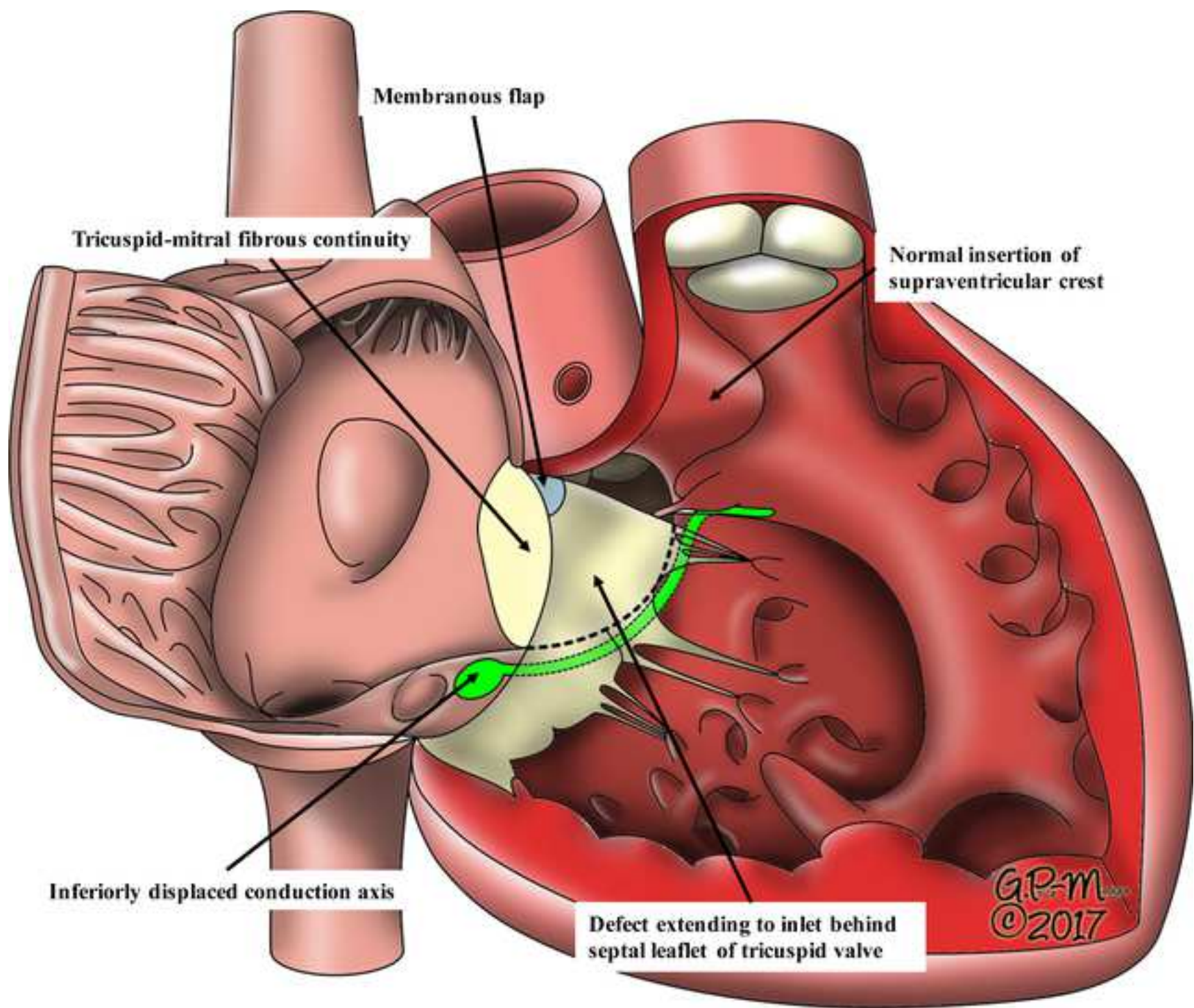
Figure 7. A) Illustration of an outlet perimembranous defect located between the limbs of the septal band and extending to the area of fibrous continuity between the tricuspid and aortic valves. Notice the malaligned muscular outlet septum. B) Pathology specimen of an outlet perimembranous defect opening into the RV outlet between the limbs of the septal band.

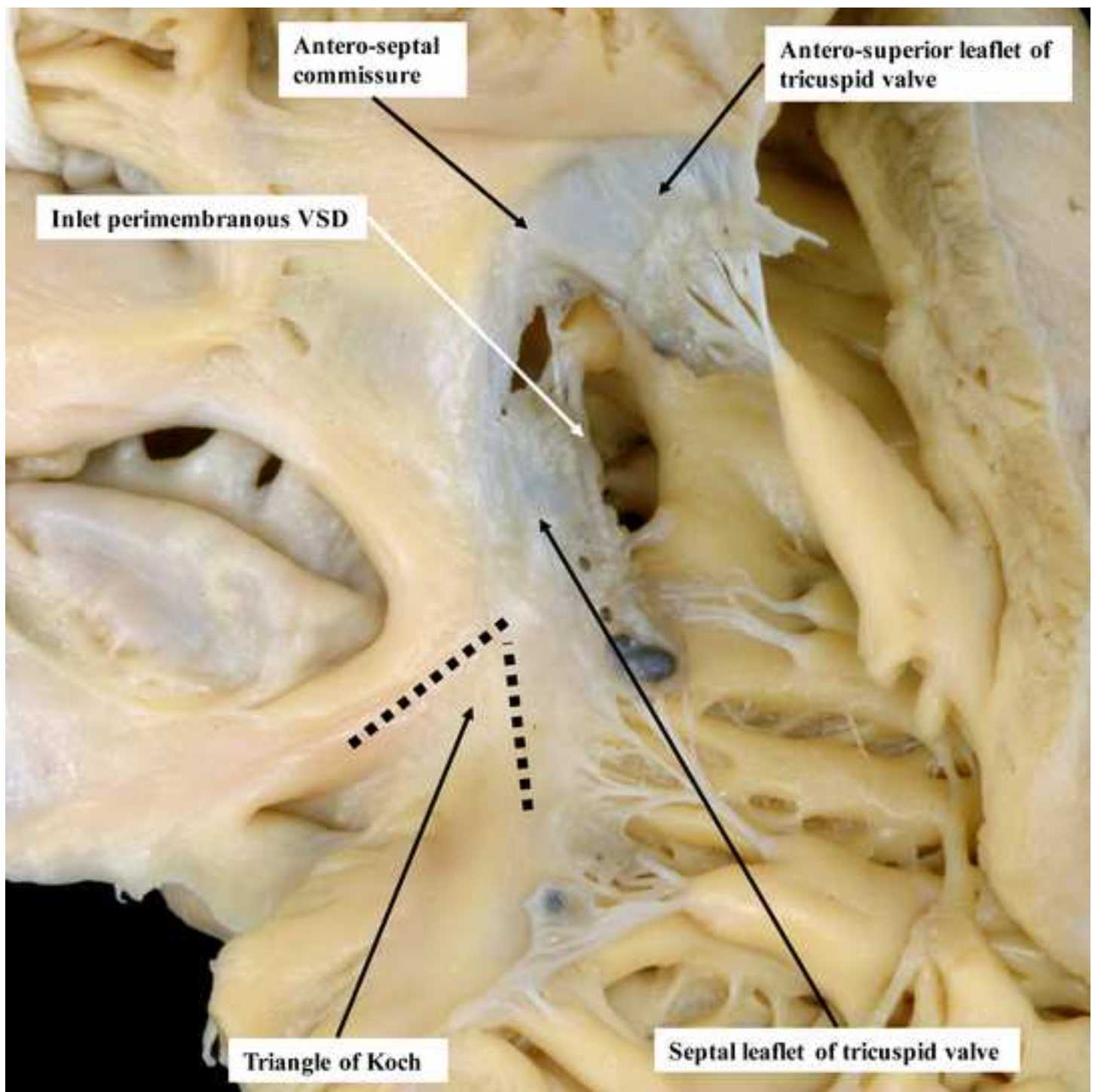
Figure 8. A) Illustration of a doubly committed juxta-arterial defect adjacent to the area of fibrous continuity between the arterial valves. Notice that the conduction pathway is remote from the defect. B) Pathology specimen of a doubly committed juxta-arterial defect located immediately below the area of fibrous continuity between the arterial valves and between the limbs of the septa band; the defect has a muscular postero-inferior rim and does not extend to the area of fibrous continuity between the tricuspid and the aortic valves.

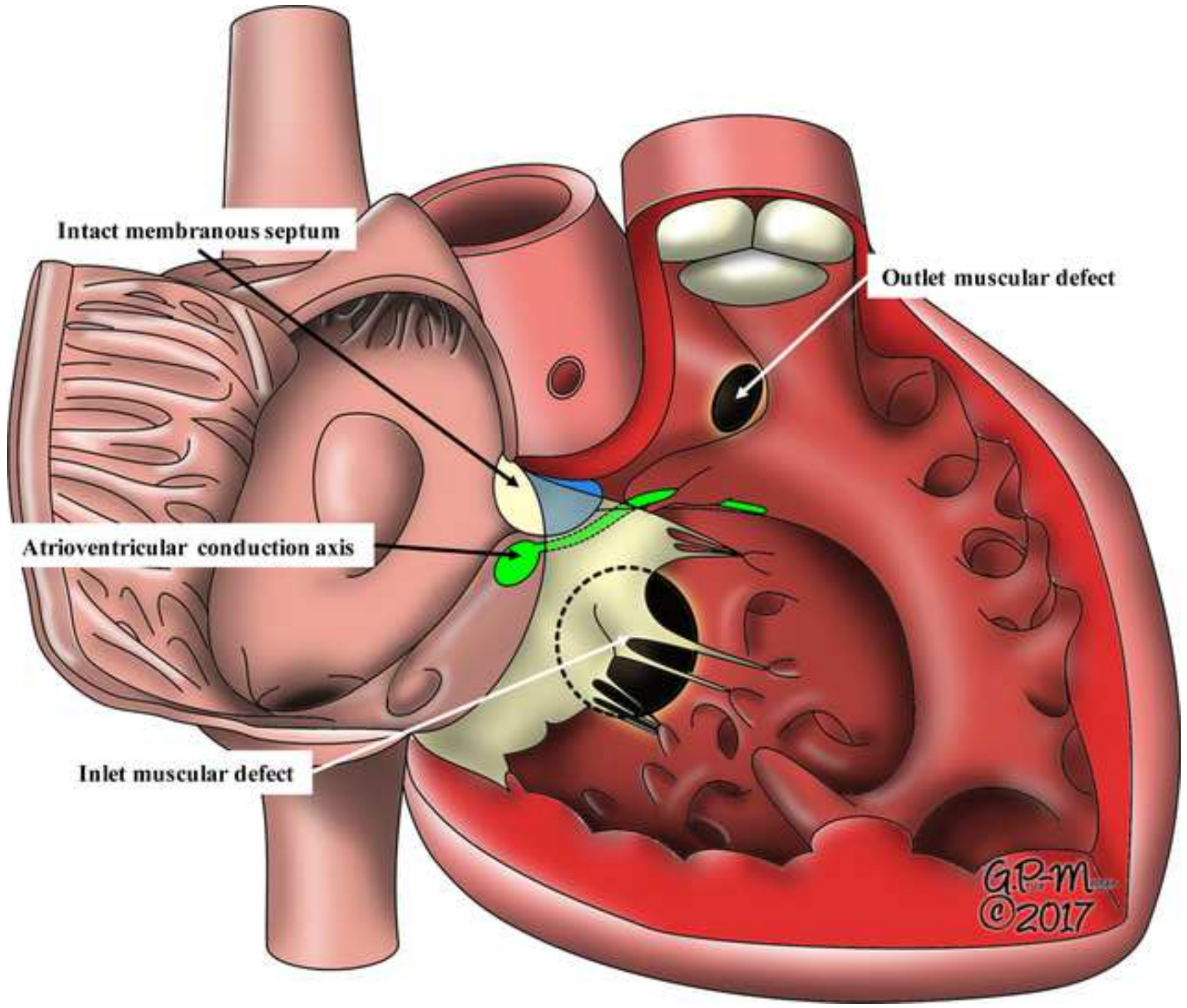


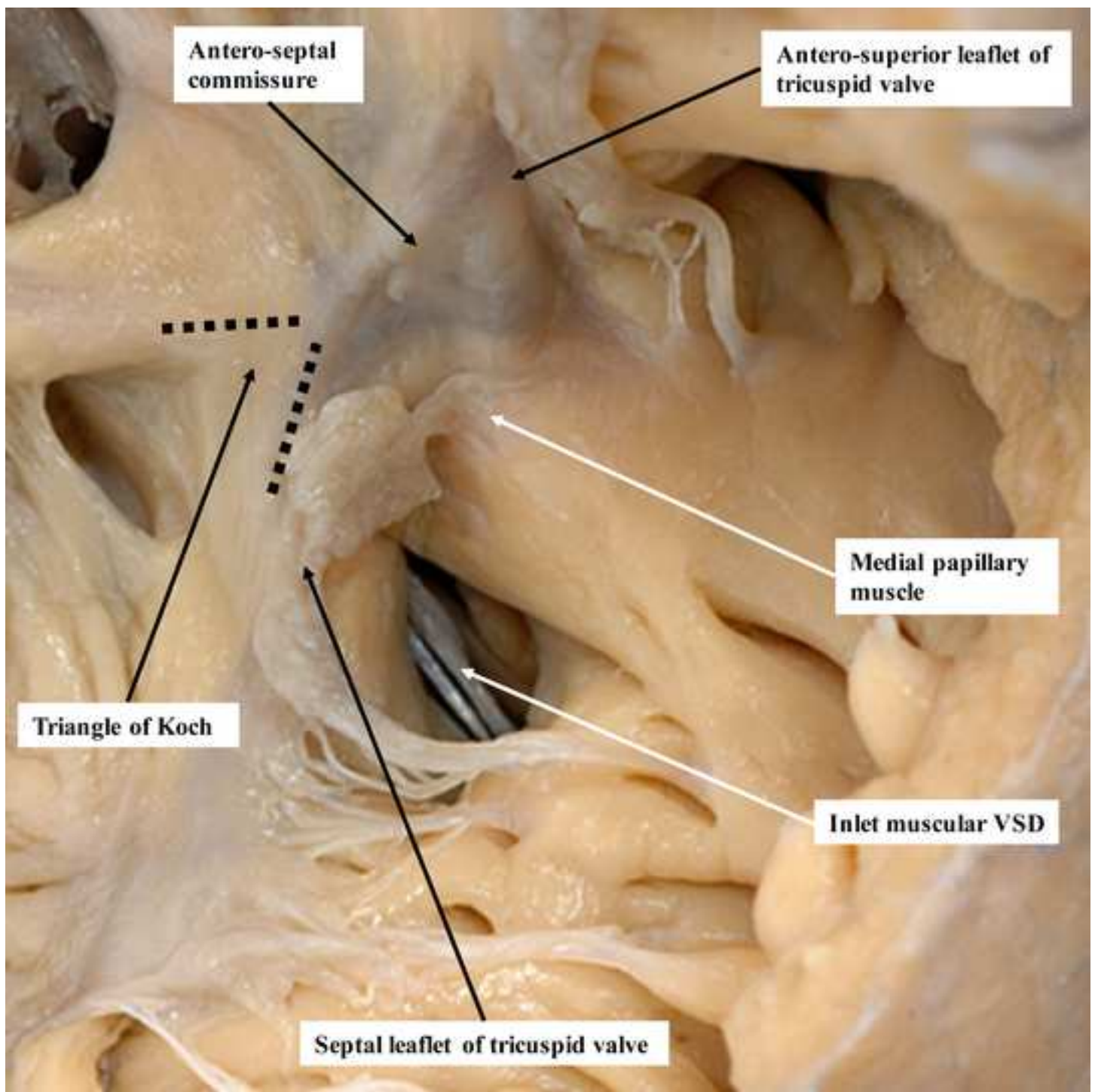


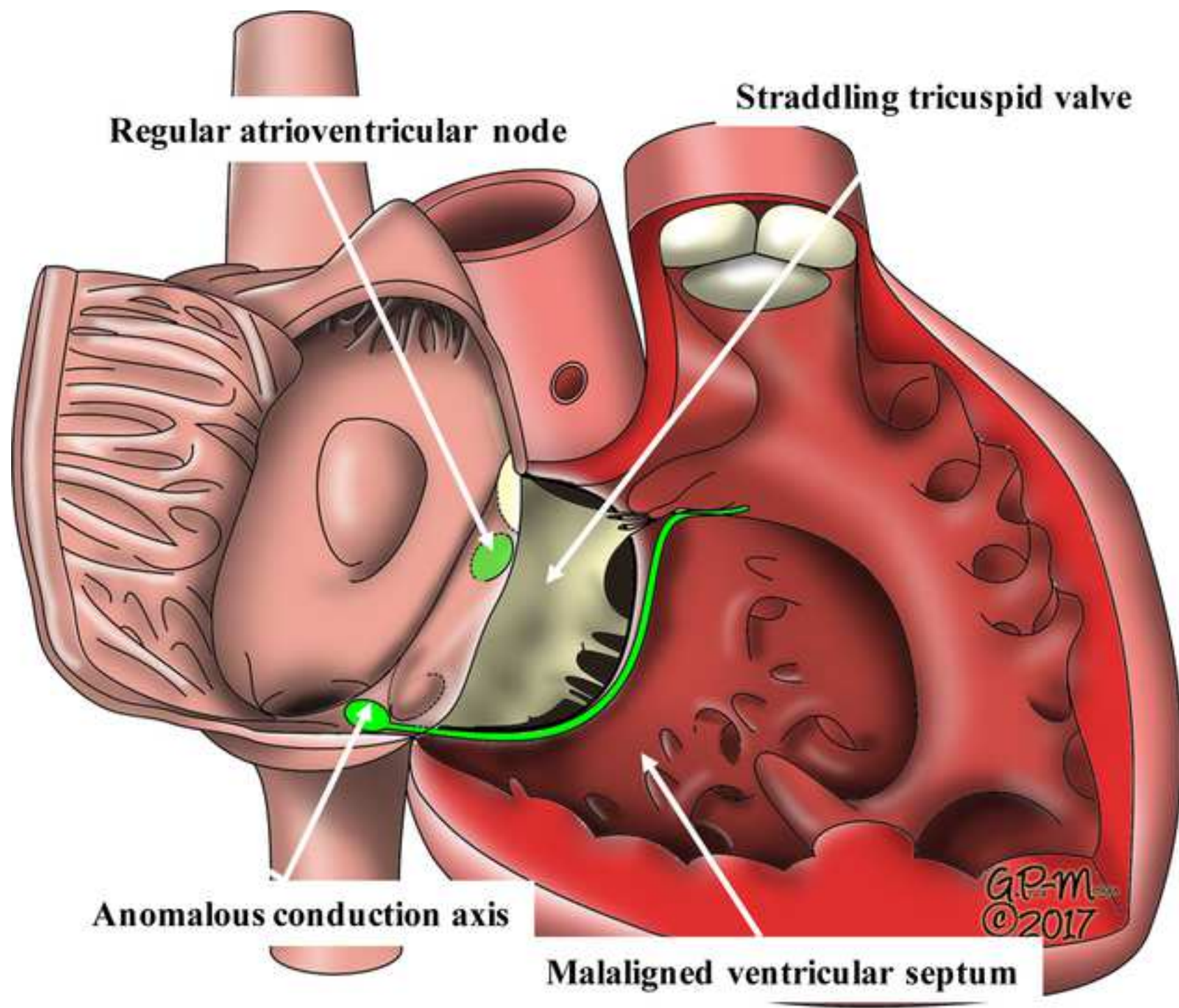


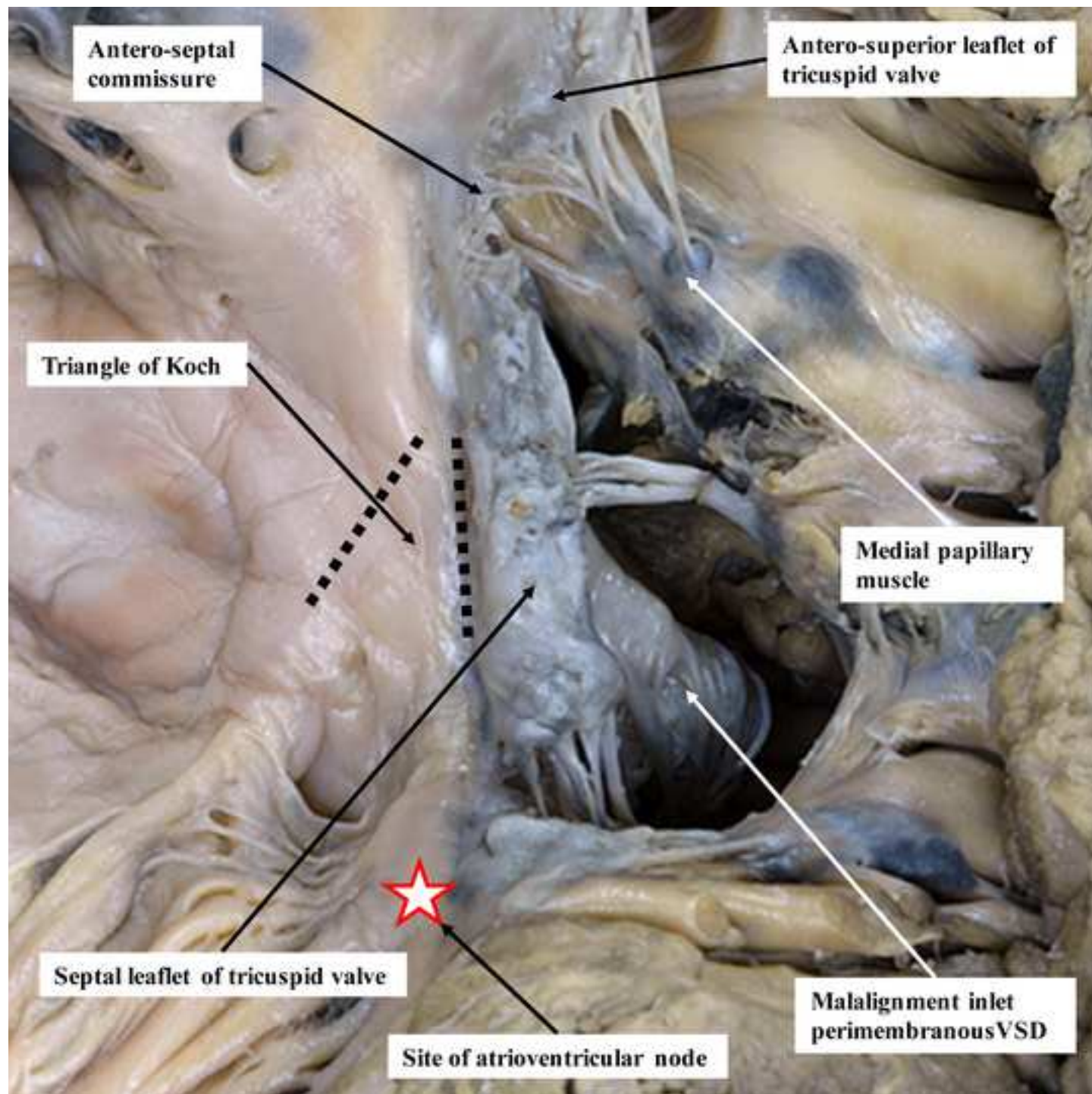


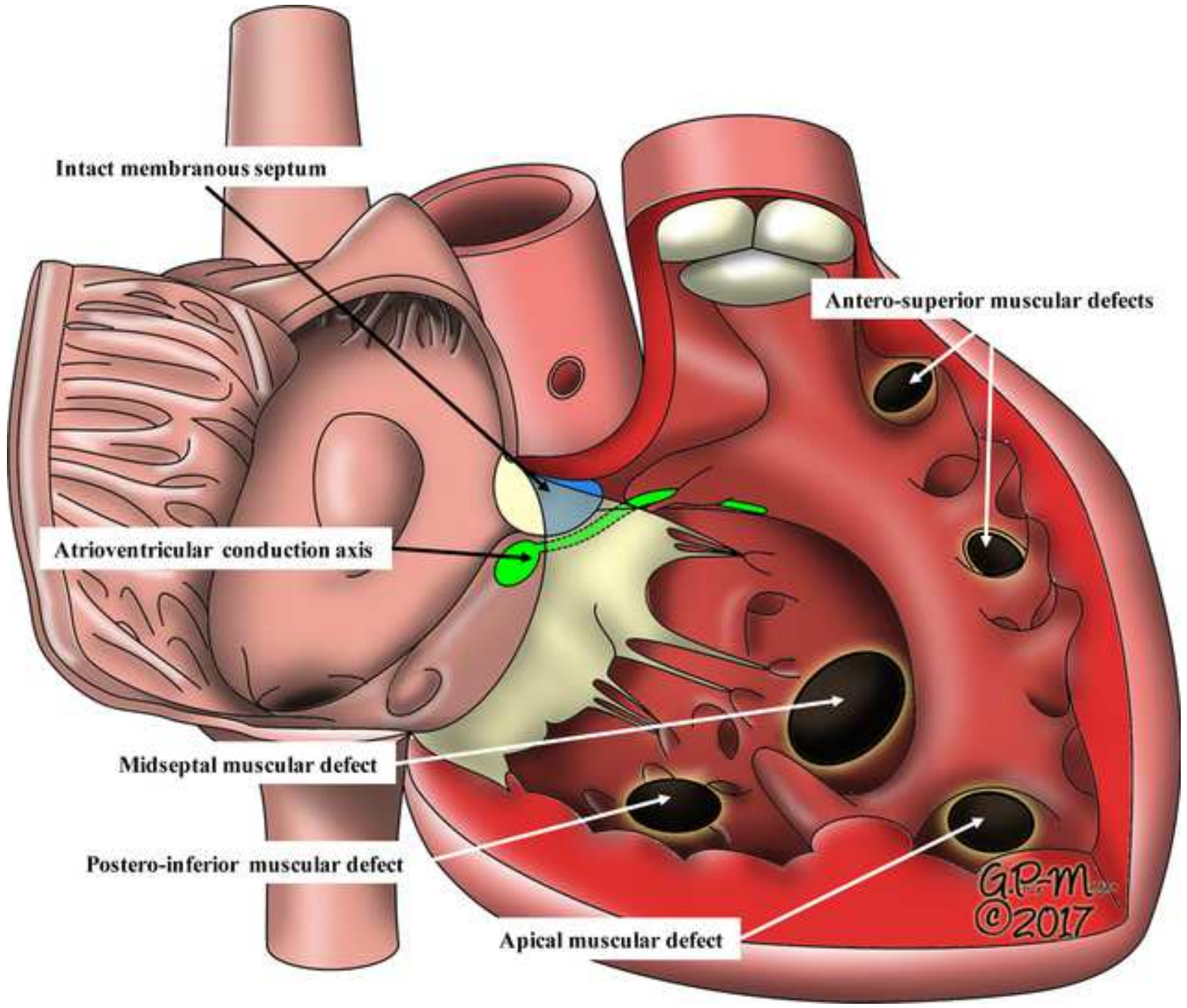


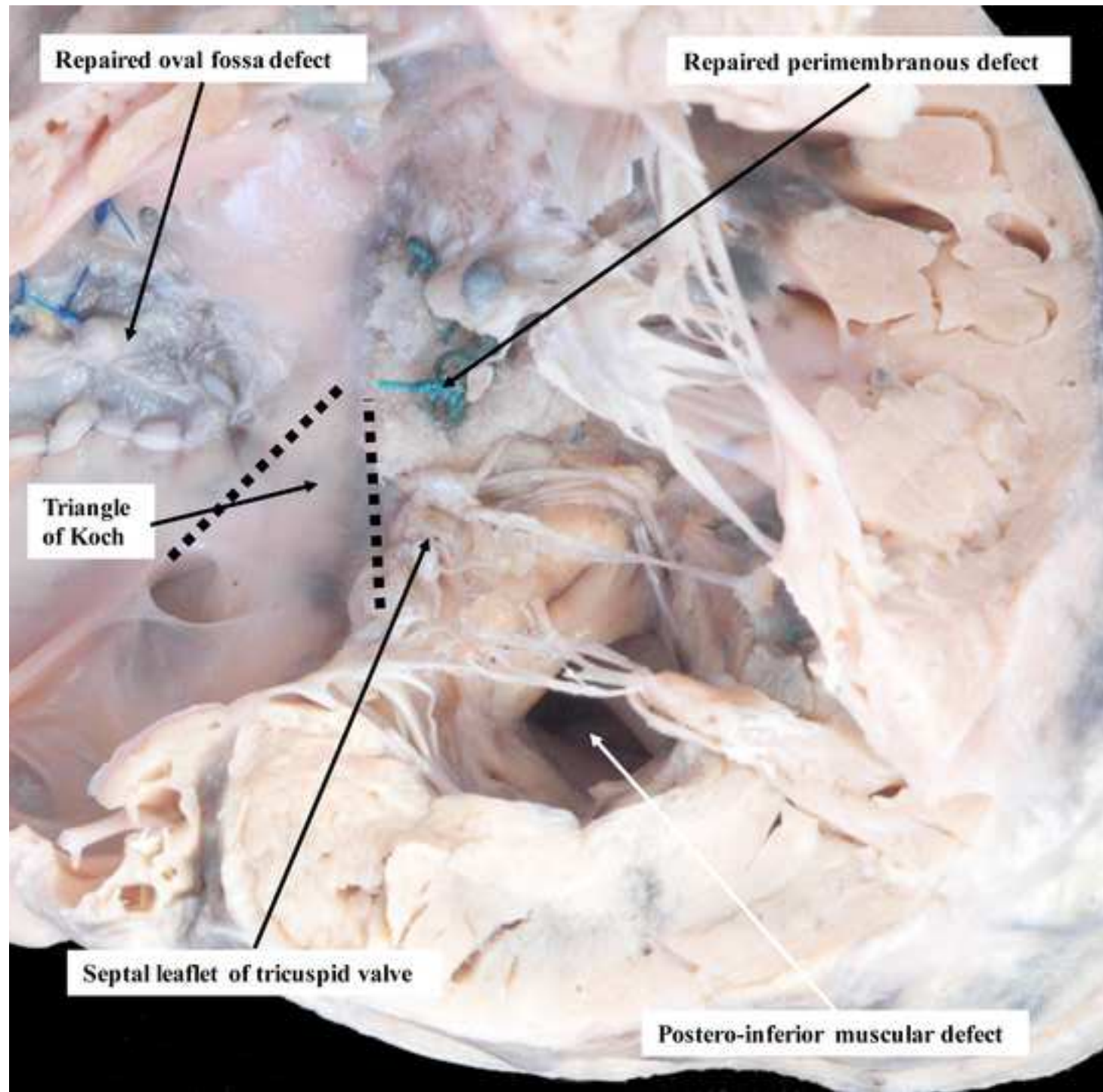


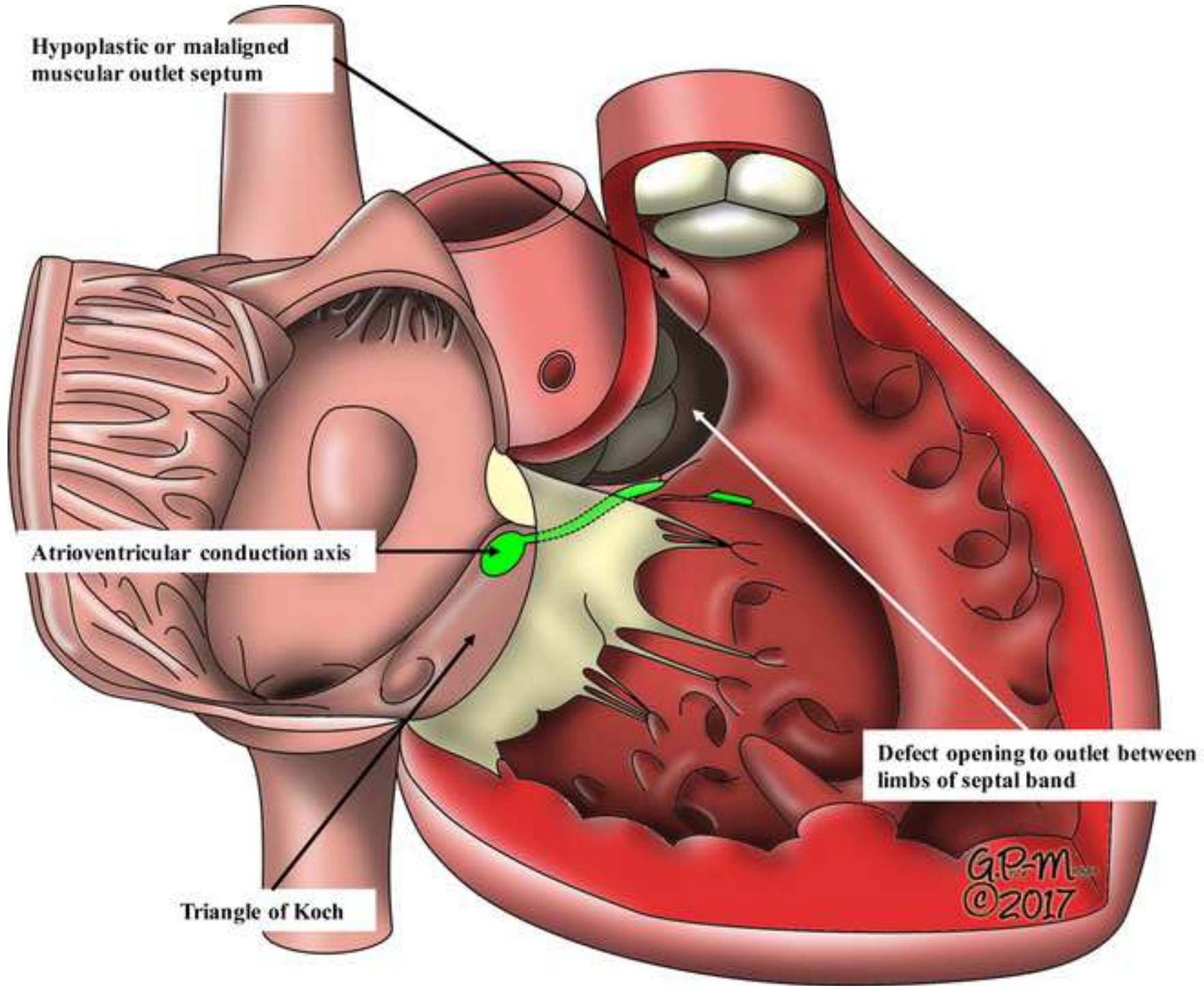


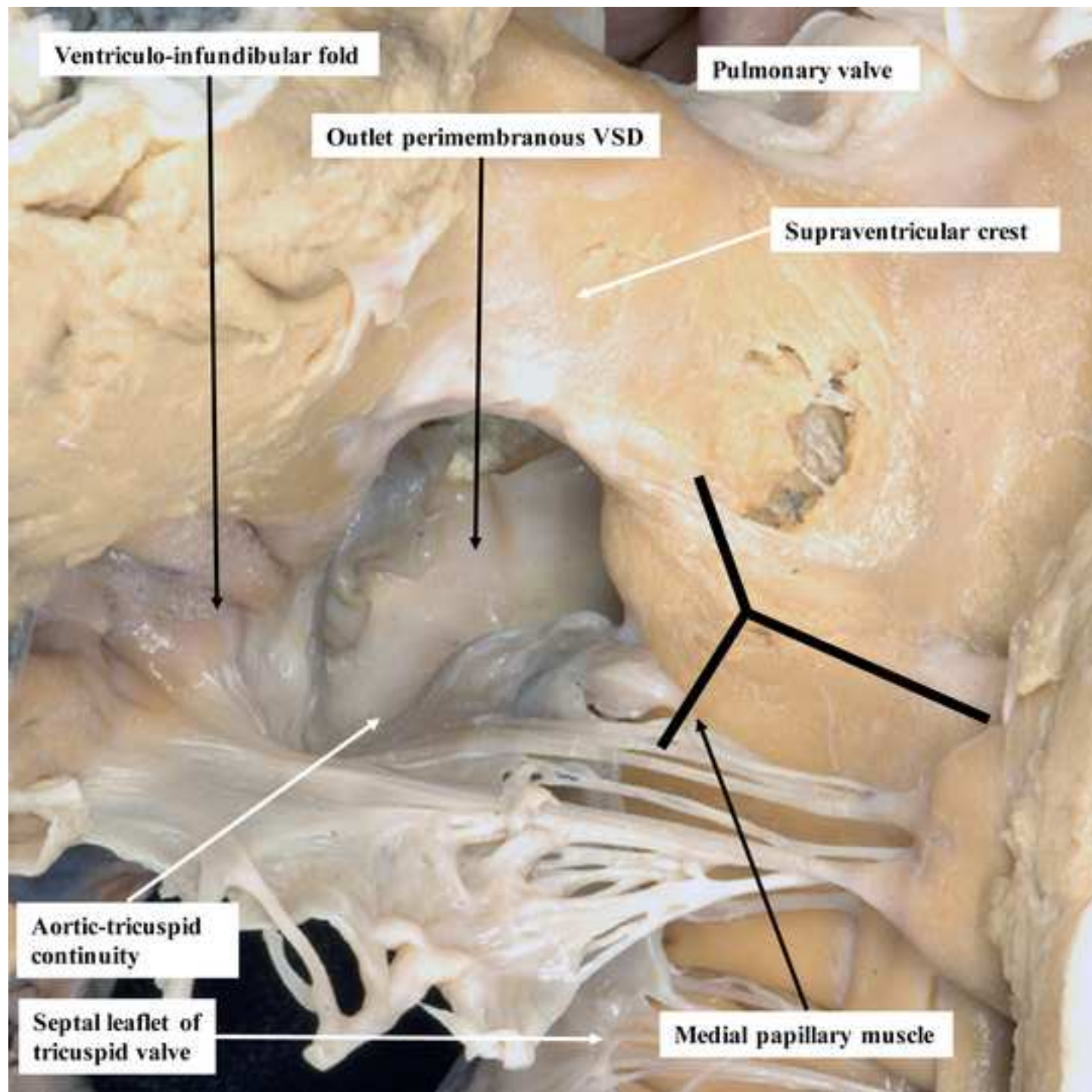


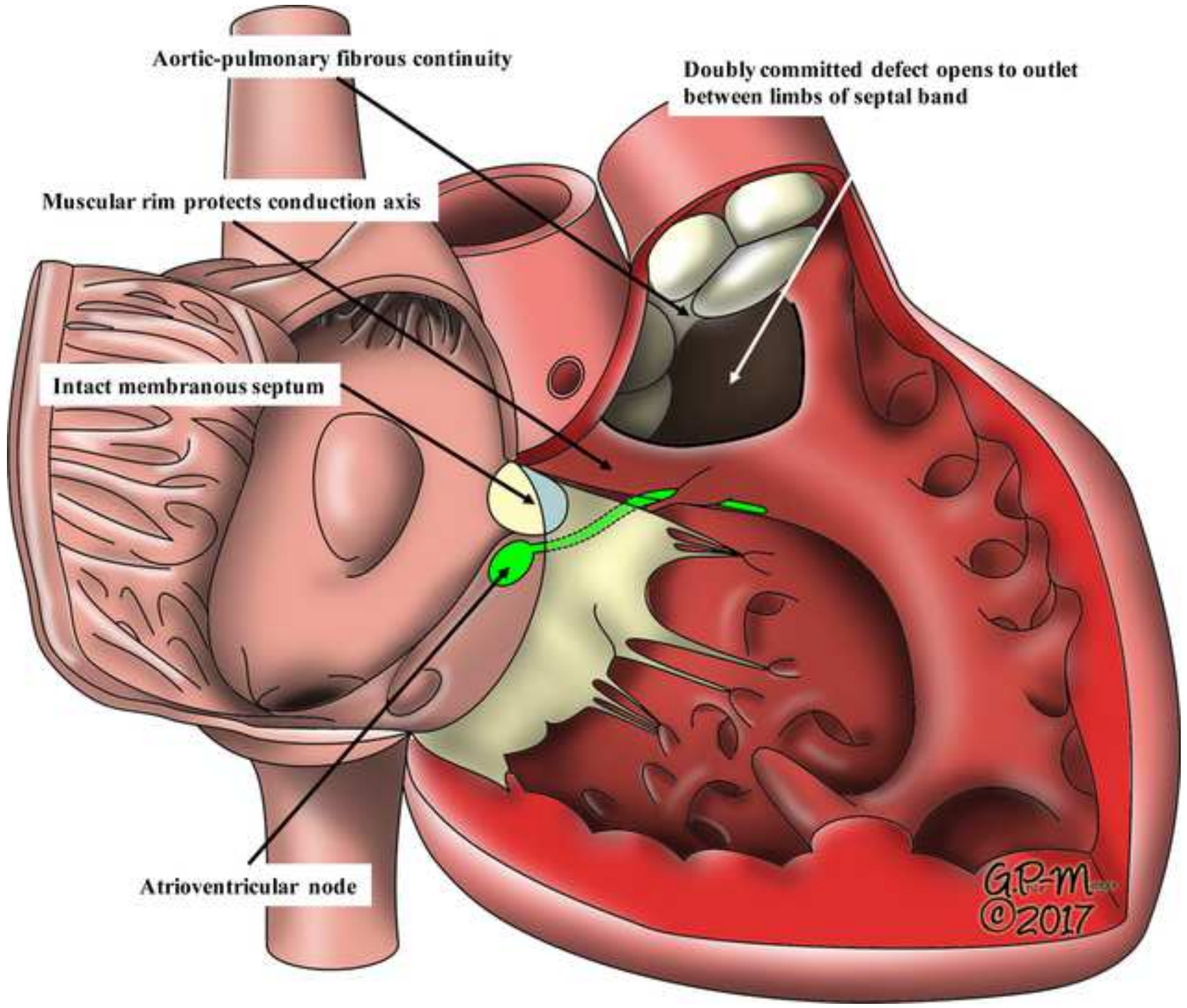


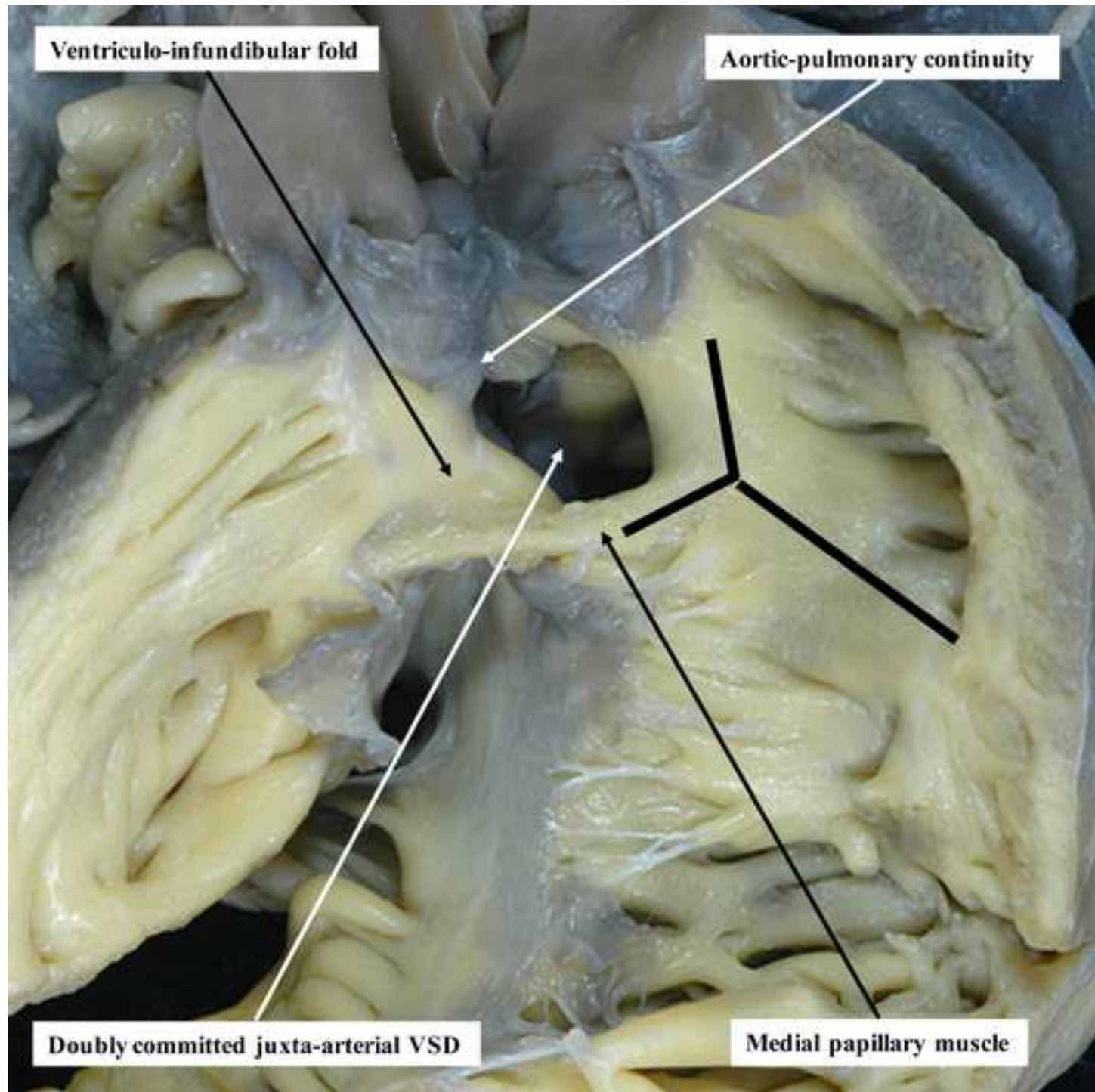















Click here to access/download

**Supplemental/Appendix material (suppl. tables, figures,
etc.)**

VSD Consensus ISNPCHD.Appendix.ATS.docx





Click here to access/download

**Supplemental/Appendix material (suppl. tables, figures,
etc.)**

Figure S1A.tif






Click here to access/download

**Supplemental/Appendix material (suppl. tables, figures,
etc.)**

Figure S1B.tif





Click here to access/download

**Supplemental/Appendix material (suppl. tables, figures,
etc.)**

Figure S1C.tif



Leo Lopez, MD, FACC, FAAP, FASE
Medical Director, Noninvasive Cardiac Imaging
Associate Chief, Cardiovascular Medicine
Nicklaus Children's Hospital
3100 SW 62nd Avenue
Ambulatory Building, 2nd Floor
Miami, Florida 33155-3009
Phone: 786-624-5365
Email: lelopezmd@gmail.com

6 June 2018

G. Alexander Patterson, MD
Editor, *The Annals of Thoracic Surgery*
The Society of Thoracic Surgeons
633 N St. Clair Street, 21st Floor
Chicago, IL 60611-3658
Email: theannals@sts.org

Dear Dr. Patterson,

On behalf of the International Society for Nomenclature of Paediatric and Congenital Heart Disease (ISNPCHD), we truly appreciate the rapid response to our submission entitled "Classification of ventricular septal defects for the eleventh iteration of the International Classification of Diseases – striving for consensus: A report from the International Society for Nomenclature of Paediatric and Congenital Heart Disease." The comments from the reviewers were very helpful, and we have revised the document to address their concerns and suggestions. The specific responses to the reviewer comments are listed at the end of this letter.

We discussed the issue of authorship with the leadership of the ISNPCHD, and we request that the authorship for this document does not change. Although, as pointed out by Reviewer #1, many consensus documents are written by only a small sub-group of people, this manuscript truly represents consensus that was five years in the making, entailing countless electronic communications and multiple face-to-face meetings involving 32 cardiologists, cardiac surgeons, and morphologists from four continents. As such, we feel that it is very important to include all the people who dedicated a significant amount of time, effort, intellectual input, and compromise to this project – these are all the authors listed in the manuscript.

Please do not hesitate to contact me if you have any questions.

Sincerely,

A handwritten signature in black ink that reads "Leo Lopez" followed by a stylized flourish.

Leo Lopez, MD, FACC, FAAP, FASE

Reviewer Comments and Responses:

Reviewer #1: This is a very useful paper and it represents an enormous effort on the part of the authors and their colleagues. The task is nearly impossible and they have done a good job looking at all of the nuances. I think the paper needs only minor edits, and I can offer a few queries and comments:

1. There are 32 authors, this might approach the record. Did everybody listed actually contribute to the paper? Or are these just the names of everybody who attended the sessions. Based on my own experience with such initiatives such papers usually are written by a small sub-group. *We have addressed this comment in the letter above.*
2. "Group of international experts" is an interesting comment. Many of the authors are experts because they say that they are. Maybe that could be phrased differently to sound less self-serving. *We appreciate this comment and have revised this statement to say "group of international specialists" on page 3.*
3. "Geographic location" seems redundant to me. Aren't all locations geographic? *We have omitted the word "geographic" from this statement on page 3.*
4. The most common Italian term for VSD is "difetto interventricolare" which is not a literal translation of ventricular septal defect. *We have removed Italian from the list of languages on page 4.*
5. The embryonic discussion is not helpful and could easily be eliminated to shorten the paper. Specifically, the strategy here is not really based on embryology but to phenotype at the time of observation. *This is a valid point, Consequently, the embryology section has been removed from the main body of the manuscript. We are now proposing to include this section as a supplemental appendix.*
6. Page 8: 'pathologic reports'? *This has been changed to "reports based on pathologic specimens."*
7. Where does the term "daughter lesions" come into play in this discussion? To most medical specialists this term is used for neoplasms, echinococcal (hydatid) cysts, and the like. I would definitely re-word that to avoid invoking new and confusing non-essential terms. *We have revised the terminology in the document so that references to parent and daughter terms are now listed as "first-order" and "second-order" terms.*

The paper is really quite good otherwise. The illustrations are some of the best I have seen, although we could have used some trans tricuspid ("surgeons") views. Part of the "acceptance" issue is that different practitioners see the pathology from different vantage points. I enjoyed reading the manuscript, and once again congratulations to the authors for taking on this nearly impossible task. *We thank the reviewer for these comments.*

Reviewer #2: I thank the authors to have brought some clarity in this confused field. The manuscript is somewhat lengthy and incorporates some repetitions and I am wondering if it should not be shortened. (e.g., page 5 and 6, page 10, page 11 and 12). *A discussed above, we have removed the entire embryology section from the body of the manuscript and are proposing to include it as a supplemental appendix to the document. In addition, we have revised the manuscript, particularly the pages listed here, to remove repetitious statements and references.*

At the bottom of page 4 - beginning of page 5. It is unclear (without checking the reference 1) whether the quoted segment has been incorporated in ICD 11. The purpose of this statement is unclear as the increased knowledge brought by this statement is not self-explanatory. *The quoted discussion on pages 4 – 5 is from the ICD-11 beta list and also incorporated into reference #1 by Franklin, et al. In addition, we have added the following sentence to clarify the significance of the quoted statement: "In order to clarify the definition of a VSD and highlight the controversies related to classification, the ISNPCHD has provided the following commentary in ICD-11 [1]."*

Table 2. Is the terminology "base" of ventricular mass well defined? *We have combined the first two elements of the section on central perimembranous defect to address this comment: "Opens into the*

central part of the base of the ventricular mass adjacent to the interventricular component of the membranous septum.”

Similarly, "behind" the septal leaflet? *We have replaced this element with the following: “Covered by open septal leaflet of the tricuspid valve.”*

Reviewer #3: Lopez and colleagues describe the development of a unified system for classification and description of VSD's by the International Society for Nomenclature of Pediatric and Congenital Heart Disease. This work spanned multiple years and the authors should all be commended for the tremendous effort put into this important endeavor. The manuscript, figures, and tables are clearly presented, and this will be a landmark paper in our field. My only suggestion is whether in table 1 the authors would consider adding some description of the "synonym" terms from other/older nomenclature to clarify this and facilitate the transition to hopefully using this newer terminology moving forward. This is discussed in the text, but it may be helpful in the tables as well. *We are hesitant to list synonyms in the table because many of the common terms do not map exactly to one of the different types of VSDs in our classification system and may result in more confusion. For example, type 4 VSDs as defined by the STS actually include trabecular muscular VSDs as well as inlet muscular and outlet muscular VSDs.*

Title: Classification of ventricular septal defects for the Eleventh Iteration of the International Classification of Diseases – striving for consensus: A report from the International Society for Nomenclature of Paediatric and Congenital Heart Disease

Running Head: Classification of ventricular septal defects – striving for consensus

Authors: Leo Lopez, MD,¹ Lucile Houyel, MD,² Steven D. Colan, MD,³ Robert H. Anderson, BSc, MD, FRCPath, FRCS Ed (Hon),⁴ Marie J. Béland, MDCM,⁵ Vera D. Aiello, MD, PhD,⁶ Frederique Bailliard, MD, MS,⁷ Meryl S. Cohen, MD,⁸ Jeffrey P. Jacobs, MD,⁹ Hiromi Kurosawa, MD,¹⁰ Stephen P. Sanders, MD,³ Henry L. Walters III, MD,¹¹ Paul M. Weinberg, MD,⁸ Jeffrey R. Boris, MD,⁸ Andrew C. Cook, PhD,¹² Adrian Crucean, MD, MS, PhD,¹³ Allen D. Everett, MD,¹⁴ J. William Gaynor, MD,⁸ Jorge Giroud, MD,⁹ Kristine J. Guleserian, MD,¹ Marina L. Hughes, DPhil, MRCP, FRACP,¹⁵ Amy L. Juraszek, MD,¹⁶ Otto N. Krogmann, MD,¹⁷ Bohdan J. Maruszewski, MD, PhD,¹⁸ James D. St. Louis, MD,¹⁹ Stephen P. Seslar, MD, PhD,²⁰ Diane E. Spicer, BS, PA,²¹ Shubhika Srivastava, MBBS,²² Giovanni Stellin, MD,²³ Christo I. Tchervenkov, MD,²⁴ Lianyi Wang, MD,²⁵ Rodney C. G. Franklin, MD²⁶

Institutions and Affiliations: ¹Heart Program, Nicklaus Children’s Hospital, Miami, Florida, USA;

²Department of Congenital Cardiac Surgery, Marie-Lannelongue Hospital, Le Plessis-Robinson, France;

³Department of Cardiology, Boston Children’s Hospital, Boston, Massachusetts, USA; ⁴Institute of Genetic Medicine, Newcastle University, Newcastle-upon-Tyne, UK; ⁵Division of Paediatric Cardiology, Montreal Children’s Hospital, McGill University Health Centre, Montréal, Québec, Canada; ⁶Heart Institute (InCor), University of São Paulo School of Medicine, São Paulo, Brazil; ⁷Bailliard Henry Pediatric Cardiology, Raleigh, North Carolina, USA; ⁸Cardiac Center, Children’s Hospital of Philadelphia, Philadelphia, Pennsylvania, USA; ⁹Heart Institute, Johns Hopkins All Children’s Hospital, St Petersburg, Florida, USA; ¹⁰Cardiovascular Surgery, Tokyo Women’s Medical University, Tokyo, Japan; ¹¹Children’s Hospital of Michigan, Wayne State University School of Medicine, Detroit, Michigan, USA; ¹²Research Department of Children’s Cardiovascular Disease, UCL Institute of Cardiovascular Science, London, UK; ¹³Birmingham Women’s and Children’s Foundation Trust Hospital, University of Birmingham, Birmingham, UK; ¹⁴Division of Pediatric Cardiology, Johns

Hopkins Hospital, Baltimore, Maryland, USA; ¹⁵Great Ormond Street Hospital for Children, London, UK; ¹⁶University of Florida College of Medicine [Jacksonville](#), Jacksonville, Florida, USA; ¹⁷Paediatric Cardiology – Congenital Heart Disease, Heart Center Duisburg, Duisburg, Germany; ¹⁸Department for Paediatric and Congenital Heart Surgery, Children’s Memorial Health Institute, Warsaw, Poland; ¹⁹Department of Surgery, University of Missouri Kansas City School of Medicine, Kansas City, Missouri, USA; ²⁰Department of Pediatrics, Division of Pediatric Cardiology, Seattle Children’s Hospital, University of Washington, Seattle, Washington, USA; ²¹Department of Pediatric Cardiology, Congenital Heart Center, University of Florida, Gainesville, Florida, USA; ²²Icahn School of Medicine, Children’s Heart Center, Mount Sinai Hospital, New York, New York, USA; ²³Department of Cardiothoracic and Vascular Sciences, Pediatric and Congenital Cardiac Surgical Unit, University of Padova, Padova, Italy; ²⁴Division of Cardiovascular Surgery, Montreal Children’s Hospital, McGill University Health Centre, Montréal, Québec, Canada; ²⁵Heart Centre, First Hospital of Tsinghua University, Beijing, China; ²⁶Paediatric Cardiology Department, Royal Brompton & Harefield NHS Trust, London, UK

Meeting Presentation: 7th World Congress of Paediatric Cardiology and Cardiac Surgery, Barcelona, Spain; July 2017

Classifications: Congenital heart disease, cardiac/pathologic anatomy, pediatric, shunts

Word Count: ~~7620~~-7172 words

Corresponding Author: Leo Lopez, MD
Nicklaus Children’s Hospital – Pediatric Cardiology
3100 SW 62nd Avenue, Ambulatory Building, 2nd Floor
Miami, Florida 33155-3009
786-624-5365
leolopezmd@gmail.com

Abstract

The definition and classification of ventricular septal defects have been fraught with controversy. The International Society for Nomenclature of Paediatric and Congenital Heart Disease is a group of international ~~experts~~ specialists in pediatric cardiology, cardiac surgery, cardiac morphology, and cardiac pathology that has met annually for the past nine years in an effort to unify by consensus the divergent approaches to describe ventricular septal defects. These efforts have culminated in acceptance of the classification system by the World Health Organization into the 11th Iteration of the International Classification of Diseases (ICD-11). The scheme to categorize a ventricular septal defect utilizes both its ~~geographic~~ location and the structures along its borders, thereby bridging the two most popular and disparate classification approaches and providing a common language for describing each phenotype. Although the ~~parent~~ first-order terms are based on the geographic categories of central perimembranous, inlet, trabecular muscular, and outlet defects, inlet and outlet defects are further characterized by descriptors that incorporate the borders of the defect, namely the perimembranous, muscular, and juxta-arterial types. The Society recognizes that it is equally valid to classify these defects by geography or borders, so the emphasis in this system is on the ~~daughter~~ second-order terms that incorporate both geography and borders to describe each phenotype. The unified terminology should help the medical community describe with better precision all types of ventricular septal defects.

Introduction

The International Society for Nomenclature of Paediatric and Congenital Heart Disease (ISNPCHD) has defined a ventricular septal defect (VSD) as *a congenital cardiac malformation in which there is a hole or pathway between the ventricular chambers* [1]. It is known as a VSD in English, ~~and German, and Italian~~ and literally translated as an interventricular communication in Spanish, French, and Portuguese. It can occur in isolation or as an integral component of complex lesions like tetralogy of Fallot, transposition, common arterial trunk, or functionally univentricular heart. Even though it is the most common congenital cardiac malformation, there is no consensus on how to describe and categorize these lesions [2]. In fact, some have suggested that the terms VSD and interventricular communication are not equal [3]. The lack of consensus occurs primarily because of three scenarios: there may be different opinions about intrinsic anatomy; there may be agreement about anatomy, but different authors have used the same term differently; or there may be different terms for the same anatomic entity. The need for consensus is well recognized, since VSDs, even in isolation, can show bewildering morphologic heterogeneity, resulting in variable definitions in the literature [4-11].

In an effort to unify divergent approaches to the description and categorization of VSDs, the ISNPCHD has proposed a classification system that utilizes the terms with their linked 6 digit codes from the International Paediatric and Congenital Cardiac Code (IPCCC) to pave the way towards consensus (Table 1). This system, which includes definitions, synonyms, and commentaries, has been accepted by the World Health Organization and incorporated into the Foundation layer of the eleventh iteration of the International Classification of Diseases (ICD-11) [1, 12]. ~~The ISNPCHD has provided the following commentary~~In order to clarify the definition of a VSD and highlight the controversies related to classification, the ISNPCHD has provided the following commentary in ICD-11 [1]:

The definitions offered for a VSD, in its various forms, will be used most frequently in the setting of patients who do not have abnormalities of either atrioventricular (AV) or ventriculo-arterial (VA) connections. The definitions themselves, however, are equally applicable for the description and categorization of holes or pathways between the ventricles when the segmental connections between the cardiac components are abnormal. The key to understanding the definitions is to appreciate that the hole or pathway between the ventricles is defined both on the basis of its geographic location within the ventricular septum and its margins as seen from the aspect of the morphologically right ventricle (RV).

The ISNPCHD is a group of committed volunteers whose primary goal since ~~its inception in~~ 2002 has been to develop a naming system for pediatric and congenital heart disease (CHD) with the following characteristics: the system is comprehensive, internally consistent, and sensitive to previous work in the field, and it strives to overcome the challenges in communication related to competing nomenclature systems [13-16]. For obvious reasons, this issue has become particularly acute with the escalating reliance on multicenter data sharing as a means of tracking outcomes and responses to therapies.

Thus, the definition of a VSD provides the epitome of the challenges facing efforts to create a common language for CHD [17-21]. The diversity of entrenched systems ~~amongst at~~ centers caring for children with CHD is significant, as is the resistance to change. This ~~topic~~ has been ~~one of~~ the most challenging ~~topic~~ faced by the ISNPCHD, ~~and t~~. This document chronicles the multi-year effort to achieve consensus, requiring compromise from all participants. The terms attempt to incorporate the views of cardiologists, surgeons, morphologists, and pathologists ~~who have trained and currently practice in~~ from programs employing the full spectrum of nomenclature systems. There is no intent to declare one terminology as correct and another as incorrect. Instead, the objective is to construct a workable system with the least ambiguity that can be achieved.

Several guiding principles have evolved during our deliberations and are worth emphasizing:

- The primary goal of the ISNPCHD is to provide a rich and unambiguous classification system for use in multicenter data consolidation initiatives, such as the World Health Organization’s ICD and the databases of the Society of Thoracic Surgeons and Association for European Paediatric and Congenital Cardiology. It is not anticipated that programs ~~relying on one of the many dialects~~ will necessarily convert to the ISNPCHD system, although it is likely that an evolution in this direction will take place over time since this system facilitates multicenter data sharing.
- Ultimately, the anatomic names ~~for anatomic findings~~ are simply words used as a means of communication. They have no prima facie “scientific” correctness or incorrectness. Their correctness is based on whether they facilitate communication and whether they achieve acceptance among cardiologists, surgeons, and morphologists.
- Nomenclature is often divorced from etymology and cannot be judged right or wrong based on whether it accurately reflects the original meaning of the word. A familiar example is the term “gradient”, which etymologically means a change per unit distance, a slope value. In contrast, it is used in cardiology to designate the absolute pressure difference between two anatomic locations. This divergence between etymology and use has not impaired understanding.
- Basing nomenclature on the continuously evolving understanding of embryology has been challenging. Endocardial cushion defect and bulboventricular foramen, for example, have been problematic terms in this regard and are no longer considered as accurate descriptions of their respective phenotypes. [For a discussion of the embryologic development of the ventricular septum, please see the Supplemental Appendix.](#)
- The nomenclature requires a hierarchical system that captures the anatomic and physiologic findings at both low and high specificity, reflecting the wide range of granularity that is clinically achieved in the variable settings wherein clinical care is delivered.

Development of the Ventricular Septum

Understanding the embryonic development of the septum may provide insight into the development of VSDs. An interventricular communication is integral to the circulatory pathway during the fourth to eighth weeks of embryonic life. After ventricular looping, the developing muscular ventricular septal crest forms the floor of the hole, and the inner heart curvature forms its roof (Figure 1A). Initially, the AV canal connects the developing left atrium to the developing left ventricle (LV). After expansion of the AV canal to incorporate the developing right atrium, the fetal heart exhibits double inlet to the developing LV and double outlet from the developing RV. With expansion of the AV canal, the RV acquires its inlet. During this intermediate developmental stage, the separating arterial roots remain above the RV (Figure 1B), so that the interventricular communication serves as the outlet for the LV. After the subaortic outflow tract is transferred to the developing LV, the interventricular communication closes. This is achieved by tissue growth from the ventricular aspect of the AV cushions, subsequently becoming the membranous part of the ventricular septum (Figure 1C).

Inappropriate completion of these developmental stages, namely transfer of the RV inlet, separation of the arterial roots with transfer of the aorta to the LV, closure of the interventricular communication, and trabecular myocardial compaction to form the ventricular septum, may be the cause of some types of VSDs encountered in postnatal life. More specifically, inlet defects with AV septal malalignment may result from failure of RV inlet transfer. Some outlet defects may result from failure during aortic transfer to the LV. Central and inlet perimembranous defects may result from failure of closure of the interventricular communication.

Classification: Geography versus Borders

Historically, the classification of VSDs has been fraught with controversy. Most systems for classification utilize either the geographic approach, which focuses on the defect location within the septum from the RV perspective, or the borders approach, which focuses on the anatomic structures adjacent to and surrounding the defect. The geographic approach helps to determine the surgical incision site (through the right atrium, RV, or pulmonary artery), whereas the borders approach helps to anticipate the location of the conduction pathway (which is not easily visible) to avoid heart block during intervention [22].

Early ~~pathologic~~ reports based on pathologic specimens to promote the geographic approach divided VSDs into defects at or distant from the ventricular outflow tracts, with the former more common than the latter [4]. Others used the location relative to the supraventricular crest with terms like “infracristal” or “supracristal.” Subsequent echocardiographic reports classified defects by specified areas of the RV septum as inlet, membranous, muscular, and outlet VSDs, with the last term involving the area between the limbs of the septal band (septomarginal trabeculation) [6]. Within the geographic framework, inlet defects were occasionally associated with a straddling tricuspid valve and malalignment between the atrial and ventricular septum, and outlet defects were frequently associated with malalignment between the outlet septum (conal septum) and the remainder of the ventricular septum. Further refinement of this classification system equated inlet defects to VSDs of the AV canal type and outlet defects to conal septal or infundibular VSDs [7, 8]. In addition, conoventricular defects encompassed membranous VSDs as well as those involving malalignment of the muscular outlet septum.

Proponents of the borders approach focused on the relationship of VSDs to the AV valves, membranous septum, muscular ventricular septum, and arterial valves, highlighting the areas of fibrous continuity between the AV and arterial valves [5, 9]. In hearts with concordant VA connections, perimembranous defects were defined by their location in the area of fibrous continuity between the tricuspid and aortic valves, representing the postero-inferior border of the defect. These defects opened towards the RV inlet or outlet. The term conoventricular defect was used instead of perimembranous or membranous defect in

one report, defining its location between the limbs of the septal band, often in association with abnormalities of the outlet septum [9]. Muscular defects had a completely muscular border located anywhere in the muscular ventricular septum. Subarterial or juxta-arterial defects were defined by an absent or fibrous outlet septum, localizing them in the area of fibrous continuity between the aortic and pulmonary valves.

More recently, the Society of Thoracic Surgeons utilized a hybrid classification system involving both borders and geography for its international database project, incorporating commonly used synonyms: type 1 (subarterial, supracristal, conal septal, infundibular), type 2 (perimembranous, paramembranous, conoventricular), type 3 (inlet, AV canal type), and type 4 (muscular) [7, 10].

Within this context, the ISNPCHD has proposed a classification scheme that begins with geography but also highlights the importance of borders to facilitate the understanding of each lesion. This system uses the terms central perimembranous, inlet, trabecular muscular, and outlet VSDs (Table 1). A similarly reasonable approach might begin with borders, using the terms perimembranous, muscular, and juxta-arterial as described above, while highlighting the geographic extent of each type of defect. Although the two approaches may seem incongruent and disparate, the individual ~~daughter-second-order~~ lesions listed under each ~~parent-first-order~~ category can be found in both classification systems, with names that are identical or nearly identical, emphasizing the interdependence of geography and borders. Therefore, the ISNPCHD classification system includes synonyms (listed as parenthetical terms in this document) for the ~~daughter-second-order~~ terms used to describe the same phenotype, underscoring the validity of both approaches. In addition, it is important to recognize that two or more defect types can co-exist in the same heart as a single confluent VSD. For example, some hearts have confluent inlet and outlet VSDs as seen in patients with tetralogy of Fallot and AV septal defect (AV canal defect).

Normal Ventricular Septal Anatomy

To fully appreciate the geography and borders of VSDs, one must understand the landmarks of a normal ventricular septum from the RV perspective (Figure 21): the membranous septum with the AV conduction pathway traversing its postero-inferior margin; the septal band (septomarginal trabeculation) with its postero-inferior and anterosuperior limbs; the medial papillary muscle (papillary muscle of the conus) which is usually located on the postero-inferior limb of the septal band and supports the anteroseptal commissure of the tricuspid valve; and the subpulmonary muscular sleeve (subpulmonary infundibulum) separating the tricuspid and pulmonary valves (not delineated in Figure 21). All of these morphologic structures can vary significantly in normal hearts. An important structure in the setting of outlet defects is the outlet septum (conal septum); its presence in normal hearts is still controversial at this time [23].

Central Perimembranous Defects

Central perimembranous defects (perimembranous central defects) are located at the center of the base of the ventricular mass in the space usually occupied by the interventricular part of the membranous septum. This defect elicits the most controversy with regard to location and name, primarily because the term “perimembranous” involves borders and not geography. It refers specifically to the fibrous nature of the postero-inferior rim of the defect, and it is used to complement the geographic definition. One margin of these VSDs usually involves the area of fibrous continuity between an AV valve and an arterial (semilunar) valve. In hearts with concordant VA connections, this is where the tricuspid and aortic valves are in fibrous continuity. It is feasible that some central perimembranous defects are in continuity exclusively between the leaflets of the AV valves without involving an arterial valve. It may also be possible for a defect that is central perimembranous in location to have completely muscular borders, and some have considered this to be a “central muscular” defect. Because there is still no consensus on the characteristics of this anatomic entity, the “central muscular” defect is not currently included in ICD-11.

Central perimembranous defects are usually located at the anteroseptal commissure behind the septal leaflet of the tricuspid valve and below the commissure between the right and non-coronary leaflets of the aortic valve. The aortic valve may prolapse through the defect into the RV, with associated distortion often resulting in aortic regurgitation. These defects are located below and behind the postero-inferior limb of the septal band, in contrast to outlet defects that open into the RV between the two limbs of the septal band [11]. The postero-inferior limb does not extend to the ventriculo-infundibular fold, thereby usually allowing for fibrous continuity between the tricuspid and aortic valves at the postero-inferior rim of the defect. As a result, the AV conduction system is vulnerable to injury as it passes through the apex of the triangle of Koch into muscle just below this postero-inferior fibrous rim (Figure 32).

Common synonyms for central perimembranous defects include membranous, perimembranous, paramembranous [8], conoventricular without conal septal malalignment, and type 2 VSDs [10]; less frequently used terms include infracristal and subaortic VSDs. The ISNPCHD has created ~~a~~-this new term, ~~central perimembranous defect~~, because of the conflicting and overlapping usage of these prior terms, frequently resulting in misinterpretation. The motivation for this approach is similar to the motivation for the recommendation by the Society of Thoracic Surgeons [10] to use neutral and abstract terms (types 1 to 4) to describe VSDs as described earlier by Wells and Lindesmith [7].

Perimembranous defects with inlet extension have been classified as perimembranous inlet defects ~~in~~ ~~some reports~~ [5] ~~and~~. ~~In addition~~, perimembranous defects with anterior outlet extension, as well as conoventricular defects with malaligned outlet septum, are generally classified as outlet defects. The ISNPCHD provides the following commentary to address these issues [1]:

Although best used to describe the perimembranous defect that opens centrally at the base of the RV, this term might be used to code perimembranous defects with inlet or outlet extension. It is recommended, however, that the more precise terms be used whenever possible for coding the

latter lesions. This code is used by some as synonymous with the perimembranous, conoventricular, Type II, or the paramembranous defects. It should not be used to code an inlet VSD, or the so-called AV canal VSD. More specific terms exist for coding these entities. It is used by some to describe an isolated perimembranous VSD without extension, although it is unlikely that perimembranous defects exist in the absence of deficiency of their muscular perimeter. The conoventricular VSD with malalignment should be coded as an outlet defect, as should the perimembranous defect opening to the outlet of the RV. [Most] perimembranous defects, nonetheless, have part of their margins made up of fibrous continuity either between the leaflets of an AV and an arterial valve or, in the setting of double outlet RV or overriding of the tricuspid valve, by fibrous continuity between the leaflets of the mitral and tricuspid valves. Such defects can also extend to become doubly committed and juxta-arterial (conal septal hypoplasia) when there is also fibrous continuity between the leaflets of the arterial valves or when there is a common arterial valve. Specific codes exist for these variants, which ideally should not be coded using this term.

When there is only minor inlet or outlet extension, differentiation of the central defect from the inlet or outlet defect may be difficult by noninvasive imaging. In these instances, direct visual inspection during surgery or morphological evaluation may be the only way to distinguish one from the other.

Inlet Defects

Inlet defects open into the RV inlet and extend along the septal leaflet of the tricuspid valve. They are located below the medial papillary muscle, postero-inferior limb of the septal band, and antero-septal commissure of the tricuspid valve. Defects with distinct and separate right and left AV junctions (distinct tricuspid and mitral valves) are included here, whereas AV septal defect variants involving a common AV junction without significant atrial shunting and with exclusive ventricular shunting should be considered

as the interventricular component of an AV septal defect and not labeled as “inlet VSDs without a common AV junction” [24, 25]. Other terms used for an inlet defect include AV canal-type defect [8], perimembranous defect with posterior inlet extension, and type 3 defect [10].

Inlet perimembranous defects (perimembranous inlet defects or perimembranous defects with postero-inferior inlet extension) are bordered anterosuperiorly by the area of fibrous continuity between the leaflets of an AV valve and an arterial valve. Because the conduction system courses along its postero-inferior rim, surgical closure must involve sutures along the annulus of the septal leaflet of the tricuspid valve away from the postero-inferior border to avoid heart block (Figure 43) [22, 24]. Inlet muscular defects (muscular inlet defects) are in a similar location, but they have exclusively muscular borders and are not continuous with AV valvar tissue (Figure 54). Unlike inlet perimembranous defects, the conduction system courses near but not along the superior border of an inlet muscular defect [22, 24].

Inlet perimembranous defects are further subdivided into those with alignment of the atrial septum and postero-inferior part of the muscular ventricular septum and those with malalignment. The former involves the area of fibrous continuity between the tricuspid and mitral valves, while the latter is always associated with a straddling and/or overriding tricuspid valve or with supero-inferior ventricles with orthogonally related atrial septum and ventricular septum. When there is malalignment, the conduction axis arises from an anomalous AV node located inferiorly and to the right where the muscular ventricular septum joins the right AV groove (Figure 65) [24].

Trabecular Muscular Defects

Trabecular muscular defects have exclusively muscular borders and are located within the apical muscular component of the ventricular septum (Figure 65A). They are not synonymous with type 4 VSDs, since this classification also includes inlet muscular and outlet muscular defects that are now

classified as inlet or outlet defects (Figure 65B) [7, 10]. Many trabecular muscular defects close spontaneously without intervention. Some are complex with multiple entrances and exits on both sides of the ventricular septum, and these are coded differently than the entity of multiple VSDs from different geographic categories. Trabecular muscular defects are the least controversial with regard to nomenclature, though there does still exist some differing approaches related to muscular defects at the RV inlet and outlet (Figure 54A). Inlet muscular defects are actually in the apical trabecular muscular septum, but they open into the RV inlet (Figure 54B). In contrast, outlet muscular defects open into the RV outlet and are formed because of failed fusion between the muscularized proximal outflow cushions and the apical trabecular muscular septum. The ISNPCHD provides the following commentary regarding this issue [1]:

Defects within the muscular part of the ventricular septum that open to the inlet or the outlet of the RV [have been] considered to be within the apical part of the ventricular septum. However, these codes specifying defects within the trabecular part of the ventricular septum should not be used to code the inlet or outlet muscular defects as more specific geographical codes have been created for these latter variants.

These VSDs are further classified by their geographic location within the trabecular muscular septum (Figure 76). The most commonly used sub-classification involves the terms midseptal, apical, postero-inferior, and anterosuperior. This approach requires a complete understanding of the spatial landmarks designating anterior, posterior, inferior, and superior locations within the trabecular muscular septum, particularly in terms of the relationship of the defect to the AV valves, moderator band, subarterial infundibulum, and arterial valves. For example, apical muscular defects are distal to the moderator band, whereas anterosuperior, midseptal, and postero-inferior defects are proximal to the moderator band. Anterosuperior muscular defects are anterior to the septal band and its limbs compared to the other trabecular muscular defects. Midseptal muscular defects are distinguished from central perimembranous

defects, since the former are embedded within the middle of the apical muscular septum (Figure 76A), while the latter open in the central part of the base of the ventricular mass (Figure 32). The distinction between a postero-inferior muscular defect (Figure 67B) and an inlet muscular defect (Figure 54B) can be difficult and somewhat arbitrary, often determined by the distance of the defect from the hinge of the septal leaflet of the tricuspid valve. In addition, the postero-inferior muscular defects are often adjacent to the diaphragmatic part of the RV, precluding transcatheter device closure because of the right angle between the septum and RV free wall and the absence of a postero-inferior muscular rim.

Outlet Defects

Outlet defects open into the RV outlet between the limbs of the septal band. They may or may not be associated with malalignment between the outlet septum and the apical part of the muscular septum [11]. They can be further subdivided into outlet perimembranous defects (perimembranous outlet defects), outlet muscular defects (muscular outlet defects), and doubly-committed juxta-arterial defects with a muscular or fibrous postero-inferior rim. Many systems for classifying outlet defects have included only those defects with hypoplastic or absent muscular outlet septum, using nomenclature like infundibular, subarterial, doubly committed subarterial, conal septal [8], intraconal, type 1 [10], subpulmonary, and supracristal VSDs. However, defects with a malaligned outlet septum are also included in this category.

Outlet perimembranous defects are usually associated with a malaligned outlet septum (Figure 87). As with central and inlet perimembranous defects, these defects usually involve discontinuity between the postero-inferior limb of the septal band and the ventriculo-infundibular fold, allowing for fibrous continuity between the tricuspid and aortic valves. Once again, the AV conduction system is vulnerable as it courses along the postero-inferior rim of the defect. Outlet perimembranous defects are also distinguished from central perimembranous defects since the former are usually adjacent to the anterior leaflet and the latter are usually adjacent to the septal leaflet of the tricuspid valve [11]. In outlet muscular

defects and juxta-arterial defects with a muscular postero-inferior rim, the conduction pathway travels underneath the postero-inferior limb of the septal band (Figures 54A and 98A), thereby becoming a left-sided structure that is remote from the postero-inferior defect border. Surgical closure utilizing the postero-inferior limb as it approaches the membranous septum, therefore, should not result in disruption of the conduction axis [22].

When the muscular outlet septum is hypoplastic and aligned with the apical part of the muscular septum, the outlet defect thus formed usually has exclusively muscular borders without fibrous continuity between the leaflets of the aortic and pulmonary valves. These defects are considered outlet muscular defects without malalignment. They are not in fibrous continuity with the AV septum and are located away from the AV conduction pathway and above the postero-inferior limb of the septal band.

When the muscular outlet septum is absent (when there is a purely fibrous outlet septum), the cranial border of the defect is the area of fibrous continuity between the pulmonary and aortic valves (Figure 98), highlighting the partial deficiency of the free-standing subpulmonary infundibulum. These lesions are also described as doubly committed juxta-arterial defects, and the fibrous outlet septum can be aligned or malaligned relative to the apical part of the muscular septum. The right and non-coronary leaflets of the aortic valve can prolapse into these defects, with associated aortic valvar distortion and aortic regurgitation. In the setting of concordant VA connections, these defects can extend postero-inferiorly into the area of fibrous continuity between the tricuspid and aortic valves, resulting in a doubly committed juxta-arterial defect without malalignment and with a fibrous postero-inferior rim (perimembranous extension).

When the outlet septum is located outside the plane of the limbs of the septal band, there is malalignment between the outlet septum and the rest of the muscular ventricular septum. Some have utilized a separate and distinct category for these lesions, labeling them as malalignment defects. Outlet defects can involve

anterior or posterior malalignment of the outlet septum. Anterior malalignment is associated with overriding of the arterial valve that is supported predominantly by the LV-left ventricle, and posterior malalignment is associated with LV-left ventricular outflow tract obstruction. Outlet defects with a malaligned outlet septum usually occur with other CHDs. For example, the anterior malalignment with concordant VA connections seen in tetralogy of Fallot is associated with obstruction along the subpulmonary region. Extreme anterior malalignment results in the tetralogy of Fallot variant with pulmonary atresia. In contrast, posterior malalignment with concordant VA connections is usually associated with subaortic stenosis and aortic arch obstruction or interruption. In patients with discordant VA connections (transposition of the great arteries), anterior malalignment is associated with subaortic stenosis and a hypoplastic aortic arch, and posterior malalignment is associated with subpulmonary stenosis. Outlet defects with malalignment, particularly in the setting of tetralogy of Fallot, can also be confluent with the ventricular component of an AV septal defect, resulting in the co-existence of both lesions in the same heart.

Summary

The scheme proposed by the ISNPCHD classifies VSDs as central perimembranous, inlet, trabecular muscular, and outlet defects, using a geographic approach as the starting point of classification while highlighting the importance of describing the borders to facilitate better understanding (Table 2). In hearts with concordant VA connections, central perimembranous defects are usually adjacent to the area of fibrous continuity between the septal leaflet of the tricuspid valve and the aortic valve, and they are located below and behind the postero-inferior limb of the septal band. Inlet defects open into the RV inlet below the postero-inferior limb of the septal band and the medial papillary muscle, while outlet defects open into the RV outlet between the two limbs of the septal band. Inlet defects can be associated with malalignment of the atrial septum and ventricular septum, typically with a straddling tricuspid valve. In contrast, outlet defects are often associated with malalignment of the muscular or fibrous outlet septum

relative to the limbs of the septal band. The conduction pathway is located along the postero-inferior border of all perimembranous defects and juxta-arterial defects with a fibrous postero-inferior rim, whereas it is remote from the inferior border of all other defects. Trabecular muscular defects are embedded within the apical muscular ventricular septum and can occupy any of its geographic components. All VSDs can occur in isolation, as confluent combinations of two or more types, or as integral components of other CHDs. In fact, single defects representing confluence of two or more types (such as confluent inlet and outlet defects) will likely be a component of the next version of the ISNPCHD ICD-11 classification system. The ISNPCHD acknowledges that it is equally valid to classify VSDs based primarily on geography or borders with synonymous terminology to describe the individual phenotypes. By using an approach that incorporates both the geographic location of a VSD and its borders, the ISNPCHD system is an attempt to improve the understanding of the anatomy of holes between the ventricles and to harmonize the disparate approaches that have evolved on the basis of pathology and noninvasive imaging. In addition, this approach should encourage anyone who cares for children with VSDs to be as descriptive as possible, using the specified terminology after review and acceptance by all members of the local health care team.

Conclusion

This report is a culmination of work done by the ISNPCHD to classify VSDs, and it represents years of meetings and debates by the members of the Society. It is meant to be an organic and continuously evolving classification system that will likely change with field testing and advances in scientific knowledge. The terms attributed herein to the various types of VSDs have been accepted by the World Health Organization for incorporation into the ICD-11. They provide the medical community with a standardized way to name these lesions, enhancing national and international quality assurance and improvement efforts as well as multicenter research for individuals with CHDs.

References

1. Franklin RCG, Béland MJ, Colan SD, Walters HL, Aiello VD, Anderson RH, et al. Nomenclature for congenital and paediatric cardiac disease: the International Paediatric and Congenital Cardiac Code (IPCCC) and the Eleventh Iteration of the International Classification of Diseases (ICD-11). *Cardiol Young*. 2017;27(10):1872-938.
2. Bailliard F, Spicer DE, Mohun TJ, Henry GW, Anderson RH. The problems that exist when considering the anatomic variability between the channels that permit interventricular shunting. *Cardiol Young*. 2015;25(1):15-28.
3. Anderson RH, Spicer DE, Giroud JM, Mohun TJ. Tetralogy of Fallot: nosological, morphological, and morphogenetic considerations. *Cardiol Young*. 2013;23(6):858-66.
4. Becu LM, Burchell HB, Dushane JW, Edwards JE, Fontana RS, Kirklin JW. Anatomic and pathologic studies in ventricular septal defect. *Circulation*. 1956;14(3):349-64.
5. Soto B, Becker AE, Moulaert AJ, Lie JT, Anderson RH. Classification of ventricular septal defects. *Br Heart J*. 1980;43(3):332-43.
6. Hagler DJ, Edwards WD, Seward JB, Tajik AJ. Standardized nomenclature of the ventricular septum and ventricular septal defects, with applications for two-dimensional echocardiography. *Mayo Clin Proc*. 1985;60(11):741-52.
7. Wells WJ, Lindesmith GG. Ventricular septal defect. In: Arcineagas E, editor. *Pediatric Cardiac Surgery*. Chicago, IL: Year Book Medical; 1985. p. 141-53.
8. Van Praagh R, Geva T, Kreutzer J. Ventricular septal defects: how shall we describe, name and classify them? *J Am Coll Cardiol*. 1989;14(5):1298-9.
9. Soto B, Ceballos R, Kirklin JW. Ventricular septal defects: a surgical viewpoint. *J Am Coll Cardiol*. 1989;14(5):1291-7.
10. Jacobs JP, Burke RP, Quintessenza JA, Mavroudis C. Congenital Heart Surgery Nomenclature and Database Project: ventricular septal defect. *Ann Thorac Surg*. 2000;69(4 Suppl):S25-35.

11. Mostefa-Kara M, Bonnet D, Belli E, Fadel E, Houyel L. Anatomy of the ventricular septal defect in outflow tract defects: similarities and differences. *J Thorac Cardiovasc Surg.* 2015;149(3):682-8 e1.
12. WHO WHO. ICD-11 Beta Draft [<https://icd.who.int/dev11/f/en#/>].
13. Franklin RC, Jacobs JP, Tchervenkov CI, Béland MJ. Bidirectional crossmap of the Short Lists of the European Paediatric Cardiac Code and the International Congenital Heart Surgery Nomenclature and Database Project. *Cardiol Young.* 2002;12(5):431-5.
14. Béland MJ, Jacobs JP, Tchervenkov CI, Franklin RCG, Report from the Executive of The International Working Group for Mapping and Coding of Nomenclatures for Paediatric and Congenital Heart Disease. *Cardiol Young.* 2002;12(5):425-30.
15. Béland MJ, Franklin RC, Jacobs JP, Tchervenkov CI, Aiello VD, Colan SD, et al. Update from the International Working Group for Mapping and Coding of Nomenclatures for Paediatric and Congenital Heart Disease. *Cardiol Young.* 2004;14(2):225-9.
16. Jacobs JP, Maruszewski B, Tchervenkov CI, Lacour-Gayet FG, Jacobs ML, Clarke DR, et al. The current status and future directions of efforts to create a global database for the outcomes of therapy for congenital heart disease. *Cardiol Young.* 2005;15 Suppl 1:190-7.
17. Jacobs JP, Franklin RC, Jacobs ML, Colan SD, Tchervenkov CI, Maruszewski B, et al. Classification of the functionally univentricular heart: unity from mapped codes. *Cardiol Young.* 2006;16 Suppl 1:9-21.
18. Tchervenkov CI, Jacobs JP, Weinberg PM, Aiello VD, Béland MJ, Colan SD, et al. The nomenclature, definition and classification of hypoplastic left heart syndrome. *Cardiol Young.* 2006;16(4):339-68.
19. Jacobs JP, Franklin RC, Wilkinson JL, Cochrane AD, Karl TR, Aiello VD, et al. The nomenclature, definition and classification of discordant atrioventricular connections. *Cardiol Young.* 2006;16 Suppl 3:72-84.
20. Jacobs JP, Anderson RH, Weinberg PM, Walters HL III, Tchervenkov CI, Del Duca D, et al. The nomenclature, definition and classification of cardiac structures in the setting of heterotaxy. *Cardiol Young.* 2007;17 Suppl 2:1-28.

21. Franklin RC, Jacobs JP, Krogmann ON, Béland MJ, Aiello VD, Colan SD, et al. Nomenclature for congenital and paediatric cardiac disease: historical perspectives and The International Pediatric and Congenital Cardiac Code. *Cardiol Young*. 2008;18 Suppl 2:70-80.
22. Kurosawa H, Becker AE. Atrioventricular conduction in congenital heart disease : surgical anatomy. Tokyo ; New York: Springer-Verlag; 1987. xii, 272 p. p.
23. Anderson RH, Spicer DE, Yoo SJ, Jacobs JP, Aiello VD. Innovation and the role of the cardiac morphologist. *Cardiol Young*. 2009;19 Suppl 2:11-25.
24. Spicer DE, Anderson RH, Backer CL. Clarifying the surgical morphology of inlet ventricular septal defects. *Ann Thorac Surg*. 2013;95(1):236-41.
25. LaCorte MA, Cooper RS, Kauffman SL, Schiller MS, Golinko RJ, Griep RB. Atrioventricular canal ventricular septal defect with cleft mitral valve. Angiographic and echocardiographic features. *Pediatr Cardiol*. 1982;2(4):289-95.

Table 1: ISNPCHD Classification Scheme for VSD (IPCCC 07.10.00) as Incorporated in ICD-11

1. Perimembranous central VSD (07.10.01)
2. Inlet VSD without a common AV junction (07.14.05) *
 - a. Inlet perimembranous VSD without AV septal malalignment and without a common AV junction (07.10.02)
 - b. Inlet perimembranous VSD with AV septal malalignment and without a common AV junction (07.14.06)
 - c. Inlet muscular VSD (07.11.02)
3. Trabecular muscular VSD (07.11.01)
 - a. Trabecular muscular VSD: midseptal (07.11.04)
 - b. Trabecular muscular VSD: apical (07.11.03)
 - c. Trabecular muscular VSD: postero-inferior (07.11.12)
 - d. Trabecular muscular VSD: anterosuperior (07.11.07)
 - e. Trabecular muscular VSD: multiple (“Swiss cheese” septum) (07.11.05)
4. Outlet VSD (07.12.00)
 - a. Outlet VSD without malalignment (07.12.09)
 - i. Outlet muscular VSD without malalignment (07.11.06)
 - ii. Doubly committed juxta-arterial VSD without malalignment (07.12.01)
 1. Doubly committed juxta-arterial VSD without malalignment and with a muscular postero-inferior rim (07.12.02)
 2. Doubly committed juxta-arterial VSD without malalignment and with a fibrous postero-inferior rim (perimembranous extension) (07.12.03)
 - b. Outlet VSD with anteriorly malaligned outlet septum (07.10.17)
 - i. Outlet muscular VSD with anteriorly malaligned outlet septum (07.11.15)
 - ii. Outlet perimembranous VSD with anteriorly malaligned outlet septum (07.10.04)

- iii. Doubly committed juxta-arterial VSD with anteriorly malaligned fibrous outlet septum (07.12.12)
 - 1. Doubly committed juxta-arterial VSD with anteriorly malaligned fibrous outlet septum and a muscular postero-inferior rim ((07.12.07)
 - 2. Doubly committed juxta-arterial VSD with anteriorly malaligned fibrous outlet septum and a fibrous postero-inferior rim (perimembranous extension) (07.12.05)
- c. Outlet VSD with posteriorly malaligned outlet septum (07.10.18)
 - i. Outlet muscular VSD with posteriorly malaligned outlet septum (07.11.16)
 - ii. Outlet perimembranous VSD with posteriorly malaligned outlet septum (07.10.19)
 - iii. Doubly committed juxta-arterial VSD with posteriorly malaligned fibrous outlet septum (07.12.13)
 - 1. Doubly committed juxta-arterial VSD with posteriorly malaligned fibrous outlet septum and a muscular postero-inferior rim (07.12.08)
 - 2. Doubly committed juxta-arterial VSD with posteriorly malaligned fibrous outlet septum and a fibrous postero-inferior rim (perimembranous extension) (07.12.06)

* The interventricular communication associated with a common AV junction (VSD component of an AV septal or AV canal defect) should be considered in the common AV junction section of the IPCCC or the ICD-11 for coding purposes.

Table 2: Characteristic Anatomic Features of VSD Types with Concordant VA Connections

1. Central perimembranous defect
 - ~~a.~~—Opens into central part of base of ventricular mass
 - ~~b.~~~~a.~~ A adjacent to interventricular component of membranous septum
 - ~~e.~~~~b.~~ Behind-Covered by open septal leaflet of tricuspid valve
 - ~~f.~~~~c.~~ In area of anteroseptal commissure of tricuspid valve
 - ~~e.~~~~d.~~ Below commissure between right and non-coronary leaflets of aortic valve
 - ~~f.~~~~e.~~ Below and behind posterior limb of septal band and medial papillary muscle
 - ~~g.~~~~f.~~ Conduction system along postero-inferior rim of defect
2. Inlet defect
 - a. Can be a muscular defect or a perimembranous defect with or without AV septal alignment
 - b. Opens into inlet component of RV
 - c. Extends behind septal leaflet of tricuspid valve
 - d. Below anteroseptal commissure of tricuspid valve
 - e. Below posterior limb of septal band and papillary muscle of conus
 - f. Without and with malalignment between atrial septum and ventricular septum
 - g. Inlet perimembranous defect: conduction system along postero-inferior rim of defect
 - h. Inlet muscular defect: conduction system away from rims of defect
3. Trabecular muscular defect
 - a. Extends through the septum, thereby opening within the apical component of muscular ventricular septum
 - b. Exclusively muscular borders
 - c. Conduction system away from rims of defect
4. Outlet defect
 - a. Can be a perimembranous, muscular, or juxta-arterial defect

- b. Opens into outlet component of RV
- c. Behind or near anterior leaflet of tricuspid valve
- d. Above anteroseptal commissure of tricuspid valve
- e. Between limbs of septal band
- f. Without or with malalignment between muscular outlet septum and apical part of muscular septum
- g. Outlet perimembranous defect and juxta-arterial defect with fibrous postero-inferior rim: conduction system along postero-inferior rim of defect
- h. Outlet muscular defect and juxta-arterial defect with muscular postero-inferior rim: conduction system away from rims of defect

Figure Legends

Figure 1. Episcopic images from mouse embryos showing the changing morphology of the embryonic interventricular communication. A) At embryonic day 10.5, the developing atrial chambers communicate only with the developing LV, with the outflow tract supported exclusively above the developing RV. The interventricular communication (double-headed white arrow), therefore, is an integral part of the circulation. B) It remains integral at embryonic day 12.5 when the AV canal expands to produce the RV inlet containing the developing tricuspid valve. However, both outflow tracts remain supported by the RV, with the proximal outflow cushions still to fuse. C) It is only after transfer of the aortic root to the LV at embryonic day 13.5 that the interventricular communication is closed by growth of tissue from the ventricular aspect of the AV cushions. The proximal outflow cushions fuse with each other, followed by fusion of the septal cushion to the crest of the muscular ventricular septum, thereby committing the aortic root to the LV. Note that the RV trabeculations are compacting to form the septal band.

Figure 21. Illustration of the normal ventricular septum as viewed from the right side after dissection of the parietal ventricular wall. The circular structure above and behind the anterosuperior aspect of the septal leaflet of the tricuspid valve (yellow valvar structure) is the membranous septum with the AV conduction pathway in green traversing its postero-inferior margin; the light-yellow portion of the circle represents its AV component, and the light blue portion represents its interventricular component. The septal band is the prominent muscle bar coursing from the apex to the base and bifurcating into the postero-inferior and anterosuperior limbs.

Figure 32. A) Illustration of a central perimembranous defect. The hole is behind the septal leaflet of the tricuspid valve, below the right and/or non-coronary leaflets of the aortic valve, and below the postero-inferior limb of the septal band. Notice the conduction pathway in green coursing along the postero-inferior rim of the septal band. B) Pathology specimen of a central perimembranous defect below the medial papillary muscle and postero-inferior limb of the septal band.

Figure 43. A) Illustration of an inlet perimembranous defect with aligned atrial septum and ventricular septum. Notice the abnormally inferior AV node and conduction pathway coursing along the postero-

inferior rim (dotted line). B) Pathology specimen of an inlet perimembranous defect opening into the RV inlet below the anteroseptal commissure of the tricuspid valve; the defect extends along and is mostly covered by the septal leaflet of the tricuspid valve.

Figure 54. A) Illustration of an inlet muscular defect which opens into the RV inlet and has exclusively muscular borders. Notice that the AV conduction pathway is located near but not at the superior border. This illustration also depicts an outlet muscular defect; inlet and outlet muscular defects are not coded as trabecular muscular defects. B) Pathology specimen of an inlet muscular defect with exclusively muscular borders opening into the RV inlet.

Figure 65. A) Illustration of an inlet perimembranous defect with malalignment of the atrial septum and postero-inferior part of the ventricular septum. The tricuspid valve straddles the defect with attachments to the ~~LV~~left ventricle. Notice the abnormally inferior AV node and conduction pathway coursing along the postero-inferior rim. B) Pathology specimen of an inlet perimembranous defect with AV septal malalignment and a straddling tricuspid valve.

Figure 76. A) Illustration of trabecular muscular defects located in the midseptal, postero-inferior, apical, and anterosuperior aspects of the muscular trabecular septum. B) Pathology specimen of a large postero-inferior muscular trabecular defect with the inferior margin at the diaphragmatic wall of the ventricle.

Figure 87. A) Illustration of an outlet perimembranous defect located between the limbs of the septal band and extending to the area of fibrous continuity between the tricuspid and aortic valves. Notice the malaligned muscular outlet septum. B) Pathology specimen of an outlet perimembranous defect opening into the RV outlet between the limbs of the septal band.

Figure 89. A) Illustration of a doubly committed juxta-arterial defect adjacent to the area of fibrous continuity between the arterial valves. Notice that the conduction pathway is remote from the defect. B) Pathology specimen of a doubly committed juxta-arterial defect located immediately below the area of fibrous continuity between the arterial valves and between the limbs of the septa band; the defect has a muscular postero-inferior rim and does not extend to the area of fibrous continuity between the tricuspid and the aortic valves.