

Should all digital ulcers be included in future clinical trials of systemic sclerosis-related digital vasculopathy?

Authors:

Michael Hughes¹, Christopher P Denton² & Ariane L Herrick^{1,3}

1. Centre for Musculoskeletal Research, The University of Manchester, Salford Royal NHS Foundation Trust, Manchester Academic Health Science Centre, Manchester, UK.
2. Centre for Rheumatology and Connective Tissue Diseases, Royal Free Hospital, London, UK.
3. NIHR Manchester Biomedical Research Centre, Central Manchester NHS Foundation Trust, Manchester Academic Health Science Centre, UK.

Corresponding author:

Dr Michael Hughes.

Centre for Musculoskeletal Research, The University of Manchester, Salford Royal NHS Foundation Trust, Manchester Academic Health Science Centre, Manchester, UK.

Michael.hughes-6@postgrad.manchester.ac.uk

Telephone: +44 (0)161 206 2460

Key Words = Digital ulcers; Systemic sclerosis; Scleroderma, Clinical Trials, Vasculopathy.

Word count: Abstract = 156 /250 Manuscript = 1499 /1200-1500

References = 30/30. 1 Figure

No conflict of interests.

ABSTRACT

Digital ulcers (DU) are a common manifestation of systemic sclerosis (SSc) and occur at a variety of locations including the fingertips and over the extensor aspects of the hands. However, most recent clinical trials have only included fingertip DUs as these are believed to be ischaemic in aetiology, and therefore likely to benefit from treatment with vasoactive drug therapies. There is an emerging evidence base to suggest that all DUs could share an ischaemic component which is potentially responsive to vascular therapy. We review the evidence under the headings: 'microvascular imaging', 'structural microvascular', 'functional vascular disease', 'macrovascular involvement' and 'vascular associates'. In addition, we explore the reliability of rheumatologists grading DUs, and how this could impact on the design of future clinical trials. Based upon the current evidence, we would encourage the expert SSc community to reconsider the rationale for including only fingertip DUs in future SSc clinical trials, and suggest an agenda for future research.

INTRODUCTION

Digital ulcers (DUs) are common in patients with SSc and are responsible for much of the pain and disability associated with the disease. Despite current treatments to prevent (e.g. endothelial receptor-1 antagonists and phosphodiesterase type-5 inhibitors)(1,2) and treat DUs(3), recurrent DUs remain a major clinical burden in many patients with SSc(4–6). Recent prospective (collected over two years) data from the DUO (Digital Ulcer Outcome) registry revealed that over half of patients had either ‘recurrent’ DUs (more than 2 episodes) or ‘chronic’ DUs (present at every clinic visit) (46.2 % and 11.2%, respectively)(6).

DUs commonly occur on the fingertip and over the extensor aspects of the hands, particularly overlying the small joints of the hands. Amanzi et al(7) reported that (out of 792 DUs) fingertip DUs were commoner than extensor DUs (55% vs 31%). Whereas, in a prospective study over 12 months, the prevalence of both fingertip and extensor DUs was 6%, and both types of DU were equally disabling(5). DUs less commonly occur at other sites of the hands, including at the base of the nail and on the lateral aspects of the digits. DUs can also occur in relation to underlying subcutaneous calcinosis.

At present, fingertip DUs are generally believed to be ischaemic in aetiology, whereas, extensor aspect DUs are thought to occur due to recurrent microtrauma and increased skin tension from tissue fibrosis, often at sites of contracture. Little (if anything) is known about the pathophysiology of DUs which occur at other sites of the hands. It has been postulated that calcinosis could be related to SSc-related microangiopathy(8), which could therefore also be implicated in calcinosis-associated DUs.

Another key issue operationally is that recent clinical trials of drug therapies for SSc-associated vasculopathy (1,2,9,10) have specifically excluded extensor aspect DUs, on the basis that these are not considered ‘ischaemic’ in aetiology, and therefore not likely to benefit from vasoactive drug therapies. However, if non-fingertip DUs also have a *potentially reversible* ischaemic component, then this would strongly warrant inclusion of these neglected DU types in the design of future SSc clinical trials.

The emerging evidence base to support an ischaemic drive to DUs in SSc shall now be discussed under the headings: ‘microvascular imaging’, ‘structural’ and ‘functional microvascular disease’, ‘macrovascular involvement’ and ‘vascular associates’. It is important to highlight that these headings are arbitrary, and interlinked. Another important point is that many 'DU associations' have been examined for either ‘any’ (including extensor) DUs or for solely fingertip DUs. Therefore, it is not always possible when reviewing previous research studies to separate out the associations between the degree of SSc-related vascular disease and the individual subtypes of DUs. When reviewing the previous studies, where possible, we will describe which type(s) of DUs are being discussed.

MICROVASCULAR IMAGING

Both fingertip and extensor DUs have been shown by objective microvascular (laser Doppler and speckle) imaging to be relatively ischaemic compared to surrounding non-ulcerated skin (11,12), with a reduction in ischaemia observed with DU healing(11,12). Mechanical factors such as skin stretching over extensor surfaces may also be relevant and lead to further compromise at these sites. An example of laser Doppler imaging of both a fingertip and extensor DU is provided in Figure 1. There is often a relative hyperaemia of the skin immediately surrounding the ischaemic DU centre(12,13), the aetiology of which at present is unclear, and this could be important in DU healing. In a recent double-blind, crossover, placebo controlled study of the vasodilator glyceryl trinitrate (GTN), applied topically as ointment directly to SSc-related DUs, GTN resulted in a significant increase in perfusion to the ischaemic centre (and also to a lesser extent to the surrounding tissue), with a similar response observed with both fingertip and extensor aspect DUs(13).

STRUCTURAL MICROVASCULAR DISEASE

Nailfold capillary abnormalities have been reported by several authors to be highly predictive of future DUs in patients with SSc(14–16). In a multicentre, prospective cohort study which included 486 patients with SSc and a history of DUs, the number of capillaries in the middle finger of the non-dominant hand (odds ratio of 0.84) was one of the three strongest predictors of future DUs, along with number of DUs and the presence critical digital ischaemia at baseline

(16). We have previously described that the capillaries (as assessed by videocapillaroscopy) of the skin immediately adjacent to both fingertip and extensor DUs are abnormal, with areas of capillary enlargement and neoangiogenesis, suggesting that SSc-associated microangiopathy contributes to both types of DU(17).

FUNCTIONAL VASCULAR DISEASE

Functional microvascular disease has been associated with DUs. Blaise et al(18) reported that in patients with SSc the digital thermal hyperaemia pattern (an index of vascular function) is predictive of DU. In our retrospective study which included 138 patients (69 in each group), we assessed whether abnormal thermography (defined as a temperature gradient between the fingers and dorsum of the hand of $>1^{\circ}\text{C}$ at 30°C) was associated with DU development(19). Patients (n [%]) with abnormal (22 [32%]) compared to normal (11 [16%]) thermography were more likely to develop any DUs (including multiple episodes) within the follow-up period of up to three years.

MACROVASCULAR INVOLVEMENT

An increased prevalence of macrovascular disease has been reported in patients with SSc (20), although this remains a controversial topic. Macrovascular disease has been reported to be both associated (increased renal artery stiffness)(21) and not associated (aortic stiffness) with DU development(22). Proximal (large) vessel disease is an important consideration in clinical practice and likely reduces hand perfusion globally predisposing to DUs. In particular, selective involvement of the ulnar artery has been reported in patients with SSc(23), and has been found to be associated with the development of any DU (including fingertip, extensor and calcinosis-associated) DUs(24). In a recent prospective study which included 55 patients with SSc and 19 healthy controls, the occurrence of new ischaemic (defined as occurring on the fingertip) DUs during one year of follow was associated (odds ratio) with both ulnar artery occlusion (8.73) and pathological finger pulp blood flow (11.20)(25). Furthermore, in the multivariate analysis, the combination of both ulnar artery occlusion and pathological finger pulp blood flow was strongly associated with DU occurrence (7.45). Furthermore, a severe obliterative vasculopathy of the digital arteries has been reported in SSc(26). Digital artery involvement

could be an important contributor to the development of different types of DUs in SSc, through a generalised reduction in digital perfusion, on a background of a progressive microangiopathy.

VASCULAR ASSOCIATES

A number of vascular associates (both increased and lower risk) of DUs have been proposed in SSc, as described in a recent systematic review(27). Examples of associates with an increased risk of DUs include increased circulating levels of endothelin-1 and autoantibodies toward endothelin receptor A(28,29), and increased vascular endothelial growth factor(28). At present the evidence base for vascular associates of specific DUs subtypes is limited and requires further research.

THE RELIABILITY OF DU GRADING

This is a major concern in SSc clinical trials relating to digital vasculopathy. The overall reliability of rheumatologists with an interest in SSc (and therefore most likely to participate in clinical trials) is only poor to moderate at best(30). In a recent web-based study which included 51 rheumatologists (from 15 countries) with over 4500 gradings exploring the impact of 'real-world' clinical information, the overall inter-reliability was poor either without or with the contextual information (weighted kappa of 0.32 and 0.36, respectively)(30). This was true for all types of DU: fingertip (k= 0.37 and 0.42 without and with context). extensor (k = 0.26 and 0.30), and other DU types (k=0.31 and 0.39).

RESEARCH AGENDA

There are several key issues that need be addressed in relation to DU disease and clinical trial design. Firstly, the ischaemic aetiology to the development of DUs must be further explored, and whether this differs between different types of DUs. Secondly, as extensor DUs contribute to morbidity they should be assessed in clinical trials, and these should be documented separately, to see whether their response to treatment differs from fingertip DUs. Thirdly, what is the role of non-invasive imaging in both the prediction and monitoring of DU disease in SSc, including in future clinical trials? Fourthly, the contributory role of ischaemia on other ulcer cofactors (e.g. calcinosis and infection) should be explored, as these could also be modulated

by vascular therapies. Finally, work is needed to improve the reliability of rheumatologists grading all types of DUs as an outcome measure in clinical trials.

CONCLUSION

In conclusion, we propose that *all* DUs in SSc could share a *potentially reversible* ischaemic component. If ischaemia contributes to the development and/or persistence of extensor as well as fingertip DUs, then extensor DUs could also benefit treatment with vasoactive drug therapies. Future research is needed to further understand the aetiology and treatment response of all SSc-related DUs, the role for non-invasive imaging in clinical trials, and to improve the reliability of DU grading as an outcome measure for future studies. With the emerging evidence base we strongly encourage the SSc international community to include all DUs in the design of future clinical trials.

REFERENCES

1. Matucci-Cerinic M, Denton CP, Furst DE, et al. Bosentan treatment of digital ulcers

- related to systemic sclerosis: results from the RAPIDS-2 randomised, double-blind, placebo-controlled trial. *Ann Rheum Dis* 2011;70:32–8.
2. Hachulla E, Hatron PY, Carpentier P, et al. Efficacy of sildenafil on ischaemic digital ulcer healing in systemic sclerosis: the placebo-controlled SEDUCE study. *Ann Rheum Dis* 2016;75:1009–15.
 3. Wigley FM, Wise RA, Seibold JR, et al. Intravenous iloprost infusion in patients with Raynaud phenomenon secondary to systemic sclerosis. A multicenter, placebo-controlled, double-blind study. *Ann Intern Med* 1994;120:199–206.
 4. Mouthon L, Mestre-Stanislas C, Bérezné A, et al. Impact of digital ulcers on disability and health-related quality of life in systemic sclerosis. *Ann Rheum Dis* 2010;69(1):214–7.
 5. Ennis H, Vail A, Wragg E, et al. A prospective study of systemic sclerosis-related digital ulcers: prevalence, location, and functional impact. *Scand J Rheumatol* 2013;42:483–6.
 6. Matucci-Cerinic M, Krieg T, Guillevin L, et al. Elucidating the burden of recurrent and chronic digital ulcers in systemic sclerosis: long-term results from the DUO Registry. *Ann Rheum Dis* 2016;75:1770–6.
 7. Amanzi L, Braschi F, Fiori G, et al. Digital ulcers in scleroderma: staging, characteristics and sub-setting through observation of 1614 digital lesions. *Rheumatology (Oxford)* 2010;49:1374–82.
 8. Loughrey L, Bissell L-A, Abignano G, et al. Video-capillaroscopy assessment of pericalcinotic skin indicates specific features of severe vasculopathy associated with calcium deposits in systemic sclerosis. *Ann Rheum Dis* 2014;72:A648.
 9. Khanna D, Denton CP, Merkel PA, et al. Effect of Macitentan on the development of new ischemic digital ulcers in patients with systemic sclerosis: DUAL-1 and DUAL-2 Randomized Clinical Trials. *JAMA* 2016;;315:1975–88.
 10. Seibold JR, Wigley FM, Schioppa E, et al. Digital ulcers in SSc treated with oral treprostinil: a randomized, double-blind, placebo-controlled study with open-label follow-up. *J Scleroderma Relat Disord* 2017;2:42–9.
 11. Ruaro B, Sulli A, Smith V, Paolino S, Pizzorni C, Cutolo M. Short-term follow-up of digital ulcers by laser speckle contrast analysis in systemic sclerosis patients. *Microvasc Res* 2015;101:82–5.
 12. Murray A, Moore T, Wragg E, et al. Pilot study assessing pathophysiology and healing of digital ulcers in patients with systemic sclerosis using laser Doppler imaging and thermography. *Clin Exp Rheumatol* 2016;34:100–5.
 13. Hughes M, Moore T, Manning J, et al. Reduced perfusion in systemic sclerosis digital ulcers (both fingertip and extensor) can be increased by topical application of glyceryl trinitrate. *Microvasc Res* 2017;111:32–6.
 14. Sebastiani M, Manfredi A, Vukatana G, et al. Predictive role of capillaroscopic skin ulcer risk index in systemic sclerosis: a multicentre validation study. *Ann Rheum Dis* 2012;71:67–70.
 15. Smith V, Decuman S, Sulli A, et al. Do worsening scleroderma capillaroscopic

- patterns predict future severe organ involvement? a pilot study. *Ann Rheum Dis* 2012;71:1636–9.
16. Cutolo M, Herrick AL, Distler O, et al. Nailfold videocapillaroscopic features and other clinical risk factors for digital ulcers in systemic sclerosis: A multicenter, prospective cohort study. *Arthritis Rheumatol (Hoboken, NJ)* 2016;68:2527–39.
 17. Hughes M, Moore T, Manning J, Dinsdale G, Murray A, Herrick AL. Digital ulcers in systemic sclerosis are associated with microangiopathic abnormalities of peri-lesional skin as assessed by capillaroscopy. *Scand J Rheumatol.* 2016;46:81–2.
 18. Blaise S, Roustit M, Carpentier P, Seinturier C, Imbert B, Cracowski JL. The digital thermal hyperemia pattern is associated with the onset of digital ulcerations in systemic sclerosis during 3 years of follow-up. *Microvasc Res* 2014;94:119–22.
 19. Hughes M, Wilkinson J, Moore T, et al. Thermographic abnormalities are associated with future digital ulcers and death in patients with systemic sclerosis. *J Rheumatol* 2016;43:1519–22.
 20. Man A, Zhu Y, Zhang Y, et al. The risk of cardiovascular disease in systemic sclerosis: a population-based cohort study. *Ann Rheum Dis* 2013;72:1188–93.
 21. Rosato E, Barbano B, Gigante A, et al. Increased intrarenal arterial stiffness may predict the occurrence of new digital ulcers in systemic sclerosis. *Arthritis Care Res (Hoboken)* 2014;66:1380–5.
 22. Aïssou L, Meune C, Avouac J, et al. Small, medium but not large arteries are involved in digital ulcers associated with systemic sclerosis. *Joint Bone Spine* 2016;83:444–7.
 23. Park JH, Sung Y-K, Bae S-C, Song S-Y, Seo HS, Jun J-B. Ulnar artery vasculopathy in systemic sclerosis. *Rheumatol Int* 2009;29:1081–6.
 24. Frerix M, Stegbauer J, Dragun D, Kreuter A, Weiner SM. Ulnar artery occlusion is predictive of digital ulcers in SSc: a duplex sonography study. *Rheumatology (Oxford)* 2012;51:735–42.
 25. Lescoat A, Coiffier G, Rouil A, et al. Vascular evaluation of the hand by power doppler ultrasonography and new predictive markers of ischemic digital ulcers in systemic sclerosis: results of a prospective pilot study. *Arthritis Care Res (Hoboken)* 2017;69:543–51.
 26. Rodnan GP, Myerowitz RL, Justh GO. Morphologic changes in the digital arteries of patients with progressive systemic sclerosis (scleroderma) and Raynaud phenomenon. *Medicine (Baltimore)* 1980;59:393–408.
 27. Silva I, Almeida J, Vasconcelos C. A PRISMA-driven systematic review for predictive risk factors of digital ulcers in systemic sclerosis patients. *Autoimmun Rev* 2015;14:140–52.
 28. Silva I, Teixeira A, Oliveira J, Almeida I, Almeida R, Vasconcelos C. Predictive value of vascular disease biomarkers for digital ulcers in systemic sclerosis patients. *Clin Exp Rheumatol* 2015;33 Suppl 9(4):127–30.
 29. Avouac J, Riemekasten G, Meune C, Ruiz B, Kahan A, Allanore Y. Autoantibodies against endothelin 1 type a receptor are strong predictors of digital ulcers in systemic sclerosis. *J Rheumatol* 2015;42:1801–7.

30. Hughes M, Roberts C, Tracey A, Dinsdale G, Murray A, Herrick AL. Does the clinical context improve the reliability of rheumatologists grading digital ulcers in systemic sclerosis? *Arthritis Care Res (Hoboken)* 2016;68:1340–5.

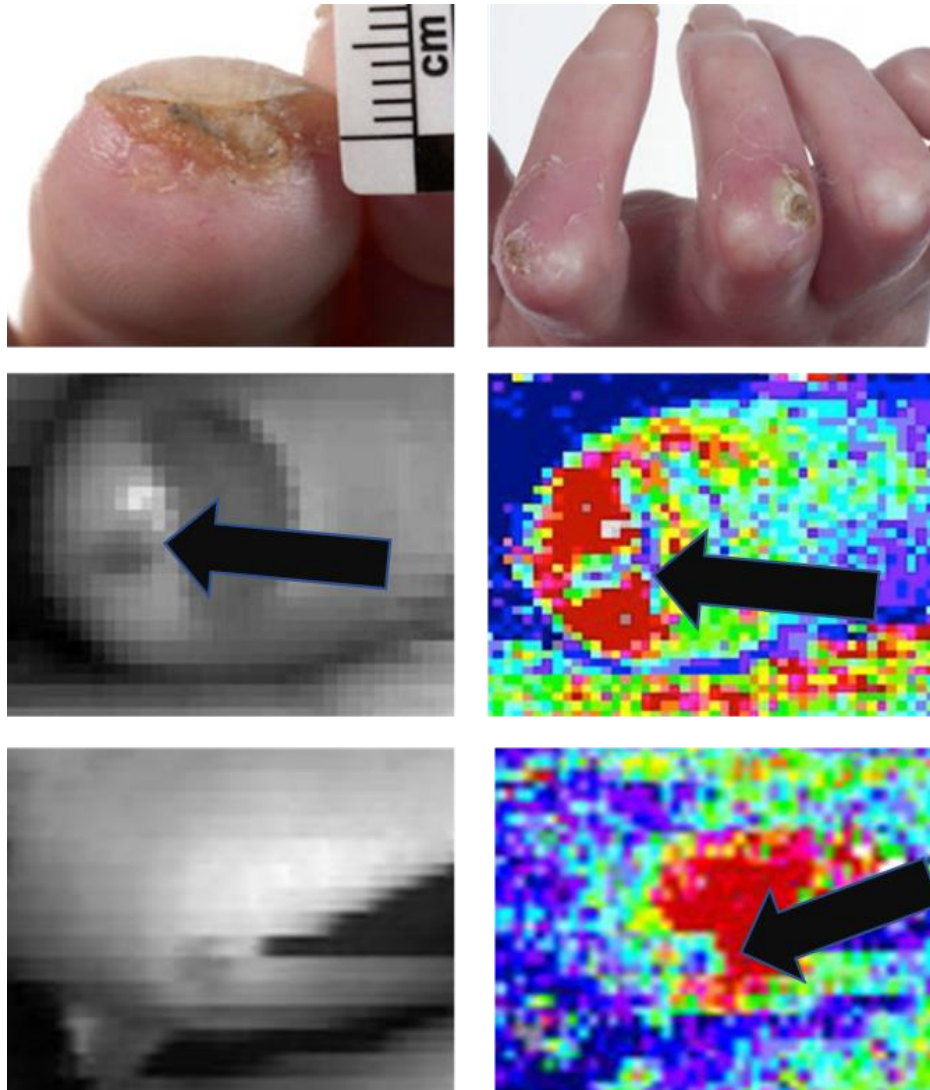


Figure 1. DUs in SSc. Top row: Clinical photographs of fingertip and extensor DUs. Middle and bottom rows: Grey scale photograph (left) and corresponding laser Doppler imaging (right) of fingertip (middle) and extensor (bottom) DUs. In both DUs there is relatively lower perfusion to the DU centre compared to the surrounding tissue.