

Paroxysmal 1:1 narrow complex tachycardia: What is the mechanism?

Jason V. Garcia, BSc, CCDS, CEPS, Holly L. Daw, BSc, CCDS, CEPS,
Jonathan M. Behar, MBBS, BSc, PhD, MRCP, CCDS, Pier D. Lambiase, PhD, FRCP, FHRS

From the Department of Electrophysiology, Barts Heart Centre, St. Bartholomew's Hospital, London, United Kingdom.

Introduction

Narrow complex tachycardias with a 1:1 atrioventricular (AV) relationship have characteristic features on surface electrocardiogram (ECG) and at the time of electrophysiology (EP) study. Differential diagnostic pacing maneuvers at the time of EP study have been well established; on most occasions the diagnosis can be made rapidly if the tachycardia response meets a criterion for the suspected mechanism. On occasion the response to pacing maneuvers can be atypical. Careful analysis of all diagnostic pacing maneuvers during tachycardia can lead to the diagnosis of a rare mechanism for tachycardia.

Case report

A 25-year-old man was transferred to our tertiary cardiac center, having been admitted to his local hospital for severely limiting, symptomatic palpitations. A previous EP study was performed at a different institution with no inducible tachycardia. A repeat EP study was performed at our institute; the atrio-His (AH) and His-ventricular baseline sinus rhythm intervals were 68 ms and 46 ms, respectively. Dual AV nodal physiology was not demonstrated in both anterograde and retrograde directions. Tachycardia spontaneously initiated and sustained with a 1 mcg/min infusion of isoprenaline. **Figure 1** shows a narrow complex tachycardia. **Figure 2** demonstrates the response to a single atrial premature depolarization (APD) from the high right atrium at the time of His refractoriness. **Figure 3A** shows a His-refractory ventricular premature depolarization (VPD) delivered from the right ventricular apex (RVA); **Figure 3B** and **C** show the response to ventricular overdrive pacing

KEYWORDS Atrioventricular nodal reentrant tachycardia; Bypass tract; Differential diagnostic pacing; Nodoventricular; Orthodromic reciprocating tachycardia
(Heart Rhythm Case Reports 2018; ■:1–5)

Dr Lambiase is supported by UCLH Biomedicine NIHR. **Address reprint requests and correspondence:** Dr Pier D. Lambiase, Barts Heart Centre, St. Bartholomews Hospital, Department of Electrophysiology, West Smithfield, London EC1A 7BE, UK. E-mail address: jason_garcia87@hotmail.com.

(VOP). A detailed discussion of the diagnostic pacing maneuvers performed during tachycardia follows.

Discussion

Tachycardia cycle length (TCL) varied between 530 ms and 600 ms. Surface ECG showed a short RP tachycardia with negative P waves in the inferior surface ECG leads. The differential diagnosis is atrioventricular nodal reentry tachycardia (AVNRT), atrial tachycardia (AT) with a long PR, junctional ectopic tachycardia (JET), intra-Hisian reentry tachycardia, orthodromic reciprocating tachycardia (ORT) with a concealed AV pathway, or ORT using a concealed nodofascicular/nodoventricular (NV) bypass tract (BPT).

Figure 1 shows tachycardia with a 1:1 AV relationship. Cycle length oscillations were observed with changes in the His-His (H-H) interval preceding changes in the atrial-atrial (A-A) interval. A His electrogram was recorded throughout the procedure with no evidence of Hisian split potentials; hence intra-Hisian reentry tachycardia was ruled out. In AVNRT and JET the atrium and ventricle are activated in parallel, as opposed to orthodromic atrioventricular reentrant tachycardia (OAVRT) and AT, where the atrium and ventricle activate sequentially. The AH intervals when pacing at the TCL were not in favor of OAVRT, AT, or AVNRT, as the intervals indicated fast pathway AV nodal conduction. However, this finding should not exclude AVNRT, as the mechanism for tachycardia can be infra-atrial. Induction of AVNRT may also depend on the site of pacing: as input and exit from the AV node can anatomically vary, a critical AH or critical His-atrial interval could also be a determinant of tachycardia induction.¹ In our case initiation of tachycardia was always with a critically timed junctional escape beat following sinus arrhythmia; the trigger for tachycardia was therefore infra-atrial and dependent on conduction system automaticity. **Figure 2** shows a His-refractory APD delivered from the high right atrium; this maneuver delayed the subsequent His, ventricular, and atrial beat or terminated tachycardia. In JET a His-synchronous APD should not terminate tachycardia, as the AV node would be refractory. A His-refractory APD could terminate tachycardia if anterograde conduction utilizes a

KEY TEACHING POINTS

- A His-refractory ventricular premature depolarization that pre-excites the next His and ventricular electrogram before atrial pre-excitation is suggestive of a bypass tract inserting into the atrioventricular (AV) node.
- Entrainment of orthodromic nodoventricular reciprocating tachycardia can have variable postpacing intervals owing to decremental properties of the AV node.
- Anterograde His capture during entrainment can be identified with a long stimulus-His time; this is a feature of a bypass tract inserting into the AV node.
- Ablation at the site of earliest atrial activation or within the slow pathway region of the AV node is curative for orthodromic reciprocating nodoventricular tachycardia.

secondary AV pathway; conduction down an AV nodal slow pathway was unlikely, as it could not be demonstrated during baseline testing. The His-ventricular interval was also unremarkable with no QRS alternans, ruling out a BPT inserting

from the atrium to the His-Purkinje network or ventricle. JET and AVNRT with a bystander AV pathway were subsequently ruled out.

Figure 3A shows a His-refractory VPD delivered from the RVA at the time of anticipated His. The surface ECG shows manifest fusion with advancement of the entire circuit on the next beat by 22 ms; this confirmed the presence of a bypass tract. A His-refractory VPD that pre-excites the next His and ventricular beat proves the BPT is participating in the circuit; further differential pacing maneuvers are required to delineate the proximal and distal insertion sites of the BPT.

The BPT proximal insertion was not suggestive of a septal concealed AV pathway because the A-A interval immediately after the His-refractory VPD was not advanced or delayed. Notably, the H-H interval is advanced before the A-A interval. A BPT inserting into the AV node could elicit this response to a His-refractory VPD. This can occur if retrograde exit to the atrium is proximal and remote to the turn-around point in the AV node; activation anterogradely via the His would then precede retrograde atrial activation.

Figure 3B shows VOP from the RVA at 530 ms, 20 ms shorter than the TCL. A V-A-H-V response to VOP was demonstrated, ruling out AT. Surface ECG showed no evidence of fusion, as the QRS morphology was identical to that of a paced beat. The stimulus-atrial time compared to the ventriculoatrial time was 135 ms. This would not be in favor of a concealed septal AV accessory pathway.² A His

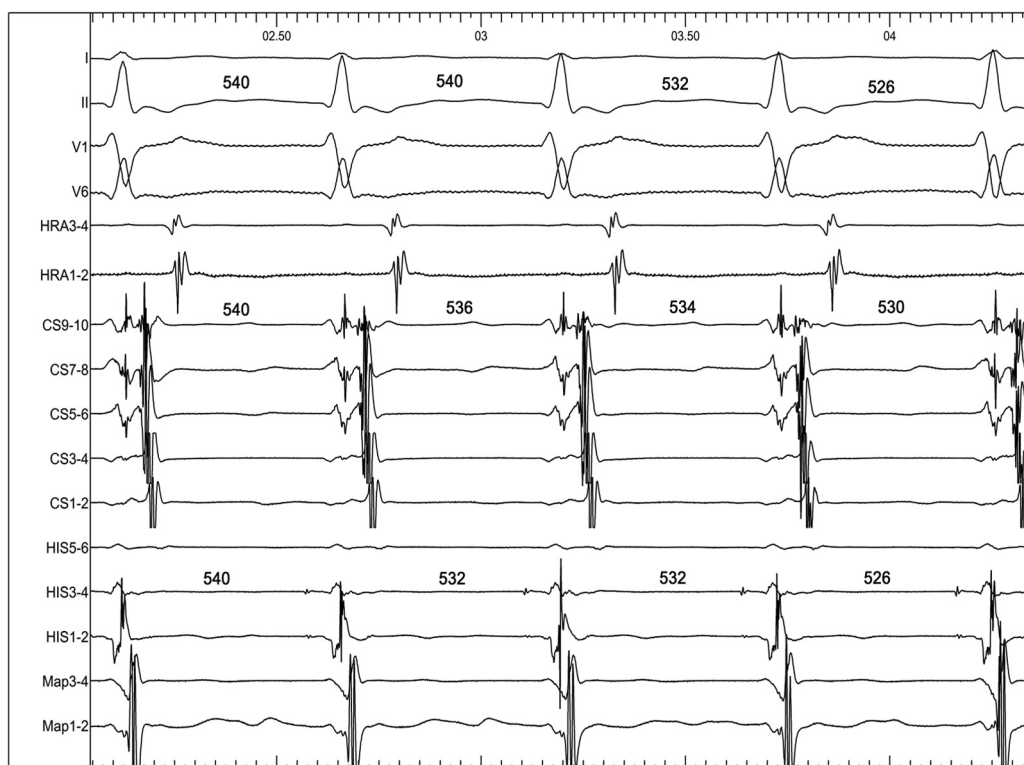

Figure 1 A 4-wire electrophysiology study demonstrating a short RP narrow complex tachycardia. Oscillations of the His bundle potential on HIS 3–4 precede changes of the atrial electrogram on CS 9–10. CS = coronary sinus; HIS = recording of His bundle potential; HRA = high right atrium; Map 1–2 = positioned at right ventricular apex.

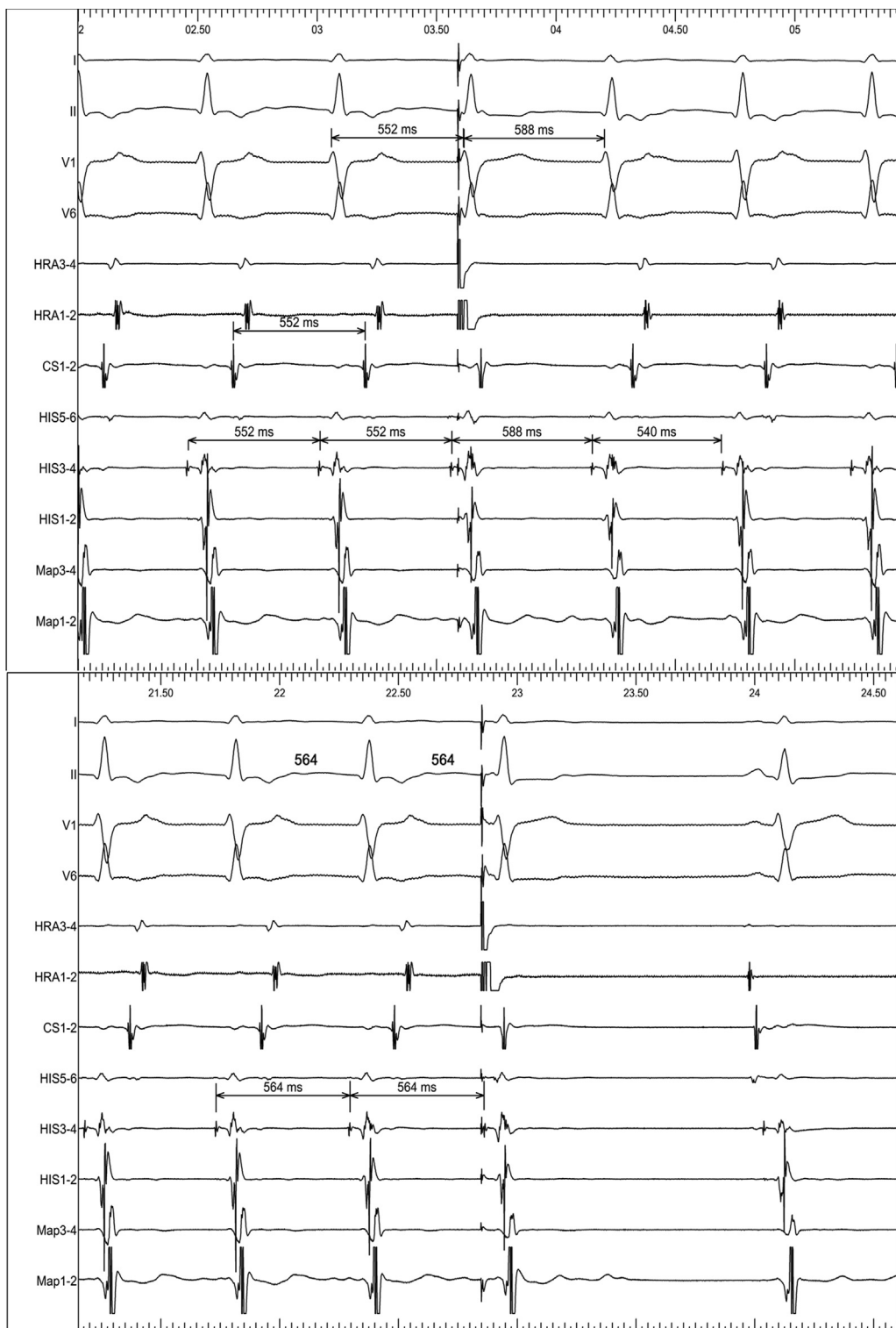


Figure 2 Programmed extrastimulus from the high right atrium at the time of His refractoriness. Each panel demonstrates the response to an atrial premature depolarization from the high right atrium at time of His refractoriness. CS = coronary sinus; HIS = recording of His bundle potential; HRA = high right atrium; Map 1-2 = positioned at right ventricular apex.

bundle potential was recorded on HIS 3-4 during VOP; the His bundle potential becomes inscribed in the ventricular electrogram during VOP. [Figure 3B](#) shows the first return H-H and A-A intervals with cessation of VOP, both intervals

approximating the paced cycle length (526 ms). This could be explained if the last stimulated wavefront captures the His anterogradely with a long stimulus-His time (indicated by arrow); the first return beat is therefore entrained but not

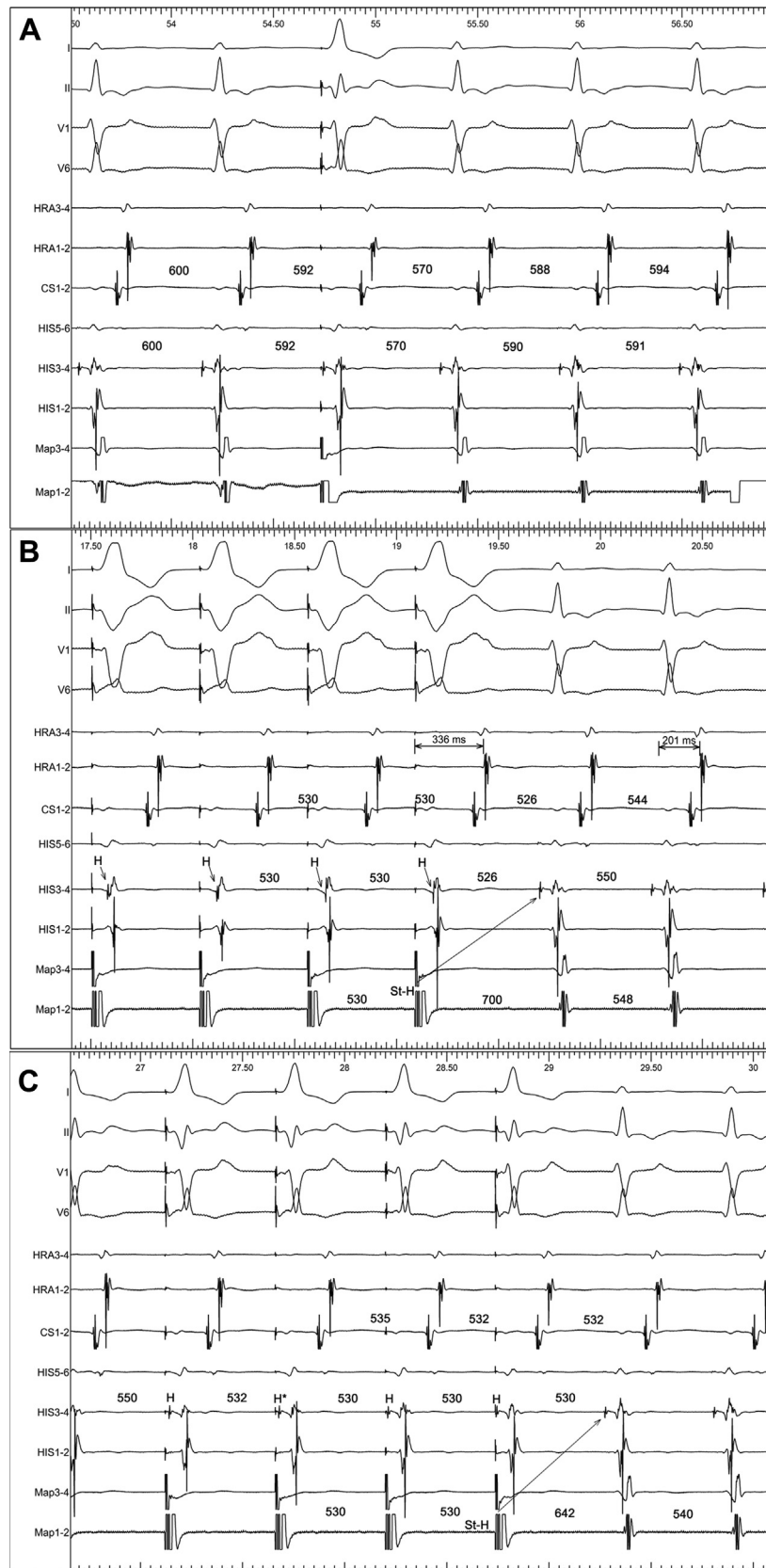


Figure 3 Ventricular pacing maneuvers during tachycardia. **A:** Shows the response to a ventricular premature depolarization at time of expected His. **B:** Shows ventricular overdrive pacing with a long postpacing interval and a long stimulus-His (St-H) interval; arrows indicate location of and acceleration of His to paced cycle length. **C:** Shows response to ventricular overdrive pacing with His electrograms labeled (H) and a St-H arrow; H* indicates first entrained His. CS = coronary sinus; HIS = recording of His bundle potential; HRA = high right atrium; Map 1-2 = positioned at right ventricular apex.

fused. In AVNRT or OAVRT the last accelerated atrial activation should immediately follow the last paced beat. In this example the atrium is being accelerated to the pacing rate after orthodromic wavefront activation of the ventricle. The most likely explanation for the lack of QRS fusion is owing to decrement being introduced into the circuit. If either limb of the circuit is susceptible to decrement, the greater antidromic wavefront penetration in the His-Purkinje network; thus less ventricular myocardium will be orthodromically activated.

A postpacing interval (PPI) – TCL of 150 ms does not meet the <115 ms criterion for diagnosing ORT; however, these values are not reliable for tachycardias with cycle lengths > 500 ms, as introducing decrement into the circuit becomes a limiting factor.³ Figure 3C shows a second attempt of VOP from the RVA pacing at 530 ms; surface ECG shows a fused QRS with the H-H interval accelerated to the paced cycle length (indicated with H*) on the second fused QRS complex and fixed A-A intervals on the third fused QRS complex; the PPI-TCL is 102 ms. A His electrogram is recorded on HIS 3–4 during VOP; the long stimulus-His interval (indicated by arrow) demonstrates an identical His morphology at the time of entrainment compared with the His during tachycardia. Entrainment of ORT with a NV-BPT is more likely to demonstrate manifest fusion, as the site of pacing can be adjacent to the BPT, thus allowing antidromic wavefront and orthodromic wavefront collision distal to the His-Purkinje network.³ In this example the antidromic paced wavefront from the RVA collides in the distal His-Purkinje network after orthodromic His, right bundle branch, and left bundle branch activation.

In conclusion, the patient had ORT with a concealed NV-BPT and passive 1:1 ventriculoatrial activation (see Supplemental Figure S1). Case reports suggest that a critical AV delay allows the NV-BPT to recover and sustain tachycardia.⁴ In our case the patient had sinus arrhythmia with junctional escape beats; this blocked atrial input to the AV node and allowed sufficient but critical time for conduction to proceed anterogradely to the ventricle and retrogradely to the AV node via the NV-BPT. A His-refractory VPD that advances the next His and ventricular beat proves the presence of a NV-BPT.⁴ Reports have suggested that the distal insertion of a NV-BPT is more likely to be located at the base of the right ventricle; this can lead to long PPIs when entrainment is performed from the RVA.⁴ Variable PPIs with entrainment and variable QRS fusion could be attributed to decremental properties of a NV-BPT.

Ablation could be targeted at the distal insertion site of the NV-BPT; however, reports suggest that ablation at the earliest atrial activation or in the slow pathway region is effective.⁴ Ablation was performed at the slow pathway region, resulting in short runs of junctional tachycardia; during delivery of ablation retrograde VA block prompted abrupt cessation of ablation.

After several ablation attempts with a similar response, an infusion of isoprenaline 1 mcg/min was recommenced, and tachycardia neither initiated spontaneously nor was induced with programmed extrastimuli. The patient confirmed complete cessation of symptoms and his recovery was uneventful. He was discharged the following day and 4 months later in clinic reported no further symptoms, having previously complained of incessant daily palpitations.

Conclusion

This is a case report of a rare arrhythmia mechanism that was identified using diagnostic pacing maneuvers at the time of EP study. NV bypass tract pathways are difficult to diagnose, as their location within the tachycardia circuit is often not identifiable. We have shown that the mechanism of tachycardia can still be diagnosed with careful analysis and systematic performance of each pacing maneuver at the time of EP study.

Appendix Supplementary data

Supplementary data associated with this article can be found in the online version at <https://doi.org/10.1016/j.hrcr.2018.06.005>.

References

1. Katritsis DG, Marine JE, Latchamsetty R, Zografos T, Tanawuttiwat T, Sheldon SH, Buston AE, Calkins H, Morady F, Josephson ME. Coexistent types of atrioventricular nodal reentrant tachycardia: Implication for the tachycardia circuit. *Circ Arrhythm Electrophysiol* 2015;8:1189–1193.
2. Bennett MT, Leong-Sit P, Gula LJ, Skanes AC, Yee R, Krahn AD, Hogg EC, Klein GJ. Entrainment for distinguishing atypical atrioventricular node reentrant tachycardia from atrioventricular reentrant tachycardia over septal accessory with long-RP tachycardia. *Circ Arrhythm Electrophysiol* 2011;4:506–509.
3. Ho RT, Frisch DR, Pavri BB, Levi SA, Greespon AJ. Electrophysiological features differentiating the atypical atrioventricular node-dependent long RP supraventricular tachycardias. *Circ Arrhythm Electrophysiol* 2013;6:597–605.
4. Badhwar N, Scheinmann MM. Nodofascicular/nodovertricular accessory pathway. In: Hirao K, eds. *Catheter Ablation*. Singapore: Springer; 2018;291–295.