

## Review Article

# Microsurgical Reconstruction of the Jaws Using Vascularised Free Flap Technique in Patients with Medication-Related Osteonecrosis: A Systematic Review

Roberto Sacco <sup>1,2,3</sup>, Nicola Sacco,<sup>4</sup> Umar Hamid,<sup>3</sup> Syed Hasan Ali,<sup>3</sup> Mark Singh,<sup>5</sup> and John St. J. Blythe<sup>6</sup>

<sup>1</sup>Barts and The London School of Medicine and Dentistry, London, UK

<sup>2</sup>Eastman Dental Institute, London, UK

<sup>3</sup>King's College Hospital, London, UK

<sup>4</sup>Department of Anaesthesiology, Resuscitation and Intensive Care Medicine, University of Campania "Luigi Vanvitelli", Naples, Italy

<sup>5</sup>Mid Essex Hospital Service NHS Trust, Chelmsford, UK

<sup>6</sup>Bart's and The London NHS Trust, London, UK

Correspondence should be addressed to Roberto Sacco; [r.sacco@ucl.ac.uk](mailto:r.sacco@ucl.ac.uk)

Received 21 January 2018; Revised 2 April 2018; Accepted 9 May 2018; Published 7 June 2018

Academic Editor: Noam Yarom

Copyright © 2018 Roberto Sacco et al. This is an open access article distributed under the Creative Commons Attribution License, which permits unrestricted use, distribution, and reproduction in any medium, provided the original work is properly cited.

**Background.** Osteonecrosis of the jaw (ONJ) has been reported to be associated with patients receiving primarily bisphosphonate (BP) therapies. However, lately it has been documented that other medications, such as RANK ligand inhibitor (denosumab) and antiangiogenic drug, can cause ONJ. Micro-osseous-vascular reconstruction of the jaws in patients affected by medication-related osteonecrosis of the jaw represents a viable option of treatment for patients affected by stage III of the disease. However, there are still considerable doubts about the success of this procedure in the short, medium, and long term. **Material and Methods.** A multidatabase (PubMed/MEDLINE, EMBASE, and CENTRAL) systematic search was performed. Any type of studies considering human patients treated with antiresorptive and antiangiogenic drugs was considered. The aim of the research is to primarily understand the success rate of micro-osseous-vascular reconstruction in the short, medium, and long period of time. This review has also the goal of better understanding any perioperative and postoperative complications resulting from the use of the reconstruction techniques. **Results.** Eighteen studies resulted eligible for the study. Fibula free flap is the most commonly utilised vascularised free flap reconstruction technique (80.76%). Ten out of eighteen studies reported no complications. Recurrence of osteonecrosis was registered in five cases (6.41%) after free flap reconstruction. The overall free flap success rate was 96.16%. **Conclusions.** Based on the limited data available in literature (Level 4 of the Oxford Evidence-based medicine scale), micro-osseous-vascular reconstruction of the jaws represents a valid treatment in patients with bisphosphonate-related osteonecrosis at stage III of the disease. However, additional data based on a larger cohort of patients are necessary to justify this type of intervention in patient affected by MRONJ.

## 1. Introduction

Bisphosphonates (BP) are antiresorptive drugs used in the management of conditions as diverse as osteoporosis and metastatic bone diseases. These drugs are widely administered and generally well tolerated by patients. In 2003, Marx et al. [1] first reported a nonhealing necrosis of the maxillofacial region in some patients taking BPs.

In the last decade researchers have discovered that BPs not exclusively cause osteonecrosis of jaws, as other

drugs, such as antiresorptive (bone-targeted) agents like denosumab, but also were found to cause it. In addition, monoclonal antibodies able to bind and selectively inhibit VEGF-A, specifically mTOR inhibitors, can also cause osteonecrosis of the jaw [2–6].

For this reason, in 2014 the bisphosphonate-related osteonecrosis of the jaw (BRONJ) nomenclature was changed by the position paper of the American Association of Oral and Maxillofacial Surgeons (AAOMS) special committee on Medication-Related Osteonecrosis of the Jaws (MRONJ) [7].

The term “medication-related osteonecrosis of the jaws” (MRONJ) refers to a complication associated with groups of medications, such as antiangiogenic or antiresorptive drugs [8]. These medications can have different indications depending on their mode of administration (Tables 1 and 2) [9, 10].

According to AAOMS, MRONJ is defined as an exposition of necrotic bone in the oral cavity lasting more than 8 weeks, in patients who took antiresorptive or antiangiogenic drugs; these patients have not been exposed to head and neck radiotherapy, nor show signs of bone metastases in the maxillofacial region [7].

A number of systemic risk factors have been associated with increased likelihood of MRONJ; they are summarised in Table 3 [11, 12].

Dental extraction or other surgical procedures such as apicectomies or cystectomies have been found in between 52% and 80% of MRONJ patients’ medical history [13–15].

During the last decade AAOMS has revised and proposed a clinical staging classification system of the disease in an attempt to guide clinicians and surgeons to an appropriate therapeutic approach (Table 4).

The management of MRONJ is reported to be very challenging and with no current “gold standard”. Published studies have reported a number of approaches to treatment, with widely varying success rates, ranging from no or limited to radical surgery. The ideal outcome is total eradication of MRONJ along with an improvement of patients’ quality of life through pain release and infection management [16].

Conservative treatment was considered to be partially successful, with resolution reported in only 50% of cases; particular concerns have been reported on MRONJ at clinical stages II and III [17–19]. In case conservative treatments fail, surgical approaches like local debridement, osteoplasty, and segmental osteotomy are normally performed [20, 21].

However, patients that show evidence of MRONJ stage III with severe pain, infection, pathologic fracture, extra-oral fistula, or osteolysis extending to the inferior border of the mandible require an invasive type of surgery which might result in a disabling outcome [7, 16, 22].

The absence of a well-established surgical treatment protocol in scientific literature makes it difficult to conduct therapy in advanced cases of the disease.

Up to date, there is no standard treatment for MRONJ associated with antiresorptive and antiangiogenic therapies. Several treatment options have been described since MRONJ was first reported. Although the initial stages of MRONJ seem to respond quite well to conservative treatments or limited bone debridement if conservative treatment fails, the treatment for stage III lesions remains still controversial [23, 24].

The objective of this review is to evaluate the outcome of free vascularised osseous tissue transfer and/or osteofasciocutaneous free flap as treatment for patients affected by MRONJ stage III. Systematic reviews have been already published. However, these reviews were not performed in a standardised manner or did not follow strict criteria. Moreover the previous reviews did not consider antiangiogenic drugs in the search criteria. This has resulted in lack of quality

assurance, summarised in Table 5 [25–27]. This review aims to improve the quality of previous research and expand on the current data available.

## 2. Materials and Methods

This systematic review was performed according to PRISMA guidelines [44].

The following the databases were used for the review: PubMed/MEDLINE, EMBASE, and Cochrane Central Register of Controlled Trials (CENTRAL). A three-stage screening approach was used to ensure precision and the quality of the search. The screening of titles and abstracts was carried out independently by three authors (AH, UH, and RS) to eliminate any irrelevant materials (i.e., reviews, animal studies, nonclinical studies, and studies that did not report on patients undergoing to free tissue graft). Disagreements were resolved by discussion.

A data screening and abstraction form was used to

- (1) verify the study eligibility derived from the above inclusion/exclusion criteria,
- (2) carry out the methodological quality assessment,
- (3) extract data on study characteristics and outcomes for the included studies.

The authors of any studies eligible for inclusion in the review, yet without sufficient information, were contacted directly (Figure 1).

### 2.1. Criteria for Inclusion in This Review

**2.1.1. Types of Studies.** The types of studies included in the research strategy were published or unpublished randomised control trials, case-controlled trials, case series, retrospective studies, and case reports. Papers were obtained from January 2003 to June 2017. Animal studies and those including patients with previous history of radiation therapy to the head and neck regions were excluded. No language restrictions were imposed to the search.

**2.1.2. Types of Participants.** The review considered studies involving patients who developed MRONJ and subsequently underwent free vascularised osseous tissue transfer and/or osteofasciocutaneous free flap reconstruction. No restriction of age, gender, or ethnic origin was applied. There was no restriction on the minimum number of patients included in the studies.

**2.1.3. Types of Interventions.** Only free vascularised osseous tissue transfer and/or osteofasciocutaneous free flap reconstruction were considered.

### 2.1.4. Types of Outcome Measures

**Primary Outcomes.** Primary outcome measures of the review included the success rate of free flap without any restrictions in follow-up. The other considered measures were the

TABLE 1: Antiresorptive drugs used in oncologic and nononcologic patients. Btl: bottle; IM: intramuscular; IV: intravenous; MM: multiple myeloma; PO: orally; SC: subcutaneous; SRE: skeletal-related event; Tab: tablet.

Pharmacologic active ingredient	Formulation	Route of administration	Indication and frequency
Alendronic acid (sodium salt)	Tab 70 mg Tab 10 mg	PO	Treatment of postmenopausal osteoporosis (70 mg/week) Treatment of osteoporosis in men (70 mg/week) Treatment and prevention of osteoporosis induced by glucocorticoids (70 mg/week)
Alendronic acid + cholecalciferol	Tab 70 mg/5600 UI	PO	Treatment of postmenopausal osteoporosis in patients with unsupplemented vitamin D deficit (70 mg/week)
Ibandronic acid (monosodium salt monohydrate)	Tab 50 mg Btl 6 mg/6 ml Tab 150 mg Btl 3 mg/3 ml	PO IV PO IV	Prevention of SREs in breast cancer patients with bone metastases (50 mg/day p.o. or 6 mg every 3–4 weeks iv.) Treatment of hypercalcemia of malignancy Treatment of postmenopausal osteoporosis in patients at high risk of fracture (150 mg/4 weeks p.o. or 3 mg every 3 months iv.)
Neridronate acid (sodium salt)	Btl 25 mg/2 ml Btl 100 mg/8 ml	IV/IM. IV	Osteogenesis imperfecta (2 mg/kg/3 months) Paget's bone disease (different schedules)
Pamidronic acid (disodium salt)	Btl 15 mg/5 ml Btl 30 mg/10 ml Btl 60 mg/10 ml Btl 90 mg/10 ml	IV	Prevention of SREs in breast cancer patients with bone metastases or MM with bone lesions (60–90 mg every 3–4 weeks) Treatment of hypercalcemia of malignancy
Zoledronic acid (monohydrate)	Btl 4 mg/5 ml Btl 5 mg/100 ml	IV IV	Prevention of SREs in cancer patients with bone metastases or MM (4 mg every 3–4 weeks). Treatment of hypercalcemia of malignancy Treatment of osteoporosis in postmenopausal women, in men at increased risk of fracture, including those with a recent hip fracture from minor trauma (5 mg once per year) Treatment of bone Paget's disease
Denosumab	Btl 120 mg Btl 60 mg	SC SC	Prevention of SREs in cancer patients with bone metastases (120 mg every 4 weeks) Treatment of hypercalcemia of malignancy. Osteoporosis (60 mg sc. every 6 months)

TABLE 2: Main antiangiogenic drugs used (IV: intravenous; MM: multiple myeloma; PO: orally; SC: subcutaneous; Btl: bottle; Tab: tablet).

Pharmacologic active ingredient	Formulation	Route of administration	Indication and frequency
Bevacizumab	Btl 400 mg Btl 100 mg	IV	Metastatic breast cancer (10 mg/kg every 2 weeks or 15 mg/kg every 3 weeks); colorectal cancer (5 mg/kg or 10 mg/kg every 2 weeks); lung/ovarian cancer (7.5 mg/kg or 15 mg/kg every 3 weeks); renal cell cancer (10 mg/kg every 2 weeks); glioblastoma (10 mg/kg every 2 weeks)
Sunitinib	Tab 12.5 mg	PO	Renal cell cancer, GISTs and neuroendocrine tumors (50 mg/day for 4 weeks)
Sorafenib	Tab 200 mg	PO	Renal cell cancer (800 mg/day)
Pazopanib	Tab 200 mg Tab 400 mg	PO	Renal cell cancer (200–800 mg/day)
Thalidomide	Tab 50 mg	PO	Myeloma (400 mg/day for 6 weeks)
Lenalidomide	Tab 5, 10, 15 and 25 mg	PO	Myeloma (tailored doses)
Everolimus	Tab 5 and 10 mg	PO	Renal cell cancer, breast cancer (10 mg every day)
Temsirolimus	Btl 30 mg	IV	Renal cell cancer (25 mg every week)

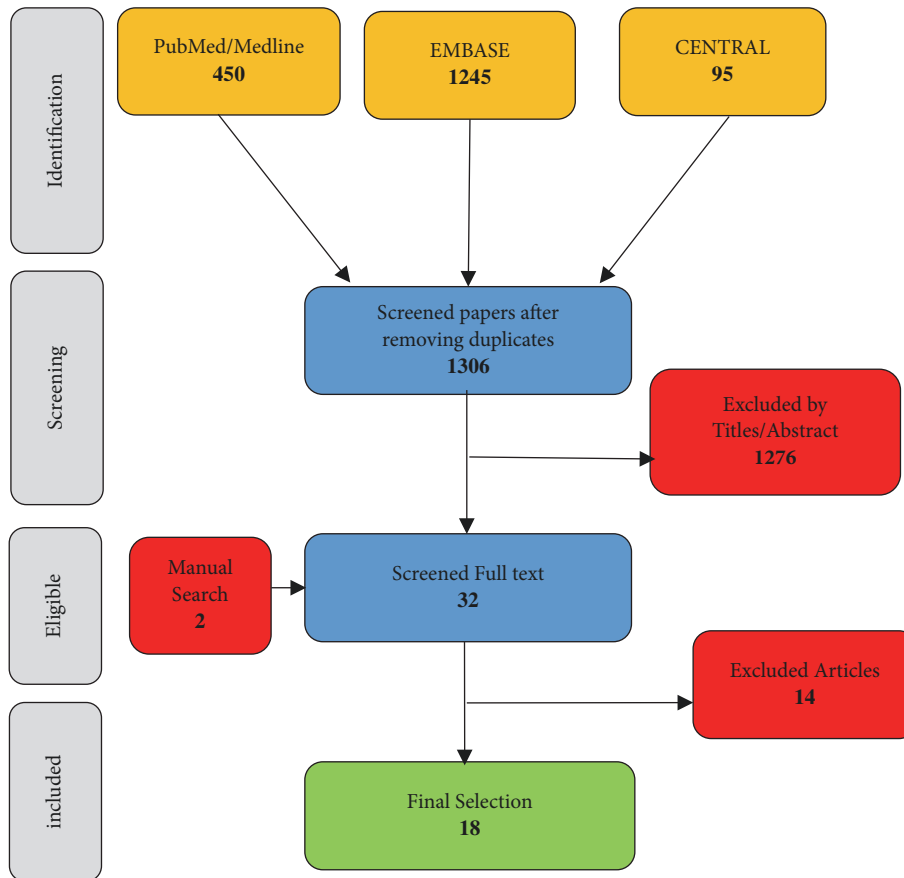


FIGURE 1: Review process for the titles, abstracts, and full-text reading of the selected references.

TABLE 3: Drug-related risk factor of osteonecrosis of the jaw in the cancer population according to Campisi et al. 2011 [11].

Risk Factor	Strenght
Zoledronate vs Other Bisphosphonate	+++
Intravenous vs Oral Bisphosphonate	++
Bisphosphonate cumulative dose	+++
Bisphosphonate duration of treatment	+++
Anti-angiogenic drugs	++
Denosumab	++
Chemotherapy	-/+
Thalilomide	+/-

frequency of MRONJ recurrence in the free flap or in the surgical residual jaw bone.

*Secondary Outcomes.* The secondary measures of the review entailed perioperative complications and those at follow-up, including the most common cause of the MRONJ and the time during which the patient was treated with the antiresorptive or antiangiogenic drugs prior ONJ.

*2.2. Data Extracted.* Data extracted from the eighteen studies included number of patients, patient sex, and age,

predisposing factors for, and localisation of, MRONJ, type of antiangiogenic or antiresorptive drugs and their cumulative dose, clinical indications for the drug or combined therapy, extent of the surgical excision, type of free vascularised tissue reconstruction, free flap failure, immediate complications, follow-up time, and MRONJ recurrence.

All selected papers were carefully read to identify author(s), year of publication, study design, population and treatment characteristics, and number of patients with recurrent MRONJ.

In case of missing information, we contacted the authors and gave them 6 weeks to reply. If the information was still missing we then indicated the missing data as “Not Reported (NR)” in the text and in the tables.

### 3. Results

Results were expressed in descriptive statistics. No randomised controlled clinical trials or case-controlled studies comparing free flap reconstruction after resection in MRONJ patients were found. A total number of 18 articles we included in the study. All the published dates were described in case report (no. 6) and case series (no. 12) from 2008 to 2017 (Table 6). A total of 83 patients, 47 females (56.62%), 19 males (22.89%), and missing information for 20.49% (NR) of the

TABLE 4: MRONJ staging according the AAOMS [7].

Stage	MRONJ clinical findings
At risk category	No apparent necrotic bone in patients who have been treated with either oral or IV bisphosphonates
Stage 0	No clinical evidence of necrotic bone, but non-specific clinical findings, radiographic changes and symptoms
Stage I	Exposed and necrotic bone, or fistulae that probes to bone, in patients who are asymptomatic and have no evidence of infection
Stage II	Exposed and necrotic bone, or fistulae that probes to bone, associated with infection as evidenced by pain and erythema in the region of the exposed bone with or without purulent drainage
Stage III	Exposed and necrotic bone or a fistula that probes to bone in patients with pain, infection, and one or more of the following: exposed and necrotic bone extending beyond the region of alveolar bone, (i.e., inferior border and ramus in the mandible, maxillary sinus and zygoma in the maxilla) resulting in pathologic fracture, extra-oral fistula, oral antral/oral nasal communication, or osteolysis extending to the inferior border of the mandible of sinus floor

TABLE 5: Systematic review currently published and their limitations.

Systematic Review	Limitation
Sacco et al. (2011) [27]	English literature limited search; Single Electronic database search.
Vercruyse et al. (2014) [25]	Search Limited to BRONJ and or bisphosphonate related necrosis; No mentioning to language limitation; Review based on a single reviewer selection of articles
Neto et al. (2016) [26]	Single Electronic database search; Search Limited to BRONJ and or bisphosphonate related necrosis; No mentioning to language limitation; No mentioning reviewer involved in the search strategy.

TABLE 6: Study selected with total number of patient treated.

Study	Type of study	Patients number
Engroff and Kim (2007) [28]	Case series	2
Ferrari et al. (2008) [29]	Case Report	1
Mücke et al. (2009) [30]	Case series	2
Nocini et al. (2009) [31]	Case series	7
Seth et al. (2010) [32]	Case series	11
Bedogni et al. (2011) [33]	Case series	3
Pautke et al. (2011) [34]	Case report	1
Bittner et al. (2012) [35]	Case report	1
Ghazali et al. (2013) [36]	Case report	1
Hanasono et al. (2013) [37]	Case series	11
Horta et al. (2014) [38]	Case series	1
Spinelli et al. (2014) [39]	Case series	8
Vercruyse et al. (2014) [25]	Case series	3
Kim et al. (2015) [40]	Case series	4
Mücke et al. (2016) [41]	Case series	14
Neto et al. (2016) [26]	Case report	1
Sotsuka et al. (2016) [42]	Case report	1
Caldrony et al. (2017) [43]	Case Series	11

cases, were treated using vascularised osseous tissue transfer and/or osteofasciocutaneous free flap reconstruction.

The most common indications for antiresorptive or antiangiogenic treatment were breast cancer (28.91%), multiple myeloma (22.89%), osteoporosis (14.45%), prostate cancer (9.63%), lung cancer (2.40%), myeloid-leukemia and

osteoporosis (1.20%), pain syndrome (1.20%), and NR in the 19.32% of the cases (Table 7). The most common site for MRONJ was the mandible 97.59% and 2.41% in the maxilla (Table 8).

Zoledronate was responsible for the majority of the MRONJ with 42.16 %, then pamidronate 7.22%, alendronate 8.43%, ibandronate 2.40%, and etidronate 1.20%. A combination of the following drugs and the relative incidence percentage were also found responsible:

- zoledronate and pamidronate (13.25%);
- zoledronate and clodronate (1.20%);
- zoledronate and denosumab (1.20%);
- pamidronate and denosumab (1.20%);
- alendronate, risedronate, and pamidronate (1.20%).

A total of 20.54% patients presented missing information with regard to the type of drug used.

69.90% of the cases missed information on the causes of the MRONJ.

The most commonly utilised vascularised free flap reconstruction was fibula free flap (81.92%), followed by iliac crest (12.04%) and scapula (6.02%).

The most frequent type of resection was subtotal (32.53%), followed by segmental (26.50%) and partial (2.40%). However a large percentage of missing data was found regarding the type of resection (NR 38.57%) (Table 9).

The patients were followed for a period of time ranging from 2 weeks up to 99 months.

Radiographic imaging with CT, cone-beam, and/or orthopantomogram was obtained during follow-up in 95% of the cases.

At follow-up and after free flap reconstruction, recurrence of MRONJ (6.02%) was observed in 5 patients: two of the patients (2.40%) on the contralateral unresected part

TABLE 7: Preoperative pharmacological analysis: type of drugs, indication for drug therapy, and time of drug exposure. ZOL: zoledronate; ALD: alendronate; PMT: pamidronate; COL: clodronate; DZM: denosumab; IBA: ibandronate; ETI: etidronate; mth: months; RSD: risedronate; NR: not reported.

Study	Type of drug	Indication for drug therapy	time of drug exposure
Engroff and Kim (2007) [28]	PMT (x 1 case) ZOL (x 1 case)	Brest Cancer (x 2 cases)	NR
Ferrari et al. (2008) [29]	PMT + ZOL	Multiple Myeloma	21 mth (PMT) 3 mth (ZOL) discontinue therapy
Mücke et al. (2009) [30]	ZOL (x 2 cases)	Brest cancer (x 1 case); Multiple Myeloma (x 1 case)	50mth (ZOL) 36 mth (ZOL)
Nocini et al. (2009) [31]	PMT and ZOL (x 5 cases) ZOL (x 2 cases)	Brest Cancer (x 5 cases); Prostate Cancer (x 1 case); Myeloid leukaemia and Osteoporosis (x 1 case)	NR
Seth et al. (2010) [32]	ZOL (x 6 cases) ALD (x 2 cases) IBA (x 2 cases) ETI (x 1 case)	Brest Cancer (x 5 cases); Prostate Cancer (x 2 cases); Multiple Myeloma (x 2 cases); Osteoporosis (x 2 cases)	NR
Bedogni et al. (2011) [33]	NR	NR	NR
Pautke et al. (2011) [34]	ZOL	Prostate Cancer	40 mth
Bittner et al. (2012) [35]	ZOL and PMT	Pain syndrome	12 mth (ZOL) 3 mth (PMT)
Ghazali et al. (2013) [36]	ALD	Osteoporosis	84 mth (ALD)
Hanasono et al. (2013) [37]	ZOL (x 9 cases) PMT (x 2 cases)	Multiple Myeloma (x 5 cases); Breast Cancer (x 2 cases); Prostate Cancer (x 2 cases); Osteoporosis (x 2 cases)	NR
Horta et al. (2014) [38]	ZOL	Lung Cancer	36 mth (ZOL)
Spinelli et al. (2014) [39]	ZOL (x 3 cases) PMT (x 3 cases) ZOL and PMT (x 2 cases)	Multiple Myeloma (x 4 cases); Breast Cancer (x 3 cases); Prostate Cancer (x 1 case)	1 x 27 mth (ZOL) 1 x 21 mth (ZOL) 1 x 35 mth (ZOL) 1 x 22 mth (PMT) 1 x 30 mth (PMT) 1 x 19 mth (PMT) 1 x 25 mth (ZOL and PMT) 1 x 17 mth (ZOL and PMT)
Vercruyssen et al. (2014) [25]	1 x ZOL 1 x ZOL + PMT 1 x ZOL + CLO	Multiple Myeloma (x 2 case); Breast Cancer (x 1 case)	1 x 22mth (ZOL) 1x 12 mth (PMT) + 26 mth (ZOL) 1x 96 mth (CLO) + 29mth (ZOL)
Kim et al. (2015) [40]	ALD (x 2) ALD + RSD + PMT (x 1) ZOL + PMT (x 1)	Osteoporosis (x 3) Multiple Myeloma (x 1)	1 x 48 mth (ALD) 1 x 120 mth (ALD) 1 x 24 mth (ALD + RSD +PMT) 1 x 30mth (ZOL +PMT)
Mücke et al. (2016) [41]	NR	NR	NR
Neto et al. (2016) [26]	ZOL	Lung Cancer	36 mth (ZOL)
Sotsuka et al (2016) [42]	ZOL	Brest Cancer	59 mth (ZOL)
Caldronney et al. (2017) [43]	7 x ZOL 2 x ALD 1 x ZOL + DZM 1 x PMT + DZM	Brest Cancer (x 4 cases) Osteoporosi (x 3 cases) Multiple Myeloma (x 3 cases) Prostate Cancer (x 1 case)	NR

of the jaw, other two patients (2.40%) on the margin of the resection, and one patient (1.20%) on the grafted flap. The overall free flap failure rate registered was 3.61% (Table 10).

**3.1. Review Quality Assessment Data.** All the studies and data extraction included in the systematic review were qualitative

and the risk of bias assessed independently by the authors. The authors used the CARE Checklist for case report and the Modified Delphi Checklist for the case series studies.

In the six case report studies, we identified lack of clarity in many of the thirteen domains, with missing information. We found that the lack of clarity was predominantly on

TABLE 8: Preoperative epidemiologic analysis (age, sex, predisposing factors, and site of the necrosis involved). M: male; F: female; NR: not reported.

Study	Type of study	Patients number	Age/Sex	Triggering cause	Site of the necrosis involved
Engroff and Kim (2007) [28]	Case series	2	64 (F); 49 (F)	Dental extraction (x 2 cases)	Mandible (x 2 cases)
Ferrari et al. (2008) [29]	Case report	1	66 (M)	NR	Mandible
Mücke et al. (2009) [30]	Case series	2	48 (F); 60 (F)	Dental Extraction (x 1 case); Spontaneous (x 1 case)	Mandible (x 2 cases)
Nocini et al. (2009) [31]	Case series	7	NR (six F); (one M)	Oral surgery (x 5 cases); Infection (x 2 cases)	Mandible (x 7 cases)
Seth et al. (2010) [32]	Case series	11	68 (M); 56 (F); 50 (F); 72 (F); 48 (F); 71 (F); 67 (F); 60 (F); 51 (F); 72 (M); 60 (F)	NR	Mandible (x 11 cases)
Bedogni et al. (2011) [33]	Case series	3	NR	NR	Mandible (x 2 cases); Maxilla (x 1 case)
Pautke et al. (2011) [34]	Case report	1	76 (M)	Dental extraction	Mandible
Bittner et al. (2012) [35]	Case report	1	41 (F)	Dental extraction	Mandible
Ghazali et al. (2013) [36]	Case report	1	82 (F)	Dental extraction	Mandible
Hanasono et al. (2013) [37]	Case series	11	63 (F); 57 (M); 65 (M); 75 (F); 72 (M); 68 (M); 60 (F); 64 (F); 70 (F); 75 (F); 67 (F)	NR	Mandible (x 11 cases)
Horta et al. (2014) [38]	Case series	1	54 M	Spontaneous	Mandible
Spinelli et al. (2014) [39]	Case series	8	73 (M); 77 (F); 64 (F); 53 (F); 62 (M); 68 (F); 57 (M); 64 (F)	Dental extraction (x 3 cases); Spontaneous x 5	Mandible (x 8 cases)
Vercruyssen et al. (2014) [25]	Case series	3	54 (F); 70 (F); 64 (F)	Dental extraction (x 1 case); Spontaneous (x 2 cases)	Mandible (x 3 cases)
Kim et al. (2015) [40]	Case series	4	69 (F), 68 (F), 62 (F), 70 (M)	NR	Mandible (x 4)
Mücke et al. (2016) [41]	Case series	14	NR	NR	Mandible (x 14 cases)
Neto et al. (2016) [26]	Case report	1	58 (M)	Spontaneous	Mandible
Sotsuka et al. (2016) [42]	Case report	1	50 (F)	NR	Maxilla
Caldrony et al. (2017) [43]	Case series	11	56 (F); 65 (F); 60 (F); 61 (F); 65 (F); 64 (F); 68 (M); 67 (M); 73 (M); 72 (F); 73 (M).	NR	Mandible (x 11 cases)

follow-up and diagnostic procedure at the time of follow-up. Hence we concluded the level of bias to be high for all the included case report studies.

In the twelve case series studies, we reported a consistent lack of clarity in some of the seven domains, predominantly regarding the outcome measurement methods. Moreover, we identified some missing information in few other domains; hence we considered the level of bias to be high for all studies

We contacted the authors of these clinical cases to clarify this bias; however we were unable to recover the missing information.

#### 4. Discussion

Some antiresorptive drugs such as BP or denosumab have demonstrated to improve the quality of life in patients affected by bone metastasis, osteoporosis, osteopenia, and Paget disease. Additionally, a new antiangiogenic therapy has been successfully used for specific cancer treatments. However, this has remarkably increased the risk of developing MRONJ. This risk is greater in patients who require a higher administration dosage and an intake period greater than 2 years [14, 45, 46].

TABLE 9: Operative analysis: type of surgery, type of free flap, flap failure, immediate postoperative complications (FFF: fibula Free flap; ICFF: iliac crest free flap; SFF: scapula free flap).

Study	Type of surgery	Type of free flap	Flap failure	Immediate post-operative complications
Engroff and Kim (2007) [28]	2 x Segmental	2 x FFF	0	Small Neck hematoma in one patient
Ferrari et al. (2008) [29]	Sub-total	1x FFF	0	0
Mücke et al. (2009) [30]	2 x Segmental	1 x FFF; 1x ICFF	0	0
Nocini et al. (2009) [31]	7 x Subtotal	7 x FFF	0	Rupture of mini-plate in one patient
Seth et al. (2010) [32]	NR	11 x FFF	0	Prolonged infection in one patient; Fistula and infection in three patients.
Bedogni et al. (2011) [33]	NR	3 x FFF	1 (a year later)	0
Pautke et al. (2011) [34]	Segmental	1 x ICFF	0	Fistula resolved with removal of plate
Bittner et al. (2012) [35]	Segmental	1 x SFF	0	0
Ghazali et al. (2013) [36]	Segmental	1 x FFF	0	Sinus bradycardia
Hanasono et al. (2013) [37]	6 x subtotal 5 x segmental	11 x FFF	1	Hematoma in one patient; Pneumonia in one patient; Deep vein thrombosis in one patient; Small bowel obstruction in one patient. All complications occurred in FFF
Horta et al. (2014) [38]	1 x segmental	1 x FFF	0	0
Spinelli et al. (2014) [39]	8 x subtotal	8 x FFF	0	0
Vercruyssen et al. (2014) [25]	2 x Partial; 1 x Segmental	3 x ICFF	1 (segmental- 16 days later)	1 (failure)
Kim et al. (2015) [40]	NR	4 x FFF	0	0
Mücke et al. (2016) [41]	NR	9 x FFF 5 x ICFF	NR	NR
Neto et al. (2016) [26]	1 x segmental	1 x FFF	0	0
Sotsuka et al. (2016) [42]	NR	1 x FFF	0	0
Caldronney et al. (2017) [43]	6 x segmental 5 x sub total	4 x SFF 7 x FFF	0	Two cases with wound infection and dehiscence and one case the plate was removed. (3 different patients). One FFF and two SFF

Moreover, literature has reported that demography, corticosteroid therapy, systemic factors, and genetic factors have been associated with MRONJ. A recent review report showed a wide-ranging MRONJ incidence from 0 to 27.5% in individuals exposed to intravenous BPs, with a mean incidence of 7%, whereas it ranges from 0.1% to 0.06% in oral administrations [47–49].

Etiopathogenesis of MRONJ is not yet fully understood.

Although no gold standard is currently available for the treatment of jaw osteonecrosis, a number of studies debate which MRONJ stage benefits the most from surgical therapy [24, 50]. In general, for early stages of the disease (MRONJ 0 and I) conservative treatments might be sufficient; surgical treatment should be restricted to advanced stages (MRONJ II and III) or after failure of conservative treatments [7, 50].

The majority of researches as well as AAOMS consider conservative treatments as the treatment of choice of MRONJ.

However, there is not a robust evidence from clinical trials as treatment recommendations mostly come from expert opinions and are, therefore, characterised by a low level of evidence [24, 47].

The authors of the 2009 AAOMS position statement recommend reserving resection and immediate reconstruction to patients with stage III of the disease; however, positive outcomes have been noted in patients with stages II and III. Having said that no recommendations were given on which type of reconstruction was to be considered the most predictable [47]. The benefits of surgical management of MRONJ have been extensively debated in literature and radical surgery seems to offer more predictable and curative



TABLE 10: Complications during follow-up time.

Study	Follow-up time	Complications during follow-up (included plate removal)	MRONJ recurrence	Site of recurrence
Engroff and Kim (2007) [28]	2x12 months	0	Recurrence in one patient	Contralateral
Ferrari et al. (2008) [29]	1 x 12 months	Plate removal	0	0
Mücke et al. (2009) [30]	2x 12 months	0	0	0
Nocini et al. (2009) [31]	1x 6 months 1 x 16 months 1 x 23 months 1 x 24 months 1 x 19 months 1 x 33 months 1 x 34 months	0	Recurrence in one patient	Margin of the resection
Seth et al. (2010) [32]	1 x 10.0 months 1x 0.5 months 1x 30.8 months 1x 21.4 months 1x 17.8 months 1x 23.7 months 1x 10.6 months 1 x 14.2 months 1x 13.9 months 1x 12.2 months 1x 6.1 months	0	0	0
Bedogni et al. (2011) [33]	NR	failure of the FFF 1 year later	0	0
Pautke et al. (2011) [34]	NR	plate removal	Recurrence in one patient	On the free flap
Bittner et al. (2012) [35]	NR	0	0	0
Ghazali et al. (2013) [36]	24 months	0	0	0
Hanasono et al. (2013) [37]	1 x 13.3 months 1x 20.1 months 1x 77.0 months 1x 23.8 months 1x 11.4 months 1 x 9.1 months 1x 9.1 months 1x 9.1 months 1x 8.1 months 2 x 3.0 months	0	0	0
Horta et al. (2014) [38]	1 x 12 months	0	0	0
Spinelli et al. (2014) [39]	1x 21.7 months 1x 25.1 months 1x 28.4 months 1x 32.2 months 1x 37 months 1x 28.4 months 1x 25.1 months 1x 32.9 months	0	0	0
Vercruyssen et al. (2014) [25]	1x 36 months 1x 65 months 1x 76 months	Plate removal in one patient	Recurrence in one patient	Contralateral
Kim et al. (2015) [40]	1 x 99 months 1 x 18 months 1 x 12 months 1 x 7 months	Fracture of plate in one patient	0	0
Mücke et al. (2016) [41]	34.25 ± 33.3 months	-	Recurrence in one of the patient	Margin of the flap

TABLE 10: Continued.

Study	Follow-up time	Complications during follow-up (included plate removal)	MRONJ recurrence	Site of recurrence
Neto et al. (2016) [26]	1 x 48 months	0	0	0
Sotsuka et al. (2016) [42]	NR	0	0	0
Caldrony et al. (2017) [43]	3 x 6 months	Plate removal in one patient	0	0
	2 x 44 months			
	1 x 69 months			
	1 x 36 months			
	1 x 28 months			
	1 x 10 months			
	1 x 17 months			
1 x 11 months				

results. However, surgical treatment of early stages of MRONJ remains controversial [47, 50–52].

Aggressive radical surgery is offered only to symptomatic patients with extensive osteonecrosis, including those who have previously failed conservative treatments [41].

This review has indicated that surgical therapy may represent a treatment option for patients affected by MRONJ stage III resulting in high success rates. Mucke et al. and Caldrony et al. have documented excellent outcomes in treating patient affected by MRONJ stage III in large cohort studies [30, 43]. Since 2008 microvascular reconstruction of the jaw has been documented as a viable option for MRONJ. This systematic review confirmed that microsurgical reconstruction therapy represents a feasible alternative in case of treatment escalation.

Even though the majority of papers included in this study were case reports and small case studies, the outcome of free flap treatment has been promising with a significant low recurrence of MRONJ and minimal surgical complications [25, 26, 28–43].

The MRONJ recurrence rate found by this systematic review was 6.02% (5 patients). The predominant recurrence sites were the contralateral unresected part of the jaw (2 cases) and the margin of the resection (2 cases), both bearing an overall recurrence rate of 2.40%. Just one case of recurrence was found on the vascular reconstruction.

Infection was the most frequent complication found with 6.02% incidence. The overall free flap success rate was 96.39%. Three free flaps failed during a follow-up period ranging from 2 weeks up to 99 months.

Amongst all the types of reconstruction, free flap fibula was the most chosen, followed by iliac crest and scapula with success rates, respectively, of 97.60%, 98.80%, and 100%.

Antiresorptive drugs were explicitly discontinued in only three studies out of the eighteen, while no mention was reported in the remaining studies [31, 33, 41]. It is unclear if the discontinuation strategy leads to a better surgical outcome due to the long skeletal life of some antiresorptive drugs.

In line with the growing body of literature, our findings confirm positive results in treating patients with MRONJ using free flaps microvascular reconstruction. In order to

obtain a possible resolution of MRONJ, patients with reasonable life expectancy should be considered for microvascular flap reconstruction after aggressive resection of the diseased bone.

## 5. Conclusion

MRONJ is a significant adverse effect amongst patients under antiresorptive agents. Although MRONJ pathogenesis remains unclear, significant progress has been made with respect to the diagnosis and staging of the disease, as well as with risk-reduction strategies and treatments. This systematic review based on multiple-reviewer quality assessment criteria was only able to select articles that meet Level 4 of the Oxford Evidence-based medicine scale. Due to the nature of the MRONJ incidence and the critical condition of the patients affected by the primary disease, it is difficult to improve the quality of evidence unless a common effort is applied. Therefore, the authors believe that additional quality studies, such as control multicentre studies or case-controlled studies, are necessary to support the hypothesis of this study.

## Conflicts of Interest

This study was not supported by any company and all the authors have not conflicts of interest.

## Authors' Contributions

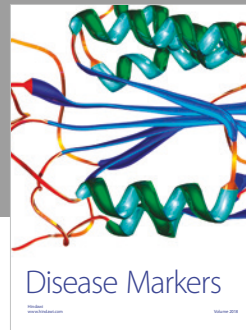

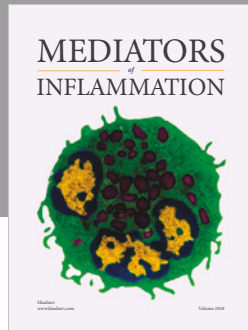
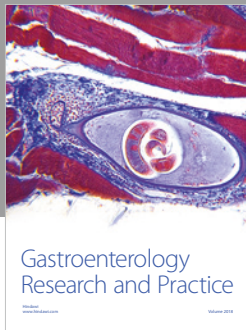
All the authors of this manuscript have substantial contributions to the conception or design of the work; to the acquisition, analysis, or interpretation of data for the work; to draft of the paper and revising it critically and finally approved the version to be published.

## References

- [1] R. E. Marx, "Pamidronate (Aredia) and zoledronate (Zometa) induced avascular necrosis of the jaws: a growing epidemic," *Journal of Oral and Maxillofacial Surgery*, vol. 61, no. 9, pp. 1115–1117, 2003.

- [2] S. L. Ruggiero, B. Mehrotra, T. J. Rosenberg, and S. L. Engroff, "Osteonecrosis of the jaws associated with the use of bisphosphonates: a review of 63 cases," *Journal of Oral and Maxillofacial Surgery*, vol. 62, no. 5, pp. 527–534, 2004.
- [3] S. Sivoilella, F. Lumachi, E. Stellini, and L. Favero, "Denosumab and anti-angiogenic drug-related osteonecrosis of the jaw: An uncommon but potentially severe disease," *Anticancer Research*, vol. 33, no. 5, pp. 1793–1798, 2013.
- [4] A. R. Santos-Silva, G. A. Belizário Rosa, G. D. Castro Júnior, R. B. Dias, A. C. Prado Ribeiro, and T. B. Brandão, "Osteonecrosis of the mandible associated with bevacizumab therapy," *Oral Surgery, Oral Medicine, Oral Pathology, Oral Radiology, and Endodontology*, vol. 115, no. 6, pp. e32–e36, 2013.
- [5] L. Ramirez, R. M. Lopez, and E. Casanas, "New non-bisphosphonate drugs that produce osteonecrosis of the jaws," *Oral Health and Preventive Dentistry*, vol. 13, pp. 385–393, 2015.
- [6] A. Brunello, G. Saia, A. Bedogni, D. Scaglione, and U. Basso, "Worsening of osteonecrosis of the jaw during treatment with sunitinib in a patient with metastatic renal cell carcinoma," *Bone*, vol. 44, no. 1, pp. 173–175, 2009.
- [7] S. L. Ruggiero, T. B. Dodson, and J. Fantasia, "American association of oral and maxillofacial surgeons position paper on medication-related osteonecrosis of the jaw—2014 update," *Journal of Oral and Maxillofacial Surgery*, vol. 72, no. 10, pp. 1938–1956, 2014.
- [8] D. Rosella, P. Papi, R. Giardino, E. Cicalini, L. Piccoli, and G. Pompa, "Medication-related osteonecrosis of the jaw: Clinical and practical guidelines," *Journal of International Society of Preventive and Community Dentistry*, vol. 6, no. 2, pp. 97–104, 2016.
- [9] S. R. Nussbaum, J. Younger, C. J. Vandepol et al., "Single-dose intravenous therapy with pamidronate for the treatment of hypercalcemia of malignancy: Comparison of 30-, 60-, and 90-mg dosages," *American Journal of Medicine*, vol. 95, no. 3, pp. 297–304, 1993.
- [10] J. R. Berenson, B. E. Hillner, R. A. Kyle et al., "American society of clinical oncology clinical practice guidelines: the role of bisphosphonates in multiple myeloma," *Journal of Clinical Oncology*, vol. 20, no. 17, pp. 3719–3736, 2002.
- [11] G. Campisi, S. Fedele, V. Fusco, G. Pizzo, O. Di Fede, and A. Bedogni, "Epidemiology, clinical manifestations, risk reduction and treatment strategies of jaw osteonecrosis in cancer patients exposed to antiresorptive agents," *Future Oncology*, vol. 10, no. 2, pp. 257–275, 2014.
- [12] A. Khan, A. Morrison, S. Ruggiero et al., "Diagnosis and management of osteonecrosis of the jaw: a systematic review and international consensus," *Journal of Bone and Mineral Research*, vol. 30, no. 1, pp. 3–23, 2015.
- [13] K. Vahtsevanos, A. Kyrgidis, E. Verrou et al., "Longitudinal cohort study of risk factors in cancer patients of bisphosphonate-related osteonecrosis of the jaw," *Journal of Clinical Oncology*, vol. 27, no. 32, pp. 5356–5362, 2009.
- [14] F. Saad, J. E. Brown, C. Van Poznak et al., "Incidence, risk factors, and outcomes of osteonecrosis of the jaw: integrated analysis from three blinded active-controlled phase III trials in cancer patients with bone metastases," *Annals of Oncology*, vol. 23, no. 5, pp. 1341–1347, 2012.
- [15] M. J. Heufelder, J. Hendricks, T. Remmerbach, B. Frerich, A. Hemprich, and F. Wilde, "Principles of oral surgery for prevention of bisphosphonate-related osteonecrosis of the jaw," *Oral Surgery, Oral Medicine, Oral Pathology, Oral Radiology, and Endodontology*, vol. 117, no. 6, pp. e429–e435, 2014.
- [16] J. B. B. Weber, R. S. Camilotti, and M. E. Ponte, "Efficacy of laser therapy in the management of bisphosphonate-related osteonecrosis of the jaw (BRONJ): a systematic review," *Lasers in Medical Science*, vol. 31, no. 6, pp. 1261–1272, 2016.
- [17] C. Pautke, F. Bauer, S. Otto et al., "Fluorescence-guided bone resection in bisphosphonate-related osteonecrosis of the jaws: First clinical results of a prospective pilot study," *Journal of Oral and Maxillofacial Surgery*, vol. 69, no. 1, pp. 84–91, 2011.
- [18] L. Montebugnoli, L. Felicetti, D. B. Gissi, A. Pizzigallo, G. A. Pelliccioni, and C. Marchetti, "Biphosphonate-associated osteonecrosis can be controlled by nonsurgical management," *Oral Surgery, Oral Medicine, Oral Pathology, Oral Radiology, and Endodontology*, vol. 104, no. 4, pp. 473–477, 2007.
- [19] T. van den Wyngaert, T. Claeys, M. T. Huizing, J. B. Vermorken, and E. Fossion, "Initial experience with conservative treatment in cancer patients with osteonecrosis of the jaw (ONJ) and predictors of outcome," *Annals of Oncology*, vol. 20, no. 2, pp. 331–336, 2009.
- [20] C. Klingelhöffer, F. Zeman, J. Meier, T. E. Reichert, and T. Ettl, "Evaluation of surgical outcome and influencing risk factors in patients with medication-related osteonecrosis of the jaws," *Journal of Cranio-Maxillo-Facial Surgery*, vol. 44, no. 10, pp. 1694–1699, 2016.
- [21] B. Atalay, S. Yalcin, Y. Emes et al., "Bisphosphonate-related osteonecrosis: Laser-assisted surgical treatment or conventional surgery?" *Lasers in Medical Science*, vol. 26, no. 6, pp. 815–823, 2011.
- [22] S. Otto, C. Schreyer, S. Hafner et al., "Bisphosphonate-related osteonecrosis of the jaws - Characteristics, risk factors, clinical features, localization and impact on oncological treatment," *Journal of Cranio-Maxillo-Facial Surgery*, vol. 40, no. 4, pp. 303–309, 2012.
- [23] P. J. Voss, J. Joshi Oshero, A. Kovalova-Müller et al., "Surgical treatment of bisphosphonate-associated osteonecrosis of the jaw: Technical report and follow up of 21 patients," *Journal of Cranio-Maxillo-Facial Surgery*, vol. 40, no. 8, pp. 719–725, 2012.
- [24] R. E. Marx, Y. Sawatari, M. Fortin, and V. Broumand, "Bisphosphonate-induced exposed bone (osteonecrosis/osteopetrosis) of the jaws: Risk factors, recognition, prevention, and treatment," *Journal of Oral and Maxillofacial Surgery*, vol. 63, no. 11, pp. 1567–1575, 2005.
- [25] H. Vercruyse, T. D. Backer, and M. Y. Mommaerts, "Outcomes of osseous free flap reconstruction in stage III bisphosphonate-related osteonecrosis of the jaw: Systematic review and a new case series," *Journal of Cranio-Maxillo-Facial Surgery*, vol. 42, no. 5, pp. 377–386, 2014.
- [26] T. Neto, R. Horta, R. Balhau et al., "Resection and microvascular reconstruction of bisphosphonate-related osteonecrosis of the jaw: The role of microvascular reconstruction," *Head & Neck*, vol. 38, no. 8, pp. 1278–1285, 2016.
- [27] R. Sacco, G. Sacco, A. Acocella, S. Sale, N. Sacco, and E. Baldoni, "A systematic review of microsurgical reconstruction of the jaws using vascularized fibula flap technique in patients with bisphosphonate-related osteonecrosis," *Journal of Applied Oral Science*, vol. 19, no. 4, pp. 293–300, 2011.
- [28] S. L. Engroff and D. Coletti, "Bisphosphonate related osteonecrosis of the palate: report of a case managed with free tissue transfer," *Oral Surgery, Oral Medicine, Oral Pathology, Oral Radiology, and Endodontology*, vol. 105, no. 5, pp. 580–582, 2008.
- [29] S. Ferrari, B. Bianchi, A. Savi et al., "Fibula Free Flap With Endosseous Implants for Reconstructing a Resected Mandible

- in Bisphosphonate Osteonecrosis," *Journal of Oral and Maxillofacial Surgery*, vol. 66, no. 5, pp. 999–1003, 2008.
- [30] T. Mücke, S. Haarmann, K.-D. Wolff, and F. Hölzle, "Bisphosphonate related osteonecrosis of the jaws treated by surgical resection and immediate osseous microvascular reconstruction," *Journal of Cranio-Maxillo-Facial Surgery*, vol. 37, no. 5, pp. 291–297, 2009.
- [31] P. F. Nocini, G. Saia, G. Bettini et al., "Vascularized fibula flap reconstruction of the mandible in bisphosphonate-related osteonecrosis," *European Journal of Surgical Oncology*, vol. 35, no. 4, pp. 373–379, 2009.
- [32] R. Seth, N. D. Futran, D. S. Alam, and P. D. Knott, "Outcomes of vascularized bone graft reconstruction of the mandible in bisphosphonate-related osteonecrosis of the jaws," *The Laryngoscope*, vol. 120, no. 11, pp. 2165–2171, 2010.
- [33] A. Bedogni, G. Saia, G. Bettini et al., "Long-term outcomes of surgical resection of the jaws in cancer patients with bisphosphonate-related osteonecrosis," *Oral Oncology*, vol. 47, no. 5, pp. 420–424, 2011.
- [34] C. Pautke, S. Otto, S. Reu et al., "Bisphosphonate related osteonecrosis of the jaw - Manifestation in a microvascular iliac bone flap," *Oral Oncology*, vol. 47, no. 5, pp. 425–429, 2011.
- [35] T. Bittner, N. Lorbeer, T. Reuther, H. Böhm, A. C. Kübler, and U. D. A. Müller-Richter, "Hemimandibulectomy after bisphosphonate treatment for complex regional pain syndrome: A case report and review on the prevention and treatment of bisphosphonate-related osteonecrosis of the jaw," *Oral Surgery, Oral Medicine, Oral Pathology, Oral Radiology, and Endodontology*, vol. 113, no. 1, pp. 41–47, 2012.
- [36] N. Ghazali, J. C. Collyer, and J. V. Tighe, "Hemimandibulectomy and vascularized fibula flap in bisphosphonate-induced mandibular osteonecrosis with polycythaemia rubra vera," *International Journal of Oral and Maxillofacial Surgery*, vol. 42, no. 1, pp. 120–123, 2013.
- [37] M. M. Hanasono, O. N. Militsakh, J. D. Richmon, E. L. Rosenthal, and M. K. Wax, "Mandibulectomy and free flap reconstruction for bisphosphonate-related osteonecrosis of the jaws," *JAMA Otolaryngology - Head and Neck Surgery*, vol. 139, no. 11, pp. 1135–1142, 2013.
- [38] R. Horta, D. Monteiro, T. Neto et al., "Microsurgical reconstruction for radiation- and bisphosphonate-induced mandible osteonecrosis based on patient-specific physiopathologic mechanisms," *The Journal of Craniofacial Surgery*, vol. 25, no. 5, pp. 1793–1796, 2014.
- [39] G. Spinelli, M. Torresetti, D. Lazzeri et al., "Microsurgical reconstruction after bisphosphonate-related osteonecrosis of the jaw: Our experience with fibula free flap," *The Journal of Craniofacial Surgery*, vol. 25, no. 3, pp. 788–792, 2014.
- [40] H. Kim, J. Hwang, and K. Ahn, "Fibula Free Flap for Mandibular Reconstruction using Simulation Surgery in Bisphosphonate related Osteonecrosis of the Jaw," *Journal of International Society for Simulation Surgery*, vol. 2, no. 1, pp. 1–6, 2015.
- [41] T. Mücke, M. Jung, S. Koerdt, D. A. Mitchell, D. Loeffelbein, and M. R. Kesting, "Free flap reconstruction for patients with bisphosphonate related osteonecrosis of the jaws after mandibulectomy," *Journal of Cranio-Maxillo-Facial Surgery*, vol. 44, no. 2, pp. 142–147, 2016.
- [42] Y. Sotsuka, T. Fujiwara, K. Kawai, S. Nishimoto, and M. Kakibuchi, "Bilateral Maxillary Reconstruction Using Fibular Flap in Bisphosphonate-related Osteonecrosis," *Plastic and Reconstructive Surgery - Global Open*, vol. 4, no. 9, p. e1045, 2016.
- [43] S. Caldrony, N. Ghazali, D. Dyalram, and J. E. Lubek, "Surgical resection and vascularized bone reconstruction in advanced stage medication-related osteonecrosis of the jaw," *International Journal of Oral and Maxillofacial Surgery*, vol. 46, no. 7, pp. 871–876, 2017.
- [44] A. Liberati, D. G. Altman, J. Tetzlaff et al., "The PRISMA statement for reporting systematic reviews and meta-analyses of studies that evaluate healthcare interventions: explanation and elaboration," *British Medical Journal*, vol. 339, Article ID b2700, 2009.
- [45] D. H. Henry, L. Costa, F. Goldwasser et al., "Randomized, double-blind study of denosumab versus zoledronic acid in the treatment of bone metastases in patients with advanced cancer (excluding breast and prostate cancer) or multiple myeloma," *Journal of Clinical Oncology*, vol. 29, no. 9, pp. 1125–1132, 2011.
- [46] P. P. L. Fung, G. Bedogni, A. Bedogni et al., "Time to onset of bisphosphonate-related osteonecrosis of the jaws: a multicentre retrospective cohort study," *Oral Diseases*, vol. 23, no. 4, pp. 477–483, 2017.
- [47] S. L. Ruggiero, T. B. Dodson, L. A. Assael, R. Landesberg, R. E. Marx, and B. Mehrotra, "American association of oral and maxillofacial surgeons position paper on bisphosphonate-related osteonecrosis of the jaws," *Journal of Oral and Maxillofacial Surgery*, vol. 67, no. 5, supplement 1, pp. 2–12, 2009.
- [48] S. Kühl, C. Walter, S. Acham, R. Pfeffer, and J. T. Lambrecht, "Bisphosphonate-related osteonecrosis of the jaws—a review," *Oral Oncology*, vol. 48, no. 10, pp. 938–947, 2012.
- [49] I. C. Benlidayi and R. Guzel, "Oral bisphosphonate related osteonecrosis of the jaw: a challenging adverse effect," *ISRN Rheumatology*, vol. 2013, Article ID 215034, 6 pages, 2013.
- [50] P. Stockmann, E. Vairaktaris, F. Wehrhan et al., "Osteotomy and primary wound closure in bisphosphonate-associated osteonecrosis of the jaw: A prospective clinical study with 12 months follow-up," *Supportive Care in Cancer*, vol. 18, no. 4, pp. 449–460, 2010.
- [51] S. L. Ruggiero, "Emerging Concepts in the Management and Treatment of Osteonecrosis of the Jaw," *Oral and Maxillofacial Surgery Clinics of North America*, vol. 25, no. 1, pp. 11–20, 2013.
- [52] Z. Jabbour, M. El-Hakim, P. Mesbah-Ardakani, J. E. Henderson, and R. Albuquerque Jr., "The outcomes of conservative and surgical treatment of stage 2 bisphosphonate-related osteonecrosis of the jaws: A case series," *International Journal of Oral and Maxillofacial Surgery*, vol. 41, no. 11, pp. 1404–1409, 2012.



**Hindawi**

Submit your manuscripts at  
[www.hindawi.com](http://www.hindawi.com)

