

SUPPLEMENTAL MATERIAL

A new multi-system disorder caused by the G6s mutation F376V

Heike Biebermann ^{1,§}, Gunnar Kleinau ^{1,2,§}, Dirk Schnabel ^{3,4,§}, Detlef Bockenhauer ⁵, Louise C. Wilson ⁶, Ian Tully ⁷, Sarah Kiff ⁸, Patrick Scheerer ², Monica Reyes ⁹, Sarah Paisdzior ¹, John W. Gregory ¹⁰, Jeremy Allgrove ⁸, Heiko Krude ¹, Michael Mannstadt ⁹, Thomas J. Gardella ⁹, Mehul Dattani ^{8,11,#}, Harald Jüppner ^{9,#}, Annette Grüters ^{3,9,10,#,*}

§ first authors contributed equally to this work

last authors contributed equally to this work

* corresponding author

¹⁻⁴ Charité – Universitätsmedizin Berlin, corporate member of Freie Universität Berlin, Humboldt-Universität zu Berlin, Germany;

¹ Institute of Experimental Pediatric Endocrinology, Augustenburger Platz 1, 13353 Berlin, Germany;

² Institut für Medizinische Physik und Biophysik, Group Protein X-ray Crystallography and Signal Transduction; 10117 Berlin, Germany;

³ Department for Pediatric Endocrinology and Diabetology; 13353 Berlin, Germany;

⁴ Center for Chronically Sick Children, 13353 Berlin, Germany;

⁵ Department of Nephrology, Great Ormond Street Hospital for Children, NW3 2PF London, UK;

⁶ Department of Clinical Genetics, Great Ormond Street Hospital for Children, WC1N 3JH London, UK;

⁷ Department of Clinical Genetics, University Hospital of Wales, CF14 4XW Cardiff, UK;

⁸ Department of Pediatric Endocrinology, Great Ormond Street Hospital for Children, WC1N 3JH London, UK;

⁹ Endocrine Unit Massachusetts General Hospital and Harvard Medical School, 02114 Boston, Ma, USA;

¹⁰ Division of Population Medicine, School of Medicine, CF14 4XN Cardiff University, UK;

¹¹ Section of Genetics and Epigenetics in Health and Disease, Genetics and Genomic Medicine Programme, UCL GOS Institute of Child Health, WC1N 1EH London, UK;

¹² University Hospital Heidelberg, 69120 Heidelberg, Germany

DETAILED PATIENTS INFORMATION

Patient 1 is a now a 7.5 year old male and single child of non-consanguineous German parents. There is no family history regarding skeletal dysplasia, hyponatremia or precocious puberty. Oligohydramnios and short limbs (arms and legs) were noted on prenatal ultrasound, and he was diagnosed with unexplained hyponatremia, without hyperkalemia, after birth with lowest sodium concentrations of 117 mmol/l. He received oral sodium supplements and concentrations fluctuated throughout the first three years and then normalized. Blood pressure was normal. Because serum sodium concentrations had normalized, oral sodium was stopped at the age of three years. After birth, large fontanelles were recorded. Bone deformities became apparent at 6 months of life and at the age of 1.5 years of life, spontaneous fractures of the left tibia occurred. These bone changes were first interpreted as metaphyseal dysplasia (*Weismann-Netter-Syndrome*). Serum PTH was measured for the first time at the age of 12 months and was found to be elevated with blood Ca^{2+} concentrations in the upper normal range. At the age of 4 years, 1-alpha calcidol (0.05 $\mu\text{g}/\text{day}$) was commenced because of increasing PTH concentrations (max. 454 pg/ml). Since then serum PTH and alkaline phosphatase concentrations remained

mostly elevated and skeletal changes were still present. Hypothyroidism was suspected because of a single low fT4 (0.75 ng/ml, normal range: 0.89 – 2.22) with a serum TSH serum concentration in the upper normal range (4.08 mU/l, normal: 0.4 -5.97) and thyroid hormone replacement (25 µg/day) was started at the age of 1 year. Thyroid ultrasound was normal with a volume of 0.7 ml. At 2 years of life enlargement of both testes was noted (6 ml) with a massive bilateral hydrocele. At 3 years of age, his testes had enlarged to 12 ml and precocious puberty was diagnosed with growth acceleration, advancement in bone age (6 years) and high serum testosterone concentrations (7.3 ng/ml, reference range 0.03-0.32). However, serum LH and FSH concentrations at baseline and after GnRH stimulation were suppressed and gonadotropin-independent precocious puberty was therefore diagnosed. Therapy with an aromatase inhibitor (Anastrozole (Arimidex), 1 mg od) and cyproterone acetate (anti-androgen, 10 mg) was instituted at 3.5 years. At the age of 5 years, cyproterone acetate was changed to Bicalutamide (50 mg od). At 6.5 years, his bone age was 13 years despite treatment. He presented with delayed motor development, which may have been confounded by immobilization because of surgical interventions for fractures and deformities. This might have also contributed to an increased BMI (23.4 kg/m², 3.2 SDS), which was present in the first four years of life, but has now normalized (age 7 years, 19.4 kg/m², 1.6 SDS). His cognitive development is slightly delayed and behavioral issues are most likely due to his early pubertal development. He is now in first grade in a normal public school.

Patient 2 is a now 3.5 year old male (weight + 3.89 SDS, height 2.82 SDS), the third child born at 39 weeks gestation to non-consanguineous Caucasian parents. He presented on day 3 of life with weight loss and hyponatremia. Serum sodium reached its lowest concentration on day 7 of life at 122 mmol/l. Plasma renin and aldosterone were within the normal neonatal reference range. Sodium supplementation (8 mmol/kg/d) and mineralocorticoid (fludrocortisone started at 25 µg daily and increased progressively to 20 µg/kg/d) were commenced, and were sufficient

to maintain the serum sodium concentration in the low-normal range.

At 2 years of age, he presented with testicular enlargement (15 ml bilaterally) and Tanner stage 3-4 pubertal development. Gonadotrophin-independent precocious puberty was diagnosed on GnRH test [peak LH 0.8 IU/l and FSH 1.2 IU/l, testosterone 3.2 ng/ml (11.1 nmol/l)]. Treatment with cyproterone (25 mg BID) was commenced, but was insufficient to slow his growth rate and bone age advancement (bone age 10.9 years at a chronological age of 3.2 years). Additionally, he developed hypocortisolemia and needed glucocorticoid replacement. Cyproterone was stopped and anastrozole (1mg OD) and spironolactone (50 mg BID) were added with improvement in behavior. However, spironolactone treatment resulted in recurrence of hyponatremia. Therefore, at the age of 3.2 years, spironolactone was stopped and Bicalutamide (25 mg OD increasing to 50 mg OD in light of recurrent concerns about behaviour) was commenced in view of its anti-androgenic effect. Repeat GnRH stimulation testing at 3.2. years suggested first the development of gonadotrophin-dependent precocious puberty (peak LH 4.2 IU/L, FSH 0.6 IU/L) and therefore a GnRH analogue was commenced. Reassessment of the hyponatremia was performed at the age of 3.2 years. Serum sodium concentrations remained normal on discontinuation of sodium chloride, fludrocortisone and spironolactone and blood pressure normalized with no further need for antihypertensive treatment. Yet urine osmolality remained high (685-1006 mOsm/kg) on multiple testing over a two week period. Plasma osmolality was in the normal range, but unrestricted oral fluid intake was low (<50 ml/kg/day). Copeptin measured on four occasions associated with normal or low serum sodium concentrations remained <3.6 pmol/l. A formal water challenge has not been performed, but an apparent spontaneous water intake had occurred, when he presented with hyponatremia (130 mmol/l) and hypo-osmolality (275 mosm/kg). This was associated with increased weight (+500 g) and increased blood pressure (112 mmHg systolic) suggesting water overload. Vasopressin, as assessed by a plasma copeptin concentration was appropriately suppressed at 3.1 pmol/l, indicating intact regulatory control of vasopressin secretion. Yet, urine

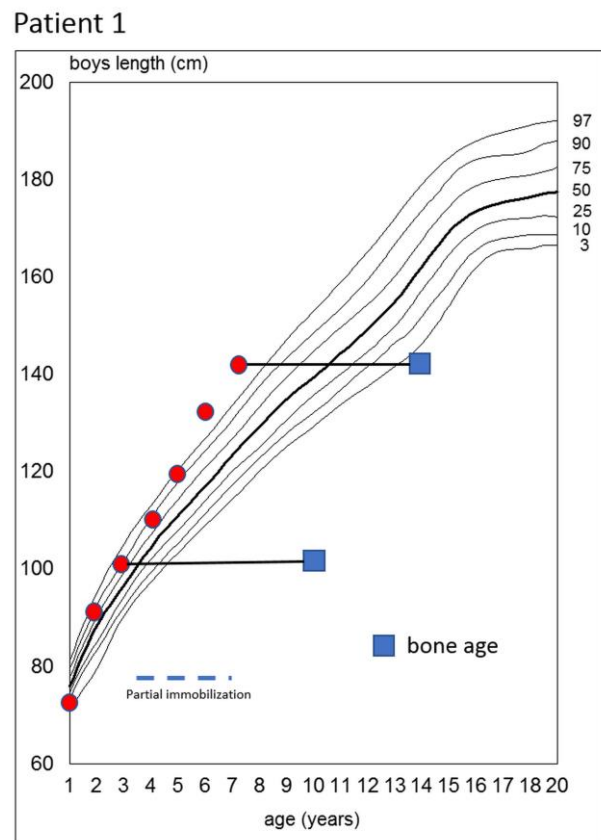
was inappropriately concentrated at 1038 mosm/kg, consistent with NSIAD. To better assess urinary dilution capacity, a tolvaptan (V2R antagonist) challenge was given. There was no response in urine output, plasma osmolality or urine osmolality, consistent with vasopressin independent urine concentration.

The patient also had persistently elevated parathyroid hormone (PTH) concentrations with low normal serum calcium concentration, mildly elevated phosphate concentrations, a low urine calcium:creatinine ratio and no evidence of nephrocalcinosis on renal ultrasound. Skeletal survey, showed no radiological features of Albright's Hereditary Osteodystrophy. Images were instead in keeping with hyperparathyroidism, with multiple sites of subperiosteal resorption, including the proximal radius, short tubular bones (particularly metacarpals and middle phalanges) and early but definite acro-osteolysis in hands and feet. Alfacalcidol (700 ng= 30 ng/kg daily) was commenced to reduce PTH concentration and prevent further effects on bone. Clinical examination revealed a persisting anterior fontanelle (which was large at birth), unusual frontal hair whorl, full eyebrows and mild synophrys, broad nasal base and tip, full lips, spaced teeth, mild micrognathia, short distal phalanges of hands and feet, muscular build but with normal fat distribution, two small café-au-lait patches and no cutaneous ossifications. No features of Albright's Hereditary Osteodystrophy (AHO) or cutaneous or skeletal features of McCune-Albright were demonstrated. The patient experienced neurocognitive, speech and motor developmental delay with normal hearing and vision. Nocturnal CPAP was required from 6 weeks to 1 year of age due to obstructive sleep apnoea. Echocardiography showed a structurally normal heart, with a transient small pericardial effusion in the neonatal period, thought to be secondary to electrolyte disturbance.

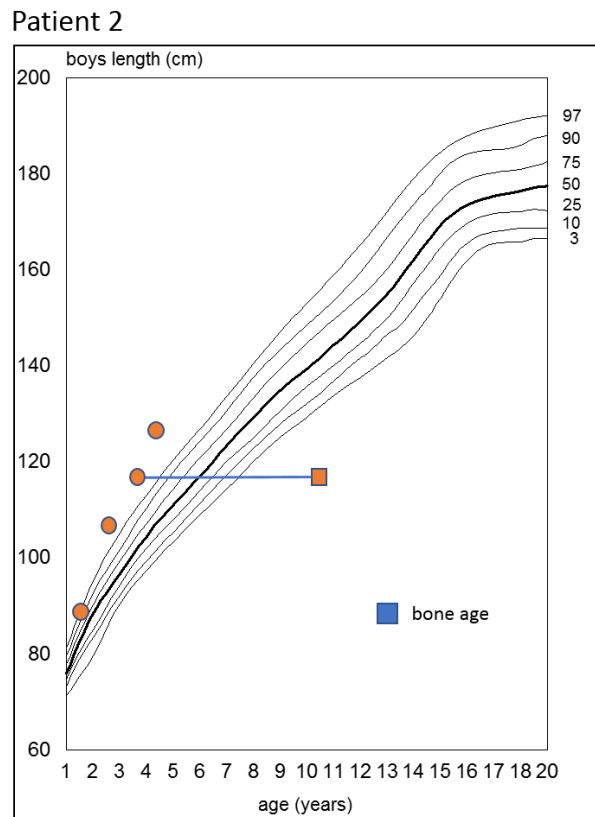
SUPPLEMENTAL FIGURES

Supplemental Figure 1

A)



B)



Supplemental figure 1: Growth charts of patient 1 (A) and patient 2 (B).

17 **Supplemental Figure 2**

18

19

20

21

22

23

24

25

26

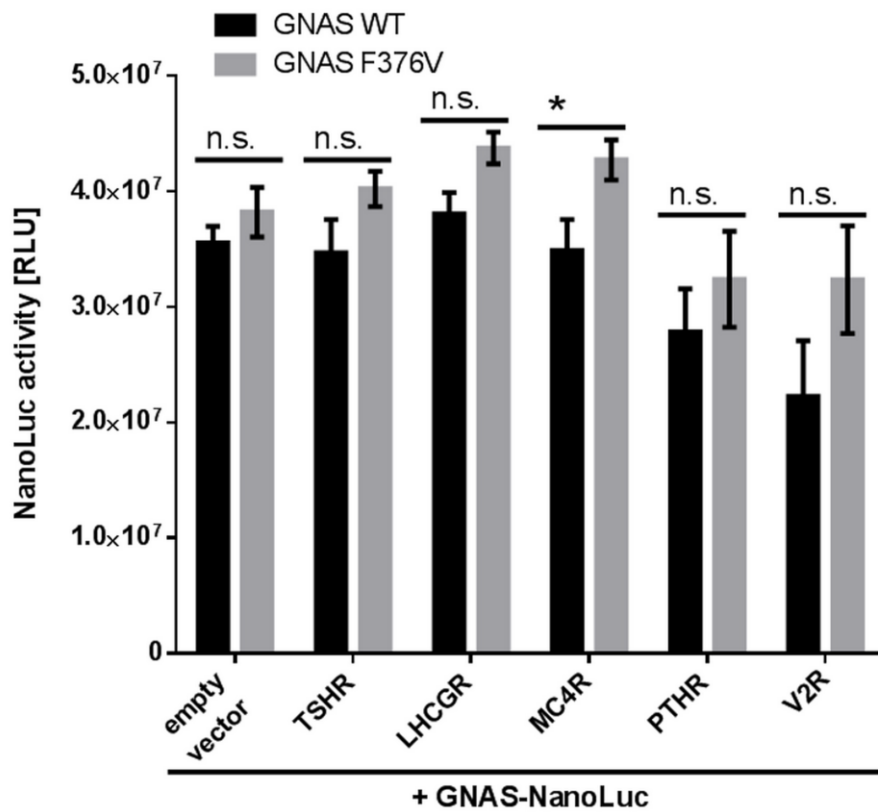
27

28

29

30

31



32 **Supplemental figure 2: Influence of receptors co-expressed with G proteins.** Co-expression

33 of all tested receptors together with wt-Gas and Gas-F376 mutant tagged with NanoLuc. To

34 ensure unimpaired coupling of the tagged G α s, the luciferase was added in between amino acids

35 324 and 325. 24 h post transfection, luciferase was measured by adding the NanoLuc substrate

36 to living cells. Data represent a minimum of three independent experiments, each performed in

37 triplicates. Value represent mean \pm SEM. Statistical analysis was performed with an unpaired

38 two-tailed T-test, comparing Gas-WT with Gas-F376 mutant; * $p \leq 0.05$

39

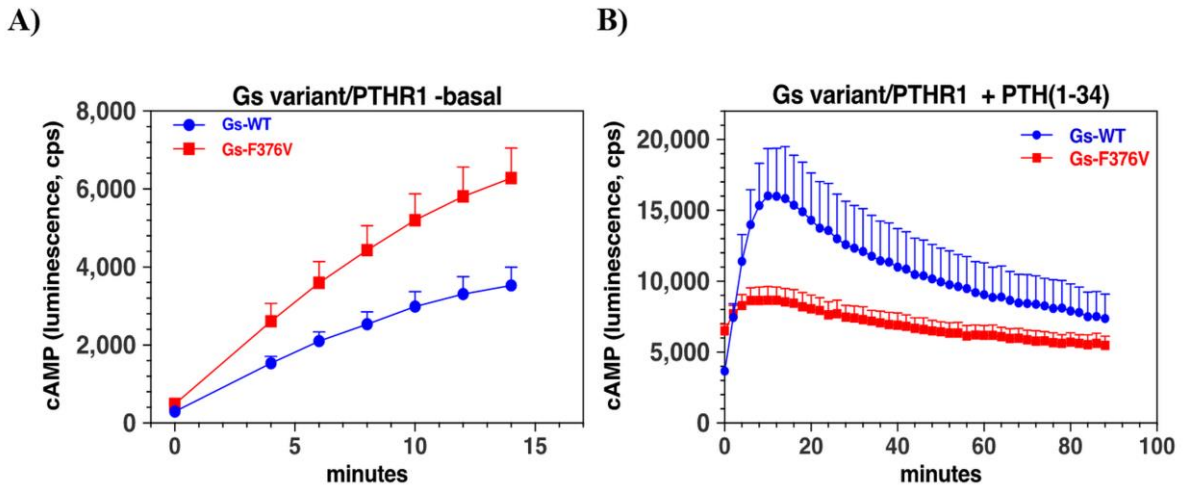
40

41

42

43 **Supplemental Figure 3**

44



45

46 **Supplemental figure 3: cAMP signaling in HEK293-Gas-KO/glosensor cells (GSG-5 cells).**

47 HEK293-derived cells engineered via CRISPR Cas9 to lack endogenous Gas and stably
48 transfected to express the Glosensor, a cAMP-dependent luciferase derivative, were transiently
49 transfected to express the hPTH1R and either wild-type Gas or the Gas-F376V mutant and then
50 basal and PTH(1-34)-induced cAMP accumulation was measured as luminescence. Basal
51 intracellular cAMP levels were measured for 14 minutes after initial addition of luciferin (**A**),
52 after which the cells were treated with PTH(1-34) (100 nM) and luminescence measured for an
53 additional 88 minutes (**B**). Data are means \pm SEM of 6 independent assays; for each assay, data
54 from replicate wells (twelf for basal and two for PTH-treated) were averaged before combining
55 the data to obtain the mean values for the six independent experiments.

56

57

58

59

60

61

62 **Supplemental Figure 4**

63

G-protein subtype		$\alpha 5$ helix sequence	
Gs alpha	369	TENIRRV <u>F</u> NDCRDIIQRMHLRQYELL	394
Gi alpha	329	TKNVQFV <u>F</u> DAVTDV I I KNNLKDCGLF	354
Gq alpha	334	TENIRFV <u>F</u> AAVKDTILQLNLKEYNLV	359
G11 alpha	334	TENIRFV <u>F</u> AAVKDTILQLNLKEYNLV	359
Transducin	329	TQNVKFV <u>F</u> DAVTD I I I KENLKDCGLF	354

64

65 **Supplemental figure 4: Sequence alignment of amino acids in the C-terminus of the α -5 helix**
66 **of different G-protein alpha-subunits.** A phenylalanine at position 376 in G α s is highly
67 conserved at the corresponding structural position among different G-protein subtypes (red,
68 underlined).

69

70

71

72

73

74

75

76