

# Accepted Manuscript

Microperimetry and swept-source optical coherence tomography in the assessment of the preferred retinal locus in a child with macular retinoblastoma in the remaining eye

Kenneth P. Johnson, MD, Aisha McLean, Bsc (Hons), Gary S. Rubin, PhD, Vasilios P. Papastefanou, PhD, MRCOphth, Aadil Hussain, MD, Yijun Cai, MD, Mandeep S. Sagoo, PhD, FRCS (Ed), M. Ashwin Reddy, MD, FRCOph

PII: S1091-8531(18)30598-6

DOI: <https://doi.org/10.1016/j.jaapos.2018.11.003>

Reference: YMPA 2949

To appear in: *Journal of AAPOS*

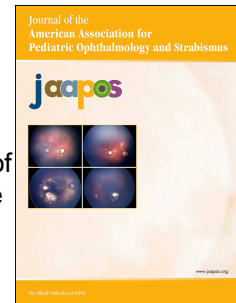
Received Date: 22 July 2018

Revised Date: 31 October 2018

Accepted Date: 1 November 2018

Please cite this article as: Johnson KP, McLean A, Rubin GS, Papastefanou VP, Hussain A, Cai Y, Sagoo MS, Reddy MA, Microperimetry and swept-source optical coherence tomography in the assessment of the preferred retinal locus in a child with macular retinoblastoma in the remaining eye, *Journal of AAPOS* (2018), doi: <https://doi.org/10.1016/j.jaapos.2018.11.003>.

This is a PDF file of an unedited manuscript that has been accepted for publication. As a service to our customers we are providing this early version of the manuscript. The manuscript will undergo copyediting, typesetting, and review of the resulting proof before it is published in its final form. Please note that during the production process errors may be discovered which could affect the content, and all legal disclaimers that apply to the journal pertain.



**Microperimetry and swept-source optical coherence tomography in the assessment of the preferred retinal locus in a child with macular retinoblastoma in the remaining eye**

Kenneth P. Johnson, MD,<sup>a</sup> Aisha McLean, Bsc (Hons),<sup>b</sup> Gary S. Rubin, PhD,<sup>b,c</sup> Vasilios P. Papastefanou, PhD, MRCOphth,<sup>c,d</sup> Aadil Hussain, MD,<sup>e</sup> Yijun Cai, MD,<sup>c</sup> Mandeep S. Sagoo, PhD, FRCS (Ed),<sup>b,c,d,f</sup> and M. Ashwin Reddy, MD, FRCOph<sup>c,d,f</sup>

*Author affiliations: <sup>a</sup>Clínica Oftalmológica Pasteur, Santiago, Chile; <sup>b</sup>Institute of Ophthalmology, University College of London, London, United Kingdom; <sup>c</sup>Moorfields Eye Hospital, Moorfields NHS Trust, London, United Kingdom; <sup>d</sup>Retinoblastoma Unit, Royal London Hospital, Barts Health NHS Trust, London, United Kingdom; <sup>e</sup>Mid Essex NHS Trust, United Kingdom; <sup>f</sup>National Institute for Health Research, Biomedical Research Centre at Moorfields Eye Hospital, NHS Foundation Trust and UCL Institute of Ophthalmology, London, United Kingdom*

*Submitted July 22, 2018.*

*Revision accepted November 1, 2018.*

*Presented as poster 44th Annual Meeting of the American Association for Pediatric Ophthalmology and Strabismus, Washington, DC, March 18-22, 2018.*

*Correspondence: Kenneth P. Johnson. Clínica Oftalmológica Pasteur. Avda Luis Pasteur 5917 Vitacura, Santiago, Chile (email: kjohnson@pasteur.cl).*

**Word count: 1,103**

**Assessing the visual capabilities that remain to children affected with bilateral retinoblastoma has relied on psychophysical tests based on recognition visual acuity. We report a case in which fundus-driven perimetry and swept-source optical coherence tomography was performed in a patient with a macular tumor in the remaining eye as a novel way of further assessing fixation after oncological disease and treatment.**

Retinoblastoma is the most common intraocular malignancy in infancy.<sup>1</sup> Clinically it can present with bilateral tumors and multiple foci. Advances in the management of children with bilateral disease have led to improved rates of survival and globe preservation. Nevertheless, 38% of children with bilateral involvement have some form of visual impairment.<sup>2</sup>

Microperimeters have emerged as a valuable resource for quantitative measure of visual field sensitivity while having a live view of the fundus,<sup>3</sup> allowing a better understanding of fixation patterns in several pediatric conditions with macular involvement,<sup>4</sup> but it has not been previously described in retinoblastoma patients. The diagnostic abilities of microperimeters broaden our understanding of the residual visual function in those patients with poor fixation stability or extrafoveal fixation patterns, particularly in those affected by macular tumors. Once an eccentric preferred retinal locus (PRL) has been identified, rehabilitation strategies, such as biofeedback training can then be considered to enhance quality of life.<sup>5</sup> Children affected with macular retinoblastoma can show unexpectedly good visual behavior, given the extent of retinal damage from the disease itself or administered treatments.<sup>6</sup> This depends on the nature of the adaptations made by the child's visual system to use a parafoveal location as a PRL. We report the use of microperimetry in locating the new fixation area of a child affected with a macular tumor in her remaining eye and the use swept-source optical coherence tomography (SS-OCT) to study the structure of the retina in the identified area.

## Case Report

This study project was approved by the Royal London Hospital Institutional Review Board. Our purpose was to assess children with one remaining eye and to confirm that the PRL was used for day-to-day activities and not suppressed when the other eye was used. We did not enroll for perimetry children with high-amplitude nystagmus, because the determination of the PRL would have been difficult.

Of 5 patients affected with bilateral retinoblastoma enrolled and consented, only 1 could complete the extensive clinical examination, microperimetry testing, and swept-source optical coherence tomography (SS-OCT) with reliable results at 9 years of age. This patient had presented to the Retinoblastoma Unit for treatment of bilateral retinoblastoma with macular involvement. Treatment with systemic chemotherapy, focal laser and cryotherapy was administered prior to enucleation of her left eye for reactivated retinoblastoma at 8 years of age. Nine months after enucleation, her best-corrected visual acuity in the right eye was recorded as 1.3 logMAR (20/400 Snellen equivalent) with Sloan optotypes. Further assessment with MP-1 microperimeter (NIDEK Technologies, Padua, Italy) was able to identify an area of fixation in which the center of the bivariate contour ellipse area corresponded to a region on the superior border of the treated macular tumor (Figure 1). The microperimetry study was completed with good cooperation using a single cross Goldmann III stimulus as a fixation target and was well tolerated by the patient after instillation of cyclopentolate 1% and phenylephrine 2.5% drops approximately 40 minutes before examination.

Subsequently SS-OCT (Triton SS-OCT, Topcon Corporation, Japan) was performed and qualitative analysis was carried out by one of the authors (VP). Quantitative study of the identified PRL involved examination of thickness maps of the neurosensory retina and choroid.

Manual corrective segmentation was used in areas where the borders were not clearly defined by automated segmentation. SS-OCT of this region showed well-defined layers of neurosensory retina superiorly to the area of atrophy, including unaffected retinal pigment epithelium photoreceptor layers (Figure 2). Choroidal thickness increased back to nearly regular levels at the point of fixation, whereas thinning was identified in the central macular scar.

Of the remaining 4 patients who were initially thought suitable for the study, 3 were not included because of low cooperation on clinical awake examination; the other patient, aged 6 years, did not produce reliable results on the microperimetry test and hence was not further studied with SS-OCT.

## **Discussion**

To our knowledge, this is the first report of microperimetry used in a child with macular retinoblastoma and a PRL identified for fixation; we have found no previous reports addressing the findings of this study in retinoblastoma patients.

Although macular tumors have been associated with poor visual outcomes in retinoblastoma,<sup>7</sup> it is difficult to predict visual behavior accurately. Microperimetry can be used as an additional investigation for the functional assessment of cooperative children with loss of central vision and unsteady or extrafoveal fixation. Our patient was found to have developed a PRL superiorly to the affected macula. Other reports studying PRL have shown that patients can have various locations for their PRL, depending on the macular disease. The superior location seen in our patient has also been found to be used in other conditions with macular involvement, such as pattern disease, Best dystrophy, and Stargardt disease.<sup>8</sup> Some reports in adults with age-related macular degeneration have found the PRL in other areas around the atrophic lesion,<sup>9</sup> but the superior location shared by our patient and others in these reports has been thought to be

useful for inferior field visual function activities such as literacy and feeding.

Tracking of the fundus also identified areas of retinal function amenable to structural study by OCT. In our patient the PRL presented with defined neurosensory retinal anatomy. It is also noteworthy that the PRL does not always develop on the border of the lesion in other diseases,<sup>8</sup> probably because of subclinical disease. In our patient, the retinal thickness per se might not have been the decisive factor for the definition of the PRL; rather, the presence of an anatomically healthy choroid and partial preservation of anatomic features of the retina may have been the critical factors. This has been previously described in children after intensive treatment of a macular tumor.<sup>10</sup>

The cooperation needed for the examination was essentially the ability to sit comfortably at the machine and to press the buzzer to indicate appearance of the stimuli. Our patient was 9 years of age, within the age range recommended for conventional perimetry in children without cognitive impairment.<sup>11</sup> Applied to children with only one remaining eye, microperimetry combined with SS-OCT testing offers clinicians a new approach in understanding the adaptive mechanisms after macular damage and may have a role in future visual rehabilitative treatments in older children with early loss of central vision by retinoblastoma.

## References

1. Kivelä T. The epidemiological challenge of the most frequent eye cancer: retinoblastoma, an issue of birth and death. *Br J Ophthalmol* 2009;93:1129-31.
2. Stacey AW, Clarke B, Moraitis C, et al. The incidence of binocular visual impairment and blindness in children with bilateral retinoblastoma. Epub ahead of print, June 19, 2018. *Ocul Oncol Pathol*.
3. Acton JH, Greenstein VC. Fundus-driven perimetry (microperimetry) compared to conventional static automated perimetry: similarities, differences, and clinical applications. *Can J Ophthalmol* 2013;48:358-63.
4. Reinhard J, Messias A, Dietz K, et al. Quantifying fixation in patients with Stargardt disease. *Vision Res* 2007;47:2076-85.
5. Vingolo EM, Salvatore S, Cavarretta S. Low-vision rehabilitation by means of MP-1 biofeedback examination in patients with different macular diseases: a pilot study. *Appl Psychophysiol Biofeedback* 2009;34:127-33.
6. Watts P, Westall C, Colpa L, et al. Visual results in children treated for macular retinoblastoma. *Eye (Lond)* 2002;16:75-80.
7. Narang S, Mashayekhi A, Rudich D, Shields CL. Predictors of long-term visual outcome after chemoreduction for management of intraocular retinoblastoma. *Clin Exp Ophthalmol* 2012;40:736-42.
8. Greenstein VC, Santos RA, Tsang SH, Smith RT, Barile GR, Seiple W. Preferred retinal locus in macular disease: characteristics and clinical implications. *Retina* 2008;28:1234-40.
9. Crossland MD, Culham LE, Kabanarou SA, Rubin GS. Preferred retinal locus

- development in patients with macular disease. *Ophthalmology* 2005;112:1579-85.
10. Samara WA, Pointdujour-Lim R, Say EA, Shields CL. Foveal microanatomy documented by SD-OCT following treatment of advanced retinoblastoma. *J AAPOS* 2015;19:368-72.
  11. Patel DE, Cumberland PM, Walters BC, Russell-Eggitt I, Rahi JS, group Os. Study of Optimal Perimetric Testing in Children (OPTIC): feasibility, reliability and repeatability of perimetry in children. *PLoS One* 2015;10:e0130895.

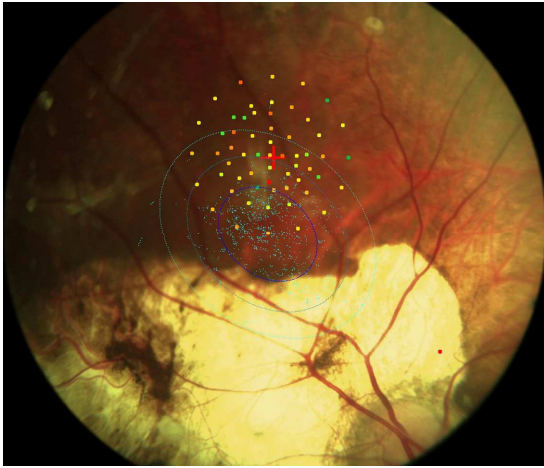


**Legends**

**FIG 1.** Identification of the preferred retinal locus (PRL) superior to macular tumor scar.

Goldmann III stimuli were projected for 200 ms in a 4-2 threshold strategy. The PRL is identified as the center of the fixation ellipse.

**FIG 2.** Swept-source optical coherence tomography showing anatomic preservation of retinal structure in the PRL, with preserved neurosensory retina (A-B) but severe disturbance of the architecture and loss of the retinal pigment epithelium–photoreceptors complex inferiorly into the macular scar (C-E).



ACCEPTED MANUSCRIPT

