



PRACTICE

CLINICAL UPDATES

Abdominal migraine

Heather Angus-Leppan *consultant neurologist*^{1 2 3}, Defne Saatci *paediatric trainee*⁴, Alastair Sutcliffe *professor of general paediatrics and honorary consultant paediatrician*⁴, Roberto J Guiloff *consultant neurologist and professor of neurology*^{5 6}

¹Clinical Neurosciences, Royal Free London NHS Foundation Trust, London NW3 2QG, UK; ²Institute of Neurology, University College London; ³Centre for Research in Primary and Community Care, University of Hertfordshire, Hatfield, UK; ⁴University College London and Great Ormond Street Institute of Child Health, University College London; ⁵Imperial College London; ⁶Faculty of Medicine, University of Chile, Santiago, Chile

What you need to know

- Abdominal migraine is episodic central abdominal pain occurring with other features of migraine and associated with other episodic syndromes (particularly cyclical vomiting and migraine limb pain)
- Abdominal migraine usually starts in childhood, though it may occur in adults, commonly with a family history of migraine
- The person is well between episodes with a normal physical examination and developmental milestones
- Abdominal migraine is a positive clinical diagnosis and requires no further investigation once "red flags" are excluded
- To manage abdominal migraine, provide an explanation of the diagnosis and discuss available acute and preventive treatments with the patient and family

Sources and selection criteria

We performed a Medline search and search of Cochrane Collaboration and Clinical Evidence databases, using the terms "abdominal migraine," "episodic (periodic) syndromes," "childhood migraine," "recurrent abdominal pain," "functional abdominal pain." We gathered evidence on the treatment of childhood migraine and childhood pain from the Cochrane Collaborations, particularly with regard to safety of acute treatment of migraine in children. Guidelines of the Rome Foundation, International Headache Society and North American Society for Pediatric Gastroenterology, Hepatology, and Nutrition informed discussion of definitions and management. These sources were supplemented by our personal archive of references, cited references from these, and discussions with other experts.

Abdominal migraine is an important, common, and under-recognised cause of recurrent abdominal pain in children. It may be associated with, or followed by, other forms of migraine, and it predicts adult migraine.¹⁻⁴ A positive diagnosis of abdominal migraine allows appropriate management and avoids unnecessary investigations and incorrect treatments.^{3,5} Although the evidence base is limited, acute and preventive treatments are available. This article highlights the diagnosis and management of abdominal migraine for non-specialists.

What is abdominal migraine?

Abdominal migraine is a functional disorder in the broad sense (a disorder without recognised structural or biochemical diagnostic abnormality⁶). It is an episodic syndrome on the migraine spectrum^{1 7} and consists of intermittent central abdominal pain severe enough to interfere with normal activities.²⁻⁸ The pain comes with migrainous features including sensory disturbance (photophobia, phonophobia), anorexia, nausea, vomiting, and pallor.^{7,8} Crucially, the patient is symptom-free and well between episodes, with a normal physical examination, stable body mass index, and expected developmental milestones. These elements are agreed by consensus diagnostic criteria for abdominal migraine (the International Classification of Headache Disorders (ICHD-3beta)⁷ and the Rome IV Classification of Gastroenterology Disorders⁹) and by earlier descriptions.^{8 10}

Other aspects of the diagnosis are debated.⁴⁻¹² Headache as an accompanying feature is omitted by one classification,⁷ excluding up to 70% of cases.³⁻¹³ The consensus classifications require an arbitrary number of episodes, and at least two

migrainous features.^{7,9} The stipulated duration of one⁹ or two⁷ hours misses briefer episodes,⁴ as found in a hospital study in India⁵ and in accord with the authors' experience. It is worth being aware of a possible diagnosis of abdominal migraine in those with some but not all consensus criteria.⁵⁻¹⁵ Patients often have other episodic syndromes, excluded from both consensus criteria.¹ Boxed Text on page 2 Box 1 provides a practical definition based on current consensus diagnostic criteria, published evidence, and the authors' experience.

Box 1 Recommended pragmatic clinical definition of abdominal migraine*

- Episodic central abdominal pain, usually lasting >1 hour
- Episodes interfere with normal activity
- Episodes occur with one or more of pallor, anorexia, nausea, vomiting, photophobia, headache, or are associated with other episodic syndromes (particularly cyclical vomiting and migraine limb pain)
- Person is well between episodes
- Normal physical and developmental examination

* Adapted from definitions of Symon and Russell,⁸ ICHD-3beta,⁷ and Rome IV⁹ and published studies²⁻¹⁵

How common is abdominal migraine?

Prevalence depends on definition, awareness, and setting in the absence of an objective diagnostic marker. In two British studies of children, population prevalence of abdominal migraine was 4.1% and 2.4% using the 1986 definition.^{2,13} Using the Rome III diagnostic criteria,¹⁶ prevalence was 9.2% in a US questionnaire study of the mothers of 949 children.¹⁷ Population prevalence in a study of British schoolchildren peaked at 6-12 years, highest at 9% at 12 years, and falling to 1% at 14 years,² with a female:male ratio of 1.6:1.²

What triggers and relieves abdominal migraine?

Stress, tiredness, travel, missed meals, and change in routine may trigger abdominal migraine,^{2,3} as for all migraine. Sometimes, triggers may be confused with premonitory symptoms (symptoms preceding or forewarning of a migraine episode).⁷ For example, bright light or low mood may seem to trigger an episode, when, in fact, photophobia and mood change are recognised premonitory symptoms.¹⁸ Relieving factors for abdominal migraine, as for other migraines, are rest (in 88% of patients), sleep (in 64%), and analgesia (in 38%).²

How do I diagnose abdominal migraine?

Typically a child with abdominal migraine presents to general practice or an emergency department with the features outlined in Boxed Text on page 2 box 1. The challenge is to distinguish it from organic and other functional causes of recurrent abdominal pain by confirming positive features and excluding "red flags" (⚠). "Red flags" suggest organic causes of abdominal pain (⚠), and so refer these children for an immediate expert opinion.²² Assessment is particularly difficult in children less than 2 years old, who may not be able to explain or point to the pain. In them, abdominal pain often manifests with non-specific features such as inconsolable crying and pulling up of the legs. Patients with abdominal migraine often have a personal or family history of other types of migraine, similar undiagnosed episodes, or other episodic syndromes.^{3,4}

Examination—including vital signs, temperature, and urine analysis—is normal apart from vasomotor changes (pallor, dark rings under the eyes).^{3,4} Urine analysis is an important part of the physical examination, as patients with diabetic ketoacidosis or urinary tract infection may present with abdominal pain. If a child with previously diagnosed abdominal migraine presents again it may suggest that the child or carer is concerned there is something different about the episode. In this situation fully re-assess, especially if there are new or atypical symptoms or signs, as they could have a second acute diagnosis.

Other than abdominal migraine, neurological causes of abdominal pain are rare. In abdominal epilepsy, the pain is usually brief (seconds to minutes) and associated with altered awareness, and sometimes followed by a tonic-clonic seizure.²³

Consensus guidelines suggest that children with a firm clinical diagnosis of abdominal migraine require no further investigations.⁹⁻²⁴

What causes abdominal migraine?

Specific changes to the gut-brain axis, vascular dysregulation, changes in the central nervous system, and genetic factors have been suggested as the cause of abdominal migraine.²⁵ It is not known why some people are vulnerable to this interaction between the central nervous system and the richly innervated gut, and whether this links with the trigemino-vascular system, which plays a major role in migraine headache.^{26,27} No studies suggest vasospasm of small gut vessels as the cause of the periumbilical pain, but regional or central changes^{28,29} in blood flow may be important, as they are for other forms of migraine.²⁶ The strong familial incidence in abdominal and other migraine suggests an important genetic role,³⁰ particularly for mutations involving cell membrane transport (channelopathies).^{31,32}

What other conditions is abdominal migraine associated with?

From population studies, 70% of those with abdominal migraine have current or previous migraine headache with or without aura.¹⁰ Patients with abdominal migraine often have other concurrent or previous episodic syndromes (60% of 84 patients³ and 30.6% of 1134 patients¹ in hospital series), particularly cyclical vomiting (66-76%)³⁻³⁶ and migraine limb pain.¹⁻³⁸ Other possible associations are benign paroxysmal vertigo,^{39,40} benign paroxysmal torticollis,^{1,31} infantile colic,^{41,42} Raynaud's disease,^{43,44} and hypermobility^{45,46} (see ⚠).

Is abdominal migraine linked to mental health?

Avoid assuming that abdominal pain in children without demonstrable pathology has a psychogenic basis.³⁻⁴⁷ Links with anxiety,^{48,49} depression,⁴⁸⁻⁵⁰ psychosocial difficulties,^{49,51} and abuse⁵² are postulated. Some studies⁴⁹⁻⁵⁴ and expert opinion¹²⁻⁵⁷ equate association and causality. Some studies are in uncontrolled⁵² or unrepresentative populations,⁵² have only pain-free controls,⁵⁰ group all functional abdominal pain as a homogenous diagnosis,⁴⁹⁻⁵⁸ or underestimate population variability of paediatric anxiety and depression (3.8-11% depending on definitions, age, severity, and setting⁵⁹). Controlled studies show that pain is associated with psychological distress, in children, adults, and families whatever the cause^{60,61} or site.⁶² Levels of depression and emotional adjustment were similar in children with functional abdominal pain and pain-free controls with minor illnesses.⁶³ Mood change as a premonitory symptom

or postdrome is recognised in outpatient studies of paediatric migraine,^{64,65} but there are no specific data on prevalence in abdominal migraine.

What happens to children with abdominal migraine as they grow up?

Children with abdominal migraine or other episodic syndromes usually have an excellent prognosis with no neurological or developmental deficits.¹⁰ A longitudinal study in 54 schoolchildren showed the clinical diagnosis of abdominal migraine was robust (using adapted criteria of Symon and Russell⁸). It resolved in 61% at 8-10 year follow-up.¹⁰ The prevalence and outcome of abdominal migraine in adults is unknown, with evidence limited to case reports and small series.¹¹⁻⁶⁸

How are children with abdominal migraine managed?

General and psychosocial approaches

A clear diagnosis³ and explanation of the condition to the patient and family is essential (see information sheets in appendix on bmj.com).^{2,3} In an observational clinic study, 60% of patients had parents with the same condition who were also relieved to understand it.³ Labelling abdominal migraine as medically unexplained⁶⁹ or psychogenic pain^{49,70} may exacerbate depression and anxiety in the child and parents. Missing the diagnosis^{5,14} led to unsuccessful surgery (mainly appendicectomy) in 4%³ and 5%⁵ of patients with abdominal migraine in British and Indian hospital series.

The biopsychosocial model of pain and symptom management emphasises a holistic view of the patient's life.^{6,9} Cognitive behavioural therapy improved functional abdominal pain in a case controlled series,⁷¹ but there are no specific data for abdominal migraine. Dietary treatments and elimination diets are unproved.¹¹ Anecdotally, understanding or avoidance of triggers (such as acute emotional stresses, missed meals, and sleep loss) is helpful.^{3,22} Acute symptoms resolve in >80% of patients with rest in a dark quiet room and simple analgesia (see Boxed Text on page 3 box 2, and ↓ on bmj.com).²

Box 2 Management strategies for abdominal migraine (see ↓ on bmj.com for supporting evidence)

General

- Explanation and education of patient and family (avoid triggers, regular lifestyle)^{2,3*}

Acute

- Rest in dark, quiet room*
- Simple analgesics such as paracetamol 15 mg/kg, ibuprofen 10 mg/kg*
- Sumatriptan—10 mg intranasal (triptan, serotonin agonist)*

Preventive treatment

- Pizotifen (serotonin agonist) 0.25 mg twice daily as syrup*
- Propranolol (β blocker) 10-20 mg twice or three times daily
- Cyproheptadine (antihistamine) 0.25-0.5 mg/kg daily as syrup
- Flunarazine (calcium channel blocker) 5-7.5 mg/day
- Sodium valproate (anti-epileptic) 500 mg three times daily intravenous—in hospital
- Dihydroergotamine (ergot) 0.5 mg intravenous, further doses possible (up to mean total 7-9 mg over several days)—in hospital

*Treatments can be given in primary care.

Pharmacological approaches

The evidence for pharmacological treatment of abdominal migraine is limited. In studies of paediatric migraine headache, resolution rates of up to 66% are reported with placebo treatment,⁸⁵ so high quality randomised controlled trials are needed to confirm efficacy of active treatments.⁸⁶ Pizotifen is the only medication meeting this standard for abdominal migraine.⁸⁷ ↓ on bmj.com summarises current evidence for treatments. Acute treatments, and if needed, prevention with pizotifen, may be managed in primary care, and will be effective in most patients. Expert advice is recommended for other medications because data are limited (cyproheptadine, propranolol, flunarazine, sodium valproate, dihydroergotamine) or absent (amitriptyline, topiramate) regarding use for abdominal migraine. It is unknown whether evidence on acute⁷⁶ or preventive management⁸⁸ of childhood migraine headache can be extrapolated to abdominal migraine. The only evidence for treatment of adult abdominal migraine is from case reports.⁶⁸

Education into practice

- Does this article improve your confidence in making a positive diagnosis of abdominal migraine in those with recurrent abdominal pain? What might you ask or do differently?
- How might you better explain or offer advice to patients and families with abdominal migraine?

Useful resources

- American Migraine Foundation* <https://americanmigrainefoundation.org/understanding-migraine/abdominal-migraine/>
- Migraine Action* www.migraine.org.uk/
- The Migraine Trust* <https://www.migrainetrust.org/>
- Patient. Migraine in children* <https://patient.info/doctor/migraine-in-children>
- The International Headache Society www.ihs-headache.org
- The Rome Foundation www.theromefoundation.org/
- The American Headache Society <https://americanheadachesociety.org/>

*Includes resources for patients and families

How patients were involved in the creation of this article

Parents and a patient with abdominal migraine reviewed the information sheets and read the article, commenting on sections which they did not feel were clear (the initial description of abdominal migraine and how the diagnosis was made). These comments were used to improve the manuscript. The patient drew the original sketch for [fig 1](#).

Acknowledgements

We thank Jacquelyn Murray-Hawkes and Steven Leigh for typing and figures, and Guy Robinson, Barnet Postgraduate Centre Library, for reprints. We thank the patients and families who contributed to the article.

Contributors: HAL formulated the plan and led the final manuscript. HAL DS and RJG drafted the manuscript. All authors researched and contributed to the manuscript and figures.

Funding: RJG was part funded by Fondecyt (Chile) Grant 1120339.

Competing interests: We have read and understood BMJ policy on declaration of interests and have no relevant interests to declare.

Provenance and peer review: Commissioned, externally peer reviewed.

- Tarantino S, Capuano A, Torriero R. Migraine equivalents as part of migraine syndrome in childhood. *Pediatr Neurol* 2014;51:645-9. 10.1016/j.pediatrneurol.2014.07.018. 25155656
- Abu-Arafeh I, Russell G. Prevalence and clinical features of abdominal migraine compared with those of migraine headache. *Arch Dis Child* 1995;72:413-7. 10.1136/adc.72.5.413 7618907
- Farquhar HG. Abdominal migraine in children. *BMJ* 1956;1:1082-5. 10.1136/bmj.1.4975.1082 13316075
- Symon DN. Is there a place for "abdominal migraine" as a separate entity in the IHS classification? *Yes! Cephalalgia* 1992;12:345-6. 10.1111/j.1468-2982.1992.00345.x 1473133
- Francis MV. Episodic syndromes that may be associated with migraine—two clinically useful markers. *J Headache Pain Manage* 2016;1:1010.4172/2472-1913.100010.
- Drossman DA. Functional GI disorders: what's in a name? *Gastroenterology* 2005;128:1771-2. 10.1053/j.gastro.2005.04.020 15940609
- Headache Classification Committee of the International Headache Society (IHS). The International Classification of Headache Disorders, 3rd edition (beta version). *Cephalalgia* 2013;33:629-808. 10.1177/0333102413485658 23771276
- Symon DN, Russell G. Abdominal migraine: a childhood syndrome defined. *Cephalalgia* 1986;6:223-8. 10.1046/j.1468-2982.1986.0604223.x 3802189
- Drossman DA. Functional gastrointestinal disorders: history, pathophysiology, clinical features and Rome IV. *Gastroenterology* 2016;S0016-5085(16)00223-7. 10.1053/j.gastro.2016.02.032. 27144617
- Dignan F, Abu-Arafeh I, Russell G. The prognosis of childhood abdominal migraine. *Arch Dis Child* 2001;84:415-8. 10.1136/adc.84.5.415 11316687
- Napthali K, Koloski N, Talley NJ. Abdominal migraine. *Cephalalgia* 2016;36:980-6. 10.1177/0333102415617748. 26582952
- Christensen MF. Double blind placebo controlled trial of pizotifen syrup in the treatment of abdominal migraine. *Arch Dis Child* 1995;73:183. 10.1136/adc.73.2.183-a 7574874
- Mortimer MJ, Kay J, Jaron A. Clinical epidemiology of childhood abdominal migraine in an urban general practice. *Dev Med Child Neurol* 1993;35:243-8. 10.1111/j.1469-8749.1993.tb11629.x 8462757
- Carson L, Lewis D, Tsou M. Abdominal migraine: an under-diagnosed cause of recurrent abdominal pain in children. *Headache* 2011;51:707-12. 10.1111/j.1526-4610.2011.01855.x. 21395574
- Worawattanakul M, Rhoads JM, Lichtman SN, Ulshen MH. Abdominal migraine: prophylactic treatment and follow-up. *J Pediatr Gastroenterol Nutr* 1999;28:37-40. 10.1097/00005176-19991000-00010 9890466
- Drossman DA. Rome III: the new criteria. *Chin J Dig Dis* 2006;7:181-5. 10.1111/j.1443-9573.2006.00265.x. 17054578
- Lewis ML, Palsson OS, Whitehead WE, van Tilburg MAL. Prevalence of functional gastrointestinal disorders in children and adolescents. *J Pediatr* 2016;177:39-43.e3. 10.1016/j.jpeds.2016.04.008 27156185
- Schulte LH, Jürgens TP, May A. Photo-, osmo- and phonophobia in the premonitory phase of migraine: mistaking symptoms for triggers? *J Headache Pain* 2015;16:14. 10.1186/s10194-015-0495-7. 25904144
- Berger MY, Gieteling MJ, Benninga MA. Chronic abdominal pain in children. *BMJ* 2007;334:997-1002. 10.1136/bmj.39189.465718.BE. 17494020
- Quek SH. Recurrent abdominal pain in children: a clinical approach. *Singapore Med J* 2015;56:125-8, quiz 132. 10.11622/smedj.2015038 25820843
- National Institute for Health and Care Excellence. Diarrhoea and vomiting caused by gastroenteritis in under 5s: diagnosis and management 2009 www.nice.org.uk/guidance/cg84.
- American Academy of Pediatrics Subcommittee on Chronic Abdominal Pain/North American Society for Pediatric Gastroenterology Hepatology, and Nutrition. Chronic abdominal pain in children. *Pediatrics* 2005;115:e370-81. 10.1542/peds.2004-2523. 15741363
- Franzon RC, Lopes CF, Schmutzler KM, Morais MI, Guerreiro MM. Recurrent abdominal pain: when should an epileptic seizure be suspected? *Arq Neuropsiquiatr* 2002;60(3-A):628-30. 10.1590/S0004-282X2002000400021 12244404
- Costa F, Mumolo MG, Marchi S, Bellini M. Differential diagnosis between functional and organic intestinal disorders: is there a role for non-invasive tests? *World J Gastroenterol* 2007;13:219-23. 10.3748/wjg.v13.i2.219 17226899
- Angus-Leppan H. Migraine: mimics, borderlands and chameleons. *Pract Neurol* 2013;13:308-18. 10.1136/practneurol-2012-000502. 23906594
- Goadsby PJ, Holland PR, Martins-Oliveira M, Hoffmann J, Schankin C, Akerman S. Pathophysiology of migraine: a disorder of sensory processing. *Physiol Rev* 2017;97:553-622. 10.1152/physrev.00034.2015. 28179394
- Kakisaka Y, Uematsu M, Wang ZI, Haginoya K. Abdominal migraine reviewed from both central and peripheral aspects. *World J Exp Med* 2012;2:75-7. 10.5493/wjem.v2.i4.75. 24520537
- Angus-Leppan H, Olausson B, Boers P, Lambert GA. Convergence of afferents from superior sagittal sinus and tooth pulp on cells in the thalamus of the cat. *Cephalalgia* 1995;15:911-9. 10.1046/j.1468-2982.1995.015003191.x 7553808
- Angus-Leppan H, Olausson B, Boers P, Lambert GA. Convergence of afferents from superior sagittal sinus and tooth pulp on cells in the upper cervical spinal cord of the cat. *Neurosci Lett* 1994;182:275-8. 10.1016/0304-3940(94)90815-X 7715826
- Sutherland HG, Griffiths LR. Genetics of migraine: insights into the molecular basis of migraine disorders. *Headache* 2017;57:537-69. 10.1111/head.13053. 28271496
- Giffin NJ, Benton S, Goadsby PJ. Benign paroxysmal torticollis of infancy: four new cases and linkage to CACNA1A mutation. *Dev Med Child Neurol* 2002;44:490-3. 10.1111/j.1469-8749.2002.tb00311.x 12162387
- Dale RC, Gardiner A, Antony J, Houlden H. Familial PRRT2 mutation with heterogeneous paroxysmal disorders including paroxysmal torticollis and hemiplegic migraine. *Dev Med Child Neurol* 2012;54:958-60. 10.1111/j.1469-8749.2012.04394.x. 22845787
- Abu-Arafeh I, Russell G. Cyclical vomiting syndrome in children: a population-based study. *J Pediatr Gastroenterol Nutr* 1995;21:454-8. 10.1097/00005176-199511000-00014 8583299
- Symon DN. Is cyclical vomiting an abdominal form of migraine in children? *Dig Dis Sci* 1999;44(Suppl):23S-5S.10490035
- Dignan F, Symon DN, Abu-Arafeh I, Russell G. The prognosis of cyclical vomiting syndrome. *Arch Dis Child* 2001;84:55-7. 10.1136/adc.84.1.55 11124785
- Salmon MA. The evolution of adult migraine through childhood migraine equivalents. In: Lanzi G, Balottin U, Cernibori A, eds. *Headaches in children and adolescents*. Elsevier Science publishers, 1989: 27-32.
- Guilloff RJ, Fruns M. Limb pain in migraine and cluster headache. *J Neurol Neurosurg Psychiatry* 1988;51:1022-31. 10.1136/jnnp.51.8.1022 3216204
- Guilloff RJ, Fruns M. Migrainous limb pain. A historical note. *Headache* 1990;30:138-41. 10.1111/j.1526-4610.1990.hed3003138.x 2182568
- Mira E, Piacentino G, Lanzi G, Balottin U, Fazzi E. Benign paroxysmal vertigo in childhood: a migraine equivalent. *ORL J Otorhinolaryngol Relat Spec* 1984;46:97-104. 10.1159/000275693 6422377
- Marcelli V, Piazza F, Pisani F, Marciano E. Neuro-otological features of benign paroxysmal vertigo and benign paroxysmal positioning vertigo in children: a follow-up study. *Brain Dev* 2006;28:80-4. 10.1016/j.braindev.2005.05.003. 16168599
- Spiri D, Rinaldi VE, Titomanlio L. Pediatric migraine and episodic syndromes that may be associated with migraine. *Ital J Pediatr* 2014;40:92. 10.1186/s13052-014-0092-4. 25928129
- Sillanpää M, Saarinen M. Infantile colic associated with childhood migraine: A prospective cohort study. *Cephalalgia* 2015;35:1246-51. 10.1177/0333102415576225. 25754178
- Zahavi I, Chagnac A, Hering R, Davidovich S, Kuritzky A. Prevalence of Raynaud's phenomenon in patients with migraine. *Arch Intern Med* 1984;144:742-4. 10.1001/archinte.1984.00350160096017 6143540
- Stein R, Chelmsky T, Li H, Chelmsky G. Functional gastrointestinal disorders in a primary care pediatric clinic. *Glob Pediatr Health* 2015;2:X14568452. 10.1177/2333794X14568452 27335938
- Clinch J, Deere K, Sayers A. Epidemiology of generalized joint laxity (hypermobility) in fourteen-year-old children from the UK: a population-based evaluation. *Arthritis Rheum* 2011;63:2819-27. 10.1002/art.30435. 21547894
- Henderson FCSr, Austin C, Benzel E. Neurological and spinal manifestations of the Ehlers-Danlos syndromes. *Am J Med Genet C Semin Med Genet* 2017;175:195-211. 10.1002/ajmg.c.31549. 28220607
- McGrath P. Psychological aspects of recurrent abdominal pain. *Can Fam Physician* 1983;29:1655-9. 21283400
- Yacob D, Di Lorenzo C, Bridge JA. Prevalence of pain-predominant functional gastrointestinal disorders and somatic symptoms in patients with anxiety or depressive disorders. *J Pediatr* 2013;163:767-70. 10.1016/j.jpeds.2013.02.033. 23522860
- Hotopf M, Carr S, Mayou R, Wadsworth M, Wessely S. Why do children have chronic abdominal pain, and what happens to them when they grow up? Population based cohort study. *BMJ* 1998;316:1196-200. 10.1136/bmj.316.7139.1196 9552994

- 50 Machnes-Maayan D, Elazar M, Apter A, Zeharia A, Krispin O, Eidlitz-Markus T. Screening for psychiatric comorbidity in children with recurrent headache or recurrent abdominal pain. *Pediatr Neurol* 2014;50:49-56. 10.1016/j.pediatrneurol.2013.07.011. 24269169
- 51 Li BU. Functional abdominal pain in children: new understanding, diagnostic criteria, and treatment approaches. *Pediatr Ann* 2009;38:241-2. 19476294
- 52 van Tilburg MA, Runyan DK, Zolotor AJ. Unexplained gastrointestinal symptoms after abuse in a prospective study of children at risk for abuse and neglect. *Ann Fam Med* 2010;8:134-40. 10.1370/afm.1053. 20212300
- 53 LeResche L, Mancl LA, Drangsholt MT, Saunders K, Von Korff M. Relationship of pain and symptoms to pubertal development in adolescents. *Pain* 2005;118:201-9. 10.1016/j.pain.2005.08.011. 16213087
- 54 Mortimer MJ, Kay J, Jaron A, Good PA. Does a history of maternal migraine or depression predispose children to headache and stomach-ache? *Headache* 1992;32:353-5. 10.1111/j.1526-4610.1992.hed3207353.x 1526767
- 55 Apley J. Psychosomatic aspects of gastrointestinal problems in children. *Clin Gastroenterol* 1977;6:311-20. 884882
- 56 Hockaday JM. Is there a place for "abdominal migraine" as a separate entity in the IHS classification? *NoI Cephalgia* 1992;12:346-8. 1473134
- 57 Nicol AR. Psychogenic abdominal pain in childhood. *Br J Hosp Med* 1982;27:351-3. 7074271
- 58 Abu-Arafeh I. Long term follow up of children with recurrent abdominal pain. Definition of recurrent abdominal pain was not applied. *BMJ* 1998;317:682-3. 10.1136/bmj.317.7159.682a 9728012
- 59 Merikangas KR, Nakamura EF, Kessler RC. Epidemiology of mental disorders in children and adolescents. *Dialogues Clin Neurosci* 2009;11:7-20. 19432384
- 60 Sawyer MG, Davidson GP, Goodwin D, Crettenden AD. Recurrent abdominal pain in childhood. Relationship to psychological adjustment of children and families: a preliminary study. *Aust Paediatr J* 1987;23:121-4. 3619782
- 61 Walker LS, Greene JW. Children with recurrent abdominal pain and their parents: more somatic complaints, anxiety, and depression than other patient families? *J Pediatr Psychol* 1989;14:231-43. 10.1093/jpepsy/14.2.231 2754574
- 62 Lighthart L, Gerrits MM, Boomsma DI, Penninx BW. Anxiety and depression are associated with migraine and pain in general: an investigation of the interrelationships. *J Pain* 2013;14:363-70. 10.1016/j.jpain.2012.12.006. 23395476
- 63 McGrath PJ, Goodman JT, Firestone P, Shipman R, Peters S. Recurrent abdominal pain: a psychogenic disorder? *Arch Dis Child* 1983;58:888-90. 10.1136/adc.58.11.888 6651325
- 64 Karsan N, Prabhakar P, Goadsby PJ. Characterising the premonitory stage of migraine in children: a clinic-based study of 100 patients in a specialist headache service. *J Headache Pain* 2016;17:94. 10.1186/s10194-016-0689-7. 27770403
- 65 Mamouri O, Cuvelier JC, Duhamel A, Vallée L, Nguyen The Tich S. Postdrome symptoms in pediatric migraine: A questionnaire retrospective study by phone in 100 patients. *Cephalalgia* 2017;33:102417721132. 10.1177/0333102417721132. 28728427
- 66 Santoro G, Curzio M, Venco A. Abdominal migraine in adults. Case reports. *Funct Neurol* 1990;5:61-4. 2401430
- 67 Roberts JE, deShazo RD. Abdominal migraine, another cause of abdominal pain in adults. *Am J Med* 2012;125:1135-9. 10.1016/j.amjmed.2012.06.008. 22939361
- 68 Woodruff AE, Cieri NE, Abeles J, Seyse SJ. Abdominal migraine in adults: a review of pharmacotherapeutic options. *Ann Pharmacother* 2013;47:e27. 10.1345/aph.1R620. 23673535
- 69 Campo JV, Di Lorenzo C, Chiappetta L. Adult outcomes of pediatric recurrent abdominal pain: do they just grow out of it? *Pediatrics* 2001;108:E1. 10.1542/peds.108.1.e1 11433080
- 70 Apley J. *The child with abdominal pains*. Blackwell Scientific Publications, 1975.
- 71 Sanders MR, Shepherd RW, Cleghorn G, Woolford H. The treatment of recurrent abdominal pain in children: a controlled comparison of cognitive-behavioral family intervention and standard pediatric care. *J Consult Clin Psychol* 1994;62:306-14. 10.1037/0022-006X.62.2.306 8201068
- 72 Oxford Centre for Evidence Based Medicine. 2011 www.cebm.net/ocbcm-levels-of-evidence/.
- 73 Perrott DA, Piira T, Goodenough B, Champion GD. Efficacy and safety of acetaminophen vs ibuprofen for treating children's pain or fever: a meta-analysis. *Arch Pediatr Adolesc Med* 2004;158:521-6. 10.1001/archpedi.158.6.521. 15184213
- 74 Cranswick N, Coghlan D. Paracetamol efficacy and safety in children: the first 40 years. *Am J Ther* 2000;7:135-41. 10.1097/00045391-200007020-00010 11319581
- 75 Kakisaka Y, Wakusawa K, Haginoya K. Efficacy of sumatriptan in two pediatric cases with abdominal pain-related functional gastrointestinal disorders: does the mechanism overlap that of migraine? *J Child Neurol* 2010;25:234-7. 10.1177/0883073809336875. 19509407
- 76 Richer L, Billinghamurst L, Linsdell MA. Drugs for the acute treatment of migraine in children and adolescents. *Cochrane Database Syst Rev* 2016;4:CD005220. 10.1002/14651858.CD005220.pub2. 27091010
- 77 Kacperski J, Kabbouche MA, O'Brien HL, Weberding JL. The optimal management of headaches in children and adolescents. *Ther Adv Neurol Disord* 2016;9:53-68. 10.1177/1756285615616586. 26788131
- 78 Sakai F. Oral triptans in children and adolescents: an update. *Curr Pain Headache Rep* 2015;19:8. 10.1007/s11916-015-0478-z. 25754598
- 79 Symon DN, Russell G. Double blind placebo controlled trial of pizotifen syrup in the treatment of abdominal migraine. *Arch Dis Child* 1995;72:48-50. 10.1136/adc.72.1.48 7717738
- 80 Kothare SV. Efficacy of flunarizine in the prophylaxis of cyclical vomiting syndrome and abdominal migraine. *Eur J Paediatr Neurol* 2005;9:23-6. 10.1016/j.ejpn.2004.11.002. 15701563
- 81 Tan V, Sahami AR, Peebles R, Shaw RJ. Abdominal migraine and treatment with intravenous valproic acid. *Psychosomatics* 2006;47:353-5. 10.1176/appi.psy.47.4.353. 16844896
- 82 Russell G, Abu-Arafeh I, Symon DN. Abdominal migraine: evidence for existence and treatment options. *Paediatr Drugs* 2002;4:1-8. 10.2165/00128072-200204010-00001 11817981
- 83 Raina M, Chelimsky G, Chelimsky T. Intravenous dihydroergotamine therapy for pediatric abdominal migraines. *Clin Pediatr (Phila)* 2013;52:918-21. 10.1177/0009922813492879. 23820001
- 84 O'Brien HL, Kabbouche MA, Kacperski J, Hershey AD. Treatment of pediatric migraine. *Curr Treat Options Neurol* 2015;17:326. 10.1007/s11940-014-0326-1. 25617222
- 85 Powers SW, Coffey CS, Chamberlin LACHAMP Investigators. Trial of amitriptyline, topiramate, and placebo for pediatric migraine. *N Engl J Med* 2017;376:115-24. 10.1056/NEJMoa1610384. 27788026
- 86 Tfelt-Hansen P, Pascual J, Ramadan International Headache Society Clinical Trials Subcommittee. Guidelines for controlled trials of drugs in migraine: third edition. A guide for investigators. *Cephalalgia* 2012;32:6-38. 10.1177/0333102411417901 22384463
- 87 Symon DN, Russell G. Double blind placebo controlled trial of pizotifen syrup in the treatment of abdominal migraine. *Arch Dis Child* 1995;72:48-50. 10.1136/adc.72.1.48 7717738
- 88 El-Chammas K, Keyes J, Thompson N, Vijayakumar J, Becher D, Jackson JL. Pharmacologic treatment of pediatric headaches: a meta-analysis. *JAMA Pediatr* 2013;167:250-8. 10.1001/jamapediatrics.2013.508. 23358935

Published by the BMJ Publishing Group Limited. For permission to use (where not already granted under a licence) please go to <http://group.bmj.com/group/rights-licensing/permissions>

Tables

Table 1 | Red flag symptoms associated with childhood abdominal pain (adapted from Rome III16 and Rome IV9 classification)

Red flag symptom	Common associated conditions
Acute	
Features of dehydration or shock*	Any acute worsening pathology
Thirst, polyuria	Diabetic ketoacidosis
Localised pain with tenderness or guarding	“Surgical” (appendicitis, volvulus, intussusception)
Fever	Infection (gastroenteritis† mesenteric adenitis)
Vomiting bile	Obstruction
Vomiting blood	Upper gastrointestinal bleed
Bloody stool	Gastrointestinal bleed, infection
Change in bowel habits (diarrhoea)	Gastroenteritis†
Dysuria, haematuria	Urinary tract infection
Pain that radiates to the groin	Testicular torsion
Chronic or recurrent	
Odynophagia	Tonsillitis, peritonsillar abscess
Dysphagia	Reflux, developmental delay, metabolic, genetic
Persistent right upper or right lower abdominal pain	IBD, coeliac disease, malignancy
Abdominal mass	Malignancy, storage diseases
Persistent vomiting	Reflux, cow's milk protein allergy, malignancy
Weight loss	IBD, coeliac disease, malignancy, metabolic, genetic
Fever, night sweats	Infection, IBD, malignancy
Change in bowel habit (bloody stool or chronic diarrhoea)	IBD, coeliac disease, cow's milk protein allergy, malignancy
Growth failure and delayed puberty	IBD, malignancy, metabolic, genetic
Perianal abnormalities (fistulae, fissures, skin tags)	IBD, coeliac disease
Arthritis or family history of IBD	IBD

*

NICE 2009²¹ provides a table of progressive features of dehydration and shock.

†

Acute gastroenteritis needs urgent expert opinion if other red flags present.

Table 2| Treatment strategies for abdominal migraine in children

Intervention	Study type	No of participants	Outcome measures	Duration	Main results	Safety* and availability	Grade of evidence†72
General‡§							
Explanation and education of patient and family (avoid triggers, regular lifestyle)2,3	Case series in UK paediatric clinic aged 18 months to 15 years3	112 with abdominal migraine and/or cyclical vomiting (defined in Boxed Text on page 2box 1)	Improvement, not otherwise specified	Not specified	100% improvement, not further specified	No adverse events	Level 4
Acute treatment‡							
Rest in dark, quiet room	Observational study of random sample of Scottish schoolchildren aged 5-15 years2	58 with abdominal migraine (Symon and Russell definition6)	Resolution of acute episode of abdominal migraine	Not specified	88% (51/58) resolved	No adverse events	Level 3
Simple analgesics such as paracetamol 15 mg/kg, ibuprofen 10 mg/kg	As above2	As above	Resolution of acute episode of abdominal migraine	Acute, not further specified	38% (22/58) resolved	No adverse events in this study. No difference between acute ibuprofen, paracetamol and placebo in adverse events in meta-analysis of children with pain or fever.73 Paracetamol safe at recommended doses, hepatotoxic in overdose74	Level 3 (safety evidence is level 1 or 2)*
Sumatriptan 10 mg intranasal (triptan, serotonin agonist)¶	Case reports, Japanese paediatric clinic75	12 year old girl with abdominal migraine (Rome III definition16). 9 year old girl with abdominal migraine (Boxed Text on page 2box 1 definition)	Resolution of acute episode of abdominal migraine	Acute, repeated over 2 years	Acute pain responded (n=2)	No adverse events in this study. Increased risk of minor adverse events in meta-analysis of paediatric migraine.76* Avoid overuse77 (may cause rebound symptoms**) Licensed >12 years (UK),78 >6 years (US)78	Level 4
Preventive treatment (consider if >2 attacks/month or major impact despite acute treatment)							
Pizotifen (serotonin agonist) 0.25 mg twice daily as syrup‡ ¶ ††	Randomised, double blind, placebo controlled, crossover trial, UK paediatric clinic79	14 patients, aged 5-14 years with abdominal migraine (Symon and Russell definition8)	Days affected. Index of severity. Index of misery (severity × duration)	2 months in each crossover arm	Improvement: fewer days (4.29 v 12.5, P<0.005); severity lower (7.29 v 23.5, P<0.005); index of misery lower (25.43 v 81.5, P<0.007)	Adverse events: mild drowsiness, weight gain (1.25 kg v 0.38 kg, P=0.035). Available worldwide but not licensed in US	Level 1 or 2
Propranolol (β blocker) 10-20 mg two or three times daily	Retrospective clinic case note review in US paediatric gastroenterology clinic, 3-15 years old15	24 patients with abdominal migraine (Boxed Text on page 2box 1 definition)	Responses: graded as excellent (pain-free), fair (improved but not resolved), or poor (no response). No of episodes in preceding 6 months versus 6 months' treatment	Duration as required: 3-6 months for 11/24, 3 years for 13/25	75% (18/24) excellent, 8% (2/24) fair, 17% (4/24) poor. Two responded to cyproheptadine. Mean (SE) No of episodes in preceding 6 months 5.4 (0.6) versus 1.0 (0.3) in 6 months' treatment	Adverse events: shortness of breath (1/24), headache (1/24), drowsiness (1/24). Asthma is contra-indication. Expert guidance recommended	Level 3 or 4
Cyproheptadine (antihistamine) 0.25-0.5 mg/kg daily as syrup‡‡	As above15	12 patients with abdominal migraine (Boxed Text on page 2box 1 definition)	As above	Duration as required: 2-11 months	33% (4/12) excellent, 50% (6/12) fair, 17% (2/12) poor. Mean (SE) No of episodes in preceding 6 months 5.8 (2.1) versus 1.3 (0.5) in 6 months' treatment	Adverse events: drowsiness (1/12), weight gain (1/12). Expert guidance recommended	Level 3 or 4

Table 2 (continued)

Intervention	Study type	No of participants	Outcome measures	Duration	Main results	Safety* and availability	Grade of evidence†‡
Flunarazine (calcium channel blocker) 5-7.5 mg/day††	Uncontrolled trial, US paediatric clinic ⁶⁰	10 patients with abdominal migraine	Percentage reduction in frequency and duration	6-24 months (mean 13 months)	Frequency reduction 61%, duration reduction 51% (headache reduction 60%)	Expert guidance recommended	Level 3
Sodium valproate (antiepileptic) 500 mg three times daily intravenous¶	Case studies, in US paediatric hospital ⁸¹	2 girls, 12 and 17 years old, with intractable abdominal migraine (Russell et al definition ^{10,82})	Cessation of refractory episode and associated behavioural disturbance	Episodic treatment when other treatments including sumatriptan failed	Episodes resolved	Adverse events: weight gain (1/2). Expert guidance recommended	Level 4
Dihydroergotamine (ergot) 0.5 mg intravenous, further doses (mean 7-9 mg total over several days) ¶ †† §§	Case series, US hospital (joint gastroenterology, neurology and autonomic departments ⁸³)	6 patients, 13-19 years, intractable abdominal migraine, unresponsive to amitriptyline, verapamil, topiramate, sodium valproate	Cessation of refractory episode Time to next episode	Episodic treatment	5/6 responders	No significant adverse events Expert guidance recommended	Level 4

*

Safety derived from abdominal migraine studies and other studies in paediatrics.

†

Evidence grades 1-5 (highest to lowest).

‡

Treatments can be given in primary care.

§

See information leaflets in appendix on bmj.com.

¶

Caution in females of childbearing age.

**

Medication overuse in children: acute analgesics >3 days/month and migraine-specific drugs, especially triptans, >9 times/month.⁷⁻⁸⁴

††

Availability limited in some parts of world.

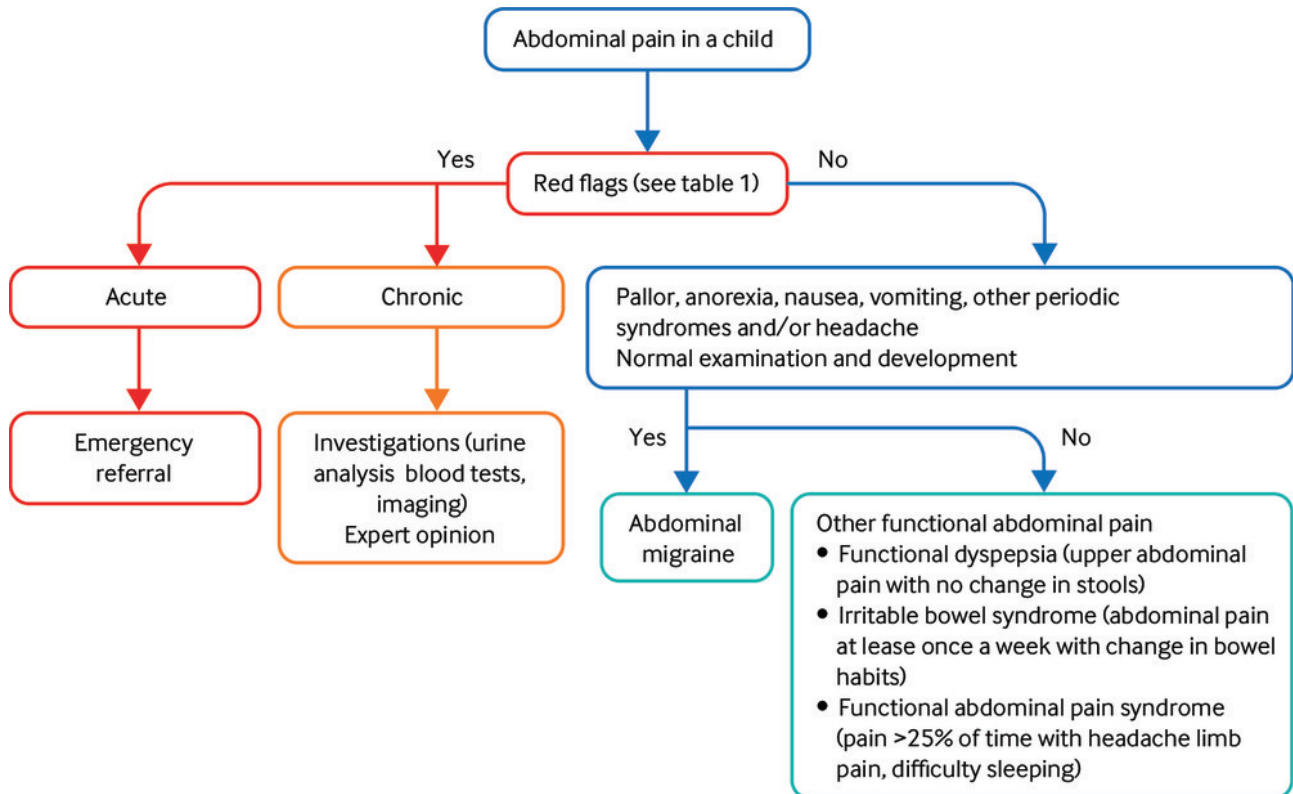
‡‡

Little used in some parts of world.

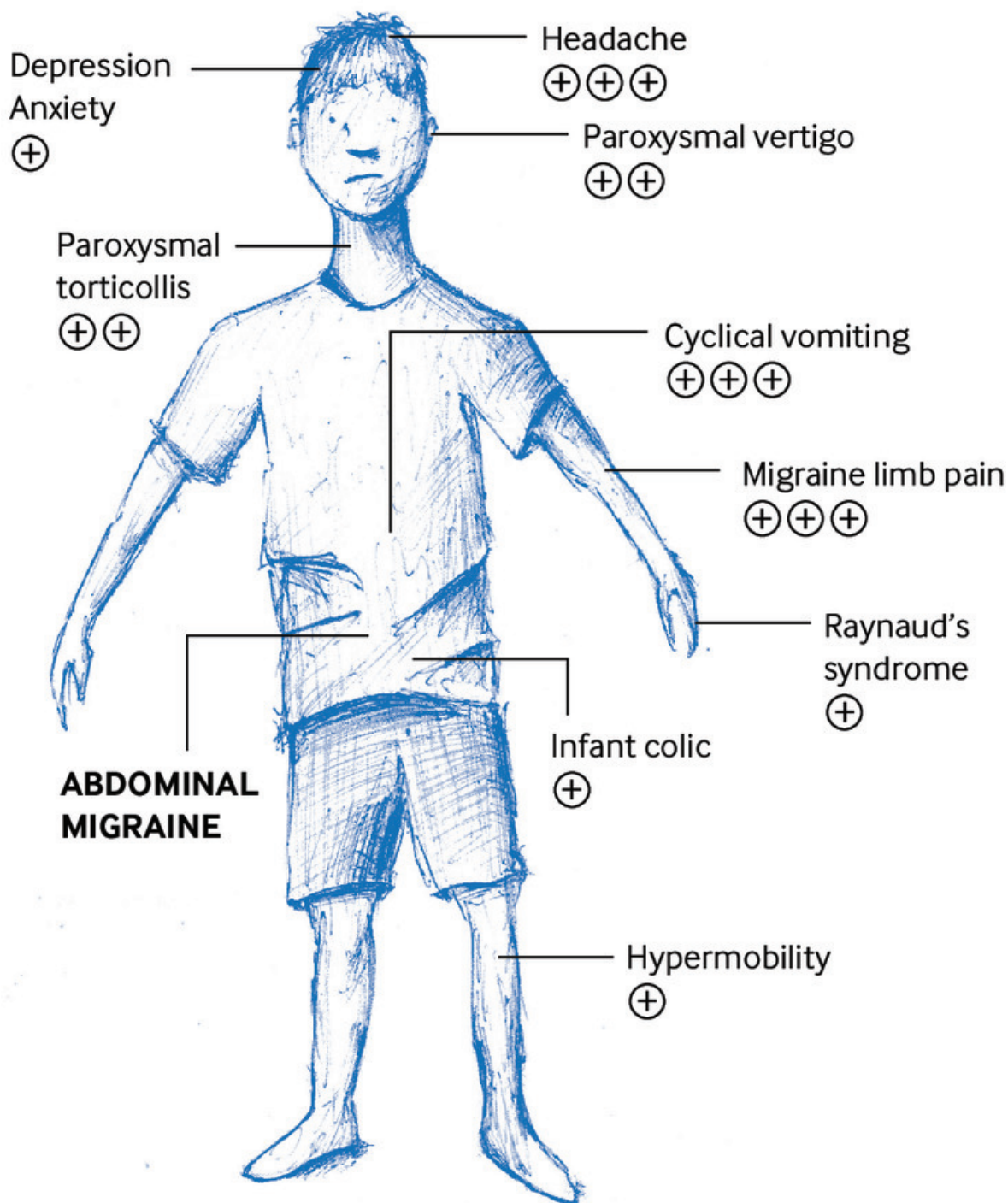
§§

Not licensed for children in UK.

Figures



Schematic approach to managing abdominal migraine (adapted from Rome III,¹⁶⁻¹⁹ Rome IV⁹ and ICHD-3 classifications,⁷ and Quek, 2015²⁰)



Strength of evidence for associations: + uncertain, ++ moderate, +++ strong association¹

A patient's view of the associations of abdominal migraine and level of evidence for these