

# Race- and Sex-Related Differences in Retinal Thickness and Foveal Pit Morphology

Melissa Wagner-Schuman,<sup>1,2</sup> Adam M. Dubis,<sup>2,3</sup> Rick N. Nordgren,<sup>4</sup> Yuming Lei,<sup>5</sup> Daniel Odell,<sup>4</sup> Hellen Chiao,<sup>4</sup> Eric Web,<sup>4</sup> William Fischer,<sup>6</sup> Yusufu Sulai,<sup>7</sup> Alfredo Dubra,<sup>6</sup> and Joseph Carroll<sup>1,3,4</sup>

**PURPOSE.** To examine sex- and race-associated differences in macular thickness and foveal pit morphology by using spectral-domain optical coherence tomography (SD-OCT).

**METHODS.** One hundred eighty eyes of 90 healthy patients (43 women, 47 men) underwent retinal imaging with spectral-domain OCT. The lateral scale of each macular volume scan was corrected for individual differences in axial length by ocular biometry. From these corrected volumes, Early Treatment Diabetic Retinopathy Study (ETDRS) grids of retinal thickness were generated and compared between the groups. Foveal morphology was measured with previously described algorithms.

**RESULTS.** Compared with the Caucasians, the Africans and African Americans had reduced central subfield thickness. Central subfield thickness was also reduced in the women compared with the men, although the women also showed significant thinning in parafoveal regions. There was no difference between the sexes in foveal pit morphology; however, the Africans/African Americans had significantly deeper and broader foveal pits than the Caucasians.

**CONCLUSIONS.** Previous studies have reported race- and sex-associated differences in macular thickness, and the inference has been that these differences represent similar anatomic features. However, the data on pit morphology collected in the present study reveal an important and significant variation. Between the sexes, the differences are due to global variability in retinal thickness, whereas the variation in thickness observed between the races appears to be driven by differences in foveal pit morphology. These differences have important implications for the use of SD-OCT in detecting and diagnosing retinal disease. (*Invest Ophthalmol Vis Sci.* 2011;52:625–634) DOI:10.1167/iov.10-5886

Optical coherence tomography (OCT) provides high-resolution views of the macula and enables quantitative assessment of macular thickness.<sup>1</sup> Spectral-domain (SD) OCT systems, with faster imaging speed and better resolution than time-domain systems, have increased the utility of this technology for assessing macular thickness. Of paramount importance to the sensitivity and accuracy of these devices for diagnosing macular disease is comparison against a normative database. Although there is well-known racial variability in the susceptibility to retinal diseases such as retinopathy of prematurity,<sup>2</sup> age-related macular degeneration (AMD),<sup>3,4</sup> and glaucoma,<sup>5</sup> widespread acceptance and use of normative databases that control for race- or sex-related differences in retinal anatomy (macula or optic nerve) are currently lacking. This deficit may be due in part to a lack of understanding of the etiology of the racial differences in retinal anatomy.

Using a retinal thickness analyzer, Asrani et al.<sup>6</sup> first reported differences in retinal thickness between the sexes and races, with black women having the thinnest retinas. As summarized in Table 1, in subsequent studies, OCT has been used to characterize sex- and race-based differences in retinal thickness.<sup>7–13</sup> Asefzadeh et al.<sup>8</sup> used time-domain OCT and observed significantly thinner total foveal and total macular thickness in African Americans compared with age-matched Caucasians in a small sample ( $n = 14$ ). This finding was replicated, also with time-domain OCT, in two larger studies that found the mean foveal thicknesses in African Americans to be significantly thinner than in Caucasians.<sup>9,12</sup> Interestingly, a study in which SD-OCT was used found no sex-related difference in central macular thickness.<sup>11</sup> A second SD-OCT study also found no difference between the sexes in retinal thickness, but did report a significant reduction in retinal thickness in African Americans compared with Caucasians.<sup>10</sup> A more recent SD-OCT study of 198 subjects showed that women had significantly thinner retinas than did men.<sup>13</sup> Understanding possible race- and sex-associated differences and the mechanism leading to such differences could significantly enhance the interpretation of OCT measurements of retinal thickness.

Recently, we developed an automated technique to quantify the morphology of the foveal pit (depth, diameter, and

From the Departments of <sup>1</sup>Biophysics, <sup>2</sup>Cell Biology, Neurobiology, and Anatomy, and <sup>4</sup>Ophthalmology, Medical College of Wisconsin, Milwaukee, Wisconsin; the <sup>5</sup>Department of Biomedical Engineering, Marquette University, Milwaukee, Wisconsin; and the <sup>6</sup>Flaum Eye Institute and <sup>7</sup>The Institute of Optics, University of Rochester, Rochester, New York.

<sup>2</sup>These authors contributed equally to the work presented here and should therefore be regarded as equivalent authors.

Presented at the annual meeting of the Association for Research in Vision and Ophthalmology, Fort Lauderdale, Florida, May 2010.

Supported by National Institutes of Health Grants P30EY001931 (Medical College of Wisconsin), P30EY001319 (University of Rochester), T32EY014537 (AMD), and R01EY017607 (JC); grants from Fight for Sight (JC), The E. Matilda Ziegler Foundation for the Blind (JC), Thomas M. Aaberg Sr, Retina Research Fund (JC), and the R. D. and Linda Peters Foundation (JC); and unrestricted departmental grants from Research to Prevent Blindness to the Ophthalmology Departments at the Medical College of Wisconsin and the University of Rochester. JC is the recipient of a Career Development Award from Research to Prevent Blindness. AD-S is the recipient of a Career Award at the Scientific Interface from the Burroughs Wellcome Fund. This investigation was conducted in a facility constructed with support from Research Facilities Improvement Program Grant Number C06 RR-RR016511 from the National Center for Research Resources, National Institutes of Health.

Submitted for publication May 14, 2010; revised July 19, 2010; accepted August 25, 2010.

Disclosure: M. Wagner-Schuman, None; A.M. Dubis, None; R.N. Nordgren, None; Y. Lei, None; D. Odell, None; H. Chiao, None; E. Web, None; W. Fischer, None; Y. Sulai, None; A. Dubra, None; J. Carroll, None

Corresponding author: Joseph Carroll, The Eye Institute, 925 N. 87th Street, Milwaukee, WI 53226; jcarroll@mcw.edu.

TABLE 1. Summary of Previous OCT Studies on Racial and Sex Differences in Retinal Thickness

Study*	ETDRS Region	Male	Female	P	Caucasian	African American	P
Wong et al. <sup>7†</sup> (n = 117)‡	Central 1 mm	203 ± 23	189 ± 20	0.001	ND	ND	ND
Asefzadeh et al. <sup>8†</sup> (n = 14)‡	Central subfield	ND	ND	ND	184 ± 29	160 ± 26	0.12
	Total foveal	ND	ND	ND	228 ± 17	204 ± 17	0.02
	Total macular	ND	ND	ND	248 ± 14	232 ± 13	0.05
Kelty et al. <sup>9†</sup> (n = 83)‡	Central 1 mm	220 ± 26	199 ± 26	≤0.001	219 ± 25	186 ± 17	≤0.001
	Temporal inner macula	281 ± 15	267 ± 23	≤0.05	275 ± 23	267 ± 18	>0.05
	Superior inner macula	294 ± 14	281 ± 22	≤0.05	290 ± 20	278 ± 19	≤0.05
	Nasal inner macula	296 ± 15	279 ± 23	≤0.001	290 ± 23	277 ± 18	≤0.05
	Inferior inner macula	293 ± 15	281 ± 20	≤0.05	290 ± 19	281 ± 18	>0.05
	Temporal outer macula	236 ± 16	227 ± 20	≤0.05	233 ± 20	227 ± 17	>0.05
	Superior outer macula	255 ± 16	248 ± 20	>0.05	252 ± 19	248 ± 18	>0.05
	Nasal outer macula	273 ± 15	268 ± 22	>0.05	272 ± 20	266 ± 19	>0.05
	Inferior outer macula	247 ± 16	242 ± 31	>0.05	245 ± 31	242 ± 17	>0.05
Grover et al. <sup>10†</sup> (n = 50)‡	Central 1 mm	273.8 ± 23.0	266.3 ± 21.9	0.10	272.7 ± 20.8	256.5 ± 16.9	0.007
Sull et al. <sup>11†</sup> (n = 40)§	Central subfield (Stratus)	208 ± 14	201 ± 19	0.240	ND	ND	ND
	Central subfield (Cirrus)	266 ± 16	258 ± 17	0.156	ND	ND	ND
	Central subfield (Topcon)	234 ± 16	226 ± 18	0.151	ND	ND	ND
Kashani et al. <sup>12  </sup> (n = 126)¶	Central point foveal	163.0 ± 3.0	154.7 ± 2.5	0.03	164.1 ± 2.8	147.2 ± 3.6	<0.0001
	Mean foveal	201.8 ± 2.7	186.9 ± 2.6	<0.001	200.2 ± 2.7	181.0 ± 3.7	<0.0001
	Temporal inner macula	263.1 ± 1.9	250.9 ± 1.8	<0.001	257.1 ± 2.4	251.5 ± 2.5	NR
	Superior inner macula	278.5 ± 1.8	265.8 ± 2.1	<0.001	272.3 ± 2.6	264.6 ± 2.8	NR
	Nasal inner macula	278.4 ± 1.9	263.0 ± 2.1	<0.001	271.9 ± 2.8	262.7 ± 2.8	NR
	Inferior inner macula	274.2 ± 2.1	261.2 ± 2.0	<0.001	268.8 ± 2.7	261.7 ± 2.8	NR
	Temporal outer macula	226.5 ± 1.8	215.4 ± 1.7	<0.001	218.6 ± 2.1	217.8 ± 2.7	NR
	Superior outer macula	244.5 ± 2.0	236.1 ± 2.0	0.003	238.7 ± 2.4	236.5 ± 3.0	NR
	Nasal outer macula	261.5 ± 2.2	251.2 ± 1.9	<0.001	256.3 ± 2.6	251.9 ± 2.8	NR
	Inferior outer macula	232.7 ± 2.0	223.7 ± 2.3	0.003	230.0 ± 2.5	225.5 ± 2.8	NR
Song et al. <sup>13†</sup> (n = 198)§	Central subfield	259.4 ± 23.0	247.9 ± 24.0	0.009	ND	ND	ND
	Temporal inner macula	309.5 ± 17.0	298.3 ± 31.7	0.015	ND	ND	ND
	Superior inner macula	320.7 ± 18.2	313.9 ± 21.0	0.040	ND	ND	ND
	Nasal inner macula	323.5 ± 18.4	316.6 ± 18.3	0.064	ND	ND	ND
	Inferior inner macula	315.0 ± 19.6	308.0 ± 20.2	0.104	ND	ND	ND
	Temporal outer macula	261.6 ± 16.0	253.7 ± 23.5	0.006	ND	ND	ND
	Superior outer macula	274.3 ± 15.7	275.3 ± 14.3	0.911	ND	ND	ND
	Nasal outer macula	293.3 ± 17.3	290.3 ± 18.4	0.400	ND	ND	ND
	Inferior outer macula	266.7 ± 14.9	261.9 ± 16.6	0.022	ND	ND	ND

ND, not done; NR, not reported; shading indicates significant differences ( $P < 0.05$ ).

\* Time-domain OCT (Stratus; Carl Zeiss Meditec, Dublin, CA) was used in all studies except Grover et al.,<sup>10</sup> who used spectral-domain OCT (Spectralis; Heidelberg Engineering, Heidelberg, Germany), Sull et al.,<sup>11</sup> who used both time-domain and spectral-domain OCT (Cirrus; Carl Zeiss Meditec; Topcon, Tokyo, Japan), and Song et al.,<sup>13</sup> who used spectral-domain OCT (Cirrus). Difference in absolute thickness between time- and spectral-domain OCT measurements have been reported.<sup>14-16</sup>

† Mean ± SD in micrometers.

‡ Right eye data (except for 4/50 in Grover et al.,<sup>10</sup> who reported left eye data).

§ One eye randomly selected from each subject.

|| Mean ± SE in micrometers.

¶ Combined data from both eyes.

slope), and observed significant variation in all three parameters.<sup>17</sup> The purpose of the present study was to examine the differences in foveal pit morphology between the sexes and races and their relationship to differences in retinal thickness. Our data indicate that retinal thickness alone is an inadequate explanation of the mechanisms behind observed race- and sex-based differences in retinal thickness. Rather, foveal morphology and retinal thickness together provide a more complete picture of foveal anatomy and should be used in tandem to construct race- and sex-based normative databases.

## METHODS

### Subjects

Ninety subjects aged 18 years and older were recruited from local communities surrounding the Medical College of Wisconsin (Milwaukee, WI) and the University of Rochester (Rochester, NY). Race was self-reported as Caucasian, African (both parents born in Africa), or African American. The Caucasian subjects were largely of Western

European heritage. Informed consent was obtained from all subjects after explanation of the nature and possible consequences of the study. All research involving human subjects adhered to the tenets of the Declaration of Helsinki and was approved by Institutional Review Boards at the Medical College of Wisconsin and University of Rochester. Table 2 provides demographic data for our study population. All subjects had normal color vision as assessed with the Neitz test<sup>18</sup> and had no history of refractive surgery or any vision-limiting ocular disease.

### SD-OCT Imaging

Volumetric images of the macula were obtained with a Cirrus HD-OCT (Carl Zeiss Meditec, Dublin, CA). The theoretical axial and transverse resolutions of the Cirrus system are approximately 5 and 20  $\mu\text{m}$ , respectively. Volumes were nominally  $6 \times 6$  mm and consisted of 128 B-scans (512 A-scans/B-scan), acquired at 27,000 A-scans/second. The internal fixation target of the system was used, which is a large green asterisk on a red background. Pupillary dilation was not performed, and focus of the LSO fundus image was optimized using built-in focus

TABLE 2. Demographic Data of the Subject Population

Demographics Category*	Caucasian (n = 60)†	African American (n = 30)‡	Men (n = 47)	Women (n = 43)	All Subjects (n = 90)
Mean age, y	28.9 ± 8.4	25.6 ± 9.9	25.7 ± 6.3	30.0 ± 10.9	27.8 ± 9.0
Mean axial length OD, mm	24.4 ± 1.3	24.3 ± 0.9	24.7 ± 1.3§	24.0 ± 1.0	24.4 ± 1.2
Mean axial length OS, mm	24.4 ± 1.4	24.2 ± 0.9	24.7 ± 1.4§	24.0 ± 1.0	24.3 ± 1.3

\* All values are mean ± 1 SD.

† 32 men and 28 women.

‡ 15 men and 15 women.

§ Significant difference between the sexes in axial length;  $t_{88} = 2.86$ ,  $P = 0.0054$ , OD;  $t_{88} = 2.72$ ,  $P = 0.0081$ , OS (unpaired *t*-test, Welch corrected).

correction. In addition, the polarization setting was optimized using the built-in function for each eye. Scan quality (automatically determined by system software) averaged  $9.58 \pm 0.75$  ( $\pm 1$  SD), with 70% of our scans having an image quality of 10 (the highest quality) and only 6 of 180 scans having an image quality lower than 8. Retinal thickness was calculated using the built-in macular analysis software of the Cirrus (ver. 5.0), which is automatically determined by taking the difference between the ILM and RPE boundaries (Supplementary Fig. S1, <http://www.iovs.org/lookup/suppl/doi:10.1167/iovs.10-5886/-/DCSupplemental>).<sup>15</sup> Individual volume scans were manually examined for segmentation errors, and there was no evidence of segmentation error in any of the scans. No subject was excluded from the subsequent analysis for any reason.

To obtain more accurate *absolute* measures of foveal pit morphology, we corrected the lateral scale of all OCT data sets for interindividual differences in axial length. Axial length measurements were obtained with an ocular biometer (IOLMaster; Carl Zeiss Meditec). To derive the actual scan lengths, we multiplied 6 mm (the nominal scan length) times the ratio of the subject's actual axial length to that assumed by the system (24.46 mm). Axial lengths in our subjects ranged from 21.56 to 28.36 mm; thus, actual macular scan lengths ranged from 5.29 to 6.96 mm. As shown in Table 2, there was a significant difference in axial length between the men and women, which is consistent with some previous reports.<sup>19,20</sup>

The location of the fovea within each volume scan was identified automatically with the built-in fovea-finder algorithm of the Cirrus (ver. 5.0). The position of the foveal center and the retinal thickness data from the volume scans were exported for offline analysis (Cirrus Research Browser, ver. 5.0; Carl Zeiss Meditec). Custom software written in a commercial program (MatLab; The MathWorks, Natick, MA) was used to generate revised Early Treatment Diabetic Retinopathy Study (ETDRS) thickness maps, incorporating the actual scan length information and retinal thickness data for each subject. These ETDRS maps consisted of a central 1-mm diameter inner ring, a 3-mm diameter inner ring divided into four quadrants, and a 6-mm diameter outer ring divided into four quadrants. The ETDRS thickness maps used for analysis were aligned with the foveal center, not necessarily the center of the volume.

### Measuring Foveal Pit Morphology

Foveal pit morphology was assessed based on a previously published MatLab algorithm.<sup>17</sup> From the retinal thickness data, six radially oriented slices through the foveal center were extracted (Supplementary Fig. S2, <http://www.iovs.org/lookup/suppl/doi:10.1167/iovs.10-5886/-/DCSupplemental>). These slices were taken at 30° intervals, mimicking the six scans obtained with the time-domain macular scan protocol (Stratus; Carl Zeiss Meditec). However, the advantage was that all six "scans" were centered on exactly the same point in the retina (the foveal center, determined using the built-in fovea-finder algorithm). Each of the six retinal thickness profiles was then fit to a difference of Gaussians (DoG) equation, and the six values were averaged to generate a single estimate of depth, diameter, and slope for each eye. We have shown previously that a DoG function provides a

good fit to the retinal thickness data.<sup>17</sup> The average RMS deviation for a given extracted slice was  $11.57 \mu\text{m}$ , with an SD of  $4.48 \mu\text{m}$ . By inspection, the fits were generally quite good (Supplementary Fig. S2, <http://www.iovs.org/lookup/suppl/doi:10.1167/iovs.10-5886/-/DCSupplemental>); when there was deviation, it was confined to the periphery beyond the rims of the foveal pit. This result is expected, as the equation is designed to capture the rim-to-rim contour and not that of the peripheral macula. Using the first derivative of this equation, which identifies information about the changing slope of the foveal contour, we automatically extracted foveal pit depth, diameter, and slope.<sup>17</sup> The reported result for each individual is an average of the six scans. The center of the foveal pit is easily identified by the central retinal location where slope transitions from negative to positive. On either side of this foveal center, we identified the rim of the foveal pit, as it also has a zero slope. Diameter was taken as the lateral rim-to-rim distance, depth was taken as the axial distance between a plane connecting the foveal rims and the bottom of the foveal pit, and pit slope was taken as the maximum value of the slope between the foveal center and the foveal rim.

### Assessing Reproducibility

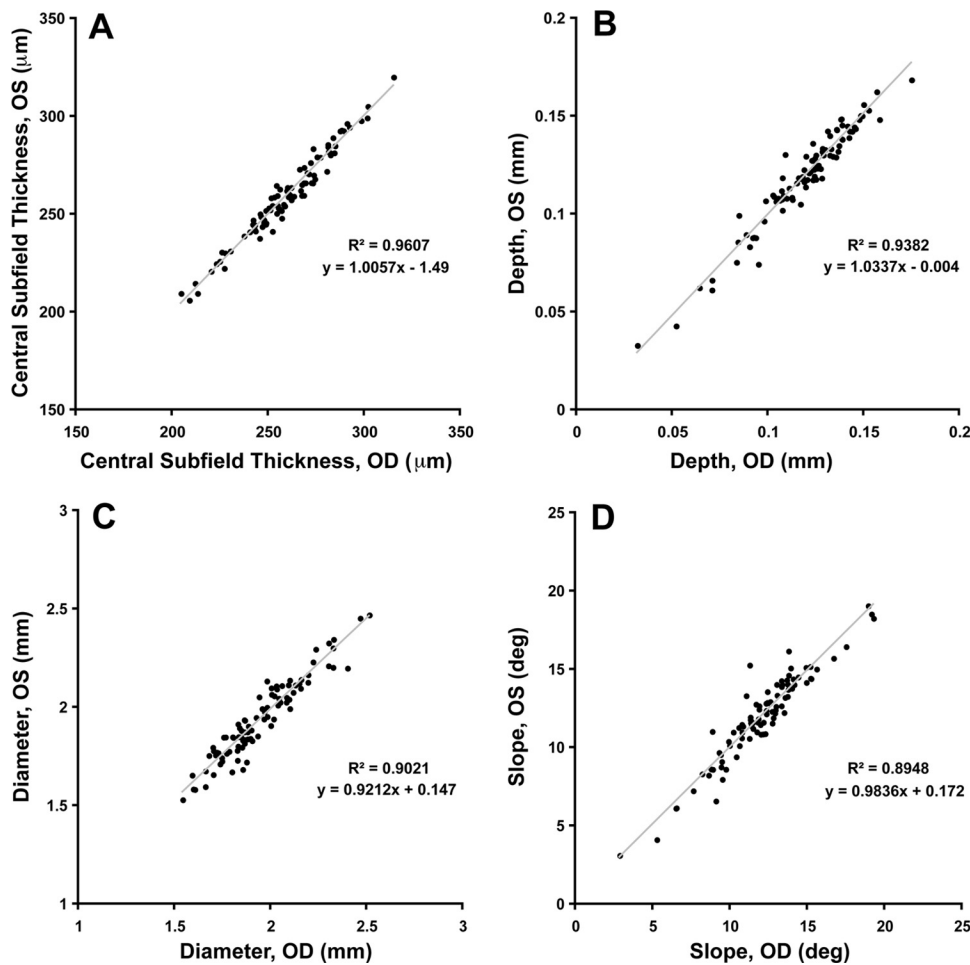
The reproducibility of retinal thickness of SD-OCT has already been assessed,<sup>21-23</sup> and thus we were interested specifically in evaluating the reproducibility of our foveal pit measurements. To assess intersession reproducibility, we imaged 23 individuals at two different time points, where the average separation between imaging sessions was 345 days (range, 195-706 days). Test-retest reproducibility was assessed by paired *t*-test. To assess intrasession reproducibility, we imaged the same 23 individuals 10 times within a single scanning session. This provides an estimate of the measurement error inherent in our measurement procedure, which includes device error, errors from eye movements or other variation in the subject, and fitting error. The coefficient of repeatability (CR), also known as the coefficient of variation, was calculated based on the within-subject variance, found by measuring the observed variance ( $\sqrt{\text{SD}}$  of the 10 measurements) in each subject and then averaging these values across the 23 subjects.<sup>24</sup> The within-subject SD ( $S_w$ ) is the square root of the within-subject variation, and CR is equal to the within-subject SD ( $S_w$ ) times 2.77.<sup>24,25</sup> The 95% confidence interval (CI) for CR is  $1.96\{S_w / \sqrt{[2n(m - 1)]}\}$ , where  $n$  is the number of subjects and  $m$  is the number of observations for each subject.<sup>25</sup> CR is reported both in terms of the measurement unit and as a percentage of the mean.

## RESULTS

### Interocular Symmetry in Macular Thickness and Foveal Pit Morphology

Previous studies have found a high degree of interocular symmetry in retinal thickness.<sup>26,27</sup> We also observed significant interocular symmetry in central subfield thickness (Fig. 1A; Pearson  $r = 0.98$ ;  $P < 0.0001$ ). Similarly, significant symmetry in retinal thickness of the other eight ETDRS segments was





**FIGURE 1.** Assessment of interocular symmetry in retinal thickness and pit morphology. There was a significant interocular correlation in ETDRS central subfield thickness (A), as in the other eight ETDRS segments (data not shown). Foveal pit morphology was calculated with a DoG fitting to determine foveal pit depth diameter and maximum slope. As with retinal thickness, the pit morphology metrics, foveal pit depth (B), diameter (C), and maximum slope (D) showed significant interocular symmetry. *Gray lines:* linear regression slope.

observed (data not shown, all  $P < 0.0001$ ). We observed significant interocular symmetry in foveal pit depth (Fig. 1B), diameter (Fig. 1C), and slope (Fig. 1D) (Pearson  $r = 0.97, 0.95$ , and  $0.94$  for depth, diameter, and slope, respectively;  $P < 0.0001$ ). In all correlations, the slope was close to 1. Thus, for all subsequent analyses, we used only the right eye from each subject. Of note is that our foveal pit metrics are all based on data that were corrected for individual differences in axial length. Not making this correction does not affect measurements of pit depth; however, it does significantly alter estimates of pit diameter and slope. The magnitude of the error varies as a function of axial length; the farther away from 24.46 mm the subject's axial length is, the larger the discrepancy in diameter and slope estimates will be (Fig. 2). For example, in our subjects, the largest error in estimating diameter was 0.23 mm (for a subject who had a 21.94 mm axial length). This represents nearly a 12% error in the diameter estimate for this individual. Slope estimates deviated by as much as 13% when not using the subjects' axial length information. Thus, we conclude that to obtain accurate measurements of foveal pit morphology from OCT data, one must incorporate an axial length correction.

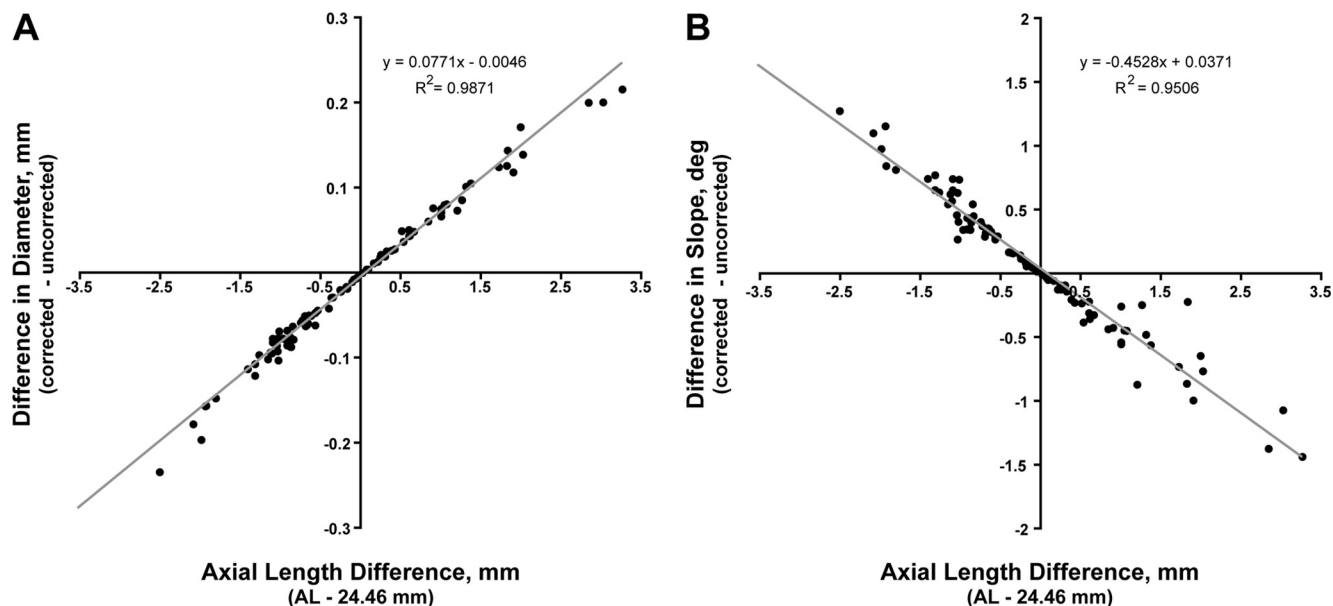
### Reliability and Reproducibility of Foveal Pit Measurements

As the reported values for foveal morphology derive from an average of six slices through the foveal center, we examined the within-subject variability of each parameter by calculating the SD of each of the parameters derived from each of the six scans. We observed good agreement across the six scans,

indicating stable fixation during acquisition and accurate centering of the volume on the foveal center by the built-in fovea-finder algorithm. The average SD for foveal depth was 0.005 mm, the average SD for foveal diameter was 0.088 mm, and the average SD for foveal slope was  $0.794^\circ$ . We suspect that foveal slope was slightly more variable, since we report the absolute maximum foveal slope, rather than averaging it over a distance along the sides of the foveal contour. Nevertheless, any one of the six radial slices provides a good estimate of the radial foveal contour. However, there can be asymmetry in the foveal contour, and so averaging the six values serves to reduce the noise in the estimates for a given subject.

Intersession reproducibility of our foveal pit measurements was assessed in 23 of the subjects. Two scans were taken, separated by an average of 345 days (Table 3). There was no significant difference between foveal parameters from the two sessions, determined with a paired  $t$ -test. The average difference in pit depth was  $-0.001$  mm ( $t_{22} = 0.944$ ,  $P = 0.36$ ), the average difference in pit diameter was 0.014 mm ( $t_{22} = 1.28$ ,  $P = 0.21$ ), and the average difference in pit slope was  $-0.186^\circ$  ( $t_{22} = 1.80$ ,  $P = 0.085$ ).

Intrasession reproducibility was assessed by acquiring 10 macular volumes within a single imaging session for the same subset of 23 subjects. The CR values ( $2.77 \times S_D$ ) for foveal pit metrics showed good reproducibility. The CR was  $5.12 \mu\text{m}$  for foveal depth (95% CI, 5.03–5.21  $\mu\text{m}$ ), 0.075 mm for foveal diameter (95% CI, 0.074–0.076 mm), and  $0.885^\circ$  for foveal slope (95% CI,  $0.869$ – $0.901^\circ$ ). When expressed as a percentage, the CR was 4.43% for foveal depth (95% CI, 4.35–4.51), 3.98% for foveal diameter (95% CI, 3.91–4.05), and 7.39% for



**FIGURE 2.** Effect of correcting the lateral dimension of SD-OCT scans on estimates of foveal diameter (A) and slope (B). The right eyes of all 90 subjects were analyzed with a nominal scan length of 6 mm, which assumes an axial length of 24.46 mm. These data were then compared to the values obtained when the lateral scale of the scan was corrected for individual differences in axial length. Along the x-axis in both plots, positive values reflect individuals with axial lengths longer than 24.46 mm, whereas negative values reflect individuals with axial lengths shorter than 24.46 mm. As axial length increased, the estimate of diameter also increased (Pearson,  $r = 0.9935$ ), whereas slopes decreased (Pearson  $r = -0.9750$ ). In both plots, the correlation was significant ( $P < 0.0001$ ). These errors can be as much as 12% or 13% of the actual diameter or slope, respectively.

foveal slope (95% CI, 7.25-7.52). The CR for retinal thickness measurements was comparable to previously reported values,<sup>23</sup> ranging from 1.4% to 2.3%. Complete intrasession repeatability data for retinal thickness are given in Table 4.

**Race- and Sex-Related Differences**

**Retinal Thickness.** The mean retinal thickness ( $\pm 1$  SD) in each ETDRS subfield is shown in Figure 3. We found that the men

had greater retinal thickness than the women (Fig. 3A). Differences were assessed for significance by one-tailed *t*-test: central subfield thickness ( $t_{88} = 2.43, P = 0.0086$ ), temporal inner ( $t_{88} = 2.52, P = 0.0069$ ), superior inner ( $t_{88} = 1.85, P = 0.034$ ), nasal inner ( $t_{88} = 2.42, P = 0.0087$ ), inferior inner ( $t_{88} = 2.72, P = 0.0039$ ), temporal outer ( $t_{88} = 2.64, P = 0.0048$ ), superior outer ( $t_{88} = 0.749, P = 0.23$ ), nasal outer ( $t_{88} = 1.24, P = 0.11$ ), and inferior outer ( $t_{88} = 2.30, P = 0.012$ ).

**TABLE 3.** Intersession Variability of Foveal Pit Morphology Measurements

Subject	Foveal Depth (mm)			Foveal Diameter (mm)			Foveal Slope (deg)			Interval between Scans (d)
	Scan 1	Scan 2	Difference	Scan 1	Scan 2	Difference	Scan 1	Scan 2	Difference	
1	0.124	0.120	0.005	1.879	1.887	-0.008	12.694	12.088	0.605	463
2	0.093	0.097	-0.004	1.660	1.733	-0.073	10.532	10.385	0.147	210
3	0.062	0.064	-0.002	1.853	1.855	-0.002	6.496	6.649	-0.153	699
4	0.139	0.138	0.000	1.968	1.942	0.026	13.720	13.879	-0.160	345
5	0.034	0.030	0.005	2.129	2.074	0.055	3.028	2.877	0.150	365
6	0.105	0.116	-0.011	1.826	1.764	0.062	11.306	13.096	-1.790	229
7	0.152	0.152	0.000	1.769	1.728	0.040	16.977	17.217	-0.240	673
8	0.104	0.104	0.000	1.590	1.519	0.071	12.898	13.521	-0.623	427
9	0.140	0.140	0.000	1.751	1.762	-0.011	15.254	15.218	0.037	208
10	0.136	0.133	0.003	2.194	2.101	0.093	11.875	12.167	-0.292	212
11	0.107	0.110	-0.003	1.925	1.945	-0.021	10.763	10.995	-0.232	209
12	0.088	0.091	-0.002	1.994	1.958	0.036	8.419	8.822	-0.403	210
13	0.128	0.136	-0.008	2.082	2.133	-0.051	12.402	12.690	-0.288	228
14	0.108	0.106	0.002	1.805	1.783	0.022	11.484	11.467	0.017	195
15	0.122	0.123	-0.001	1.941	1.919	0.022	12.178	12.423	-0.245	238
16	0.125	0.125	0.000	1.765	1.868	-0.103	13.718	12.936	0.782	228
17	0.105	0.105	0.000	1.935	1.920	0.015	10.779	10.843	-0.064	695
18	0.134	0.132	0.002	2.032	2.040	-0.009	12.794	12.576	0.218	229
19	0.140	0.137	0.004	1.935	1.802	0.133	14.728	15.241	-0.513	706
20	0.124	0.128	-0.004	1.748	1.734	0.014	13.574	14.291	-0.717	218
21	0.157	0.153	0.004	2.517	2.487	0.030	11.842	11.759	0.083	213
22	0.067	0.069	-0.002	1.758	1.807	-0.049	7.329	7.463	-0.134	517
23	0.115	0.117	-0.002	1.661	1.630	0.031	13.327	13.785	-0.458	228
Average	0.114	0.114	-0.001	1.901	1.886	0.014	11.657	11.843	-0.186	345

TABLE 4. Intrasection Repeatability of Retinal Thickness Measurements

ETDRS Segment*	CR ( $\mu\text{m}$ )	95% CI ( $\mu\text{m}$ )	CR (%)†	95% CI (%)
Central 1 mm	4.96	4.88–5.05	1.88	1.85–1.92
Nasal inner	4.75	4.67–5.84	1.45	1.43–1.48
Superior inner	6.28	6.17–6.39	1.94	1.90–1.97
Temporal inner	4.80	4.71–4.88	1.54	1.51–1.56
Inferior inner	5.54	5.44–5.64	1.73	1.70–1.76
Nasal outer	4.01	3.94–4.08	1.35	1.33–1.37
Superior outer	6.37	6.26–6.49	2.29	2.25–2.33
Temporal outer	4.50	4.42–4.58	1.73	1.70–1.76
Inferior outer	5.26	5.17–5.35	1.96	1.92–1.99

\* CR values calculated from 10 repeated measures.

† Expressed as a percentage of the mean value for that respective ETDRS segment.

We observed differences between the races in macular thicknesses, with the African/African American group having a significantly reduced central subfield thickness compared with the Caucasian group (Fig. 3B). However, in contrast to the differences between the sexes, no significant racial differences in retinal thickness were observed in any of the other ETDRS segments. Differences were assessed for significance by one-tailed *t*-test: central subfield thickness ( $t_{88} = 4.85$ ,  $P < 0.0001$ ), temporal inner ( $t_{88} = 1.07$ ,  $P = 0.14$ ), superior inner ( $t_{88} = 0.341$ ,  $P = 0.37$ ), nasal inner ( $t_{88} = 1.58$ ,  $P = 0.059$ ), inferior inner ( $t_{88} = 0.771$ ,  $P = 0.22$ ), temporal outer ( $t_{88} = 0.919$ ,  $P = 0.18$ ), superior outer ( $t_{88} = 1.22$ ,  $P = 0.11$ ), nasal outer ( $t_{88} = 0.496$ ,  $P = 0.31$ ), and inferior outer ( $t_{88} = 0.167$ ,  $P = 0.43$ ).

**Foveal Pit Morphology.** Sex-associated differences in foveal pit morphology are shown in Figure 4, and these were assessed for significance by two-tailed *t*-test. The average foveal pit depth ( $\pm 1$  SD) was  $0.120 \pm 0.027$  mm in the men and  $0.119 \pm 0.019$  mm in the women, and there was no significant difference between the two groups ( $t_{88} = 0.22$ ,  $P = 0.82$ ). Average foveal pit diameter ( $\pm 1$  SD) was  $1.93 \pm 0.22$  mm in the men and  $1.96 \pm 0.19$  mm in the women, and there was no significant difference between the two groups ( $t_{88} = 0.89$ ,  $P = 0.38$ ). Finally, the average maximum slope of the foveal pit ( $\pm 1$  SD) was  $12.2 \pm 3.2^\circ$  in the men and  $11.8 \pm 2.2^\circ$  in the women, and there was no significant difference between the two groups ( $t_{88} = 0.70$ ,  $P = 0.49$ ).

When comparing the Caucasian and African/African American groups, we found significant differences in pit morphology (Fig. 5), assessed for significance using a two-tail *t*-test. The average foveal pit depth ( $\pm 1$  SD) was  $0.114 \pm 0.025$  mm in the Caucasian group and  $0.129 \pm 0.019$  mm in the African/African American group, and this difference was significant ( $t_{88} = 2.83$ ,  $P = 0.0058$ ). Average foveal pit diameter ( $\pm 1$  SD) was  $1.88 \pm 0.16$  mm in the Caucasian group and  $2.07 \pm 0.22$  mm in the African/African American group, and this difference was also significant ( $t_{88} = 4.69$ ,  $P < 0.0001$ ). Finally, the average maximum slope of the foveal pit ( $\pm 1$  SD) was  $11.9 \pm 2.9^\circ$  in the Caucasian group and  $12.3 \pm 2.3^\circ$  in the African/African American group, and there was no significant difference between the two groups ( $t_{88} = 0.61$ ,  $P = 0.54$ ).

Initially, one might expect that, as the populations have significantly different depths and diameters, slope would also be different. However, the absence of a difference in slope between the groups is expected from the geometrical relationship between the parameters, and our data support this prediction. Analysis of the entire data set showed a positive correlation between foveal pit depth and pit slope (as depth increases, so does the maximum slope) and a negative corre-

lation between diameter and maximum slope (as diameter increases, maximum slope decreases), data not shown. Thus, the increased depth and diameter in the African and African American group cancel each other out with respect to their effect on maximum slope.

## DISCUSSION

### Comparison with Previous Results

The racial differences in retinal thickness reported herein are consistent with previous findings using OCT.<sup>9,10,12</sup> In addition, previous studies have shown that women have reduced retinal thickness than do men,<sup>7,9,12,13</sup> and our results are in agreement with this. In contrast, two recent studies using SD-OCT reported no significant difference in retinal thickness between men and women.<sup>10,11</sup> However, inspection of the observed differences in both studies showed a difference of similar magnitude between the sexes as observed by us and others (8–20  $\mu\text{m}$ ). Sull et al.<sup>11</sup> examined 21 men and 19 women, and Grover et al.<sup>10</sup> examined 26 men and 24 women. A simple calculation assuming a difference of 14  $\mu\text{m}$  and an SD of 22  $\mu\text{m}$  indicates that, to detect such a difference at the 0.05 significance level, one would require approximately 40 subjects in each group. Thus, we believe that the lack of an observed sex-related difference in these two studies is due to an insufficient sample size. This, combining our data with findings in the numerous other studies that have shown a sex-associated difference leads us to conclude that there is indeed a sex-related difference in retinal thickness.

While there are no data stemming from examination of sex- or race-based differences in foveal pit depth, there have been two other reports of calculation of foveal pit depth measured by SD-OCT imaging. Using an adaptive optics SD-OCT system, Hammer et al.<sup>28</sup> examined five normal control subjects and

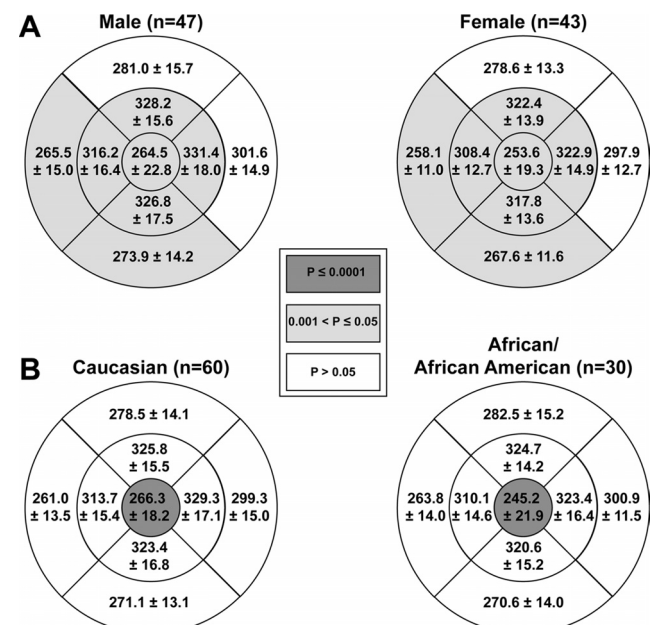


FIGURE 3. Mean ETDRS retinal thickness maps showing (A) sex and (B) race-related differences. To account for individual differences in axial length, the lateral scale of the individual thickness maps were scaled before averaging. The values within each ETDRS subfield represent the mean  $\pm 1$  SD. Shaded subfields indicate those in which there was a significant difference in thickness between the male and female groups (A) or the Caucasian and African/African American groups (B). See text for individual *P* values (one-tailed *t*-test).

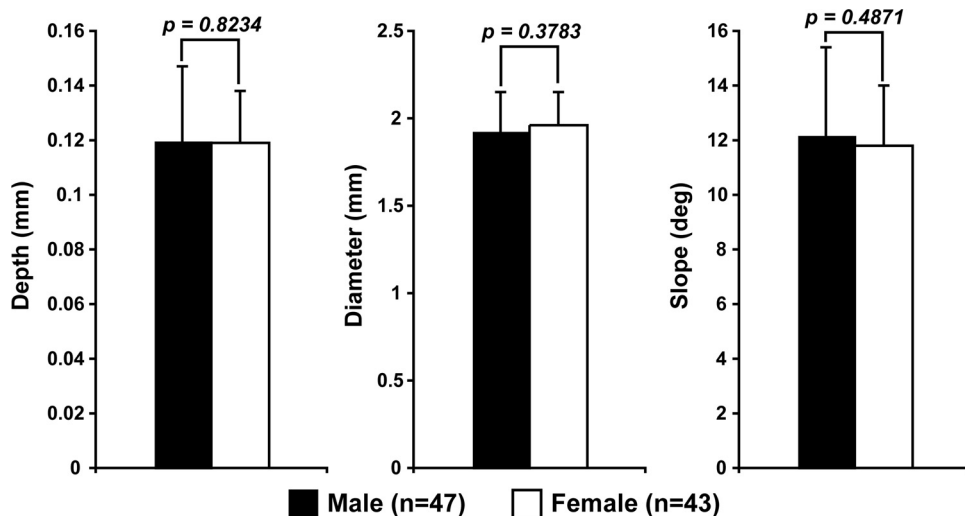


FIGURE 4. Foveal pit morphology did not differ between the male and female groups. Bars represent the mean  $\pm$  1 SD. There was no significant sex-related difference between average foveal pit depth, diameter, or maximum slope.

found a mean ( $\pm$ SE) foveal pit depth of  $121 \pm 4.3 \mu\text{m}$ . They defined pit depth as the distance from the base of the pit to an arbitrarily chosen point where the pit reached a radius of  $728 \mu\text{m}$ . Chui et al. (*IOVS* 2009;50:ARVO E-Abstract 1108) used SD-OCT (Spectralis; Heidelberg Engineering, Heidelberg, Germany) to image eight normal emmetropic eyes. They fit an eighth-order polynomial equation to the foveal contour to extract foveal pit depth and reported a mean ( $\pm$ SD) depth of  $137.56 \pm 15.53 \mu\text{m}$ . As the findings in both studies are generally consistent with ours and we have shown our method to be highly reproducible, we conclude that our DoG-fitting procedure provides an accurate in vivo picture of foveal pit morphology.

There have been reports on the effect of race and sex on foveal pit diameter. With respect to sex, Delori et al.<sup>29</sup> used fundus reflectometry to estimate the diameter of the foveal depression in 18 subjects, and they found that women had a significantly larger radius of foveal reflex than men had ( $0.27^\circ \pm 0.07^\circ$  versus  $0.16^\circ \pm 0.04^\circ$ ). They interpreted this to mean that women have a “flatter foveal floor and/or broader foveal depression,” which contradicts our findings. A difficulty in using the foveal reflex is that it is confounded by differences in axial length, although they applied a correction based on the refractive error of the subject. However, as men have been shown to have longer axial lengths than women,<sup>19,20</sup> this correction would serve to underestimate the radius of curva-

ture of the ILM surface in men compared with women. A direct comparison of fundus reflectometry and OCT in the same cohort of subjects is needed to clarify the relationship between these two techniques and to shed light on the difference between our study and that of Delori et al.<sup>29</sup> Nolan et al.<sup>30</sup> used time-domain OCT to examine foveal width and found no significant difference between the sexes in a sample of 59 subjects. In fact, of their two techniques for measuring foveal width, one showed women to have slightly larger diameters, while the other showed men to have larger diameters. These data, taken together with our findings, support our conclusion that there is no sex-related difference in foveal pit diameter.

Consistent with our findings, in examining racial differences in foveal morphology, Nolan et al.<sup>30</sup> reported that white subjects had significantly narrower foveal width measurements than did nonwhite subjects ( $P < 0.05$ ). However they observed about a  $100\text{-}\mu\text{m}$  difference in foveal diameter between whites and nonwhites, which is half the magnitude of the difference we report here. The most likely explanation of the discrepancy is the mixed ethnic makeup of their nonwhite group (five Indian, six Asian, three Hispanic/Spanish, and four black), whereas we were examining exclusively Africans and African Americans. Across all their subjects, the absolute value of foveal diameter reported by Nolan et al. ranged from 0.63 to 1.67 mm across, while ours ranged from 1.54 to 2.51 mm in our 90 subjects. It is not surprising that our estimates, which

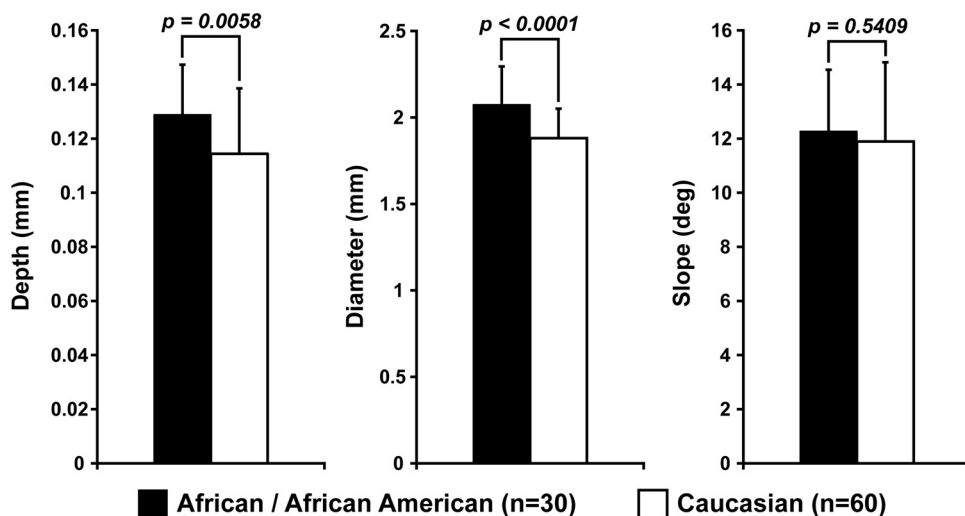


FIGURE 5. Foveal pit morphology shows significant differences between the Caucasian and African/African American groups. Bars represent the mean  $\pm$  1 SD. The African/African American group had significantly deeper and wider foveal pits than did the Caucasians. There was no significant difference in maximum slope between the two groups, which is explained by the simple geometric relationship between these three parameters.

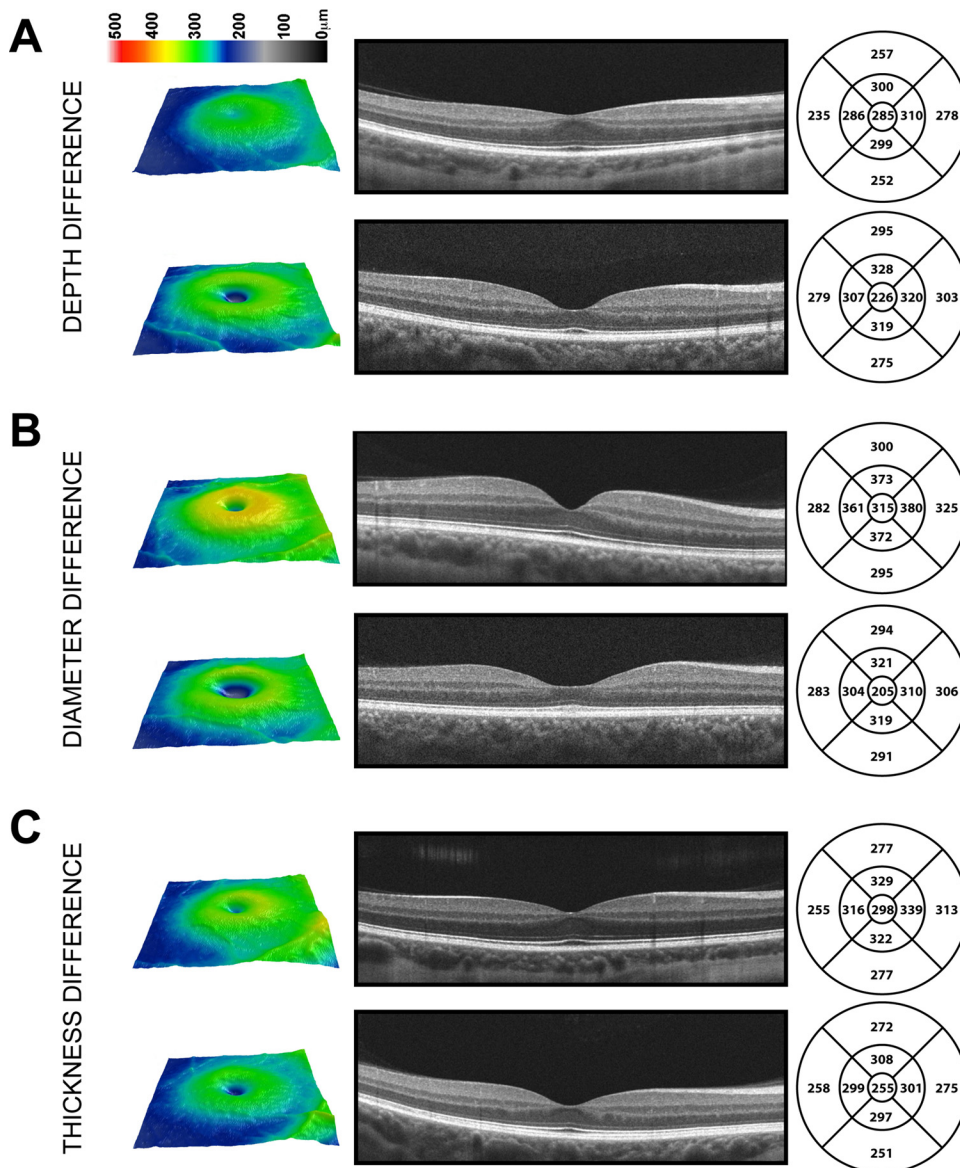


are based on the rim-to-rim diameter are larger than those reported by Nolan et al., which are based on caliper measurements from peak foveal crest-to-crest and from each side where the nerve fiber layer is absent. It is worth noting that the range of values is of the same magnitude ( $\sim 1$  mm) between the two studies, supporting the idea that the different measurement techniques introduce simply a static offset between the data sets. Closer to our values, Chui et al. (*IOVS* 2009;50:ARVO E-Abstract 1108) reported an average foveal diameter of 1.74 mm, measured at the half-height of the foveal pit. The measurements reported by both Chui et al. and Nolan et al.<sup>30</sup> failed to account for individual differences in axial length. As discussed earlier, not correcting the lateral scale of the OCT scans can induce errors of up to 12% in estimates of foveal diameter; this error would be present regardless of the technique used to measure diameter. Thus, we believe that our estimates of foveal diameter are more accurate than those previously reported in the literature. It is worth noting that these errors should not affect comparisons of foveal pit diameter between different groups if both groups have similar distributions of axial length, but they would affect examinations of correlation of foveal pit diameter with other measures of retinal anatomy

or visual function. Moreover, if one wants to study pit morphology in a sample in which axial length systematically deviates in one direction from the assumed value of the instrument (i.e., myopia), it will not only introduce substantial errors in the absolute values obtained, but will also preclude meaningful comparison of this group against a group that has a significantly different axial length distribution (i.e., emmetropia).

### Maps of Retinal Thickness Are Confounded by Changes in Foveal Pit Morphology

We have shown that significant differences in retinal thickness can exist both in the presence and absence of significant differences in foveal pit morphology. Thus, differences in retinal thickness, specifically the central subfield thickness, should be interpreted with caution. A finding that an individual has a thinner central subfield thickness than another individual tells nothing about whether there is any corresponding difference in foveal morphology. To illustrate this point, Figure 6 shows SD-OCT data from three pairs of individuals; in all cases, one individual has a thinner central subfield thickness than the other. In the first pair (Fig. 6A), the difference in thickness can



**FIGURE 6.** Multiple routes to generating differences in ETDRS thickness maps. *Left:* topographic macular thickness maps from the Cirrus HD-OCT (Carl Zeiss Meditec, Dublin, CA) for six different individuals. *Middle:* single image taken through the center of fixation. *Right:* ETDRS subfield thickness maps (corrected for individual differences in axial length). The retinas in (A) have the same foveal pit diameter, but the one on the bottom has a deeper foveal pit, which results in a reduced central subfield thickness. The retinas in (B) have the same foveal pit depth, but the one on the bottom has a wider foveal pit, which also results in a reduced central subfield thickness. Finally, the retinas in (C) have the same foveal pit depth and diameter, but the one on the bottom still has a thinner central subfield thickness (indicating a “real” difference in retinal thickness between these two subjects). These data illustrate the confound between differences in foveal pit morphology and true differences in retinal thickness.



be accounted for by a difference in foveal pit depth. In the second pair (Fig. 6B), the difference can be accounted for by a difference in foveal pit diameter. In the third pair (Fig. 6C), the individuals had nearly identical foveal pit depth and diameter; thus, the difference in central subfield thickness can be thought to represent a “true” difference in retinal thickness. Considering this confound, the results of our study indicate that sex-related differences in retinal thickness represent real differences in thickness, whereas race-associated differences are more likely due to differences in foveal pit morphology. The previous literature had hinted at such a relationship, in that sex-based differences tended to include multiple ETDRS segments, while race-related differences were largely confined to the central subfield.<sup>9,11</sup> Indeed, the differences between the sexes in our group were found in six of nine ETDRS segments, whereas the differences between the races were observed only in the central subfield.

The impact of these findings is significant. Many studies use retinal thickness as measured with OCT to evaluate treatment results for diseases such as diabetic retinopathy. In such studies, the same retinal thickness values are used across the patient populations as a metric for study inclusion and/or treatment evaluation.<sup>31–33</sup> Given the significant differences in retinal thickness (either real or induced by variation in foveal pit morphology), it is worth asking whether the same minimum foveal subfield thickness should be used as an inclusion criterion for all potential study subjects or whether race- and sex-specific databases should be applied. Even within a given race or sex, there is substantial variability in foveal morphology, which could easily be adopted as an additional metric in normative databases to assist with the interpretation of retinal thickness measurements. Until the origin or significance of such variation is understood, it should be kept in mind when interpreting any OCT dataset.

### Consequences of Variation in Foveal Pit Morphology

Further investigations into the mechanisms underlying the differences in foveal pit morphology are needed to understand the consequences of these differences and how they might relate to variability in the incidence of retinal disease. However, we pose the following question: All other things being equal, which of the retinas in Figure 6A is more susceptible to the development of AMD? While environmental<sup>34</sup> and genetic<sup>35,36</sup> risk factors for AMD have been well studied, relatively little attention has been paid to possible anatomic risk factors. Although AMD selectively affects the macula, it remains unclear why the macula shows such a strong predilection for the disease. As such, the anatomic specializations associated with the macula should be evaluated for a possible role in setting the stage for susceptibility to AMD—for it is this anatomy on which genetic and environmental factors must act. It has been suggested that increased macular pigment in the Henle fiber layer is protective against oxidative stress.<sup>37,38</sup> A second anatomic feature linked to reduced incidence of AMD is increased melanin. Increased melanin in either the RPE<sup>3,39</sup> or the choroid<sup>40</sup> may have direct protective effects against oxidative stress. A third anatomic feature proposed to be associated with AMD is the elastic lamina of Bruch’s membrane, which has been shown to be selectively more porous and thinner in the macula in all retinas examined and selectively disrupted in retinas diagnosed with AMD.<sup>41</sup> Our data provide a fourth anatomic factor to consider: foveal pit morphology. While the morphology of the foveal pit itself may not be directly linked, it may be associated with other factors, such as differences in foveal cone packing, Henle fiber layer distribution, or RPE/Bruch’s membrane integrity, that could play a direct role in the disease.

Finally, given the significant sex- and/or race-based differences in many retinal conditions (including AMD),<sup>2–5,42</sup> it seems that reconsidering the general role of anatomy in susceptibility to retinal disease would be worthwhile.

### Acknowledgments

The authors thank Kimberly E. Stepien and Phyllis M. Summerfelt, for technical assistance, and Janice M. Burke and Thomas B. Connor, Jr, for helpful discussion.

### References

- Huang D, Swanson EA, Lin CP, et al. Optical coherence tomography. *Science*. 1991;254:1178–1181.
- Saunders RA, Donahue ML, Christmann LM, et al. Racial variation in retinopathy of prematurity. The Cryotherapy for Retinopathy of Prematurity Cooperative Group. *Arch Ophthalmol*. 1997;115:604–608.
- Chang MA, Bressler SB, Munoz B, West SK. Racial differences and other risk factors for incidence and progression of age-related macular degeneration: Salisbury Eye Evaluation (SEE) Project. *Invest Ophthalmol Vis Sci*. 2008;49:2395–2402.
- Klein R, Klein BE, Knudtson MD, et al. Prevalence of age-related macular degeneration in 4 racial/ethnic groups in the multi-ethnic study of atherosclerosis. *Ophthalmology*. 2006;113:373–380.
- Friedman DS, Wolfs RC, O’Colmain BJ, et al. Prevalence of open-angle glaucoma among adults in the United States. *Arch Ophthalmol*. 2004;122:532–538.
- Asrani S, Zou S, d’Anna S, Vitale S, Zeimer R. Noninvasive mapping of the normal retinal thickness at the posterior pole. *Ophthalmology*. 1999;106:269–273.
- Wong AC, Chan CW, Hui SP. Relationship of gender, body mass index, and axial length with central retinal thickness using optical coherence tomography. *Eye*. 2005;19:292–297.
- Asefzadeh B, Cavallerano AA, Fisch BM. Racial differences in macular thickness in healthy eyes. *Optom Vis Sci*. 2007;84:E941–E945.
- Kelty PJ, Payne JF, Trivedi RH, Kelty J, Bowie EM, Burger BM. Macular thickness assessment in healthy eyes based on ethnicity using Stratus OCT optical coherence tomography. *Invest Ophthalmol Vis Sci*. 2008;49:2668–2672.
- Grover S, Murthy RK, Brar VS, Chalam KV. Normative data for macular thickness by high-definition spectral-domain optical coherence tomography (Spectralis). *Am J Ophthalmol*. 2009;148:266–271.
- Sull AC, Vuong LN, Price LL, et al. Comparison of spectral/Fourier domain optical coherence tomography instruments for assessment of normal macular thickness. *Retina*. 2010;30:235–245.
- Kashani AH, Zimmer-Galler IE, Shah SM, et al. Retinal thickness analysis by race, gender, and age using Stratus OCT. *Am J Ophthalmol*. 2010;149:496–502 e491.
- Song WK, Lee SC, Lee ES, Kim CY, Kim SS. Macular thickness variations with sex, age, and axial length in healthy subjects: a spectral domain-optical coherence tomography study. *Invest Ophthalmol Vis Sci*. 2010;51:3913–3918.
- Leung CK, Cheung CY, Weinreb RN, et al. Comparison of macular thickness measurements between time domain and spectral domain optical coherence tomography. *Invest Ophthalmol Vis Sci*. 2008;49:4893–4897.
- Legarreta JE, Gregori G, Punjabi OS, Knighton RW, Lalwani GA, Puliafito CA. Macular thickness measurements in normal eyes using optical coherence tomography. *Ophthalmic Surg Lasers Imaging*. 2008;39:S43–S49.
- Geitzenauer W, Kiss CG, Durbin MK, et al. Comparing retinal thickness measurements from Cirrus spectral domain- and Stratus time domain-optical coherence tomography. *Retina*. 2010;30:596–606.
- Dubis AM, McAllister JT, Carroll J. Reconstructing foveal pit morphology from optical coherence tomography imaging. *Br J Ophthalmol*. 2009;93:1223–1227.
- Neitz M, Neitz J. A new mass screening test for color-vision deficiencies in children. *Color Res Appl*. 2001;26:S239–S249.

19. Miglior S, Brigatti L, Velati P, et al. Relationship between morphometric optic disc parameters, sex and axial length. *Curr Eye Res.* 1994;13:119-124.
20. Fotedar R, Wang JJ, Burlutsky G, et al. Distribution of axial length and ocular biometry measured using partial coherence laser interferometry (IOL Master) in an older white population. *Ophthalmology.* 2010;117:417-423.
21. Wolf-Schnurrbusch UE, Ceklic L, Brinkmann CK, et al. Macular thickness measurements in healthy eyes using six difference optical coherence tomography instruments. *Invest Ophthalmol Vis Sci.* 2009;50:3432-3437.
22. Pierro L, Giatsidis SM, Mantovani E, Gagliardi M. Macular thickness interoperator and intraoperator reproducibility in healthy eyes using 7 optical coherence tomography instruments. *Am J Ophthalmol.* 2010;150:138-140.e2.
23. Forooghian F, Stetson PF, Meyer SA, et al. Relationship between photoreceptor outer segment length and visual acuity in diabetic macular edema. *Retina.* 2010;30:63-70.
24. Bland JM, Altman DG. Statistics notes: measurement error. *BMJ.* 1996;313:744.
25. Patel PJ, Chen FK, Ikeji F, Tufail A. Intersession repeatability of optical coherence tomography measures of retinal thickness in early age-related macular degeneration. *Acta Ophthalmol.* Published online November 9, 2009, DOI:10.1111/j.1755-3768.2009.01761.x.
26. Huynh SC, Wang XY, Burlutsky G, Mitchell P. Symmetry of optical coherence tomography retinal measurements in young children. *Am J Ophthalmol.* 2007;143:518-520.
27. El-Ashry M, Hegde V, James P, Pagliarini S. Analysis of macular thickness in British population using optical coherence tomography (OCT): an emphasis on interocular symmetry. *Curr Eye Res.* 2008;33:693-699.
28. Hammer DX, Iftimia NV, Ferguson RD, et al. Foveal fine structure in retinopathy of prematurity: an adaptive optics Fourier domain optical coherence tomography study. *Invest Ophthalmol Vis Sci.* 2008;49:2061-2070.
29. Delori FC, Goger DG, Keilhauer C, Salvetti P, Staurengli G. Bimodal spatial distribution of macular pigment: evidence of a gender relationship. *J Opt Soc Am A.* 2006;23:521-538.
30. Nolan JM, Stringham JM, Beatty S, Snodderly DM. Spatial profile of macular pigment and its relationship to foveal architecture. *Invest Ophthalmol Vis Sci.* 2008;49:2134-2142.
31. Chew E, Strauber S, Beck R, et al. Randomized trial of peribulbar triamcinolone acetamide with and without focal photocoagulation for mild diabetic macular edema: a pilot study. *Ophthalmology.* 2007;114:1190-1196.
32. Maia OO Jr, Takahashi BS, Costa RA, Scott IU, Takahashi WY. Combined laser and intravitreal triamcinolone for proliferative diabetic retinopathy and macular edema: one-year results of a randomized clinical trial. *Am J Ophthalmol.* 2009;147:291-297.e292.
33. Lam DS, Chan CK, Mohamed S, et al. Intravitreal triamcinolone plus sequential grid laser versus triamcinolone or laser alone for treating diabetic macular edema: six-month outcomes. *Ophthalmology.* 2007;114:2162-2167.
34. Clemons TE, Milton RC, Klein R, Seddon JM, Ferris FL 3rd. Risk factors for the incidence of advanced age-related macular degeneration in the Age-Related Eye Disease Study (AREDS). AREDS report no. 19. *Ophthalmology.* 2005;112:533-539.
35. Patel N, Adewoyin T, Chong NV. Age-related macular degeneration: a perspective on genetic studies. *Eye.* 2008;22:768-776.
36. Gehrs KM, Jackson JR, Brown EN, Allikmets R, Hageman GS. Complement, age-related macular degeneration and a vision of the future. *Arch Ophthalmol.* 2010;128:349-358.
37. Snodderly DM, Auran JD, Delori FC. The macular pigment: II, spatial distribution in primate retinas. *Invest Ophthalmol Vis Sci.* 1984;25:674-685.
38. Landrum JT, Bone RA, Kilburn MD. The macular pigment: a possible role in protection from age-related macular degeneration. *Adv in Pharmacol.* 1997;38:537-556.
39. Age-Related Eye Disease Study Research Group. Risk factors associated with age-related macular degeneration: a case-control study in the age-related eye disease study. Age-Related Eye Disease Study Report Number 3. *Ophthalmology.* 2000;107:2224-2232.
40. Hu DN, Simon JD, Sarna T. Role of ocular melanin in ophthalmic physiology and pathology. *Photochem Photobiol.* 2008;84:639-644.
41. Chong NH, Keonin J, Luthert PJ, et al. Decreased thickness and integrity of the macular elastic layer of Bruch's membrane correspond to the distribution of lesions associated with age-related macular degeneration. *Am J Pathol.* 2005;166:241-251.
42. la Cour M, Friis J. Macular holes: classification, epidemiology, natural history and treatment. *Acta Ophthalmol Scand.* 2002;80:579-587.