

The challenge of the laboratory diagnosis in a confirmed congenital Zika virus syndrome in utero

A case report

Elena Sulleiro, MD^{a,b}, Marie Antoinette Frick, MD^{a,b}, Carlota Rodó, PhD^{a,b}, Mateu Espasa, MD^a, Claire Thorne, PhD^{b,c}, María Espiau, PhD^{a,b}, Andrea Martín-Nalda, MD^{a,b}, Anna Suy, PhD^{a,b}, Carlo Giaquinto, PhD^{b,d}, Susana Melendo, MD^a, Ariadna Rando, MD^a, Ana Alarcón, PhD^{b,e}, Federico Martínón-Torres, PhD^{b,f}, Tomás Pumarola, PhD^a, Pere Soler-Palacín, PhD^a, Antoni Soriano-Arandes, PhD^{a,b,*}

Abstract

Introduction: Zika virus (ZIKV) has caused one of the most challenging global infectious epidemics in recent years because of its causal association with severe microcephaly and other congenital malformations. The diagnosis of viral infections usually relies on the detection of virus proteins or genetic material in clinical samples as well as on the infected host immune responses. Serial serologic testing is required for the diagnosis of congenital infection when diagnostic molecular biology is not possible.

Patient concerns: A 2-year-old girl, born to a mother with confirmed ZIKV infection during pregnancy, with a confirmed ZIKV infection in utero, showed at birth a severe microcephaly and clinical characteristics of fetal brain disruption sequence compatible with a congenital ZIKV syndrome (CZS).

Diagnosis: ZIKV-RNA and ZIKV-IgM serological response performed at birth and during the follow-up time tested always negative. Serial serologic ZIKV-IgG tests were performed to assess the laboratory ZIKV diagnosis, ZIKV-IgG seroreversion was observed at 21 months of age. ZIKV diagnosis of this baby had to be relied on her clinical and radiological characteristics that were compatible with a CZS.

Interventions: The patient was followed-up as per protocol at approximately 1, 4, 9, 12, 18–21, and 24 months of age. Neurological, radiological, audiological, and ophthalmological assessment were performed during this period of time. Prompt rehabilitation was initiated to prevent potential adverse long-term neurological outcomes.

Outcomes: The growth of this girl showed a great restriction at 24 months of age with a weight of 8.5 kg (−2.5 z-score) and a head circumference of 40.5 cm (−4.8 z-score). She also had a great neurodevelopmental delay at the time of this report.

Conclusion: We presume that as a consequence of prenatal ZIKV infection, the fetal brain and other organs are damaged before birth through direct injury. Following this, active infection ends during intrauterine life, and as a consequence the immune system of the infant is unable to build up a consistent immune response thereafter. Further understanding of the mechanisms taking part in the pathogenesis of ZIKV congenital infection is needed. This finding might change our paradigm regarding serological response in the ZIKV congenital infection.

Abbreviations: AF = amniotic fluid, CSF = cerebrospinal fluid, CZS = Congenital ZIKV syndrome, DENV = dengue virus, HIV = Human immunodeficiency virus, IgG = immunoglobulin G antibodies, IgM = immunoglobulin M antibodies, MRI = magnetic resonance imaging, PRNT = plaque reduction neutralization test, RNA = ribonucleic acid, RT-PCR = reverse-transcriptase-polymerase-chain-reaction, TORCH = Toxoplasma gondii, rubella virus, cytomegalovirus, herpes virus I and II, and HIV, ZIKV = Zika virus.

Keywords: arboviruses, microcephaly, serologic test, syndrome, ZIKA Virus

Editor: N/A.

ES and AS-A contributed equally to this work.

Consent for publication: Informed written consent was obtained from the patient's mother for publication of this case report and accompanying images.

Funding: The publication of this manuscript has been funded by the ZIKAction consortium, European Union's Horizon 2020 research and innovation programme under grant agreement No 734857.

The authors report no conflicts of interest.

^aHospital Universitari Vall d'Hebron, Barcelona, Spain, ^bZIKAction Consortium, European Union's Horizon 2020 Research and Innovation Programme under Grant Agreement No 734857, ^cUniversity College London, London, United Kingdom, ^dUniversity of Padova, PENTA Foundation, Padova, Italy, ^eHospital Sant Joan de Déu, Esplugues de Llobregat, Barcelona, Spain, ^fHospital Clínico Universitario, Santiago de Compostela, Spain.

* Correspondence: Antoni Soriano-Arandes, Hospital Universitari Vall d'Hebron, Avinguda Drassanes, 17-21, 08001 Barcelona, Spain (e-mail: tsorianoarandes@gmail.com/asoriano@vhebron.net).

Copyright © 2019 the Author(s). Published by Wolters Kluwer Health, Inc.

This is an open access article distributed under the terms of the Creative Commons Attribution-Non Commercial License 4.0 (CCBY-NC), where it is permissible to download, share, remix, transform, and buildup the work provided it is properly cited. The work cannot be used commercially without permission from the journal.

Medicine (2019) 98:20(e15532)

Received: 9 January 2019 / Received in final form: 27 March 2019 / Accepted: 9 April 2019

<http://dx.doi.org/10.1097/MD.00000000000015532>

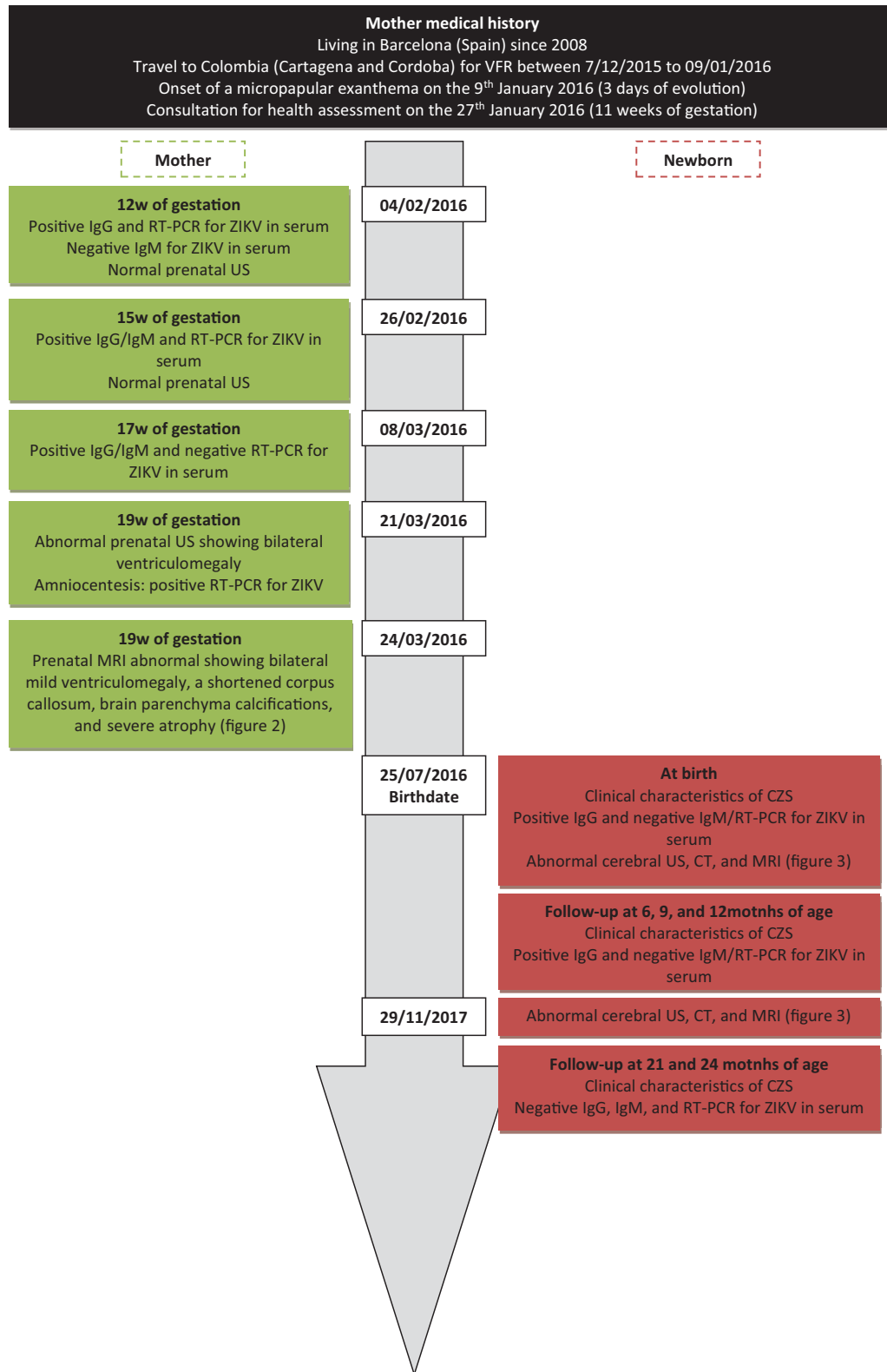


Figure 1. Case report timeline.

1. Introduction

Zika virus (ZIKV) has caused one of the most challenging global infectious epidemics in recent years, mainly because of its causal

association with severe microcephaly and other congenital malformations.^[1-4]

The diagnosis of viral infections usually relies on the detection of virus proteins or genetic material in clinical samples as well as

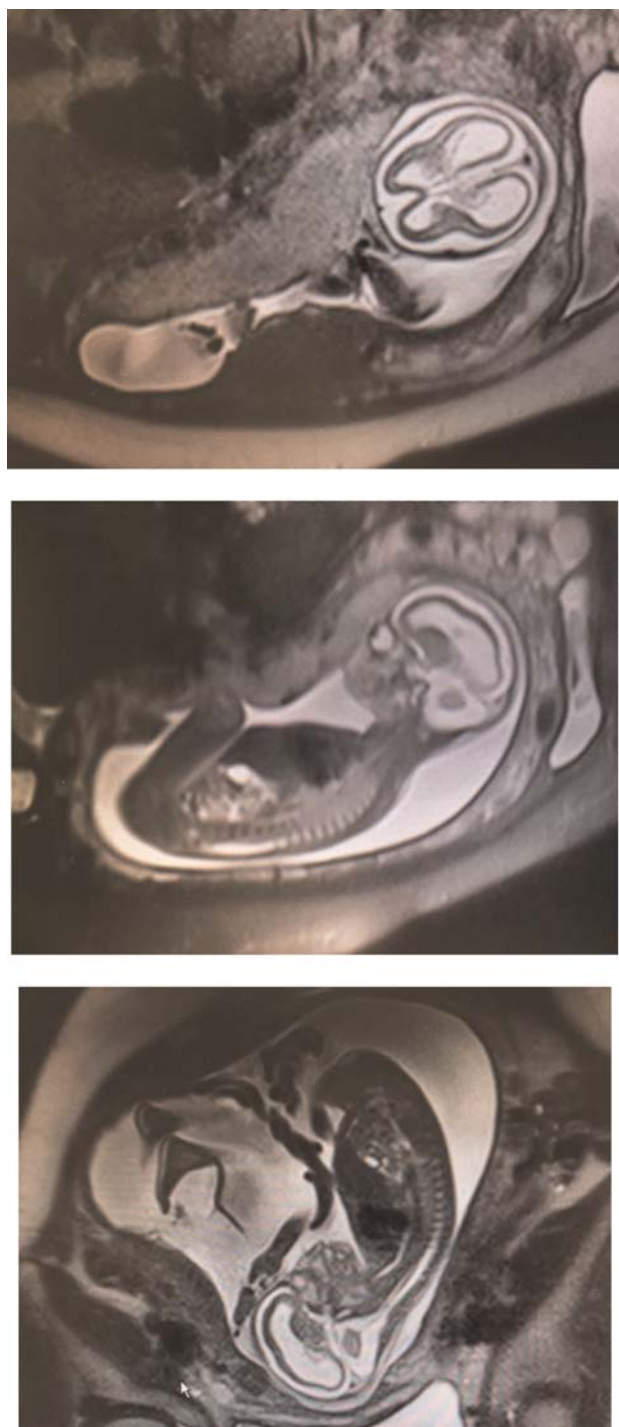


Figure 2. Fetal MRI showing bilateral mild ventriculomegaly, partial collapsed skull, and severe atrophy in the fetal brain.

the infected host's immune responses. Immunoglobulin G (IgG) antibodies cross the placenta, and serial serologic testing is required for the diagnosis of congenital infection when specific IgG is detected in the newborn. Transplacentally acquired maternal IgG usually becomes undetectable by 6 to 12 months of age, whereas infants with congenital infection show persistence of IgG antibodies. Before availability of molecular diagnosis, mother-to-child Human Immunodeficiency Virus (HIV) infection

was diagnosed based on persistence of the serological response beyond the age of 18 months.^[5] Likewise, serial serologic testing is used for the diagnosis of congenital toxoplasmosis.^[6] Seroreversion can be achieved following prompt and adequate treatment of some congenital infections (e.g., syphilis).^[7]

2. Case report

We here describe a congenital Zika syndrome (CZS) case of a 2-year-old girl born in Barcelona to a mother infected with ZIKV during pregnancy, who presented a complete seroreversion of ZIKV-IgG serological response (Fig. 1). Her mother was infected during pregnancy while on a 1-month duration visit from Spain to Colombia (her country of origin) in December 2015; she was symptomatic with fever and micro-papular exanthema at 9 weeks of gestation within 2 weeks after returning to Spain. Following the US Centers for Disease Control and Prevention (CDC) protocol,^[8] the mother was tested for ZIKV and other flaviviruses to assess the risk of fetal involvement. ZIKV infection was confirmed at 11 weeks of gestation, when she tested positive for ZIKV RNA by reverse-transcriptase-polymerase-chain-reaction (RT-PCR) assay (RealStar Zika Virus RT-PCR Kit 1.0, Altona Diagnostics) in serum, and later at 19 weeks in amniotic fluid (AF). The mother also tested positive for ZIKV-IgG (IIFT, Arboviral fever Mosaic, Euroimmun, Germany), and for ZIKV plaque reduction neutralization test (PRNT) achieving a maximum titer of 1/1024. Serological IgG response to dengue virus (DENV) tested positive, but was negative for chikungunya virus. Fetal neurosonography and magnetic resonance imaging (MRI) revealed bilateral mild ventriculomegaly, a shortened corpus callosum, brain parenchyma calcifications, and severe atrophy (Fig. 2). Genetic, *Toxoplasma gondii*, rubella virus, cytomegalovirus, herpes virus I and II, and HIV (TORCH) testing in AF with microarray-based comparative genomic hybridization (SurePrint G3 Unrestricted CGH ISCA v2 Microarray Kit, 8x60K, Agilent Technologies) and PCR were respectively normal and negative.

The infant was delivered by caesarean section at 37 weeks and one-day gestation because of suspected intrauterine growth restriction. At birth, all the RT-PCR assays of the maternal (serum, urine, AF, placenta, membranes, and umbilical cord) and neonatal samples (serum, urine, cerebrospinal fluid [CSF], and saliva) were negative for ZIKV (Table 1). In the first 24 h of life ZIKV immunoglobulin M (ZIKV-IgM) (IIFT, Arboviral fever Mosaic, Euroimmun, Germany) was negative in neonatal serum and CSF, while ZIKV-IgG was positive in both samples. At the same time, we also tested ZIKV-PRNT with a positive result (Table 1). Congenital cytomegalovirus infection was ruled out by PCR in urine.

Microcephaly (Table 1), and features of fetal brain disruption sequence^[1,2] were present at birth, including severe microcephaly, craniofacial disproportion, partially collapsed skull, prominent occiput, and excess nuchal skin. Neurological exam showed irritability, hyperexcitability, exacerbation of the primitive reflexes, inconsolable crying, and joint contractures. Postnatal ultrasonography, computed tomography and MRI studies confirmed the microcephaly with a thinned corpus callosum and brain atrophy with parenchymal calcifications (Fig. 3). Ophthalmological examination was normal. Hearing test by brainstem auditory evoked potentials was normal. Clinical and radiological features were considered compatible with CZS.^[1-3]

Table 1
Clinical and laboratory results of the Congenital Zika Syndrome case.

Age Data	Birth	6 months	9 months	12 months	21 months	24 months
Anthropometrics						
Weight (z-score)*	2,540 g (−0.8)	6390 g (−1.1)	7050 g (−1.2)	7,300 g (−1.6)	8,470 g (−1.8)	8550 g (−2.5)
Length (z-score)*	48 cm (0.4)	64 cm (−0.7)	70 cm (0.06)	73 cm (−0.2)	79 cm (−0.9)	83 cm (−0.8)
Head circumference (z-score)*	30 cm (−2.24)	35.5 cm (−5.1)	37 cm (−5.0)	38 cm (−5.0)	39.5 cm (−5.0)	40.5 cm (−4.8)
Samples						
Blood						
Hb (gr/dL)	15.9			12.5	13.6	
Hct. (%)	46			35.9	38.7	
Leukocytes (per mm ³)	15,690			9,930	7,010	
Neutrophils (per mm ³)	11,200			1,800	1,800	
Lymphocytes (per mm ³)	2,600			7,000	4,300	
Platelets (per mm ³)	252,000			411,000	419,000	
AST (U/L)	22				21	
ALT (U/L)	5				15	
Serum						
RT-PCR ZIKV	Negative		Negative	Negative	Negative	Negative
IgM-ZIKV [†]	Negative		Negative	Negative	Negative [§]	Negative
IgG-ZIKV [†]	Positive		Positive	Positive	Negative [§]	Negative
PRNT ZIKV [‡]	Positive [†]					
IgM-DENV			Negative		Negative	Negative
IgG-DENV			Positive (2.34)		Negative	Negative
IgM-CMV					Negative	
IgG-CMV					Negative	
IgM-CHKV						Negative
IgG-CHKV						Negative
Urine						
RT-PCR ZIKV	Negative					
RT-PCR CMV	Negative					
Saliva						
RT-PCR ZIKV	Negative	Negative				
CSF						
Leukocytes (per mm ³)	3					
Erythrocytes (per mm ³)	40					
Glucose (mg/dL)	43					
Proteins (mg/dL)	214					
RT-PCR ZIKV	Negative					
IgG ZIKV (IIFT)	Positive					
IgM ZIKV (IIFT)	Negative					

* For z-scores, intergrowth-21st standards were used in the neonatal period and WHO Child Growth Standards were used thereafter.

[†] Tested by IIFT (Arboviral fever Mosaic, Euroimmun, Germany) from birth to 18 months and ELISA (ELISA Zika virus IgM and ELISA Zika virus IgG, Euroimmun, Germany) from 21 to 24 months of age.

[‡] Performed in the Spanish National Reference Center for Arboviruses (ISCIII-Madrid).

[§] Studied in our center and confirmed by the Spanish National Reference Center for Arboviruses (ISCIII-Madrid).

The patient was followed-up as per protocol at approximately 1, 4, 9, 12, 18–21, and 24 months of age, by a multidisciplinary team. During the follow-up period she stayed in Barcelona, with no travel to arboviral-endemic areas. Her growth showed major restriction and at 24 months her weight was 8.5 kg (−2.5 z-score) and head circumference was 40.5 cm (−4.8 z-score) (Table 1). The patient never tested positive for any of the molecular biological tests or specific ZIKV-IgM. Her ZIKV-IgG response was monitored throughout follow-up, and seroreversion was first observed in May 2018 (at 21 months of age) being confirmed at 24 months of age (Table 1). However, we could not perform a new lumbar puncture after seroreversion to check the ZIKV-IgG response in CSF because the mother declined this additional investigation. The mother remained positive for ZIKV-IgG and DENV-IgG in July 2018, when her daughter was 2 years old.

Ethics committee of the Hospital Universitari Vall d'Hebron approved the data collection registry for this case and also for all the children born to ZIKV-infected mothers (PR(AMI)103/2016).

3. Discussion

CZS due to mother-to-child transmitted ZIKV infection has been documented extensively in the recent epidemic.^[1,2] The case we describe here has the distinctive clinical and radiological features of CZS (Table 1). Moreover, we have evidence that the mother was infected, at least once, in early pregnancy as ZIKV was detected in serum in association with clinical symptoms. Indeed, the detection of ZIKV RNA in the AF confirmed the involvement of the fetus and constitutes the only laboratory evidence of prenatal infection in this child.

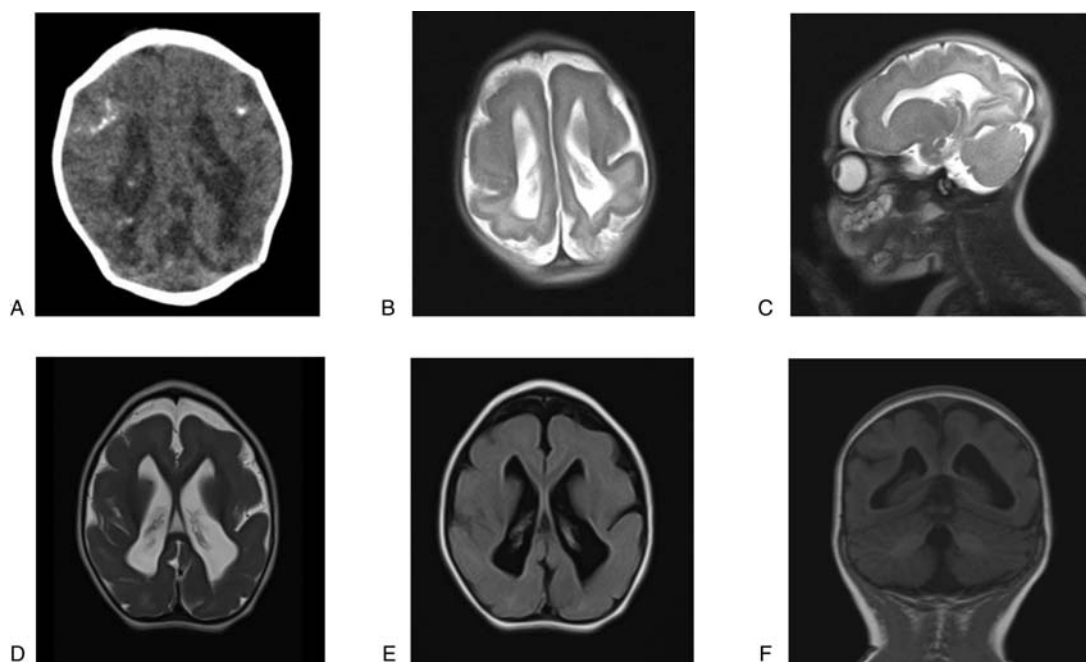


Figure 3. Axial CT (A), axial (B), and sagittal (C) T2-weighted MR images showing microcephaly and skull collapse. There is moderate ventricular dilatation, enlargement of extra-axial cerebrospinal fluid spaces and thinning of brain parenchyma. The gyral pattern is abnormally smooth for gestational age. Subcortical calcifications are predominantly located in the frontal lobes. Axial (D) and (E) T2-weighted, and coronal (F) T1-weighted follow-up MR images registered at 16-month-old showing the same pattern observed at birth.

There are important challenges for ZIKV laboratory diagnosis, partly due to the narrow time-frame for the detection of the ZIKV RNA. Additionally, the considerable antigenic homology between ZIKV and DENV can cause cross-reactivity in serological assays. In our case, we were unable to demonstrate ZIKV congenital infection by RT-PCR or ZIKV-IgM in postnatal samples. As inferred from other well-known congenital infections such as HIV and *Toxoplasma*, we initially interpreted the persistence of ZIKV-IgG in serum as the best serological marker to confirm congenital ZIKV infection due to the lack of evidence from other laboratory tests. However, seroreversion of ZIKV-IgG was first observed at 21 months of age, and then confirmed at 24 months (Table 1).

To our knowledge, this is the first description of a case of ZIKV congenital infection showing a non-permanent serological IgG response alongside the characteristic clinical phenotype. Furthermore, the location of this case in Europe and the absence of travel to endemic areas (thus no vectorial transmission risk) means that we have described the true serological response to prenatal ZIKV infection in early fetal life. We hypothesize that the following mechanisms could explain our findings. First, the low and transient ZIKV viremia, compared to reported DENV infections,^[9] could lead to a lack of ZIKV levels of antigen detection, and additionally to the absence of a strong immune response. Second, the specific and direct tropism of ZIKV for the central nervous system and other organs (i.e., female and male genital tract) may provide ZIKV with the ability to escape the immune system, becoming a silent virus for the host response. And finally, ZIKV may be able to avoid triggering a strong innate immune response, similar to what has been shown in some cases of pediatric HIV,^[10] because the active viral replication may have ceased during intrauterine life or soon afterwards. However, we

do not know whether the same IgG dynamic is present in case of post-natal infection or reinfections, which could be very common in ZIKV endemic countries.

This case underscores the importance of the clinical and radiological characteristics in the diagnosis of CZS, given the challenges in laboratory ascertainment of ZIKV infection in the perinatal period. Therefore, an approach from the host perspective using genomic and transcriptomic approaches and new biomarkers for understanding pathogenesis and improving diagnosis may finally give us the tools to solve these difficulties in the future.^[3]

4. Conclusion

We presume that as a consequence of prenatal ZIKV infection, the fetal brain and other organs are damaged before birth through direct injury. Following this, active infection ends during intrauterine life, and as a consequence the immune system of the infant is unable to build up a consistent immune response thereafter. Further understanding of the mechanisms taking part in the pathogenesis of ZIKV congenital infection is needed.

Author contributions

Conceptualization: Elena Sulleiro, Carlota Rodó, Claire Thorne, Antoni Soriano-Arandes.

Data curation: Elena Sulleiro, Carlota Rodó, Mateu Espasa, Anna Suy, Ariadna Rando, Tomás Pumarola, Antoni Soriano-Arandes.

Formal analysis: Elena Sulleiro, Carlota Rodó, Mateu Espasa, Ana Alarcón, Tomás Pumarola, Antoni Soriano-Arandes.

Funding acquisition: Carlo Giaquinto, Antoni Soriano-Arandes.

Investigation: Elena Sulleiro, Carlota Rodó, Anna Suy, Ana Alarcón, Antoni Soriano-Arandes.

Methodology: Elena Sulleiro, Claire Thorne, Carlo Giaquinto, Ana Alarcón, Antoni Soriano-Arandes.

Project administration: Antoni Soriano-Arandes.

Resources: Elena Sulleiro, Carlota Rodó, Antoni Soriano-Arandes.

Software: Antoni Soriano-Arandes.

Supervision: Elena Sulleiro, Marie Antoinette Frick, Carlota Rodó, Claire Thorne, Maria Espiau, Andrea Martín-Nalda, Anna Suy, Carlo Giaquinto, Ana Alarcón, Federico Martín-Torres, Tomás Pumarola, Pere Soler-Palacín, Antoni Soriano-Arandes.

Validation: Elena Sulleiro, Carlota Rodó, Andrea Martín-Nalda, Anna Suy, Carlo Giaquinto, Ariadna Rando, Ana Alarcón, Federico Martín-Torres, Tomás Pumarola, Pere Soler-Palacín, Antoni Soriano-Arandes.

Visualization: Elena Sulleiro, Marie Antoinette Frick, Carlota Rodó, Claire Thorne, Maria Espiau, Andrea Martín-Nalda, Anna Suy, Carlo Giaquinto, Susana Melendo, Ariadna Rando, Ana Alarcón, Federico Martín-Torres, Tomás Pumarola, Pere Soler-Palacín, Antoni Soriano-Arandes.

Writing – original draft: Elena Sulleiro, Carlo Giaquinto, Ana Alarcón, Federico Martín-Torres, Antoni Soriano-Arandes.

Writing – review & editing: Elena Sulleiro, Marie Antoinette Frick, Carlota Rodó, Mateu Espasa, Claire Thorne, Maria Espiau, Andrea Martín-Nalda, Anna Suy, Susana Melendo, Ariadna Rando, Ana Alarcón, Federico Martín-Torres,

Tomás Pumarola, Pere Soler-Palacín, Antoni Soriano-Arandes.

Antoni Soriano-Arandes orcid: 0000-0001-9613-7228.

References

- [1] Moore CA, Staples JE, Dobyns WB, et al. Characterizing the pattern of anomalies in congenital Zika syndrome for pediatric clinicians. *JAMA Pediatr* 2017;171:288–95.
- [2] Del Campo M, Feitosa IM, Ribeiro EM, et al. The phenotypic spectrum of congenital Zika syndrome. *Am J Med Genet A* 2017;173:841–57.
- [3] Soriano-Arandes A, Rivero-Calle I, Nastouli E, et al. What we know and what we don't know about perinatal Zika virus infection: a systematic review. *Expert Rev Anti Infect Ther* 2018;16:243–54.
- [4] Krauer F, Riesen M, Revez L, et al. Zika virus infection as a cause of congenital brain abnormalities and Guillain-Barre syndrome: systematic review. *PLOS Med* 2017;14:e1002203.
- [5] Mother-to-child transmission of HIV infection. The European Collaborative Study. *Lancet*; 1988;2:1039–43.
- [6] Maldonado YA, Read JS. Committee on Infectious Diseases. Diagnosis, treatment, and prevention of congenital toxoplasmosis in the United States. *Pediatrics* 2017;139.
- [7] Singh AE, Guenette T, Gratrix J, et al. Seroreversion of treponemal tests in infants meeting Canadian surveillance criteria for confirmed early congenital syphilis. *Pediatr Infect Dis J* 2013;32:199–202.
- [8] Petersen EE, Staples JE, Meaney-Delman D, et al. Interim guidelines for pregnant women during a Zika virus outbreak—United States, 2016. *MMWR* 2016;65:30–3.
- [9] Musso D, Rouault E, Teissier A, et al. Molecular detection of Zika virus in blood and RNA load determination during the French Polynesian outbreak. *J Med Virol* 2017;89:1505–10.
- [10] Goulder PJ, Lewin SR, Leitman EM. Paediatric HIV infection: the potential for cure. *Nat Rev Immunol* 2016;16:259–71.