

Validation of Computational Lesion Detection Methods in MRI Negative, Focal Epilepsy

Baris Kanber^{1,2,3,4} (ORCID: 0000-0003-2443-8800), John S. Duncan^{2,3,4} (ORCID: 0000-0002-1373-0681), Roman Rodionov^{2,3}, Fahmida Amin Chowdhury^{2,3}, Gavin P. Winston^{2,3,5} (ORCID: 0000-0001-9395-1478)

¹ Centre for Medical Image Computing, Department of Medical Physics and Biomedical Engineering, University College London, London, UK

² Department of Clinical and Experimental Epilepsy, Queen Square Institute of Neurology, University College London, London, UK

³ MRI Unit, Epilepsy Society, Chalfont St Peter, UK

⁴ National Institute for Health Research University College London NHS Foundation Trust Biomedical Research Centre, London UK

⁵ Department of Medicine, Division of Neurology, Queen's University, Kingston, Ontario, Canada

Corresponding author: Dr Baris Kanber, MRI Unit, Epilepsy Society, Chesham Lane, Chalfont St Peter, Buckinghamshire, SL9 0RJ, UK. E-mail: b.kanber@ucl.ac.uk, Telephone: +44 (0) 1494 601 360

Keywords: epilepsy; lesion; detection; MRI; negative

Statistics: Number of text pages (2); Number of words (436); Number of references (7); Number of figures (1 in colour); Number of tables (0).

Dear Editor,

Accurate detection and characterization of cerebral abnormalities is fundamental when neurosurgery is being considered to treat focal epilepsy that is not controlled with medication. Magnetic resonance imaging (MRI) is both sensitive and specific for identifying such abnormalities but, in 20% to 40% of individuals with refractory focal epilepsy who are candidates for surgery, no relevant abnormality is revealed on visual reading of optimally acquired brain MRI images¹. Recently, computational analysis of brain MRI has been shown to help the detection of covert lesions, with a need to balance sensitivity and specificity²⁻⁷.

Optimal evaluation of such methods would be a clinical trial in which it could be tested whether their inclusion in the clinical workflow results in more patients being offered surgery, and more patients becoming seizure free. However, before such an evaluation could be performed, the reliability of these methods must be demonstrated. An important issue is how this can be done in a structured manner.

In recent studies involving covert epileptic lesions, this assessment has been based on the observation of spatial overlap between the computationally detected clusters of imaging abnormalities and an area of presumed seizure onset approximately localised by a consensus of experts^{2,7} or inferred from resected brain areas^{3,7}. While the former is only an approximation, the latter, namely resected brain areas cannot be assumed to be the ground truth unless seizure freedom post-surgery can be demonstrated. Furthermore, the covert nature of some lesions may mean surgery cannot be offered in some patients or may be declined by the patient if the risk-to-benefit ratio of chances of seizure freedom and of causing new deficits is not favourable.

We suggest that a better comparison would be to determine whether computationally detected abnormalities are co-localized with the intracranial/stereo EEG contacts that are irrefutably involved in seizure onset, early propagation, and interictal epileptic activity. Accordingly, we have developed a structured method for comparing the anatomical coordinates of cerebral abnormalities detected by computational methods with the results

of intracranial/stereo EEG recordings (Figure 1) and have set up an online survey where such results can be shared across research groups (MRI-negative focal epilepsy-intracranial/stereo EEG structured evaluation programme, accessible at <https://redcap.slms.ucl.ac.uk/surveys/index.php?s=DKATRKAPLC>).

The survey is currently populated with 25 case results from our own ongoing study and is openly available to other research centres for comparing computational neuroimaging analyses with intracranial/stereo EEG data and contributing to the database. Recognizing that there are a variety of neuroimaging analysis methods being developed, a standardised method of validation will facilitate the determination of optimal protocols for lesion detection in MRI-negative focal epilepsy that could be evaluated in a clinical trial.

Acknowledgements

This work was funded by the Medical Research Council (MR/M00841X/1), Engineering and Physical Sciences Research Council (EP/L016478/1), Sobell Foundation, and the National Institute for Health Research (University College London Hospitals NHS Foundation Trust Biomedical Research Centre).

Disclosures

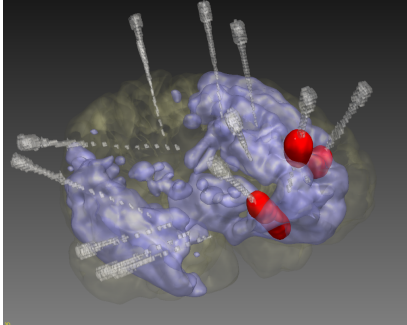
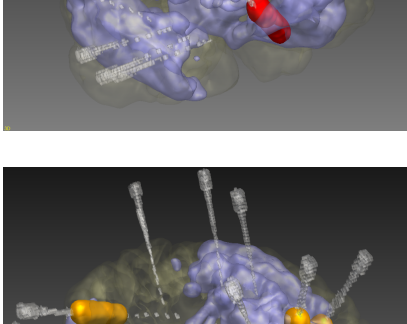
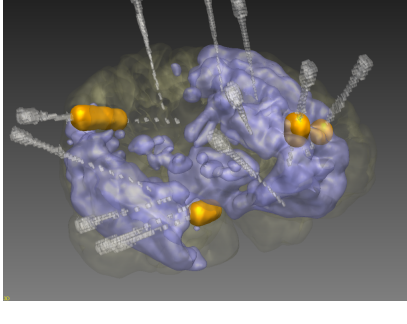
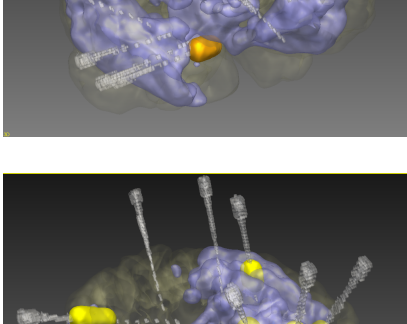
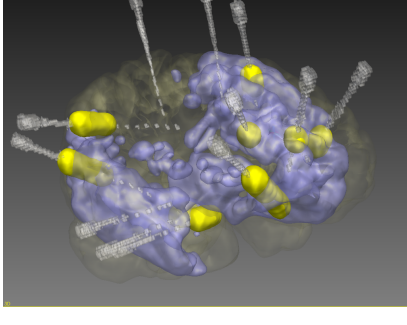
The authors have no conflicts of interest to report. We confirm that we have read the Journal's position on issues involved in ethical publication and affirm that this letter is consistent with those guidelines.

References

1. Leeman-Markowski B. Review of MRI-Negative Epilepsy. *JAMA Neurol* 2016;73:1377–1377.
2. Azami ME, Hammers A, Jung J, et al. Detection of Lesions Underlying Intractable Epilepsy on T1-Weighted MRI as an Outlier Detection Problem. *PLOS ONE* 2016;11:e0161498.
3. Ahmed B, Thesen T, Blackmon KE, et al. Decrypting “Cryptogenic” Epilepsy: Semi-supervised Hierarchical Conditional Random Fields For Detecting Cortical Lesions In MRI-Negative Patients. *Journal of Machine Learning Research* 2016;17:1–30.
4. Ahmed B, Brodley CE, Blackmon KE, et al. Cortical feature analysis and machine learning improves detection of “MRI-negative” focal cortical dysplasia. *Epilepsy Behav* 2015;48:21–8.

5. Jin B, Krishnan B, Adler S, et al. Automated detection of focal cortical dysplasia type II with surface-based magnetic resonance imaging postprocessing and machine learning. *Epilepsia* 2018;59:982–92.
6. Hong S-J, Kim H, Schrader D, et al. Automated detection of cortical dysplasia type II in MRI-negative epilepsy. *Neurology* 2014;83:48–55.
7. Alaverdyan Z, Jung J, Bouet R, et al. Regularized siamese neural network for unsupervised outlier detection on brain multiparametric magnetic resonance imaging: Application to epilepsy lesion screening. *Medical Image Analysis* 2020;60:101618.

Figure 1: Structured comparison of the anatomical coordinates of epileptogenic areas detected by a computational method with the results of intracranial/stereo EEG recordings in an example case. (right) three-dimensional visualisations showing the EEG electrodes in grey, seizure onset zone in red, spread in orange, and interictal activity in yellow. Epileptogenic areas detected by the computational method are shown in blue. (left) part of the online assessment form for the same case.

<p>5) SoZ in abnormal area? * must provide value</p>	<p> <input checked="" type="radio"/> Yes <input type="radio"/> No <input type="radio"/> SoZ not identified by intracranial/stereo EEG </p> <p>Choose Yes if the seizure onset zone identified during intracranial/stereo EEG was within any of the areas identified as being abnormal by your computational method</p>	
<p>6) Seizure propagation within abnormal area? * must provide value</p>	<p> <input checked="" type="radio"/> Yes <input type="radio"/> No <input type="radio"/> No seizures during intracranial/stereo EEG </p> <p>Choose Yes if there was seizure propagation during intracranial/stereo EEG within any of the areas identified as being abnormal by your computational method</p>	
<p>7) Interictal epileptic discharges within abnormal area? * must provide value</p>	<p> <input checked="" type="radio"/> Yes <input type="radio"/> No </p> <p>Choose Yes if there were interictal epileptic discharges during intracranial/stereo EEG within any of the areas identified as being abnormal by your computational method</p>	
<p>8) Seizure onset outside abnormal area? * must provide value</p>	<p> <input type="radio"/> Yes <input checked="" type="radio"/> No <input type="radio"/> SoZ not identified by intracranial/stereo EEG </p> <p>Choose Yes if the seizure onset zone identified during intracranial/stereo EEG was outside the abnormal areas detected by your computational method</p>	
<p>9) Propagation outside abnormal area? * must provide value</p>	<p> <input checked="" type="radio"/> Yes <input type="radio"/> No <input type="radio"/> No seizures during intracranial/stereo EEG </p> <p>Choose Yes if there was seizure propagation during intracranial/stereo EEG outside the areas identified as being abnormal by your computational method</p>	
<p>10) Interictal discharges outside abnormal area? * must provide value</p>	<p> <input checked="" type="radio"/> Yes <input type="radio"/> No </p> <p>Choose Yes if there were interictal epileptic discharges during intracranial/stereo EEG outside the areas identified as being abnormal by your computational method</p>	