



OPEN LETTER

Management of intracranial tuberculous mass lesions: how long should we treat for? [version 1; peer review: awaiting peer review]

Suzaan Marais ¹, Ronald Van Toorn², Felicia C. Chow ³, Abi Manesh⁴, Omar K. Siddiqi ^{5,6}, Anthony Figaji ⁷, Johan F. Schoeman², Graeme Meintjes⁸, Tuberculous Meningitis International Research Consortium

¹Department of Neurology, Inkosi Albert Luthuli Central Hospital and University of KwaZulu-Natal, Durban, 4091, South Africa

²Department of Pediatrics and Child Health, Stellenbosch University, Cape Town, 7505, South Africa

³Weill Institute of Neurosciences and Department of Neurology and Division of Infectious Diseases, University of California, San Francisco, California, 94110, USA

⁴Department of Infectious Diseases, Christian Medical College, Vellore, 632004, India

⁵Department of Neurology, Beth Israel Deaconess Medical Center, Boston, Massachusetts, 02215, USA

⁶Department of Internal Medicine, University of Zambia School of Medicine, Lusaka, Zambia

⁷Division of Neurosurgery and Neuroscience institute, University of Cape Town, Cape Town, 7700, South Africa

⁸Wellcome Centre for Infectious Diseases Research in Africa, Institute of Infectious Disease and Molecular Medicine, Department of Medicine, University of Cape Town, Cape Town, 7925, South Africa

v1 **First published:** 15 Oct 2019, 4:158 (<https://doi.org/10.12688/wellcomeopenres.15501.1>)
Second version: 31 Oct 2019, 4:158 (<https://doi.org/10.12688/wellcomeopenres.15501.2>)
Latest published: 26 Feb 2020, 4:158 (<https://doi.org/10.12688/wellcomeopenres.15501.3>)

Abstract

Tuberculous intracranial mass lesions are common in settings with high tuberculosis (TB) incidence and HIV prevalence. The diagnosis of such lesions, which include tuberculoma and tuberculous abscesses, is often presumptive and based on radiological features, supportive evidence of TB elsewhere and response to TB treatment. However, the treatment response is unpredictable, with lesions frequently enlarging paradoxically or persisting for many years despite appropriate TB treatment and corticosteroid therapy. Most international guidelines recommend a 9-12 month course of TB treatment for central nervous system TB when the infecting *Mycobacterium tuberculosis* (*M.tb*) strain is sensitive to first-line drugs. However, there is variation in opinion and practice with respect to the duration of TB treatment in patients with tuberculomas or tuberculous abscesses. A major reason for this is the lack of prospective clinical trial evidence. Some experts suggest continuing treatment until radiological resolution of enhancing lesions has been achieved, but this may unnecessarily expose patients to prolonged periods of potentially toxic drugs. It is currently unknown whether persistent radiological enhancement of intracranial tuberculomas after 9-12 months of treatment represents active disease, inflammatory response in a sterilized lesion or merely revascularization. The consequences of stopping TB treatment prior to

Open Peer Review

Reviewer Status

	Invited Reviewers		
	1	2	3
version 3 (revision) 26 Feb 2020			
version 2 (revision) 31 Oct 2019			
version 1 15 Oct 2019			

- Jerome H. Chin**, NYU Langone Health, New York City, USA
- Benedict Michael**, University of Liverpool, Liverpool, UK

resolution of lesional enhancement have rarely been explored. These important issues were discussed at the 3rd International Tuberculous Meningitis Consortium meeting. Most clinicians were of the opinion that continued enhancement does not necessarily represent treatment failure and that prolonged TB therapy was not warranted in patients presumably infected with *M.tb* strains susceptible to first-line drugs. In this manuscript we highlight current medical treatment practices, benefits and disadvantages of different TB treatment durations and the need for evidence-based guidelines regarding the treatment duration of patients with intracranial tuberculous mass lesions.

Keywords

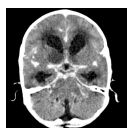tuberculosis, central nervous system, treatment duration, management, imaging, tuberculous meningitis, tuberculoma, tuberculous abscess

3 **Julie Higashi**, Los Angeles County Department of Public Health, Los Angeles, USA
University of California, San Francisco, San Francisco, USA

Any reports and responses or comments on the article can be found at the end of the article.



This article is included in the [Wellcome Centre for Infectious Diseases Research in Africa \(CIDRI-Africa\)](#) gateway.



This article is included in the [Tuberculous Meningitis International Research Consortium](#) collection.

Corresponding author: Suzaan Marais (marais.suzaan@gmail.com)

Author roles: **Marais S:** Conceptualization, Project Administration, Resources, Visualization, Writing – Original Draft Preparation, Writing – Review & Editing; **Van Toorn R:** Writing – Original Draft Preparation, Writing – Review & Editing; **Chow FC:** Visualization, Writing – Original Draft Preparation, Writing – Review & Editing; **Manesh A:** Writing – Original Draft Preparation, Writing – Review & Editing; **Siddiqi OK:** Writing – Original Draft Preparation, Writing – Review & Editing; **Figaji A:** Writing – Original Draft Preparation, Writing – Review & Editing; **Schoeman JF:** Writing – Original Draft Preparation, Writing – Review & Editing; **Meintjes G:** Conceptualization, Supervision, Writing – Original Draft Preparation, Writing – Review & Editing;

Competing interests: No competing interests were disclosed.

Grant information: This work was supported by the Wellcome Trust [098316 and 203135 to GM]. FCC was supported by National Institutes of Health/Fogarty International Center [R21TW011035]. OKS was supported by the National Institutes of Health [K23 NS084054-01]. AF was supported by the National Research Foundation SARChI Chair in Clinical Neurosciences. GM is also supported by the South African Research Chairs Initiative of the Department of Science and Technology and National Research Foundation (NRF) of South Africa [64787], NRF incentive funding [UID: 85858] and the South African Medical Research Council through its TB and HIV Collaborating Centres Programme with funds received from the National Department of Health [RFA# SAMRC-RFA-CC: TB/HIV/AIDS-01-2014]. The funders had no role in the study design, data collection, data analysis, data interpretation, or writing of this report. The opinions, findings and conclusions expressed in this manuscript reflect those of the authors alone.

The funders had no role in study design, data collection and analysis, decision to publish, or preparation of the manuscript.

Copyright: © 2019 Marais S *et al.* This is an open access article distributed under the terms of the [Creative Commons Attribution License](#), which permits unrestricted use, distribution, and reproduction in any medium, provided the original work is properly cited.

How to cite this article: Marais S, Van Toorn R, Chow FC *et al.* **Management of intracranial tuberculous mass lesions: how long should we treat for?** [version 1; peer review: awaiting peer review] Wellcome Open Research 2019, 4:158 (<https://doi.org/10.12688/wellcomeopenres.15501.1>)

First published: 15 Oct 2019, 4:158 (<https://doi.org/10.12688/wellcomeopenres.15501.1>)

Disclaimer

The views expressed in this article are those of the author(s). Publication in Wellcome Open Research does not imply endorsement by Wellcome.

Introduction

Neurological tuberculosis (TB) manifests as meningitis, radiculomyelitis, bony spinal disease and tuberculoma/tuberculous abscess that may occur intracranially or within the spinal space¹. Similar to the other neurological TB manifestations, tuberculous mass lesions are common in settings with high TB incidence^{2,3}, and high HIV prevalence⁴⁻⁷, where this diagnosis accounts for a significant proportion of intracranial space occupying lesions. The diagnosis of intracranial tuberculoma is most often presumptive and based on radiological features, supportive evidence of TB elsewhere and response to TB treatment. However, the treatment response of tuberculomas is unpredictable and lesions may persist for many years despite appropriate TB treatment and adjunctive corticosteroid therapy⁸⁻¹². The optimal duration of TB treatment is unknown and clinical practice varies. In this manuscript we highlight current divergent clinical practice, benefits and disadvantages of different TB treatment durations and the need for prospective clinical trial data to determine the optimal treatment duration in patients with intracranial tuberculous mass lesions.

Pathogenesis and pathology

Hematogenous seeding after the primary infection is one proposed mechanism of central nervous system (CNS) involvement in TB¹³. Miliary disease may increase the risk of hematogenous spread to the CNS¹⁴. *Mycobacterium tuberculosis* (*M.tb*) may enter the CNS via direct infection of endothelial cells or trafficking through infected phagocytes^{15,16}, which is followed by the formation of tubercles, most commonly in the brain cortex or meninges. Rupture of an adjacent tubercle into the subarachnoid space results in tuberculous meningitis (TBM), whilst tubercles that do not rupture may progress to form tuberculomas¹³. Tuberculomas show granulomatous inflammation with a central area of caseous necrosis surrounded by epithelioid histiocytes, Langerhan's giant cells, lymphocytes, astrocytes and vascular proliferation that evolves to develop a thick vascular connective tissue layer.

The mycobacterial burden in CNS TB is low. The impressive pathology and evolution of lesions during TB therapy highlights the role of the host inflammatory response in pathogenesis. Microglia in the CNS are infected by *M.tb* and activated microglia release many cytokines that play a crucial role in pathogenesis¹⁷. TNF- α is a central molecule in the control and mediation of inflammation in CNS TB. While TNF- α is involved in granuloma formation and control of disease, elevated levels are associated with markers of increased pathology such as cerebrospinal fluid leukocytosis, higher levels of other soluble inflammatory mediators, increased *M.tb* load and clinical deterioration¹⁸. Studies focused on the vasculature associated with tuberculomas have revealed significant vasculitis with proliferative changes in the basement membrane¹⁹.

Occasionally, tubercles may coalesce or continue to progress to form a tuberculous abscess, which is a large pus-filled

encapsulated lesion containing bacilli^{20,21}. Histopathologically, the tuberculous abscess wall shows chronic vascular granulation tissue whilst lacking the granulomatous reaction of a tuberculoma.

Clinical presentation

The clinical features of tuberculomas depend on their anatomic location in the brain, related to local mass effect, obstruction of cerebrospinal fluid pathways, and/or seizures. Supratentorial lesions are common in adults while infratentorial involvement is slightly more common in children²². Patients usually present sub-acutely with symptoms and signs such as headaches, seizures, depressed level of consciousness, and focal neurological deficits^{12,23,24}. Infratentorial lesions commonly present with hydrocephalus. Pituitary apoplexy and movement disorders like chorea are rare manifestations of tuberculomas^{25,26}. If associated with TBM, meningeal symptoms and signs may dominate the clinical picture. Tuberculous abscesses have a more accelerated course, often presenting acutely with associated fever²¹.

Imaging findings

Neuroimaging is essential for identifying intracranial tuberculous mass lesions with findings determined by the composition of the lesion. Tuberculomas have classically been categorized as non-caseating, caseating solid, and caseating liquid, that can be differentiated on computed tomography (CT) and magnetic resonance imaging (MRI)²¹. Multiple lesions are seen more often than isolated lesions though the latter is still common^{27,28}. Perilesional edema can be present or absent.

CT is the most frequent modality used to identify tuberculomas due to its wide availability though it has limitations in resolution. Tuberculomas typically appear as round or lobulated nodules that are hypodense or isodense to the brain parenchyma. CT with contrast most commonly shows rim enhancement of lesions but nodular or homogeneous enhancement can also be seen¹². The presence of a "target sign" on CT which consists of a rim enhancing lesion with central calcification is highly suggestive of a tuberculoma but uncommon²⁹.

MRI is the preferred modality for the identification of tuberculomas due to superior resolution and better visualization of the posterior fossa relative to CT. Non-caseating granulomas are hypointense or isointense on T1-weighted imaging (T1WI) and hyperintense on T2-weighted imaging (T2WI, "T2-bright") with homogeneous contrast enhancement²¹. Caseating solid granulomas are hypointense or isointense on T1WI and hypointense on T2WI ("T2-black") with rim enhancement. Caseating liquid granulomas, which are rare, are hypointense on T1WI and hyperintense on T2WI with rim enhancement. Tuberculous abscesses may be indistinguishable from tuberculomas with a liquid center on standard MRI settings, but they are usually larger (>3 cm in diameter) and thin-walled in appearance²¹. Miliary tuberculomas appear as multiple, small (2–3 mm), scattered lesions that typically rim enhance with contrast administration and lack perilesional edema³⁰.

Evidence of a satisfactory radiological response on serial brain imaging after TB treatment initiation includes a reduction in

perilesional edema, decrease in lesion size and calcification (seen on CT). Other findings supportive of improvement of liquified tuberculomas and abscesses on MRI are a decrease in T2 brightness and, subsequently, loss of T2 signal. Evolution of TB abscesses from early-stage “T2-bright” with edema to “T2-black” lesions may represent a marker for cure³¹. In our experience, the resultant homogeneous “T2-black” tuberculoma (with rim T1 contrast enhancement) may persist for many months in asymptomatic patients without relapse off TB treatment. CT of such lesions usually shows gradual calcification, which most often involves the capsule.

Paradoxical reactions

Paradoxical enlargement or the development of new intracranial tuberculomas or abscesses in patients with CNS or extraneural TB on appropriate treatment is well-described^{8,32–44}. Such reactions typically occur within the first six months after TB treatment initiation^{35,41,42,45}, but may rarely be delayed for a year or more^{10,45–47}. Paradoxical reactions are often identified when patients present with neurological deterioration during TB treatment, prompting brain imaging. In case series of predominantly HIV-uninfected patients with CNS TB, clinical deterioration due to paradoxical tuberculoma reaction has been described in 6–29%^{8,32–39}. However, many of these patients are asymptomatic during these episodes and the frequency of detecting paradoxical tuberculoma development or enlargement increases substantially (from 29% to 65%) if surveillance brain imaging is performed during the first six months of TB treatment³⁵. Paradoxical TB reactions are more common in HIV-infected patients, particularly in those who commence antiretroviral therapy (ART) after starting TB treatment, in which case it is referred to as paradoxical TB-immune reconstitution

inflammatory syndrome (TB-IRIS)^{48–51}. The influence of HIV on the frequency of paradoxical tuberculoma reactions (separate from the effect of ART) has rarely been reported. One recent study of 47 HIV-infected and 14 HIV-uninfected adults with tuberculomas found no difference in the frequency of paradoxical reactions by HIV status (36% in each group)¹². The majority of HIV-infected patients were receiving ART prior to tuberculoma presentation or did not start ART after diagnosis, precluding the development of TB-IRIS in this group. The pathogenesis of paradoxical reactions (including IRIS) remains unclear but is likely related to an aberrant immune response to TB antigens rather than failure of TB treatment^{42,52}. Clinical findings supporting this view are the observation that new or enlarging tuberculomas in TBM patients frequently appear in those known to be infected with drug-susceptible strains who show clinical and radiological improvement of other aspects of TBM (Figure 1)⁴³. Another argument is that anti-inflammatory drugs (corticosteroids and thalidomide) are effective in the prevention and management of paradoxical TB reactions, including tuberculomas^{43,53–55}.

Medical treatment

The mainstay of treatment of intracranial tuberculomas is similar to that of TBM and includes TB therapy and corticosteroids. The World Health Organization, Centers for Disease Control and Prevention of America and the British Thoracic Society recommend a 9–12 month course of TB treatment for CNS TB when the *M.tb* strain is sensitive to all drugs^{56–58}. However, these guidelines are based on expert opinion rather than randomized controlled trials. Specifically, no studies have compared different treatment durations in patients with intracranial tuberculomas. The morphology of the lesion plays an

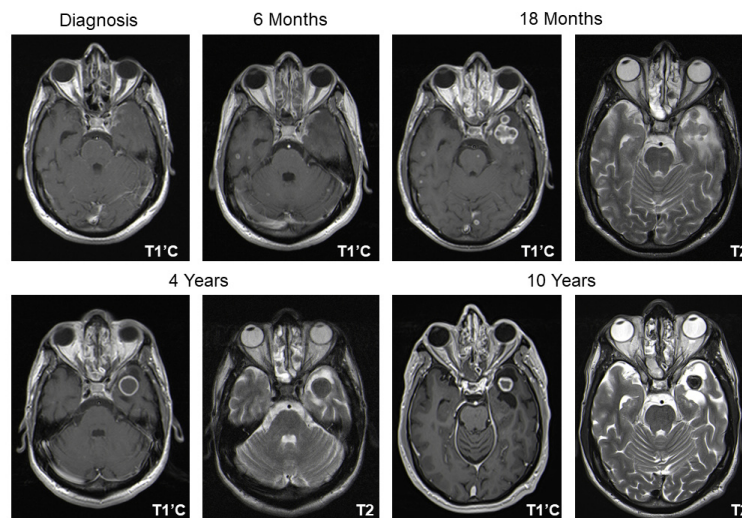


Figure 1. Serial magnetic resonance imaging of a patient with drug-susceptible central nervous system tuberculosis who received TB treatment for 4 years. Axial T1-weighted post-contrast (T1’C) images and T2-weighted (T2) images are shown. At diagnosis, a miliary pattern with focal meningeal enhancement of the left temporal lobe was noted, which persisted at 6-months follow-up. At 18 months, a lobulated rim-enhancing tuberculoma had developed in the left temporal lobe which was of mixed intensity on T2-weighted images with surrounding edema. Despite gradual reduction in lesion size and perilesional edema with associated atrophy, rim-enhancement persisted during the next 8.5 years of follow-up. Notably, the patient did not deteriorate clinically after cessation of TB treatment and the T2-signal of the lesion became increasingly hypointense (“T2-Black”) suggesting cure.

important role in response to therapy and a one-size-fits-all approach may therefore be inappropriate in the decision regarding tuberculoma treatment duration. This is suggested by the almost invariably good response of miliary tuberculomas to TB treatment (presumably non-caseous) and the frequent persistence of caseous and liquified TB lesions (e.g. abscesses) despite TB treatment^{43,59}.

Some guidelines suggest adjunctive systemic corticosteroids in all forms of CNS TB, including those in whom a strong suspicion of tuberculoma exists⁵⁸. Corticosteroid therapy may be of particular value when there is significant perilesional edema (resulting in symptomatology) and in cases where there is paradoxical enlargement despite optimal TB therapy⁶⁰. Corticosteroid duration should be tailored according to the radiological response of the tuberculoma and clinical wellbeing of the patient and balanced against side effects.

TB abscesses are often unresponsive to standard TB therapy with corticosteroids. Although no clinical trials exist, adjunctive thalidomide therapy (3–5 mg/kg/day) has been shown to be beneficial in patients who develop enlarging TB abscesses⁴³. In our experience, thalidomide can be stopped without relapse when clinical improvement is optimal or reached a plateau, regardless of whether radiological resolution has been achieved.

Surgical management

There are no controlled studies to determine the role of surgery in patients with intracranial tuberculous mass lesions. However, there are general principles from clinical practice and the existing literature that can be summarized^{10,61}. Biopsy for diagnosis is considered: 1) at the outset if the definitive diagnosis is unclear, and 2) for persistence or paradoxical growth of a presumed tuberculoma despite medical treatment (for diagnostics and drug sensitivity testing). Resection of the lesion may be considered: 1) to relieve symptomatic or potentially life-threatening mass effect and/or hydrocephalus, and 2) to treat medically refractory seizures. Drainage of abscesses is considered for symptomatic mass effect or hydrocephalus, especially when large and/or in the posterior fossa. However, surgery for tuberculous mass lesions is rarely performed in TB endemic settings as the clinical and imaging information is usually sufficient to make the diagnosis. Furthermore, risks associated with surgery, especially if the lesion is located in an eloquent or difficult to access brain area, and inadequate neurosurgical facilities usually combine to preclude surgical management.

Duration of TB treatment: what happens in practice?

There is variation in opinion and practice with respect to the duration of TB treatment in patients with intracranial tuberculomas or tuberculous abscesses. A major reason for this is the lack of prospective clinical trial evidence. In rare cases where a microbiological diagnosis is achieved, it is not feasible to access repeated clinical specimens from the site of disease to ascertain whether and when culture conversion has occurred, unlike pulmonary TB where sputum *M.tb* culture can be monitored and treatment duration adjusted

accordingly. Monitoring is performed clinically and with brain imaging.

The routine duration of TB treatment in intracranial tuberculoma cases include periods of 6⁶², 9^{24,32,40,63}, 12⁶⁴, 15³⁹ and 18^{9,10,23,35,65,66} months depending on the clinician's preference. **Table 1** presents duration of treatment and outcome in tuberculoma studies published in English^{8,9,11,12,23,24,32,33,36,46,59,64,65,67–72}. Although some studies describe radiological resolution of tuberculoma in more than 80% of patients after 6–12 months of TB treatment^{33,62,64,69,70}, others have reported persistently enhancing lesions in the vast majority (71–82%) of cases after 9–12 months of treatment^{23,32}. Even after 24 months of therapy, tuberculomas may persist in 22%–46% of cases^{9,12,23} (**Figure 1**). Larger lesions (>2.5 cm) are significantly more likely to persist after 18 to 24 months of treatment^{9,12}. The medical management of patients with persistent intracranial tuberculoma after a “complete treatment course” (6–18 months) is particularly controversial. Some experts suggest continuing treatment until radiological resolution of enhancing lesions has been achieved^{23,73}, which may unnecessarily expose patients to potentially toxic drugs for many years^{8,9,11,12,23,64,67,74}; in a study from South Africa, more than 50% of tuberculoma patients followed for 9 months or more (31/57) received TB treatment for more than 18 months (range 19–46 months)¹². Others are of the opinion that lesional persistence beyond 18 months does not reflect treatment failure, but rather represents a persistent immune response at the disease site that has been sterilized, hence extending TB treatment beyond this period will not add any benefit⁷⁵.

Rationale for using longer versus shorter regimens

It is currently unknown whether persistent radiological enhancement of intracranial tuberculomas after 9–12 months of appropriate treatment represents active disease, inflammatory response in a sterilized lesion or merely revascularization. The consequences of stopping TB treatment prior to complete radiological resolution of these lesions has rarely been explored. These important issues were discussed at the 3rd International TBM Consortium meeting. Most clinicians were of the opinion that the continued enhancement does not necessarily represent treatment failure and that prolonged TB therapy (beyond 9–12 months) is not warranted in patients suspected of infection with or with proven *M.tb* strains susceptible to first-line drugs. This position is supported by the asymptomatic state of many patients and the paucity of AFB on staining and sterility of tuberculoma biopsy samples obtained prior to and following TB treatment initiation^{23,68}. Immunohistochemical staining of excised tuberculomas also demonstrates high expression of vascular endothelial growth factor (VEGF) in the lesions with intense positivity of inflammatory mononuclear cells as well as reactive astrocytes and fibrocytes⁷⁶. The VEGF-induced angiogenesis in the granuloma capsule may therefore contribute, in addition to inflammation, to the persistent and prolonged contrast enhancement frequently seen on serial brain imaging. Furthermore, one trial reports no clinical or radiological deterioration at 24 months follow-up in 20 patients with persistent intracranial tuberculomas after completion of 9 months' TB therapy²⁴.

Table 1. Summary of reported medical management strategies and clinical and radiologic outcomes of intracranial tuberculoma case series.

Study, First author, year published, country	Study design	Patients, n (age group) ¹	Duration of ATT, Months: %	Steroid use,%	Favorable clinical outcome, %, (n/N) ²	Radiologic persistent tuberculoma(s), % (n/N): months F/U
Afghani ⁶⁷ , 1994, multiple	Case report + review	41 (C + A)	10-24: 100	80 ³	68 (25/37)	N/A
Anuradha ³² , 2011, India	Retrospective observational	43 (C + A)	9: 100	100	26 (11/43)	79 (30/38): 9
Awada ³³ , 1998, Saudi Arabia	Retrospective observational	18 (C + A)	12-18: 100	67	N/A	100 (18/18): 12
Bayindir ⁶⁸ , 2006, Turkey	Retrospective observational	23 (C + A)	12-18: 100	N/A	100 (15/15)	N/A
Gupta ⁶⁹ , 1990, India	Prospective observational	31 (C + A)	11-12: 97	N/A	N/A	14 (4/29): 12
Gupta ³ , 2003, India	Prospective observational	9 (C + A)	16: 11 18-34: 88	89	44 (4/9)	N/A
Harder ⁷⁰ , 1983, Saudi Arabia	Retrospective observational	20 (C + A)	12: 61 9-24: 39 ⁴	75	35 (7/20)	0 (0/10): 12 ⁵
Idris ⁶⁵ , 2007, Sudan	Retrospective observational	16 (A)	18: 100 ⁶	56	N/A	13 (2/16): 18
Li ⁶⁶ , 2012, China	Retrospective observational	6 (A)	18: 100	33	83 (5/6)	N/A
Man ³⁶ , 2010, France	Retrospective observational	23 (A)	9-18: 88 21: 12 ⁴	43	53 (10/19)	75 (12/16): 9-21
Marais ¹² , 2019, South Africa	Retrospective observational	66 (A)	≥9: 96% 19-46: 54 ⁴	76	37 (20/54)	49 (20/41): 18 33 (14/42): 24
Nair ⁹ , 2019, India	Retrospective observational	86 (C + A)	≥18: 100 >24-120: 22	N/A	N/A	22 (19/86): 24
Poonnoose ²³ , 2003, India	Retrospective observational	28 (C + A)	≥18: 100	54	68 (19/28)	69 (19/28): 18 46 (13/28): 24
Rajeswari ²⁴ , 1995, India	RCT	108 (C + A)	9: 100 ⁴	100	90 (97/108)	22 (20/91): 9 12 (11/89): 24
Ravenscroft ⁵⁹ , 2001, South Africa	Prospective observational	34 (C)	≥6: 100 12: 6	N/A	N/A	44 (14/32): 6 ⁷
Shah, 2016 ⁶⁴ , India	Prospective observational	28 (C + A)	≥12: 100 18-24: 17 ⁸	79	N/A	17 (4/24): 12 13 (3/24): 24
Shah, 2019 ¹¹ , India	Case series	6 (C)	23-32: 100	83	83 (5/6)	83 (5/6): >24
Tandon ⁷¹ , 1985, India	Retrospective observational	50 (C + A)	12-18: 98	N/A	78 (39/50)	40 (20/50): N/A
Wasay ⁴⁶ , 2004, Pakistan	Retrospective observational	102 (C + A)	9-12: 100 ⁴	79 ⁴	34 (17/50)	NA
Yaramis ⁷² , 1998, Turkey	Retrospective observational	4 (C)	12: 100 24: 50	100	100 (4/4)	N/A

Abbreviations: n, number; ATT, antituberculous therapy; N, number with known data; F/U, follow-up; C, children; A, adults; N/A, data not available; RCT, randomized controlled trial

¹ All studies included HIV-uninfected patients or patients with unknown HIV status, except studies by Man *et al.*³⁶ and Marais *et al.*¹², that included 7, and 47 HIV-infected patients, respectively;

² The definition varies between studies and include descriptions such as “complete recovery”, “no neurological disability”, “asymptomatic” and unspecified “good clinical recovery”. Several studies included patients with co-existing tuberculous meningitis that might have influenced clinical outcomes.

³ Including 30 patients with available data

⁴ Including patients followed up for at least 9 months

⁵ Including patients treated medically without surgical intervention

⁶ Excluding 1 patient who died during therapy

⁷ “32” refers to number of meningeal tuberculomas in 25 patients

⁸ Including patients followed up for at least 12 months

A theoretical argument in favor of continuing treatment longer than 9–12 months is that drug penetration into the CNS is sub-optimal and is likely even more suboptimal into the tuberculoma or tuberculous abscess. Drug penetration into cerebrospinal fluid is poor for rifampicin, the key sterilizing drug⁷⁷. Tuberculous abscesses that, unlike tuberculomas, are teeming with bacilli may potentially act as an immune sanctuary protecting the bacilli from immune effector cells within pus²¹. The consequence of these factors may be that sterilization is not always achieved with 9–12 months treatment and that a longer duration may be required. The inability to obtain specimens to confirm sterilization make this an area of uncertainty. Pertinent, too, is that relapse of CNS TB could have catastrophic consequences. Furthermore, some patients need late re-initiation of immunomodulatory treatment and this should ideally be done while on TB treatment to avoid relapse resulting from iatrogenic immunosuppression. However, if treatment is continued because of residual lesions, when does the clinician stop therapy? Should this be until all contrast enhancing lesions have resolved – which can take years – or some arbitrary timepoint before then?

Conclusion

Intracranial tuberculoma represents a major health concern in developing countries. Routine practices often include prescription of TB therapy until lesional enhancement has

resolved, which may expose some patients to an unnecessarily prolonged treatment course. Because of the lack of evidence-based guidelines and equipoise with respect to shorter versus longer duration regimens, further research is needed. In the first instance, a multi-country audit of existing practice and outcomes in terms of cure and relapse would help in defining the spectrum of current practice. Ultimately, a randomized controlled trial comparing a standardized duration of TB treatment with duration based on brain imaging would provide a definitive answer to this question.

Ethics statement

Images presented in [Figure 1](#) were obtained during a retrospective study of patients who presented with intracranial tuberculoma to Inkosi Albert Luthuli Central Hospital in Durban, South Africa. The Biomedical Research Ethics Committee (BREC) of the University of KwaZulu-Natal (UKZN) approved the study (BREC class approval number BCA325/15). As this was a retrospective folder review, and data were analyzed anonymously outside of the clinical setting, the ethics committee of UKZN waived the requirement for informed consent and informed consent was not obtained.

Data availability

Underlying data

No data is associated with this article.

References

- Dastur DK, Manghani DK, Udani PM: **Pathology and pathogenetic mechanisms in neurotuberculosis.** *Radial Clin North Am.* 1995; **33**(4): 733–52. [PubMed Abstract](#)
- Dastur HM: **Diagnosis and neurosurgical treatment of tuberculous disease of the CNS.** *Neurosurg Rev.* 1983; **6**(3): 111–7. [PubMed Abstract](#) | [Publisher Full Text](#)
- Garg RK, Desai P, Kar M, et al.: **Multiple ring enhancing brain lesions on computed tomography: an Indian perspective.** *J Neurol Sci.* 2008; **266**(1–2): 92–6. [PubMed Abstract](#) | [Publisher Full Text](#)
- Bhigjee AI, Naidoo K, Patel VB, et al.: **Intracranial mass lesions in HIV-positive patients—the KwaZulu/Natal experience.** *Neuroscience AIDS Research Group, S Afr Med J.* 1999; **89**(12): 1284–8. [PubMed Abstract](#)
- Choe PG, Park WB, Song JS, et al.: **Spectrum of intracranial parenchymal lesions in patients with human immunodeficiency virus infection in the Republic of Korea.** *J Korean Med Sci.* 2010; **25**(7): 1005–10. [PubMed Abstract](#) | [Publisher Full Text](#) | [Free Full Text](#)
- Modi M, Mochan A, Modi G: **Management of HIV-associated focal brain lesions in developing countries.** *QJM.* 2004; **97**(7): 413–21. [PubMed Abstract](#) | [Publisher Full Text](#)
- Smego RA Jr, Orlovic D, Wadula J: **An algorithmic approach to intracranial mass lesions in HIV/AIDS.** *Int J STD AIDS.* 2006; **17**(4): 271–6. [PubMed Abstract](#) | [Publisher Full Text](#)
- Gupta M, Bajaj BK, Khwaja G: **Paradoxical response in patients with CNS tuberculosis.** *J Assoc Physicians India.* 2003; **51**: 257–60. [PubMed Abstract](#)
- Nair BR, Rajshekhkar V: **Factors Predicting the Need for Prolonged (>24 Months) Antituberculous Treatment in Patients with Brain Tuberculomas.** *World Neurosurg.* 2019; **125**: e236–e247. [PubMed Abstract](#) | [Publisher Full Text](#)
- Rajshekhkar V: **Surgery for brain tuberculosis: a review.** *Acta Neurochir (Wien).* 2015; **157**(10): 1665–78. [PubMed Abstract](#) | [Publisher Full Text](#)
- Shah I, Shetty NS: **Duration of anti-tuberculous therapy in children with persistent tuberculomas.** *SAGE Open Med Case Rep.* 2019; **7**: 2050313X18823092. [PubMed Abstract](#) | [Publisher Full Text](#) | [Free Full Text](#)
- Marais S, Roos I, Mitha A, et al.: **Presentation and outcome of patients with intracranial tuberculoma in a high HIV prevalence setting.** *International Journal of Tuberculosis and Lung Disease.* 2019[In press].
- Rich AR, McCordock HA: **The pathogenesis of tuberculous meningitis.** *Bull Johns Hopkins Hosp.* 1933; **52**: 2–37.
- Donald PR, Schaaf HS, Schoeman JF: **Tuberculous meningitis and miliary tuberculosis: the Rich focus revisited.** *J Infect.* 2005; **50**(3): 193–5. [PubMed Abstract](#) | [Publisher Full Text](#)
- Jain SK, Paul-Satyaseela M, Lamichhane G, et al.: **Mycobacterium tuberculosis invasion and traversal across an in vitro human blood-brain barrier as a pathogenic mechanism for central nervous system tuberculosis.** *J Infect Dis.* 2006; **193**(9): 1287–95. [PubMed Abstract](#) | [Publisher Full Text](#)
- Krishnan N, Robertson BD, Thwaites G: **The mechanisms and consequences of the extra-pulmonary dissemination of Mycobacterium tuberculosis.** *Tuberculosis (Edinb).* 2010; **90**(6): 361–6. [PubMed Abstract](#) | [Publisher Full Text](#)
- Davis AG, Rohlwick UK, Proust A, et al.: **The pathogenesis of tuberculous meningitis.** *J Leukoc Biol.* 2019; **105**(2): 267–80. [PubMed Abstract](#) | [Publisher Full Text](#) | [Free Full Text](#)
- Tsenova L, Bergtold A, Freedman VH, et al.: **Tumor necrosis factor alpha is a determinant of pathogenesis and disease progression in mycobacterial infection in the central nervous system.** *Proc Natl Acad Sci U S A.* 1999; **96**(10): 5657–62. [PubMed Abstract](#) | [Publisher Full Text](#) | [Free Full Text](#)
- Dastur DK, Dave UP: **Ultrastructural basis of the vasculopathy in and around brain tuberculomas. Possible significance of altered basement membrane.** *Am J Pathol.* 1977; **89**(1): 35–50. [PubMed Abstract](#) | [Free Full Text](#)
- Kumar R, Pandey CK, Bose N, et al.: **Tuberculous brain abscess: clinical**

- presentation, pathophysiology and treatment (in children). *Childs Nerv Syst.* 2002; **18**(3–4): 118–23.
[PubMed Abstract](#) | [Publisher Full Text](#)
21. Bernaerts A, Vanhoenacker FM, Parizel PM, *et al.*: Tuberculosis of the central nervous system: overview of neuroradiological findings. *Eur Radiol.* 2003; **13**(8): 1876–90.
[PubMed Abstract](#) | [Publisher Full Text](#)
 22. Arseni C: Two hundred and one cases of intracranial tuberculoma treated surgically. *J Neurol Neurosurg Psychiatry.* 1958; **21**(4): 308–11.
[PubMed Abstract](#) | [Publisher Full Text](#) | [Free Full Text](#)
 23. Poonnoose SI, Rajshekhar V: Rate of resolution of histologically verified intracranial tuberculomas. *Neurosurgery.* 2003; **53**(4): 873–8.
[PubMed Abstract](#) | [Publisher Full Text](#)
 24. Rajeswari R, Sivasubramanian S, Balambal R, *et al.*: A controlled clinical trial of short-course chemotherapy for tuberculoma of the brain. *Tuber Lung Dis.* 1995; **76**(4): 311–7.
[PubMed Abstract](#) | [Publisher Full Text](#)
 25. Deogaonkar M, De R, Sil K, *et al.*: Pituitary tuberculosis presenting as pituitary apoplexy. *Int J Infect Dis.* 2006; **10**(4): 338–9.
[PubMed Abstract](#) | [Publisher Full Text](#)
 26. Kalita J, Ranjan P, Misra UK, *et al.*: Hemichorea: a rare presentation of tuberculoma. *J Neurol Sci.* 2003; **208**(1–2): 109–11.
[PubMed Abstract](#) | [Publisher Full Text](#)
 27. Azeemuddin M, Alvi A, Sayani R, *et al.*: Neuroimaging Findings in Tuberculosis: A Single-Center Experience in 559 Cases. *J Neuroimaging.* 2019; **29**(5): 657–668.
[PubMed Abstract](#) | [Publisher Full Text](#)
 28. Sonmez G, Ozturk E, Sildiroglu HO, *et al.*: MRI findings of intracranial tuberculomas. *Clin Imaging.* 2008; **32**(2): 88–92.
[PubMed Abstract](#) | [Publisher Full Text](#)
 29. Gupta RK, Husain N, Kathuria MK, *et al.*: Magnetization transfer MR imaging correlation with histopathology in intracranial tuberculomas. *Clin Radiol.* 2001; **56**(8): 656–63.
[PubMed Abstract](#) | [Publisher Full Text](#)
 30. Patkar D, Narang J, Yanamandala R, *et al.*: Central nervous system tuberculosis: pathophysiology and imaging findings. *Neuroimaging Clin N Am.* 2012; **22**(4): 677–705.
[PubMed Abstract](#) | [Publisher Full Text](#)
 31. van Toorn R, du Plessis AM, Schaaf HS, *et al.*: Clinicoradiologic response of neurologic tuberculomass lesions in children treated with thalidomide. *Pediatr Infect Dis J.* 2015; **34**(2): 214–8.
[PubMed Abstract](#) | [Publisher Full Text](#)
 32. Anuradha HK, Garg RK, Sinha MK, *et al.*: Intracranial tuberculomas in patients with tuberculous meningitis: predictors and prognostic significance. *Int J Tuberc Lung Dis.* 2011; **15**(2): 234–9.
[PubMed Abstract](#)
 33. Awada A, Daif AK, Pirani M, *et al.*: Evolution of brain tuberculomas under standard antituberculous treatment. *J Neurol Sci.* 1998; **156**(1): 47–52.
[PubMed Abstract](#) | [Publisher Full Text](#)
 34. Haris M, Gupta RK, Husain M, *et al.*: Assessment of therapeutic response in brain tuberculomas using serial dynamic contrast-enhanced MRI. *Clin Radiol.* 2008; **63**(5): 562–74.
[PubMed Abstract](#) | [Publisher Full Text](#)
 35. Kalita J, Prasad S, Misra UK: Predictors of paradoxical tuberculoma in tuberculous meningitis. *Int J Tuberc Lung Dis.* 2014; **18**(4): 486–91.
[PubMed Abstract](#) | [Publisher Full Text](#)
 36. Man H, Sellier P, Boukobza M, *et al.*: Central nervous system tuberculomas in 23 patients. *Scand J Infect Dis.* 2010; **42**(6–7): 450–4.
[PubMed Abstract](#) | [Publisher Full Text](#)
 37. Ranjan P, Kalita J, Misra UK: Serial study of clinical and CT changes in tuberculous meningitis. *Neuroradiology.* 2003; **45**(5): 277–82.
[PubMed Abstract](#) | [Publisher Full Text](#)
 38. Tai ML, Nor HM, Kadir KA, *et al.*: Paradoxical Manifestation is Common in HIV-negative Tuberculous Meningitis. *Medicine (Baltimore).* 2016; **95**(1): e1997.
[PubMed Abstract](#) | [Publisher Full Text](#) | [Free Full Text](#)
 39. Unal A, Sutlas PN: Clinical and radiological features of symptomatic central nervous system tuberculomas. *Eur J Neurol.* 2005; **12**(10): 797–804.
[PubMed Abstract](#) | [Publisher Full Text](#)
 40. Vidal JE, Hernandez AV, Oliveira AC, *et al.*: Cerebral tuberculomas in AIDS patients: a forgotten diagnosis? *Arg Neuropsiquiatr.* 2004; **62**(3B): 793–6.
[PubMed Abstract](#) | [Publisher Full Text](#)
 41. Lesprit P, Zagdanski AM, de La Blanchardiere A, *et al.*: Cerebral tuberculosis in patients with the acquired immunodeficiency syndrome (AIDS). Report of 6 cases and review. *Medicine (Baltimore).* 1997; **76**(6): 423–31.
[PubMed Abstract](#) | [Publisher Full Text](#)
 42. Nicolls DJ, King M, Holland D, *et al.*: Intracranial tuberculomas developing while on therapy for pulmonary tuberculosis. *Lancet Infect Dis.* 2005; **5**(12): 795–801.
[PubMed Abstract](#) | [Publisher Full Text](#)
 43. Schoeman JF, Fieggen G, Sellaer N, *et al.*: Intractable intracranial tuberculous infection responsive to thalidomide: report of four cases. *J Child Neurol.* 2006; **21**(4): 301–8.
[PubMed Abstract](#) | [Publisher Full Text](#)
 44. van Toorn R, Rabie H, Dramowski A, *et al.*: Neurological manifestations of TB-IRIS: a report of 4 children. *Eur J Paediatr Neurol.* 2012; **16**(6): 676–82.
[PubMed Abstract](#) | [Publisher Full Text](#)
 45. Jain SK, Kwon P, Moss WJ: Management and outcomes of intracranial tuberculomas developing during antituberculous therapy: case report and review. *Clin Pediatr (Phila).* 2005; **44**(5): 443–50.
[PubMed Abstract](#) | [Publisher Full Text](#)
 46. Wasay M, Moolani MK, Zaheer J, *et al.*: Prognostic indicators in patients with intracranial tuberculoma: a review of 102 cases. *J Pak Med Assoc.* 2004; **54**(2): 83–7.
[PubMed Abstract](#)
 47. Pauranik A, Behari M, Maheshwari MC: Appearance of tuberculoma during treatment of tuberculous meningitis. *Jpn J Med.* 1987; **26**(3): 332–4.
[PubMed Abstract](#) | [Publisher Full Text](#)
 48. Singh AK, Malhotra HS, Garg RK, *et al.*: Paradoxical reaction in tuberculous meningitis: presentation, predictors and impact on prognosis. *BMC Infect Dis.* 2016; **16**: 306.
[PubMed Abstract](#) | [Publisher Full Text](#) | [Free Full Text](#)
 49. Narita M, Ashkin D, Hollender ES, *et al.*: Paradoxical worsening of tuberculosis following antiretroviral therapy in patients with AIDS. *Am J Respir Crit Care Med.* 1998; **158**(1): 157–61.
[PubMed Abstract](#) | [Publisher Full Text](#)
 50. Brown CS, Smith CJ, Breen RA, *et al.*: Determinants of treatment-related paradoxical reactions during anti-tuberculosis therapy: a case control study. *BMC Infect Dis.* 2016; **16**: 479.
[PubMed Abstract](#) | [Publisher Full Text](#) | [Free Full Text](#)
 51. Marais S, Meintjes G, Pepper DJ, *et al.*: Frequency, severity, and prediction of tuberculous meningitis immune reconstitution inflammatory syndrome. *Clin Infect Dis.* 2013; **56**(3): 450–60.
[PubMed Abstract](#) | [Publisher Full Text](#) | [Free Full Text](#)
 52. Walker NF, Stek C, Wasserman S, *et al.*: The tuberculosis-associated immune reconstitution inflammatory syndrome: recent advances in clinical and pathogenesis research. *Curr Opin HIV AIDS.* 2018; **13**(6): 512–21.
[PubMed Abstract](#) | [Publisher Full Text](#) | [Free Full Text](#)
 53. Schoeman JF, Van Zyl LE, Laubscher JA, *et al.*: Effect of corticosteroids on intracranial pressure, computed tomographic findings, and clinical outcome in young children with tuberculous meningitis. *Pediatrics.* 1997; **99**(2): 226–31.
[PubMed Abstract](#) | [Publisher Full Text](#)
 54. Meintjes G, Wilkinson RJ, Morroni C, *et al.*: Randomized placebo-controlled trial of prednisone for paradoxical tuberculosis-associated immune reconstitution inflammatory syndrome. *AIDS.* 2010; **24**(15): 2381–90.
[PubMed Abstract](#) | [Publisher Full Text](#) | [Free Full Text](#)
 55. Meintjes G, Stek C, Blumenthal L, *et al.*: Prednisone for the Prevention of Paradoxical Tuberculosis-Associated IRIS. *N Engl J Med.* 2018; **379**(20): 1915–25.
[PubMed Abstract](#) | [Publisher Full Text](#)
 56. World Health Organization: Treatment of tuberculosis guidelines. Fourth edition. 2010; Accessed: Sept 09 2019.
[Reference Source](#)
 57. Nahid P, Dorman SE, Alipanah N, *et al.*: Official American Thoracic Society/ Centers for Disease Control and Prevention/Infectious Diseases Society of America Clinical Practice Guidelines: Treatment of Drug-Susceptible Tuberculosis. *Clin Infect Dis.* 2016; **63**(7): e147–e95.
[PubMed Abstract](#) | [Publisher Full Text](#) | [Free Full Text](#)
 58. Thwaites G, Fisher M, Hemingway C, *et al.*: British Infection Society guidelines for the diagnosis and treatment of tuberculosis of the central nervous system in adults and children. *J Infect.* 2009; **59**(3): 167–87.
[PubMed Abstract](#) | [Publisher Full Text](#)
 59. Ravenscroft A, Schoeman JF, Donald PR: Tuberculous granulomas in childhood tuberculous meningitis: radiological features and course. *J Trop Pediatr.* 2001; **47**(1): 5–12.
[PubMed Abstract](#) | [Publisher Full Text](#)
 60. Donald PR, Van Toorn R: Use of corticosteroids in tuberculous meningitis. *Lancet.* 2016; **387**(10038): 2585–7.
[PubMed Abstract](#) | [Publisher Full Text](#)
 61. Akhaddar A: Surgical therapy. In "Tuberculosis Of The Central Nervous System: Pathogenesis, Imaging, And Management" eds M. Turgut, A. Akhaddar, A.T. Turgut, R.K. Garg. Springer. ISBN 978-3-319-50711-8, 2017; 173–191.
[Publisher Full Text](#)
 62. Schoeman JF, Van Zyl LE, Laubscher JA, *et al.*: Serial CT scanning in childhood tuberculous meningitis: prognostic features in 198 cases. *J Child Neurol.* 1995; **10**(4): 320–9.
[PubMed Abstract](#) | [Publisher Full Text](#)
 63. Thwaites GE, Macmullen-Price J, Tran TH, *et al.*: Serial MRI to determine the effect of dexamethasone on the cerebral pathology of tuberculous meningitis: an observational study. *Lancet Neurol.* 2007; **6**(3): 230–6.
[PubMed Abstract](#) | [Publisher Full Text](#) | [Free Full Text](#)
 64. Shah IA, Asimi RP, Kawoos Y, *et al.*: Tuberculomas of the brain with and without associated meningitis: a cohort of 28 cases treated with anti-tuberculosis drugs at a tertiary care centre. *International Journal of Contemporary Medical Research.* 2016; **3**(12): 3484–7.
[Reference Source](#)
 65. Idris MN, Sokrab TE, Arbab MA, *et al.*: Tuberculoma of the brain: a series of 16 cases treated with anti-tuberculosis drugs. *Int J Tuberc Lung Dis.* 2007; **11**(1): 91–5.
[PubMed Abstract](#)

66. Li H, Liu W, You C: **Central nervous system tuberculoma**. *J Clin Neurosci*. 2012; **19**(5): 691–5.
[PubMed Abstract](#) | [Publisher Full Text](#)
67. Afghani B, Lieberman JM: **Paradoxical enlargement or development of intracranial tuberculomas during therapy: case report and review**. *Clin Infect Dis*. 1994; **19**(6): 1092–9.
[PubMed Abstract](#) | [Publisher Full Text](#)
68. Bayindir C, Mete O, Bilgic B: **Retrospective study of 23 pathologically proven cases of central nervous system tuberculomas**. *Clin Neurol Neurosurg*. 2006; **108**(4): 353–7.
[PubMed Abstract](#) | [Publisher Full Text](#)
69. Gupta RK, Jena A, Singh AK, *et al.*: **Role of magnetic resonance (MR) in the diagnosis and management of intracranial tuberculomas**. *Clin Radiol*. 1990; **41**(2): 120–7.
[PubMed Abstract](#) | [Publisher Full Text](#)
70. Harder E, Al-Kawi MZ, Carney P: **Intracranial tuberculoma: conservative management**. *Am J Med*. 1983; **74**(4): 570–6.
[PubMed Abstract](#) | [Publisher Full Text](#)
71. Tandon PN, Bhargava S: **Effect of medical treatment on intracranial tuberculoma--a CT study**. *Tubercle*. 1985; **66**(2): 85–97.
[PubMed Abstract](#) | [Publisher Full Text](#)
72. Yaramis A, Gurkan F, Elevli M, *et al.*: **Central nervous system tuberculosis in children: a review of 214 cases**. *Pediatrics*. 1998; **102**(5): E49.
[PubMed Abstract](#) | [Publisher Full Text](#)
73. Monteiro R, Carneiro JC, Costa C, *et al.*: **Cerebral tuberculomas - A clinical challenge**. *Respir Med Case Rep*. 2013; **9**: 34–7.
[PubMed Abstract](#) | [Publisher Full Text](#) | [Free Full Text](#)
74. Jinks JR: **Computed tomography of intracranial tuberculosis**. *Neuroradiology*. 1991; **33**(2): 126–35.
[PubMed Abstract](#) | [Publisher Full Text](#)
75. Wasay M: **Central nervous system tuberculosis and paradoxical response**. *South Med J*. 2006; **99**(4): 331–2.
[PubMed Abstract](#) | [Publisher Full Text](#)
76. Husain N, Awasthi S, Haris M, *et al.*: **Vascular endothelial growth factor as a marker of disease activity in neurotuberculosis**. *J Infect*. 2008; **56**(2): 114–9.
[PubMed Abstract](#) | [Publisher Full Text](#)
77. Wasserman S, Davis A, Wilkinson RJ, *et al.*: **Key considerations in the pharmacotherapy of tuberculous meningitis**. *Expert Opin Pharmacother*. 2019; **20**(15): 1–5.
[PubMed Abstract](#) | [Publisher Full Text](#) | [Free Full Text](#)