

Diagnosis and management of subcutaneous implantable cardioverter-defibrillator infections based on process mapping

Larry M. Baddour MD, FIDSA, FAHA¹  | Raul Weiss MD, FACC²  |
 George E. Mark MD, FACC, FHRS³ | Mikhael F. El-Chami MD⁴  | Mauro Biffi MD⁵  |
 Vincent Probst MD⁶  | Pier D. Lambiase PhD, FRCP, FHRS⁷  | Marc A. Miller MD⁸ |
 Timothy McClernon PhD⁹ | Linda K. Hansen MPH, PhD¹⁰  | Bradley P. Knight MD,
 FACC, FHRS¹¹ 

¹Division of Infectious Diseases, Department of Medicine, and Department of Cardiovascular Diseases, Mayo Clinic College of Medicine and Science, Rochester, Minnesota

²The Ohio State University Wexner Medical Center, Cardiology, DHLRI, Columbus, Ohio

³Department of Cardiology, Cooper University Hospital, Camden, New Jersey

⁴Division of Cardiology, Section of Electrophysiology, Emory University Hospital, Atlanta, Georgia

⁵Institute of Cardiology, S. Orsola Malpighi Hospital, Bologna, Italy

⁶L'Institut du Thorax, CHU de Nantes, Cardiology, Nantes, France

⁷UCL Institute of Cardiovascular Science, and Barts Heart Center, London, UK

⁸Icahn School of Medicine at Mount Sinai, Mount Sinai Hospital, New York

⁹People Architects, Inc., Minneapolis

¹⁰Boston Scientific Corp., St. Paul, Minnesota

¹¹Center for Heart Rhythm Disorders Bluhm Cardiovascular Institute, Northwestern Memorial Hospital, Chicago, Illinois

Correspondence

Larry M. Baddour, M.D., FIDSA, FAHA, Mayo Clinic, 200 First Street SW, Rochester, MN 55905.

Email: baddour.larry@mayo.edu

Funding information

Boston Scientific Corporation

Abstract

Background: Infection is a well-recognized complication of cardiovascular implantable electronic device (CIED) implantation, including the more recently available subcutaneous implantable cardioverter-defibrillator (S-ICD). Although the AHA/ACC/HRS guidelines include recommendations for S-ICD use, currently there are no clinical trial data that address the diagnosis and management of S-ICD infections. Therefore, an expert panel was convened to develop consensus on these topics.

Methods: A process mapping methodology was used to achieve a primary goal – the development of consensus on the diagnosis and management of S-ICD infections. Two face-to-face meetings of panel experts were conducted to recommend useful information to clinicians in individual patient management of S-ICD infections.

Results: Panel consensus of a stepwise approach in the diagnosis and management was developed to provide guidance in individual patient management.

Conclusion: Achieving expert panel consensus by process mapping methodology in S-ICD infection diagnosis and management was attainable, and the results should be helpful in individual patient management.

KEYWORDS

antibiotics, diagnosis, extraction, infection, mapping, subcutaneous implantable cardioverter-defibrillator

Abbreviations: CIED, cardiovascular implantable electronic device; ICD, implantable cardioverter-defibrillator; S-ICD, subcutaneous implantable cardioverter-defibrillator; TV, transvenous.

This is an open access article under the terms of the Creative Commons Attribution-NonCommercial License, which permits use, distribution and reproduction in any medium, provided the original work is properly cited and is not used for commercial purposes.

© 2020 The Authors. *Pacing and Clinical Electrophysiology* published by Wiley Periodicals LLC

1 | INTRODUCTION

Infection is a well-recognized complication of cardiovascular implantable electronic device (CIED) implantation, and multiple risk factors associated with transvenous (TV) CIED infection have been identified.^{1,2} Complete device extraction is recommended for CIED infection with a reevaluation of device need, in part due to biofilm formation on the device surface by an infecting microbe, which is highly resistant to both host defense and antimicrobial therapy.² National trend data indicate that CIED infection has become a predominant cause of CIED TV lead extraction (~50% in 2012 vs <30% in 2006),³ which has a risk of adverse outcomes. Moreover, two different study cohorts have demonstrated an increased incidence of CIED infection over recent decades.^{4,5}

Among selected patients who meet criteria for an implantable cardioverter-defibrillator (ICD), a subcutaneous rather than TV device option has been available since 2012. AHA/ACC/HRS guidelines published in 2017 outlined recommendations for choice of a subcutaneous implantable cardioverter-defibrillator (S-ICD).⁶ These included a “Class I” recommendation for S-ICD use “in patients who meet criteria for an ICD who have inadequate vascular access or are at high risk for infection, and in whom pacing for bradycardia or VT termination or as part of CRT is neither needed nor anticipated.”

The desire to avoid a TV CIED is understandable among “high risk” patients as bloodstream infection with or without lead and/or valve involvement is common with TV CIED infections and predisposes to increased morbidity and mortality.^{7,8} CIED-related infective endocarditis, for example, has been reported in 22-41% of patients with CIED infection.^{9,10} Moreover, CIED-related infective endocarditis has been significantly associated with increased mortality in both short-term (30-days or less) and long-term (>30 days) follow-up in a multivariable model.¹¹ Of note, endovascular CIED infections have been linked to *S. aureus* in cases that are due to staphylococcal species and have a higher mortality rate (25%) as compared to coagulase-negative staphylococci etiology (9.5%).¹² S-ICD infections, in contrast, have rarely been complicated by systemic infection, which could be explained by S-ICDs having no endovascular components. While certain aspects of S-ICD infection diagnosis and management are similar to that seen with other CIEDs, S-ICD infections also have some unique features that are important to understand to optimize care in patients with CIED infection.

2 | S-ICD INFECTION RATE

S-ICD infection rates have been calculated in four large cohort studies that included patients from multiple countries¹³⁻¹⁶ during the early era of S-ICD availability (Table 1). Over follow-up periods varying from <30 days to 6.1 years post-S-ICD implantation, infection rates ranged from 1.25% at 180 days to 6.8% at 6.1 years.

It is noteworthy that the majority of S-ICD infections occur early after implantation. In the Dutch S-ICD cohort, six of eight infections seen in 118 patients occurred within the first year, with three of these reported in the first 30 days post-implantation. One of the two infec-

tions reported between years 2 and 6 occurred within one month of elective generator replacement.¹³ Similarly, in the EFFORTLESS S-ICD registry, 22 infections occurred within the first year in this cohort of 985 patients with only two additional infections reported later, one each in years 4 and 5.¹⁶ In contrast, 37% of TV-ICD infections reported in the Leiden device registry occurred after 12 months post-implant.¹⁷ The frequency of TV-ICD infections in later years suggests that the presence of TV leads poses an ongoing risk of late infection that has not been observed as frequently with S-ICD, though longer follow-up data, particularly including change-outs, are desirable. Furthermore, studies have demonstrated a learning curve associated with adoption of the S-ICD, with the number of complications, including device infection, significantly lower as an implanter gains experience¹⁸ as well as in later study quartiles of patient enrollment,¹⁹ suggesting that the early S-ICD infection rates may decline further as the device gains acceptance with more experienced implanters.

Is the CIED infection rate for S-ICD similar to that of TV CIED? This is an important question that could impact use of the above-cited clinical practice recommendations.⁶ Of note, data that address this question yield mixed results. A meta-analysis that included five case-control studies demonstrated similar ICD infection rates for subcutaneous versus TV devices.²⁰ More recently, a meta-analysis that included the same five case-control studies and five additional series was published²¹ and yielded similar results to the initial meta-analysis. However, in a subsequent review²² that included seven observational investigations that pooled data, the incidence rate ratio suggested that ICD infection was more prevalent in patients with subcutaneous versus TV-ICD.

Ultimately, large, randomized trials are needed to address the above-stated question. In this regard, data from the large, prospective, multicenter, clinical trial [PRAETORIAN; NCT01296022] that includes a comparison of device-related major adverse events, including CIED infection rates, for TV versus subcutaneous ICD in 700 randomized patients are eagerly awaited.²³ A second investigation, “ATLAS” [NCT01296022], will prospectively enroll and randomize 500 patients in several Canadian centers to evaluate S-ICD- versus TV-ICD-related outcomes, which includes device infection as a secondary outcome.²⁴ There is a concern, however, whether these two randomized trials will have adequate sample sizes to statistically compare device infection rates, based on recently published data from two large, randomized trials of TV-CIED that examined device infection prevention interventions,^{25,26} regardless of whether a device is subcutaneous or TV.

3 | METHODS

A modified process mapping methodology was employed during one initial and one follow-up face-to-face meeting of experienced electrophysiologists and an infectious diseases physician who have expertise in the field of cardiovascular device infections. Details of the modified process mapping approach have been outlined in a prior publication that examined anesthesia for S-ICD implantation.²⁷ A focused review of a stepwise approach to S-ICD infection diagnosis and management

TABLE 1 Infection complication data from four major cohorts from the United States and Europe. The number of S-ICD infection complications and extractions are presented from four large S-ICD clinical studies

Study first author/country Study name/NCT number Years of patient enrollment	Number of sites/Number of patients	Number of patients with S-ICD infection/Number with S-ICD extraction	Comments
<ul style="list-style-type: none"> Gold et al, 2019³⁷ S-ICD post-approval study/NCT01736618 2013–2016 	86/1637	44 (2.7%)/44 (2.7%)	Infection complications at 365 days post-S-ICD implantation
<ul style="list-style-type: none"> Quast AFBE, et al., 2018¹³/the Netherlands Dutch cohort study 2008–2011 	4/118	8 (6.8%)/8 (6.8%) over 6 years	Mean follow-up = 6.1 years. Eight patients had “non-systemic pocket infection”, all eight were extracted. Three infections at ≤30 days, three at >30 day and <1 year; two at >1 year
<ul style="list-style-type: none"> Weiss R, et al., 2013¹⁵/USA, UK, Netherlands, New Zealand IDE Cohort Study/NCT01064076 January 2010–October 2011 	33/321	4 (1.25%)/4 (1.25%)	Follow-up of 180 days after S-ICD implantation. Fourteen (4.36%) other patients with superficial or incisional infections with no S-ICD explantation
<ul style="list-style-type: none"> Boersma L, et al., 2017¹⁶/Europe and New Zealand (non-US) EFFORTLESS Study/NCT01085435 August 2009–December 2014 	42/985	18 (4%)/10 (2.2%)	Follow-up of 60 months after S-ICD implantation

Abbreviations: NCT, National Clinical Trial; S-ICD, subcutaneous implantable cardioverter defibrillator.

permitted input from all participants on both behavioral workflow and cognitive decision-making steps in individual patient management of S-ICD infections. Figure 1 is a portion of the map that was developed by this working group.

A literature search was also conducted on August 2, 2019 in preparation of this manuscript. A comprehensive search strategy that included the following keywords and medical subject headings was performed: defibrillators, implantable, cardiac resynchronization therapy devices, pacemaker, artificial or cardiac pacing, heart assist device, heart/artificial, cardiac device or implant, experimental, endocarditis, bacteremia, sepsis or septic, infection, surgical wound infection, prosthesis-related infection, antibiotic prophylaxis, infection, pocket, subcutaneous, and cardiovascular implantable electronic device. Ovid MEDLINE (<1946 to August 1, 2019), Embase (<1974 to 2019 week 30), and SCOPUS (>1989) were used, and only English language articles were identified (see Appendix). The titles and abstracts of all published articles were reviewed and used to identify pertinent articles for complete individual review and possibly other published manuscripts that required individual evaluation by hand. Case reports and conference abstracts were excluded in the search.

4 | DIAGNOSIS

S-ICD infection presents with pocket site and/or parasternal lead incision site inflammatory changes, with or without local pain or discomfort. The presentation of pocket infections in S-ICD mirrors that of TV-ICD or other CIED pocket infections, which include swelling, erythema, or drainage. Wound dehiscence can occur and be a complication of infection or of poor wound healing with S-ICD infection as a secondary event, particularly with device exposure. Unique to the S-ICD patient, signs and/or symptoms along the subcutaneous lead

track may be indicative of lead infection. In contrast to some patients with TV CIED infections, “systemic” S-ICD infection has rarely been reported; nonetheless, signs of bacteremia (fever, chills, shock) should be included in patient assessments. In a large Dutch cohort,¹³ eight patients developed localized pocket infections that ultimately required S-ICD extraction; no systemic infections were identified. In a small case series,²⁸ two patients had “systemic” manifestations of S-ICD infection, but only one of the two patients had positive blood cultures. Both patients required chronic hemodialysis for end-stage renal disease and had insulin-dependent diabetes mellitus. While there were implant site findings consistent with S-ICD infection, there was no mention of whether fever or chills had been present. Certainly, it is understandable that “systemic” infection would be uncommon in patients with S-ICD since it has no endovascular component. Thus, except for an extremely rare exception, blood cultures will not be helpful in securing a diagnosis of S-ICD infection.

As etiologies other than CIED infection (Figure 2A, B) can cause inflammatory changes at the pocket and incision sites,²⁹ the diagnosis of S-ICD infection, as with other CIED infections, can be difficult. Superficial skin and soft tissue infection (eg, cellulitis, stitch abscess) can occur, and non-infectious syndromes due to allergic reactions to components of the device or tape, glue, or dressing used at an incision site, hematoma formation, and nonspecific postoperative changes are some of the conditions that have to be considered in the management of patients in the early postoperative period following S-ICD placement. In cases where a diagnosis is not established, serial cell phone pictures may be helpful in establishing a diagnosis over time and can be part of an electronic-health record for the respective patient. In addition, “before and after” pictures can be useful in patients administered empiric oral antibiotic therapy (see Section 5) to assist in monitoring response to therapy.

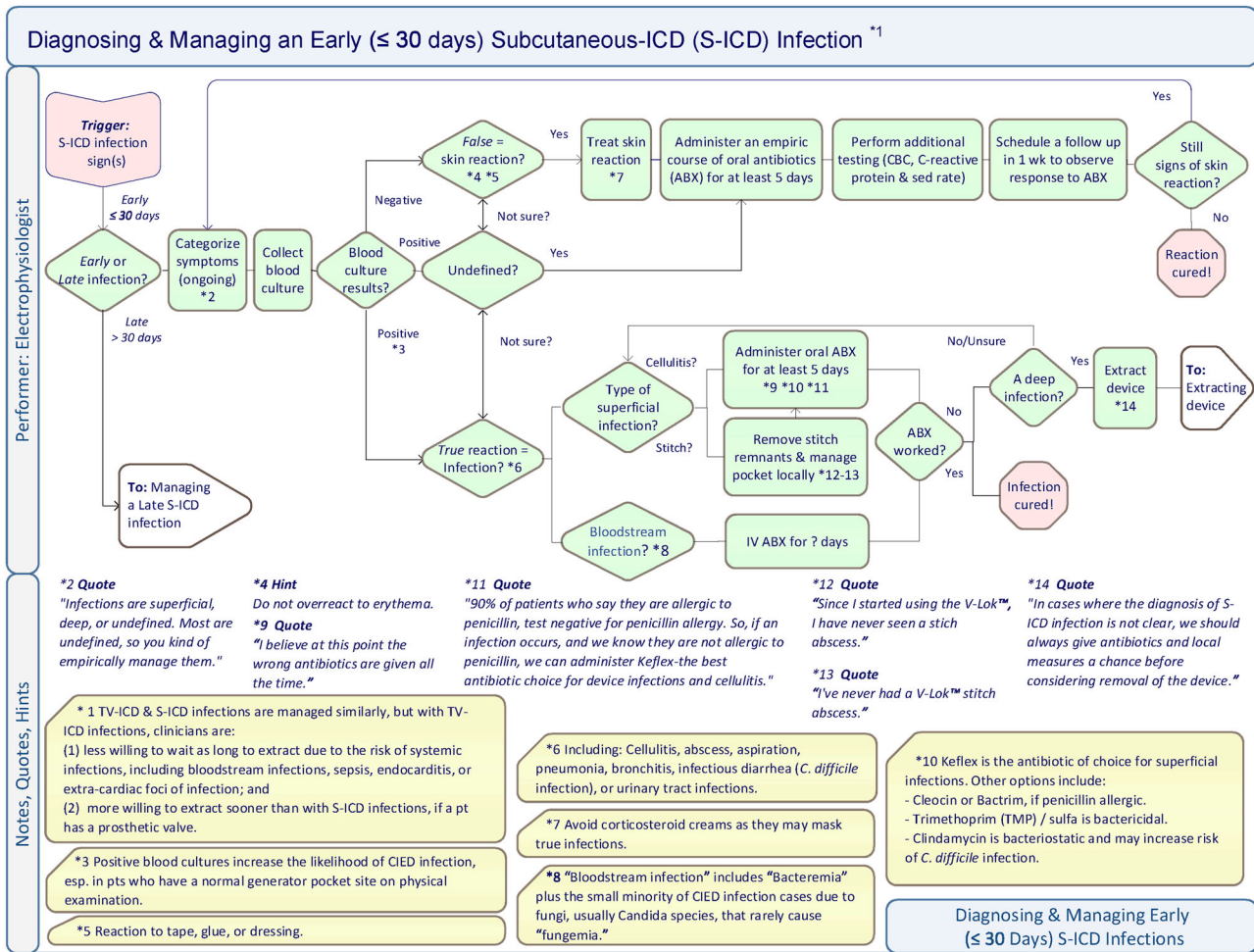


FIGURE 1 Process map for diagnosing and managing an early S-ICD infection. The steps in diagnosing and managing a possible infection of an implanted S-ICD are delineated, along with suggestions and quotes from the physician panel during the mapping process. Abbreviations: ABX, antibiotics; CBC, complete blood count; CIED, cardiovascular implantable electronic device; S-ICD, subcutaneous implantable cardioverter defibrillator; TV-ICD, transvenous implantable cardioverter defibrillator [Color figure can be viewed at wileyonlinelibrary.com]

In the absence of purulent drainage for culture, an etiologic diagnosis of infection is uncommon in the early postoperative period following S-ICD implantation, unless device removal is performed. Inflammatory markers (CRP, ESR) and CBC should be obtained but are not specific. Blood cultures, as stated above, will generally not be helpful in securing a device infection diagnosis since S-ICD infection remains localized to the subcutaneous tissue of the implant site, with rare exception. Due to the proximity of surgery in an early presentation, radiologic, ultrasonography, and nuclear medicine studies are also not likely to be useful in confirming a diagnosis of S-ICD infection.

S-ICD infection can be delayed (>30 days) in onset following device implantation with pocket site and/or lead incision site manifestations similar to that of early S-ICD infections. In cases where the diagnosis of S-ICD infection is in question, imaging studies, which may have been compromised by the proximity of implantation time to presentation in early infections, may be important in supporting a diagnosis in late infections. Ultrasound, ¹⁸F-FDG PET/CT, and indium white blood

cell imaging have been used to support or refute a diagnosis of CIED infection. ¹⁸F-FDG PET/CT, in particular, has garnered considerable attention as a diagnostic tool in confirmation of CIED infection.³⁰ Of note, the ¹⁸F-FDG is a measure of increased metabolic activity, rather than a direct measure of inflammation or macrophage activity, and now ¹⁸F-FDG/CT is commonly used in difficult-to-diagnose cases of possible CIED infection. Results of a systematic review and meta-analysis that included 11 studies demonstrated a pooled sensitivity and pooled specificity of 87% (95% confidence interval, 82-91%) and 94% (95% CI, 88-98%), respectively, regarding the diagnostic accuracy of ¹⁸F-FDG PET/CT in the diagnosis of CIED infection.^{31,32} In a sub-analysis, the location of CIED infection (pocket versus lead- or valve-related) impacted the sensitivity and specificity of ¹⁸F-FDG PET/CT in the diagnosis of CIED infection with higher values for pocket site infections.

Pocket tissue and the extracted ICD should be sent for microbiologic evaluation, including culture. A sonication procedure of the device in Ringer's solution is used to disrupt biofilm and enhance culture results in the etiologic diagnosis of CIED infections.³³

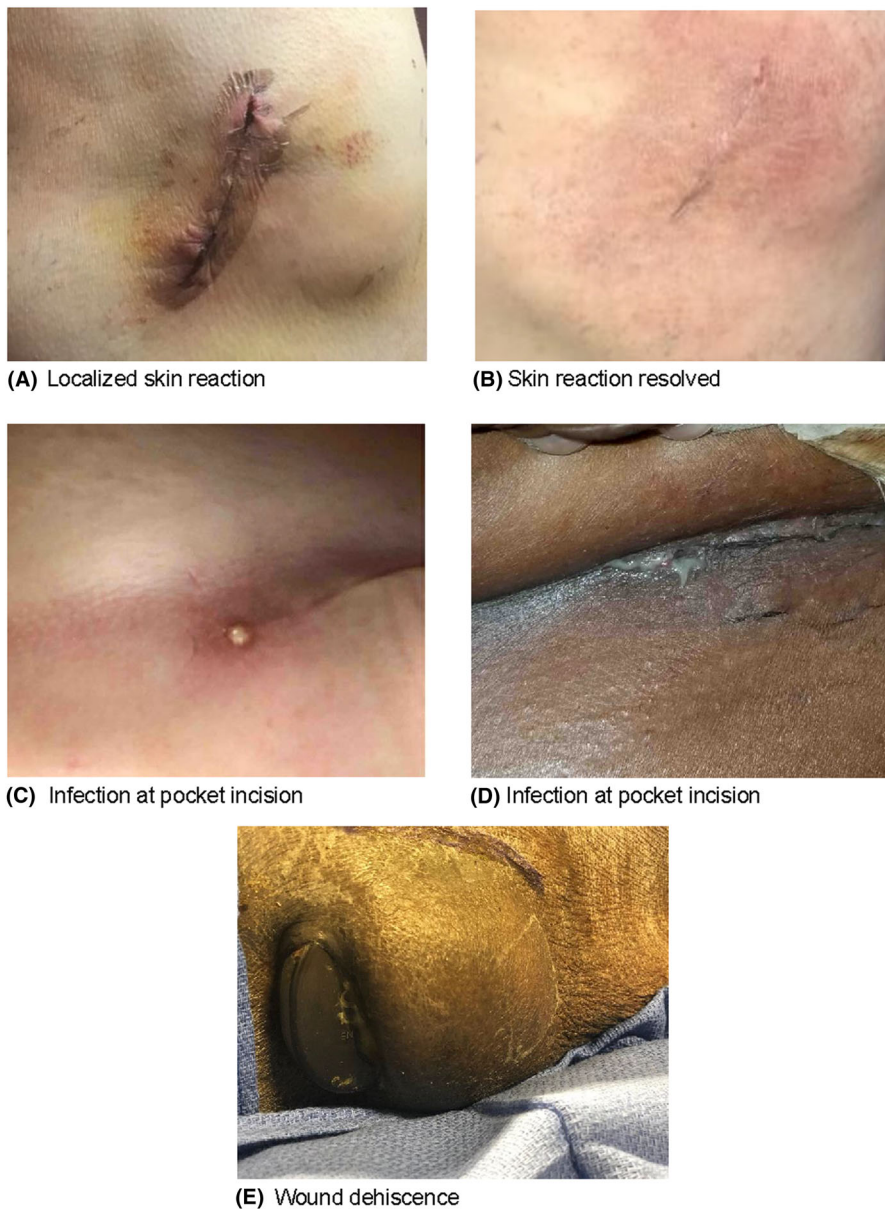

FIGURE 2 Examples of infection and non-infection reactions at S-ICD implant sites. A, Noninfection localized skin reaction at 5 days post-implant. B, Same site as in (A) at 14 days. (Photo credit: George Mark, MD, FACC, FHRS, Cooper University Hospital). C, Pocket infection. 36-year-old woman with congenital heart disease two weeks postimplant. The superficial infection resolved with oral antibiotics without the need for device removal. (Photo credit: Bridget Loftus, RN, Northwestern Memorial Hospital). D, Pocket infection. 56-year-old woman with morbid obesity and heart failure fifteen days postimplant. There were no systemic symptoms. The infection resolved, and the incision healed with local wound care measures without the need for antibiotic therapy or device removal. (Photo credit: Jeremiah Wasserlauf, MD, MS, Northwestern Memorial Hospital). E, Wound dehiscence with negative blood culture and positive wound culture for methicillin-susceptible *Staphylococcus aureus*; device explanted four months after implant. Prior TV-ICD infection with bacteremia and endocarditis followed by device explantation 2 years prior to S-ICD implant. (Photo credit: Marc A. Miller, MD, Icahn School of Medicine at Mount Sinai)

5 | MANAGEMENT

Currently, there are no clinical trial data that can be used to develop an optimal management strategy for either TV or subcutaneous CIED infections. Moreover, several of the tenets of TV-CIED infection management have been applied to S-ICD infection because the experience with S-ICD infection is more limited. One overarching theme for CIED infection management has been that complete removal of a device

(generator and leads) is strongly recommended (Class I recommendation) for attempted infection cure.¹ A major limitation has been in cases where, despite investigation, S-ICD infection is suspect, but the diagnosis is not conclusive. These cases are commonly seen and unless there are systemic manifestations of infection or rapidly progressive implant site changes, a period of observation, with or without empiric antibiotic therapy, is reasonable, rather than proceeding to S-ICD removal (Figure 2C, D).

5.1 | Early (≤ 30 days post implantation)

In cases where S-ICD infection is not obvious, an oral antibiotic, often cephalexin, is used as empiric treatment of superficial skin and soft tissue infection for approximately 7-10 days to determine if local axillary findings improve or resolve. Trimethoprim/sulfamethoxazole is a treatment option for patients with a history of IgE-mediated penicillin or cephalosporin allergy. Clindamycin is another treatment option in penicillin-allergic patients, but it is not favored for use due to its increased risk of *Clostridioides difficile* infection. If not done previously, allergy consultation should also be obtained to evaluate the history of beta-lactam allergy, since antibiotic therapy may be needed subsequently, and antibiotic prophylaxis will be indicated for future new CIED implantation. Because systemic infection, which is characterized by increased morbidity and mortality, is an extremely rare event complicating S-ICD implantation, a trial of empiric oral antibiotic therapy is reasonable as an initial first step in the treatment of cases that are not initially diagnosed as definite S-ICD infection or as another diagnosis in the differential. Close monitoring is warranted among patients who receive empiric treatment. This can include “before and after” cellular telephone pictures to aid in gauging changes in local implant site findings, but these do not obviate the need for serial patient clinic visits. During this time, all topically applied ointments to sternal and generator implant site areas should be discontinued or avoided; this includes antimicrobial- or corticosteroid-containing products, since the former can cause allergic reactions and the latter can mask infection manifestations.

If local implant site changes worsen or systemic symptoms develop, then complete S-ICD system removal should be undertaken. Deep tissue and device cultures should be obtained at extraction to identify a pathogen(s) and if isolated, obtain in vitro susceptibility screening to assist in subsequent selection of antimicrobial therapy. Of note, sonication of the extracted device can improve culture results, if locally available. Antimicrobial therapy should be administered, either by parenteral or oral route or a combination of both, for a total of 10-14 days. Although an extremely rare complication, if bloodstream infection is documented, then antimicrobial therapy may have to be extended, depending on pathogen recovered and whether there are other complications, such as infective endocarditis or musculoskeletal infection.

An individualized approach to patient management will be required for a subset of patients in whom the diagnosis of S-ICD infection remains a conundrum despite serial evaluation and empiric antibiotic therapy. This approach requires an ongoing evaluation of patient-, device-, and procedure-related factors to determine whether complete device extraction should be done.

5.2 | Late (> 30 days post implantation)

Due to the limited use of S-ICD to date, a profile of the frequency of causes of implant site changes that are characteristic of late S-ICD infections is not available. Moreover, evaluation of changes by local clinicians, rather than by physicians experienced in management of

CIED infections, may be initially performed and can result in deviations from optimal management strategies.

Device erosion, which has been seen in late TV CIED infections, is also a presentation seen with late S-ICD infections and requires complete device removal (Figure 2E). Superficial infection is less likely to be a cause of inflammatory changes of the implant site in the late period and system infection should be strongly considered. In these cases, imaging is often used to investigate whether there is evidence for S-ICD infection (see “DIAGNOSIS” above). Increased adoption of intermuscular S-ICD generator placement³⁴ may be operative in reducing skin erosion, which is more often associated with late infections, and the overall device infection rate, although data are limited to date.

In cases where implant site changes are acute and worsening, complete device removal is warranted. In indolent cases, an individualized approach that includes imaging procedures with multispecialty consultation is needed. In these cases, imaging studies should be obtained. Avoidance of empiric antibiotic therapy is necessary as it could interfere with the sensitivity of imaging.

5.3 | Complete Device Removal

Once S-ICD system infection is diagnosed, complete device removal (i.e., both lead and generator) is recommended to achieve cure. Risk of infection relapse is increased when partial device removal or no removal is performed. Timing of device removal is predicated, in part, on the clinical status of the patient. Since systemic infection is extremely rare with S-ICD infection, elective admission within 2-3 days for complete S-ICD extraction should be performed with scheduling for extraction in the electrophysiology or catheterization laboratory. If systemic infection is present, based on a patient’s clinical features, then emergent surgery for device extraction will be required. Infectious Diseases and Anesthesia evaluations should be obtained with baseline laboratory studies (including CBC and at least two sets of blood cultures drawn from separate peripheral venous sites). The first dose of antibiotic treatment can be withheld in patients without evidence of systemic infection until extraction is completed with tissue and device gram stain and cultures obtained, as outlined above (see Section 4). Intravenous vancomycin is one treatment option since the majority ($>60\%$) of CIED infections are due to staphylococcal species, some of which are methicillin- (and cefazolin-) resistant.

S-ICD removal typically does not require specialized equipment or unique skill set. There is one case report of an S-ICD electrode requiring a mechanical sheath for removal due to fibrosis around the coil and distal tip.³⁵ In addition, without the risk of vascular tears during extraction, as seen during TV lead extraction, the need for on-call cardiovascular surgeons during lead extraction is not required as it is with TV lead extraction. Therefore, more EPs are involved in S-ICD system extraction as compared to the number who perform TV device removal. Initially, the S-ICD is deactivated before the axillary pocket, and the xiphoid incision are opened with removal of the device and tissue debridement. A superior sternal incision should also be opened, if present. Deep tissue and the device should be collected for

microbiologic studies. A drain could be placed in the pocket site, and the incisions should be closed.

Prior to patient discharge, a reevaluation for the need of an S-ICD should be performed. If there is no plan to place a new CIED at a later date, then the patient can be discharged with a wound check scheduled within 1-2 weeks. For patients who will require a new device, an evaluation for wearable defibrillator use and future ICD placement is needed with outpatient evaluation by an infectious disease specialist in approximately 6 weeks to evaluate for clearance of infection and timing of new device placement. In addition, determination of an antibiotic regimen for surgical site infection prophylaxis should be performed. Electrophysiology follow-up should be done for preoperative evaluation for new CIED placement. Successful replacement of another S-ICD following removal and antibiotic treatment of infected S-ICDs has been described.³⁶

6 | CONCLUSION

The S-ICD is a novel device with distinct advantages for many ICD-indicated patients. Although device infection remains a potential complication of S-ICD use, unlike TV-ICD, systemic infections are rare. Of note, if S-ICD infection does occur, then systemic infection has been an extremely rare event, unlike that seen in recipients of TV-ICD, which can be complicated by bloodstream infection with or without lead-related infection or valvular endocarditis. Because of this, the diagnosis and management of S-ICD infection requires a different approach than that used in TV ICD infection. Currently, two prospective, randomized clinical trials comparing S-ICD and TV-ICD outcomes that include 1200 patients are being conducted, which may determine if the risk of S-ICD infection is different than that of TV ICD infection.^{23,24}

DISCLOSURES

The expert panel mapping program was developed and conducted by Timothy McClernon, PhD (managing partner at People Architects, Inc.) and was sponsored by Boston Scientific, Inc. Dr Baddour reports royalty payments from UpToDate, Inc., and consulting payments from Boston Scientific. Dr Weiss receives honoraria for speaking and serving as a consultant, and institution receives fellowship support from Boston Scientific, Medtronic, Biotronik, and Biosense Webster. Drs Mark, Biffi, and Probst report no disclosures. Dr El-Chami receives Honoraria for consulting for Medtronic and Boston Scientific. Dr Lambiase reports speaker, advisory fees and research grants from Boston Scientific and is supported by UCL Biomedicine and NIHR. Dr Miller received consulting fees and grant support from Boston Scientific. Dr Hansen receives salary from Boston Scientific. Dr Knight receives honoraria for consulting and speaking for Medtronic Inc. and Boston Scientific.

ACKNOWLEDGMENTS

The authors are grateful to Patricia J. Erwin, M.L.S. (Mayo), for her expertise in the literature review, Sharon Gohman (Boston Scien-

tific) for concept development, and Bridget Loftus, RN, and Jeremiah Wasserlauf, MD, MS (Northwestern Memorial Hospital) for providing infection images.

AUTHOR CONTRIBUTIONS

Study concept/design: Baddour, Weiss, Mark, El-Chami, McClernon, Knight. Analysis and interpretation of data: Baddour, Weiss, Mark, El-Chami, Biffi, Probst, Lambiase, Miller, McClernon, Hansen, Knight. Literature review: Baddour. Drafting of the manuscript: Baddour. Critical revision of the manuscript for important intellectual content: Baddour, Weiss, Mark, El-Chami, Biffi, Probst, Lambiase, Miller, McClernon, Hansen, Knight.

ORCID

Larry M. Baddour MD, FIDSA, FAHA 

<https://orcid.org/0000-0002-4473-7077>

Raul Weiss MD, FACC 

<https://orcid.org/0000-0003-1489-4028>

Mikhael F. El-Chami MD 

<https://orcid.org/0000-0003-4978-7177>

Mauro Biffi MD 

<https://orcid.org/0000-0003-4590-8584>

Vincent Probst MD 

<https://orcid.org/0000-0002-5492-8619>

Pier D. Lambiase PhD, FRCP, FHRS 

<https://orcid.org/0000-0002-9055-9267>

Linda K. Hansen MPH, PhD 

<https://orcid.org/0000-0003-3651-0419>

Bradley P. Knight MD, FACC, FHRS 

<https://orcid.org/0000-0002-2129-0401>

REFERENCES

- Baddour LM, Cha YM, Wilson WR. Clinical practice. Infections of cardiovascular implantable electronic devices. *N Engl J Med*. 2012;367:842-849.
- DeSimone DC, Sohail MR. Infection Management. *Card Electrophysiol Clin*. 2018;10:601-607.
- Deshmukh A, Patel N, Noseworthy PA, et al. Trends in use and adverse outcomes associated with transvenous lead removal in the United States. *Circulation*. 2015;132:2363-2371.
- Greenspon AJ, Patel JD, Lau E, et al. 16-year trends in the infection burden for pacemakers and implantable cardioverter-defibrillators in the United States 1993 to 2008. *J Am Coll Cardiol*. 2011;58:1001-1006.
- Dai M, Cai C, Vaibhav V, et al. Trends of cardiovascular implantable electronic device infection in 3 decades: a population-based study. *JACC Clin Electrophysiol*. 2019;5:1071-1080.
- Al-Khatib SM, Stevenson WG, Ackerman MJ, et al. AHA/ACC/HRS guideline for management of patients with ventricular arrhythmias and the prevention of sudden cardiac death: executive summary: a report of the American College of Cardiology/American Heart Association Task Force on Clinical Practice Guidelines and the Heart Rhythm Society. *Heart Rhythm*. 2017;15:e190-e252.
- Kusumoto FM, Schoenfeld MH, Wilkoff BL, et al. HRS expert consensus statement on cardiovascular implantable electronic device lead management and extraction. *Heart Rhythm*. 2017;14:e503-e551.
- Baddour LM, Epstein AE, Erickson CC, et al. Update on cardiovascular implantable electronic device infections and their management: a

- scientific statement from the American Heart Association. *Circulation*. 2010;121:458-477.
9. Le KY, Sohail MR, Friedman PA, et al. Clinical predictors of cardiovascular implantable electronic device-related infective endocarditis. *Pacing and Clin Electrophysiol*. 2011;34:450-459.
 10. Tarakji KG, Chan EJ, Cantillon DJ, et al. Cardiac implantable electronic device infections: presentation, management, and patient outcomes. *Heart Rhythm*. 2010;7:1043-1047.
 11. Habib A, Le KY, Baddour LM, et al. Predictors of mortality in patients with cardiovascular implantable electronic device infections. *Am J Cardiol*. 2013;111:874-879.
 12. Le KY, Sohail MR, Friedman PA, et al. Clinical features and outcomes of cardiovascular implantable electronic device infections due to staphylococcal species. *Am J Cardiol*. 2012;110:1143-1149.
 13. Quast ABE, van Dijk VF, Yap SC, et al. Six-year follow-up of the initial Dutch subcutaneous implantable cardioverter-defibrillator cohort: long-term complications, replacements, and battery longevity. *J Cardiovasc Electrophysiol*. 2018;29:1010-1016.
 14. Gold MR, Aasbo JD, El-Chami MF, et al. Subcutaneous implantable cardioverter-defibrillator post-approval study: clinical characteristics and perioperative results. *Heart Rhythm*. 2017;14:1456-1463.
 15. Weiss R, Knight BP, Gold MR, et al. Safety and efficacy of a totally subcutaneous implantable-cardioverter defibrillator. *Circulation*. 2013;128:944-953.
 16. Boersma L, Barr C, Knops R, et al. Implant and midterm outcomes of the subcutaneous implantable cardioverter-defibrillator registry: the EFFORTLESS study. *J Am Coll Cardiol*. 2017;70:830-841.
 17. Lekkerkerker JC, vanNieuwkoop C, Trines SA, et al. Risk factors and time delay associated with cardiac device infections: leiden device registry. *Heart (British Cardiac Society)*. 2009;95:715-720.
 18. Knops RE, Brouwer TF, Barr CS, et al. The learning curve associated with the introduction of the subcutaneous implantable defibrillator. *Europace*. 2016;18:1010-1015.
 19. Burke MC, Gold MR, Knight BP, et al. Safety and efficacy of the totally subcutaneous implantable defibrillator: 2-year results from a pooled analysis of the IDE study and EFFORTLESS registry. *J Am Coll Cardiol*. 2015;65:1605-1615.
 20. Basu-Ray I, Liu J, Jia X, et al. Subcutaneous versus transvenous implantable defibrillator therapy: a meta-analysis of case-control studies. *JACC Clin Electrophysiol*. 2017;3:1475-1483.
 21. Leon Salas B, Trujillo-Martin MM, Garcia Garcia J, et al. Subcutaneous implantable cardioverter-defibrillator in primary and secondary prevention of sudden cardiac death: a meta-analysis. *Pacing Clin Electrophysiol*. 2019;42:1253-1266.
 22. Baalman SWE, Quast ABE, Brouwer TF, Knops RE. An overview of clinical outcomes in transvenous and subcutaneous ICD patients. *Curr Cardiol Rep*. 2018;20:72.
 23. Olde Nordkamp LR, Knops RE, Bardy GH, et al. Rationale and design of the PRAETORIAN trial: a prospective, randomized comparison of subcutaneous and transvenous implantable cardioverter-defibrillator therapy. *Am Heart J*. 2012;163:753-760.e2.
 24. Mondesert B, Bashir J, Philippon F, et al. Rationale and design of the randomized prospective ATLAS study: avoid transvenous leads in appropriate subjects. *Am Heart J*. 2019;207:1-9.
 25. Krahn AD, Longtin Y, Philippon F, et al. Prevention of arrhythmia device infection trial: the PADIT trial. *J Am Coll Cardiol*. 2018;72:3098-3109.
 26. Tarakji KG, Mittal S, Kennergren C, et al. Antibacterial envelope to prevent cardiac implantable device infection. *New Engl J Med*. 2019;380:1895-1905.
 27. Essandoh MK, Mark GE, Aasbo JD, et al. Anesthesia for subcutaneous implantable cardioverter-defibrillator implantation: perspectives from the clinical experience of a U.S. panel of physicians. *Pacing Clin Electrophysiol*. 2018. 41:807-816.
 28. Looser PM, Saleh L, Thomas G, Cheung JW. Systemic infection due to subcutaneous implantable cardioverter-defibrillator implantation: importance of early recognition and treatment of device pocket-related complications. *HeartRhythm Case Rep*. 2017;3:40-42.
 29. Korantzopoulos P, Plakoutsi S, Florou E, Bechlioulis A. Skin lesions over the pocket area that may mimic cardiac implantable electronic device infection: a case series. *Pacing Clin Electrophysiol*. 2018;41:897-901.
 30. Chen W, Sajadi MM, Dilsizian V. Merits of FDG PET/CT and functional molecular imaging over anatomic imaging with echocardiography and CT angiography for the diagnosis of cardiac device infections. *JACC Cardiovasc Imaging*. 2018;11:1679-1691.
 31. Mahmood M, Kendi AT, Farid S, et al. Role of (18)F-FDG PET/CT in the diagnosis of cardiovascular implantable electronic device infections: a meta-analysis. *J Nucl Cardiol*. 2019;26:958-970.
 32. Juneau D, Golfam M, Hazra S, et al. Positron emission tomography and single-photon emission computed tomography imaging in the diagnosis of cardiac implantable electronic device infection: a systematic review and meta-analysis. *Circ Cardiovasc Imaging*. 2017;10:1-11.
 33. Nagpal A, Patel R, Greenwood-Quaintance KE, et al. Usefulness of sonication of cardiovascular implantable electronic devices to enhance microbial detection. *Am J Cardiol*. 2015;115:912-917.
 34. Viani S, Migliore F, Tola G, et al. Use and outcomes of subcutaneous implantable cardioverter-defibrillator (ICD) after transvenous ICD extraction: an analysis of current clinical practice and a comparison with transvenous ICD reimplantation. *Heart Rhythm*. 2019;16:564-571.
 35. Ip JE. Technique for subcutaneous implantable cardioverter-defibrillator extraction. *J Cardiovasc Electrophysiol*. 2019;30:789-791.
 36. Brouwer TF, Driessen AHG, Olde Nordkamp LRA, et al. Surgical management of implantation-related complications of the subcutaneous implantable cardioverter-defibrillator. *JACC Clin Electrophysiol*. 2016;2:89-96.
 37. Gold MR, Aasbo JD, Weiss R, et al. Infection predictors and outcomes in subcutaneous implantable cardioverter defibrillator patients. *Heart Rhythm*. 2019;16:S162.

SUPPORTING INFORMATION

Additional supporting information may be found online in the Supporting Information section at the end of the article.

How to cite this article: Baddour LM, Weiss R, Mark GE, et al. Diagnosis and management of subcutaneous implantable cardioverter-defibrillator infections based on process mapping. *Pacing Clin Electrophysiol*. 2020;43:958-965. <https://doi.org/10.1111/pace.13902>

APPENDIX

Literature Search Strategy

A literature search was conducted on August 2, 2019, to identify relevant articles, using the search strategy identified herein. Ovid MEDLINE (<1946 to August 1, 2019), Embase (<1974 to 2019 week 30), and SCOPUS (>1989) were used and only English language articles were identified. Case reports and conference abstracts were excluded. The number of references found is presented in parenthesis at the end of each search line.