

# Osteochondral scaffolds for early treatment of cartilage defects in osteoarthritic joints: from bench to clinic

Maryam Tamaddon<sup>1</sup>, Helena Gilja<sup>1</sup>, Ling Wang<sup>2</sup>, J. Miguel Oliveira<sup>3,4,5</sup>, Xiaodan Sun<sup>6</sup>, Rongwei Tan<sup>7</sup>, Chaozong Liu<sup>1,\*</sup>

## Key Words:

cartilage injury; osteoarthritis; osteochondral scaffold; regenerative medicine; subchondral defect; tissue engineering

## From the Contents

<b>Introduction</b>	<b>3</b>
<b>The Current State of the Art of Osteoarthritis Treatment</b>	<b>6</b>
<b>Osteochondral Scaffold: From Bench to the Clinics</b>	<b>8</b>
<b>Challenges and Opportunities in the Early Treatment of Osteoarthritis</b>	<b>12</b>
<b>Perspective Insight</b>	<b>13</b>

## ABSTRACT

Osteoarthritis is a degenerative joint disease, typified by the loss in the quality of cartilage and bone at the interface of a synovial joint, resulting in pain, stiffness and reduced mobility. The current surgical treatment for advanced stages of the disease is joint replacement, where the non-surgical therapeutic options or less invasive surgical treatments are no longer effective. These are major surgical procedures which have a substantial impact on patients' quality of life and lifetime risk of requiring revision surgery. Treatments using regenerative methods such as tissue engineering methods have been established and are promising for the early treatment of cartilage degeneration in osteoarthritic joints. In this approach, 3-dimensional scaffolds (with or without cells) are employed to provide support for tissue growth. However, none of the currently available tissue engineering and regenerative medicine products promotes satisfactory durable regeneration of large cartilage defects. Herein, we discuss the current regenerative treatment options for cartilage and osteochondral (cartilage and underlying subchondral bone) defects in the articulating joints. We further identify the main hurdles in osteochondral scaffold development for achieving satisfactory and durable regeneration of osteochondral tissues. The evolution of the osteochondral scaffolds – from monophasic to multiphasic constructs – is overviewed and the osteochondral scaffolds that have progressed to clinical trials are examined with respect to their clinical performances and their potential impact on the clinical practices. Development of an osteochondral scaffold which bridges the gap between small defect treatment and joint replacement is still a grand challenge. Such scaffold could be used for early treatment of cartilage and osteochondral defects at early stage of osteoarthritis and could either negate or delay the need for joint replacements.

## \*Corresponding author:

Chaozong Liu,  
chaozong.liu@ucl.ac.uk.

<http://doi.org/10.3877/cma.j.issn.2096-112X.2020.01.002>

## How to cite this article:

Tamaddon, M.; Gilja, H.; Wang, L.; Oliveira, J.; Sun, X.; Tan, R.; Liu, C. Osteochondral scaffolds for early treatment of cartilage defects in osteoarthritic joints: from bench to clinic. *Biomater Transl.* 2020, 1(1), 3-17.



## Introduction

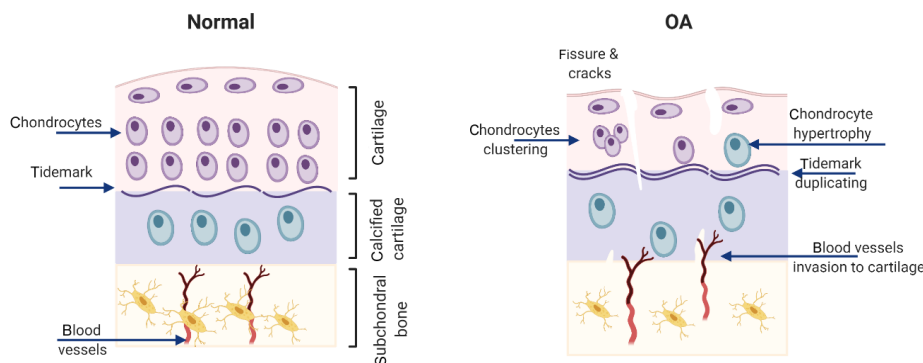
Osteoarthritis (OA) is a degenerative joint disease, typified by a loss of quality of cartilage and bone at the interface of a joint, resulting in pain, stiffness and reduced mobility. So far, the joint disease affects around 400 million people worldwide, representing an enormous socioeconomic challenge.<sup>1</sup> Historically, OA had been looked into from cartilage-centred view, but increasing evidence suggests that it should be considered as a “whole joint disease”, even though some controversy still exists regarding the cascade of the pathological processes involved.<sup>2,3</sup> Articular cartilage, subchondral bone and calcified cartilage are three constituents of the joint forming a bio-composite unit, defined as osteochondral (OC) unit, possessing the unique ability to transfer loads during

weight-bearing and joint movements. OC unit has a thickness of around 3–5 mm in adults. The OC unit consists of 90% articular cartilage, 5% of the calcified cartilage and the remaining 5% the subchondral bone plate.<sup>4</sup> Any alteration or disruption to this unit, the constituents or their interface can result in “joint failure” and development of clinical features of OA.<sup>5</sup>

OA is characterised by an unbalanced degeneration and regeneration of articular cartilage and bone, where the intrinsic repair mechanisms are insufficient. Mechanisms that can cause OA are beginning to be understood. There is a genetic component with around 40–60% heritable involvement.<sup>6</sup> The model is of multiple gene expression to various strengths combining with environmental factors.

The environment can be manifest by direct damage such as trauma or more subtle changes in morphology and mechanical alignment and loading. During the evolution of OA (**Figure 1**), cartilage degradation

could be initiated with an increase in cartilage water content due to loss of PG negative charge, resulting in swelling of the matrix, which gradually progresses from the superficial zone to the deeper zones of cartilage.<sup>7</sup>



**Figure 1.** Changes in the osteochondral unit in osteoarthritic joints. Cartilage thinning, blood vessels infiltration into cartilage and subchondral plate thickening with the progress of osteoarthritis (OA). Created with BioRender.com.

A group of inflammatory cytokines, such as  $TNF\alpha$  and members of the interleukin family shifts the chondrocytes away from a homeostatic state.<sup>8</sup> In an effort to maintain this homeostasis, there is an enhanced matrix remodeling in both cartilage and bone. Articular chondrocytes increase the synthesis of matrix molecules but also the synthesis of proinflammatory cytokines including interleukin-1 and tissue destructive enzymes such as matrix metalloproteinases and a disintegrin and metalloproteinase with thrombospondin motifs, which contribute to their destruction.<sup>9</sup> The cells start to express molecules that are associated with chondrocyte hypertrophy, such as vascular endothelial growth factor, runt-related transcription factor 2 and matrix metalloproteinase-13. This leads to cartilage calcification and thinning of the articular surface.<sup>9</sup>

In subchondral bone, altered cellular function and increased remodelling lead to decreased bone density.<sup>10,11</sup> As OA progresses, repetitive loading causes an imbalance between anabolic and catabolic chondrocyte activity. These changes are associated with the development of surface fibrillation, increased collagen breakdown and fragmentation of the matrix, causing microcracks on the surface of the cartilage.<sup>2</sup> Infiltration of blood vessels into cartilage and thickening of the cortical plate occurs in subchondral bone, with subsequent development of bone cysts, osteophytes and deformations of subchondral bone contours.<sup>10,11</sup>

In the late-stage of OA, chondrocyte apoptosis and development of chondrocyte clusters occur. In addition, chondrocytes undergo hypertrophic differentiation in the deeper zones of the cartilage. Osteophytes and bone cysts develop in subchondral bone, and bone attrition occurs (altered bone contour, flattening and deformation of the cortical plate). With OA disease progression calcified cartilage and subchondral bone are exposed due to cartilage loss caused by deep fissures, duplication of the tidemark

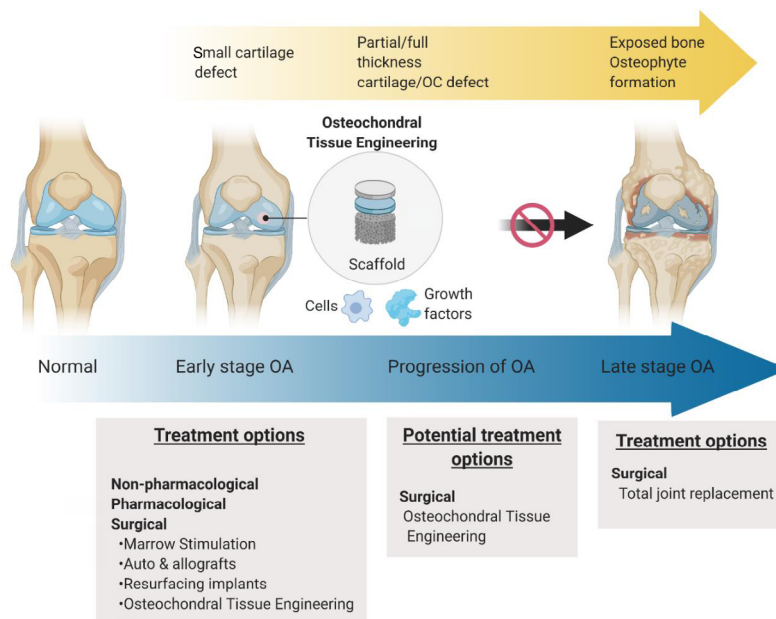
and new bone formation at OC junction occur.<sup>3,11</sup> When OA progress to this level where it significantly affects the patient's quality of life and other treatments are not effective anymore, total joint replacement is the only option left.

Joint replacement procedure has a substantial impact on patients' quality of life and lifetime risk of requiring revision surgery and full function of the joint is rarely achieved. According to National Joint Registry (<http://www.njrcentre.org.uk/njrcentre/>), there were 234,401 total joint operations were performed in the UK (excluding Scotland) in 2019, of which 108,973 were hip procedures and 114,852 were knee procedures, predominantly due to OA (88.8%). These are major surgical procedures, which are only undertaken when the disease has progressed to the stage where there is no alternative but a severely limited lifestyle. This can mean that patients will have suffered long periods of pain, discomfort and reduced mobility before an operation is performed.

The issues with these major operations have led to the development of OC tissue engineering therapy for the treatment of cartilage defects at the early stage of OA. In this application, a scaffold is used to provide a support framework and allow regeneration of the cartilage and bone so that the joint will effectively be "renewed". Addressing the changes in early stages of OA (**Figure 2**) could potentially stop or delay the need for joint replacement and thus reduce the impact of the OA, both on personal and socio-economical levels.<sup>12</sup>

Treatments using tissue engineering methods have been established and are promising for the early treatment of OA. The goal of these methods is to repair the cartilage and OC defects (OCDs) in the joint and restore its function, by treating the damage in the earlier stages of the disease, therefore either

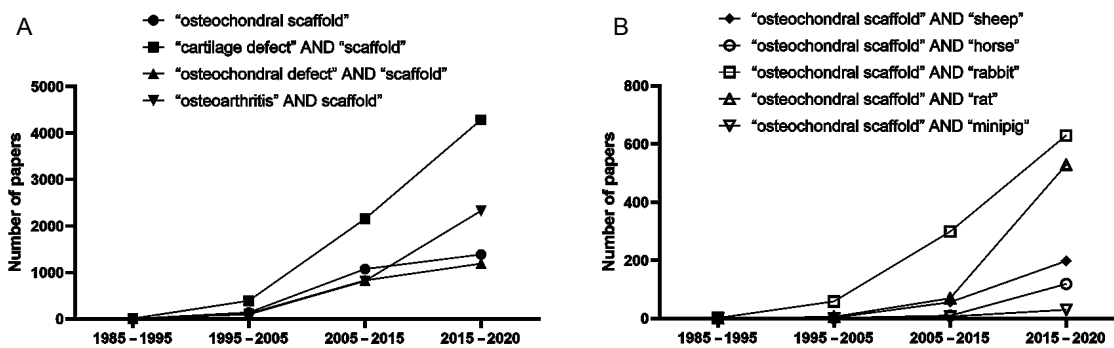
1 Institute of Orthopaedic & Musculoskeletal Science, University College London, Royal National Orthopaedic Hospital, London, UK; 2 State Key Laboratory for Manufacturing System Engineering, School of Mechanical Engineering, Xi'an Jiaotong University, Xi'an, Shaanxi Province, China; 3 3B's Research Group, I3Bs - Research Institute on Biomaterials, Biodegradables and Biomimetics, University of Minho, Headquarters of the European Institute of Excellence on Tissue Engineering and Regenerative Medicine, AvePark, Portugal; 4 ICVS/3B's - PT Government Associate Laboratory, Braga/Guimarães, Portugal; 5 The Discoveries Centre for Regenerative and Precision Medicine, Headquarters at University of Minho, Avepark, Portugal; 6 School of Materials Science and Engineering, Tsinghua University, Beijing, China; 7 Shenzhen Lando Biomaterials Co. Ltd. Merchants Guangming Science Park, Shenzhen, Guangdong Province, China



**Figure 2.** Osteoarthritis (OA) progression and treatment options: non-pharmacological and pharmacological therapies can be used for the treatment of mild and non-acute OA; when the cartilage and bone loss at the joint has significantly impacted the quality of life of the patient, and non-surgical treatments are no longer effective the current state of the art in terms of surgical intervention is a joint replacement operation. Osteochondral (OC) scaffold (with or without addition of cells, such as chondrocytes or stem cells and growth factors such as transforming growth factor- $\beta$ ) seeks to repair and regenerate the local cartilage defects at an early stage to stop or delay the progression of OA to avoid the use of joint replacements. Adapted from Tamaddon et al.<sup>12</sup>

stopping or delaying its progression and the need for a joint replacement. **Figure 3A** reports a literature search on scaffolds for cartilage and OC tissue engineering for the period comprised between 1985 and 2020 using Science Direct Database. The search indicated a steady upward trend in research on scaffold therapy in repairing and regeneration of cartilage and OCDs. This trend

heralds the growing importance of tissue engineering in the early treatment of OA. As a result, this increasing number of researches on the evaluation of OC scaffolds in animal models ranging from small rat model to large sheep models, as reported in **Figure 3B**, shows the mounting interest in moving these towards pre-clinical and clinical endpoints.



**Figure 3.** A literature search on scaffolds for cartilage repair was performed using Science Direct Databases from their inception to date for publications in English. The literature search showing: (A) the increasing number of researches on scaffolds for cartilage and osteochondral defects, and (B) *in vivo* performance evaluation of osteochondral scaffolds using animal models.

Regenerative approaches and tissue engineering treatment modalities are based on harnessing the intrinsic repair capacity of the tissue.<sup>13</sup> This means that tissue engineering approaches are most effective when applied in the early stage of the disease when there is still some regenerative potential in the tissue. The regenerative potential may be comprised or diminished in the advanced disease stages.<sup>14</sup> However, the diagnosis of OA in the early stages is not

always straightforward.

Late stages of OA are usually diagnosed by radiographs indicating morphological changes in the joint such as osteophytes formation, joint space narrowing, subchondral bone sclerosis and cysts. Clinically, the severity of OA is usually assessed by radiography and graded based on Kellgren and Lawrence grading system, as outlined in **Table 1**.<sup>13, 15, 16</sup>

**Table 1. Kellgren and Lawrence grading scoring system based on radiography.**

Grade	Description of changes
Grade 0	No changes
Grade I	Doubtful narrowing of the joint space and possible osteophytic lipping
Grade II	Definite osteophytes and possible narrowing of the joint space
Grade III	Moderate multiple osteophytes, definite narrowing of the joint space, and some sclerosis, and possible deformity of the bone ends
Grade IV	Large osteophytes marked narrowing of the joint space, severe sclerosis, and definite deformity of the bone ends

Note: The description of Kellgren and Lawrence grading system is according to Luyten et al.<sup>13,15,16</sup>

However, diagnosis of early stages of OA, for example, Kellgren and Lawrence I and II, is more complicated as the signs/symptoms may still be limited.<sup>13</sup> Radiographic examination, which is a routine diagnostic tool in established OA, cannot detect changes in the soft tissue characterising early stages of OA.<sup>14,17</sup> New imaging techniques, in particular magnetic resonance imaging (MRI) and arthroscopy, which are to a certain extent complementary, can be used to identify more pathologies in the joint in the earlier stages of the disease.<sup>13</sup> Especially, arthroscopic assessment can reveal early macroscopic changes in the cartilage including tissue softening and loss of integrity,<sup>17</sup> and International Cartilage Repair Society grading can be used to classify cartilage defects into four stages based on the lesion depth<sup>17,18</sup> (Table 2).

For example, in the knee, a patient can be classified as having early OA, if these criteria are met: 1) pain in the knee, 2) Kellgren and Lawrence grading score of up to II (osteophyte only), and 3) arthroscopic or MRI findings of cartilage/joint lesions.<sup>13</sup> The target patient group of tissue engineering therapy is usually a patient with a disease in this stage so that OA progression can be decelerated or arrested, and cartilage “renewed”. There have been a few of tissue engineering products available for the treatment of OA. However, none of these products promotes long-term satisfactory durable regeneration of large defects. The treatment of OA remains a challenge because treatments to date have failed to achieve a satisfactory restoration of the joint cartilage surface and its functionality.

**Table 2. International Cartilage Repair Society grading of cartilage.**

Grade	Description of changes
Grade 0	Normal –
Grade 1	Nearly normal Superficial lesions. Soft indentation and/or superficial fissures and cracks
Grade 2	Abnormal Lesions extending down to < 50% of cartilage depth
Grade 3	Severely abnormal Cartilage defects extending down > 50% of cartilage depth as well as down to calcified layer and down to but not through the subchondral bone. Blisters are included in this Grade
Grade 4	Severely abnormal Osteochondral injuries, lesions extending to the subchondral bone plate or deeper into the trabecular bone

Note: The description of International Cartilage Repair Society grading system is according to Brittberg and Winalski.<sup>18</sup>

This paper is to review the evolution of the scaffolds for the repair and regeneration of cartilage and OCDs in OA joints and examine their efficacy in clinical applications. First, the current surgical treatment options for cartilage defects are reviewed. Then, the concept of tissue engineering and evolution of OC scaffolds for the early treatment of OA is discussed. From this, the efficacy of those scaffolds that have progressed to clinical studies is examined. Based on examinations of the clinical outcomes of the commercially available scaffolds, we have developed clinical specification and requirements for OC scaffold and developed a novel OC scaffold system which has moved to clinical trials for early treatment of large cartilage/OCD in OA joints. The preclinical data of this novel OC scaffold are briefly discussed in this paper. Based on the critical review of the scaffolds, we developed perspective insight on tissue engineering strategy for early intervention of OA progression, and its impact on surgical practices in the treatment of OA.

### The Current State of the Art of Osteoarthritis Treatment

As aforementioned, there are various conservative and surgical treatment options available for defects in OA, depending on the

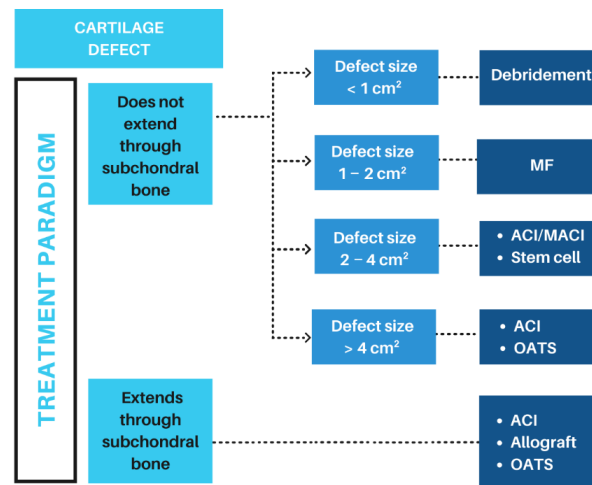
stage of the disease. In the initial stages of OA conservative, non-pharmacological treatment such as education, weight loss and walking aids are considered as a key first-line treatment.<sup>19</sup> More acute symptoms and presentations of OA are usually treated with analgesics, non-steroidal anti-inflammatory drugs or an intra-articular injection with corticosteroids for fast symptom relief. For non-acute treatment symptomatic slow-acting drugs for OA are available. However, as the disease progresses surgical treatments may become necessary. In this section, we review the applicable surgical treatment options in the mild OA.

Regenerative or reparative treatment will be considered when the OA progressed to a stage and non-surgical treatments are no longer effective while it is still too early for a joint replacement. The goal of reparative treatment is to repair the cartilage damage in the joint and restore its function, in order to delay or remove the need for a mechanical replacement. The choice of treatment of a cartilage defect depends on the size of the lesion, its chronicity, and the associated symptoms. For smaller cartilage defects, the current state of the art in terms of medically necessary surgical intervention of defects include excision combined with debridement and bone marrow stimulation. OC

## Osteochondral scaffold for early OA treatment

autograft transfer system, autologous chondrocyte implantation (ACI) and matrix-induced ACI (MACI)<sup>20-22</sup> are considered as treatment options for larger cartilage defects. These techniques are “reparative” techniques, capable to repair articular cartilage by the formation of fibrous tissue with inferior mechanical qualities.<sup>23</sup> An algorithm that aids clinician in choosing the most suitable surgical option is given in **Figure 4**. When the

defect has progressed to a stage that these interventions are no longer effective, joint replacement operation is the current state of the art in terms of surgical intervention – which can range from traditional designs to resurfacing. These are major surgical procedures, which are only undertaken when the disease has progressed to the stage where there is no alternative but a severely limited lifestyle.



**Figure 4.** Cartilage/OCD treatment algorithm according to the condition and size of the defect. ACI: autologous chondrocyte implantation; MACI: matrix-assisted autologous chondrocyte implantation; MF: microfracture; OATS: osteochondral autograft transfer system.

### Marrow stimulation techniques

Microfracture, debridement and drilling are marrow-stimulating techniques usually used for small cartilage defects (< 2–3 cm<sup>2</sup>).<sup>24-26</sup> For defects with an area < 2 cm<sup>2</sup> the outcome of microfracture is generally good. But as the area of the defects increases, the outcome becomes inappropriate.<sup>27</sup> These techniques are minimally invasive, they are inexpensive and simple to perform.<sup>28</sup> Microfracture is a minimally invasive procedure for repair of cartilage damage and acts through releasing mesenchymal stem cells from the underlying bone which then differentiate to become chondrocytes and create new cartilage. The procedure involves removing the damaged cartilage and then drilling into or otherwise puncturing the surface of the underlying bone in order to allow blood and bone marrow to come through to the bone/cartilage interface. The mesenchymal stem cells in the bone marrow contribute to the formation and repair of the cartilage and bone. However, the cartilage which is created is fibrocartilage, which is not expected to have the same durability as the articular cartilage (the type of cartilage in synovial joints) which has been damaged or removed by the disease.<sup>24, 29</sup> Additionally, insufficient filling of the defect, ossification of the repaired tissue and uneven surfaces are also the associated risks of this approach.<sup>30-33</sup> Clinical results suggest that these techniques were more suitable for younger patients in the early stages of OA. However symptomatic improvement was only demonstrated for shorter-term (1 year) in approximately 50% of patients undergoing this procedure. There is a 30–50% re-operation rate for 5-year post-surgery.<sup>24, 28, 34</sup>

### Cell-based regenerative approach

For larger defects of up to 4 cm<sup>2</sup>, the treatment options include

ACI and MACI therapies. Compared to microfracture, ACI is a more expensive two-stage surgical technique, used for the treatment of larger defects (> 2.5 cm<sup>2</sup>) or multiple lesions.<sup>26, 29</sup> The ACI procedure involves harvesting cartilage from the patient through a minimally invasive procedure. Cells isolated from the cartilage are then grown in culture over a four to six-week period until an expanded population of cells is available for the second stage. In the second stage, a periosteal patch is sutured onto the surrounding articular cartilage and injection of chondrocytes underneath.<sup>28</sup> Clinical studies suggest ACI is effective in around 77% of cases, but the fact that the procedure requires two operations, a cell expansion step and a managed rehab programme makes it a very expensive procedure. Some studies suggested that ACI is superior when compared to other techniques, such as mosaicplasty (multiple autografts). Whereas other studies have shown similar results of ACI when compared to Microfracture.<sup>35-37</sup>

Complications associated with ACI therapy have been reduced by the second (membranes to retain autologous chondrocytes in the cartilage defect) and third-generation techniques (cell-loaded membranes or MACI).<sup>38</sup> MACI involves implantation of chondrocytes previously expanded *in vitro* and cultured under special culture condition in a collagen matrix – a type I/III collagen matrix bilayer. One side has a roughened surface with a wide spatial distribution of collagen fibres between which chondrocytes are seeded. Spongy chondral phase covering a flat chamber – reservoir for implanted cells. Following successful outcomes of preclinical animal studies, multiple pieces of research evaluating the efficiency and safety of MACI procedures have

been published to date. Histological outcomes were positive, demonstrating early cartilage-like tissue formation and positive chondrocytes markers, with superiority over microfracture procedure. However, several researchers have also noted the cost-intensiveness of this procedure, thus its wide clinical use has been limited.<sup>39-41</sup> Very sparse literature is available on MRI analyses of regenerated cartilage with MACI technique. Further studies are also needed to evaluate the long-term structural and functional integrity of the grafted area, as diverse reported complications of failure of graft integration, periosteal hypertrophy, delamination, and chondrocyte phenotype loss during the *in vitro* expansion.<sup>42</sup> From studies evaluating MACI procedure, pathology of both subchondral bone and lamina are also notable, despite histology of regenerated tissue showing rebuilt cancellous bone in the osseous phase. National guidelines in the United Kingdom recommend that ACI should be used in patients in which previous cartilage defect treatments have failed.<sup>43</sup>

### OC autograft transfer system

OC autograft transfer system is recommended for defects that extend to the subchondral bone. This is a single-stage procedure employed in the treatment of lesions between 1 and 4 cm<sup>2</sup>, via reliable tissue transfer.<sup>26,44</sup> This technique is performed through the arthroscopic approach and facilitates bone-to-bone healing as cartilage tissue is known to have limited healing capacity.<sup>34</sup> Additionally, mosaicplasty had been introduced involving transplantation of multiple OC plugs. However, the recent evidence showed that numerous plugs are related to worse clinical outcomes, possibly as they are harvested from different sites and do not allow good reconstruction of physiological condylar surface convexity.<sup>45</sup> These techniques are also associated with donor site morbidity, limiting the overall benefits.<sup>46</sup> On the other hand, one study demonstrated that mosaicplasty showed significant clinical improvement when used in 82 athletes with signs of OA, but only in short-term, as some radiographic degenerative changes were observed in about 35% of the patients at mid- to long-term follow-up.<sup>47</sup>

Fresh OC allograft transplantation is another technique, using an open surgery approach, usually for the treatment of larger chondral defects, osteochondritis dissecans and uni-compartmental arthritis. Shell allograft transplantation for repair of early tibial plateau OA defects demonstrated survivorship of 80% at 10-year follow-up.<sup>48</sup> Besides general complications of the open surgery, there is also a risk of disease transmission from the allograft, and due to poor integration subchondral collapse can occur, which is, in fact, the reason for the majority of graft-related failures.<sup>34</sup>

Most of these tissue engineering and regenerative medicine techniques are focus on the repair and regeneration of cartilage, few addressed the repair and regeneration of the subchondral bone. The recent on early treatment of cartilage defects suggested that the inappropriate subchondral bone regeneration had been the most common cause of failure of these treatments.<sup>49</sup>

### Osteochondral Scaffold: From Bench to the Clinics

To address the challenges with the currently available treatments, tissue engineering approaches have been developed and increasingly

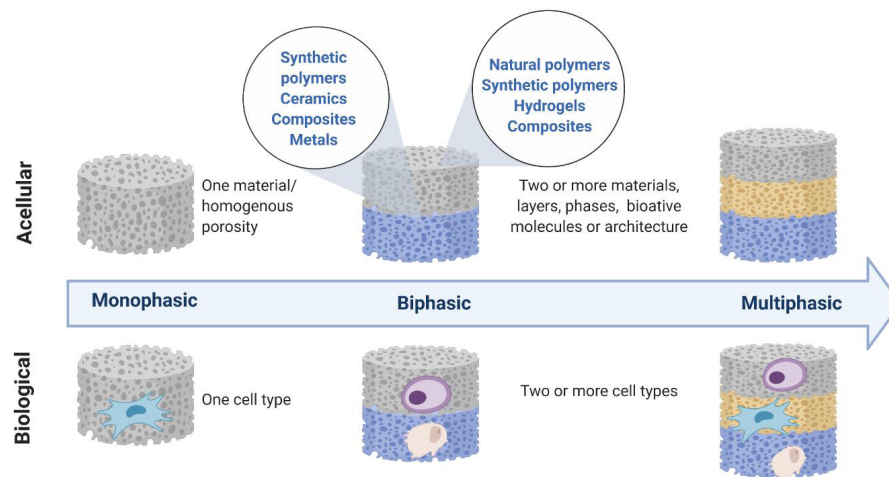
researched to regenerate the damaged tissue. Tissue engineering is a combination of biology, transplantation of cells, materials science and bioengineering, aiming to construct biological substitutes, used for restoration and/or maintenance of normal function of injured or diseased tissues.<sup>24</sup> In this approach, scaffolds are designed and used with the aim of providing a physical environment to support the activity of cells and facilitate tissue regeneration. Scaffolds are usually implanted via arthroscopic approach or by mini-arthrotomy and fixed by press-fit. Some cases would require additional fixation with suturing, pinning or gluing with fibrin glue. Lesion sizes range from 2 to 8 cm<sup>2</sup> can be repaired by pre-determined patches/plugs to match the size and shape of the cartilage defects.<sup>25,34</sup> Several commercially available scaffolds have been used in clinical trials, with or without cells, for small cartilage and OCDs, with varying degrees of success.<sup>25</sup>

Researchers in their earlier works have demonstrated that “cartilage” only approach resulted in poor cartilage fills, fibrocartilage formation and inappropriate integration of newly formed cartilage with the underlying subchondral bone. Subchondral bone and adjacent cartilage form a functional unit, and an appropriate stable physical environment provided by the subchondral bone is crucial for the healthy growth of the overlying cartilage. To achieve better integration and cartilage fill, OC scaffold therapy has been developed<sup>24</sup> with a concept to regenerate the subchondral bone simultaneously with the regeneration of the overlying cartilage. Without support from the subchondral bone, the overlying cartilage would not get sufficient mechanical support and would collapse.

### Evolution of OC scaffold therapy

The challenge in treating OCDs is the complexity of the natural tissue, where the target site comprises of distinct layers with different property with respect to the mechanical property, morphology, physiology and potential to heal. Initially, monophasic scaffolds, where the scaffolds comprised of a single material or composite without any spatial variation, were designed for regeneration of OC unit. However, such scaffolds were not able to recapitulate the biological environment of native OC tissue and were thus inadequate to repair the interface between cartilage and underlying subchondral bone.<sup>4,50</sup> The associated issue with this kind of scaffold is usually the poor integration of regenerated cartilage with the underlying subchondral bone. To address this issue, biphasic and multiphasic scaffolds were developed to mimic the natural OC microenvironment and provide biological and biomechanical cues to the cells that are specifically for the regeneration of bone or cartilage simultaneously. Biochemical cues may come from the natural polymer mimicking the extracellular matrix of target tissue for the cells, or they may be incorporated in form of bioactive molecules such as bone morphogenic protein-2 or transforming growth factor- $\beta$ . In these multi-layered OC scaffolds, two or more different materials, composites, bioactive molecules or architectures are used to create a significant depth-dependent variation in the properties and functionality.<sup>50</sup> **Figure 5** depicts the evolution of OC scaffolds from monophasic to multiphasic state.

Natural and synthetic biopolymers and as well as hydrogels have been used in the construction of bi- and multi-layered scaffolds. Collagen,<sup>51-56</sup> alginate,<sup>57</sup> hyaluronic acid,<sup>58</sup> chitosan<sup>59</sup> and silk<sup>60,61</sup>



**Figure 5.** Evolution of osteochondral scaffolds from monophasic to bi- and multi-phasic states seek to recapitulate the zonal property of osteochondral tissue, concept adapted from Jeon et al.<sup>50</sup> with permission from Elsevier.

are among the most studied families of natural polymers for the regeneration of cartilage. In the design of biphasic/multiphasic scaffolds, synthetic polymers, such as polycaprolactone,<sup>62, 63</sup> polylactic acid<sup>59</sup> and poly (lactic-co-glycolic) acid<sup>64-68</sup> have been utilised, both for cartilage and bone sections. Ceramics, such as hydroxyapatite<sup>52, 54, 57, 69</sup> or tricalcium phosphate<sup>62, 70</sup> are usually used in the form of composite for the bone layer regeneration because they are chemically and structurally similar to the mineral phase of native bone.<sup>71</sup> Porous metallic matrices such as Ti<sup>72-74</sup> or tantalum<sup>75, 76</sup> have also shown potential to be used for the bone portion of a multi-layered scaffold.

Kumbhar et al.<sup>69</sup> have engineered a bi-layered OC scaffold based on bacterial cellulose, composited with glycosaminoglycan for cartilage and with hydroxyapatite for bone. Upon implantation of this acellular scaffold in rats' knee, they observed progressive regeneration of cartilage, and better regeneration of subchondral bone when compared to a control. A multiphasic approach was used by Kang et al.<sup>77</sup> to design a functionally graded tri-layer scaffold with depth-varying pore architecture and mineral environment. The scaffold included a biomineralized bottom layer, a cryogel middle layer, and a hydrogel top layer. They were partially loaded with cells and were implanted subcutaneously into mice, which resulted in a lubricin-rich cartilage surface.

### OC scaffold technology in clinical study

OC tissue engineering is an evolving field, with an increasing number of preclinical and clinical studies being carried out worldwide in order to address the existing challenges in the early treatment of OA, as no currently available treatment option provides a long-term satisfactory solution. Several OC scaffolds have now progressed into clinical trials. **Table 3** summarised the OC scaffolds that have proceeded to clinical studies.

As observed in **Table 3**, most of the currently researched scaffolds in clinical settings are biphasic scaffolds.<sup>78-96</sup> Agili-CTM, which is based on aragonite-hyaluronate is a typical example of such product evaluated to date. A long term (12 months) study in goats showed that the defects treated with the Agili-CTM scaffold were mostly reconstructed, with the repair tissue compatible

with hyaline cartilage and normal bone<sup>78, 97, 98</sup> The results of an eight-year follow-up study of the ChondroMimetic<sup>®</sup> have demonstrated favourable improvement for clinical outcomes of reducing pain, function and activity level in the most recent data release from its manufacturer, Collagen Solutions (Glasgow, UK).<sup>99</sup> The few multiphasic scaffolds have found their way into clinics. MaioRegen<sup>®</sup> is a typical tri-layer OC scaffold based on collagen and hydroxyapatite, which has been extensively studied and is currently in phase III clinical trial. The clinical outcomes of these scaffolds- where data available- are discussed in the next section.

### Efficacy of OC scaffold in the repair of cartilage defects – clinical outcomes

A search in Clinicaltrials.gov with the key phrases “osteochondral”, was carried out and retrieved 72 studies, 10 of which were found relevant to this review and are included in **Table 4**. This search also revealed other treatments for chondral- and OC lesions currently undergoing clinical studies, which appear to be “enhancements” to already available marrow stimulation treatments. In this section, we limited our analyses to scaffolds and decellularized matrices and excluded allografts and primarily cell-based approaches. Although not currently in the clinical trial, TruFit<sup>™</sup> is also included in our analysis here as an example of a scaffold which has been withdrawn from the market.

Chondrofix<sup>®</sup> Osteochondral Allograft (Zimmer Biomet, Zimmer Orthobiologics, Inc., Austin, TX, USA) is allogeneic, cylindrical, decellularized OC graft, composed of donated human decellularized hyaline cartilage and cancellous bone. The study with the aim to evaluate this composite for the treatment of patients with cartilage lesions in the knee has been terminated due to inadequate enrolment and decreased need for clinical data to support the product. One study has reported that this plug should be used with caution due to delamination of superficial layers of the plug 6 months after the implantation, resulting in revision surgery.<sup>100</sup> Additionally, Farr et al.<sup>101</sup> have reported failure of Chondrofix plug in 72% of their patients, due to structural damage to the allograft noted on MRI. Bishop et al.<sup>102</sup> have reported two cases of delamination of Chondrofix plug within a year of implantation,

**Table 3. Osteochondral scaffolds for repair of cartilage damages.**

Structure	Device	Materials	References
Biphasic	Agili-C™ (CartiHeal, Tel Aviv, Israel)	Aragonite-hyaluronate biphasic scaffold. Thin hyaluronate covered cartilage phase, overlying a thick bone phase	Kon et al. <sup>78</sup>
	TruFit™ (Smith and Nephew, USA)	Chondral phase: PLGA, osseous phase: calcium sulfate and PGA fibres	Carmont et al. <sup>79-84</sup>
	Chondro-mimetic (Collagen Solutions, UK)	Chondral phase: Collagen-GAG; Osseous layer: Collagen, GAG, CP	Getgood et al. <sup>85</sup>
	Biphasic	Chondral phase: PLGA; Osseous phase: PLGA-TCP, made by particulate leaching method	Chiang et al. <sup>86</sup>
	Chondro-Gide	Bilayered collagen I/III scaffold	Kusano et al. <sup>87-89</sup>
Multiphasic	MaioRegen® (Fin-Ceramica Faenza S.p.A., Italy)	Chondral phase: Type I equine collagen;	Kon et al. <sup>90-96</sup>
		Intermediate phase: Type I collagen (60%) and Mg-enriched HA (40%);	
		Osseous phase: A mineralised blend of type I collagen (30%) and 70% of Mg-enriched HA	

Note: CP: calcium phosphate; GAG: glycosaminoglycan; HA: hydroxyapatite; Mg: magnesium; PGA: polyglycolic acid; PLGA: poly (lactic-co-glycolic) acid; TCP: tricalcium phosphate.

with a 2-year survivorship rate of only 19.6%.

GelrinC® (Regentis Biomaterials, Or-Akiva, Israel) is a cell-free, off-the-shelf hydrogel implant for the treatment of knee articular cartilage injuries. It is a solution composed of synthetic component – polyethylene glycol diacrylate, and a natural denatured human fibrinogen. There is a currently pivotal clinical study ongoing to evaluate the efficacy of this implant for the treatment of cartilage defects in the knee. GelrinC is used in liquid form and applied usually after the marrow stimulation technique. It is then cured with ultraviolet light *in situ* and converted into a soft implant, which gradually erodes over time until complete resorption within 6–12 months *in vivo*.<sup>103</sup> Twenty-one patients were treated with GelrinC between 2009 and 2012, for a single full-thickness cartilage defect of the femoral condyle, patella or trochlea (size 1 to 6 cm<sup>2</sup>, < 6 mm into subchondral bone). Researchers have reported increased MOCART scores with significant improvement between 6 and 12 months post-operatively. They observed from histological examinations that collagen organisation was like native hyaline cartilage in 81% of patients at 24-month follow-up. They have concluded that significant improvement can be expected after 1-year post-implantation and are planning to publish the results beyond 24-months post-operatively.<sup>103</sup>

MaioRegen® is one of the products that has now progressed to phase III clinical trials. While the pilot study of 30 patients showed favourable clinical and histological results, two patients required re-operation at 2<sup>nd</sup> and 5<sup>th</sup> month postoperatively due to loosening of the graft and graft hypertrophy. Also, worsening of the objective scores was found between 12 and 24 months postoperatively in three cases including limited knee range of movement or effusion, two patients had adverse effects, and the swelling was observed in six patients in first 6 months. Although clinical improvements were maintained at 2 years, the level of physical activity was significantly lower than that at the pre-injury level.<sup>94</sup> Slower recovery was noted in older and less active patients,<sup>94</sup> which is consistent with the studies conducted by Marcacci et al.<sup>93</sup> and Berruto et al.<sup>49</sup> Additionally, patients with adverse effects had worse outcomes at 6- and

12-months. Kon et al.<sup>104</sup> reported significantly lower scores for patients who underwent previous surgery concomitant anterior cruciate ligament treatment. Athletes had a better outcome when compared to non-athletes. Although this difference cannot be justified clearly, it can be related to age, as the mean age of athletes was lower than non-athletes in most studies. Sex and defect size did not significantly affect functional outcomes of MaioRegen® scaffold.<sup>94</sup> Delcogliano et al.<sup>105</sup> suggested that better outcomes were related with lesion site, favouring medial femoral condyle and tibial plateau lesions. Whereas Berruto et al.<sup>49</sup> found greater improvement in patients affected by osteochondritis dissecans. In Delcogliano's study,<sup>105</sup> only 10 patients reached 3-year follow-up due to pain, high movement limitation, recurrent swelling and stiffness. Marcacci et al.<sup>93</sup> demonstrated that combined biological and mechanical approach provided good results at medium follow-up for unicompartmental OA patients eligible for knee resurfacing. They suggested that other structures in the knee are also damaged, which causes instability and misalignment. It is essential to address this since it is likely that the regenerated tissue will fail if the correct alignment is not restored. This is also consistent with the studies conducted by Berruto et al.<sup>49</sup> and Kon et al.<sup>104</sup> Although Berruto and his cohort<sup>49</sup> reported five failure cases due to osteonecrosis, mechanical instability, degenerative changes or need for degenerative surgery, generally favourable positive clinical results were reported for MaioRegen® scaffold. However, Christensen et al.<sup>106</sup> suggested that good results obtained from sheep studies cannot be translated to humans due to interspecies differences and that unhealed defects worsen over time due to increased rim stress. The study reflects that it is necessary to report consistent radiological findings at longer-term in combination with clinical scores. Since this report, the clinical trials of have been discontinued in Denmark with the advice of precaution when using MaioRegen® implant for the treatment of cartilage defects in OA joints. Similarly, Albano et al.<sup>107</sup> have found that autologous matrix-induced chondrogenesis with MaioRegen implant failed in 31% of patients, requiring re-intervention. On the other hand, Kon et al.<sup>104</sup> highlighted the



**Table 4. Osteochondral scaffolds in clinical studies registered with Clinicaltrial.gov.**

No.	Study title	Identifier No.	Submission date	Status/sponsor	Conditions	Intervention/follow up/results
1	Clinical and Radiological Results of Osteochondral (OC) Repair Using MaioRegen in Knee and Ankle Surgery	NCT02345564	11-Sep-14	Unknown/Barmherzige Brüder Eisenstadt	OC lesion of talus degenerative lesion of articular cartilage of knee; size 2–4 cm <sup>2</sup>	MaioRegen/18 months/no results posted
2	A Prospective, Post-marketing Registry on the Use of ChondroMimetic for the Repair of OCDs	NCT01209390	6-Aug-10	Terminated (slow recruitment rate)/TiGenix n.v.	OCDs knee, less than 12 mm diameter and 8 mm depth	Chondromimetic device/6, 12, 24, 36 months/no results posted
3	Study for the Treatment of Knee Chondral and OC Lesions	NCT01282034	21-Jan-11	Completed Feb 2016/FinCeramica Faenza Spa	Chondral and OC knee lesions; Grades III/IV outerbridge, 2–9 cm <sup>2</sup>	MaioRegen/6, 12, 24 months/no results posted
4	Repair of articular OCD	NCT01409447	3-Aug-11	Unknown/National Taiwan University Hospital	Osteochondritis dissecans knee, less than 3 cm	BiPhasic/-/no results posted
5	Chondrofix OC allograft prospective study	NCT01410136	2-Aug-11	Terminated/Zimmer Orthobiologics, Inc.	Articular cartilage disorder, degeneration, defect and acute injury; Up to two cartilage lesion, each measuring less than 8 cm <sup>2</sup>	Chondrofix OC allograft/24 up to 60 months/no results posted
6	Agili-C™ Implant Performance Evaluation in the Repair of Cartilage and OCDs	NCT02423629	3-Dec-14	Completed/Cartiheal (2009) Ltd.	Cartilage or OCD of the knee, ICRS Grade III or above, 1–7 cm <sup>2</sup>	Agili-C/6, 12, 18, 24 months/no results posted
7	BiPhasic Cartilage Repair Implant (BiCRI) IDE Clinical Trial - Taiwan	NCT01477008	14-Nov-11	Active, not recruiting/BioGend Therapeutics Co. Ltd.	Chondral and OCD of femoral condyles and trochlea; ICRS grade 3–4 lesion, Outerbridge grade 4, or OCD grades 3–4, 12.5 mm diameter with one implant or if larger with two implants	BiPhasic Cartilage Implant/preop, 6 weeks, 3, 6 and 12 months/no results posted
8	Evaluation of the Agili-C Biphasec Implant in the Knee Joint	NCT01471236	10-Nov-11	Completed/Cartiheal (2009) Ltd.	Cartilage diseases, osteochondritis dissecans, less than 2 cm <sup>2</sup> and 3 mm depth	Agili-C/3, 6, 9, 12, 18, 24 months/no results posted
9	Pivotal Study to Evaluate the Safety and Efficacy of GelrinC for Treatment of Cartilage Defects	NCT03262909	17-Aug-17	Recruiting/Regentis Biomaterials	Knee joint cartilage defects, ICRS III or IV, lesion size between 1 and 5 cm <sup>2</sup> post debridement, less than or equal to 2.5 cm in diameter	GelrinC/24 months/no results posted

Note: ICRS: International Cartilage Repair Society; OA: osteoarthritis; OC: osteochondral; OCD: osteochondral defect.

safety and potential of a biomimetic implant, but their imaging evaluation confirmed concerns previously raised in the literature on slow restoration of the subchondral bone area.

Another well-explored scaffold TruFit Plug was withdrawn from the global market in 2013. Initial favourable results from pre-clinical animal studies have been obtained. Histology from a goat model shown a good integration of bony part, with good resorption and hyaline-like cartilage formation in the surface layer and good interface integration at 12-months follow-up.<sup>108,109</sup> Some studies reported that MRI examinations at 3 and 6 months

revealed a lack of integration and high fluid signal. Initially, it was suggested that scaffolds require longer periods to integrate.<sup>79</sup> However, later studies reported that bone integration is delayed, causing instability and failure. This has affected both the cartilage construct and the native cartilage due to increase contact pressure by the instability leading to failure.<sup>84</sup> Generally, the studies reporting the results of TruFit plug use have been mixed, although earlier improvement has been recorded up to 12-month follow up.<sup>82,84</sup> On the other hand, two studies (15 and 10 patients) reported 20%<sup>81</sup> and 70%<sup>82</sup> of failure at 12 months follow-up,

including subchondral bone remodelling in the presence of bone oedema in all cases. This suggested an ongoing resorption process of the plug into the underlying bone during healing process. Similarly, a study from 2015 has reported that no bony ingrowth was detected, bone cysts and oedema were revealed on MRI and CT examinations.<sup>110</sup>

### Challenges and Opportunities in the Early Treatment of Osteoarthritis

The scaffolds have been developed to date for treating chondral and OC-lesions reported mixed clinical outcomes and results in short- to medium-term follow-ups. Looking at the analysed studies, it is interesting to note that the modes of failure can be classified into two categories: a) insufficient cartilage repair due to poor integration of with surrounding tissues and/or b) insufficient subchondral bone regeneration and formation of bone cysts.

Cartilage and bone are two different types of tissue, and they have very different mechanical properties and biological composition. The junction between cartilage and bone is a progressively evolved “multi-tissue” structure: hyaline cartilage-fibrocartilage - mineralized fibrocartilage - bone. These tissues have progressively increasing Young’s moduli, which distribute the forces generated in cartilage and transmitted onto the bone. To successfully repair and regenerate the diseased OCDs, it is critical for the newly formed cartilage to firmly integrate with the underlying subchondral bone to allow stress transmission to the bone. In the case of Chondrofix for example, majority of cases failed as observed in the clinical study were due to delamination of the top cartilage layer from the osseous layer. In the natural OC unit, the cement line indicates the separation of the cartilage and underlying bone. It is recognized to be a region of weakness since no collagen fibres are continuous between the calcified cartilage and subchondral bone plate.<sup>111, 112</sup> The steep stiffness gradient between cartilage and subchondral bone unit may be one of the causes of cartilage layer delamination from the bone due to shear stresses.<sup>111</sup>

In particular, the poor outcome of TruFit plug seemed to be affected by the presence of bone oedema in most of the cases, while Maioregen showed slow restoration of the subchondral bone area. Incomplete bone regeneration was also detected in some of the failed cases of Chondrofix scaffold. The significant of subchondral bone integration in maintaining healthy articular cartilage is well established<sup>106, 113</sup> from biomechanical and nutritive perspectives. Therefore, degeneration of cartilage in long run is expected if the support from subchondral bone is compromised, pointing to a possible reason for the failure of high quality cartilage as reported in the some of the studies.<sup>25</sup> The “unfilled bone voids”<sup>82, 84</sup> or cyst-like cavities observed in the MRI<sup>26, 106, 114</sup> resembles the subchondral bone cysts observed in terminal cases of OA patients. Without stable biomechanical support, the newly formed cartilage would “collapse” and would not be subjected to mechanical stimulation, which is a critical factor for the formation of a healthy hyaline cartilage.<sup>25</sup>

The main issues in the current commercially available OCD treatments are poor cartilage fill and associated fibrocartilaginous repair rather than hyaline cartilage, as well as subchondral

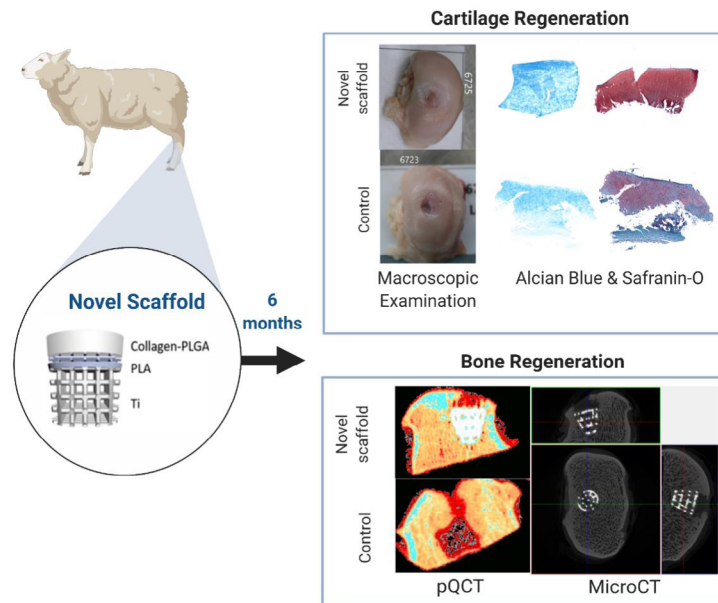
bone resorption, as observed in clinical studies. The authors believe this is due to the weak biomechanical properties and high permeability of the scaffold that allows liquid exudation and prevents hydrostatic pressure that has been shown to enhance chondrocytes. This result in an inappropriate physical environment for cartilage healing. In order to promote healthy cartilage growth, the OC scaffold should provide an appropriate physical environment (that includes the generation of appropriate biomechanical environment and hydrostatic pressure) to support overlying cartilage healing that is critical for cartilage fill and hyaline cartilage formation.

Once the OC scaffold is implanted in the joint, it is exposed to a dynamic biomechanical environment, and to achieve a healthy cartilage repair using multilayered scaffolds, it is crucial for each layer to have mechanical properties that match the surrounding tissue, and that the scaffold is mechanically stable to withstand the joint’s physiological loading without fatigue or failure.<sup>12, 115</sup>

Studies on the compressive behaviour of articular cartilage reveal values of compressive modulus varying from 2–10 MPa shortly after application of load.<sup>116</sup> In terms of bone, mid-range values for the compressive modulus of cancellous bone are 90–400 MPa. The modulus for the calcified cartilage is more than an order of magnitude lower than the modulus of the underlying subchondral bone. As such in designing an OC scaffold the criterion for compressive modulus of this layer should be set an order of magnitude lower than the bone section.<sup>12, 117, 118</sup>

To this end, researchers at University College London invented a novel OC scaffold system based on titanium, PLA and collagen-PLGA composite system (**Figure 6**). The developed scaffold combines a titanium matrix for subchondral bone and PLGA reinforced collagen for cartilage repair. These materials have been previously used in medical devices and present a history of safe use, improving the translatability of this scaffold into clinic. The dense junction layer of PLA acts as “calcified cartilage” between articular cartilage and subchondral bone and forms a graded structure with respect to the mechanical property, structure and composition.<sup>119</sup> Each layer was designed to have a compressive modulus within the range the neighbouring natural tissue; Ti with a modulus of  $73 \pm 4.4$  MPa, PLA with  $11.1 \pm 0.8$  MPa and collagen-PLGA with  $1.46 \pm 0.9$  MPa.

The performance of this OC scaffold has been tested in the sheep stifle condyle for up to 6 months, with a collagen-hydroxyapatite – based tri-layered scaffold as control. The *in vivo* sheep study has demonstrated that this scaffold achieved improved mechanical and biological fixation in the joints and which led to improved cartilage fill through improved bone ingrowth and hyaline cartilage formation as revealed by examination of retrieved tissues (**Figure 6**). This is while there are “unfilled bone voids” observed in TruFit,<sup>82</sup> MaioRegen<sup>106</sup> and Chondromimetic.<sup>120</sup> The “cyst-like” cavities in scaffold developed by Levingstone et al.<sup>121</sup> seem to resolve after 12 months. Result obtained from a clinical dog shoulder model, which was highlighted in Channel 4’s SuperVet Bionic Specials: Flo & Izzy has demonstrated the scaffold has the strength needed to bear the physical load of the joints and encourages consistent cartilage fill and a smooth articular surface. The function of the shoulder was restored 3 months post-



**Figure 6.** The novel multilayer osteochondral scaffold developed at University College London has achieved improved stable fixation via good bone integration which provides a strong support to the overlying cartilage healthy growth. Six months *in vivo* studies showed a hyaline-like cartilage formation, over 90% cartilage fill, and improved subchondral bone regeneration in a large OCD of sheep knee. OCD: osteochondral defect; PLA: polylactic acid; PLGA: polylactic acid; pQCT: peripheral quantitative computed tomography; Ti: titanium.

operation with a good outcome after 2 years. Subsequently, the novel OC scaffold has proceeded to first in human clinical study which is being carried out at the Royal National Orthopaedic Hospital.

The emerging OC scaffold technology has shown the potential to tackle the unmet clinical need for repair of large chondral- and OCDs in the early stage of OA by bridging the gap between small lesion treatment and joint replacement. It is hoped that it will provide clinicians with a practical treatment option in situations where the disease has progressed beyond a small defect, but where a full joint replacement could still be avoided. This would lead to tangible and clinically relevant results in a one-step surgical procedure for the treatment of large cartilage and OCDs.

### Perspective Insight

OA is a degenerative joint disease, typified by the degradation of cartilage and changes in the subchondral bone. The current state of the art in terms of surgical intervention of OA is a joint replacement operation. There are limited options for young OA patients and those not suitable for joint replacements. Many new technologies, such as stem cell therapies, have been studied and applied to the repair of cartilage defects in OA patients. However, issues such as expensive cell-based therapies and two-step procedures, which not only increase the cost but also subject patients to several hospital visits and stays, as well as fibrocartilage formation, are the main concerns in the application of cell therapies in the treatment of chondral- and OC-defects.

The goal of a tissue engineering approach is to repair the defect in the joint and restore its function in order to delay or remove the need for a joint replacement. In this approach, the scaffolds, with or without cells, applied to the local defect sites in the joint. It has

shown the potential for the repair and regeneration of chondral- and OCDs in OA joints, and restore its function early in the process of OA development. The increasing number of research in tissue engineering strategy, especially over the past 10 years, has demonstrated the importance of tissue engineering approach in the management of OA and in the improvement of the patient's quality of life. Polymer and polymer composite scaffolds are emerging onto the market for bone and cartilage applications, but these have limited mechanical properties, and are not suitable for large defect and load-bearing applications. None of these products has yet been demonstrated to provide an appropriate physical environment with the appropriate biomechanical properties to promote satisfactory durable regeneration of OCDs in OA patients.

Development of an OC scaffold which will bridge the gap between small treatment and joint replacement is still a grand challenge. However, with the advancement of OC scaffold biotechnology, it is hoped that a novel OC scaffold with improved capability for biomechanical and biological fixation would lead to tangible and clinically relevant results in a one-step surgical procedure for the treatment of large chondral- and OC-defects, relieving pain and keeping people active. It is anticipated that this will create new treatments for early OA and could either negate or delay the need for joint replacement. This can reduce the financial burden to healthcare providers and the patients themselves. The beneficiaries reflect the value chain from the patient, through the clinician, the hospital and healthcare providers, to the industrial generators of the underpinning technology and materials. This will have a significant impact on clinical practice in the future.

### Author contributions

Conceptualisation, supervision, and resources: CL; investigation: MT

and HG; original draft preparation and visualisation: MT; original draft manuscript: HG; manuscript review and editing: MT, LW, JMO, XS, RT. All authors approved the final version of the manuscript.

#### Financial support

This work was financially supported by the Versus Arthritis (No. 21160); Rosetree Trust (No. A1184); European Commission via H2020 MSCA RISE BAMOS programme (No. 734156); Innovative UK via Newton Fund (No. 102872); and Ministry of Science and Technology of China via National Key R&D Program (No. 2018YFE0207900).

#### Acknowledgement

None.

#### Conflicts of interest statement

The authors declare no competing financial interest.

#### Data sharing statement

This is an open access journal, and articles are distributed under the terms of the Creative Commons Attribution-NonCommercial-ShareAlike 4.0 License, which allows others to remix, tweak, and build upon the work non-commercially, as long as appropriate credit is given and the new creations are licensed under the identical terms.

1. Hunter, D. J.; Schofield, D.; Callander, E. The individual and socioeconomic impact of osteoarthritis. *Nat Rev Rheumatol.* **2014**, *10*, 437-441.
2. Loeser, R. F.; Goldring, S. R.; Scanzello, C. R.; Goldring, M. B. Osteoarthritis: a disease of the joint as an organ. *Arthritis Rheum.* **2012**, *64*, 1697-1707.
3. Lories, R. J.; Luyten, F. P. The bone-cartilage unit in osteoarthritis. *Nat Rev Rheumatol.* **2011**, *7*, 43-49.
4. Longley, R.; Ferreira, A. M.; Gentile, P. Recent approaches to the manufacturing of biomimetic multi-phasic scaffolds for osteochondral regeneration. *Int J Mol Sci.* **2018**, *19*, 1755.
5. Goldring, S. R.; Goldring, M. B. Changes in the osteochondral unit during osteoarthritis: structure, function and cartilage-bone crosstalk. *Nat Rev Rheumatol.* **2016**, *12*, 632-644.
6. Williams, F. M. K.; Spector, T. D. Osteoarthritis. *Medicine.* **2006**, *34*, 364-368.
7. Roberts, S.; Weightman, B.; Urban, J.; Chappell, D. Mechanical and biochemical properties of human articular cartilage in osteoarthritic femoral heads and in autopsy specimens. *J Bone Joint Surg Br.* **1986**, *68*, 278-288.
8. Findlay, D. M. Vascular pathology and osteoarthritis. *Rheumatology (Oxford).* **2007**, *46*, 1763-1768.
9. Findlay, D. M.; Kuliwaba, J. S. Bone-cartilage crosstalk: a conversation for understanding osteoarthritis. *Bone Res.* **2016**, *4*, 16028.
10. Burr, D. B.; Gallant, M. A. Bone remodelling in osteoarthritis. *Nat Rev Rheumatol.* **2012**, *8*, 665-673.
11. Goldring, M. B.; Goldring, S. R. Articular cartilage and subchondral bone in the pathogenesis of osteoarthritis. *Ann N Y Acad Sci.* **2010**, *1192*, 230-237.
12. Tamaddon, M.; Wang, L.; Liu, Z.; Liu, C. Osteochondral tissue repair in osteoarthritic joints: clinical challenges and opportunities in tissue engineering. *Bio-design and manufacturing.* **2018**, *1*, 101-114.
13. Luyten, F. P.; Denti, M.; Filardo, G.; Kon, E.; Engebretsen, L. Definition and classification of early osteoarthritis of the knee. *Knee Surg Sports Traumatol Arthrosc.* **2012**, *20*, 401-406.
14. Madry, H.; Kon, E.; Condello, V.; Peretti, G. M.; Steinwachs, M.; Seil, R.; Berruto, M.; Engebretsen, L.; Filardo, G.; Angele, P. Early osteoarthritis of the knee. *Knee Surg Sports Traumatol Arthrosc.* **2016**, *24*, 1753-1762.
15. Kellgren, J. H.; Lawrence, J. S. Radiological assessment of osteo-arthrosis. *Ann Rheum Dis.* **1957**, *16*, 494-502.
16. Kohn, M. D.; Sassoon, A. A.; Fernando, N. D. Classifications in brief: Kellgren-Lawrence classification of osteoarthritis. *Clin Orthop Relat Res.* **2016**, *474*, 1886-1893.
17. Casula, V.; Hirvasniemi, J.; Lehenkari, P.; Ojala, R.; Haapea, M.; Saarakkala, S.; Lammentausta, E.; Nieminen, M. T. Association between quantitative MRI and ICRS arthroscopic grading of articular cartilage. *Knee Surg Sports Traumatol Arthrosc.* **2016**, *24*, 2046-2054.
18. Brittberg, M.; Winalski, C. S. Evaluation of cartilage injuries and repair. *J Bone Joint Surg Am.* **2003**, *85-A Suppl 2*, 58-69.
19. Nelson, A. E.; Allen, K. D.; Golightly, Y. M.; Goode, A. P.; Jordan, J. M. A systematic review of recommendations and guidelines for the management of osteoarthritis: The chronic osteoarthritis management initiative of the U.S. bone and joint initiative. *Semin Arthritis Rheum.* **2014**, *43*, 701-712.
20. Giannini, S.; Buda, R.; Grigolo, B.; Vannini, F. Autologous chondrocyte transplantation in osteochondral lesions of the ankle joint. *Foot Ankle Int.* **2001**, *22*, 513-517.
21. Giannini, S.; Vannini, F. Operative treatment of osteochondral lesions of the talar dome: current concepts review. *Foot Ankle Int.* **2004**, *25*, 168-175.
22. Rothrauff, B. B.; Murawski, C. D.; Angthong, C.; Becher, C.; Neher, S.; Niemeyer, P.; Sullivan, M.; Valderrabano, V.; Walther, M.; Ferkel, R. D. Scaffold-based therapies: Proceedings of the International Consensus Meeting on Cartilage Repair of the Ankle. *Foot Ankle Int.* **2018**, *39*, 41s-47s.
23. Vannini, F.; Filardo, G.; Kon, E.; Roffi, A.; Marcacci, M.; Giannini, S. Scaffolds for cartilage repair of the ankle joint: The impact on surgical practice. *Foot Ankle Surg.* **2013**, *19*, 2-8.
24. Yousefi, A. M.; Hoque, M. E.; Prasad, R. G.; Uth, N. Current strategies in multiphasic scaffold design for osteochondral tissue engineering: A review. *J Biomed Mater Res A.* **2015**, *103*, 2460-2481.
25. Tamaddon, M.; Liu, C. Enhancing biological and biomechanical fixation of osteochondral scaffold: a grand challenge. *Adv Exp Med Biol.* **2018**, *1059*, 255-298.
26. Yan, L.; Oliveira, J. M.; Oliveira, A. L.; Reis, R. L. Current concepts and challenges in osteochondral tissue engineering and regenerative medicine. *ACS Biomater Sci Eng.* **2015**. doi: 10.1021/ab500038y.
27. Hirahara, A. M.; Mueller, K. W. Jr. BioCartilage: A new biomaterial to treat chondral lesions. *Sports Med Arthrosc Rev.* **2015**, *23*, 143-148.
28. Melton, J. T.; Wilson, A. J.; Chapman-Sheath, P.; Cossey, A. J. TruFit CB bone plug: chondral repair, scaffold design, surgical technique and early experiences. *Expert Rev Med Devices.* **2010**, *7*, 333-341.
29. Ye, K.; Di Bella, C.; Myers, D. E.; Choong, P. F. The osteochondral dilemma: review of current management and future trends. *ANZ J Surg.* **2014**, *84*, 211-217.
30. Salzmann, G. M.; Niemeyer, P.; Steinwachs, M.; Kreuz, P. C.; Südkamp, N. P.; Mayr, H. O. Cartilage repair approach and treatment characteristics across the knee joint: a European survey. *Arch Orthop Trauma Surg.* **2011**, *131*, 283-291.
31. Kreuz, P. C.; Erggelet, C.; Steinwachs, M. R.; Krause, S. J.; Lahm, A.; Niemeyer, P.; Ghanem, N.; Uhl, M.; Südkamp, N. Is microfracture of chondral defects in the knee associated with different results in patients aged 40 years or younger? *Arthroscopy.* **2006**, *22*, 1180-1186.
32. Kreuz, P. C.; Steinwachs, M. R.; Erggelet, C.; Krause, S. J.; Konrad, G.; Uhl, M.; Südkamp, N. Results after microfracture of full-thickness chondral defects in different compartments in the knee. *Osteoarthritis Cartilage.* **2006**, *14*, 1119-1125.
33. Salzmann, G. M.; Sah, B.; Südkamp, N. P.; Niemeyer, P. Clinical outcome following the first-line, single lesion microfracture at the knee joint. *Arch Orthop Trauma Surg.* **2013**, *133*, 303-310.
34. Angele, P.; Niemeyer, P.; Steinwachs, M.; Filardo, G.; Gomoll, A. H.; Kon,

- E.; Zellner, J.; Madry, H. Chondral and osteochondral operative treatment in early osteoarthritis. *Knee Surg Sports Traumatol Arthrosc.* **2016**, *24*, 1743-1752.
35. Bentley, G.; Bhamra, J. S.; Gikas, P. D.; Skinner, J. A.; Carrington, R.; Briggs, T. W. Repair of osteochondral defects in joints--how to achieve success. *Injury.* **2013**, *44 Suppl 1*, S3-10.
  36. Brittberg, M.; Lindahl, A.; Nilsson, A.; Ohlsson, C.; Isaksson, O.; Peterson, L. Treatment of deep cartilage defects in the knee with autologous chondrocyte transplantation. *N Engl J Med.* **1994**, *331*, 889-895.
  37. Knutsen, G.; Drogset, J. O.; Engebretsen, L.; Grøntvedt, T.; Isaksen, V.; Ludvigsen, T. C.; Roberts, S.; Solheim, E.; Strand, T.; Johansen, O. A randomized trial comparing autologous chondrocyte implantation with microfracture. Findings at five years. *J Bone Joint Surg Am.* **2007**, *89*, 2105-2112.
  38. Nixon, A. J.; Sparks, H. D.; Begum, L.; McDonough, S.; Scimeca, M. S.; Moran, N.; Matthews, G. L. Matrix-induced autologous chondrocyte implantation (MACI) using a cell-seeded collagen membrane improves cartilage healing in the equine model. *J Bone Joint Surg Am.* **2017**, *99*, 1987-1998.
  39. Bartlett, W.; Skinner, J. A.; Gooding, C. R.; Carrington, R. W.; Flanagan, A. M.; Briggs, T. W.; Bentley, G. Autologous chondrocyte implantation versus matrix-induced autologous chondrocyte implantation for osteochondral defects of the knee: a prospective, randomised study. *J Bone Joint Surg Br.* **2005**, *87*, 640-645.
  40. Behrens, P.; Bitter, T.; Kurz, B.; Russlies, M. Matrix-associated autologous chondrocyte transplantation/implantation (MACT/MACI)--5-year follow-up. *Knee.* **2006**, *13*, 194-202.
  41. Ventura, A.; Memeo, A.; Borgo, E.; Terzaghi, C.; Legnani, C.; Albisetti, W. Repair of osteochondral lesions in the knee by chondrocyte implantation using the MACI® technique. *Knee Surg Sports Traumatol Arthrosc.* **2012**, *20*, 121-126.
  42. Oliveira, J.; Pina, S.; Reis, R. L.; Roman, J. S. *Osteochondral Tissue Engineering: Challenges, Current Strategies, and Technological Advances.* Springer International Publishing. **2018**.
  43. NICE. Autologous chondrocyte implantation for treating symptomatic articular cartilage defects of the knee. Report No. Technology appraisal guidance [TA477]. **2017**.
  44. Filardo, G.; Kon, E.; Roffi, A.; Di Martino, A.; Marcacci, M. Scaffold-based repair for cartilage healing: a systematic review and technical note. *Arthroscopy.* **2013**, *29*, 174-186.
  45. Filardo, G.; Kon, E.; Perdisa, F.; Tetta, C.; Di Martino, A.; Marcacci, M. Arthroscopic mosaicplasty: long-term outcome and joint degeneration progression. *Knee.* **2015**, *22*, 36-40.
  46. Filardo, G.; Kon, E.; Perdisa, F.; Balboni, F.; Marcacci, M. Autologous osteochondral transplantation for the treatment of knee lesions: results and limitations at two years' follow-up. *Int Orthop.* **2014**, *38*, 1905-1912.
  47. Hangody, L.; Dobos, J.; Baló, E.; Pánics, G.; Hangody, L. R.; Berkes, I. Clinical experiences with autologous osteochondral mosaicplasty in an athletic population: a 17-year prospective multicenter study. *Am J Sports Med.* **2010**, *38*, 1125-1133.
  48. Shasha, N.; Krywulak, S.; Backstein, D.; Pressman, A.; Gross, A. E. Long-term follow-up of fresh tibial osteochondral allografts for failed tibial plateau fractures. *J Bone Joint Surg Am.* **2003**, *85-A Suppl 2*, 33-39.
  49. Berruto, M.; Delcogliano, M.; de Caro, F.; Carimati, G.; Uboldi, F.; Ferrua, P.; Ziveri, G.; De Biase, C. F. Treatment of large knee osteochondral lesions with a biomimetic scaffold: results of a multicenter study of 49 patients at 2-year follow-up. *Am J Sports Med.* **2014**, *42*, 1607-1617.
  50. Jeon, J. E.; Vaquette, C.; Klein, T. J.; Huttmacher, D. W. Perspectives in multiphasic osteochondral tissue engineering. *Anat Rec (Hoboken).* **2014**, *297*, 26-35.
  51. Gotterbarm, T.; Richter, W.; Jung, M.; Berardi Vilei, S.; Mainil-Varlet, P.; Yamashita, T.; Breusch, S. J. An in vivo study of a growth-factor enhanced, cell free, two-layered collagen-tricalcium phosphate in deep osteochondral defects. *Biomaterials.* **2006**, *27*, 3387-3395.
  52. Ahn, S.; Yoon, H.; Kim, G.; Kim, Y.; Lee, S.; Chun, W. Designed three-dimensional collagen scaffolds for skin tissue regeneration. *Tissue Eng Part C Methods.* **2010**, *16*, 813-820.
  53. Marquass, B.; Somerson, J. S.; Hepp, P.; Aigner, T.; Schwan, S.; Bader, A.; Josten, C.; Zscharnack, M.; Schulz, R. M. A novel MSC-seeded triphasic construct for the repair of osteochondral defects. *J Orthop Res.* **2010**, *28*, 1586-1599.
  54. Sartori, M.; Pagani, S.; Ferrari, A.; Costa, V.; Carina, V.; Figallo, E.; Maltarello, M. C.; Martini, L.; Fini, M.; Giavaresi, G. A new bi-layered scaffold for osteochondral tissue regeneration: In vitro and in vivo preclinical investigations. *Mater Sci Eng C Mater Biol Appl.* **2017**, *70*, 101-111.
  55. Crovace, A. M.; Giancamillo, A. D.; Gervaso, F.; Mangiavini, L.; Zani, D.; Scalera, F.; Palazzo, B.; Izzo, D.; Agnoletto, M.; Domenicucci, M.; Sosio, C.; Sannino, A.; Giancamillo, M. D.; Peretti, G. M. Evaluation of in vivo response of three biphasic scaffolds for osteochondral tissue regeneration in a sheep model. *Vet Sci.* **2019**, *6*, 90.
  56. Liu, X.; Wei, Y.; Xuan, C.; Liu, L.; Lai, C.; Chai, M.; Zhang, Z.; Wang, L.; Shi, X. A biomimetic biphasic osteochondral scaffold with layer-specific release of stem cell differentiation inducers for the reconstruction of osteochondral defects. *Adv Healthc Mater.* **2020**, e2000076.
  57. Filardo, G.; Perdisa, F.; Gelinsky, M.; Despang, F.; Fini, M.; Marcacci, M.; Parrilli, A. P.; Roffi, A.; Salamanna, F.; Sartori, M.; Schütz, K.; Kon, E. Novel alginate biphasic scaffold for osteochondral regeneration: an in vivo evaluation in rabbit and sheep models. *J Mater Sci Mater Med.* **2018**, *29*, 74.
  58. Vainieri, M. L.; Lolli, A.; Kops, N.; D'Atri, D.; Eglin, D.; Yayon, A.; Alini, M.; Grad, S.; Sivasubramanian, K.; van Osch, G. Evaluation of biomimetic hyaluronic-based hydrogels with enhanced endogenous cell recruitment and cartilage matrix formation. *Acta Biomater.* **2020**, *101*, 293-303.
  59. Frenkel, S. R.; Bradica, G.; Brekke, J. H.; Goldman, S. M.; Ieska, K.; Issack, P.; Bong, M. R.; Tian, H.; Gokhale, J.; Coutts, R. D.; Kronengold, R. T. Regeneration of articular cartilage--evaluation of osteochondral defect repair in the rabbit using multiphasic implants. *Osteoarthritis Cartilage.* **2005**, *13*, 798-807.
  60. Feng, X.; Xu, P.; Shen, T.; Zhang, Y.; Ye, J.; Gao, C. Influence of pore architectures of silk fibroin/collagen composite scaffolds on the regeneration of osteochondral defects in vivo. *J Mater Chem B.* **2020**, *8*, 391-405.
  61. Pérez-Silos, V.; Moncada-Saucedo, N. K.; Peña-Martínez, V.; Lara-Arias, J.; Marino-Martínez, I. A.; Camacho, A.; Romero-Díaz, V. J.; Lara Banda, M.; García-Ruiz, A.; Soto-Dominguez, A.; Rodriguez-Rocha, H.; López-Serna, N.; Tuan, R. S.; Lin, H.; Fuentes-Mera, L. A cellularized biphasic implant based on a bioactive silk fibroin promotes integration and tissue organization during osteochondral defect repair in a porcine model. *Int J Mol Sci.* **2019**, *20*, 5145.
  62. Shao, X. X.; Huttmacher, D. W.; Ho, S. T.; Goh, J. C.; Lee, E. H. Evaluation of a hybrid scaffold/cell construct in repair of high-load-bearing osteochondral defects in rabbits. *Biomaterials.* **2006**, *27*, 1071-1080.
  63. Zheng, P.; Hu, X.; Lou, Y.; Tang, K. A rabbit model of osteochondral regeneration using three-dimensional printed polycaprolactone-hydroxyapatite scaffolds coated with umbilical cord blood mesenchymal stem cells and chondrocytes. *Med Sci Monit.* **2019**, *25*, 7361-7369.

64. Cui, W.; Wang, Q.; Chen, G.; Zhou, S.; Chang, Q.; Zuo, Q.; Ren, K.; Fan, W. Repair of articular cartilage defects with tissue-engineered osteochondral composites in pigs. *J Biosci Bioeng.* **2011**, *111*, 493-500.
65. Reyes, R.; Delgado, A.; Sánchez, E.; Fernández, A.; Hernández, A.; Evora, C. Repair of an osteochondral defect by sustained delivery of BMP-2 or TGF $\beta$ 1 from a bilayered alginate-PLGA scaffold. *J Tissue Eng Regen Med.* **2014**, *8*, 521-533.
66. Qi, Y.; Du, Y.; Li, W.; Dai, X.; Zhao, T.; Yan, W. Cartilage repair using mesenchymal stem cell (MSC) sheet and MSCs-loaded bilayer PLGA scaffold in a rabbit model. *Knee Surg Sports Traumatol Arthrosc.* **2014**, *22*, 1424-1433.
67. Duan, P.; Pan, Z.; Cao, L.; Gao, J.; Yao, H.; Liu, X.; Guo, R.; Liang, X.; Dong, J.; Ding, J. Restoration of osteochondral defects by implanting bilayered poly(lactide-co-glycolide) porous scaffolds in rabbit joints for 12 and 24 weeks. *J Orthop Translat.* **2019**, *19*, 68-80.
68. Niederauer, G. G.; Slivka, M. A.; Leatherbury, N. C.; Korvick, D. L.; Harroff, H. H.; Ehler, W. C.; Dunn, C. J.; Kieswetter, K. Evaluation of multiphase implants for repair of focal osteochondral defects in goats. *Biomaterials.* **2000**, *21*, 2561-2574.
69. Kumbhar, J. V.; Jadhav, S. H.; Bodas, D. S.; Barhanpurkar-Naik, A.; Wani, M. R.; Paknikar, K. M.; Rajwade, J. M. In vitro and in vivo studies of a novel bacterial cellulose-based acellular bilayer nanocomposite scaffold for the repair of osteochondral defects. *Int J Nanomedicine.* **2017**, *12*, 6437-6459.
70. Gotterbarm, T.; Breusch, S. J.; Jung, M.; Streich, N.; Wiltfang, J.; Berardi Vilei, S.; Richter, W.; Nitsche, T. Complete subchondral bone defect regeneration with a tricalcium phosphate collagen implant and osteoinductive growth factors: a randomized controlled study in Göttingen minipigs. *J Biomed Mater Res B Appl Biomater.* **2014**, *102*, 933-942.
71. O'Brien, F. J. Biomaterials & scaffolds for tissue engineering. *Mater Today.* **2011**, *14*, 88-95.
72. Tamaddon, M.; Samizadeh, S.; Wang, L.; Blunn, G.; Liu, C. Intrinsic osteoinductivity of porous titanium scaffold for bone tissue engineering. *Int J Biomater.* **2017**, *2017*, 5093063.
73. Chang, Y. S.; Gu, H. O.; Kobayashi, M.; Oka, M. Comparison of the bony ingrowth into an osteochondral defect and an artificial osteochondral composite device in load-bearing joints. *Knee.* **1998**, *5*, 205-213.
74. Duan, X.; Zhu, X.; Dong, X.; Yang, J.; Huang, F.; Cen, S.; Leung, F.; Fan, H.; Xiang, Z. Repair of large osteochondral defects in a beagle model with a novel type I collagen/glycosaminoglycan-porous titanium biphasic scaffold. *Mater Sci Eng C Mater Biol Appl.* **2013**, *33*, 3951-3957.
75. Bal, B. S.; Rahaman, M. N.; Jayabalan, P.; Kuroki, K.; Cockrell, M. K.; Yao, J. Q.; Cook, J. L. In vivo outcomes of tissue-engineered osteochondral grafts. *J Biomed Mater Res B Appl Biomater.* **2010**, *93*, 164-174.
76. Mrosek, E. H.; Schagemann, J. C.; Chung, H. W.; Fitzsimmons, J. S.; Yaszemski, M. J.; Mardones, R. M.; O'Driscoll, S. W.; Reinholz, G. Porous tantalum and poly-epsilon-caprolactone biocomposites for osteochondral defect repair: preliminary studies in rabbits. *J Orthop Res.* **2010**, *28*, 141-148.
77. Kang, H.; Zeng, Y.; Varghese, S. Functionally graded multilayer scaffolds for in vivo osteochondral tissue engineering. *Acta Biomater.* **2018**, *78*, 365-377.
78. Kon, E.; Filardo, G.; Shani, J.; Altschuler, N.; Levy, A.; Zaslav, K.; Eisman, J. E.; Robinson, D. Osteochondral regeneration with a novel aragonite-hyaluronate biphasic scaffold: up to 12-month follow-up study in a goat model. *J Orthop Surg Res.* **2015**, *10*, 81.
79. Carmont, M. R.; Carey-Smith, R.; Saithna, A.; Dhillon, M.; Thompson, P.; Spalding, T. Delayed incorporation of a TruFit plug: perseverance is recommended. *Arthroscopy.* **2009**, *25*, 810-814.
80. Spalding, T.; Carey-Smith, R.; Carmont, M.; Dunn, K. TruFit plugs for articular cartilage repair in the knee: 2 year experience, results and MRI appearances (SS-59). *Arthroscopy.* **2009**, *25*, e32-e33.
81. Dhollander, A. A.; Liekens, K.; Almqvist, K. F.; Verdonk, R.; Lambrecht, S.; Elewaut, D.; Verbruggen, G.; Verdonk, P. C. A pilot study of the use of an osteochondral scaffold plug for cartilage repair in the knee and how to deal with early clinical failures. *Arthroscopy.* **2012**, *28*, 225-233.
82. Joshi, N.; Reverte-Vinaixa, M.; Diaz-Ferreiro, E. W.; Domínguez-Oronoz, R. Synthetic resorbable scaffolds for the treatment of isolated patellofemoral cartilage defects in young patients: magnetic resonance imaging and clinical evaluation. *Am J Sports Med.* **2012**, *40*, 1289-1295.
83. Pearce, C. J.; Gartner, L. E.; Mitchell, A.; Calder, J. D. Synthetic osteochondral grafting of ankle osteochondral lesions. *Foot Ankle Surg.* **2012**, *18*, 114-118.
84. Bekkers, J. E.; Bartels, L. W.; Vincken, K. L.; Dhert, W. J.; Creemers, L. B.; Saris, D. B. Articular cartilage evaluation after TruFit plug implantation analyzed by delayed gadolinium-enhanced MRI of cartilage (dGEMRIC). *Am J Sports Med.* **2013**, *41*, 1290-1295.
85. Getgood, A. M.; Kew, S. J.; Brooks, R.; Aberman, H.; Simon, T.; Lynn, A. K.; Rushton, N. Evaluation of early-stage osteochondral defect repair using a biphasic scaffold based on a collagen-glycosaminoglycan biopolymer in a caprine model. *Knee.* **2012**, *19*, 422-430.
86. Chiang, H.; Liao, C. J.; Hsieh, C. H.; Shen, C. Y.; Huang, Y. Y.; Jiang, C. C. Clinical feasibility of a novel biphasic osteochondral composite for matrix-associated autologous chondrocyte implantation. *Osteoarthritis Cartilage.* **2013**, *21*, 589-598.
87. Kusano, T.; Jakob, R. P.; Gautier, E.; Magnussen, R. A.; Hoogewoud, H.; Jacobi, M. Treatment of isolated chondral and osteochondral defects in the knee by autologous matrix-induced chondrogenesis (AMIC). *Knee Surg Sports Traumatol Arthrosc.* **2012**, *20*, 2109-2115.
88. Gille, J.; Behrens, P.; Volpi, P.; de Girolamo, L.; Reiss, E.; Zoch, W.; Anders, S. Outcome of autologous matrix induced chondrogenesis (AMIC) in cartilage knee surgery: data of the AMIC Registry. *Arch Orthop Trauma Surg.* **2013**, *133*, 87-93.
89. Dhollander, A.; Moens, K.; Van der Maas, J.; Verdonk, P.; Almqvist, K. F.; Victor, J. Treatment of patellofemoral cartilage defects in the knee by autologous matrix-induced chondrogenesis (AMIC). *Acta Orthop Belg.* **2014**, *80*, 251-259.
90. Kon, E.; Filardo, G.; Perdisa, F.; Di Martino, A.; Busacca, M.; Balboni, F.; Sessa, A.; Marcacci, M. A one-step treatment for chondral and osteochondral knee defects: clinical results of a biomimetic scaffold implantation at 2 years of follow-up. *J Mater Sci Mater Med.* **2014**, *25*, 2437-2444.
91. Kon, E.; Filardo, G.; Perdisa, F.; Venieri, G.; Marcacci, M. Clinical results of multilayered biomaterials for osteochondral regeneration. *J Exp Orthop.* **2014**, *1*, 10.
92. Kon, E.; Filardo, G.; Di Martino, A.; Busacca, M.; Moio, A.; Perdisa, F.; Marcacci, M. Clinical results and MRI evolution of a nano-composite multilayered biomaterial for osteochondral regeneration at 5 years. *Am J Sports Med.* **2014**, *42*, 158-165.
93. Marcacci, M.; Filardo, G.; Kon, E. Treatment of cartilage lesions: what works and why? *Injury.* **2013**, *44* Suppl 1, S11-15.
94. Kon, E.; Delcogliano, M.; Filardo, G.; Busacca, M.; Di Martino, A.; Marcacci, M. Novel nano-composite multilayered biomaterial for osteochondral regeneration: a pilot clinical trial. *Am J Sports Med.* **2011**, *39*, 1180-1190.
95. Kon, E.; Delcogliano, M.; Filardo, G.; Pressato, D.; Busacca, M.; Grigolo,

## Osteochondral scaffold for early OA treatment

- B.; Desando, G.; Marcacci, M. A novel nano-composite multi-layered biomaterial for treatment of osteochondral lesions: technique note and an early stability pilot clinical trial. *Injury*. **2010**, *41*, 693-701.
96. Kon, E.; Delcogliano, M.; Filardo, G.; Fini, M.; Giavaresi, G.; Francioli, S.; Martin, I.; Pressato, D.; Arcangeli, E.; Quarto, R.; Sandri, M.; Marcacci, M. Orderly osteochondral regeneration in a sheep model using a novel nano-composite multilayered biomaterial. *J Orthop Res*. **2010**, *28*, 116-124.
  97. Young, R. Orthopaedics this week. <https://ryortho.com/2019/05/getting-cartilage-repair-right-after-25-years/>. Accessed by May 30, 2019.
  98. Kon, E.; Drobnic, M.; Davidson, P. A.; Levy, A.; Zaslav, K. R.; Robinson, D. Chronic posttraumatic cartilage lesion of the knee treated with an acellular osteochondral-regenerating implant: case history with rehabilitation guidelines. *J Sport Rehabil*. **2014**, *23*, 270-275.
  99. Collagen solutions plc positive eight-year results of ChondroMimetic® cartilage repair clinical study. <https://ir.collagensolutions.com/content/news/2018/210218>. Accessed by February 21, 2018.
  100. Degen, R. M.; Tetreault, D.; Mahony, G. T.; Williams, R. J. Acute delamination of commercially available decellularized osteochondral allograft plugs: a report of two cases. *Cartilage*. **2016**, *7*, 316-321.
  101. Farr, J.; Gracitelli, G. C.; Shah, N.; Chang, E. Y.; Gomoll, A. H. High failure rate of a decellularized osteochondral allograft for the treatment of cartilage lesions. *Am J Sports Med*. **2016**, *44*, 2015-2022.
  102. Bishop, M. E.; Seigo, M. A.; Hadley, C. J.; Freedman, K. B. Failure after osteochondral allograft transplantation with the chondrofix implant: a report of two cases. *JBS Case Connect*. **2018**, *8*, e86.
  103. Trattnig, S.; Ohel, K.; Mlynarik, V.; Juras, V.; Zbyn, S.; Korner, A. Morphological and compositional monitoring of a new cell-free cartilage repair hydrogel technology - GelrinC by MR using semi-quantitative MOCART scoring and quantitative T2 index and new zonal T2 index calculation. *Osteoarthritis Cartilage*. **2015**, *23*, 2224-2232.
  104. Kon, E.; Filardo, G.; Brittberg, M.; Busacca, M.; Condello, V.; Engebretsen, L.; Marlovits, S.; Niemeyer, P.; Platzer, P.; Posthumus, M.; Verdonk, P.; Verdonk, R.; Victor, J.; van der Merwe, W.; Widuchowski, W.; Zorzi, C.; Marcacci, M. A multilayer biomaterial for osteochondral regeneration shows superiority vs microfractures for the treatment of osteochondral lesions in a multicentre randomized trial at 2 years. *Knee Surg Sports Traumatol Arthrosc*. **2018**, *26*, 2704-2715.
  105. Delcogliano, M.; de Caro, F.; Scaravella, E.; Ziveri, G.; De Biase, C. F.; Marotta, D.; Marengi, P.; Delcogliano, A. Use of innovative biomimetic scaffold in the treatment for large osteochondral lesions of the knee. *Knee Surg Sports Traumatol Arthrosc*. **2014**, *22*, 1260-1269.
  106. Christensen, B. B.; Foldager, C. B.; Jensen, J.; Jensen, N. C.; Lind, M. Poor osteochondral repair by a biomimetic collagen scaffold: 1- to 3-year clinical and radiological follow-up. *Knee Surg Sports Traumatol Arthrosc*. **2016**, *24*, 2380-2387.
  107. Albano, D.; Martinelli, N.; Bianchi, A.; Messina, C.; Malerba, F.; Sconfienza, L. M. Clinical and imaging outcome of osteochondral lesions of the talus treated using autologous matrix-induced chondrogenesis technique with a biomimetic scaffold. *BMC Musculoskelet Disord*. **2017**, *18*, 306.
  108. Williams, R. J.; Gamradt, S. C. Articular cartilage repair using a resorbable matrix scaffold. *Instr Course Lect*. **2008**, *57*, 563-571.
  109. Saithna, A.; Arbuthnot, J.; Almazedi, B.; Spalding, T. Does acl reconstruction with accelerated rehabilitation influence the outcome of concomitant meniscal repair? *Orthop Proc*. **2010**, *92-B*, 423-423.
  110. Verhaegen, J.; Clockaerts, S.; Van Osch, G. J.; Somville, J.; Verdonk, P.; Mertens, P. TruFit Plug for Repair of Osteochondral Defects-Where Is the Evidence? Systematic Review of Literature. *Cartilage*. **2015**, *6*, 12-19.
  111. Madry, H.; van Dijk, C. N.; Mueller-Gerbl, M. The basic science of the subchondral bone. *Knee Surg Sports Traumatol Arthrosc*. **2010**, *18*, 419-433.
  112. Flachsmann, E. R.; Broom, N. D.; Oloyede, A. A biomechanical investigation of unconstrained shear failure of the osteochondral region under impact loading. *Clin Biomech (Bristol, Avon)*. **1995**, *10*, 156-165.
  113. Radin, E. L.; Rose, R. M. Role of subchondral bone in the initiation and progression of cartilage damage. *Clin Orthop Relat Res*. **1986**, 34-40.
  114. Brix, M.; Kaipel, M.; Kellner, R.; Schreiner, M.; Apprich, S.; Boszotta, H.; Windhager, R.; Domayer, S.; Trattnig, S. Successful osteoconduction but limited cartilage tissue quality following osteochondral repair by a cell-free multilayered nano-composite scaffold at the knee. *Int Orthop*. **2016**, *40*, 625-632.
  115. Guilak, F.; Butler, D. L.; Goldstein, S. A. Functional tissue engineering: the role of biomechanics in articular cartilage repair. *Clin Orthop Relat Res*. **2001**, S295-305.
  116. Setton, L. A.; Elliott, D. M.; Mow, V. C. Altered mechanics of cartilage with osteoarthritis: human osteoarthritis and an experimental model of joint degeneration. *Osteoarthritis Cartilage*. **1999**, *7*, 2-14.
  117. Pal, S. Mechanical properties of biological materials. In *Design of Artificial Human Joints & Organs*, Pal, S., ed. Springer US: Boston, MA, **2014**; pp 23-40.
  118. Kubicek, M.; Florian, Z. Stress strain analysis of knee joint. *Eng Mech*. **2009**, *16*, 315-322.
  119. Liu, C.; Blunn, G. Osteochondral scaffold. WO Patent publication No. WO 2017/118863 A1. World Intellectual Property Organization International Bureau.
  120. Getgood, A.; Henson, F.; Skelton, C.; Brooks, R.; Guehring, H.; Fortier, L. A.; Rushton, N. Osteochondral tissue engineering using a biphasic collagen/GAG scaffold containing rhFGF18 or BMP-7 in an ovine model. *J Exp Orthop*. **2014**, *1*, 13.
  121. Levingstone, T. J.; Ramesh, A.; Brady, R. T.; Brama, P. A. J.; Kearney, C.; Gleeson, J. P.; O'Brien, F. J. Cell-free multi-layered collagen-based scaffolds demonstrate layer specific regeneration of functional osteochondral tissue in caprine joints. *Biomaterials*. **2016**, *87*, 69-81.

Received: June 30, 2020

Revised: September 14, 2020

Accepted: September 25, 2020

Available online: December 28, 2020