

Atypical Cardiac Defects in Patients with RASopathies:

Updated data on CARNET study.

Giulio Calcagni^a, Giulia Gagliostro^b, Giuseppe Limongelli^c, Marta Unolt^a, Enrica De Luca^b, M. Cristina Digilio^d, Anwar Baban^a, Sonia B. Albanese^a, Giovanni B. Ferrero^e, Giuseppina Baldassarre^e, Gabriella Agnoletti^e, Elena Banaudi^e, Jan Marek^g, Juan P. Kaski^h, Giulia Tuoⁱ, Maurizio Marasiniⁱ, Francesca Cairelloⁱ, Andrea Madrigali^b, M. Giovanna Russo^c, Ornella Milanese^j, Roberto Formigari^{a,k}, Gabriele Egidy Assenza^k, Andrea Donti^k, Fabrizio Drago^a, Bruno Dallapiccola^d, Marco Tartaglia^d, Bruno Marino^b and Paolo Versacci^b

^a Department of Pediatric Cardiology and Cardiac Surgery, Bambino Gesù Children's Hospital and Research Institute, Rome, Italy

^b Pediatric Cardiology, Department of Pediatrics, Obstetrics and Gynecology, Sapienza University, Rome, Italy

^c Cardiologia SUN, Monaldi Hospital, II University of Naples, Naples, Italy

^d Genetics and Rare Diseases Research Division, Bambino Gesù Children's Hospital and Research Institute, Rome, Italy

^e Department of Pediatric and Public Health Sciences, Città della Salute e della Scienza, University of Turin, Italy

^g Cardiorespiratory Unit, Great Ormond Street Hospital for Children, London, UK - UCL Institute of Cardiovascular Science, London, UK

^h Centre for Inherited Cardiovascular Diseases, Great Ormond Street Hospital, London, UK - UCL Institute of Cardiovascular Science, London, UK

ⁱ Cardiovascular Department, Giannina Gaslini Institute, Genoa, Italy

^j Department of Woman and Child's Health, Pediatric Cardiology, University of Padova, Padua, Italy

^k Cardiology and Cardiac Surgery, Sant'Orsola Malpighi Hospital, Bologna, Italy

Corresponding author:

Paolo Versacci, MD, PhD,

Department of Pediatrics, Obstetrics and Gynecology,

Sapienza University of Rome,

Viale Regina Elena, 324, 00161 Rome, Italy.

e-mail: *paolo.versacci@uniroma1.it*

ABSTRACT

Background

RASopathy syndromes are a relatively common autosomal dominant disorder with heterogeneity in clinical and genetic features. Cardiac outcomes in terms of mortality and morbidity for typical congenital heart defects (such as pulmonary valve stenosis, hypertrophic cardiomyopathy, atrioventricular canal and atrial septal defect) have been previously reported. Nevertheless, other Atypical Cardiac Defects (ACDs) are also described. Aim of our study was to report prevalence and cardiac outcome of ACDs in patients with mutations of RAS/MAPK disorders.

Design and Methods A retrospective, multicentric observational study conducted in different centres with recognized experience in RAS-MAPK disorders (Cardiac Rasopathy NETwork - CARNET study) was performed. All clinical and surgical data of RASopathies patients followed until December 2019 were collected. Molecular analysis was also performed in all patients.

Results

Among patients followed up in CARNET centres (more than 440 patients), a total of 45 patients with ACDs, clinical and molecularly confirmed diagnosis of RAS/MAPK disorders were included in the study. Noonan Syndrome (NS), NS Multiple Lentigines (NSML) and CardioFacioCutaneous Syndrome (CFCS) were present in 36, 5 and 4 patients, respectively. Median age at last follow-up was 20.1 years (range 6.9 - 47 years). All patients underwent a preliminary genetic evaluation and all genes associated with these disorders were analyzed. Different ACDs were reported, such as mitral and aortic valve dysfunction, ascending and descending aortic arch anomalies, isolated coronary arteries disorders, coronary arteries dilation, enlargement of left appendage and isolated pulmonary branches diseases. Five

patients (11%) underwent cardiac surgery and only one needed a second intervention for mitral valve replacement and severe pericardial effusion. No patients died in our cohort.

Conclusions

Patients with RASopathies syndromes usually present a typical spectrum of CHDs. However, our data suggest that also ACDs must be carefully identified for the possible impact on the clinical outcome of these patients. No long-term follow up of these disorders has been yet reported in literature, but our preliminary data suggest a careful longitudinal follow up till adult age.

INTRODUCTION

RASopathies syndromes are an heterogeneous group of genetic multisystemic disorder characterised by distinctive facial features, developmental delay, learning difficulties, short stature, congenital heart disease (CHDs), renal anomalies, lymphatic malformations and bleeding disorders (1-4) ([23875798](#), [20876176](#), [20958325](#), [26446362](#)). They include different syndromes. The most common are Noonan syndrome (NS; OMIM #163950) CardioFacioCutaneous Syndrome (CFCS; OMIM #115150), Costello syndrome (CS; OMIM #218040) and NS with multiple lentigines (NSML; also known as LEOPARD syndrome; OMIM #151100). These syndromes overlap cardiac and extracardiac features and similar germline mutations of the RAS/MAPK pathway.

Heart defects, in terms of CHDs or cardiomyopathies (CMP), were reported in 60 – 90% of patients affected by RASopathies. Specific types of CHDs and correlation with the specific gene mutations have been described[(5, 6) ([28745539](#), [29525650](#)).

Typical CHDs (such as pulmonary valve stenosis - PVS, atrioventricular septal defect - AVSD, atrial septal defect - ASD) were classically reported (7-9) ([10586172](#), [22781091](#), [32022400](#)). Hypertrophic cardiomyopathy (HCM) in the obstructive or non-obstructive form, is the most common CMP associated with this group of syndromes (6) ([29525650](#)). Dilated CMP was reported as well, due to a pathological different mechanism in the RAS/MAPK cascade (10) ([26380542](#)).

Recently, our group reported a multi-centric study on 371 patients followed up in the CARNET database (Cardiac Rasopathies NETwork). These data reported the interventional and surgical results with specific genotype-phenotype correlations with gene and prognosis (11, 12) ([28768581](#), [29541661](#)). In literature, however, Atypical

Cardiac Defects (ACDs) were also reported associated with these patients, but no specific cardiac outcome has been previously reported.

Aim of our study was to update CARNET experience (updated up to December 2019) and analyze prevalence, gene correlations and outcome for ACDs associated with these mutations of RAS/MAPK disorders.

METHODS

Study design and populations

This is a multicentric retrospective observational study from centres participating in previous CARNET study (11) ([28768581](#)). The same seven cardiac centres (Italy and UK) with expertise in RASopathies, retrospectively analyzed data of patients with mutations in genes involved in the RAS/MAPK cascade. All patients with or without cardiac defects were preliminary included in the study. All patients had to have a molecularly confirmed diagnosis of NS, NSML, CS or CFCS. Patients were collected and updated until December 2019.

The following clinical data were collected: date of birth and sex, cardiac details at diagnosis and mutated genes.

Cardiac information was based on the following parameters: cardiologists' clinical evaluations and reports, electrocardiograms (ECGs), echocardiograms, discharge letters. When appropriate, cardiac procedures or cause of cardiac or extracardiac deaths were reported. All data was centralized in a unique database.

Once the database had been completed, we studied our population and selected a specific subgroup of patients, not previously reported, for further considerations. In these patients, "Atypical Cardiac Defects" (ACDs) were diagnosed. In detail, we defined ACDs, all the structural defects that are not classically associated with

RASopathy syndromes, thus having a low prevalence in this population. Particularly, as widely reported by literature, the following were considered “Typical” Cardiac Defects: Pulmonary Valve Stenosis (PVS) with usual supra-valvular involvement, complete or partial AtrioVentricular Canal Defects (AVCD), Atrial Septal Defects (ASD) and Hypertrophic Cardiomyopathy (HCM) in the obstructive or non-obstructive forms. When ACDs were associated with classical cardiac defects, these patients were not included in our subgroup of analysis. Persistent Foramen Ovalis after one year of age, due to its high prevalence among the general population, was not considered a cardiac defect.

All other defects, different from those reported above, were classified as ACD and described.

As known in literature, molecular diagnosis was performed through a combination of Sanger sequencing and targeted resequencing directed to scan the entire coding sequence of *CBL*, *PTPN11*, *SOS1*, *KRAS*, *HRAS*, *NRAS*, *SHOC2*, *RAF1*, *BRAF*, *MAP2K1* and *MAP2K2*, *SOS2*, *LZTR1*, *RIT1* genes, which had been recognized as RASopathy disease genes at the time of this study (4, 9, 13) [20958325](#), [27942422](#), [32022400](#)).

Clinical and genetic analyses were conducted with the approval of the institutional review boards of the participating institutions.

RESULTS

Study populations

Among patients followed up in CARNET centres (440 patients), we excluded all patients who did not present any cardiac defect associated with molecular gene's mutation (83 pts). Among these remaining 357 patients, we subsequently excluded all patients with molecular diagnosis of RASopathies syndrome and classical CHDs (PVS, ASD, AVSD) or HCM (a total of 312 pts). The remaining 45 patients were included in this study and analyzed in terms of type of CHD, mutated genes and cardiac outcome. NS, NSML and CFCS were present in 36, 5 and 4 patients, respectively. No CS patients were present in the remaining population. Figure 1 shows our cohort of patients and the subgroup with ACDs.

Median age at last follow-up was 20.1 ± 9.7 years (range 6.9-47 years). Twenty patients were female (44.4%). Different genes were reported in our population, including the more recent mutations discovered. The most common gene mutated was *PTPN11* gene, followed by *SOS1* and *BRAF*. Other genes were reported with a lower prevalence. Table 1 reports demographic, clinical and molecular characteristics of included patients.

Heart Defects

All patients reported had cardiac involvement, either with a single anomaly or multiple defects. Over half of the patients had a valvular disease, with mostly mitral or aortic valve involvement. Mitral valve regurgitation was more frequent than stenosis, which was recognized in one patient only. In particular, the insufficiency could be due to the high prevalence of anatomic dysplasia, which was described in about one third of

patients. Aortic valve regurgitation was similarly reported, significantly more frequent than aortic stenosis (about 25% versus 9%). Seven coronary artery (CA) dilations were reported and, in all cases, left CA was involved. No patients presented coronary artery stenosis. Structural abnormalities of ascending and descending aorta were present in 5 patients, including kinking, aortic coarctation and aortic root dilation. Interestingly, we reported 3 cases with moderate enlargement of left appendages, in all cases without other heart defects and also in absence of any intracardiac thrombus. Finally, even though PVS was excluded, isolated pulmonary branches abnormalities, in terms of dilation or stenosis or crossed pulmonary arteries were considered when no PVS was concomitantly reported. These anomalies were present in 7 patients (15,6%).

Table 2 reports in detail heart defects and all genes which were mutated in each different heart disease's subgroup.

Cardiac Prognosis

Among patients with ACD, 5 patients (5/45: 11%) underwent surgical treatment. One patient underwent end-to-end anastomosis for aortic coarctation, while a second patient had aortic valve replacement. Plasty of the mitral valve was necessary in one patient for severe regurgitation and in another one for stenosis. In a third patient, aged 5 at the time of first intervention, with prolapse and severe regurgitation, the plasty of the mitral valve was followed by a prosthesis implantation 20 months later. The early post-surgical outcome of the latter patient was characterized by severe pericardial effusion that required surgical drainage. All these 5 patients were affected by NS with *PTPN11*, *KRAS* and *SOS1* mutated genes (3, 1 and 1 patient, respectively). No patient died in our cohort for cardiac or extracardiac diseases. No other surgical complications have been reported, including post-surgical chylotorax. The remaining

patients did not need any surgical operation or percutaneous procedures at the time of the present retrospective analysis and they are on regular clinical and instrumental cardiac follow-up.

DISCUSSION

RASopathies are a heterogeneous group of genetic disorders with similar cardiac and extracardiac features.

Typically, mutations in genes involved in the RAS/MAPK cascade have been reported since *PTPN11* gene mutation was discovered in 2001 (14) ([11704759](#)). This mutation has been reported in about 50% of patients with NS. An additional 30% can be explained by other mutations in RAS/MAPK pathway genes, including *SOS1*, *RAF1*, *RIT1*, *KRAS*, *SHOC2*, *NRAS*, *SOS2*, *BRAF*, *A2ML1*, *LZTR1*, *MYST4*, *RASA2*, *RRAS*, *SPRY1* and *SYNGAP1* (13, 15-18) ([30896080](#), [27942422](#), [27412009](#), [23791108](#), [25795793](#)).

CHDs and CPM are very common features in patients with RASopathies, particularly in NS, with a prevalence greater than 50-80%. (9) ([32022400](#)).

Classically, PVS, HCM, AVCD and ASD have been considered as typical HD in the spectrum of these disorders. Minor defects have been also reported (7, 9) ([10586172](#), [32022400](#)), but a specific genotype-phenotype correlation of these anomalies with mutated genes and their prognosis is lacking in literature.

This study presents 45 patients from different centres with high experience in RAS/MAPK disorders. Particularly, regarding cardiac prognosis in these patients, we can affirm that ACDs in RASopathies are benign, well tolerated and generally no treatment should be indicated. In fact, in our cohort, only 5 patients with ACD needed cardiac treatment, mainly due to valvular involvement.

This result is in line with our previous experience regarding a large cohort of children and adolescents with RASopathies, where we underlined how the need for cardiac intervention, in terms of cardiac surgery or cardiac catheterization, appeared in less than 50% of our cohort (28768581) (11). Similar data were reported by other groups (19, 20) (24534818, 23750712). Anyway, a few selected cases, particularly when mitral or aortic valve were involved, could need cardiac treatment. Despite a worsening role of mitral and aortic valve in RASopathies with CHDs or HCM was previously reported (11) (28768581), it is interesting to note how these valvular diseases may have a clinical relevance also in absence of typical HDs. Mitral valve prolapse particularly with valve regurgitation may also need surgical treatment in cases of severe valve dysplasia. Even more so, for patients with significant valvular regurgitation and RASopathies, mitral valve plasty could not be enough, due to the anatomic characteristics of their mitral valve, where an abnormal and dysplastic anterior leaflet insertion is usually reported. This data stress the hypothesis that mitral or aortic valve involvement in RASopathies should not be considered as a minor defect either in the absence of major HD.

Surgical treatment is also mandatory for selected cases with other “structural” ACDs, such as aortic coarctation. Preliminary data conducted prior to an exhausted gene’s screening, reported left sided obstructive and particularly aortic coarctation in NS (21, 22) (9805134, 9048939).

Coronary arteries anomalies in RASopathies are not a rare entity. *PTPN11* gene mutations are usually associated with this finding, particularly in NSML patients (23) (16904216), but other genes mutations have been reported (24) (26686981). The phenomenon of coronary ectasia as a consequence of HCM is well known. It is supposed to be the result of an increased mass, diastolic dysfunction and obstruction

of the outflow tract of the left ventricle (25) (17697839). In the cohort of our patients, no individuals with coronary artery ectasia were affected by HCM or by other typical cardiovascular defects. This vascular phenotype may be secondary to the RAS pathway defect, independently from the underlying HCM and/or cardiovascular defects. Cardiologists should be aware of the dilation of the coronary arteries in these patients in order to prevent cardiovascular risks for myocardial infarction, such as arterial hypertension and hypercholesterolemia that can accelerate the atherosclerotic coronary artery disease. If the coronary abnormality is recognized on echocardiography, further evaluation with coronary CT angiography or MR angiography should be taken into account especially after pediatric age, especially to monitor the progression of the dilation. Due to the fact that the long-term outcome of ectasia of coronary arteries in patients with RASopathy is not known and that the dilated coronary arteries predispose to thrombosis event, it would be suitable the use of antiplatelet or anticoagulant agents even in these patients.

Regarding the dilation of the ascending aorta recognized in 2 of our patients, it is noteworthy that although it is a rare condition, aortic root dilation, aortic dissection and giant aneurysms of the sinuses of Valsalva have been described in adult patients with *PTPN11* gene mutation. In particular, histological evaluation of the surgically removed giant aneurysms showed deficiency of medial elastin and non-specific myxoid degeneration, suggesting a connective tissue disorder-like change in the wall of their aorta (26-29) (6465040, 2924789, 15964762, 16830086).

Aortic dilatation may be unnoticed until aortic dissection appears. For these reasons, a strict long-term follow-up, notably interval aortic measurements, is required (29)(16830086).

A dilation of the left atrial appendage was present in 3 patients. Only one case of congenital aneurysm of the left atrial appendage has been described in an adult patient with features consistent with both CFCS and NS (30) (20136862). Although patients with RASopathies are predisposed to haematological disorders, such as abnormal bleeding or bruising caused by coagulation defects, they may develop thrombi in the enlarged left atrial appendage or atrial fibrillation over the years. Hence, if antiaggregant or anticoagulant therapy may be necessary in these patients, a careful evaluation of the coagulation system is mandatory.

Although only a few patients required surgical treatment, we could observe that these lesions are benign in terms of morbidity. Furthermore, it is important to highlight these data to confirm the significant role of echocardiography for screening at the time of diagnosis of RASopathies and also during the clinical follow up even in absence of CHDs or CMPs. No patients died in our cohort, confirming that even though cardiac involvement is common in these syndromes, these lesions are usually benign in terms of mortality. Anyway, an accurate follow up with clinical evaluation, ECG and echocardiogram should be required, as previously reported in NS patients (3, 31, 32) (22980313, 20876176, 23312968).

Regarding genes, according to literature, *PTPN11* was the most common gene involved also in ACDs related to RASopathies, followed by *SOS1* and *BRAF*. These data are in line with our previous experience on typical HD (PVS, AVCD and HCM), where the prevalence reported in both populations was similar. Interesting to note, between the “new gene” recently discovered (15) (23791108), *RIT1* mutation was reported only in one case in our populations. This data may be explained by the major cardiac involvement of *RIT1* mutation, according to previous experience by our and other groups (33, 34) (27101134, 27684039)

STUDY LIMITATIONS

The retrospective design of the study represents per se a limitation. Moreover, RASopathy patients with negative genetic characterization may have biased our results. Finally, another limitation concerns the absence of specific statistical analysis in terms of Kaplan-Mayer for mortality or morbidity. Anyway, the absence of patients who died for cardiac and extracardiac reasons and a very low numerosity of patients who underwent a reintervention, could not allow to extrapolate these results.

CONCLUSIONS

Patients with RASopathies need lifetime cardiac follow-up, not only for the most common CHDs and HCM, but also for atypical cardiac features. No data regarding dilation CA or left appendage prognosis have prospectively reported in this population. Therefore, these apparently minor cardiac conditions may require cardiac surgery or percutaneous procedure in case of worsening of valvulopathy. Medical management aimed to prevent complications due to coronary arteries dilation and enlarged left atrial appendage might be needed. With a deeper understanding of cardiac characteristics and genotype-phenotype correlations of patients with RASopathies, it will be more and more achievable to offer appropriate counselling to families regarding prognosis and tailor management for optimal patient outcome.

References

1. Rauen KA. The RASopathies. *Annu Rev Genomics Hum Genet.* 2013;14:355-69.
2. Aoki Y, Niihori T, Inoue S, Matsubara Y. Recent advances in RASopathies. *J Hum Genet.* 2016 Jan;61(1):33-9.
3. Romano AA, Allanson JE, Dahlgren J, Gelb BD, Hall B, Pierpont ME, et al. Noonan syndrome: clinical features, diagnosis, and management guidelines. *Pediatrics.* 2010 Oct;126(4):746-59.
4. Tartaglia M, Gelb BD. Disorders of dysregulated signal traffic through the RAS-MAPK pathway: phenotypic spectrum and molecular mechanisms. *Ann N Y Acad Sci.* 2010 Dec;1214:99-121.
5. Calcagni G, Unolt M, Digilio MC, Baban A, Versacci P, Tartaglia M, et al. Congenital heart disease and genetic syndromes: new insights into molecular mechanisms. *Expert Rev Mol Diagn.* 2017 Sep;17(9):861-70.
6. Calcagni G, Adorisio R, Martinelli S, Grutter G, Baban A, Versacci P, et al. Clinical Presentation and Natural History of Hypertrophic Cardiomyopathy in RASopathies. *Heart Fail Clin.* 2018 Apr;14(2):225-35.
7. Marino B, Digilio MC, Toscano A, Giannotti A, Dallapiccola B. Congenital heart diseases in children with Noonan syndrome: An expanded cardiac spectrum with high prevalence of atrioventricular canal. *J Pediatr.* 1999 Dec;135(6):703-6.
8. Digilio MC, Romana Lepri F, Dentici ML, Henderson A, Baban A, Roberti MC, et al. Atrioventricular canal defect in patients with RASopathies. *Eur J Hum Genet.* 2013 Feb;21(2):200-4.
9. Linglart L, Gelb BD. Congenital heart defects in Noonan syndrome: Diagnosis, management, and treatment. *Am J Med Genet C Semin Med Genet.* 2020 Feb 5.
10. Gelb BD, Roberts AE, Tartaglia M. Cardiomyopathies in Noonan syndrome and the other RASopathies. *Prog Pediatr Cardiol.* 2015 Jul 1;39(1):13-9.
11. Calcagni G, Limongelli G, D'Ambrosio A, Gesualdo F, Digilio MC, Baban A, et al. Cardiac defects, morbidity and mortality in patients affected by RASopathies. CARNET study results. *Int J Cardiol.* 2017 Oct 15;245:92-8.
12. Calcagni G, Limongelli G, D'Ambrosio A, Gesualdo F, Digilio MC, Baban A, et al. Data on cardiac defects, morbidity and mortality in patients affected by RASopathies. CARNET study results. *Data Brief.* 2017 Dec 2;16:649-54.
13. Tidyman WE, Rauen KA. Expansion of the RASopathies. *Curr Genet Med Rep.* 2016 Sep;4(3):57-64.
14. Tartaglia M, Mehler EL, Goldberg R, Zampino G, Brunner HG, Kremer H, et al. Mutations in PTPN11, encoding the protein tyrosine phosphatase SHP-2, cause Noonan syndrome. *Nat Genet.* 2001 Dec;29(4):465-8.

15. Aoki Y, Niihori T, Banjo T, Okamoto N, Mizuno S, Kurosawa K, et al. Gain-of-function mutations in RIT1 cause Noonan syndrome, a RAS/MAPK pathway syndrome. *Am J Hum Genet.* 2013 Jul 11;93(1):173-80.
16. Yamamoto GL, Agüena M, Gos M, Hung C, Pilch J, Fahiminiya S, et al. Rare variants in SOS2 and LZTR1 are associated with Noonan syndrome. *J Med Genet.* 2015 Jun;52(6):413-21.
17. Yu KPT, Luk HM, Leung GKC, Mak CCY, Cheng SSW, Hau EWL, et al. Genetic landscape of RASopathies in Chinese: Three decades' experience in Hong Kong. *Am J Med Genet C Semin Med Genet.* 2019 Jun;181(2):208-17.
18. Tidyman WE, Rauen KA. Pathogenetics of the RASopathies. *Hum Mol Genet.* 2016 Oct 1;25(R2):R123-32.
19. Prendiville TW, Gauvreau K, Tworog-Dube E, Patkin L, Kucherlapati RS, Roberts AE, et al. Cardiovascular disease in Noonan syndrome. *Arch Dis Child.* 2014 Jul;99(7):629-34.
20. Colquitt JL, Noonan JA. Cardiac findings in Noonan syndrome on long-term follow-up. *Congenit Heart Dis.* 2014 Mar-Apr;9(2):144-50.
21. Digilio MC, Marino B, Giannotti A, Dallapiccola B. Noonan syndrome with cardiac left-sided obstructive lesions. *Hum Genet.* 1997 Feb;99(2):289.
22. Digilio MC, Marino B, Picchio F, Prandstraller D, Toscano A, Giannotti A, et al. Noonan syndrome and aortic coarctation. *Am J Med Genet.* 1998 Nov 2;80(2):160-2.
23. Pacileo G, Calabro P, Limongelli G, Santoro G, Digilio M, Sarkozy A, et al. Diffuse coronary dilation in a young patient with LEOPARD syndrome. *Int J Cardiol.* 2006 Sep 20;112(2):e35-7.
24. Calcagni G, Baban A, De Luca E, Leonardi B, Pongiglione G, Digilio MC. Coronary artery ectasia in Noonan syndrome: Report of an individual with SOS1 mutation and literature review. *Am J Med Genet A.* 2016 Mar;170(3):665-9.
25. Limongelli G, Pacileo G, Marino B, Digilio MC, Sarkozy A, Elliott P, et al. Prevalence and clinical significance of cardiovascular abnormalities in patients with the LEOPARD syndrome. *Am J Cardiol.* 2007 Aug 15;100(4):736-41.
26. Shachter N, Perloff JK, Mulder DG. Aortic dissection in Noonan's syndrome (46 XY turner). *Am J Cardiol.* 1984 Aug 1;54(3):464-5.
27. Morgan JM, Coupe MO, Honey M, Miller GA. Aneurysms of the sinuses of Valsalva in Noonan's syndrome. *Eur Heart J.* 1989 Feb;10(2):190-3.
28. Purnell R, Williams I, Von Oppell U, Wood A. Giant aneurysms of the sinuses of Valsalva and aortic regurgitation in a patient with Noonan's syndrome. *Eur J Cardiothorac Surg.* 2005 Aug;28(2):346-8.
29. Power PD, Lewin MB, Hannibal MC, Glass IA. Aortic root dilatation is a rare complication of Noonan syndrome. *Pediatr Cardiol.* 2006 Jul-Aug;27(4):478-80.

30. DeSena HC, Niyazov DM, Parrino PE, Lucas VW, Shah SB, Moodie DS. An unusual cardiac defect in a patient with clinical features overlapping between cardiofaciocutaneous and Noonan syndromes. *Congenit Heart Dis.* 2010 Jan-Feb;5(1):70-5.
31. Wilkinson JD, Lowe AM, Salbert BA, Sleeper LA, Colan SD, Cox GF, et al. Outcomes in children with Noonan syndrome and hypertrophic cardiomyopathy: a study from the Pediatric Cardiomyopathy Registry. *Am Heart J.* 2012 Sep;164(3):442-8.
32. Roberts AE, Allanson JE, Tartaglia M, Gelb BD. Noonan syndrome. *Lancet.* 2013 Jan 26;381(9863):333-42.
33. Calcagni G, Baban A, Lepri FR, Marino B, Tartaglia M, Digilio MC. Congenital heart defects in Noonan syndrome and RIT1 mutation. *Genet Med.* 2016 Dec;18(12):1320.
34. Kouz K, Lisowski C, Spranger S, Mitter D, Riess A, Lopez-Gonzalez V, et al. Genotype and phenotype in patients with Noonan syndrome and a RIT1 mutation. *Genet Med.* 2016 Dec;18(12):1226-34.

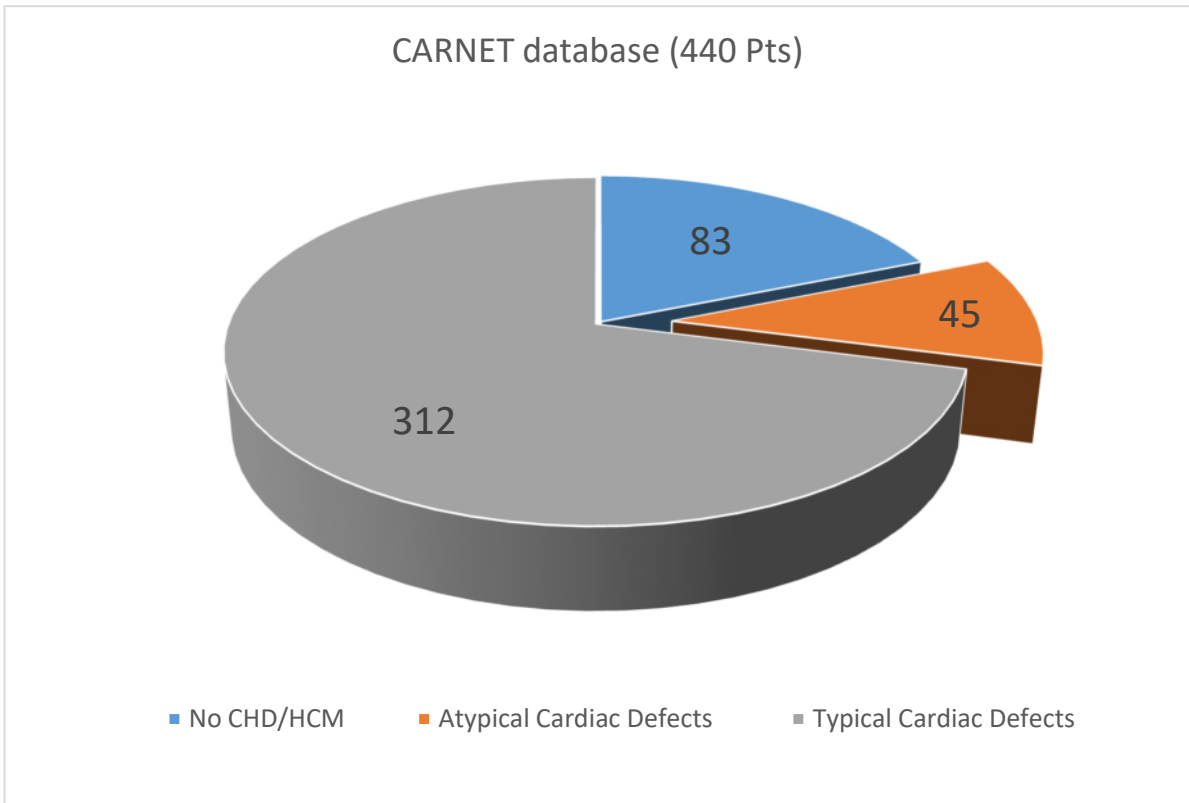


Figure1: cohort of patients and subgroup with ACDs (45 pts)

table 1: Demographic and molecular characteristics of patients

Age at last follow up (median and range)	20,1ys (6.9-47 ys)
Female sex	20 (44,4%)
Syndrome (n=45)	
NS	36 (80,0%)
LS	5 (11,1%)
CFC	4 (8,9%)
Mutated genes (n=45)	
<i>PTPN11</i>	27 (60,0%)
<i>SOS1</i>	5 (11,1%)
<i>BRAF</i>	4 (8,9%)
<i>SHOC2</i>	2 (4,4%)
<i>KRAS</i>	1 (2,2%)
<i>NRAS</i>	1 (2,2%)
<i>RAF1</i>	1 (2,2%)
<i>CBL</i>	1 (2,2%)
<i>LZTR1</i>	1 (2,2%)
<i>MEK1</i>	1 (2,2%)
<i>SOS2</i>	1 (2,2%)

Table2: heart defect and gene mutated

Type of heart defects		n (%)	gene	n
			<i>PTPN11</i>	9
			<i>RAF1</i>	1
Mitral valve anatomic anomalies (n=19)	prolapse	3 (6,7%)	<i>SOS1</i>	2
	dysplasia	16 (35,6%)	<i>SHOC2</i>	2
			<i>KRAS</i>	1
			<i>BRAF</i>	2
			<i>CBL</i>	1
			<i>LZTR1</i>	1
			<i>PTPN11</i>	5
			<i>SOS1</i>	2
Mitral valve disfunction (n=12)	Insufficiency	11 (24,4%)	<i>SHOC2</i>	1
	stenosis	1 (2,2%)	<i>KRAS</i>	1
			<i>BRAF</i>	1
			<i>CBL</i>	1
			<i>LZTR1</i>	1
			<i>PTPN11</i>	10
			<i>RAF1</i>	1
Aortic valve functional anomalies (n=16)	insufficiency	12 (24,4%)	<i>SOS1</i>	1
	stenosis	4 (8,9%)	<i>BRAF</i>	1
			<i>CBL</i>	1
			<i>SOS2</i>	1
			<i>LZTR1</i>	1
			<i>PTPN11</i>	5
			<i>SOS2</i>	2
			<i>PTPN11</i>	3
Aortic arch anomalies (N=5)	aortic coartation	1 (2,2%)	<i>SOS1</i>	1
	Kinking	2 (4,4%)	<i>BRAF</i>	1
	aortic root dilatation	2 (4,4%)		
Left appendage dilation (n=3)	dilatation	3 (6,7%)	<i>PTPN11</i>	2
			<i>NRAS</i>	1
Isolated Pulmonary Arteries Anomalies (n=7)	stenosis	5 (11,1%)	<i>PTPN11</i>	4
	dilatation	1 (2,2%)	<i>SHOC2</i>	1
	Crossing PAs	1 (2,2%)	<i>RIT1</i>	1
			<i>MEK1</i>	1