


Immediate implant placement in fresh alveolar sockets with a minimal split-thickness envelope flap: A randomised controlled clinical trial

Ruben Garcia-Sanchez^{1,2}  | Nikos Mardas³ | Jacopo Buti⁴ | Antonio Jose Ortiz Ruiz¹ | Guillermo Pardo Zamora¹

¹Universidad de Murcia, Murcia, Spain

²Guy's and St Thomas' NHS Foundation Trust, London, UK

³QMUL, The London School of Dentistry, London, UK

⁴UCL, Eastman Dental Institute, London, UK

Correspondence

Ruben Garcia-Sanchez, Unit of Periodontology, Guy's Hospital London, Great Maze Pond, London, SE1 9RT, UK.
Email: ruben.garciasanchez@gstt.nhs.uk

Abstract

Objectives: Comparing PES/WES scores, modified success rate, survival, success, buccal bone thickness and patient-reported outcomes of immediate dental implants placed in fresh alveolar sockets using a flap or a minimal split-thickness envelope flap (MSTEF).

Materials and methods: Implants following random assignment into a flap or MSTEF group were placed immediately in anterior and premolar areas. Guided bone regeneration and autogenous connective tissue graft were used in all cases. A temporary prosthesis was provided followed by the final prosthesis at 16–18 weeks. Success and survival rates together with radiographic buccal bone thickness and patient satisfaction were evaluated at 12-month post-loading. The aesthetic outcome was evaluated through the Pink (PES) and White (WES) Aesthetic Score by 8 blind clinicians of different training background and incorporated in modified success criteria.

Results: 28 implants were placed on 28 patients. No statistically significant differences were noted in PES (10.54 control versus 10.80 test), WES scores (6.97 control versus 6.95 test) or success criteria including aesthetic parameters (modified success criteria) for the different specialty groups (Range 69%–92%). In addition, no statistically significant differences were noted in survival (100%), success (100%), buccal wall thickness between control (0.72 ± 0.22) and test group (0.92 ± 0.31) and patients' reported outcomes.

Conclusions: Immediate dental implant treatment with flap/ MSTEF provided similar mean PES/WES scores, modified success rate, survival, mean buccal bone levels and patients' satisfaction. However, aesthetic failures were common in both groups.

KEYWORDS

aesthetics, bone, cone-beam computed tomography, dental implant, immediate implant, PES, WES

This is an open access article under the terms of the Creative Commons Attribution-NonCommercial-NoDerivs License, which permits use and distribution in any medium, provided the original work is properly cited, the use is non-commercial and no modifications or adaptations are made.

© 2021 The Authors. *Clinical Oral Implants Research* published by John Wiley & Sons Ltd.

1 | INTRODUCTION

Immediate implant placement or Type 1 implant placement involves the insertion of a dental implant immediately into a fresh extraction socket (Hämmerle et al. 2004, Lazzara, 1989). It has been suggested that this therapeutic protocol could be advantageous over late implant placement protocols by mitigating the effect of post-extraction alveolar ridge resorption (Araujo & Lindhe, 2009; Schropp et al., 2003), and thus supporting a faster and aesthetically pleasing implant restoration (Chen & Buser, 2014; Cosyn et al., 2011; Felice et al., 2015; Lang et al., 2012; Schropp et al., 2003). Clinical studies referring to the survival rate of immediate implants showed comparable results to implants placed in healed sites (Felice et al., 2015, Raes et al. 2016, Tonetti et al., 2017). However, clinical and experimental evidence has shown that buccal bone resorption and the resulting reduction in height and width of the alveolar ridge still takes place in immediately placed implants (Araujo et al., 2005; 2006; Benic et al., 2012; Botticelli et al., 2004; Liñares et al., 2011). One of the main side effects associated with this remodelling is the appearance of mid-facial recession of the mucosa with the consequent aesthetic compromise (Chen et al., 2007; 2014; Covani et al., 2014; Meijer et al., 2019; Tonetti et al., 2017; Zuiderveld et al., 2018). Several strategies have been adopted during the last years to prevent this recession. Some authors have tried augmentation techniques with various grafting materials (Cosyn et al., 2011; Prosper et al., 2003) and the use of resorbable (Hurzelar et al., 1998) or non-resorbable barriers (Hurzelar et al., 1997). Another strategy adopted by clinicians was the thickening of the soft tissues by placing a connective tissue graft (Zuiderveld et al., 2018), an allogeneic dermal graft (Hirsch et al., 2005), or xenogeneic collagen matrix (Lorenzo et al., 2012) at the time of surgery, with the aim to minimise this mid-facial recession. Finally, consideration has been given to the impact of flap elevation on the post-extraction bone resorption process. In 1965, Pfeifer (1965) suggested that avoiding elevation of a full-thickness flap during tooth extraction would have a positive impact on buccal bone remodelling, reducing the amount of bone resorption caused by the disruption of the periosteum-bone continuity. The same concept was tested in a preclinical immediate implant model in dogs, and it was concluded that a flapless approach could minimise buccal bone resorption (Blanco et al., 2008).

However, there seems to be a lack of human RCTs evaluating implant-related outcomes of immediate dental implants placed in fresh alveolar sockets with a flap versus a minimal split-thickness envelope flap (MSTEF) approach. Based on this, the aim of this study was to compare the Pink (PES) and White (WES) aesthetic score, success and survival rates, radiographic buccal wall thickness, and patient satisfaction of single-tooth immediate implants in the anterior maxillary region treated with either a flap (control) or a MSTEF (test) approach at 1-year post-loading.

2 | MATERIALS AND METHODS

This study was a randomised, controlled, single blind, single centre, university-based trial designed to compare the clinical, radiographic, aesthetic and patient-reported outcomes of immediate dental implants placed with a flap or MSTEF in the maxillary anterior and premolar region. The study was conducted according to the Declaration of Helsinki principles (version, 2008). The study protocol was approved by the Universidad de Murcia Ethical Committee and competent local authorities (Study ID: 1738/2017) and registered in ISRCTN (Study ID: ISRCTN81931981). The CONSORT guidelines for reporting clinical trials were followed (<http://www.consort-statement.org/>). Written informed consent was obtained from all the subjects included in the study. Patients were recruited in University of Murcia Hospital (Morales Meseguer) and received the allocated treatment from April 2018 to February 2020.

2.1 | Study population

Patients that were initially screened for eligibility, including a CBCT examination, were enrolled in the study based on the following criteria:

2.1.1 | Inclusion criteria

- Adult patients (age above 21 years old) in need of a single-tooth extraction (with both neighbouring teeth present) in the maxillary incisors, canine, premolars area due to trauma, periodontitis, endodontic or unrestorable caries.
- Full-mouth plaque (FMPS) (O'Leary et al., 1972) below 25% and bleeding scores (FMBS) (Lang et al., 1986) below 10% at study baseline.
- In case of active periodontal disease, the patient should have successfully completed periodontal treatment before enrolment.
- Intact buccal plate as judged in pre-extraction CBCT screening and clinically after the extraction.
- Adequate mesio-distal space for implant placement (allowing at least 1.5 mm of bone on each side of planned implant platform after placement).
- Patient had adequate quantity of native bone to achieve a satisfactory primary stability. This was defined as a minimum insertion torque of 30 Ncm.

Patients included in the study were randomly assigned to the test or control group by balanced block randomisation using a computer-generated table (Figure 1). Treatment assignment was concealed to the treating surgeon (GPZ) by opaque envelopes that were opened only after completion of tooth extraction and assessment of the feasibility for immediate implant placement.

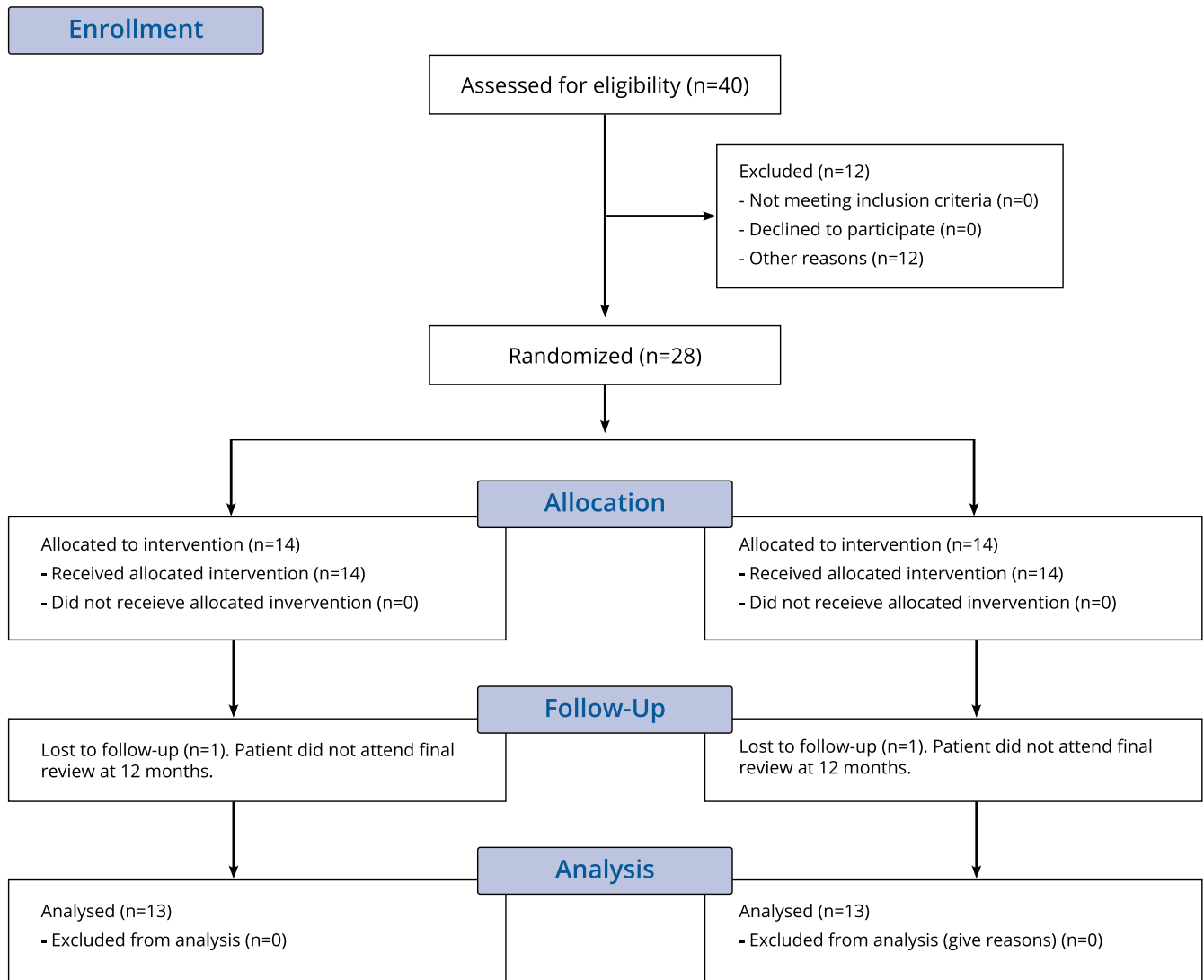


FIGURE 1 Consort diagram

2.2 | Clinical interventions

One hour before surgery, all subjects were pre-medicated with Amoxicillin/Clavulanic acid 1,000 mg/125 mg (Augmentin) or Clindamycin 600 mg (Dalacin) in case of an allergy to penicillin. Following minor intra-ligament incision, the affected tooth was atraumatically extracted by means of fine periostomes, attempting to preserve the integrity of surrounding osseous walls. After tooth extraction, granulation tissue was removed and the integrity of buccal plate was assessed by running a probe within the socket wall to corroborate the absence of dehiscences, fenestrations or fractures in buccal wall. At this stage, the surgeon proceeded as indicated in the randomisation envelope, by placing the dental implant with a flap or MSTEF. In the control group, a mid-crestal incision extending intra-crevicular one or two teeth mesially and distally was performed to increase flap mobility. No vertical releasing incisions were carried out. A full-thickness muco-periosteal flap was elevated 3–4mm from the buccal/lingual bone crest in the area of the tooth to

be extracted. Flap mobility was increased by periosteum dissection at the base of the flap when it was indicated. In the test group, no incisions other than the initial intra-ligament around the tooth were made and no flap was reflected. Self-tapping, tapered, Biomimetic OCEAN, Avinent® implants were immediately placed into the fresh extraction socket in both groups. The choice of implant diameter and its final three-dimensional position were restoratively driven and guided by pre-fabricated surgical guides in order to achieve an implant position compatible with a screw-retained restoration. In the apico-coronal direction, the implants were placed 3mm apical to the projected zenith of implant-supported restoration in both groups (as indicated in the surgical guide). The horizontal distance (in mm) between the mid buccal surface of the implant and the external aspect of buccal cortical plate and the mean vertical distance (in mm) between implant shoulder and first BIC were measured with a calliper and periodontal probe, respectively. The gap between the internal walls of the socket and the implant surface was filled with an allograft (Gen-Os, Osteógenos s.r.l., Madrid,

Spain) and covered with an equine pericardium collagen membrane (Evolution, Osteógenos, s.r.l., Madrid, Spain). An autogenous connective tissue graft (CTG), 1–2 mm in thickness, harvested from the palatal areas of the patient, was placed and stabilised in the buccal aspect of the socket by means of a mattress sutures. In the MSTEF group, a small, partial thickness pouch was created in the buccal aspect to accommodate the CTG without separating the periosteum from the underlying bone. A semi-submerged healing abutment of the same or narrower diameter than the implant was placed allowing more space for the horizontal development of the soft tissues (Salama et al., 1995). In both groups, the flaps were secured around the healing abutment by means of non-resorbable single interrupted sutures (5–0, Prolene, Ethicon). Post-operative medications included continuation of the antibiotic regimen for 5 days and a second dose of diclofenac or paracetamol. The patients were instructed to avoid chewing or brushing around the treated area and rinse twice, daily with chlorhexidine 0.12% for the first 2 weeks. The sutures were removed at 1 week after the procedure. The normal oral hygiene regime was resumed by week 3. Post-surgical controls consisting of professional prophylaxis and oral hygiene instructions were performed at weeks 3, 9 and 12. A removable provisional prosthesis (RPD) with no buccal extension was provided to all patients to preserve prosthetic space.

A temporary implant-supported, screw-retained restoration was provided between weeks 8 and 10 after implant insertion to allow contouring of peri-implant soft tissues. At this visit, occlusion was adjusted to have minimal contact on the implant-supported restoration on inter-cuspal (IC) position and during lateral/anterior guidance when implant-supported restoration was involved. The final screw-retained restoration was fitted at week 16–18 after implant insertion with a torque of 30 Ncm. Standardised photographs of implant supra-structure including the surrounding tissues and a periapical radiograph were taken and any adverse events were recorded.

At six-month post-loading review, the occlusion was checked and adjusted as needed, and the oral hygiene was assessed by using a disclosing agent (Plac-Control®, DENTAID, Barcelona, Spain). Removal of supra/subgingival deposits and oral hygiene instructions were given accordingly, while any adverse events were recorded.

At the final, 12-month post-loading review, occlusion and oral hygiene were assessed in a similar way. All outcome variables were recorded including the radiographic buccal bone thickness measurements in CBCT and clinical photographs. Any adverse events were also recorded.

2.3 | Study outcomes

2.3.1 | Primary outcomes

- **Pink Aesthetic Score (PES).** PES assessment was recorded for the test and control group by eight examiners of different clinical background (two periodontists, two orthodontists, two prosthodontists and two general dentists) based on previously reported

criteria (Fürhauser et al., 2005) using the same standardised photographs taken at 1-year post-loading.

- **White Aesthetic Score (WES).** The WES assessment was recorded for the test and control group by eight examiners of different clinical background (two periodontists, two orthodontists, two prosthodontists and two general dentists) based on previously reported criteria (Belser et al., 2009) using the same standardised photographs taken at 1-year post-loading.

The average and the range of PES and WES scores out of all 8 examiners was calculated. To evaluate the intra-examiner reproducibility, all PES and WES measurements of all examiners were repeated by all examiners after 8–12 weeks. An anonymised PES/WES table with a patient code was provided with each picture to be evaluated by the eight independent assessors.

- **Modified success criteria** were applied to incorporate the aesthetic outcomes in success rates. According to this set of modified success criteria, a dental implant was considered successful if all the above success and survival criteria were met and an average PES score of 8 or above with an average WES score of 6 or above was recorded at the final assessment (Cosyn et al., 2011).

2.3.2 | Secondary outcomes

- **Implant survival.** A surviving implant was any dental implant which remained in situ (ITI consensus 2004).
- **Implant success.** A successful implant was defined according to the criteria set by Albrektsson et al. (1986):
 - a. Absence of any continuous peri-implant radiolucency based on radiographic findings.
 - b. Absence of implant mobility.
 - c. Absence of a recurrent peri-implant infection with suppuration.
 - d. Bone level changes evaluated on periapical radiographs around dental implants less than 1 mm during the first year after placement.
- **Buccal plate thickness.** A CBCT examination was performed at 12-month post-loading. The distance from DI surface (mid buccal) to external aspect of buccal plate measured at 0mm, 3mm and 6mm from DI shoulder at 12-month post-loading CBCT. This was performed by a single calibrated examiner who was unaware of the treatment assignment using the proprietary software for the Vatech 3D scanner (Ez3D). Radiographic measurements were twice, leaving at least 3 days in between measurements to assess agreement. CBCT images were anonymised in respect to patients' identity and group allocation.
- **Patients' satisfaction questionnaire.** At 12-month post-loading review visit, the patients' treatment satisfaction was evaluated by means of the following questionnaire developed by de Bruyn et al. (1997):
 - a. Do you experience any difficulties during talking?
 - b. Are you happy with the final aesthetic outcome?
 - c. Would you undergo the same intervention again?
 - d. Would you recommend this treatment to another patient?

- e. *Do you feel the implant tooth as one of your own?*
- f. *How do you feel about the oral hygiene measures needed to look after the implant tooth?*
- g. *How do you feel about the help provided by your dentist during the treatment?*
- h. *What do you think about the cost-effectiveness of this treatment?*

The possible answers were stratified as extremely negative, moderately negative, slightly negative, slightly positive, moderately positive and extremely positive.

- A *visual analogue scale* rating the overall patients' aesthetic perception of final restoration was also recorded at the day of the fit and at 12-month review (Aitken, 1969). The scale ranged from 0 (very poor aesthetics) to 10 (excellent aesthetics).

2.4 | Statistical analysis & sample size calculation

Primary outcomes of the study were considered PES and WES (on the basis of which the sample size was calculated) as well as the modified success criteria proposed.

Sample size was calculated using a two-tailed alpha of 0.05 and a power of 0.8. As previously reported (Cosyn et al., 2011) for PES a potential *SD* of 2.47 mm was considered. The assumed relevant expected difference between groups would be 3. A total of at least 13 patients per group were then estimated. For WES, a potential *SD* of 1.52 mm was considered with an expected relevant difference of 2. A total of 11 patients per group were needed. Therefore, a total sample size of 14 patients per group was considered to have sufficient power for both outcomes and to allow for possible drop-outs.

Descriptive statistics were expressed as mean and standard deviation for continuous variables and frequency or percentage for dichotomous variables. Differences between the two groups in success rate or survival rate were calculated by means of Fisher Exact test. Between-group differences for buccal bone were estimated by an independent samples *t* test, while non-parametric test was applied for PES and WES scores by Kruskal–Wallis/Mann–Whitney U test. Intra-class correlation (ICC) analysis to assess the inter-examiner reliability for mean total PES and WES score outcomes at 12-month post-loading were assessed within each dentist groups (GDP, Orthodontist, Periodontist, Prosthodontist), between dentist groups, treatment groups (flap/ MSTEF) and

overall. Mixed effect model for total PES and WES Score was created using treatment group (flap/flapless), dentist groups (GDP, Orthodontist, Periodontist, Prosthodontist), distance DI to buccal bone plate (mm) at 12 months as fixed effects covariates while measurement occasion nested examiner as random effects covariate. Within-group comparisons for patient-reported outcomes (aesthetic) between baseline and 12 months were made by paired *t* tests, while between-group differences were estimated by an independent samples *t* test. The Mann–Whitney U test was used to compare differences between the two independent groups for each question of the survey (ordinal outcome).

JMP® Pro 13 was used as statistical software. All statistical comparisons were conducted at the 0.05 level of significance.

3 | RESULTS

3.1 | Patient's characteristics

Out of 40 patients that were initially screened for eligibility, including CBCT examination, 28 patients were enrolled in the study. The patient characteristics and reason for extractions were similar in the two groups (Table 1). Good levels of oral hygiene were recorded (FMPS below 25%) throughout the study period for all subjects. Although patients with controlled periodontal disease were considered in the inclusion criteria, none of the patients finally included in the study presented any evidence of periodontal disease or attachment loss in teeth neighbouring the implant site. All subjects completed the post-surgical follow-up but one subject in each group missed the 12-month follow-up and was not included in analyses.

3.2 | Surgical intervention characteristics

The surgical intervention characteristics including implant diameter, length, insertion torque, intra-operative measurements, type of soft & hard tissue grafting are included in Table 2. No post-operative complications were noted in the test or control group during the study. One patient in each group did not have a GBR procedure because there was no vestibular gap between the implant and the socket wall. For one patient in control group and one patient in test group, 12-month

TABLE 1 Patient's characteristics

	Flap [n = 14] (%)	Flapless [n = 14] (%)
Males	5 (35.72)	5 (35.72)
Females	9 (64.28)	9 (64.28)
Age at implant insertion (mean, <i>SD</i>)	47 (10.28)	47 (10.88)
Extraction due to tooth/root fracture	6 (42.9)	9 (64.3)
Extraction due to unrestorable tooth due to extensive carious lesion.	3 (21.4)	1 (7.1)
Extraction due to endodontic pathology.	2 (14.3)	1 (7.1)
Extraction due to retained root	3 (21.4)	3 (21.5)

TABLE 2 Intervention characteristics

	Flap [n = 14] (%)	Flapless [n = 14] (%)
Implants at central incisor position	2 (14.3)	0 (0)
Implants at lateral incisor position	0 (0)	2 (14.3)
Implants at canine position	2 (14.3)	1 (7.1)
Implants at 1st premolar position	5 (35.7)	4 (28.6)
Implants at 2nd premolar position	5 (35.7)	7 (50)
Implants 10mm long	1 (7.1)	4 (28.6)
Implants 11.5mm long	6 (42.9)	8 (57.1)
Implants 13mm long	6 (42.9)	2 (14.3)
Implants 15mm long	1 (7.1)	0 (0)
Mean implant length	12.29 (1.22)	11.29 (0.99)
Implants with 3.5mm diameter	3 (21.4)	2 (14.3)
Implants with 4.0mm diameter	10 (71.5)	5 (35.7)
Implants with 4.5mm diameter	1 (7.1)	7 (50)
Insertion torque below 35 n/cm	2 (14.3)	1 (7.1)
Average insertion torque (SD)	38.33 (5.40)	45.57 (7.11)
Mean horizontal distance (mm) between implant (mid buccal) and external aspect of buccal cortical plate (SD).	3.71 (1.45)	3.63 (1.32)
Mean vertical distance (mm) between implant shoulder and first BIC (SD).	3.79 (1.55)	4.32 (2.37)
Sites augmented with xenograft and membrane at implant placement	13(92.85)	13(92.85)
Site augmented with soft tissue graft at implant placement	14 (100)	14 (100)

post-loading pictures could not be retrieved and final CBCT could not be performed. These subjects were not included in the statistical analysis performed for the aesthetic and radiographic outcomes.

3.3 | Implant outcomes

3.3.1 | Primary outcomes

- PES/WES scores. In relation to the aesthetic outcomes, PES and WES are presented analytically in Tables 3 and 4, respectively, reporting mean PES/WES outcomes at 12-month post-loading with standard deviations are in parenthesis. The total PES scores were similar in the test and control groups although some statistical differences were noted in some items of PES scores. The total WES scores were also similar between groups and no statistically significant difference was noted. The majority of cases had PES/WES scores greater than the arbitrarily set clinical acceptability level.
- *Implant modified success*. There was not statistically significant difference between groups based on the modified success criteria proposed by Cosyn et al., 2011; the latter was 69% in the test

TABLE 3 PES at 12-month post-loading

Flap	Mesial Papilla N (%)	Distal Papilla N (%)	Soft tissue level N (%)	Soft tissue contour N (%)	Alveolar process deficiency N (%)	Soft tissue colour N (%)	Soft tissue texture N (%)	Total PES Score Mean (SD)
0	0 (0%)	35 (17%)	3 (1%)	12 (6%)	5 (2%)	9 (4%)	12 (6%)	10.54 (2.49)
1	65 (31%)	107 (51%)	63 (30%)	95 (46%)	59 (28%)	85 (41%)	93 (45%)	
2	143 (69%)	66 (32%)	142 (68%)	101 (49%)	144 (69%)	114 (55%)	103 (50%)	
Flapless								
0	10 (5%)	17 (8%)	11 (5%)	14 (7%)	4 (2%)	4 (2%)	13 (6%)	10.80 (2.23)
1	70 (34%)	77 (37%)	70 (34%)	94 (45%)	65 (31%)	65 (31%)	79 (38%)	
2	128 (62%)	114 (55%)	127 (61%)	100 (48%)	139 (67%)	139 (139%)	116 (58%)	
Mean Difference (SE)	-	-	-	-	-	-	-	0.25 (0.23)
p-value	0.0641 ^a	<0.0001 ^{a*}	0.0784 ^a	0.8511 ^a	0.6328 ^a	0.0093 ^{a*}	0.2603 ^a	0.4608 ^b

^aKruskal-Wallis test

^bMann-Whitney Test

*Statistically significant difference

TABLE 4 WES at 12-month post-loading

	Tooth form N (%)	Tooth volume/outline N (%)	Colour (hue/value) N (%)	Surface texture N (%)	Translucency N (%)	Total WES Score Mean (SD)
Flap						
0	18 (9%)	21 (10%)	18 (9%)	2 (1%)	14 (7%)	6.97 (1.97)
1	109 (52%)	115 (55%)	117 (56%)	71 (34%)	77 (37%)	
2	81 (39%)	72 (35%)	73 (35%)	135 (65%)	117 (56%)	
Flapless						
0	22 (11%)	29 (14%)	25 (12%)	5 (2%)	15 (7%)	6.95 (2.40)
1	101 (49%)	93 (45%)	99 (48%)	70 (34%)	78 (38%)	
2	85 (41%)	86 (41%)	84 (40%)	133(64%)	115 (55%)	
Mean Difference (SE)	–	–	–	–	–	–0.01 (0.22)
P-value	0.9089 ^a	0.5904 ^a	0.6028 ^a	0.7574 ^a	0.8244 ^a	0.6066 ^b

^aKruskal–Wallis test^bMann–Whitney Test.

and 92% in the control group ($p = .3217$) for GDPs; 85% in the test and 85% in the control group ($p = 1.0000$) for Periodontists; 85% in the test and 92% in the control group ($p = 1.0000$) for Prosthodontists; and 85% in the test and 92% in the control group ($p = 1.0000$) for Orthodontists.

3.3.2 | Secondary outcomes

- *Implant survival.* The implant survival rate was 100% for both the test and control group ($p = 1.000$).
- *Implant success.* The success rate according to the Albrektsson et al. (1986) criteria were also 100% for both groups ($p = 1.000$).
- *Buccal plate thickness.* The mean distance from dental implant to external aspect of cortical plate (at 0mm) measured in CBCT at 12-month post-loading was 2.78mm in control group and 2.54mm in test group ($p = .600$). None of these differences was statistically significant. Similar results were obtained for the measurements at 3 and 6mm (data not presented).
- *Patients' satisfaction questionnaire.* The majority of the patients (84.6% in the test group and 69.2% in the control group) replied with a "slightly positive" to "extremely positive" answer to all the questions included in the questionnaire.
- *Visual Analogue Scale (VAS).* The overall patients' satisfaction with the final aesthetic outcome, as measured with VAS was high in both groups at 12-month post-loading. Overall, patients' satisfaction was high at 12-month post-loading and no statistically significant differences were noted between groups.

3.4 | Inter-Examiner correlation analysis

Intra-class correlation (ICC) coefficients for the inter-examiner reliability (between first and second evaluation) for mean PES/WES outcomes at 12-month post-loading for each specialty group were

calculated. These were obtained to assess operator agreement in the evaluation. An overall strong inter-examiner agreement was noted for all dental groups. However, the inter-examiner correlation coefficients between each specialty group (GDP, Orthodontist, Periodontist, Prosthodontist) showed a weak-to-moderate correlation.

3.5 | Mixed model effect analysis

Finally, mixed effect model for total PES and WES Score was created using treatment group (flap/ MSTEF), dentist groups (GDP, Orthodontist, Periodontist, Prosthodontist) and radiographic buccal plate thickness at 12 months as fixed effects covariates while measurement occasion nested examiner as random effects covariate. GDP group was used as a reference group, so all the estimated differences were calculated against that group. Based on this, a statistically significant association was found between "Total PES Score" and Examiner (Orthodontist and Prosthodontist group).

4 | DISCUSSION

This randomised controlled clinical trial was the first in our knowledge, to compare implant-related outcomes of immediate dental implants placed with a flap or a MSTEF. Based on our findings, similar PES, WES, success rates, survival and patients' satisfaction should be expected following restoration of single missing teeth in the maxillary incisor, canine and premolar area with immediate dental implant placed with a flap or a MSTEF. The thickness of the buccal bone at 12-month post-loading was also similar in both groups. One previous study that investigated the impact of flap elevation on the success of buccal bone augmentation during immediate implant placement, favoured the flap-elevation group where a higher coronal level of the regenerated bone was achieved (Covani et al., 2008). Two other

studies (Grassi et al., 2019; Mazzocco et al., 2017) that investigated the impact of flap elevation on the buccal plate thickness of immediately placed implants, did not report any significant differences between groups at 6 months. Contradictory results were reported in previous studies that compared the impact of flap elevation on delayed or late dental implant placement (Bashutski et al., 2013; De Bruyn et al., 2011; Froum et al., 2011; Maló & Nobre, 2008; Sunitha & Sapthagiri, 2013). Increased bone resorption was noted for the flapless group in two studies (De Bruyn et al., 2011; Maló & Nobre, 2008) in contrast to the other two that favoured the flapless approach (Bashutski et al., 2013; Sunitha & Sapthagiri, 2013).

For the aesthetic assessment of the cases, PES/WES indexes were used. No differences were noted for PES/WES between the two groups. In previous immediate implant studies, the reported PES scores at twelve-month post-loading ranged significantly between 8 and 13 (Cosyn et al., 2011; Cosyn et al., 2013; De Angelis et al., 2011; Esposito et al., 2015; Felice et al., 2015; Nimwegen et al., 2018). The implant location, surgical and prosthetic protocol and especially the provision of an immediate restoration in addition to immediate placement (Cosyn et al., 2011; Esposito et al., 2015; Felice et al., 2015; Nimwegen et al., 2018) may have accounted for the higher PES scores in some of these studies.

Of particular importance is the overall aesthetic outcome combining the results of the PES and WES. 19.2% of patients in the test group and 13.4% control group recorded PES and WES scores that are considered as indicative of optimal aesthetic outcomes (PES equal or above 12 and WES equal or above 9). This was in agreement with previous reports on the aesthetic outcomes of single implant restorations (7%–35%) (Belser et al., 2009; Buser et al., 2009; Cosyn et al., 2011; Raes et al., 2011) and indicates that optimal aesthetics seem difficult to achieve and suboptimal aesthetic outcomes are quite prevalent in single-tooth immediate implants in the anterior maxilla. Therefore, patients should be warned about these aesthetic challenges before embarking with treatment. Regarding the present study, the difficulties to match papilla levels and gingival margin contour with the neighbouring/contralateral tooth and achieving an acceptable shape and shade in the final restoration were the most common reasons for negative scores in PES and WES, respectively. Some of the pitfall regarding WES scores could have been managed by retaking the shade and/or providing additional restorative work on the neighbouring teeth.

When using the success criteria defined by Albrektsson (Albrektsson et al., 1986), the one-year success rate in our study for both groups (100%) seem to correlate to the success rate of immediate implants reported in previous studies using the same criteria (Atieh et al., 2013; Block et al., 2009; Esposito et al., 2015; Malchiodi et al., 2013). However, recent systematic reviews have suggested that the Albrektsson criteria (Albrektsson et al., 1986) may not be adequate to evaluate all treatment outcomes comprehensively. It was suggested that future studies should include other elements, such as soft tissue profile/ detailed aesthetics and patient-reported outcomes in the definition of success criteria (den Hartog et al., 2008; Lang et al., 2012). On this line, our study found that suboptimal

aesthetic outcomes were not rare in both groups as it was shown in the modified success criteria. Similarly, in another immediate implant study where the same modified success criteria were used, a failure rate of 21% at 3-year post-loading was reported (Cosyn et al., 2011).

Regarding the early survival rate of immediate implants in both groups was similar, if not higher, to the survival rates reported in previous systematic reviews (Chrcanovic et al., 2015; Cosyn et al., 2019; Lang et al., 2012) indicating that both flap and minimal split-thickness approaches are valid treatment modalities for immediate implant placement.

Currently, there are not much data published about the buccal plate thickness following immediate implants placed with different types of flap designs. This is an important aspect to consider, as the loss of buccal plate may lead to soft tissue recession and the associated aesthetic deficiency (Benic et al., 2012; Buser et al., 2013; Miyamoto & Obama, 2011). Therefore, a surgical technique that would minimise the anticipated post-extraction resorption or mitigate its negative effect would be desirable. In our study, no significant differences were found between groups regarding buccal plate thickness at 12-month post-loading. Some preclinical studies investigating the impact of flap elevation on buccal bone plate reported no impact on bone remodelling (Caneva et al., 2010) whereas others reported less buccal plate resorption following a flapless approach (Blanco et al., 2008). Similar to our study, previous clinical trials concluded that flap elevation does not seem to have an impact on buccal bone dimensions following immediate implantation (Grassi et al., 2019; Mazzocco et al., 2017). This could have provided accurate information when compared with CBCT examination at 12 months, mainly regarding the impact of flap elevation on buccal bone remodelling.

Regarding the use of soft tissue graft, evidence shows that augmented sites with ACTG at the time of implant placement will result in thicker peri-implant tissues and more mid-facial tissue stability (Seysens et al., 2021). Based on this, it was decided that ACTG should be used in this study for soft tissue augmentation in all test/control subjects to support aesthetic outcomes in both groups (Nimwegen et al., 2018). However, it is not possible to quantify the impact that the use of ACTG had in the final PES score for the present study based on the information gathered.

The overall patients' satisfaction with the final aesthetic outcome was high (>85% in the VAS scale at 12-month post-loading review) for both test and control subjects. This seems to be in agreement with a recent systematic review evaluating patients' satisfaction with implant-supported prosthesis using a similar visual scale scoring system (Wittneben et al., 2018). The authors reported a mean "VAS for mucosa" of 8.47 (median: 8.67; min-max: 7.3–9.2) and mean "VAS for restoration" of 8.89 (median: 9.03; min-max: 8.0–9.4). Based on this, it seems reasonable to state that both treatment modalities were equally successful according to the patient's aesthetic point of view and it may be argued that the success rate quoted in this study according to clinicians' perception may not necessarily match the one of the patients. Similar findings were reported by Cosyn et al., 2013, Meijndert et al., 2007 and Esposito et al., 2009 in the sense that patients were less critical than clinicians when judging aesthetics.

There are some limitations that should be considered when interpreting the results of this trial. These are listed below:

- A larger sample size may have been necessary to identify potential statistical significant differences between some of the recorded outcomes reducing the chance for a type-II error in the statistical analysis. However, this study provides significant and unique data on the expected variance for each outcome parameter and could be used for the design of future larger studies with higher degree of power.
- Similar to our study most of the current studies investigating immediate implant placement are providing outcomes at 12-month post-loading. However, longer follow-up periods would be desirable to ascertain the long-term performance of investigated treatment modalities.
- For ethical reasons, no CBCT examination was available at the time of implant placement immediately after the tooth extraction. This could have provided accurate information on buccal bone plate thickness changes when compared with CBCT examination at 12 months. Consequently, no robust conclusions can be drawn from our study regarding this as no baseline CBCT was obtained.
- Gingival phenotype was not recorded at baseline. Currently, there is no clear evidence on the correlation between soft tissue thickness and underlying bony wall thickness (Chappuis et al., 2015) and the possible association between thin phenotype and post-extraction bone loss (Akcali et al., 2017). However, gingival phenotype could have had an impact in PES scores due to the challenges in restoring normal papilla height in thin-phenotype patients.
- The inclusion of more specific measurements evaluating vertical soft tissue change at the interproximal and mid-facial aspect could have also provided valuable additional information.
- Our results regarding patient-reported outcomes (PROMs) have to be interpreted cautiously. The use of VAS has been validated to measure PROMs in dentistry, especially in relation to treatment-related anxiety (Appukkuttan et al., 2014; Facco et al., 2011), but not for aesthetic outcomes. Although the information obtained may be valuable from an exploratory point of view, the validity of this approach still needs to be confirmed. The survey used to assess patients' satisfaction with treatment provided was based in a questionnaire developed by de Bruyn et al. in 1997. However, neither this questionnaire nor the modifications introduced for our study were validated as a tool to measure the desired effect, therefore, the limitations mentioned for the VAS also apply to this questionnaire. The use of non-validated tools to measure PROMs in implant dentistry seems to be a common drawback in most of the studies reporting this type of outcomes. This was the conclusion reached by a systemic review conducted by De Bruyn et al., 2015 in which it was concluded that "an 'ad hoc' approach is commonly employed using non-standardised questions and different scoring methods, which may compromise validity and reliability."

5 | CONCLUSIONS

Within the limitations of this study, it was concluded that no differences could be detected for immediate dental implant treatment between a flap and minimal split-thickness envelope flap approach in terms of PES/WES scores, success/modified success rate, survival, mean buccal plate resorption and patients' satisfaction. Optimal aesthetics seemed difficult to achieve and aesthetic failures were recorded in both groups despite careful patient selection. Further prospective, randomised studies with a larger sample size and longer observation periods that will include aesthetic parameters are needed to confirm our results on the effect of flap management on soft/hard tissue dynamics and the aesthetic outcomes following immediate implant placement.

ACKNOWLEDGEMENTS

The present study was partly supported by Avinent® that provided the dental implants used in this study and Osteógenos s.r.l.® that provided grafting materials and resorbable membranes used during this study. The support of Dr. Jose Dopico, Dr. Robin Amanullah, Dr. Luis Ferrandez, Dr. Charlotte Rademeyer, Dr. Anthony Lam, Dr. Colin McGuirck and Dr. Christian Day as PES/WES examiners is highly appreciated.

CONFLICT OF INTEREST

The authors do not report any conflict of interest related to the present study.

AUTHOR CONTRIBUTION

Ruben Garcia Sanchez: Conceptualization (equal); Investigation (equal); Methodology (equal); Project administration (equal); Visualization (lead); Writing-original draft (equal); Writing-review & editing (equal). **Nikos Mardas:** Supervision (equal); Writing-original draft (equal); Writing-review & editing (equal). **Jacopo Buti:** Data curation (equal); Formal analysis (lead); Software (lead). **antonio jose ortiz-Ruiz:** Conceptualization (equal); Data curation (equal); Funding acquisition (supporting); Project administration (equal); Supervision (equal). **Guillermo Pardo-Zamora:** Conceptualization (equal); Data curation (equal); Funding acquisition (lead); Methodology (equal); Project administration (equal); Resources (equal); Supervision (equal).

ORCID

Ruben Garcia-Sanchez  <https://orcid.org/0000-0003-2051-0668>

REFERENCES

- Aitken, R. C. (1969). Measurement of feelings using visual analogue scales. *Proceedings of the Royal Society of Medicine*, 62(10), 989–993.
- Akcali, A., Trullenque-Eriksson, A., Sun, C., Petrie, A., Nibali, L., & Donos, N. (2017). What is the effect of soft tissue thickness on crestal bone loss around dental implants? A systematic review. *Clinical Oral Implants Research*, 28(9), 1046–1053. <https://doi.org/10.1111/clr.12916>
- Albrektsson, T., Zarb, G., Worthington, P., & Eriksson, A. R. (1986). The long-term efficacy of currently used dental implants: A review

- and proposed criteria of success. *International Journal of Oral and Maxillofacial Implants*, 1(1), 11–25.
- Appukkuttan, D., Vinayagavel, M., & Tadepalli, A. (2014). Utility and validity of a single-item visual analog scale for measuring dental anxiety in clinical practice. *Journal of Oral Science*, 56, 151–156. <https://doi.org/10.2334/josnusd.56.151>
- Araujo, M. G., & Lindhe, J. (2009). Ridge alterations following tooth extraction with and without flap elevation: An experimental study in the dog. *Clinical Oral Implants Research*, 20(6), 545–549. <https://doi.org/10.1111/j.1600-0501.2008.01703.x>
- Araujo, M. G., Sukekava, F., Wennstrom, J. L., & Lindhe, J. (2005). Ridge alterations following implant placement in fresh extraction sockets: An experimental study in the dog. *Journal of Clinical Periodontology*, 32(6), 645–652. <https://doi.org/10.1111/j.1600-051X.2005.00726.x>
- Araújo, M. G., Sukekava, F., Wennström, J. L., & Lindhe, J. (2006). Tissue modeling following implant placement in fresh extraction sockets. *Clin Oral Implants Res*, 17(6), 615–624. <https://doi.org/10.1111/j.1600-0501.2006.01317.x>
- Atieh, M. A., Alsabeeha, N. H., Duncan, W. J., de Silva, R. K., Cullinan, M. P., Schwass, D., & Payne, A. G. (2013). Immediate single implant restorations in mandibular molar extraction sockets: A controlled clinical trial. *Clinical Oral Implants Research*, 24(5), 484–496. <https://doi.org/10.1111/j.1600-0501.2011.02415.x>
- Bashutski, J. D., Wang, H. L., Rudek, I., Moreno, I., Koticha, T., & Oh, T. J. (2013). Effect of flapless surgery on single-tooth implants in the esthetic zone: A randomized clinical trial. *Journal of Periodontology*, 84(12), 1747–1754. <https://doi.org/10.1902/jop.2013.120575>
- Belser, U. C., Grutter, L., Vailati, F., Bornstein, M. M., Weber, H. P., & Buser, D. (2009). Outcome evaluation of early placed maxillary anterior single-tooth implants using objective esthetic criteria: A cross-sectional, retrospective study in 45 patients with a 2- to 4-year follow-up using pink and white esthetic scores. *Journal of Periodontology*, 80(1), 140–151. <https://doi.org/10.1902/jop.2009.080435>
- Benic, G. I., Mokti, M., Chen, C. J., Weber, H. P., Hämmerle, C. H., & Gallucci, G. O. (2012). Dimensions of buccal bone and mucosa at immediately placed implants after 7 years: A clinical and cone beam computed tomography study. *Clinical Oral Implants Research*, 23(5), 560–566. <https://doi.org/10.1111/j.1600-0501.2011.02253.x>
- Blanco, J., Nunez, V., Aracil, L., Munoz, F., & Ramos, I. (2008). Ridge alterations following immediate implant placement in the dog: Flap versus flapless surgery. *Journal of Clinical Periodontology*, 35(7), 640–648. <https://doi.org/10.1111/j.1600-051X.2008.01237.x>
- Block, M. S., Mercante, D. E., Lirette, D., Mohamed, W., Ryser, M., & Castellon, P. (2009). Prospective evaluation of immediate and delayed provisional single tooth restorations. *Journal of Oral & Maxillofacial Surgery*, 67(11 Suppl), 89–107. <https://doi.org/10.1016/j.joms.2009.07.009>
- Botticelli, D., Berglundh, T., & Lindhe, J. (2004). Hard-tissue alterations following immediate implant placement in extraction sites. *Journal of Clinical Periodontology*, 31(10), 820–828. <https://doi.org/10.1111/j.1600-051X.2004.00565.x>
- Buser, D., Chappuis, V., Bornstein, M. M., Wittneben, J. G., Frei, M., & Belser, U. C. (2013). Long-term stability of contour augmentation with early implant placement following single tooth extraction in the esthetic zone: A prospective, cross-sectional study in 41 patients with a 5- to 9-year follow-up. *Journal of Periodontology*, 84(11), 1517–1527. <https://doi.org/10.1902/jop.2013.120635>
- Buser, D., Halbritter, S., Hart, C., Bornstein, M. M., Grutter, L., Chappuis, V., & Belser, U. C. (2009). Early implant placement with simultaneous guided bone regeneration following single-tooth extraction in the esthetic zone: 12-month results of a prospective study with 20 consecutive patients. *Journal of Periodontology*, 80(1), 152–162. <https://doi.org/10.1902/jop.2009.080360>
- Caneva, M., Botticelli, D., Salata, L. A., Souza, S. L. S., Bressan, E., & Lang, N. P. (2010). Flap vs. “flapless” surgical approach at immediate implants: A histomorphometric study in dogs. *Clinical Oral Implants Research*, 21(12), 1314–1319. <https://doi.org/10.1111/j.1600-0501.2010.01959.x>
- Chappuis, V., Engel, O., Shahim, K., Reyes, M., Katsaros, C., & Buser, D. (2015). Soft tissue alterations in esthetic postextraction sites: a 3-dimensional analysis. *Journal of Dental Research*, 94(9 Suppl), 187s–193s. <https://doi.org/10.1177/0022034515592869>
- Chen, S. T., & Buser, D. (2014). Esthetic outcomes following immediate and early implant placement in the anterior maxilla—a systematic review. *International Journal of Oral and Maxillofacial Implants*, 29(Suppl), 186–215. <https://doi.org/10.11607/jomi.2014suppl.g3.3>
- Chen, S. T., Darby, I. B., & Reynolds, E. C. (2007). A prospective clinical study of non-submerged immediate implants: Clinical outcomes and esthetic results. *Clinical Oral Implants Research*, 18(5), 552–562. <https://doi.org/10.1111/j.1600-0501.2007.01388.x>
- Chrcanovic, B. R., Albrektsson, T., & Wennerberg, A. (2015). Dental implants inserted in fresh extraction sockets versus healed sites: A systematic review and meta-analysis. *Journal of Dentistry*, 43(1), 16–41. <https://doi.org/10.1016/j.jdent.2014.11.007>
- Cosyn, J., De Lat, L., Seyssens, L., Doornewaard, R., Deschepper, E., & Vervaeke, S. (2019). The effectiveness of immediate implant placement for single tooth replacement compared to delayed implant placement: A systematic review and meta-analysis. *Journal of Clinical Periodontology*, 46(Suppl 21), 224–241. <https://doi.org/10.1111/jcpe.13054>
- Cosyn, J., Eghbali, A., De Bruyn, H., Collys, K., Cleymaet, R., & De Rouck, T. (2011). Immediate single-tooth implants in the anterior maxilla: 3-year results of a case series on hard and soft tissue response and aesthetics. *Journal of Clinical Periodontology*, 38(8), 746–753. <https://doi.org/10.1111/j.1600-051X.2011.01748.x>
- Cosyn, J., Eghbali, A., Hanselaer, L., De Rouck, T., Wyn, I., Sabzevar, M. M., Cleymaet, R., & De Bruyn, H. (2013). Four modalities of single implant treatment in the anterior maxilla: A clinical, radiographic, and aesthetic evaluation. *Clinical Implant Dentistry and Related Research*, 15(4), 517–530. <https://doi.org/10.1111/j.1708-8208.2011.00417.x>
- Covani, U., Canullo, L., Toti, P., Alfonsi, F., & Barone, A. (2014). Tissue stability of implants placed in fresh extraction sockets: A 5-year prospective single-cohort study. *Journal of Periodontology*, 85(9), e323–332. <https://doi.org/10.1902/jop.2014.140175>
- Covani, U., Cornelini, R., & Barone, A. (2008). Buccal bone augmentation around immediate implants with and without flap elevation: A modified approach. *International Journal of Oral and Maxillofacial Implants*, 23(5), 841–846.
- De Angelis, N., Felice, P., Pellegrino, G., Camurati, A., Gambino, P., & Esposito, M. (2011). Guided bone regeneration with and without a bone substitute at single post-extractive implants: 1-year post-loading results from a pragmatic multicentre randomised controlled trial. *European Journal of Oral Implantology*, 4(4), 313–325.
- De Bruyn, H., Atashkadeh, M., Cosyn, J., & van de Velde, T. (2011). Clinical outcome and bone preservation of single TiUnite™ implants installed with flapless or flap surgery. *Clinical Implant Dentistry and Related Research*, 13(3), 175–183. <https://doi.org/10.1111/j.1708-8208.2009.00200.x>
- de Bruyn, H., Collaert, B., Linden, U., & Bjorn, A. L. (1997). Patient's opinion and treatment outcome of fixed rehabilitation on Branemark implants. A 3-year follow-up study in private dental practices. *Clinical Oral Implants Research*, 8(4), 265–271. <https://doi.org/10.1034/j.1600-0501.1997.080403.x>
- De Bruyn, H., Raes, S., Matthys, C., & Cosyn, J. (2015). The current use of patient-centered/reported outcomes in implant dentistry: A systematic review. *Clinical Oral Implants Research*, 26(Suppl 11), 45–56. <https://doi.org/10.1111/clr.12634>
- den Hartog, L., Slater, J. J., Vissink, A., Meijer, H. J., & Raghoobar, G. M. (2008). Treatment outcome of immediate, early and conventional single-tooth implants in the aesthetic zone: A systematic review to

- survival, bone level, soft-tissue, aesthetics and patient satisfaction. *Journal of Clinical Periodontology*, 35(12), 1073–1086. <https://doi.org/10.1111/j.1600-051X.2008.01330.x>
- Esposito, M., Barausse, C., Pistilli, R., Jacotti, M., Grandi, G., Tuco, L., & Felice, P. (2015). Immediate loading of post-extractive versus delayed placed single implants in the anterior maxilla: Outcome of a pragmatic multicenter randomised controlled trial 1-year after loading. *European Journal of Oral Implantology*, 8(4), 347–358.
- Esposito, M., Grusovin, M. G., & Worthington, H. V. (2009). Agreement of quantitative subjective evaluation of esthetic changes in implant dentistry by patients and practitioners. *International Journal of Oral and Maxillofacial Implants*, 24(2), 309–315.
- Facco, E., Zanette, G., Favero, L., Bacci, C., Sivolella, S., Cavallin, F., & Manani, G. (2011). Toward the validation of visual analogue scale for anxiety. *Anesthesia Progress*, 58(1), 8–13. <https://doi.org/10.2344/0003-3006-58.1.8>
- Felice, P., Pistilli, R., Barausse, C., Trullenque-Eriksson, A., & Esposito, M. (2015). Immediate non-occlusal loading of immediate post-extractive versus delayed placement of single implants in preserved sockets of the anterior maxilla: 1-year post-loading outcome of a randomised controlled trial. *European Journal of Oral Implantology*, 8(4), 361–372.
- Froum, S. J., Cho, S. C., Elian, N., Romano, G., Jalbout, Z., Natour, M., & Tarnow, D. P. (2011). Survival rate of one-piece dental implants placed with a flapless or flap protocol—a randomized, controlled study: 12-month results. *International Journal of Periodontics & Restorative Dentistry*, 31(6), 591–601.
- Furhauer, R., Florescu, D., Benesch, T., Haas, R., Mailath, G., & Watzek, G. (2005). Evaluation of soft tissue around single-tooth implant crowns: The pink esthetic score. *Clinical Oral Implants Research*, 16(6), 639–644. <https://doi.org/10.1111/j.1600-0501.2005.01193.x>
- Grassi, F. R., Grassi, R., Rapone, B., Alemanno, G., Balena, A., & Kalemaj, Z. (2019). Dimensional changes of buccal bone plate in immediate implants inserted through open flap, open flap and bone grafting and flapless techniques: A cone-beam computed tomography randomized controlled clinical trial. *Clinical Oral Implants Research*, 30(12), 1155–1164. <https://doi.org/10.1111/clr.13528>
- Hämmerle, C. H., Chen, S. T., & Wilson, T. G., Jr. (2004). Consensus statements and recommended clinical procedures regarding the placement of implants in extraction sockets. *International Journal of Oral & Maxillofacial Implants*, 19 Suppl, 26–28.
- Hirsch, A., Goldstein, M., Goultshin, J., Boyan, B. D., & Schwartz, Z. (2005). A 2-year follow-up of root coverage using sub-pedicle acellular dermal matrix allografts and subepithelial connective tissue autografts. *Journal of Periodontology*, 76(8), 1323–1328. <https://doi.org/10.1902/jop.2005.76.8.1323>
- Hürzeler, M. B., Kohal, R. J., Naghsbandi, J., Mota, L. F., Conrath, J., Hutmacher, D., & Caffesse, R. G. (1998). Evaluation of a new bioresorbable barrier to facilitate guided bone regeneration around exposed implant threads. An experimental study in the monkey. *International Journal of Oral and Maxillofacial Surgery*, 27(4), 315–320. [https://doi.org/10.1016/S0901-5027\(05\)80623-X](https://doi.org/10.1016/S0901-5027(05)80623-X)
- Hürzeler, M. B., Quiñones, C. R., Hutmacher, D., & Schüpbach, P. (1997). Guided bone regeneration around dental implants in the atrophic alveolar ridge using a bioresorbable barrier. An experimental study in the monkey. *Clinical Oral Implants Research*, 8(4), 323–331. <https://doi.org/10.1034/j.1600-0501.1997.080411.x>
- Lang, N. P., Joss, A., Orsanic, T., Gusberti, F. A., & Siegrist, B. E. (1986). Bleeding on probing. A predictor for the progression of periodontal disease? *Journal of Clinical Periodontology*, 13(6), 590–596. <https://doi.org/10.1111/j.1600-051x.1986.tb00852.x>
- Lang, N. P., Pun, L., Lau, K. Y., Li, K. Y., & Wong, M. C. (2012). A systematic review on survival and success rates of implants placed immediately into fresh extraction sockets after at least 1 year. *Clinical Oral Implants Research*, 23(s5), 39–66. <https://doi.org/10.1111/j.1600-0501.2011.02372.x>
- Lazzara, R. J. (1989). Immediate implant placement into extraction sites: Surgical and restorative advantages. *International Journal of Periodontics & Restorative Dentistry*, 9(5), 332–343.
- Liñares, A., Mardas, N., Dard, M., & Donos, N. (2011). Effect of immediate or delayed loading following immediate placement of implants with a modified surface. *Clinical Oral Implants Research*, 22(1), 38–46. <https://doi.org/10.1111/j.1600-0501.2010.01988.x>
- Lorenzo, R., García, V., Orsini, M., Martin, C., & Sanz, M. (2012). Clinical efficacy of a xenogeneic collagen matrix in augmenting keratinized mucosa around implants: A randomized controlled prospective clinical trial. *Clinical Oral Implants Research*, 23(3), 316–324. <https://doi.org/10.1111/j.1600-0501.2011.02260.x>
- Malchiodi, L., Cucchi, A., Ghensi, P., & Nocini, P. F. (2013). Evaluation of the esthetic results of 64 nonfunctional immediately loaded postextraction implants in the maxilla: Correlation between interproximal alveolar crest and soft tissues at 3 years of follow-up. *Clinical Implant Dentistry & Related Research*, 15(1), 130–142. <https://doi.org/10.1111/j.1708-8208.2011.00424.x>
- Maló, P., & Nobre, M. (2008). Flap vs. flapless surgical techniques at immediate implant function in predominantly soft bone for rehabilitation of partial edentulism: A prospective cohort study with follow-up of 1 year. *European Journal of Oral Implantology*, 1(4), 293–304.
- Mazzocco, F., Jimenez, D., Barallat, L., Paniz, G., Del Fabbro, M., & Nart, J. (2017). Bone volume changes after immediate implant placement with or without flap elevation. *Clinical Oral Implants Research*, 28(4), 495–501. <https://doi.org/10.1111/clr.12826>
- Meijer, H. J. A., Slagter, K. W., Vissink, A., & Raghoobar, G. M. (2019). Buccal bone thickness at dental implants in the maxillary anterior region with large bony defects at time of immediate implant placement: A 1-year cohort study. *Clinical Implant Dentistry and Related Research*, 21(1), 73–79. <https://doi.org/10.1111/cid.12701>
- Meijndert, L., Meijer, H. J., Stellingsma, K., Stegenga, B., & Raghoobar, G. M. (2007). Evaluation of aesthetics of implant-supported single-tooth replacements using different bone augmentation procedures: A prospective randomized clinical study. *Clinical Oral Implants Research*, 18(6), 715–719. <https://doi.org/10.1111/j.1600-0501.2007.01415.x>
- Miyamoto, Y., & Obama, T. (2011). Dental cone beam computed tomography analyses of postoperative labial bone thickness in maxillary anterior implants: Comparing immediate and delayed implant placement. *International Journal of Periodontics & Restorative Dentistry*, 31(3), 215–225.
- Nimwegen, W., Raghoobar, G., Zuiderveld, E., Jung, R., Meijer, H., & Mühlemann, S. (2018). Immediate placement and provisionalization of implants in the aesthetic zone with or without a connective tissue graft: A 1-year randomized controlled trial and volumetric study. *Clinical Oral Implants Research*, 29, <https://doi.org/10.1111/clr.13258>
- O'Leary, T. J., Drake, R. B., & Naylor, J. E. (1972). The plaque control record. *Journal of Periodontology*, 43(1), 38. <https://doi.org/10.1902/jop.1972.43.1.38>
- Pfeifer, J. S. (1965). The reaction of alveolar bone to flap procedures in man. *Periodontics*, 3, 135–140.
- Proceedings of the Third ITI (International Team for Implantology) Consensus Conference. Gstaad, Switzerland, August 2003. (2004). *Int J Oral Maxillofac Implants*, 19 Suppl, 7–154, 2003 Proceedings of the Third ITI (International Team for Implantology) Consensus Conference. Gstaad, Switzerland, August 2003. (2004). *The International Journal of Oral & Maxillofacial Implants*, 19 Suppl, 7–154.
- Prosper, L., Gherlone, E. F., Redaelli, S., & Quaranta, M. (2003). Four-year follow-up of larger-diameter implants placed in fresh extraction sockets using a resorbable membrane or a resorbable alloplastic material. *International Journal of Oral and Maxillofacial Implants*, 18(6), 856–864.
- Raes, F., Cosyn, J., Crommelinck, E., Coessens, P., & De Bruyn, H. (2011). Immediate and conventional single implant treatment in the anterior maxilla: 1-year results of a case series on hard and soft tissue

- response and aesthetics. *Journal of Clinical Periodontology*, 38(4), 385–394. <https://doi.org/10.1111/j.1600-051X.2010.01687.x>
- Raes, S., Raes, F., Cooper, L., Giner Tarrida, L., Vervaeke, S., Cosyn, J., & De Bruyn, H. (2016). Oral health-related quality of life changes after placement of immediately loaded single implants in healed alveolar ridges or extraction sockets: A 5-year prospective follow-up study. *Clinical Oral Implants Research*, 22, 22. <https://doi.org/10.1111/clr.12858>
- Salama, H., Salama, M., Garber, D., & Adar, P. (1995). Developing optimal peri-implant papillae within the esthetic zone: Guided soft tissue augmentation. *Journal of Esthetic and Restorative Dentistry*, 7(3), 125–129. <https://doi.org/10.1111/j.1708-8240.1995.tb00729.x>
- Schropp, L., Wenzel, A., Kostopoulos, L., & Karring, T. (2003). Bone healing and soft tissue contour changes following single-tooth extraction: A clinical and radiographic 12-month prospective study. *International Journal of Periodontics & Restorative Dentistry*, 23(4), 313–323.
- Seyssens, L., De Lat, L., & Cosyn, J. (2021). Immediate implant placement with or without connective tissue graft: A systematic review and meta-analysis. *Journal of Clinical Periodontology*, 48(2), 284–301. <https://doi.org/10.1111/jcpe.13397>
- Sunitha, R. V., & Sapthagiri, E. (2013). Flapless implant surgery: A 2-year follow-up study of 40 implants. *Oral Surgery, Oral Medicine, Oral Pathology and Oral Radiology*, 116(4), e237–243. <https://doi.org/10.1016/j.oooo.2011.12.027>
- Tonetti, M. S., Cortellini, P., Graziani, F., Cairo, F., Lang, N. P., Abundo, R., & Wetzel, A. (2017). Immediate versus delayed implant placement after anterior single tooth extraction: The timing randomized controlled clinical trial. *Journal of Clinical Periodontology*, 44(2), 215–224. <https://doi.org/10.1111/jcpe.12666>
- Wittneben, J. G., Wismeijer, D., Bragger, U., Joda, T., & Abou-Ayash, S. (2018). Patient-reported outcome measures focusing on aesthetics of implant- and tooth-supported fixed dental prostheses: A systematic review and meta-analysis. *Clinical Oral Implants Research*, 29(Suppl 16), 224–240. <https://doi.org/10.1111/clr.13295>
- Zuiderveld, E. G., Meijer, H. J. A., den Hartog, L., Vissink, A., & Raghoobar, G. M. (2018). Effect of connective tissue grafting on peri-implant tissue in single immediate implant sites: A RCT. *Journal of Clinical Periodontology*, 45(2), 253–264. <https://doi.org/10.1111/jcpe.12820>

SUPPORTING INFORMATION

Additional supporting information may be found online in the Supporting Information section.

How to cite this article: Garcia-Sanchez, R., Mardas, N., Buti, J., Ortiz Ruiz, A. J., & Pardo Zamora, G. (2021). Immediate implant placement in fresh alveolar sockets with a minimal split-thickness envelope flap: A randomised controlled clinical trial. *Clinical Oral Implants Research*, 00, 1–12. <https://doi.org/10.1111/clr.13806>