

# The Journal of Laryngology & Otology

<http://journals.cambridge.org/JLO>

Additional services for *The Journal of Laryngology & Otology*:

Email alerts: [Click here](#)

Subscriptions: [Click here](#)

Commercial reprints: [Click here](#)

Terms of use : [Click here](#)



---

## The medical management of vertigo

Linda M. Luxon

The Journal of Laryngology & Otology / Volume 111 / Issue 12 / December 1997, pp 1114 - 1121

DOI: 10.1017/S0022215100139507, Published online: 29 June 2007

**Link to this article:** [http://journals.cambridge.org/abstract\\_S0022215100139507](http://journals.cambridge.org/abstract_S0022215100139507)

### How to cite this article:

Linda M. Luxon (1997). The medical management of vertigo. The Journal of Laryngology & Otology, 111, pp 1114-1121

doi:10.1017/S0022215100139507

**Request Permissions :** [Click here](#)

## Editorial Review

# The medical management of vertigo

LINDA M. LUXON

Vertigo is the cardinal symptom of a disordered vestibular system and is most commonly the result of primary labyrinthine pathology, but may be a symptom of neurological disease or general medical disorders, such as cardiac dysrhythmias, hypoglycaemia and transient ischaemic attacks of the vertebrobasilar territory (O Mahoney and Luxon, 1997).

The management of vertigo relies upon an accurate diagnosis. The clinician needs to define the primary underlying condition as being due to a general medical, neurological or otological disorder, with a few other unusual, but problematic conditions falling outside this general classification, namely visual vertigo, (Bronstein, 1995) cervical vertigo (O Mahoney and Luxon, 1997) and the multisensory dizziness syndrome (Drachman and Hart, 1972). A full history, highlighting the character of the disorder, the time course of the symptoms and

associated symptoms together with systematic general medical, neurological, otological and eye movement examinations will, in general, enable the clinician to refer appropriate conditions to the general physician or neurologist and allow the otologist to carry out further investigations to determine the site and aetiology of vestibular pathology (Figure 1). Specific general medical and neurological disorders should be treated appropriately and are outside the scope of this short review, but the reader is referred to standard medical texts.

Patients with recurrent or persistent vertigo of more than six weeks duration should be investigated neuro-otologically to allow further differentiation of specific disorders associated with vertigo, such as Ménière's disease, vestibular schwannoma and benign positional vertigo for which specific treatment regimes exist. Central vestibular disorders associated with such conditions as multiple sclerosis, vertebro-

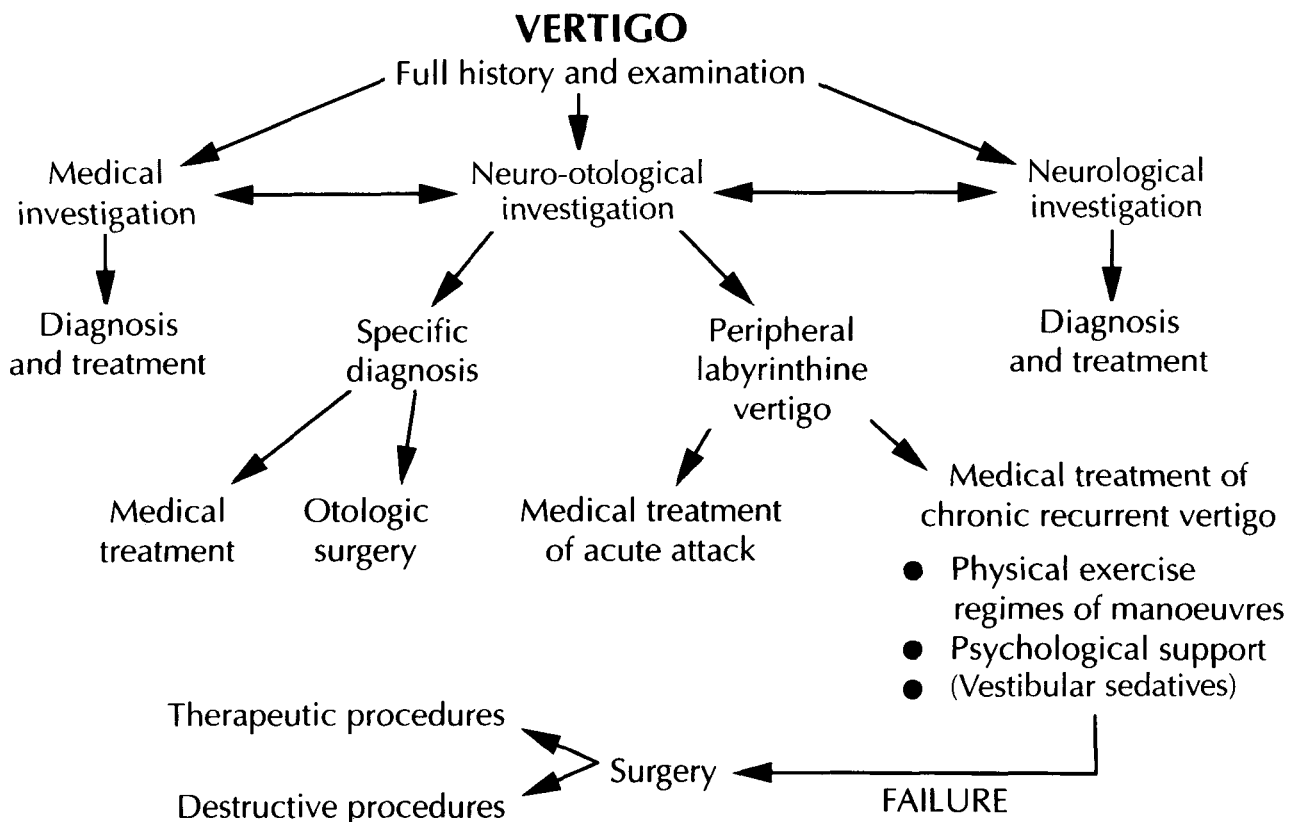


FIG. 1  
 Diagram to illustrate the management of vertigo.

NATURAL HISTORY OF PERIPHERAL VESTIBULAR PATHOLOGY

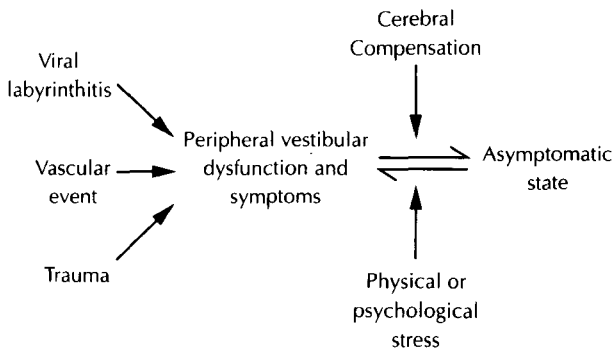


FIG. 2

Diagram to illustrate the inter-relationship of compensation and decompensation following peripheral vestibular pathologies

basilar ischaemia and cerebellar degeneration will also be defined, but the majority of patients will fall into the category of those with peripheral labyrinthine pathology on the basis of viral labyrinthitis, ischaemic events or trauma. Normally, cerebral compensation facilitates recovery from such acute vestibular episodes, but the commonest reason for persistent symptoms is inadequate or intermittent failure of compensation, such that recurrent symptoms persist (Figure 2).

**Specific disorders**

The medical management of Ménière's disease remains controversial, but a recent review has considered extensively the literature in this field (Brookes, 1996). The initial management of Ménière's disease is aimed at preventing recurrent attacks of acute vertigo and reducing the likelihood of a permanent sensorineural hearing impairment.

*Vestibular schwannoma* rarely presents with acute vertigo, although all large reported series suggest an incidence of between five and 10 per cent of vertigo in the presenting symptom complex (Morrison, 1984). Detailed audiovestibular investigation will almost always identify central auditory or vestibular dysfunction suggesting the need for magnetic resonance imaging (MRI) scanning and appropriate intervention.

*Benign positional vertigo of paroxysmal type (BPPV)* is a common vestibular disorder, characterized by acute shortlived episodes of severe vertigo, which tend to occur when the patient assumes a critical head position, commonly, associated with neck extension and turning of the head to either right or left (Dix and Hallpike, 1952). BPPV is diagnosed by

the characteristic finding on the Hallpike manoeuvre: rotational nystagmus, developing after a latent period and directed towards the undermost ear, which adapts and fatigues, and is associated with vegetative symptoms (Table I).

Until recently, the underlying pathological mechanism of cupulolithiasis was proposed to explain the symptomatology (Schuknecht, 1969; Schuknecht and Ruby, 1973). Debris from the macula utriculae was thought to become attached to the cupula of the posterior semi-circular canal such that on assuming the critical head position, the 'heavy' cupula, being hypersensitive to the effect of gravity, produced a burst of neuronal activity leading to the characteristic nystagmus (Figure 3B). However, more recent work has led to the theory of canalithiasis (Figure 3C) which explains more effectively the characteristics of benign positional vertigo outlined above (Baloh, 1996). This theory is based on calcium carbonate crystal debris collecting in the most dependent portion of the posterior semi-circular canal. Upon assuming the critical head position, this 'clot' of debris moves in an ampullofugal direction and thus acts as a 'plunger' within the narrow posterior semi-circular canal. This causes the endolymph to move with a resultant ampullofugal movement of the cupula, producing a brief paroxysm of vertigo and nystagmus.

In 1980, Brandt and Daroff reported that complete symptomatic relief in 66 of 67 patients with this disorder was achieved using rapid repetitive exercises, involving movements, which precipitated the troublesome symptoms (Figure 4) by lying on one side and then rapidly swinging over to lie on the other side. They proposed that otolithic debris was loosened and dispersed from the cupula of the posterior semi-circular canal, as a result of the rapid and aggressive vertigo provocative movements. However, on the basis of the canalithiasis model, it would seem likely that these repeated manoeuvres cleared the debris from the most dependent part of the posterior semi-circular canal into the utricle, where the debris no longer interferes with semi-circular canal dynamics and, thus, the patient is rendered asymptomatic.

The improved pathophysiological understanding of this condition has led to the development of positional manoeuvres (Semont *et al.*, 1988; Epley, 1992), which should now be considered as the first line of management for this condition. These manoeuvres rely upon the anatomical configuration of the posterior semi-circular canal and by moving the head into three different anatomical positions, it

TABLE I  
CHARACTERISTICS OF POSITIONAL NYSTAGMUS

	Benign paroxysmal type	Central type
Latent period	2-20 seconds	None
Adaptation	Disappears in 50 seconds	Persists
Fatigue ability	Disappears on repetition	Persists
Vertigo	Always present	Typically absent
Direction of nystagmus	Rotational to undermost ear	Variable
Incidence	Relatively common	Relatively uncommon

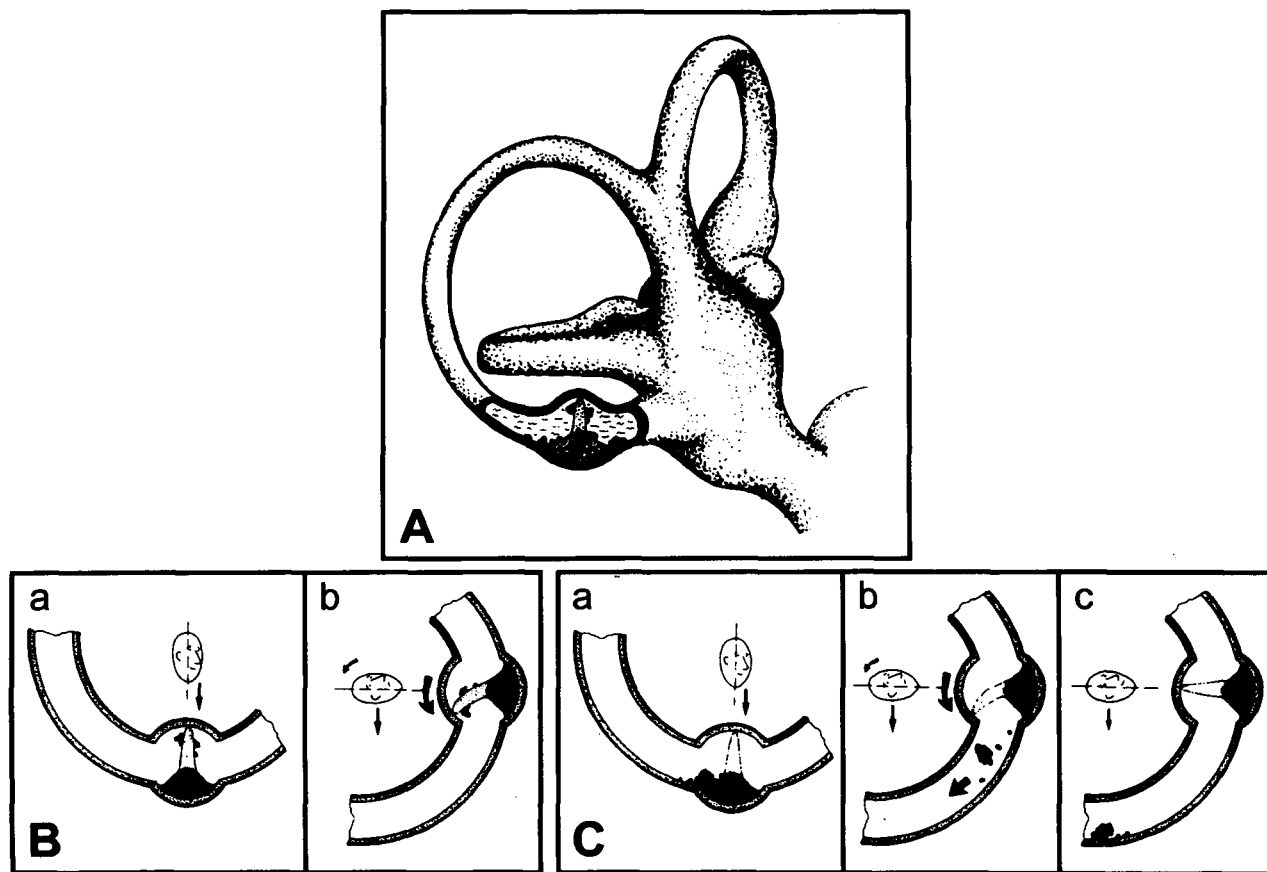


FIG. 3

Diagram to illustrate the pathophysiological mechanisms of cupulolithiasis and canalithiasis.  
 A: Illustration of the cupula in the ampulla of posterior semi-circular canal with debris attached to around the cupula.  
 B: Illustration of the effects of gravity on the cupula and debris as proposed by the theory of cupulolithiasis.  
 C: Illustration of the effect of gravity on the cupula and debris as proposed by the theory of canalithiasis.  
 (From Brandt and Steddins (1993) Current view of the mechanism of benign positioning vertigo; cupulolithiasis or canalolithiasis? *Journal of Vestibular Research* 3: 373-382. Reproduced with kind permission).

is possible to encourage the offending debris in the posterior canal, to migrate, under gravity, via the common crus into the utricle (Figure 5).

Epley (1992) emphasized the value of mastoid vibration at each stage of the manoeuvre to ensure that all the debris is transferred to the most dependent part of the canal and a recent study supported this technique (Li, 1995), but this is not the author's experience and further controlled studies are necessary. In addition, Epley reported that he pre-medicated his patients prior to treatment, but in the author's experience this has never been necessary. After the particle repositioning procedure, it has been advised that the patients should remain in the upright position for at least 48 hours and, thus, it is necessary for them to sleep propped up in bed, or sleep in a chair. Epley (1992), further suggested that the patients should not sleep on the affected side. To date there are no appropriately controlled trials of these various factors and, while it is common to instruct patients to keep their head as still as possible for two days after the procedure and to ensure that they sleep propped up, the other

measures are not generally advocated and despite this, the success rate appears to be extremely good from all workers (Beynon, 1997).

The reported studies suggest that between 70 and 95 per cent of patients improve from the symptoms of benign positional vertigo, following the first particle repositioning procedure (Beynon, 1997). Herdman *et al.* (1993) compared the Semont and

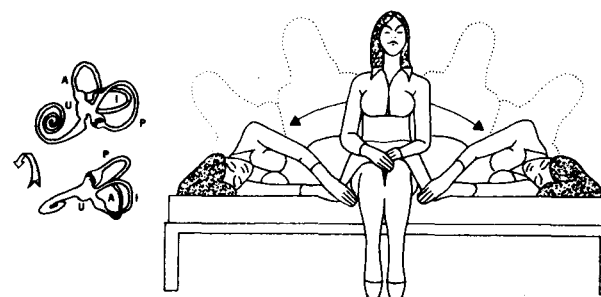


FIG. 4.

Diagram to illustrate the Brandt Daroff Exercises (From: Brandt and Daroff (1980). Physical therapy for benign paroxysmal positional vertigo. *Archives of Otolaryngology* 106: 484-485. Reproduced with kind permission).

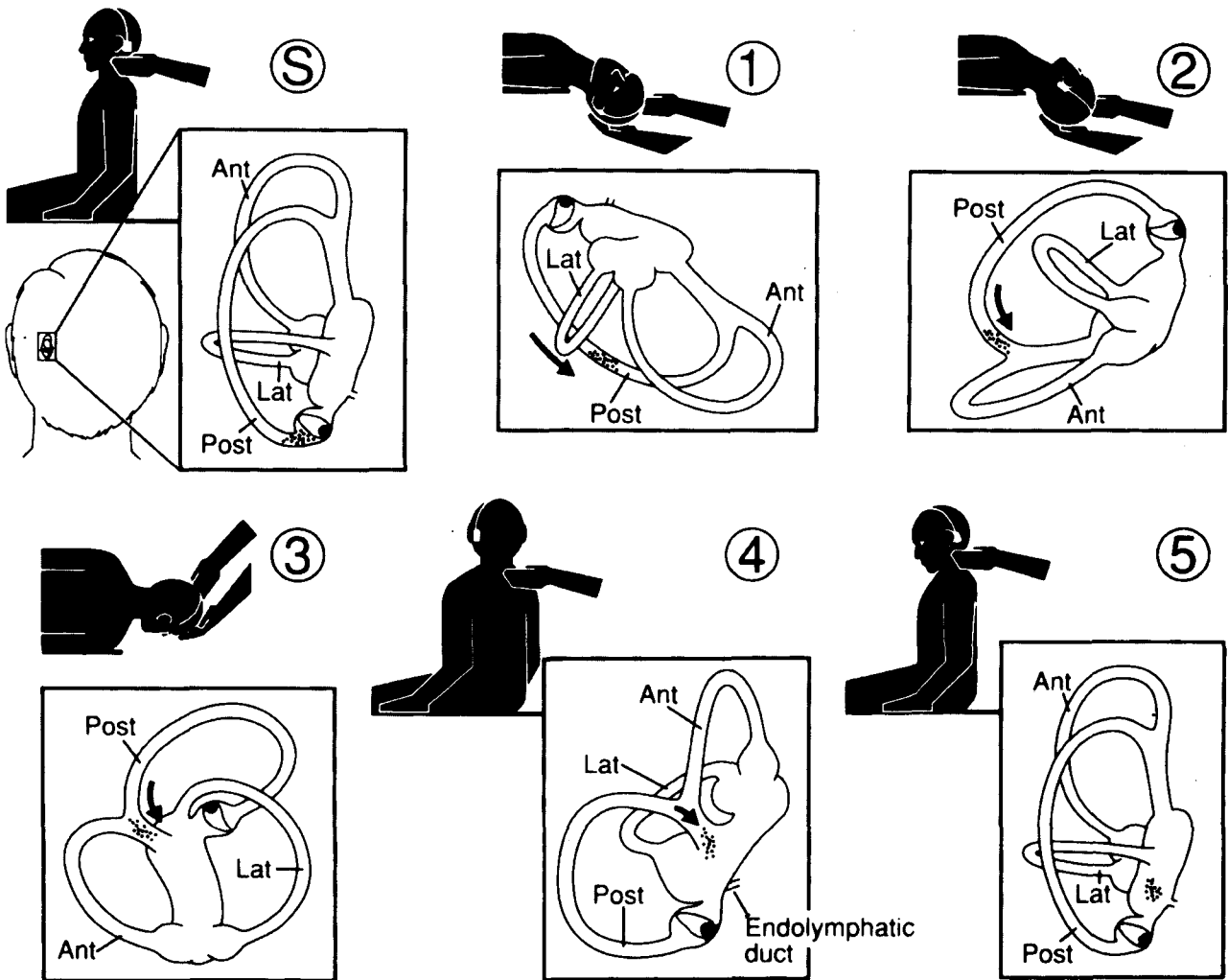


FIG. 5

Diagram to illustrate the particle repositioning procedure for canalithiasis of left posterior semi-circular canal as described by Epley (From: Epley, (1992) Canalith repositioning procedure. *Otolaryngology – Head and Neck Surgery* 107: 399–404. Reproduced with kind permission).

Epley positional manoeuvres and found a comparable cure rate of between 70 and 90 per cent with both. However, the consensus view is that if the initial treatment fails, the manoeuvre should be repeated. Shepard (1995) has noted that the success rate of the particle repositioning procedure is marginally lower in patients with evidence on vestibular investigations of peripheral vestibular dysfunction involving the horizontal semi-circular canal. Approximately 10–30 per cent of patients are reported to suffer a relapse or fail to be cured by the initial manoeuvre (Beynon, 1997) and a further 10–20 per cent of patients report feeling persistent unsteadiness or disorientation, which may last for up to a week. In the author’s experience, it may be necessary to repeat the procedure on up to four occasions in order to bring about recovery, particularly after traumatically induced BPPV.

There are rare reports of patients becoming acutely vertiginous while the particle repositioning procedure is being carried out and it has been suggested that this is the result of debris becoming obstructed in the posterior semi-circular canal

(Soileau, 1995). This event is accompanied by acute vertigo and vomiting, such that patients may require sedation and anti-emetics at this point. If the patient becomes acutely unwell during the particle repositioning procedure the correct management of this situation is the immediate ‘reversal’ of the positions used in the procedure, together with mastoid vibration, which it is hoped will bring about clearing of the debris obstructed within the canal. It is for this reason that it is perhaps sensible to always ensure that this procedure is carried out with a doctor to hand, although it is perfectly reasonable for Audiological Scientists, Hearing Therapists, Physiotherapists or other health care professionals involved in the care of vestibular rehabilitation and treatment to assist in performing this manoeuvre.

Rarely, patients present with prolonged intractable benign positional vertigo, which is not amenable to the particle repositioning procedure and in these cases surgical intervention is required. Originally singular neurectomy (Gacek, 1978) was the procedure of choice, but more recently canal plugging procedures have been developed (Parnes and

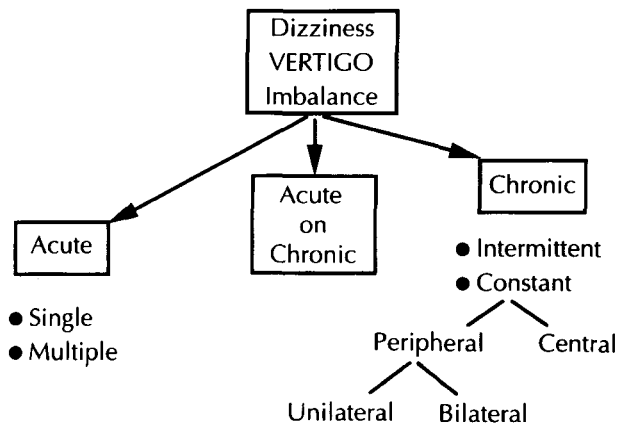


FIG. 6

Diagram to illustrate symptomatic approach to management of dizziness.

McClure, 1991). The main complication of these procedures is the development of sensorineural hearing loss, which has been reported to be as high as 10 per cent in some patient groups.

In addition to benign positional vertigo arising from the posterior horizontal canal, anterior and horizontal semi-circular canal variants have been reported, although these are much rarer (Baloh, 1996). The anterior canal variant may be treated successfully by positional manoeuvres but the horizontal variant is not amenable to this approach (Baloh *et al.*, 1993).

The more difficult patient group in terms of management strategy are those with persistent dizziness/vertigo/dysequilibrium due to failure of compensation. In considering the management strategies applicable to an individual case of vertigo it is helpful to consider the symptomatology in terms of the severity of the symptoms: acute, acute on chronic and chronic (Figure 6).

#### Acute vertigo

Acute vertigo may occur with a single episode, for example, in labyrinthitis and as multiple episodes, e.g., in Ménière's disease and is commonly associated with nausea, vomiting, sweating, pallor and, more rarely, diarrhoea.

Immediate intervention with an anti-emetic such as prochlorperazine, by buccal absorption, intramuscularly or by suppository or alternatively metoclopramide intramuscularly to alleviate nausea and vomiting is essential. Reassurance is required as patients are frequently distressed and frightened by symptoms, which they assume must indicate serious intracranial pathology. A vestibular sedative may then be administered and the most effective is cinnarizine 15 mg 8 hourly, although the elderly patient should be warned of sedative side-effects and the dose titrated accordingly. Cyclizine, dimenhydrinate and promethazine are also effective vestibular sedatives and may be given orally or intra-muscularly. It should be emphasized that while such drugs are of value in the immediate management of acute vertigo, they have no place in the management of

long-term chronic symptoms of dysequilibrium, as there is some evidence to suggest that they may impair the compensatory mechanisms essential for recovery and the asymptomatic state (Zee, 1988).

#### Chronic/recurrent or persistent vertigo

##### Peripheral vestibular disorders

In general, following an acute peripheral vestibular insult, cerebral compensation allows symptomatic recovery over a period of some weeks. In certain cases, recurrent vertigo may be a manifestation of progressive vestibular pathology, such as that associated with auto-immune diseases (Vyse *et al.*, 1994), the development of idiopathic vestibular failure (Rinne *et al.*, 1995), the Tullio phenomenon (O Mahoney *et al.*, (in press)) or a central vestibular disorder, (O Mahoney and Luxon, 1997) and such conditions must be identified.

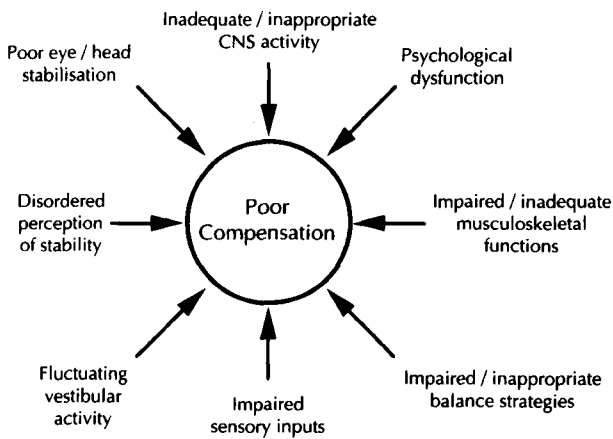
However, in the majority of cases, such intractable symptoms result from failure of compensation of peripheral vestibular pathology, which may be the result of psychological, neurological, locomotor, or general medical pathology (Luxon, 1997) and is associated with a significant morbidity in terms of both occupational and social activities. The management of failure of compensation requires a structured rehabilitation programme (Table II) including an initial assessment to identify factors, which may compromise the rehabilitation effort and specific remediation (Figure 7) for example, a fitness programme to improve poor physical condition, the treatment of musculo-skeletal disorders, such as arthritis. Correction of visual deficits, for example cataract removal, optical correction and gait and stance retraining where appropriate. Specific vestibular rehabilitation may be considered in three main areas (Figure 8): psychology, physiotherapy and pharmacology.

##### a) Physical exercise regimes

Physiotherapy for patients with peripheral vestibular disorders was introduced by Cawthorne and Cooksey in the mid 1940s (Cawthorne, 1945; Cooksey, 1945). They designed a graduated series of exercises aimed at encouraging head and eye movements, recognizing that patients recover more

TABLE II  
REHABILITATION PROGRAMME

1.	Investigation and diagnosis	
2.	Explanation	
3.	Rehabilitation plan:	
	* Correction of remediable problems	
	* General fitness programme	
	* Physical exercise regimes	
	* Psychological assessment	
	* Medication	
	* Realistic	
	family	} goals
	social	
	occupational	
4.	Monitoring/feedback/follow-up	
5.	Discharge	



**Factors Affecting Compensation**

FIG. 7

Diagram to illustrate factors predisposing to decompensation (after Shumway-Cook and Horak (1990). Rehabilitation strategies for patients with vestibular deficits. *Neurology Clinics of North America* 8: 441-457).

rapidly using a systematic regime to provoke dizziness. The exercises were repeated several times a day and, assessing symptomatic response, Dix (1984) reported approximately 80 per cent of patients with vestibular disorders responded favourably to the Cawthorne Cooksey regime. This empirical approach to vestibular rehabilitation has subsequently received support from animal experiments in which physical activity and visual input have been shown to promote recovery (Lacour *et al.*, 1976). Recent programmes of physical exercise regimes have concentrated on 'customized' exercises which are developed for each individual (Shepard *et al.*, 1993; Herdman, 1994). These workers have emphasized the need for a pre-rehabilitation assessment of vestibular deficit, posture, gait and balance in order to identify the best stimuli to induce compensation, that is 'customized' exercises based on the patient's functional difficulties. Patients are instructed to work at the limit of their ability, on exercises precipitating their symptoms.

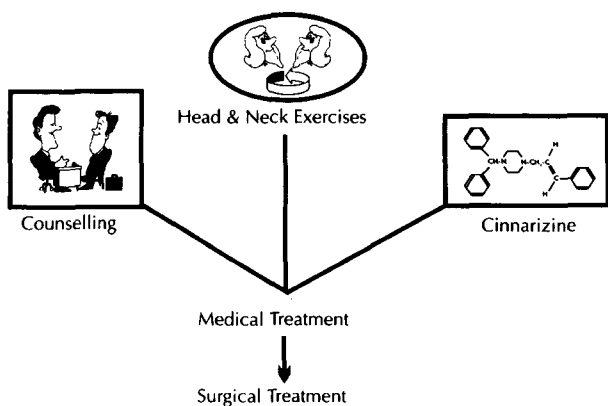


FIG. 8

Diagram to illustrate three main modes of management for peripheral vestibular dysfunction.

*b) Psychological support*

Psychological sequelae (Figure 9) are extremely common in vestibular disorders (Eagger *et al.*, 1992; Yardley and Luxon, 1994). A structured vestibular rehabilitation programme confers significant psychological benefits on the patient with chronic vertigo, partly as a result of the detailed explanation which is required in order for patients to comply with the rehabilitation effort. This necessitates an understanding of vertigo and thus allays fears of sinister pathology. In addition, patients are encouraged to cope actively with their symptoms rather than avoid them (Yardley and Luxon, 1994), and this places the patient in control of their symptoms. Many of the symptoms associated with chronic vertigo are bizarre and include such sensations as feeling 'spaced out' and feeling that 'the brain is lagging behind the head'. Such symptoms suggest to the patient that they are 'going mad' and inexperienced clinicians may compound this anxiety by inappropriate management, such as dismissing the patient's complaints or suggesting a psychiatric referral rather than vestibular investigation.

Psychological symptoms in patients with dysequilibrium are well documented. (Eagger *et al.*, 1992) and in particular panic attacks, anxiety disorders and depression have been reported. Avoidance behaviour is common and active management of psychological disturbances, particularly behavioural therapy is crucial if recovery in psychologically disturbed patients is to ensue (Davidson, 1997; Laczko-Schroeder, 1997).

*c) Pharmacological management*

Drug therapy for vertigo is directed at the relief of symptoms rather than specific remediation of the underlying aetiological process. As noted above the use of vestibular sedatives and anti-emetics are of value in the treatment of acute vertigo, but have no place in the long-term management of chronic vertigo of peripheral origin as they may impair vestibular compensation. Moreover, psychotropic

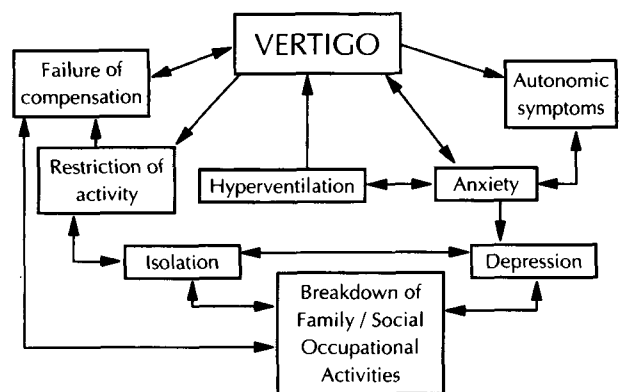


FIG. 9

Diagram to illustrate the inter-relationships between vertigo and psychological symptoms.

drugs, including tranquillisers, anti-depressants, neuroleptics and narcotics may impair vestibular compensation.

A variant of approaches including betahistine, a synthetic analogue of histamine, thiazide diuretics and a low salt diet has been advocated in the management of Ménière's disease, but there is no definitive control trial to support these various pharmacological approaches (Brookes, 1996). Chemical ablation of the diseased labyrinth in Ménière's disease has been suggested using gentamicin or streptomycin with good effects, although a recent study has reported a high prevalence of post-operative hearing loss and the need for revision surgery consequent upon failure of resolution of symptoms (Monsell and Shelton, 1992).

At the present time, the management of central vestibular vertigo is based on pharmacological intervention, although in many cases the underlying pathophysiology is unclear and thus treatment is primarily symptomatic.

While uncompensated unilateral peripheral vestibular pathology is the commonest cause of persistent vertigo, bilateral vestibular hypofunction should be borne in mind as an unusual cause of repeated, shortlived severe vertigo (Rinne et al., 1995). This condition is most commonly idiopathic, but may be associated with oto-toxic drugs, bilateral otological pathology, trauma, neurological disorders and autoimmune disease. Intensive physical exercise regimes may alleviate constant dysequilibrium and oscillopsia, but the acute episodes of vertigo are difficult to treat as they are erratic, unprecipitated and brief. The chronic symptoms may be further alleviated by wearing thick rubber soles to reduce oscillopsia associated with walking and the use of a walking stick to provide additional proprioceptive input through the upper limbs. The patient should be specifically advised to avoid situations in which they may be in danger, for example swimming alone, standing on the edge of railway platforms or cliffs. As in all peripheral pathology, vestibular sedatives should be avoided to maximize the use of any residual vestibular function in compensation.

#### *Central vestibular vertigo*

The management of central vestibular dysfunction remains poorly understood and empirical in approach. Acute vertigo occurs in approximately 20 per cent of patients with multiple sclerosis (Herrera, 1990) and may be associated with a canal paresis suggesting peripheral pathology. Acute vertigo may resolve along a similar time course to an acute labyrinthine insult, but chronic vertigo is a common complaint in longstanding multiple sclerosis and is frequently accompanied by disordered eye movements. Downbeat, periodic alternating and pendular nystagmus and macrosaccadic oscillations may all be associated with vertigo, which may on occasions be reduced by the use of clonazepam, (Currie and Matsuo, 1986) titrating the dose of sedative side-effects and buclofen titrating the dose against the side-effect of muscular weakness. Brain-

stem strokes and Arnold Chiari malformations are also commonly associated with eye movement abnormalities, which may or may not be accompanied by chronic vertigo. Clonazepam, baclofen (Halmagyi et al., 1980) and/or carbamazepine have all been reported of value in individual cases, although no controlled trials of therapy are available (Frohman et al., 1997).

#### **Acute-on-chronic vertigo**

Acute-on-chronic vertigo may be a manifestation of recurrent decompensation from a fixed vestibular deficit and requires vestibular rehabilitation to expedite compensation for the underlying vestibular abnormality.

Benign positional vertigo of paroxysmal type may manifest in addition to chronic vestibular symptoms as part of the labyrinthine concussion syndrome, or following a viral or vascular labyrinthitis with involvement of both the otolith organs and semi-circular canal. The acute positional vertigo should be managed as outlined above, using the Epley manoeuvre and this should be followed by standard vestibular rehabilitation therapy with physical exercise regimes.

Migraine and Ménière's disease may also give rise to acute vestibular episodes on a background of chronic symptoms, as may idiopathic progressive vestibular failure. Migraine requires appropriate prophylaxis, while the management of Ménière's disease and idiopathic progressive vestibular failure are outlined above. In all cases of acute-on-chronic vertigo the acute symptoms should be managed symptomatically, any specific remediable condition which might preclude vestibular failure should be corrected and then vestibular rehabilitation should be recommenced.

In conclusion, vertigo is a common symptom which has significant morbidity economically, occupationally and socially. Appropriate management requires a systematic method of evaluation of such patients with aggressive early intervention, using physical exercise regimes, together with appropriate psychological management, in those cases defined as uncompensated peripheral vestibular disorders. Specific conditions for which effective management regimes are available must be defined, such as benign positional vertigo of paroxysmal type, syphilitic labyrinthitis, Ménière's disease, specific autoimmune disorders and retrocochlear pathology. A full general history is required to ensure remediation of associated and contributing factors such as rheumatological disease, ophthalmological disease and general medical pathology. Appropriate management enables a marked improvement in the quality of life in the majority of patients with chronic vertigo. Unfortunately, despite claims of improvement of central vestibular symptoms using physical exercise regimes, the management of such conditions remains poorly understood and ill-defined.



## References

- Baloh, R. W. (1996) Benign positional vertigo. In *Handbook of Neuro-otology/Vestibular System*. (Baloh, R. W, Halmagyi, M. eds.). Oxford University Press, New York, pp 328-339.
- Baloh, R. W., Jacobson, K., Honrubia, V. (1993) Horizontal semicircular canal variant of benign positional vertigo. *Neurology* **43**: 2542-2549.
- Beynon, G. J. (1997) A review of management of benign paroxysmal positional vertigo by exercise therapy and by repositioning manoeuvres. *British Journal of Audiology* **31**: 11-26.
- Brandt, T., Darroff, R. B. (1980) Physical therapy for benign paroxysmal positional vertigo. *Archives of Otolaryngology* **106**: 484-484.
- Bronstein, A. (1995) Visual vertigo syndrome: clinical and posturography findings. *Journal of Neurology, Neurosurgery and Psychiatry* **59**: 472-476.
- Brookes, G. B. (1996) The pharmacological treatment of Menière's disease. *Clinical Otolaryngology* **21**: 3-11.
- Cawthorne, T. E. (1945) Vestibular injuries. *Proceedings of the Royal Society of Medicine* **39**: 270-273.
- Cooksey, F. S. (1945) Rehabilitation of vestibular injuries. *Proceedings of the Royal Society of Medicine* **39**: 273-278.
- Currie, J. N., Matsuo, V. (1986) The use of clonazepam in the treatment of nystagmus-induced oscillopsia. *Ophthalmology* **93**: 924-932.
- Davidson, A. (1997) Behavioural psychotherapy. In *Handbook of Vestibular Rehabilitation* (Luxon, L. M. and Davies, R. A., eds.) Whurr, London, pp 74-79.
- Dix, M. R. (1984) Rehabilitation of vertigo. In *Vertigo* (Dix, M. R. and Hood, J. D., eds.) Wiley and Sons, Chichester, 23-39.
- Dix, M. R., Hallpike, C. S. (1952) Pathology, symptomatology and diagnosis of certain disorders of the vestibular system. *Proceedings of the Royal Society of Medicine* **45**: 341-354.
- Drachman, D. A., Hart, C. (1972) A new approach to the dizzy patient. *Neurology* **22**: 323-334.
- Eagger, S., Luxon, L. M., Davies, R. A., Coehlo, A., Ron, M. A. (1992) Psychiatric morbidity in patients with peripheral vestibular disorder: a clinical and neuro-otological study. *Journal of Neurology, Neurosurgery and Psychiatry* **55**: 383-387.
- Epley, J. M. (1992) The canalith repositioning procedure: For treatment of benign paroxysmal positional vertigo. *Otolaryngology - Head and Neck Surgery* **107**: 399-404.
- Frohman, E. M., Solomon, D., Zee, D. S. (1997) Vestibular dysfunction and nystagmus in multiple sclerosis. *Multiple Sclerosis* **3**: 87-99.
- Gacek, R. R. (1978) Further observations on posterior ampullary nerve transection for positional vertigo. *Annals of Otolaryngology and Laryngology* **87**: 300-305.
- Halmagyi, G. M., Rudge, P., Gresty, M. A., Leigh, R. J., Zee, D. S. (1980) Treatment of periodic alternating nystagmus. *Annals of Neurology* **8**: 609-611.
- Herdman, S. J. (1994) *Vestibular Rehabilitation*. F. A. Davis Company, Philadelphia, pp 287-313.
- Herdman, S. J., Tusa, R. J., Zee, D. S., Proctor, L. R., Mattox, D. E. (1993) Single treatment approaches to benign paroxysmal positional vertigo. *Archives of Otolaryngology - Head and Neck Surgery* **119**: 450-454.
- Herrera, W. G. (1990) Vestibular and other balance disorders in multiple sclerosis. *Neurologic Clinics* **8** (2): 407-420.
- Lacour, M., Roll, J. P., Appaix, M. (1976) Modifications and development of spinal reflexes in the adult baboon (*Papio papio*) following unilateral vestibular neurotomy. *Brain Research* **113**: 255-269.
- Laczko-Schroeder, T. (1997) Psychological aspects. In *Handbook of Vestibular Rehabilitation* (Luxon, L. M. and Davies, R. A., eds.) Whurr, London, pp 64-73.
- Li, J. C. (1995) Mastoid oscillation: A critical factor for success in canalith repositioning procedure. *Otolaryngology - Head and Neck Surgery* **112**(6): 670-675.
- Luxon, L. M. (1997) Vestibular compensation. In *Handbook of Vestibular Rehabilitation*. (Luxon, L. M. and Davies, R. A., eds.), Whurr, London, pp 17-29.
- Monsell, E. M., Shelton, C. (1992) Labyrinthotomy with streptomycin infusion: early results of a multicentre study. *American Journal of Otolaryngology* **13**: 416-422; discussion 422-425.
- O Mahoney, C., Luxon, L. M. (1997) Causes of balance disorder. In *Scott Brown's Otolaryngology* (Kerr, A. G., Stephens, S. D. G., eds.) 6th Edition, vol. 6, Butterworths, London, pp 2/20/1-2/20/58.
- O Mahoney, C., Luxon, L. M., Bronstein, A., Colebatch, J., Davies, R. A., Gresty, M., Ludman, H., Rothwell, J. Further insights into the origin and aetiology of the Tullio phenomenon: Findings in 14 patients (In press).
- Parnes, L. S., McClure, J. A. (1991) Posterior semicircular canal occlusion in the normal ear. *Otolaryngology - Head and Neck Surgery* **104**: 52-57.
- Rinne, T., Bronstein, A. M., Rudge, P., Gresty, M., Luxon, L. M. (1995) Bilateral loss of vestibular function. *Acta Otolaryngologica-Supplement* **520**: 247-250.
- Schuknecht, H. (1969) Cupulolithiasis. *Archives of Otolaryngology* **90**: 765-778.
- Schuknecht, H., Ruby, R. (1973) Cupulolithiasis. *Advances in Otorhinolaryngology* **20**: 434-443.
- Semont, A., Freyss, G., Vitte, E. (1988) Curing BPPV with a liberatory manoeuvre. *Advances in Otorhinolaryngology* **42**: 290-293.
- Shepard, N. T. (1995) New approaches to the dizzy patient; referral, investigation and treatment. BSA London Evening Meeting, April.
- Shepard, N. T., Telian, S. A., Smith-Wheelock, M., Raj, A. (1993) Vestibular and balance rehabilitation therapy. *Annals of Otolaryngology, Rhinology and Laryngology* **102**(3): 198-204.
- Soileau, T. (1995) Management of benign positional vertigo. Vestibular assessment Workshop, Guymark UK Meeting, London, March.
- Vyse, T., Luxon, L. M., Walport, M. J. (1994) Audio-vestibular manifestations of the antiphospholipid syndrome. *Journal of Laryngology and Otolaryngology* **108**: 57-59.
- Yardley, L., Luxon, L. M. (1994) Treating dizziness with vestibular rehabilitation. *British Medical Journal* **308**: 1252.
- Zee, D. S. (1988) The management of patients with vestibular disorders. In *Vestibular Disorders*. (Barber, H. O., Sharpe, J. A., eds.) Year Book Medical Publishers Inc, Chicago, IL, pp 254-274.

Address for correspondence:  
 Professor L. M. Luxon,  
 Division of Academic Audiological Medicine,  
 Institute of Laryngology & Otolaryngology,  
 330-333 Grays Inn Road,  
 London WC1X 8EE.