

A functional magnetic resonance imaging study mapping the episodic memory encoding network in temporal lobe epilepsy

Meneka K. Sidhu, Jason Stretton, Gavin P. Winston, Silvia Bonelli, Maria Centeno, Christian Vollmar, Mark Symms, Pamela J. Thompson, Matthias J. Koepp and John S. Duncan

Department of Clinical and Experimental Epilepsy, UCL Institute of Neurology, Queen Square, London WC1N 3BG, UK

Correspondence to: Prof. John S. Duncan,
UCL Institute of Neurology,
Queen Square,
London WC1N 3BG,
UK
E-mail: j.duncan@ucl.ac.uk

Functional magnetic resonance imaging has demonstrated reorganization of memory encoding networks within the temporal lobe in temporal lobe epilepsy, but little is known of the extra-temporal networks in these patients. We investigated the temporal and extra-temporal reorganization of memory encoding networks in refractory temporal lobe epilepsy and the neural correlates of successful subsequent memory formation. We studied 44 patients with unilateral temporal lobe epilepsy and hippocampal sclerosis (24 left) and 26 healthy control subjects. All participants performed a functional magnetic resonance imaging memory encoding paradigm of faces and words with subsequent out-of-scanner recognition assessments. A blocked analysis was used to investigate activations during encoding and neural correlates of subsequent memory were investigated using an event-related analysis. Event-related activations were then correlated with out-of-scanner verbal and visual memory scores. During word encoding, control subjects activated the left prefrontal cortex and left hippocampus whereas patients with left hippocampal sclerosis showed significant additional right temporal and extra-temporal activations. Control subjects displayed subsequent verbal memory effects within left parahippocampal gyrus, left orbitofrontal cortex and fusiform gyrus whereas patients with left hippocampal sclerosis activated only right posterior hippocampus, parahippocampus and fusiform gyrus. Correlational analysis showed that patients with left hippocampal sclerosis with better verbal memory additionally activated left orbitofrontal cortex, anterior cingulate cortex and left posterior hippocampus. During face encoding, control subjects showed right lateralized prefrontal cortex and bilateral hippocampal activations. Patients with right hippocampal sclerosis showed increased temporal activations within the superior temporal gyri bilaterally and no increased extra-temporal areas of activation compared with control subjects. Control subjects showed subsequent visual memory effects within right amygdala, hippocampus, fusiform gyrus and orbitofrontal cortex. Patients with right hippocampal sclerosis showed subsequent visual memory effects within right posterior hippocampus, parahippocampal and fusiform gyri, and predominantly left hemisphere extra-temporal activations within the insula and orbitofrontal cortex. Correlational analysis showed that patients with right hippocampal sclerosis with better visual memory activated the amygdala bilaterally, right anterior parahippocampal gyrus and left insula. Right sided extra-temporal areas of reorganization observed in patients with left hippocampal sclerosis during word encoding and bilateral lateral temporal reorganization in patients with right hippocampal sclerosis during face encoding were not associated with subsequent memory formation. Reorganization within the medial temporal lobe, however, is an efficient

Received April 3, 2012. Revised February 7, 2013. Accepted February 24, 2013. Advance Access publication May 14, 2013

© The Author (2013). Published by Oxford University Press on behalf of the Guarantors of Brain.

This is an Open Access article distributed under the terms of the Creative Commons Attribution Non-Commercial License (<http://creativecommons.org/licenses/by-nc/3.0/>), which permits non-commercial re-use, distribution, and reproduction in any medium, provided the original work is properly cited. For commercial re-use, please contact journals.permissions@oup.com

process. The orbitofrontal cortex is critical to subsequent memory formation in control subjects and patients. Activations within anterior cingulum and insula correlated with better verbal and visual subsequent memory in patients with left and right hippocampal sclerosis, respectively, representing effective extra-temporal recruitment.

Keywords: temporal lobe epilepsy; episodic memory; functional MRI

Introduction

Lesional, functional imaging and computational analyses have shown that the medial temporal lobe, prefrontal cortex and sub-cortical structures are involved in episodic memory processes (Simons and Spiers, 2003; Squire *et al.*, 2004). A recent meta-analysis of functional MRI event-related studies identified other brain regions critical to memory encoding such as the fusiform gyrus, posterior parietal and premotor cortex in healthy individuals (Hongkeun, 2011).

Specific processes that mediate memory encoding have been shown to occur in different subregions of the prefrontal cortex; semantic and phonological elaborations in the inferior frontal gyrus (Otten and Rugg, 2001), and material organization and manipulation within the middle frontal gyrus (Wig *et al.*, 2004). The orbitofrontal cortex, with its close anatomical connections to the medial temporal lobe (Carmichael and Price, 1995), is thought to be critical to the successful encoding of both verbal (Savage *et al.*, 2001) and visual material (Frey and Petrides, 2002). Individuals with medial temporal lobe epilepsy have significant material-specific episodic memory impairments, with greater verbal and visual memory deficits with left and right temporal lobe epilepsy, respectively. More recently, however, widespread cognitive deficits have been described with variable memory performance between patients despite a homogenous clinical presentation (Helmstaedter *et al.*, 2003; Elger *et al.*, 2004). This is in concert with more widespread morphological (Woermann *et al.*, 1999) and functional abnormalities with disrupted connectivity as remote as the orbitofrontal and occipital cortices being described (Voets *et al.*, 2009).

Functional MRI studies in healthy control subjects have shown a material-specific functional hemispheric lateralization of verbal and visual memory encoding to the left and right hemispheres, respectively (Kelley *et al.*, 1998; Golby *et al.*, 2002). Functional MRI studies in patients with temporal lobe epilepsy have consistently shown atypical material-specific involvement of the medial temporal lobe in episodic memory encoding, with reorganization of memory functions to the contralesional side (Golby *et al.*, 2002; Richardson *et al.*, 2003; Powell *et al.*, 2007). Extra-temporal activations during verbal and visual memory encoding in temporal lobe epilepsy have only been investigated in relatively small studies in which differences in the encoding network compared with control subjects have been described within the prefrontal cortex, lateral temporal, parietal and occipital cortex (Dupont *et al.*, 2000, 2002; Maccotta *et al.*, 2007; Alessio *et al.*, 2013). Greater contralateral right prefrontal cortex activations in varied stereotactic brain regions have been shown during word encoding in patients with left temporal lobe epilepsy (Dupont *et al.*, 2000; Maccotta *et al.*, 2007; Alessio *et al.*, 2013). Visual encoding in

patients with right temporal lobe epilepsy has been investigated in relatively fewer studies (Maccotta *et al.*, 2007; Alessio *et al.*, 2013). These studies were analysed using a blocked model and no correlations were made with memory performance; therefore, it is not known if these extra-temporal regions are involved in subsequent memory formation.

Several subsequent memory studies using an event-related analysis of functional MRI comparing activations related to items that are subsequently remembered to those forgotten have been reported within the medial temporal lobe (Richardson *et al.*, 2003, 2006; Powell *et al.*, 2007; Bonelli *et al.*, 2010). By contrast, extra-temporal subsequent memory effects have been less well described. A verbal subsequent memory analysis in a small heterogeneous group of patients with right and left frontal and temporal lobe epilepsy showed that activations within the insula, cuneus and cingulate cortex were contributory to subsequent verbal memory in patients but not control subjects (Eliassen *et al.*, 2008). The extra-temporal functional anatomy of episodic memory processes in those with temporal lobe epilepsy has not been investigated in detail. This is an important consideration for patients who may be candidates for epilepsy surgery.

The blocked analysis investigates neural correlates during the encoding task and provides a good reflection of strategies employed during encoding. Although it is more sensitive than an event-related analysis, the latter addresses a more specific issue of successful subsequent memory (Powell *et al.*, 2005). We employed a blocked analysis to test the hypotheses that: (i) healthy control subjects have a material-specific representation of memory encoding; left hemispheric activations for verbal memory and right for visual; and (ii) patients with left and right temporal lobe epilepsy have greater activations for verbal and visual memory encoding within the contralateral 'healthy' hemisphere.

Additionally, we investigated the neural correlates of successful subsequent memory in patients with temporal lobe epilepsy at a whole brain level using an event-related analysis. Further, correlations of out-of-scanner visual and verbal memory performance with subsequent memory activations were conducted to investigate the effectiveness of subsequent memory activations (Powell *et al.*, 2007).

Materials and methods

Subjects

We studied 44 patients with medically refractory temporal lobe epilepsy (24 left: median age 42 years, range 19–54 years; and 20 right: median age 42.5, range 21–56) due to unilateral hippocampal sclerosis, who underwent presurgical evaluation at the National Hospital for

Neurology and Neurosurgery, London. All patients had undergone structural MRI at 3T, including quantification of hippocampal volumes and T_2 relaxation times confirming unilateral hippocampal sclerosis with normal contralateral medial temporal structures (Table 1). Prolonged interictal and ictal EEG-video telemetry confirmed ipsilateral seizure onset zones in all patients. All patients received anti-epileptic medication and spoke fluent English. Twenty-six healthy native English speaking control subjects, median age 37 years (range 19–58 years) with no neurological or psychiatric history were also studied.

All patients underwent detailed presurgical neuropsychometry. Handedness and language dominance were determined using a standardized questionnaire (Oldfield, 1971) and language functional MRI tasks (Powell *et al.*, 2006), respectively. Expressive language lateralization within an inferior and middle frontal gyrus mask was calculated (Bonelli *et al.*, 2010). Only left language dominant control subjects and patients were included in this study (language lateralization index of ≤ -0.5) (Table 1). This study was approved by the National Hospital for Neurology and Neurosurgery and the UCL Institute of Neurology Joint Research Ethics Committee. Written informed consent was obtained from all participants.

Neuropsychological testing

All patients and control subjects underwent standardized cognitive assessments including measures of intellectual functioning, IQ (Nelson and O'Connell, 1978; Wechsler, 1997) and measures of verbal learning and design learning (Coughlan *et al.*, 2007) previously demonstrated to be sensitive to the integrity of temporal structures (Baxendale *et al.*, 2006) (Table 1). In the verbal learning task, participants are read a list of 15 words that they subsequently recall. This was done five times. A total sum of recalled words is calculated as a verbal performance measure. A similar neuropsychological test in which an abstract design was presented was used to calculate design learning scores.

Magnetic resonance data acquisition

Studies were performed using a 3T General Electric Excite HDx MRI scanner with a gradient strength of 40m/Tm and slew rate 150Tm/s. For the functional MRI, gradient-echo planar images were acquired, providing blood oxygen level-dependent contrast. Each volume comprised 36 contiguous oblique axial slices, slice thickness 2.5mm (0.3mm gap), field of view 24cm, matrix 96 × 96 interpolated to 128 × 128 during image reconstruction, in-plane resolution 2.5, SENSE factor 2.5, echo time 25ms, repetition time 2.75s. The field of view was positioned to cover the temporal and frontal lobes with the slices aligned with the long axis of the hippocampus on the sagittal view.

Memory encoding paradigm

Two material types, visual stimuli (faces) and verbal stimuli (words) were visually presented to patients during a single scanning session. Black and white photographs of non-famous faces unfamiliar to the subjects and single concrete nouns were presented on a magnetic resonance compatible screen viewed through a mirror (Bonelli *et al.*, 2010). Each item was presented for 3s in 60s blocks. We used a different interstimulus interval (3s) to our repetition time of 2.75s to introduce jitter and facilitate random sampling. Each block consisted of 10 faces and 10 words followed by 15s cross-hair fixation. We presented a total of 10 blocks (100 faces and 100 words). Participants were explicitly instructed to memorize items for subsequent out of scanner recall. A deep encoding task (Craik, 2002), which involved a subjective decision on whether each stimulus was pleasant or unpleasant, using a joystick, was performed.

Forty minutes after scanning, face and word recognition was tested separately in an out-of-scanner recognition task. In each recognition task, subjects were shown the same 100 items intermixed with an additional 50 novel faces/words as foils in random order at the same speed as items were displayed within the scanner.

A button box was used to indicate if items were remembered, familiar or novel. These responses were used to sort each item shown in the scanner to items remembered, familiar and forgotten. Recognition accuracy (%) was calculated for both faces and words (true positive – false positive).

Data analysis

Analysis was performed using Statistical Parametric Mapping 8 (<http://www.fil.ion.ucl.ac.uk/spm/>). The imaging time series was realigned, normalized into standard anatomical space (using a scanner specific template created from 30 healthy control subjects, 15 patients with left hippocampal sclerosis and 15 patients with right hippocampal sclerosis using the high resolution whole brain echo planar image) and smoothed with a Gaussian kernel of 8mm full-width at half-maximum.

Blocked design

Regressors of interest were formed by creating two box-car functions for faces and words convolved with the canonical haemodynamic response function. Movement parameters were included as confounds and parameter estimates for the regressors were calculated for each voxel. Contrasts were generated for both 'words' and 'faces' corresponding to the main effect of material-specific encoding. These contrast images were used for the second-level analysis.

A random effects analysis was performed at the second level. Subjects were divided into three groups: control subjects, patients

Table 1 Demographic details and results of standard neuropsychometry in control subjects and patients

	Age (years)	Age at onset (years)	Duration (years)	No. of AEDs	Language LI within frontal ROI	Right HC Volume (cm ³)	Left HC Volume (cm ³)	IQ	List Learning /75	Design Learning /45	RA Words %	RA Faces %
C	37 (23.3)	n/a	n/a	n/a	-0.82 (0.13)	2.76 (0.21)	2.70 (0.3)	111.5 (11)	57.4 (8.9)	39.3 (5.3)	75 (12.1)	27 (12.2)
LHS	42 (9.3)	15.8 (2.8)	24.1 (14)	3 (1)	-0.76 (0.12)	2.76 (0.35)	1.82* (0.4)	97* (9.8)	44.5* (10.9)	34.2 (7.4)	49* (15.7)	15* (9.4)
RHS	42.5 (13.5)	13.5 (2.5)	28.7 (16.5)	3 (1)	-0.75 (0.14)	1.92* (0.41)	2.74 (0.32)	99* (14.7)	44* (10)	27* [#] (9)	59* (20.6)	14* (9.7)

Age and number of anti-epileptic drugs (AEDs) are shown as median (IQR), all others shown as mean (SD). LI = lateralization index; ROI = region of interest; HC = hippocampus, RA = recognition accuracy. *Control subjects (C) > patient group indicated $P < 0.001$, [#]left hippocampal sclerosis > right hippocampal sclerosis; $P = 0.004$.

with left hippocampal sclerosis and patients with right hippocampal sclerosis. A one-sample *t*-test was performed to examine the group effect of each contrast. An ANOVA was performed to quantitatively assess statistically different brain activations between all three groups. To ensure that only differences in activation were analysed, the difference maps were masked with the main effect of condition.

All results for the main effects are shown corrected for multiple comparisons [family wise error (FWE)], $P < 0.05$ and group comparisons at $P < 0.001$ uncorrected unless otherwise stated. Activations within the medial temporal lobe are shown corrected for multiple comparisons using a small volume correction within a sphere of 6 mm, FWE $P < 0.001$ (Bonelli *et al.*, 2010).

Event-related analysis

Event-related analysis on a blocked designed experiment have been performed in memory studies (Richardson *et al.*, 2003; Powell *et al.*, 2007; Bonelli *et al.*, 2010) and other cognitive tasks (Mechelli *et al.*, 2003; Seghier *et al.*, 2012; Seghier and Price, 2012). We compared the encoding-related responses for stimuli that were subsequently remembered versus stimuli that were subsequently forgotten or rated familiar. A two-level event-related random-effects analysis was employed. One individual with left hippocampal sclerosis had a complex partial seizure during the recognition task and one patient with right hippocampal sclerosis had a complex partial seizure after scanning. Recognition tasks and therefore event-related analysis were not performed in these two patients.

First level

For each subject, trial-specific delta functions were convolved with the canonical haemodynamic response function and its temporal derivative. Six regressors of interest for each of the event types, words remembered (WR), words familiar (WFam), words forgotten (WF), faces remembered (FR), faces familiar (FFam) and faces forgotten (FF) were created. Each subject's movement parameters were included as confounds. Contrast images were created for each subject for verbal subsequent memory [defined by (WR) – (WFam + WF)] and visual subsequent memory [defined by (FR) – (FFam + FF)]. These images were used for the second-level analysis.

Second level

One-sample *t*-tests were used to examine the group effect of each contrast in each group.

Correlations with memory performance

Verbal and visual subsequent memory activations from the event-related analyses were correlated with verbal and design learning scores in control subjects, patients with left hippocampal sclerosis and patients with right hippocampal sclerosis, respectively. Positive and negative correlations were explored using memory scores as a continuous regressor in an analysis of covariance (ANCOVA), using the group verbal and visual activation maps as a mask. All activations are shown at a threshold of $P < 0.001$ uncorrected. Medial temporal lobe activations are shown corrected for multiple comparisons using a small volume correction within a sphere of 6 mm (FWE $P < 0.05$) unless otherwise stated.

Results

Behavioural

Control subjects performed significantly better than patients with left and patients with right hippocampal sclerosis on both word [mean % (SD), 75 (12.1), 49 (15.7), 59 (20.6), respectively] and face [27 (12.2), 15 (9.4), 14 (9.7)] recognition. There was no significant difference between the patient groups in word and face recognition accuracy. Both control subjects and patients had significantly higher recognition accuracy for words than faces (Table 1 and Fig. 1).

Control subjects performed better than both patients with left and patients with right hippocampal sclerosis on the verbal learning task [57.4 (8.9), 44.5 (10.9), 44 (10)]. There was no significant verbal learning difference between patients with left and patients with right hippocampal sclerosis. Both control subjects and patients with left hippocampal sclerosis performed significantly better than those with right hippocampal sclerosis on the design learning task [39.3 (5.3), 34.2 (7.4), 27 (9.0)] (Table 1).

Main effects

Word encoding

All three groups showed activations in the left inferior frontal gyrus, middle frontal gyrus, anterior prefrontal cortex, left precentral and bilateral fusiform gyri. Although activations were left lateralized within the prefrontal cortex, control subjects also showed activations in the right middle frontal gyrus. Patients with left hippocampal sclerosis showed activations in the right middle frontal gyrus, inferior frontal gyrus, angular gyrus, superior parietal lobule and left post-central gyrus that were not seen in the other groups. Qualitatively, both patient groups showed activations in the left inferior temporal gyrus and inferior parietal lobule that were not seen in control subjects. Control subjects and both patient groups activated the left hippocampus during word encoding. Patients with left hippocampal sclerosis also

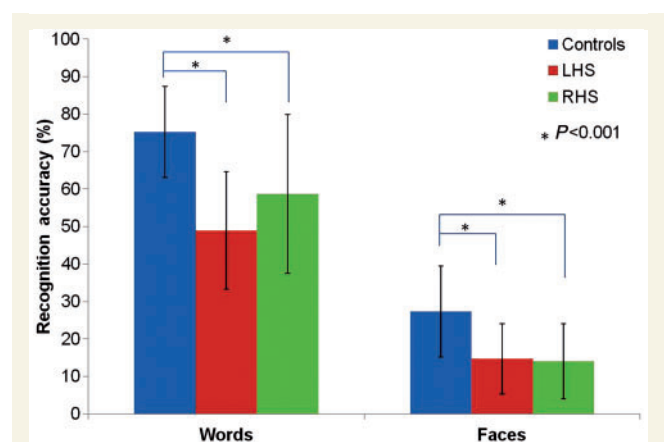


Figure 1 Histograms showing mean percentage recognition accuracy with error bars (± 1 SD) for word and face recognition across all groups. LHS = left hippocampal sclerosis; RHS = right hippocampal sclerosis.

showed contralateral right hippocampus and amygdala activation. Patients with right hippocampal sclerosis also activated the left parahippocampal gyrus (Table 2 and Fig 2).

Face encoding

Control subjects and patients with left hippocampal sclerosis showed right lateralized prefrontal cortex activations. Patients with right hippocampal sclerosis showed bilateral, albeit reduced, prefrontal cortex activations. All three groups activated the right

superior parietal lobule, bilateral fusiform gyri, left pre- and post-central gyri and left insula. Only control subjects activated the right orbitofrontal cortex, anterior prefrontal cortex and left occipital cortex. Patients with left hippocampal sclerosis also activated the right inferior temporal gyrus and temporal poles bilaterally. Control subjects showed bilateral activations within the hippocampus, parahippocampal gyrus and amygdala. Both patient groups showed qualitatively more activations in the contralesional medial temporal lobe (Table 3 and Fig. 3).

Table 2 Whole brain activations in control subjects, patients with left hippocampal sclerosis and patients with right hippocampal sclerosis during word encoding shown corrected for multiple comparisons (FWE) $P < 0.05$

FWE $P < 0.05$	Word encoding											
	Left hemisphere						Right hemisphere					
	Controls	z	LHS	z	RHS	z	Controls	z	LHS	z	RHS	z
Ant PFC	-4 52 -22	4.89	-38 30 -14	5.54	-34 30 -12	5.64						
	-42 28 -18	5.07										
Inf Frontal G	-42 24 -4	5.41	-46 24 -6	5.97	-48 30 4	6.87			40 32 16	6.27		
	-44 16 6	5.03	-48 28 20	6.18	-46 18 22	6.16			36 26 8	6.14		
	-38 24 14	5.06	-50 16 -4	6.1	-44 6 24	6.13			50 18 -10	6.08		
	-40 6 28	6.54	-48 8 22	5.72	-50 28 -10	5.95			54 14 6	6		
Mid Frontal G			-52 10 10	4.78	-56 10 12	5.78						
	-36 -4 56	6.37	-48 12 36	6.24	-52 28 22	5.85	38 0 50	5.14	58 14 30	5.88		
			-40 2 36	5.36					40 2 52	5.51		
Med Frontal G	-6 4 54	6.19	-4 12 50	6.44					36 44 28	4.78		
	-2 -4 56	6.04							10 12 48	5.87		
Insula	-32 24 2	5.25	-48 -26 18	5.07					6 2 56	5.75		
	-40 0 12	4.69					36 26 -2	4.84	32 20 4	5.59		
Precentral G	-32 -10 64	6.71	-40 -16 54	5.56	-44 -16 58	4.89	56 8 42	5.05	50 8 30	6.7		
	-38 -24 58	6.21			-54 0 42	5.71						
	-36 -14 60	6.26										
Postcentral G			-42 -40 62	5.61								
			-38 -26 52	5.52								
			-50 -14 54	5.44								
Angular G									30 -58 46	4.88		
Supramarginal	-52 -22 18	5.28	-54 -38 24	5.01								
Sup Parietal L	-26 -58 52	5.08							34 -58 54	4.92		
Inf Parietal L			-32 -48 46	5.1	-32 -60 52	4.88						
Thalamus			-14 -12 4	5.84					14 -6 -2	4.95		
Putamen	-26 0 -6	5.53					18 6 8	4.81				
Fusiform G							24 4 8	4.95				
	-42 -52 -14	6.01	-42 -54 -16	6.25	-46 -58 -18	5.41	34 -38 24	3.85	32 -38 -24	4.65	42 -52 -24	4.32
	-36 -38 -24	5.57	-34 -64 -8	4.23	-44 -46 -22	4.63			38 -52 -12	4.47		
Inf Temporal G	-40 -56 -10	6.36	-40 -24 -8	5.83	-46 -58 -18	5.41			34 -6 -46	3.71		
			-50 -52 -10	5.62	-37 -14 -36	4.23						
			-50 -44 -10	5.96								
Mid Temporal G			-46 -66 -6	4.87								
			-48 -54 -2	5.27								
Occipital	-40 -58 -8	6.65			-54 -64 -16	5.60						
Cerebellum			-28 -48 -22	5.59			4 -56 -10	5.53	6 -60 -18	4.74		
MTL activations, Family wise error correction within a 6 mm sphere, $P < 0.001$												
Hippocampus	-30 -18 -12	4.65	-26 -24 -8	4.38	-32 -14 -18	5.08			32 -20 -8	4.45		
	-24 -22 -10	4.69	-32 -22 -10	4.1	-26 -22 -14	4.65			28 -24 -8	4.31		
	-14 -28 -10	4.23	-28 -28 -6	4.38					32 -16 -12	3.69		
	-12 -6 -16	4.39	-16 -26 -8	4.01								
PHG					-14 -30 -10	3.74						
Amygdala	-22 -8 -12	4.24	-26 2 -16	4.01					22 6 -16	3.39		
	-26 -2 -16	3.38										

Medial temporal lobe activations are shown corrected for multiple comparisons using a small volume correction within a sphere of 6 mm, FWE $P < 0.001$. All groups showed left prefrontal cortex (PFC) activations during word encoding. Patients with left hippocampal sclerosis (LHS) additionally activated the right middle frontal gyrus and inferior frontal gyrus. Patients with right hippocampal sclerosis (RHS) showed no right prefrontal cortex activation but showed activations in the left inferior temporal gyrus and parahippocampal gyrus (PHG) that was not seen in control subjects. Ant = anterior; Med = medial; G = gyrus; L = lobule; Sup = superior; Mid = middle; Inf = inferior; MTL = medial temporal lobe.

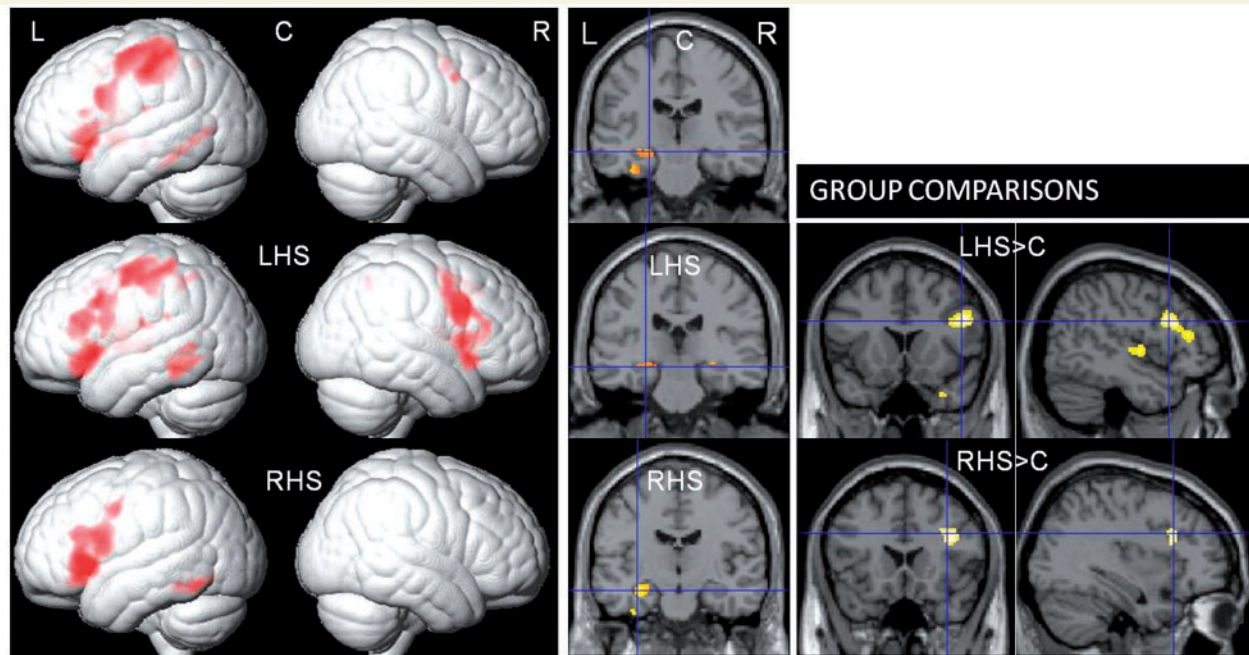


Figure 2 Rendered image showing whole brain activations, coronal image showing medial temporal lobe activations and group comparisons during word encoding in control subjects (C), patients with left hippocampal sclerosis (LHS) and right hippocampal sclerosis (RHS). Control subjects and patients with right hippocampal sclerosis showed robust left lateralized prefrontal cortex and hippocampal activations whereas patients with left hippocampal sclerosis activated the prefrontal cortex and hippocampus bilaterally. Group comparisons showed greater right prefrontal cortex activations in patients with left hippocampal sclerosis than control subjects. Patients with right hippocampal sclerosis activated the prefrontal cortex bilaterally greater than control subjects; only right prefrontal cortex activation greater than control subjects is shown in this image. L = left; R = right.

Group comparisons

Word encoding

Quantitative analysis revealed significantly greater right hemispheric activations within the middle frontal gyrus, inferior frontal gyrus and superior temporal gyrus in patients with left hippocampal sclerosis compared with control subjects whereas those with right hippocampal sclerosis activated the right superior temporal gyrus and middle frontal gyrus bilaterally, greater than control subjects (Table 4 and Fig. 2).

Both patient groups showed reduced left hemispheric activations compared with control subjects. In patients with left hippocampal sclerosis this reduction was seen at a lower threshold; left middle temporal gyrus ($P = 0.002$) and left inferior frontal operculum ($P = 0.007$) (Table 4).

Face encoding

Patients with left hippocampal sclerosis showed significantly greater right hemispheric activations within the inferior frontal gyrus, superior temporal gyrus and supramarginal gyrus compared with control subjects whereas those with right hippocampal sclerosis showed greater bilateral superior temporal gyrus activations compared with control subjects during face encoding. No significant extra-temporal increased activation was seen in patients with right hippocampal sclerosis compared with control subjects (Table 4 and Fig. 3).

Both patient groups showed significantly less medial orbitofrontal cortex activation than control subjects. Patients with left hippocampal sclerosis also showed significantly fewer left hemisphere activations within the inferior frontal gyrus, lateral orbitofrontal cortex, middle occipital gyrus, amygdala and hippocampus than control subjects, whereas those with right hippocampal sclerosis showed significantly fewer right hemisphere activations within the middle frontal gyrus, middle occipital gyrus and amygdala than control subjects (Table 4).

Event-related analysis

Verbal subsequent memory

In control subjects, verbal subsequent memory activations were seen within the left orbitofrontal cortex, parahippocampal gyrus and fusiform gyrus. Patients with left hippocampal sclerosis showed subsequent memory effects within the right posterior parahippocampal gyrus and hippocampus, right fusiform gyrus and inferior temporal gyrus bilaterally. No extra-temporal subsequent memory activations were seen in patients with left hippocampal sclerosis. Patients with right hippocampal sclerosis activated the left orbitofrontal cortex and inferior frontal gyrus, right insula and bilateral parahippocampal gyrus, precentral gyrus and temporal poles during verbal subsequent memory. The extra-temporal areas of significantly increased activation compared with control subjects during word encoding in both patients with left

Table 3 Whole brain activations in control subjects, patients with left hippocampal sclerosis and patients with right hippocampal sclerosis during face encoding shown corrected for multiple comparisons (FWE) $P < 0.05$

FWE $P < 0.05$	Face encoding											
	Left hemisphere						Right hemisphere					
	Controls	z	LHS	z	RHS	z	Controls	z	LHS	z	RHS	z
Ant PFC	–38 30 –20	5.74					2 52 –20	5.34				
							10 62 –10	4.79				
							32 32 –20	5.65				
Inf Frontal G	–40 6 28	5.38	–36 8 30	5.1	–42 6 26	5.34	46 18 24	6.69	48 8 30	7	42 8 22	5.68
					–30 26 –10	5.17	50 36 10	6.24	46 32 14	5.77	50 32 24	5.36
							30 26 –14	5.26	52 16 6	5.76		
Mid Frontal G							40 4 42	5.72	42 2 52	5.76	48 10 34	5.37
							44 28 36	5.13				
Med Frontal G	–6 6 52	6.21	–4 10 52	6.76			6 18 46	5.82	0 18 50	6.11		
	–2 –8 54	5.65										
Insula	–42 –2 10	4.77	–36 18 8	5.2	–34 22 4	5.36	38 26 –2	6.69	34 22 4	4.87		
	–30 16 4	5.34										
Precentral G	–32 –10 64	6.36	–40 –26 62	5.9	–38 –4 46	5.19	52 8 44	6.12				
Postcentral G	–38 –24 60	6.14	–46 –38 62	6.17	–50 –34 54	5.09						
			–54 –18 54	5.95								
Angular G							32 –56 44	4.91				
Sup Parietal L							32 –58 56	6.21	30 –56 46		34 –60 44	5.44
Inf Parietal L					–28 –50 48	5.41						
Putamen	–22 –4 0	7.07	–26 –2 2	5.44			18 2 –2	6.85	22 6 6	5.08		
Fusiform G	–38 –46 –18		–40 –44 –22	5.65	–38 –52 –24	5.84	44 –42 20	6.41	44 –54 –8	5.42	38 –50 –24	5.57
					–36 –62 –18	5.44	44 –52 –12	6.03	42 –38 –22	5.26		
							34 –38 –24	5.74				
Temporal Pole			–48 16 –10	5.2					54 18 –10	5.93		
Inf Temporal G									44 –40 –20	5.46		
Occipital	–38 60 –8	6.44					44 –64 –2	5.96			24 –100 10	6.01
	–38 –70 0	5.61					32 –84 14	6.27			42 –74 –12	4.90
Cerebellum					–36 –54 –24	5.93	4 –56 –10	5.45			36 –52 –26	6.13
											26 –48 –26	5.68
MTL activations, Family wise error correction within a 6mm sphere, $P < 0.001$												
Hippocampus	–26 –24 –8	5.18			–22 –16 –14	4.83	20 –30 –8	5.53	26 –22 –10	4.2		
							28 –20 –10	4.3	14 –4 –16	4.51		
Amygdala/ PHG	22 –2 –24	5.43	–24 –2 –16	4.22	–18 –4 –14	4.68	18 –6 –22		20 2 –20	5.29		

Medial temporal lobe activations (MTL) are shown corrected for multiple comparisons using a small volume correction within a sphere of 6 mm, FWE $P < 0.001$. Only control subjects activated the anterior prefrontal cortex (Ant PFC). Although all groups activated the right middle and inferior frontal gyri, patients with right hippocampal sclerosis showed reduced activations in these regions. Ant = anterior; Med = medial; G = gyrus; L = lobule; Sup = superior; Mid = middle; Inf = inferior; PHG = parahippocampal gyrus.

hippocampal sclerosis (right middle frontal gyrus and inferior frontal gyrus) and those with right hippocampal sclerosis (bilateral middle frontal gyrus) were not involved in subsequent verbal memory formation (Table 5 and Fig. 4).

Correlation of verbal subsequent memory activations with out-of-scanner verbal learning scores

Control subjects showed no significant positive correlations. Activations within the posterior cingulate cortex bilaterally correlated negatively with verbal learning scores in control subjects. Although patients with left hippocampal sclerosis showed no extra-temporal verbal subsequent memory effects as a group, correlation with verbal learning scores showed a positive correlation with extra-temporal activation within the left orbitofrontal cortex and anterior cingulate cortex. Positive correlation was also seen with temporal activations within the right posterior parahippocampal gyrus and hippocampus, bilateral middle temporal gyrus and left posterior hippocampus activations [left posterior hippocampus activation was seen at a lower threshold (uncorrected $P = 0.01$)].

In patients with right hippocampal sclerosis, left hippocampus, bilateral anterior parahippocampal gyrus, right posterior parahippocampal gyrus and hippocampus activations correlated positively with verbal learning scores. No negative correlations with verbal learning scores were seen in either patient group (Table 6 and Fig. 5).

Visual subsequent memory

Control subjects activated the right orbitofrontal cortex, fusiform gyrus, hippocampus, amygdala and inferior temporal gyrus. Activations were also seen in the left parahippocampal gyrus, left temporal pole and middle temporal gyri bilaterally. In patients with left hippocampal sclerosis activations were seen in the right anterior parahippocampal gyrus and amygdala, left insula, left superior and middle temporal gyri and left anterior cingulate cortex. Patients with right hippocampal sclerosis activated the left insula, orbitofrontal cortex, precentral and post-central gyri, right anterior and posterior parahippocampal gyrus and right posterior hippocampus (Table 7 and Fig. 6).

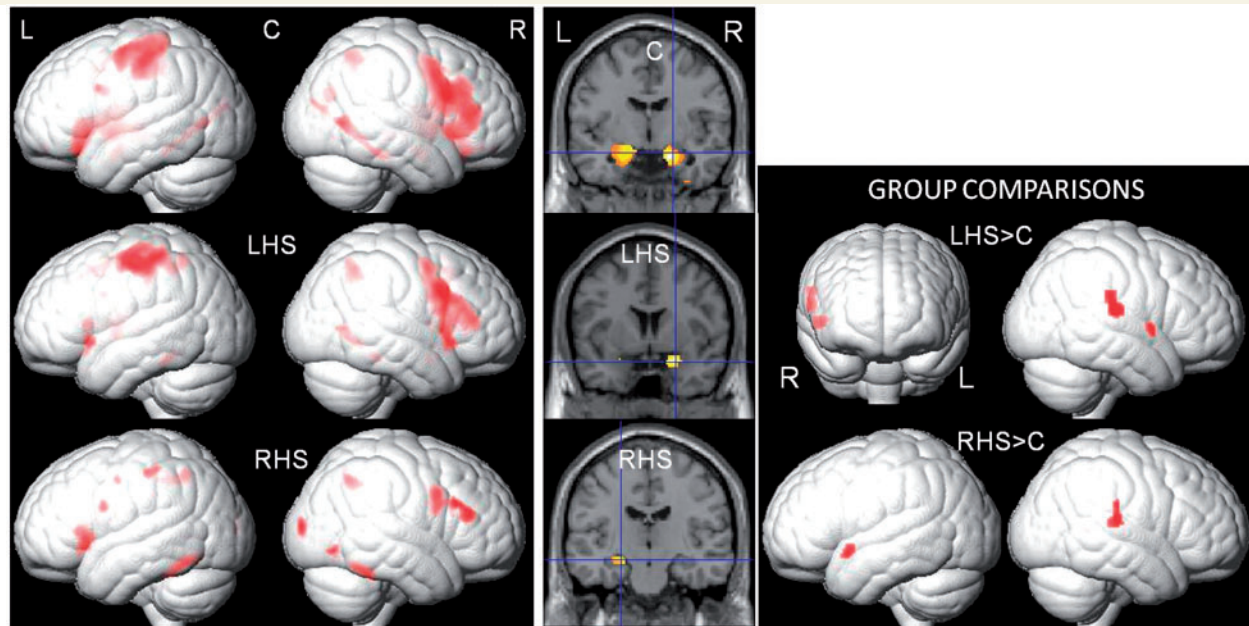


Figure 3 Rendered image showing whole brain activations, coronal image showing medial temporal lobe activations and group comparisons during face encoding in control subjects (C), patients with left hippocampal sclerosis (LHS) and right hippocampal sclerosis (RHS). Control subjects showed bilateral prefrontal cortex (right lateralized) and medial temporal lobe activations during face encoding. Patients with left hippocampal sclerosis activated predominantly the right prefrontal cortex and medial temporal lobe whereas patients with right hippocampal sclerosis showed fewer activations than control subjects in the right prefrontal cortex and only left medial temporal lobe activation. Group comparisons are shown on a rendered image. Patients with left hippocampal sclerosis activated the right prefrontal cortex, superior temporal gyrus and supramarginal gyrus more than control subjects. Patients with right hippocampal sclerosis activated the superior temporal gyri bilaterally (anterior on left, posterior on right) greater than control subjects. L = left; R = right.

Correlation of visual subsequent memory activations with out-of-scanner design learning scores

Control subjects showed no significant positive correlation. Activations within the middle cingulate cortex and supplementary motor area correlated negatively with design learning scores in control subjects. Patients with right hippocampal sclerosis showed significant positive correlation with right anterior parahippocampal gyrus and amygdala, left amygdala and left insula activations (Table 6 and Fig. 7). No negative correlation with design learning scores was seen in patients with right hippocampal sclerosis. Patients with left hippocampal sclerosis showed neither positive nor negative correlation with design learning scores.

Effect size analysis

In our event-related analysis above we showed brain regions that were important for successful memory formation in patients but not in control subjects. To further strengthen the methodology and validity of our findings we performed a *post hoc* analysis where we investigated the effect size of brain activations for remembered, familiar and forgotten trials individually in a brain region that was important for subsequent memory in patients but not control subjects. Effect size quantification was performed within the left insula where we showed significant successful subsequent visual memory activation in patients with right hippocampal sclerosis but not in control subjects in the event-related analysis.

Effect size quantification was performed by extracting the mean blood oxygen level-dependent percentage signal change for remembered, familiar and forgotten faces individually using the MarsBar toolbox in SPM8 (Brett *et al.*, 2002). This was performed in all patients with right hippocampal sclerosis and control subjects at the single subject level. There was a significant difference in percentage signal change between the remembered, familiar and forgotten faces [mean % signal change (SEM), 0.035 (0.012), -0.002 (0.014), 0.008 (0.017), respectively] in patients with right hippocampal sclerosis (paired *t*-test, $P < 0.05$) with the highest positive percentage signal change for remembered faces. There was a negative percentage signal change for faces remembered, familiar and forgotten [-0.003 (0.012), -0.021 (0.013), -0.012 (0.014), respectively] in control subjects at the left insula with no significant difference in effect size between the three trials ($P > 0.05$, paired *t*-test; Fig. 8). Patients with right hippocampal sclerosis showed a significantly higher percentage signal change for faces remembered compared with control subjects ($P < 0.05$, independent sample *t*-test).

A significant difference in effect size between remembered, familiar and forgotten faces was only seen in patients with right hippocampal sclerosis but not in control subjects. There was a higher percentage signal change for faces remembered in patients with right hippocampal sclerosis compared with control subjects. These findings corroborate the findings from the event-related analysis above that the left insula was significantly involved in

Table 4 Coordinates, P-values and z-scores of whole brain group differences in activations comparing control subjects, patients with left hippocampal sclerosis and patients with right hippocampal sclerosis during word and face encoding

Group differences: word encoding							
Region	Coordinate	P-value	Z-score	Region	Coordinate	P-value	Z-score
LHS < Controls				RHS < Controls			
Lt mid temporal gyrus	−62 −14 −14	0.002	2.87	Lt postcentral gyrus	−54 −20 40	0.000	3.37
Lt frontal operculum	−38 6 18	0.007	2.47				
LHS > Controls				RHS > Controls			
Rt mid frontal gyrus	48 16 26	0.000	4.19	Rt sup temporal gyrus	56 2 −2	0.000	3.32
Rt inf frontal gyrus	52 26 20	0.000	3.37	Rt mid frontal gyrus	40 20 24	0.001	3.22
Rt sup temporal gyrus	60 −24 14	0.001	3.08	Lt mid frontal gyrus	−32 40 10	0.001	3.01
Group differences: face encoding							
Region	Coordinate	P-value	Z-score	Region	Coordinate	P-value	Z-score
LHS < Controls				RHS < Controls			
LHS < Controls				RHS < Controls			
Medial OFC	4 56 −18	0.000	4.26	Medial OFC	2 58 −12	0.000	3.46
Lt mid occipital	−30 −90 16	0.000	3.33	Rt mid occipital gyrus	32 −78 24	0.000	3.63
Rt post central gyrus	40 −32 44	0.000	3.32	Rt mid frontal gyrus	44 2 42	0.000	3.46
Lt OFC	−38 28 −16	0.001	3.07	Rt amygdala	18 −2 −22	0.06*	2.40
Lt inf frontal gyrus	−42 24 −6	0.001	2.97				
Lt hippocampus	−14 −2 −14	0.021*	2.89	RHS > Controls			
Lt amygdala	−22 −8 −12	0.028*	2.77	Rt sup temporal gyrus	66 −26 16	0.001	3.18
LHS > Controls				Lt sup temporal gyrus	−48 8 −10	0.001	2.98
Rt sup temporal gyrus	66 −24 16	0.000	3.62				
Rt inf frontal gyrus	54 6 0	0.000	3.33				
Rt supramarginal gyrus	66 −24 28	0.001	2.99				

*Family wise error corrections $P < 0.05$ using a small volume correction within a sphere of 6 mm for medial temporal lobe activations. Lt = left; Rt = right; Inf = inferior; Mid = middle; Sup = superior; G = gyrus; OFC = orbitofrontal cortex; NS = no significant activations.

Table 5 Coordinates, P-values and z-scores of whole brain verbal subsequent memory activations in control subjects, patients with left hippocampal sclerosis and patients with right hippocampal sclerosis

Words: remembered – familiar forgotten							
Region	Left hemisphere			Right hemisphere			
	Coordinate	P-value	Z-score	Region	Coordinate	P-value	Z-score
Controls							
Medial OFC	−4 60 −8	0.000	3.36				
PHG	−24 0 −30	0.058*	2.49				
Fusiform G	−32 −42 −22	0.05*	2.53				
LHS							
Inf Temporal G	−46 −6 −36	0.001	3.18	Posterior PHG/ Hippocampus	38 −32 −16	0.03*	3.46
				Inf temporal G	50 −12 −26	0.000	3.40
				Fusiform G	28 −42 −8	0.001	3.23
RHS							
Pre-central G	−40 −6 −34	0.000	3.85	Temporal pole	32 12 −26	0.000	3.94
Caudate	−10 −4 16	0.000	3.66	Insula	32 2 14	0.000	3.62
PHG	−12 0 −26	0.005*	3.41	Caudate	10 2 16	0.000	3.50
Temporal pole	−34 14 −24	0.000	3.4	Precentral G	40 −14 36	0.001	3.20
OFC	−30 36 −4	0.001	3.10	PHG	18 0 −28	0.019*	2.97
Inf Frontal G	−44 4 24	0.001	3.00				
Inf Frontal G	−50 16 16	0.001	2.97				

*Family wise error corrections $P < 0.05$ using a small volume correction within a sphere of 6 mm for medial temporal lobe activations. Lt = left; Rt = right; OFC = orbitofrontal cortex; Sup superior; Inf = inferior; G = gyrus; C = cortex; PHG = parahippocampal gyrus; NS = no significant activations.

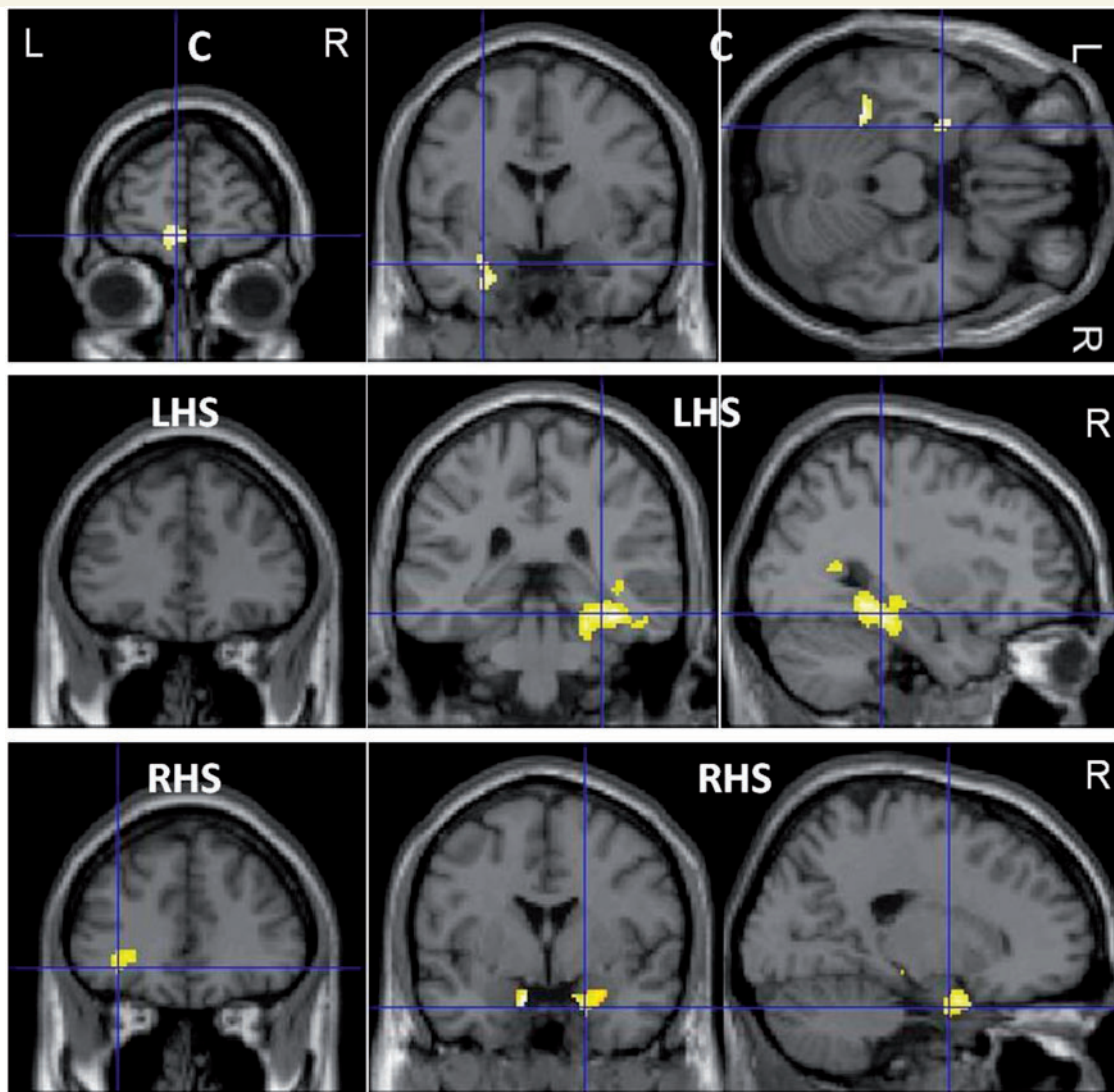


Figure 4 Whole brain verbal subsequent memory in control subjects (C), patients with left hippocampal sclerosis (LHS) and right hippocampal sclerosis (RHS). *Top row:* Activations in control subjects, *middle row:* patients with left hippocampal sclerosis; and *bottom row:* patients with right hippocampal sclerosis. Medial temporal lobe activations are displayed at a threshold of $P < 0.01$, uncorrected. Control subjects showed verbal subsequent memory effects within the left medial orbitofrontal cortex, parahippocampal gyrus and fusiform gyrus. Patients with left hippocampal sclerosis showed no orbitofrontal cortex and only right sided activations within the hippocampus, parahippocampal gyrus and fusiform gyrus. Patients with right hippocampal sclerosis showed left orbitofrontal cortex, and bilateral parahippocampal gyrus activations. L = left; R = right.

subsequent memory formation for faces in patients with right hippocampal sclerosis but not in control subjects.

Discussion

Control subjects showed material-specific memory encoding activations with predominantly left hemispheric activations for word encoding and right for face encoding.

Patients with left hippocampal sclerosis showed greater right-sided activations both temporally (superior temporal gyrus) and extra-temporally for word (middle frontal gyrus and inferior frontal gyrus) and face (supramarginal gyrus, inferior frontal gyrus)

encoding. Patients with right hippocampal sclerosis similarly showed increased activations both temporally (right superior temporal gyrus) and extra-temporally (bilateral middle frontal gyrus) for word encoding, but increases in activation were limited to the temporal lobe (bilateral superior temporal gyrus) for face encoding. Whereas patients with left hippocampal sclerosis showed predominantly right hemispheric increases for word and face encoding, those with right hippocampal sclerosis showed increased activation bilaterally.

Subsequent memory activations in control subjects were material-specific with predominantly left sided activations for verbal subsequent memory and similar right sided activations for visual subsequent memory. Patients with left hippocampal sclerosis

Table 6 Coordinates, P-values and z-scores of positive and negative correlations of verbal and visual subsequent memory activations with verbal memory (VL) and visual memory (DL) performance in control subjects, patients with left hippocampal sclerosis and patients with right hippocampal sclerosis

Correlations with verbal and visual memory scores					
Controls		Coordinate	P-value	Z-score	Region
	Better VL		NS		
	Worse VL	6 -38 16	0.000	3.87	Rt posterior Cingulate C
		-12 44 16	0.000	3.84	Lt posterior Cingulate C
	Better DL		NS		
	Worse DL	16 -16 56	0.000	4.74	SMA / Rt Mid Cingulate C
		14 -12 30	0.000	3.61	Mid Cingulate C
LHS	Better VL	64 -26 -16	0.000	3.97	Rt Mid Temporal G
		-50 -38 2	0.001	3.26	Lt Mid Temporal G
		-36 56 -6	0.001	3.21	Lt OFC
		2 42 10	0.001	3.05	Anterior Cingulate C
		26 -36 -10	0.048*	2.57	Rt posterior PHG
		18 -32 -4	0.01*	2.54	Rt posterior HC
		-20 -36 2	0.01	2.25	Lt posterior HC
	Worse VL		NS		
	Better DL		NS		
	Worse DL		NS		
RHS	Better VL	-34 -30 -10	0.001*	3.88	Lt HC
		24 0 -26	0.003*	3.62	Rt anterior PHG/ amygdala
		18 -30 -12	0.008*	3.28	Rt posterior PHG
		-14 -2 -22	0.032*	2.74	Lt anterior PHG
		36 -36 -4	0.048*	2.57	Rt posterior HC
	Worse VL		NS		
	Better DL	24 2 -24	0.017*	3.18	Rt amygdala/ anterior PHG
		-1 0 -18	0.059*	2.62	Lt amygdala
		-42 2 -2	0.001	3.06	Lt insula
	Worse DL		NS		

* Family wise error corrections $P < 0.05$ using a small volume correction within a sphere of 6 mm for medial temporal lobe activations. Lt = left; Rt = right; OFC = orbitofrontal cortex; C = cortex; G = gyrus; Mid = middle; HC = hippocampus; PHG = parahippocampal gyrus; SMA = supplementary motor area; NS = no significant activations.

showed predominantly right temporal verbal subsequent memory activations and no extra-temporal activations. By contrast, those with right hippocampal sclerosis showed bilateral temporal and extra-temporal verbal subsequent memory effects (Table 8). Patients with left hippocampal sclerosis and those with right hippocampal sclerosis showed visual subsequent memory activations within the right anterior medial temporal lobe (anterior parahippocampal gyrus, amygdala) but patients with right hippocampal sclerosis additionally showed activations within the right posterior parahippocampal gyrus and hippocampus. Both patient groups showed left extra-temporal visual subsequent memory activations (Table 9). Across both tasks, patients with right hippocampal sclerosis showed greater extra-temporal subsequent memory effects than those patients with left hippocampal sclerosis.

Although patients with left hippocampal sclerosis as a group showed only right temporal subsequent memory activations and no extra-temporal activations, patients with a better verbal memory showed additional activations within the left orbitofrontal cortex, anterior cingulate cortex and left posterior hippocampus

correlating positively with verbal learning scores (Table 8). In patients with right hippocampal sclerosis with a better verbal memory, activations within the left hippocampus and right posterior hippocampus in addition to the bilateral anterior parahippocampal gyrus activation seen during verbal subsequent memory correlated positively with verbal learning scores. Patients with right hippocampal sclerosis with a better visual memory showed significant correlations with activation within the left amygdala in addition to activations within the right anterior parahippocampal gyrus and left insula that were seen in the visual subsequent memory analysis (Table 9). No additional areas correlated with design learning in patients with left hippocampal sclerosis.

The areas of significantly increased activation observed in patients compared to control subjects on word and face encoding were not associated with subsequent memory formation across both material types but additional contralateral medial temporal lobe activations correlated with better memory performance within the patient groups. Extra-temporally, the orbitofrontal cortex is involved in successful verbal and visual subsequent

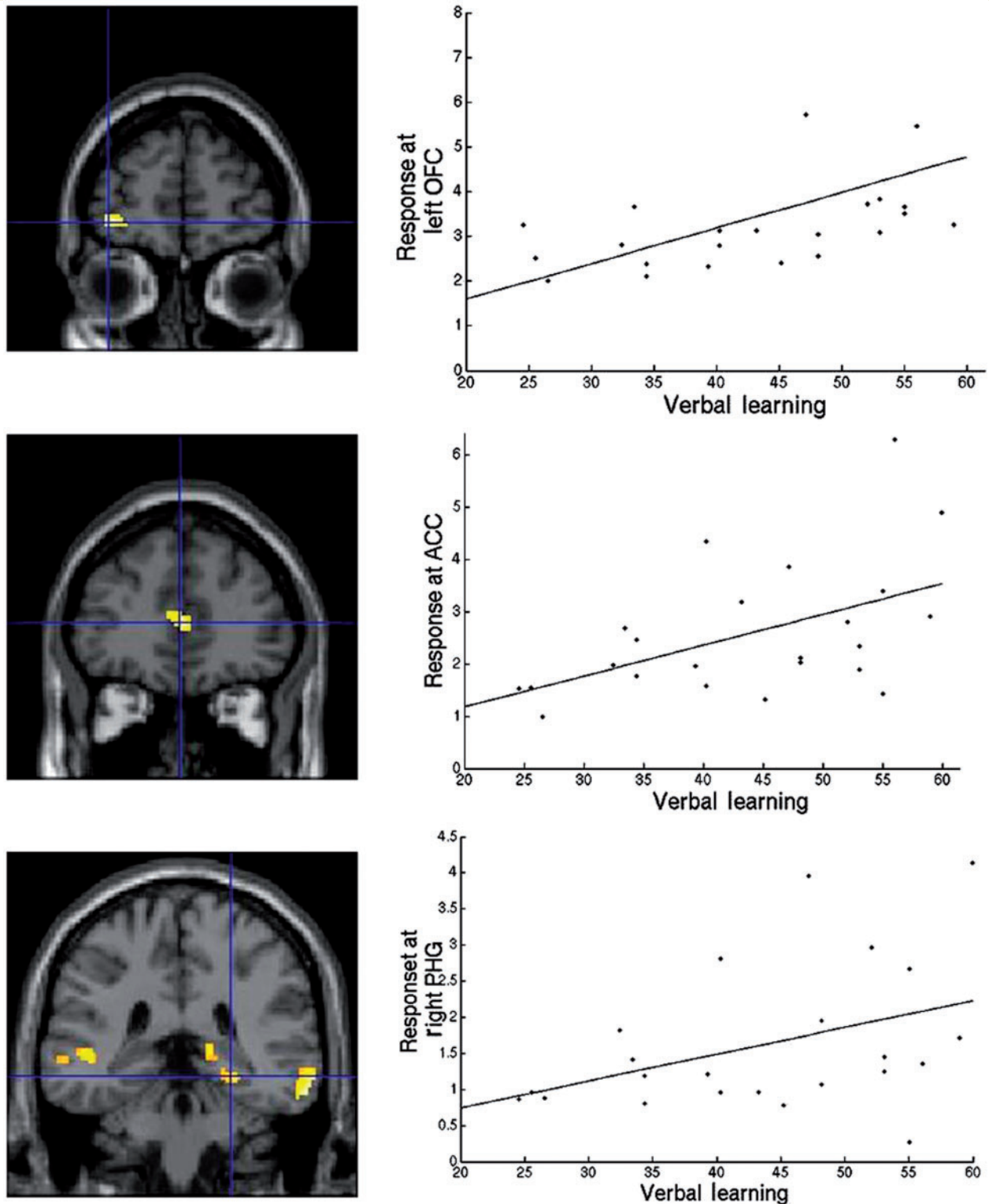


Figure 5 Positive correlation of verbal subsequent memory activations with verbal learning in patients with left hippocampal sclerosis. Correlation maps are shown on a coronal image with their corresponding dot plot graphs plotted on SPMS8 shown on the *right*. Medial temporal lobe activations are displayed at a threshold of $P < 0.01$, uncorrected. The top row shows correlations with left orbitofrontal cortex activation (OFC), middle row, activations within the anterior cingulate cortex (ACC) and bottom row, activation correlation within the right posterior parahippocampal gyrus (PHG). The coronal image on the bottom row also shows activations within the right and left middle temporal gyri and right posterior hippocampus that correlate positively with verbal learning in patients with left hippocampal sclerosis.

Table 7 Coordinates, P-values and z-scores of whole brain visual subsequent memory activations in control subjects, patients with left hippocampal sclerosis and patients with right hippocampal sclerosis

Faces: remembered – familiar forgotten							
Left hemisphere				Right hemisphere			
Region	Coordinate	P-value	Z-score	Region	Coordinate	P-value	Z-score
Controls							
Temporal pole	–34 16 –34	0.000	3.46	Mid temporal G	58 0 –24	0.001	3.52
Mid temporal G	–54 4 –22	0.001	3.09	OFC	34 36 –9	0.000	3.34
PHG	–24 2 –36	0.024*	3.06	Amygdala	20 –2 –20	0.015*	3.15
PHG	–20 –2 –32	0.025*	2.95	Fusiform G	32 –2 –46	0.001	3.15
				Hippocampus	34 –14 –18	0.046*	2.70
				Inf temporal G	42 –6 –32	0.001	3.04
LHS							
Insula / Sup temporal G	–44 –18 8	0.000	4.43	PHG/amygdala	30 4 –32	0.051*	2.53
Sup temporal G	–62 –38 16	0.001	3.11				
Mid temporal G	–60 –22 –4	0.001	3.10				
Ant cingulate C	–4 6 28	0.001	2.98				
RHS							
Insula	–40 –16 22	0.000	3.59	Sup temporal G	60 –32 18	0.001	3.09
Precentral G	–52 –6 50	0.000	3.31	Posterior PHG	32 –38 –12	0.026*	2.83
OFC	–4 62 –2	0.000	3.30	Posterior HC	22 –32 –4	0.044*	2.60
Postcentral G	–60 –16 20	0.001	3.22	Anterior PHG/fusiform G	34 –4 –40	0.055*	2.50

*Family wise error corrections using a small volume correction within a sphere of 6 mm for medial temporal lobe activations. Lt = left; Rt = right; OFC = orbitofrontal cortex; Sup = superior; Mid = middle; Inf = inferior; G = gyrus; C = cortex; Ant = anterior; PHG = parahippocampal gyrus; NS = no significant activations.

memory in control subjects and patients with right hippocampal sclerosis and is activated in verbal subsequent memory in patients with left hippocampal sclerosis with better verbal memory. The orbitofrontal cortex therefore appears to be a critical region for encoding in control subjects and patients. Activations within anterior cingulum and insula correlated with better verbal and visual subsequent memory only in left and right hippocampal sclerosis patients respectively, but not in control subjects.

Memory performance

Both patient groups performed significantly worse than control subjects in the out-of-scanner verbal learning task. In the design learning task however, patients with left hippocampal sclerosis showed no significant difference compared with control subjects. Patients with right hippocampal sclerosis were significantly worse than control subjects and those with left hippocampal sclerosis. In the recognition task within the scanner both patient groups had significantly worse word and face recognition accuracy than control subjects. Both control subjects and patients had significantly lower face recognition than word recognition accuracy. This is possibly due to the fact that memorizing words that are familiar and are associated with semantic inferences is an 'easier' task than memorizing unfamiliar faces.

Both patient groups were impaired across both visual and verbal domains in line with current evidence suggesting a shift away from the material-specific model of memory deficits in temporal lobe epilepsy (Baxendale, 1998; Gleissner *et al.*, 2002; Glikmann-Johnston *et al.*, 2008; Saling, 2009). Both widespread

physiological dysfunction due to ongoing seizure activity (Hermann *et al.*, 2006) and extensive structural deficits beyond the lesional temporal lobe (Focke *et al.*, 2008; Keller *et al.*, 2009) have been associated with widespread cognitive deficits seen in patients with temporal lobe epilepsy.

Memory in control subjects

During memory encoding, control subjects showed widespread material-specific frontal, parietal, temporal and occipital activation; left for verbal and right for visual encoding. During subsequent memory analyses although still material-specific, the extra-temporal activations were limited to the left orbitofrontal cortex for verbal subsequent memory and right orbitofrontal cortex and inferior frontal gyrus for visual subsequent memory.

Memory encoding is a complex dynamic process with activations representing a task-specific network (Fletcher and Henson, 2001). Inferior frontal gyrus activations are seen during semantic and phonological elaborations (Otten and Rugg, 2001) with material organization and manipulation mediated within the middle frontal gyrus (Wig *et al.*, 2004). A fronto-parietal interaction between the premotor cortex and posterior parietal cortex has been shown to be critical to attention during encoding (Corbetta *et al.*, 2008). The medial temporal lobe has been widely recognized for its key storage function of these memory representations for subsequent recall (Squire *et al.*, 2004).

Robust activations that we showed in control subjects during encoding reflect the global cognitive state during the task and include strategies and stages of memory encoding as described

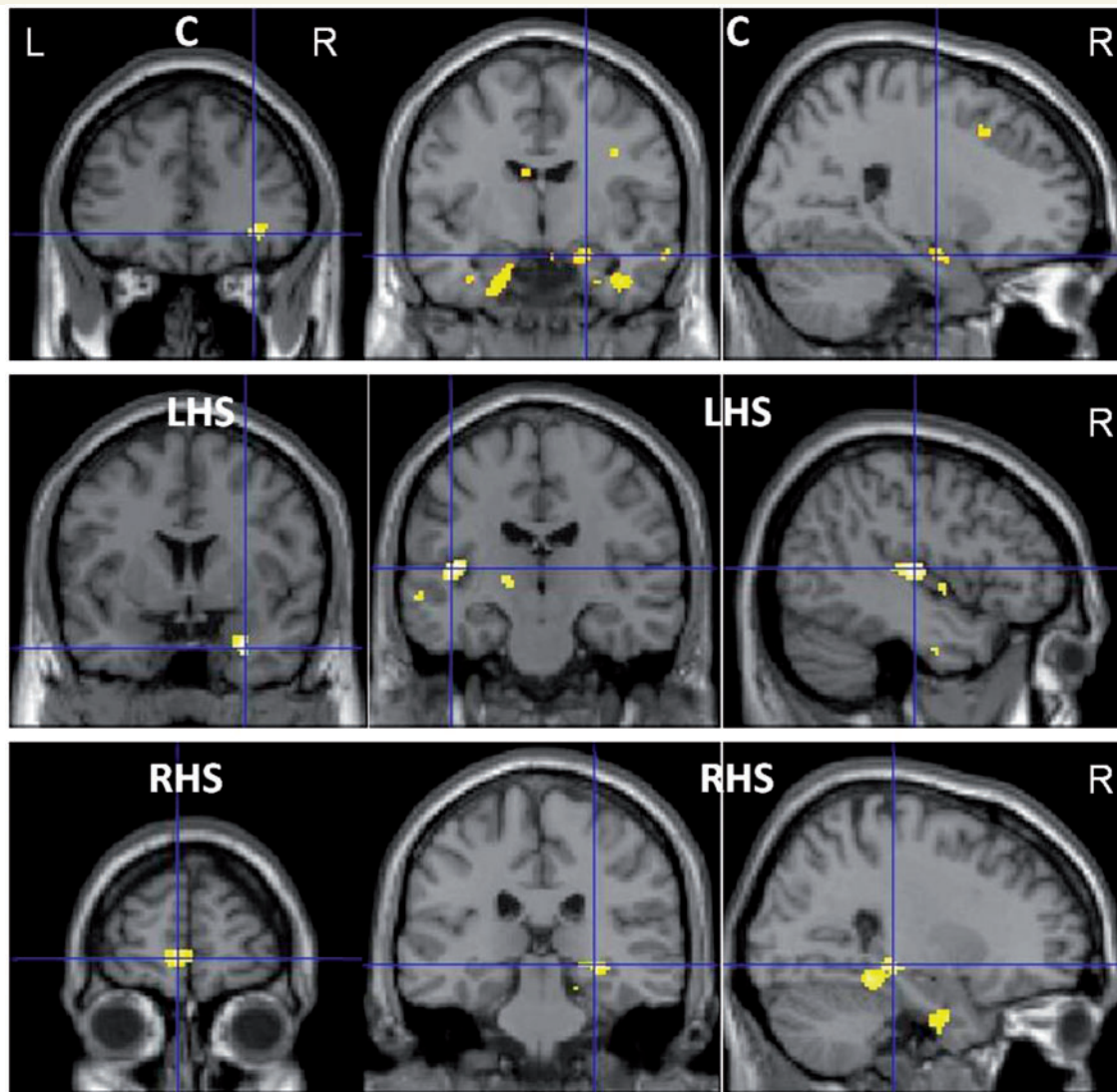


Figure 6 Whole brain visual subsequent memory in control subjects (C), patients with left hippocampal sclerosis (LHS) and patients with right hippocampal sclerosis (RHS). *Top row*: activation in control subjects; *middle row*: patients with left hippocampal sclerosis; and *bottom row*: patients with right hippocampal sclerosis. Medial temporal lobe activations are displayed at a threshold of $P < 0.01$, uncorrected. Control subjects showed visual subsequent memory effects within the right orbitofrontal cortex, right hippocampus and parahippocampal gyri bilaterally. In patients with left hippocampal sclerosis visual subsequent memory effects within the right parahippocampal gyrus and left insula are shown. In patients with right hippocampal sclerosis, visual subsequent memory effects within the left medial orbitofrontal cortex, right posterior hippocampus and parahippocampal gyrus are shown. L = left; R = right.

above. Subsequent memory paradigms, however, are specific to activations that represent successful memory formation and bear some relevance to memory storage function (Hongkeun, 2011). Extra-temporally, we showed that the orbitofrontal cortex was involved in both verbal and visual subsequent memory in control subjects.

The orbitofrontal cortex is well connected to limbic structures including the amygdala, hippocampus, temporal pole, entorhinal, perirhinal and parahippocampal cortices (Insausti *et al.*, 1987; Carmichael and Price, 1995; Lavenex *et al.*, 2002) and may explain its critical role in successful memory formation along with medial temporal lobe structures. A lesional study of the

orbitofrontal cortex in rhesus monkeys revealed impairments in recognition memory similar to that seen after medial temporal lesions (Meunier *et al.*, 1997). In a PET study of a visual memory encoding paradigm, the orbitofrontal cortex and parahippocampal gyrus were the only regions that showed more activity with increasing encoding demands (Frey and Petrides, 2002).

The discrepancy in activation seen during encoding and subsequent memory analyses is due to the task differences explored by the two different analysis methods. Encoding explores the global cognitive task irrespective of whether an item is successfully encoded, whereas subsequent memory paradigms specifically investigate activations for items successfully encoded.

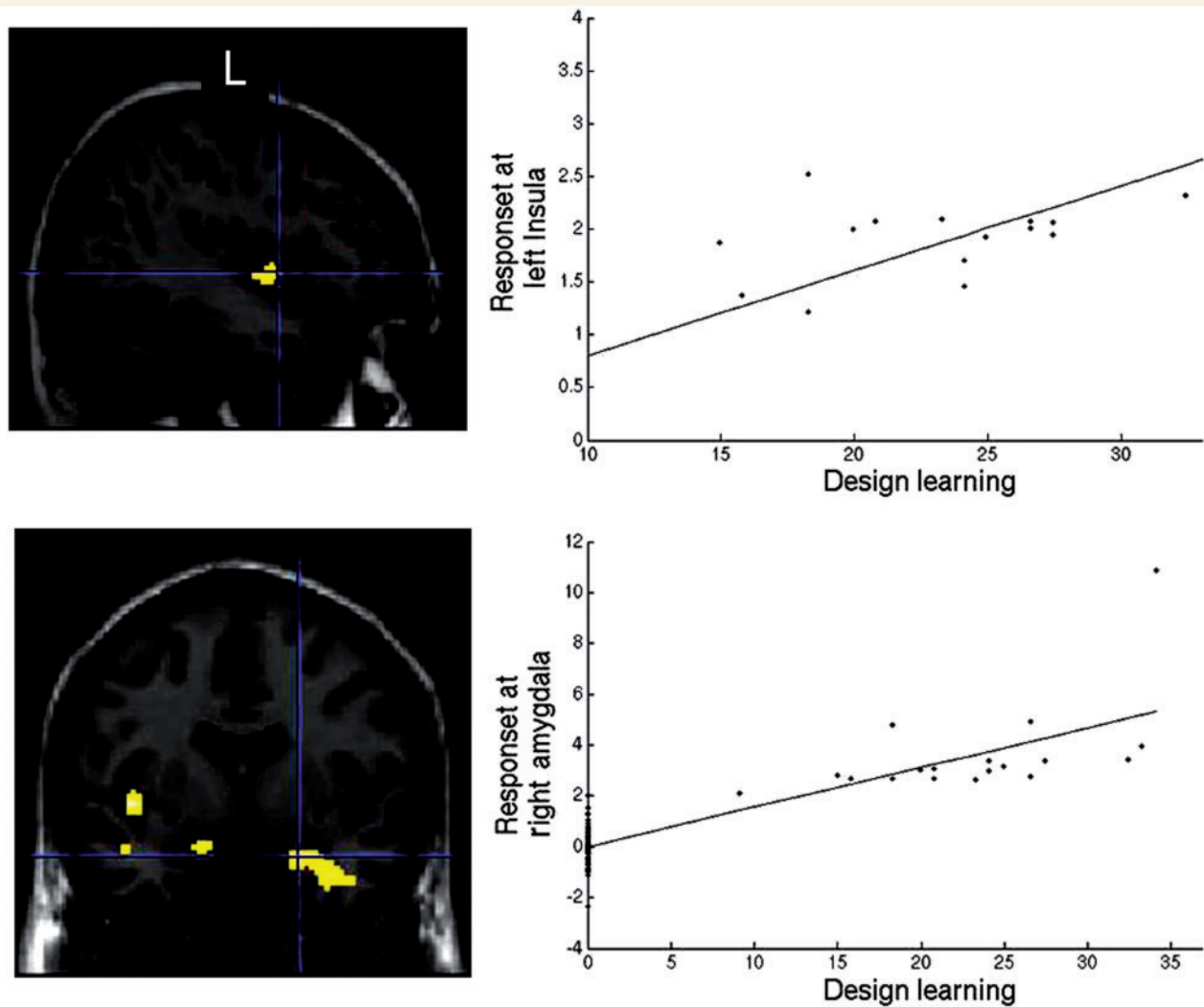


Figure 7 Positive correlations of visual subsequent memory activations with design learning (DL) in patients with right hippocampal sclerosis. Medial temporal lobe activations are displayed at a threshold of $P < 0.01$, uncorrected. Correlation maps are shown on the *left* with corresponding dot plot graphs plotted on SPM8 on the *right*. The *top* row shows correlation with left insula activation and bottom row shows right amygdala and anterior parahippocampal gyrus (PHG) correlation with design learning scores in patients with right hippocampal sclerosis. The bottom image also shows activation in the left amygdala that correlate positively with design learning scores in patients with right hippocampal sclerosis.

Memory encoding in temporal lobe epilepsy

Verbal memory encoding

Reorganization of memory function to the contralesional hemisphere in patients with temporal lobe epilepsy has been consistently described particularly within the medial temporal lobe (Richardson *et al.*, 2003; Powell *et al.*, 2007; Bonelli *et al.*, 2010). This process is thought to occur as a 'compensatory' effort in patients with temporal lobe epilepsy who have been shown to have widespread physiological and structural deficits. Both left hippocampal sclerosis and right hippocampal sclerosis patients showed increased recruitment of the right superior temporal gyrus compared with control subjects. Extra-temporally,

patients with left hippocampal sclerosis showed significantly greater right inferior frontal gyrus and middle frontal gyrus activations whereas patients with right hippocampal sclerosis showed bilateral middle frontal gyrus increases.

A few other studies have reported extra-temporal activations during verbal memory tasks in patients with both left and right temporal lobe epilepsy, but these have been small (Dupont *et al.*, 2000, 2002; Maccotta *et al.*, 2007; Alessio *et al.*, 2013). In a heterogeneous group of patients with right and left temporal lobe epilepsy, Maccotta *et al.* (2007) showed reorganization to the right inferior frontal gyrus in both patient groups, left temporal lobe epilepsy greater than right temporal lobe epilepsy, compared with control subjects. As activations were explored within a limited inferior frontal gyrus region it is not known if there were differences in other frontal lobe regions (Maccotta *et al.*, 2007).

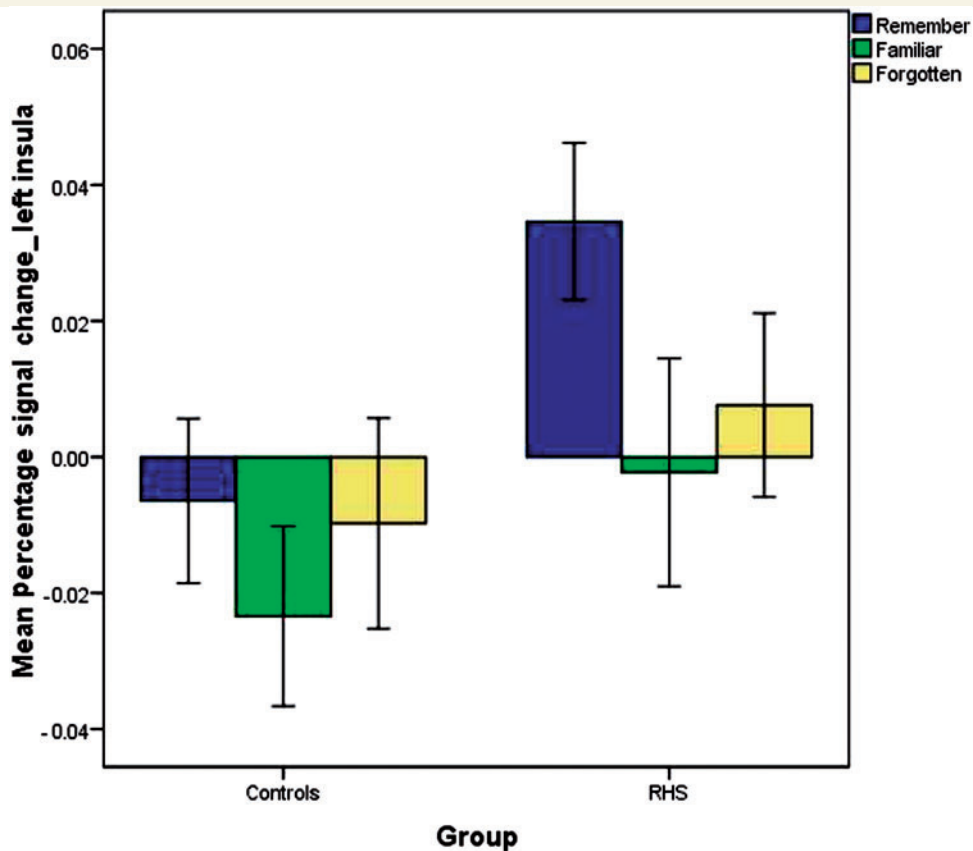


Figure 8 Mean percentage signal change and standard error (SEM) at the left insula for faces remembered, familiar and forgotten in patients with right hippocampal sclerosis (RHS) and control subjects.

Dupont *et al.* (2002) showed increased bilateral with right more than left middle frontal gyrus activations in patients with left hippocampal sclerosis, whereas those with right hippocampal sclerosis only showed increased left middle frontal gyrus activations. In this study control subjects only activated the left inferior frontal gyrus (Dupont *et al.*, 2002). In contrast, Alessio *et al.* (2013) showed no difference in middle frontal gyrus activations in patients with left hippocampal sclerosis compared with control subjects during a similar word encoding task, but both left hippocampal sclerosis and right hippocampal sclerosis patients showed bilateral inferior frontal gyrus activations that were lateralized to the contralesional hemisphere; activations that was not seen in control subjects (Alessio *et al.*, 2013). Areas of reorganization described in the latter two studies were reported qualitatively based on group activation maps, therefore it is not known if inter-group differences were statistically significant.

Visual memory encoding

Patients with left hippocampal sclerosis showed both temporal and extra-temporal reorganization compared with those with right hippocampal sclerosis, who only showed temporal reorganization during face encoding. Although we described reduced medial orbitofrontal cortex and ipsilesional medial temporal lobe activations in both patient groups compared with control subjects, patients with

left hippocampal sclerosis showed greater network dysfunction compared to those with right hippocampal sclerosis with additional regions of reduced extra-temporal activation both ipsilesionally (left inferior frontal gyrus and orbitofrontal cortex) and contralesionally (right post-central gyrus) positing an explanation for the more widespread reorganization seen in patients with left hippocampal sclerosis.

Few studies have investigated the extra-temporal neural correlates of visual encoding (Maccotta *et al.*, 2007; Alessio *et al.*, 2013). In an abstract pattern encoding task, Alessio *et al.* (2013) reported right frontal activations in control subjects and bilateral frontal activations within the superior frontal gyrus and inferior frontal gyrus in patients with right hippocampal sclerosis and with left hippocampal sclerosis. All three groups showed bilateral parieto-occipital activations. Group differences, however, were only reported qualitatively (Alessio *et al.*, 2013).

Maccotta *et al.* (2007) reported right lateralized frontal activations in control subjects and patients with right and left temporal lobe epilepsy in a visual encoding task. Although patients performed significantly worse than control subjects in a subsequent recognition test, no differences in the visual encoding network were seen between control subjects and patient groups. In this study, group differences were only explored within a limited inferior frontal gyrus region of interest and an implicit encoding task

Table 8 Summary of verbal memory findings in patients with left hippocampal sclerosis and patients with right hippocampal sclerosis patients

Summary of verbal memory findings in patients with left hippocampal sclerosis		
Word encoding (blocked analysis) LHS > Controls	Verbal subsequent memory (event-related analysis)	Positive correlation of verbal subsequent memory with verbal learning scores
Rt Superior Temporal G Rt Inferior Frontal G Rt Middle Frontal G	Rt posterior PHG and Hippocampus Rt Inferior Temporal G Rt Fusiform G Lt Inferior Temporal G	Rt Mid Temporal G Lt Mid Temporal G Lt Orbitofrontal Cortex Anterior Cingulate Cortex Rt posterior PHG Rt posterior Hippocampus Lt posterior Hippocampus
Summary of verbal memory findings in patients with right hippocampal sclerosis		
Word encoding RHS > Controls	Verbal subsequent memory	Positive correlation of verbal subsequent memory with verbal learning scores
Rt Superior Temporal G Rt Middle Frontal G Lt Middle Frontal G	Lt Precentral G Lt Parahippocampal G Lt Temporal pole Lt Orbitofrontal Cortex Lt Inferior Frontal G Rt Temporal pole Rt Insula Rt Precentral G Rt Parahippocampal G	Lt Hippocampus Lt anterior Parahippocampal G Rt posterior PHG and Hippocampus Rt anterior PHG and Amygdala

Lt = left; Rt = right; G = gyrus; C = cortex; PHG = parahippocampal gyrus; RHS = right hippocampal sclerosis; LHS = left hippocampal sclerosis.

Table 9 Summary of visual memory findings in patients with left hippocampal sclerosis and patients with right hippocampal sclerosis

Summary of Visual Memory Findings in patients with left hippocampal sclerosis		
Face encoding (blocked analysis) LHS > Controls	Visual subsequent memory (event related analysis)	Positive correlation of visual subsequent memory with design learning scores
Rt Superior Temporal G Rt Inferior Frontal G Rt Supramarginal G	Rt Anterior PHG and amygdala Lt Insula Lt Superior Temporal G Lt Middle Temporal G Lt Anterior Cingulate Cortex	No significant correlation seen
Summary of visual memory findings in patients with right hippocampal sclerosis		
Face encoding RHS > controls	Visual subsequent memory	Positive correlation of visual subsequent memory with design learning scores
Rt Superior Temporal G (posterior) Lt Superior Temporal G	Rt Superior Temporal G (anterior) Rt Posterior PHG and hippocampus Rt anterior Parahippocampal G Rt Fusiform G Lt Insula Lt Precentral G Lt Orbitofrontal Cortex Lt Postcentral G	Rt anterior PHG and Amygdala Lt Amygdala Lt Insula

Lt = left; Rt = right; G = gyrus; PHG = parahippocampal gyrus.

in which memorization was not encouraged was performed (Maccotta *et al.*, 2007). Greater inferior frontal gyrus activation has been shown in explicit paradigms in which memorization is encouraged (Dove *et al.*, 2006). These factors may explain the lack of network differences reported.

During verbal and visual encoding, we showed extra-temporal contralesional reorganization in patients with left hippocampal sclerosis. Patients with right hippocampal sclerosis, in contrast, showed increased extra-temporal reorganization bilaterally at word encoding but reorganization was limited to the temporal lobe for face encoding.

Subsequent memory: event related analysis

Activations in the event-related design represent activations associated with successful memory formation in control subjects and patients. Though a less efficient network than control subjects (as patients perform significantly worse than control subjects across both tasks), activations in this specific paradigm represent a 'necessary' network for patients for subsequent memory formation. These activations were further correlated with neuropsychological memory performance measures. Activations that correlated positively represent areas of effective recruitment in patients who performed better.

Verbal subsequent memory and correlation with verbal learning performance

Control subjects showed predominantly left hemisphere verbal subsequent memory activations. As most control subjects performed uniformly well, no positive correlation with verbal learning was seen. Negative correlation was seen with activation within the posterior cingulate, a region that is typically activated as part of the default mode network (Raichle *et al.*, 2001), implying that poor performance in control subjects is likely to be due to distraction or reduced attention during the task.

During verbal subsequent memory, patients with left hippocampal sclerosis as a group showed predominantly right temporal activations with no extra-temporal activations; however, in patients with left hippocampal sclerosis who performed better, positive correlation was seen with additional activations temporally within the ipsilesional posterior hippocampus and extra-temporally within the left orbitofrontal cortex and anterior cingulate cortex implying areas of effective recruitment in this patient group.

By contrast, patients with right hippocampal sclerosis showed bilateral temporal and extra-temporal verbal subsequent memory activations. Patients with right hippocampal sclerosis who performed better showed positive correlation with activation within the anterior medial temporal lobes bilaterally and right posterior medial temporal lobe implying effective recruitment of these regions for verbal memory performance.

In both our patient groups recruitment of the ipsilesional posterior hippocampus and bilateral medial temporal lobe was an efficient process for verbal subsequent memory.

Visual subsequent memory and correlation with design learning performance

Predominantly right extra-temporal activations were seen in control subjects for visual subsequent memory. As in verbal learning, no positive correlation was seen in control subjects with design learning and negative correlation was seen with activation within the default mode system.

In contrast to bilateral extra-temporal activations for verbal subsequent memory, patients with right hippocampal sclerosis showed mainly left extra-temporal visual subsequent memory activations (left insula, orbitofrontal cortex, left precentral and postcentral gyri). Patients with right hippocampal sclerosis showed widespread areas of reduced right extra-temporal activations compared with control subjects during face encoding, which may explain the 'compensatory' left extra-temporal recruitment in these patients during visual subsequent memory. Patients with right hippocampal sclerosis as a group showed visual subsequent memory activations within the right temporal lobe (parahippocampal gyrus, amygdala and posterior hippocampus), however, patients who performed better showed positive correlation with design learning scores with activations within the left amygdala in addition to right amygdala and left insula activations. Left amygdala and insula activation was not seen in control subjects and represent areas of efficient recruitment in patients with right hippocampal sclerosis for visual memory.

Patients with left hippocampal sclerosis showed right medial temporal lobe activations for visual subsequent memory as in verbal subsequent memory, but also showed significant extra-temporal visual subsequent memory activations within the left insula and anterior cingulate cortex that were not seen for verbal subsequent memory. No correlation with design learning was seen in patients with left hippocampal sclerosis possibly because these patients did not perform significantly worse than control subjects on the design learning task.

Medial temporal subsequent memory effects

In both patient groups, bilateral medial temporal lobe activation correlated positively with verbal and visual memory performance implying efficient network reorganization within these structures. Several verbal (Richardson *et al.*, 2003) and visual (Guedj *et al.*, 2011) event-related studies have shown subsequent memory effects and correlations within the medial temporal lobe in patients with left and right temporal lobe epilepsy (Powell *et al.*, 2007; Bonelli *et al.*, 2010). Richardson *et al.* (2003) showed that activation within the right medial temporal lobe in patients with left hippocampal sclerosis was an efficient process during verbal subsequent memory (Richardson *et al.*, 2003). Powell *et al.* (2007), however, showed that only left medial temporal lobe activations during verbal subsequent memory correlated with better memory performance. Bonelli *et al.* (2010) and Powell *et al.* (2007) showed that only right medial temporal lobe activation represented efficient reorganization in a face encoding task; however,

Guedj *et al.* (2011) showed that bilateral medial temporal lobe activation represented an efficient network.

To assess subsequent memory, we used a robust paradigm of ‘remember – familiar + forgotten’ whereas a paradigm of ‘remember – forgotten’ was used by Powell *et al.* (2007) and Bonelli *et al.* (2010), ‘remember – familiar’ by Richardson *et al.* (2003) and ‘remember’ by Guedj *et al.* (2011). Powell *et al.* (2007) acquired functional MRI data on a 1.5T scanner, Richardson *et al.* (2003) on a 2T scanner whereas we used a 3T scanner. These methodological differences as well as the differences in number of patients and pathology may account for the differences seen.

Extra-temporal subsequent memory effects

Both patient groups did not activate the ipsilesional orbitofrontal cortex as control subjects did. In an electrical stimulation study, responses in the orbitofrontal cortex were detected upon stimulation of the hippocampus positing a role of the orbitofrontal cortex in propagation of medial temporal lobe seizures (Wilson and Engel, 1993). The lesser activation we observed in patients may therefore be a result of either network dysfunction caused by propagation of epileptic activity, be due to concomitant frontal structural deficits (Bonilha *et al.*, 2007), or both.

The importance of the orbitofrontal cortex to successful verbal memory formation was demonstrated in patients with left hippocampal sclerosis where only those with a better verbal memory showed significant positive correlation with activation within the left orbitofrontal cortex. In a verbal encoding study, healthy participants who spontaneously used a semantic strategy to memorize items showed greater activation in the orbitofrontal cortex, indicating that orbitofrontal cortex activation predicted which subjects would initiate effective verbal learning strategies (Savage *et al.*, 2001). In patients with left hippocampal sclerosis who perform better, left orbitofrontal cortex activation may reflect the effective strategies employed. The left orbitofrontal cortex was also seen in patients with right hippocampal sclerosis during both verbal and visual subsequent memory analyses.

In a verbal subsequent memory study of non-amnesic temporal and frontal lobe epilepsy patients, activation within the right insula, left cuneus and bilateral anterior cingulate cortex was reported to be an efficient network (Eliassen *et al.*, 2008). Using correlation analysis in a larger homogenous group of patients with left hippocampal sclerosis we showed that anterior cingulate cortex activation similarly represents effective recruitment for verbal subsequent memory in these patients but not in control subjects. Anterior cingulate cortex activation has been shown to be related to motivation, goal directed behaviour (Devinsky *et al.*, 1995) and is activated particularly in tasks with greater difficulty (Fu *et al.*, 2002). This may explain anterior cingulate activation in patients with left hippocampal sclerosis who performed better.

Left insula visual subsequent memory activations were seen in both left and right hippocampal sclerosis but not in control subjects. The insula has been functionally implicated in higher order cognition and emotional recognition from facial expression (Calder

et al., 2000; Singer *et al.*, 2004) and atrophy in the insula has been associated with a reduced ability to discern facial expression in patients with dementia (Hsieh *et al.*, 2012). Encoding emotional faces has been shown to be associated with better subsequent recognition memory (Nomi *et al.*, 2013). In patients with right hippocampal sclerosis, insula activation was associated with better visual memory implying efficient recruitment. This may be attributed to better emotional recognition in patients who performed better.

Study strengths and limitations

Our study has several methodological strengths. Activations within the medial temporal lobe are susceptible to geometric distortions and signal loss. Factors that influence this include scanning parameters such as slice thickness, echo time and gradients used (Powell *et al.*, 2005). In whole brain blocked design studies, no medial temporal lobe activations were seen during memory encoding (Dupont *et al.*, 2000; Alessio *et al.*, 2013). We scanned in the oblique axial plane on a 3T scanner with a slice thickness of 2.5 mm, echo time of 25 ms and showed robust anterior hippocampus and amygdala activations in both the blocked design and event-related analysis.

Second, we included a relatively large homogeneous cohort of patients with hippocampal sclerosis who were all left-language dominant to ensure that there was no inherent bias to contralateral activations during the verbal encoding task.

Third, during memory encoding, activations within the prefrontal cortex, medial temporal lobe and parietal lobe have been described with familiarity judgements (Skinner and Fernandes, 2007). We therefore assessed successful memory formation by subtracting activations that represented neural correlates of not just items forgotten, but also items deemed familiar, to generate a more specific model of successful subsequent memory.

Fourth, we applied robust analysis methods and used conservative statistical thresholds that allow inferences to be made about patients with hippocampal sclerosis as a population.

There are several limitations to our study. For an event-related analysis it is important that there are adequate stimuli to create events for items remembered and those deemed familiar and forgotten. In control subjects and higher functioning patients there can be relatively fewer familiar or forgotten responses particularly for words so in our study we incorporated a greater number of stimuli than previously used (Powell *et al.*, 2007). Although this has conferred greater sensitivity to our event-related analysis, this imbalance remains a methodological limitation.

Although we attempted maximal brain coverage, our field of view did not incorporate the whole of the superior frontal gyrus. Anti-epileptic drugs may have a detrimental effect on cognition. Although both patient groups were on equal numbers of antiepileptic drugs, this effect was not accounted for in our analysis.

Clinical implications and future work

In well selected patients with refractory temporal lobe epilepsy, temporal lobe resection may render up to 50% of patients seizure-free in the long term (de Tisi *et al.*, 2011); however, reports

have shown that amnesia may ensue from unilateral temporal lobe resection (Penfield and Milner, 1958; Kapur and Preveet, 2003). Functional MRI is a useful tool in predicting decline of memory after anterior temporal lobe resection. Asymmetry of medial temporal lobe activations and absolute hippocampal activations preoperatively have been correlated with memory performance postoperatively to predict memory change (Richardson *et al.*, 2003; Rabin *et al.*, 2004; Powell *et al.*, 2008; Bonelli *et al.*, 2010). Although these studies describe correlations of postoperative memory decline to preoperative medial temporal lobe activations, little is known of the predictive value of preoperative extra-temporal activations for postoperative memory change.

We are investigating the predictive ability of the extra-temporal activations shown in this study to memory function postoperatively.

Conclusion

Both right and left temporal lobe epilepsy owing to hippocampal sclerosis have altered memory networks with a predominantly ipsilesional hemisphere reduction in activations during encoding. Patients with left hippocampal sclerosis engaged contralateral extra-temporal and temporal regions during both word and face encoding greater than control subjects, whereas those with right hippocampal sclerosis show bilateral extra-temporal increases during word encoding and only temporal increases during face encoding. These areas of reorganization in patients with left hippocampal sclerosis and those with right hippocampal sclerosis were not involved in subsequent memory formation. The neural correlates of subsequent memory formation differed between control subjects and patients with hippocampal sclerosis. Both left and right hippocampal sclerosis patients who performed better showed effective recruitment of the contralesional medial temporal lobe during verbal and visual encoding, respectively. The orbitofrontal cortex is critical to subsequent memory formation in control subjects and patients. Activations within anterior cingulum and insula correlated with better verbal and visual subsequent memory in patients with left and right hippocampal sclerosis, respectively, representing areas of effective extra-temporal recruitment.

Acknowledgements

We are grateful to Professor Karl Friston for methodological input and discussions. We thank the radiographers at the Epilepsy Society MRI Unit, Philippa Bartlett, Jane Burdett and Elaine Williams for their help and all our patients and control subjects for their participation in this study.

Funding

This work was supported by The Wellcome Trust (programme grant no 083148). The Wolfson Trust and the Epilepsy Society support the Epilepsy Society MRI scanner. This work was undertaken at UCLH/UCL who received a proportion of funding from the Department of Health's NIHR Biomedical Research Centres funding scheme.

References

- Alessio A, Pereira FRS, Sercheli MS, Rondina JM, Ozelo HB, Bilevicius E, et al. Brain plasticity for verbal and visual memories in patients with mesial temporal lobe epilepsy and hippocampal sclerosis: an fMRI study. *Hum Brain Mapp* 2013; 34: 186–99.
- Baxendale S. Amnesia in temporal lobectomy patients: historical perspective and review. *Seizure* 1998; 7: 15–24.
- Baxendale S, Thompson P, Harkness W, Duncan J. Predicting memory decline following epilepsy surgery: a multivariate approach. *Epilepsia* 2006; 47: 1887–94.
- Bonelli SB, Powell RH, Yogarajah M, Samson RS, Symms MR, Thompson PJ, et al. Imaging memory in temporal lobe epilepsy: predicting the effects of temporal lobe resection. *Brain* 2010; 133: 1186–99.
- Bonilha L, Alessio A, Rorden C, Baylis G, Damasceno BP, Min LL, et al. Extrahippocampal gray matter atrophy and memory impairment in patients with medial temporal lobe epilepsy. *Hum Brain Mapp* 2007; 28: 1376–90.
- Brett M, Anton JL, Valabregue R, Poline JB. Region of interest analysis using an SPM toolbox [abstract]. Presented at the 8th International Conference on Functional Mapping of the Human Brain, June 2–6, 2002, Sendai, Japan, 2002; Available from CD-ROM in NeuroImage, Vol 16.
- Calder AJ, Keane J, Manes F, Antoun N, Young AW. Impaired recognition and experience of disgust following brain injury. *Nat Neurosci* 2000; 3: 1077–8.
- Carmichael ST, Price JL. Limbic connections of the orbital and medial prefrontal cortex in macaque monkeys. *J Comp Neurol* 1995; 363: 615–41.
- Corbetta M, Patel G, Shulman GL. The reorienting system of the human brain: from environment to theory of mind. *Neuron* 2008; 58: 306–24.
- Coughlan AK, Oddy M, Crawford AR. BIRT memory and information processing battery (BMIPB). London: Brain Injury Rehabilitation Trust; 2007.
- Craik FI. Levels of processing: past, present and future? *Memory* 2002; 10: 305–18.
- de Tisi J, Bell GS, Peacock JL, McEvoy AW, Harkness WF, Sander JW, et al. The long-term outcome of adult epilepsy surgery, patterns of seizure remission, and relapse: a cohort study. *Lancet* 2011; 378: 1388–95.
- Devinsky O, Morrell MJ, Vogt BA. Contributions of anterior cingulate cortex to behaviour. *Brain* 1995; 118: 279–306.
- Dove A, Brett M, Cusack R, Owen AM. Dissociable contributions of the mid-ventrolateral frontal cortex and the medial temporal lobe system to human memory. *Neuroimage* 2006; 31: 1790–1801.
- Dupont S, Samson Y, Van de Moortele PF, Samson S, Poline JB, Hasboun D, et al. Bilateral hemispheric alteration of memory processes in right medial temporal lobe epilepsy. *J Neurol Neurosurg Psychiatry* 2002; 73: 478–85.
- Dupont S, Van de Moortele PF, Samson S, Hasboun D, Poline JB, Adam C, et al. Episodic memory in left temporal lobe epilepsy: a functional MRI study. *Brain* 2000; 123 (Pt 8): 1722–32.
- Elger CE, Helmstaedter C, Kurthen M. Chronic epilepsy and cognition. *Lancet Neurol* 2004; 3: 663–72.
- Eliassen JC, Holland SK, Szaflarski JP. Compensatory brain activation for recognition memory in patients with medication-resistant epilepsy. *Epilepsy Behav* 2008; 13: 463–9.
- Fletcher PC, Henson RN. Frontal lobes and human memory: insights from functional neuroimaging. *Brain* 2001; 124: 849–81.
- Focke NK, Yogarajah M, Bonelli SB, Bartlett PA, Symms MR, Duncan JS. Voxel-based diffusion tensor imaging in patients with mesial temporal lobe epilepsy and hippocampal sclerosis. *Neuroimage* 2008; 40: 728–37.
- Frey S, Petrides M. Orbitofrontal cortex and memory formation. *Neuron* 2002; 36: 171–6.

- Fu CH, Morgan K, Suckling J, Williams SC, Andrew C, Vythelingum GN, et al. A functional magnetic resonance imaging study of overt letter verbal fluency using a clustered acquisition sequence: greater anterior cingulate activation with increased task demand. *Neuroimage* 2002; 17: 871–9.
- Gleissner U, Helmstaedter C, Schramm J, Elger CE. Memory outcome after selective amygdalohippocampectomy: a study in 140 patients with temporal lobe epilepsy. *Epilepsia* 2002; 43: 87–95.
- Glikmann-Johnston Y, Saling MM, Chen J, Cooper KA, Beare RJ, Reutens DC. Structural and functional correlates of unilateral mesial temporal lobe spatial memory impairment. *Brain* 2008; 131: 3006–18.
- Golby AJ, Poldrack RA, Illes J, Chen D, Desmond JE, Gabrieli JD. Memory lateralization in medial temporal lobe epilepsy assessed by functional MRI. *Epilepsia* 2002; 43: 855–63.
- Guedj E, Bettus G, Barbeau EJ, Liégeois-Chauvel C, Confort-Gouny S, Bartolomei F, et al. Hyperactivation of parahippocampal region and fusiform gyrus associated with successful encoding in medial temporal lobe epilepsy. *Epilepsia* 2011; 52: 1100–1109.
- Helmstaedter C, Kurthen M, Lux S, Reuber M, Elger CE. Chronic epilepsy and cognition: a longitudinal study in temporal lobe epilepsy. *Ann Neurol* 2003; 54: 425–32.
- Hermann BP, Seidenberg M, Dow C, Jones J, Rutecki P, Bhattacharya A, et al. Cognitive prognosis in chronic temporal lobe epilepsy. *Ann Neurol* 2006; 60: 80–7.
- Hongkeun K. Neural activity that predicts subsequent memory and forgetting: a meta-analysis of 74 fMRI studies. *Neuroimage* 2011; 54: 2446–61.
- Hsieh S, Hornberger M, Piguet O, Hodges JR. Brain correlates of musical and facial emotion recognition: evidence from the dementias. *Neuropsychologia* 2012; 50: 1814–22.
- Insausti R, Amaral DG, Cowan WM. The entorhinal cortex of the monkey. III. Subcortical afferents. *J Comp Neurol* 1987; 264: 396–408.
- Kapur N, Preveit M. Unexpected amnesia: are there lessons to be learned from cases of amnesia following unilateral temporal lobe surgery? *Brain* 2003; 126: 2573–85.
- Keller SS, Baker G, Downes JJ, Roberts N. Quantitative MRI of the prefrontal cortex and executive function in patients with temporal lobe epilepsy. *Epilepsy Behav* 2009; 15: 186–95.
- Kelley WM, Miezin FM, McDermott KB, Buckner RL, Raichle ME, Cohen NJ, et al. Hemispheric specialization in human dorsal frontal cortex and medial temporal lobe for verbal and nonverbal memory encoding. *Neuron* 1998; 20: 927–36.
- Lavenex P, Suzuki WA, Amaral DG. Perirhinal and parahippocampal cortices of the macaque monkey: projections to the neocortex. *J Comp Neurol* 2002; 447: 394–420.
- Maccotta L, Buckner RL, Gilliam FG, Ojemann JG. Changing frontal contributions to memory before and after medial temporal lobectomy. *Cereb Cortex* 2007; 17: 443–56.
- Mechelli A, Henson RN, Price CJ, Friston KJ. Comparing event-related and epoch analysis in blocked design fMRI. *Neuroimage* 2003; 18: 806–10.
- Meunier M, Bachevalier J, Mishkin M. Effects of orbital frontal and anterior cingulate lesions on object and spatial memory in rhesus monkeys. *Neuropsychologia* 1997; 35: 999–1015.
- Nelson HE, O'Connell A. Dementia: the estimation of premorbid intelligence levels using the New Adult Reading Test. *Cortex* 1978; 14: 234–44.
- Nomi JS, Rhodes MG, Cleary AM. Emotional facial expressions differentially influence predictions and performance for face recognition. *Cogn Emot* 2013; 27: 141–9.
- Oldfield RC. The assessment and analysis of handedness: the Edinburgh inventory. *Neuropsychologia* 1971; 9: 97–113.
- Otten LJ, Rugg MD. Task-dependency of the neural correlates of episodic encoding as measured by fMRI. *Cereb Cortex* 2001; 11: 1150–60.
- Penfield W, Milner B. Memory deficit produced by bilateral lesions in the hippocampal zone. *AMA Arch Neurol Psychiatry* 1958; 79: 475–97.
- Powell HW, Koepp MJ, Symms MR, Boulby PA, Salek-Haddadi A, Thompson PJ, et al. Material-specific lateralization of memory encoding in the medial temporal lobe: blocked versus event-related design. *Neuroimage* 2005; 27: 231–9.
- Powell HW, Parker GJ, Alexander DC, Symms MR, Boulby PA, Wheeler-Kingshott CA, et al. Hemispheric asymmetries in language-related pathways: a combined functional MRI and tractography study. *Neuroimage* 2006; 32: 388–99.
- Powell HW, Richardson MP, Symms MR, Boulby PA, Thompson PJ, Duncan JS, et al. Reorganization of verbal and nonverbal memory in temporal lobe epilepsy due to unilateral hippocampal sclerosis. *Epilepsia* 2007; 48: 1512–25.
- Powell HW, Richardson MP, Symms MR, Boulby PA, Thompson PJ, Duncan JS, et al. Preoperative fMRI predicts memory decline following anterior temporal lobe resection. *J Neurol Neurosurg Psychiatry* 2008; 79: 686–93.
- Rabin ML, Narayan VM, Kimberg DY, Casasanto DJ, Glosser G, Tracy JJ, et al. Functional MRI predicts post-surgical memory following temporal lobectomy. *Brain* 2004; 127: 2286–98.
- Raichle ME, MacLeod AM, Snyder AZ, Powers WJ, Gusnard DA, Shulman GL. A default mode of brain function. *Proc Natl Acad Sci USA* 2001; 98: 676–82.
- Richardson MP, Strange BA, Duncan JS, Dolan RJ. Preserved verbal memory function in left medial temporal pathology involves reorganization of function to right medial temporal lobe. *Neuroimage* 2003; 20 (Suppl. 1): S112–9.
- Richardson MP, Strange BA, Duncan JS, Dolan RJ. Memory fMRI in left hippocampal sclerosis: optimizing the approach to predicting postsurgical memory. *Neurology* 2006; 66: 699–705.
- Saling MM. Verbal memory in mesial temporal lobe epilepsy: beyond material specificity. *Brain* 2009; 132: 570–82.
- Savage CR, Deckersbach T, Heckers S, Wagner AD, Schacter DL, Alpert NM, et al. Prefrontal regions supporting spontaneous and directed application of verbal learning strategies: evidence from PET. *Brain* 2001; 124: 219–31.
- Seghier ML, Neufeld NH, Zeidman P, Leff AP, Mechelli A, Nagendran A, et al. Reading without the left ventral occipito-temporal cortex. *Neuropsychologia* 2012; 50: 3621–35.
- Seghier ML, Price CJ. Functional heterogeneity within the default network during semantic processing and speech production. *Front Psychol* 2012; 3: 281.
- Simons JS, Spiers HJ. Prefrontal and medial temporal lobe interactions in long-term memory. *Nat Rev Neurosci* 2003; 4: 637–48.
- Singer T, Seymour B, O'Doherty J, Kaube H, Dolan RJ, Frith CD. Empathy for pain involves the affective but not sensory components of pain. *Science* 2004; 303: 1157–62.
- Skinner EI, Fernandes MA. Neural correlates of recollection and familiarity: a review of neuroimaging and patient data. *Neuropsychologia* 2007; 45: 2163–79.
- Squire LR, Stark CE, Clark RE. The medial temporal lobe. *Annu Rev Neurosci* 2004; 27: 279–306.
- Voets NL, Adcock JE, Stacey R, Hart Y, Carpenter K, Matthews PM, et al. Functional and structural changes in the memory network associated with left temporal lobe epilepsy. *Hum Brain Mapp* 2009; 30: 4070–81.
- Wechsler D, editor. *Manual for the Wechsler Adult Intelligence Scale—III*. San Antonio: The Psychological Corporation; 1997.
- Wig GS, Miller MB, Kingstone A, Kelley WM. Separable routes to human memory formation: dissociating task and material contributions in the prefrontal cortex. *J Cogn Neurosci* 2004; 16: 139–48.
- Wilson CL, Engel J Jr. Electrical stimulation of the human epileptic limbic cortex. *Adv Neurol* 1993; 63: 103–13.
- Woermann FG, McLean MA, Bartlett PA, Parker GJ, Barker GJ, Duncan JS. Short echo time single-voxel 1H magnetic resonance spectroscopy in magnetic resonance imaging-negative temporal lobe epilepsy: different biochemical profile compared with hippocampal sclerosis. *Ann Neurol* 1999; 45: 369–76.