

A Distinct Mitochondrial Myopathy, Lactic Acidosis and Sideroblastic Anemia (MLASA) Phenotype Associates with *YARS2* Mutations

Rojeen Shahni,¹ Yehani Wedatilake,¹ Maureen A. Cleary,² Keith J. Lindley,³ Keith R. Sibson,⁴ and Shamima Rahman^{1,2*}

¹Mitochondrial Research Group, Clinical and Molecular Genetics Unit, UCL Institute of Child Health, London, UK

²Metabolic Unit, Great Ormond Street Hospital, London, UK

³Gastroenterology Unit, Great Ormond Street Hospital, London, UK

⁴Haematology Unit, Great Ormond Street Hospital, London, UK

Manuscript Received: 19 March 2013; Manuscript Accepted: 2 May 2013

Nuclear-encoded disorders of mitochondrial translation are clinically and genetically heterogeneous. Genetic causes include defects of mitochondrial aminoacyl-tRNA synthetases, and factors required for initiation, elongation and termination of protein synthesis as well as ribosome recycling. We report on a new case of myopathy, lactic acidosis and sideroblastic anemia (MLASA) syndrome caused by defective mitochondrial tyrosyl aminoacylation. The patient presented at 1 year with anemia initially attributed to iron deficiency. Bone marrow aspirate at 5 years revealed ringed sideroblasts but transfusion dependency did not occur until 11 years. Other clinical features included lactic acidosis, poor weight gain, hypertrophic cardiomyopathy and severe myopathy leading to respiratory failure necessitating ventilatory support. Long-range PCR excluded mitochondrial DNA rearrangements. Clinical diagnosis of MLASA prompted direct sequence analysis of the *YARS2* gene encoding the mitochondrial tyrosyl-tRNA synthetase, which revealed homozygosity for a known pathogenic mutation, c.156C>G;p.F52L. Comparison with four previously reported cases demonstrated remarkable clinical homogeneity. First line investigation of MLASA should include direct sequence analysis of *YARS2* and *PUS1* (encoding a tRNA modification factor) rather than muscle biopsy. Early genetic diagnosis is essential for counseling and to facilitate appropriate supportive therapy. Reasons for segregation of specific clinical phenotypes with particular mitochondrial aminoacyl tRNA-synthetase defects remain unknown.

© 2013 The Authors. American Journal of Medical Genetics Part A/ Published by Wiley Periodicals, Inc.

Key words: sideroblastic anemia; MLASA; *YARS2*; mitochondrial disease; mitochondrial myopathy; lactic acidosis

INTRODUCTION

The congenital sideroblastic anemias are rare inborn errors of metabolism caused by defects of mitochondrial energy production,

How to Cite this Article:

Shahni R, Wedatilake Y, Cleary MA, Lindley KJ, Sibson KR, Rahman S. 2013. A distinct mitochondrial myopathy, lactic acidosis and sideroblastic anemia (MLASA) phenotype associates with *YARS2* mutations.

Am J Med Genet Part A 161A:2334–2338.

heme biosynthesis and iron–sulfur cluster biogenesis [Bergmann et al., 2010; Fleming, 2011]. The most commonly recognized congenital sideroblastic anemias are X-linked sideroblastic anemia (XLSA) secondary to mutations in *ALAS2* encoding delta amino levulinic acid synthetase, and the Pearson marrow-pancreas syndrome caused by sporadically arising large-scale rearrangements of the mitochondrial genome. Mitochondrial DNA (mtDNA) encodes 13 polypeptide subunits of the oxidative phosphorylation

This is an open access article under the terms of the Creative Commons Attribution License, which permits use, distribution and reproduction in any medium, provided the original work is properly cited.

Contributions: R.S. performed the genetic analysis and co-wrote the manuscript; Y.W. collated clinical data and co-wrote the manuscript; M. A.C., K.L. and K.S. provided clinical data; and S.R. diagnosed the patient, supervised genetic analysis and co-wrote the manuscript.

Grant sponsor: Great Ormond Street Hospital Children's Charity; Grant sponsor: Wellcome Trust Research Training Fellowship.

*Correspondence to:

Dr. Shamima Rahman, Mitochondrial Research Group, Clinical and Molecular Genetics Unit, UCL Institute of Child Health, 30 Guilford Street, London WC1N 1EH, UK.

E-mail: shamima.rahman@ucl.ac.uk

Article first published online in Wiley Online Library (wileyonlinelibrary.com): 5 August 2013

DOI 10.1002/ajmg.a.36065

(OXPHOS) system, together with 22 transfer RNA (tRNA) and two ribosomal RNA (rRNA) molecules required for intramitochondrial synthesis of these 13 polypeptides. The mtDNA rearrangements in Pearson syndrome typically delete several tRNA genes, leading to global impairment of mitochondrial translation [Rotig et al., 1995]. More recently, nuclear-encoded disorders of mitochondrial translation are emerging including two gene defects (*PUS1* and *YARS2* mutations) that appear to specifically associate with a syndrome of myopathy, lactic acidosis and sideroblastic anemia (MLASA) [Bykhovskaya et al., 2004; Riley et al., 2010; Rotig, 2011].

XLSA and Pearson syndrome can be easily distinguished clinically since the former causes a pure sideroblastic anemia phenotype (which may be late-onset and not require regular transfusions), whilst the latter causes an infantile-onset transfusion-dependent sideroblastic anemia associated with lactic acidosis and multisystem disturbances. Clinical manifestations of Pearson syndrome include exocrine and endocrine pancreatic insufficiency, renal tubulopathy and faltering growth [Rotig et al., 1995]. Death in infancy or early childhood frequently follows overwhelming lactic acidosis or acute liver failure [Rotig et al., 1995]. Survivors develop a progressive neurological disorder including ophthalmoplegia, cardiac conduction defects and cerebellar ataxia, within the Kearns-Sayre syndrome spectrum [McShane et al., 1991; Rahman and Leonard, 2000].

YARS2 mutations have previously been reported in four patients from three apparently unrelated families [Riley et al., 2010; Sasarman et al., 2012]. Here we describe another case of MLASA caused by *YARS2* mutation and show that this is a clinically distinct phenotype that can be diagnosed without recourse to muscle biopsy, the “gold-standard” method for diagnosing mitochondrial disease.

PATIENT AND METHODS

The patient, the second child of healthy unrelated Lebanese parents, was born at term after an uncomplicated pregnancy. Two siblings aged 7 and 16 years are healthy. Aged 1 year, following an episode of pallor and jaundice, the patient was diagnosed with iron deficiency anemia and was prescribed iron supplements. At 5 years, the family migrated to the UK and he was diagnosed with congenital sideroblastic anemia following a bone marrow aspirate (Fig. 1a). Pyridoxine was commenced and his hemoglobin remained stable (9–11 g/dl) until 11.5 years. At 10 years he presented with abdominal pain, poor weight gain and lethargy. Upper gastrointestinal (GI) endoscopy revealed reflux esophagitis and patchy duodenal erythema with mild focal lymphocyte infiltration. Poor growth and intermittent vomiting persisted despite serial interventions including gluten-free diet and nasogastric, gastrostomy and (eventually) parenteral feeding. Repeat upper GI endoscopy and video capsule endoscopy revealed multiple ileal ulcers, and an atrophic duodenal bulb, with absent villi and duodenal ulcers. A trial of azathioprine and prednisolone was commenced for presumed inflammatory bowel disease.

At 11.5 years he developed transfusion-dependent anemia; repeat bone marrow aspiration and trephine biopsy appearances were unchanged. The worsening anemia was initially attributed to chronic low-grade gastrointestinal bleeding. He also required

twice-weekly granulocyte colony stimulating factor infusions for neutropenia. Nine months later he developed shortness of breath and was found to have a pericardial effusion, necessitating pericardiocentesis. Transthoracic echocardiogram also showed severe biventricular hypertrophy with preserved biventricular systolic function. Due to recurrent episodes of dizziness he underwent 24 hr Holter monitoring which showed sinus rhythm.

At 12.5 years he became increasingly lethargic, with declining weight despite parenteral nutrition and regular transfusions every 2–3 weeks. Examination showed myopathic facies, bilateral ptosis, pallor and cachexia, (weight 23.6 kg, 0.4th centile and height 139.9 cm, 2nd centile), with generalized muscle weakness. Electromyography demonstrated severe myopathic changes. Sleep study revealed severe hypoventilation with evidence of CO₂ retention and he was commenced on nocturnal BiPAP ventilation. Blood investigations showed anemia (Hb 6.2–8.4 g/dl), neutropenia (neutrophils $0.26 \times 10^9/L$), elevated lactate and respiratory acidosis (venous blood gas pH 7.3, pCO₂ 9.9 kPa, HCO₃ 37 mmol/L). Plasma amino acids demonstrated raised alanine (1113 μmol/L, reference range 150–450) and low arginine (28 μmol/L, reference range 40–120). Acylcarnitine analysis revealed low free carnitine levels. Urine organic acid analysis demonstrated strongly raised lactate and pyruvate with moderately raised 2-hydroxybutyrate and mildly raised 2-hydroxyisovalerate, secondary to disturbed lactate metabolism. Stool elastase was normal (>500 μg/g, normal >200).

All genetic studies were performed with informed parental consent and ethical approval for the study was obtained from the National Research Ethics Committee London Bloomsbury, UK. Long-range PCR of mitochondrial DNA was used to screen for large-scale mtDNA rearrangements. Because of a clinical suspicion of MLASA syndrome, and the Lebanese origin of the patient, the *YARS2* gene was sequenced in the patient and both parents. PCR amplification was performed using primers and conditions as previously reported, and PCR products were directly sequenced on an ABI PRISM 3730 automated sequencer (Source Biosciences) [Riley et al., 2010]. Sequence comparisons and analysis were performed using the Sequencher program, V.4.9.

RESULTS

Long range PCR of genomic DNA extracted from peripheral blood leucocytes did not detect any mtDNA rearrangements, excluding Pearson syndrome. On the basis of phenotype similarities between our patient and previously reported patients we sequenced the *YARS2* gene, which encodes the human mitochondrial tyrosyl-RNA synthetase, and identified a homozygous mutation, c.156C > G;p.F52L (Fig. 1b), which affects a highly conserved amino acid residue and has previously been reported to be pathogenic [Riley et al., 2010].

DISCUSSION

The combination of sideroblastic anemia and lactic acidosis is strongly suspicious of a mitochondrial disorder. In infantile-onset sideroblastic anemia with lactic acidosis, the most frequent cause is Pearson marrow-pancreas syndrome associated with single large-scale mtDNA rearrangements. Several lines of evidence argued

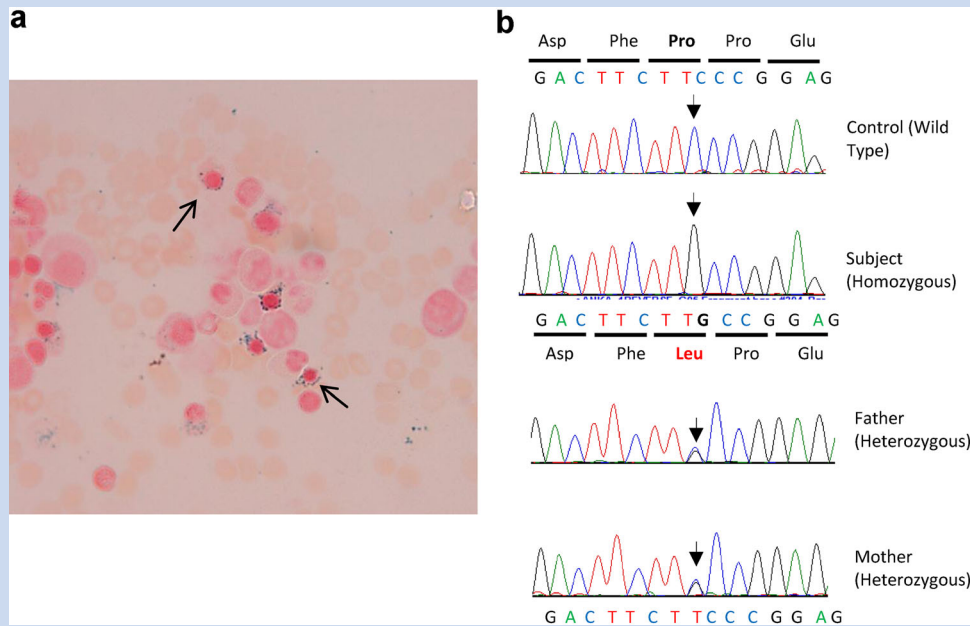


FIG. 1. a: Bone marrow aspirate stained for iron with Perl's Prussian blue stain (original magnification 60 \times). Arrows indicate two of the numerous ringed sideroblasts seen. **b:** Sequence electropherogram of part of exon 1 of the *YARS2* gene. The control sequence is wild-type homozygous (top panel) whilst the patient is homozygous for the c.156C>G mutation resulting in proline to leucine substitution (second panel) and the parents are both heterozygous (lower two panels).

against Pearson syndrome in our patient: continuing transfusion dependency at 13 years (in Pearson syndrome transfusion dependency typically resolves by the age of 2 years, as mutant mtDNA is progressively cleared from rapidly dividing hemopoietic cells), absence of pancreatic insufficiency (normal stool elastase levels), lack of neurological symptoms other than myopathy by teenage years (in particular, no evidence of cerebellar ataxia), and absence of renal tubulopathy, pigmentary retinopathy and sensorineural hearing loss (which are all typical of Pearson and Kearns–Sayre syndromes) [Pitceathly et al., 2012]. The bone marrow appearances were also atypical for Pearson syndrome, in which there is usually vacuolization of early erythroid and myeloid progenitors in addition to the presence of ringed sideroblasts, whereas in our patient no significant vacuolization was seen. Finally, Pearson syndrome was definitively excluded in our patient by the absence of mtDNA rearrangements in leukocyte DNA.

A clinically more fitting diagnosis in our patient was MLASA, that is, mitochondrial myopathy, lactic acidosis and sideroblastic anemia syndrome. This was confirmed by *YARS2* analysis, which revealed homozygosity for the known pathogenic mutation c.156C>G;p.F52L. Parents were both heterozygous for the mutation, although they are not known to be related, lending weight to the hypothesis that this is a Lebanese founder mutation [Riley et al., 2010]. Two different homozygous mutations have been reported in *YARS2*, c.156C>G;p.F52L (as in our patient) and c.137G>A;p.G46D, in three apparently unrelated families of Lebanese descent. Our patient is the fifth with *YARS2* mutations reported to date. All five patients had MLASA.

A characteristic clinical phenotype of *YARS2*-related MLASA syndrome appears to be emerging (Table I). Gastro-intestinal disturbance and feeding difficulties appear to occur frequently in MLASA, whereas exocrine pancreatic insufficiency (a cardinal feature of Pearson syndrome) has never been reported. Respiratory failure requiring ventilatory support and cardiomyopathy were present in two cases including ours. In Pearson and Kearns–Sayre syndromes cardiomyopathy may occur, but the most significant cardiac problem is usually heart block, which has not been reported in MLASA. Compared to Pearson syndrome, hearing and vision appear to be relatively spared in *YARS2*-associated MLASA. One case had asymmetric ptosis and limitation of lateral gaze bilaterally in his thirties [Sasarman et al., 2002], while no hearing loss was reported in any of the five cases.

There appears to be a common pathogenic mechanism in Pearson syndrome and MLASA, namely global impairment of mitochondrial translation, manifest histologically by a ragged-red fiber myopathy with subsarcolemmal mitochondrial proliferation. In Pearson syndrome multiple mitochondrial tRNA genes are deleted, whilst in MLASA caused by *PUS1* mutations there is a defect in post-transcriptional modification (pseudouridylation) of multiple mitochondrial and cytosolic tRNAs [Patton et al., 2005]. *YARS2* mutations lead to failure of aminoacylation of the mitochondrial tRNA tyrosine. Interestingly the common 4,977 bp mtDNA deletion causing Pearson syndrome does not include the tRNA for tyrosine [Rotig et al., 1995]. Only two mutations have previously been reported in the *MT-TY* gene encoding the mitochondrial tRNA tyrosine molecule, and neither of these was

TABLE I. Clinical Phenotype Associated with *YARS2* Autations

Reference	Riley et al. [2010]			Sasarman et al. [2012] ^a	This report
Patient	P1	P2	P3	P4	P5
Sex	M	F	F	M	M
Age at onset	10 weeks	Infancy	7y	31y	1y
Age at death	18y	Alive at 16y	Alive at 24y	Alive at 34y	Alive at 13y
Consanguinity	Yes	Yes	Yes	No	No
Family history	Sibling (P2)	Sibling (P1)	Maternal aunt died of SA at 26y ^b	No	Paternal uncle similarly affected ^b
Ethnicity	Lebanese	Lebanese	Lebanese	Lebanese	Lebanese
Sideroblastic anemia	Yes	Yes	Yes	Yes	Yes
Transfusion-dependent	Yes—initially 2–3 monthly, later every 3–4 weeks	Yes	No	No	From 11.5y
Faltering growth	Yes	—	—	—	Yes
Dysphagia/feeding difficulties	Yes—eventually permanent vocal cord paresis	Yes	—	—	Yes
Hypertrophic cardiomyopathy	Yes	—	—	—	Yes
Exercise intolerance	Yes	Yes	Yes	Yes	Yes
Respiratory failure	17y	—	No	—	12y
Blood lactate (mmol/L)	3–13.7	2.5–8.4	4.1	3.8	5.6–10.1
Muscle histology	“Incipient”, reduced COX staining		Lipid vacuoles	Severely reduced COX staining and increased SDH; EMsubsarcolemmal aggregation of peripheral mitochondria, many containing crystalline inclusions	ND
Muscle respiratory chain enzyme activities (% of control)	CI	CI	CI	CI (<6%)	ND
<i>YARS2</i> mutations	Homozygous	Homozygous	Homozygous	Homozygous c.137G > A;p.G46D	Homozygous
	c.156C > G;p.52L	c.156C > G;p.52L	c.156C > G;p.52L		c.156C > G;p.52L

Key: CI, complex I; CII + III, complexes II + III; CIII, complex III; CIV, complex IV; COX, cytochrome c oxidase; ND, not determined; RRF, ragged red fibres; —, information not provided in original report.^aClinical features of P4 initially reported in Sasarman et al. [2002].

^bThese individuals have not been tested for *YARS2* mutations.

associated sideroblastic anemia, providing further evidence that impaired translation of tyrosine residues is not the cause of sideroblastic anemia [Pulkes et al., 2000; Scaglia et al., 2003]. However, the two patients did have some clinical features in common with our patient with *YARS2* mutations, namely myopathy and lactic acidosis in the first case and cardiomyopathy in the second, arguing for a role for impaired tyrosine aminoacylation in causation of some of the features of MLASA [Pulkes et al., 2000; Scaglia et al., 2003]. The mechanistic link between *YARS2* and *PUS1* mutations is also

unclear. *PUS1* has been shown to modify bases 27 and/or 28 of several mitochondrial tRNA species [Suzuki et al., 2011], but the pseudouridylation status of mitochondrial tRNA tyrosine has not yet been reported.

Defects of several other mitochondrial tRNA aminoacyl synthetases do not appear to cause congenital sideroblastic anemia [Konovalova and Tynismaa, 2013]. Moreover, a large number of nuclear-encoded mitochondrial translation defects have now been described and most are not associated with congenital side-

roblastic anemia [Rotig, 2011]. The reasons for the tissue specificity associated with *YARS2* and *PUS1* mutations are currently not understood, but it is possible that the *YARS2* protein has a second function necessary for hematopoiesis that may be unrelated to its role in mitochondrial protein synthesis. Moonlighting functions are recognised for other mitochondrial proteins, for example one subunit of respiratory chain complex I is a tumour suppressor and another is involved in caspase-independent cell death, whilst various complex I assembly factors have been implicated in immune pathways and to enhance tumour growth in some cancers [Rahman and Thorburn, 2013].

In conclusion, patients with congenital sideroblastic anemia should be assessed for features of MLASA and consideration should be given to screening the *YARS2* gene in patients with lactic acidosis and sideroblastic anemia persisting beyond early childhood, particularly if mtDNA deletions have been excluded. Although no specific curative therapies are available, early diagnosis and initiation of appropriate supportive therapy is likely to be important in the prevention of the longterm complications of this disorder. Direct targeting of the *YARS2* and *PUS1* genes in MLASA patients can avoid invasive muscle biopsy for diagnosis of this subgroup of inborn errors of mitochondrial metabolism.

ACKNOWLEDGMENTS

S.R. is supported by Great Ormond Street Hospital Children's Charity and Y.W. by a Wellcome Trust Research Training Fellowship. We gratefully acknowledge funding from the Muscular Dystrophy Campaign.

REFERENCES

- Bergmann AK, Campagna DR, McLoughlin EM, Agarwal S, Fleming MD, Bottomley SS, Neufeld EJ. 2010. Systematic molecular genetic analysis of congenital sideroblastic anemia: evidence for genetic heterogeneity and identification of novel mutations. *Pediatr Blood Cancer* 54:273–278.
- Bykhovskaya Y, Casas K, Mengesha E, Inbal A, Fischel-Ghodsian N. 2004. Missense mutation in pseudouridine synthase 1 (*PUS1*) causes mitochondrial myopathy and sideroblastic anemia (MLASA). *Am J Hum Genet* 74:1303–1308.
- Fleming MD. 2011. Congenital sideroblastic anemias: Iron and heme lost in mitochondrial translation. *Hematology Am Soc Hematol Educ Program* 2011:525–531.
- Konovalova S, Tynymmaa H. 2013. Mitochondrial aminoacyl-tRNA synthetases in human disease. *Mol Genet Metab* 108:206–211.
- McShane MA, Hammans SR, Sweeney M, Holt IJ, Beattie TJ, Brett EM, Harding AE. 1991. Pearson syndrome and mitochondrial encephalomyopathy in a patient with a deletion of mtDNA. *Am J Hum Genet* 48:39–42.
- Patton JR, Bykhovskaya Y, Mengesha E, Bertolotto C, Fischel-Ghodsian N. 2005. Mitochondrial myopathy and sideroblastic anemia (MLASA): missense mutation in the pseudouridine synthase 1 (*PUS1*) gene is associated with the loss of tRNA pseudouridylation. *J Biol Chem* 280:19823–19828.
- Pitceathly RD, Rahman S, Hanna MG. 2012. Single deletions in mitochondrial DNA—molecular mechanisms and disease phenotypes in clinical practice. *Neuromuscul Disord* 22:577–586.
- Pulkes T, Siddiqui A, Morgan-Hughes JA, Hanna MG. 2000. A novel mutation in the mitochondrial tRNA(Tyr) gene associated with exercise intolerance. *Neurology* 55:1210–1212.
- Rahman S, Leonard JV. 2000. Early onset of complete heart block in Pearson syndrome. *J Inherit Metab Dis* 23:753–754.
- Rahman S, Thorburn DR. 2013. 189th ENMC International workshop Complex I deficiency: Diagnosis and treatment 20–22 April 2012, Naarden, The Netherlands. *Neuromuscul Disord* 23:506–515.
- Riley LG, Cooper S, Hickey P, Rudinger-Thirion J, McKenzie M, Compton A, Lim SC, Thorburn D, Ryan MT, Giege R, Bahlo M, Christodoulou J. 2010. Mutation of the mitochondrial tyrosyl-tRNA synthetase gene, *YARS2*, causes myopathy, lactic acidosis, and sideroblastic anemia—MLASA syndrome. *Am J Hum Genet* 87:52–59.
- Rotig A. 2011. Human diseases with impaired mitochondrial protein synthesis. *Biochim Biophys Acta* 1807:1198–1205.
- Rotig A, Bourgeron T, Chretien D, Rustin P, Munnich A. 1995. Spectrum of mitochondrial DNA rearrangements in the Pearson marrow-pancreas syndrome. *Hum Mol Genet* 4:1327–1330.
- Sasarman F, Karpati G, Shoubridge EA. 2002. Nuclear genetic control of mitochondrial translation in skeletal muscle revealed in patients with mitochondrial myopathy. *Hum Mol Genet* 11:1669–1681.
- Sasarman F, Nishimura T, Thiffault I, Shoubridge EA. 2012. A novel mutation in *YARS2* causes myopathy with lactic acidosis and sideroblastic anemia. *Hum Mutat* 33:1201–1206.
- Scaglia F, Vogel H, Hawkins EP, Vladutiu GD, Liu LL, Wong LJ. 2003. Novel homoplasmic mutation in the mitochondrial tRNA^{Tyr} gene associated with atypical mitochondrial cytopathy presenting with focal segmental glomerulosclerosis. *Am J Med Genet Part A* 123A:172–178.
- Suzuki T, Nagao A, Suzuki T. 2011. Human mitochondrial tRNAs: Biogenesis, function, structural aspects, and diseases. *Annu Rev Genet* 45:299–329.