

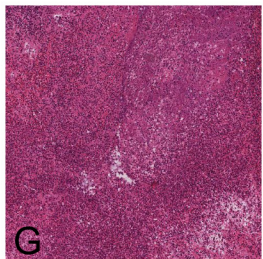
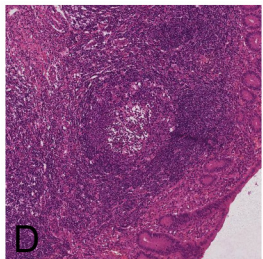
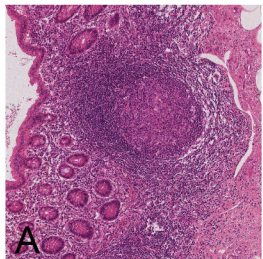
## Definition

Few granulocytes present.

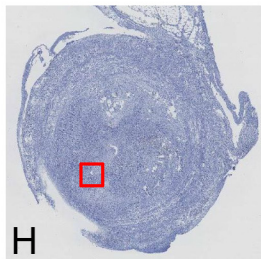
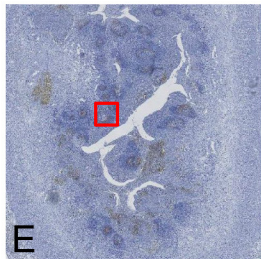
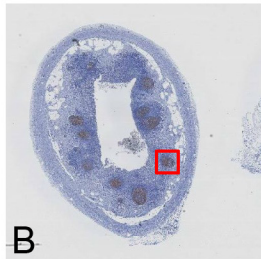
Disseminated granulocytes into the muscularis, leaving the follicular structure intact.

Confluent granulocytes, purulent inflammation. May extend into the lumen, often destroying follicular structure.

## H&E



## CD21



## Rejection rate

