




2810372017





Institute of  
Ophthalmology

# **THE USE OF ANTIBIOTICS AGENTS IN OCULAR INFECTION**

By

**Aliakbar Safiee**

**Under supervision of  
Professor Susan Lightman**

A thesis submitted in fulfilment of the conditions  
required for the degree of Master of Philosophy  
at the University College London

**2008**

UNIVERSITY COLLEGE LONDON  
INSTITUTE OF OPHTHALMOLOGY  
11-43 Bath Street  
London, EC1V 9EL

UMI Number: U593404

All rights reserved

INFORMATION TO ALL USERS

The quality of this reproduction is dependent upon the quality of the copy submitted.

In the unlikely event that the author did not send a complete manuscript and there are missing pages, these will be noted. Also, if material had to be removed, a note will indicate the deletion.



UMI U593404

Published by ProQuest LLC 2013. Copyright in the Dissertation held by the Author.  
Microform Edition © ProQuest LLC.

All rights reserved. This work is protected against  
unauthorized copying under Title 17, United States Code.



ProQuest LLC  
789 East Eisenhower Parkway  
P.O. Box 1346  
Ann Arbor, MI 48106-1346

## **A) ACKNOWLEDGEMENTS**

I wish to express my sincere gratitude to Professor Susan Lightman for her valuable efforts and kindness throughout my studies and would like to thank her for giving me the opportunity to be part of this investigation.

I thank all my colleagues at the Pharmacy department at Moorfields Eye Hospital, for their support throughout my studies.

On a personal level, I am deeply grateful to my sister Dr Roghieh Saffie-Siebert for her sincere support and for helping me through difficult times.

I am especially indebted to my parents Yahya and Maliah for their love and trust in me, for their continuous support with letters and phone calls that kept me going, and for believing in my work and my abilities.

I wish to thank my brothers and my sister, for their constant emotional support with visits, letters or phone calls.

Finally, I would like to thank my wife Mrs Sara Bahadorian. Without her love, support, encouragement, her patience and confidence in my abilities, nothing would have been achieved.

## **B) TABLE OF CONTENTS**

<b>A) ACKNOWLEDGEMENTS</b>	<b>1</b>
<b>B) TABLE OF CONTENTS</b>	<b>2</b>
<b>C) FIGURES AND TABLES</b>	<b>7</b>
<b>D) ABSTRACT:</b>	<b>8</b>
<b>E) INTRODUCTION</b>	<b>10</b>
<b>I ANATOMY OF THE EYE AND ITS RELATIONSHIP TO INFECTIOUS PROCESSES</b>	<b>10</b>
<b>I.1 STRUCTURE OF THE EYE</b>	<b>12</b>
<b><i>I.1.1 ORBITS, THEIR SOFT TISSUE CONTENTS, AND ADJACENT STRUCTURES</i></b>	<b>12</b>
<b><i>I.1.2 BLOOD SUPPLY OF THE ORBITS</i></b>	<b>13</b>
<b><i>I.1.3 EYELIDS AND LACRIMAL SYSTEM</i></b>	<b>14</b>
<b><i>I.1.4 THE GLOBE, INCLUDING THE SCLERA AND CHOROID</i></b>	<b>14</b>
<b><i>I.1.5 ANTERIOR CHAMBER, AQUEOUS HUMOR, CORNEA, AND IRIS</i></b>	<b>15</b>
<b><i>I.1.6 POSTERIOR CHAMBER, LENS, AND VITREOUS HUMOR</i></b>	<b>16</b>
<b><i>I.1.7 RETINA AND OPTIC NERVE</i></b>	<b>16</b>
<b>II. PATHOGENESIS OF INFECTION AND THE OCULAR IMMUNE RESPONSE</b>	<b>17</b>
<b>II.1 IMMUNE SYSTEM</b>	<b>17</b>

<i>II.1.1 INNATE &amp; ADAPTIVE IMMUNE SYSTEMS</i>	17
<i>II.1.2 CENTRAL AND PERIPHERAL TOLERANCE</i>	18
<b>II.1.2A CENTRAL TOLERANCE</b>	18
<b>II.1.2B PERIPHERAL TOLERANCE</b>	18
<b>II.1.3 FACTORS</b>	19
<b>II.1.3A VASCULAR SUPPLY</b>	19
<b>II.1.3B VASCULAR BARRIER</b>	19
<b>II.1.3C LYMPHATIC ROLE</b>	19
<b>II.1.3D THE EYE, APCs &amp; MHCs</b>	20
<b>II.1.3E ANTERIOR CHAMBER ASSOCIATED IMMUNE DEVIATION (ACAID)</b>	21
<b>II.2 OCULAR DEFENSE MECHANISMS</b>	22
<b>II.2.1 ANATOMIC DEFENSES</b>	22
<b>II.2.2 DEFENSES OF THE TEAR FILM</b>	24
<b>II.2.3 CONJUNCTIVAL DEFENSE</b>	24
<b>II.2.4 CORNEAL RESPONSE</b>	25
<b>II.2.5 CELLULAR IMMUNE RESPONSE</b>	25
<b>II.2.6 LEUKOCYTE DEFENSE</b>	26
<b>III. BIOLOGY OF THE INFECTIOUS AGENTS RELEVANT TO OCULAR DISEASE</b>	27
<b>III.1 VIRUSES</b>	27
<b>III.2 FUNGI</b>	29
<b>III.3 PROTOZOA</b>	32

<b>III.4 BACTERIA</b>	34
<b>IV. DETECTION OF BACTERIA BY PCR</b>	38
<b>V. DISPOSITIONS OF OPHTHALMIC DRUGS</b>	42
<b>V.1 GENERAL PRINCIPLES OF ANTIBIOTIC THERAPY</b>	42
<b>V.2 OVER-THE-COUNTER OPHTHALMIC PREPARATIONS</b>	44
<b>V.2.1 INFECTIVE CONJUNCTIVITIS</b>	46
<b>V.2.2. ALLERGIC CONJUNCTIVITIS</b>	48
<b>V.2.3 DRY EYE CONDITIONS</b>	48
<b>V.3 PRESCRIPTION DRUG: TOPICAL OCULAR ANTIBIOTICS</b>	49
<b>V.3.1 AMINOGLYCOSIDES</b>	51
<b>V.3.2 CHLORAMPHENICOL</b>	52
<b>V.3.3 CHLORTETRACYCLINE</b>	55
<b>V.3.4 FUSIDIC ACID</b>	56
<b>V.3.5 DIAMIDINES</b>	58
<b>V.3.6 FLUOROQUINOLONES</b>	60
<b>V.3.7 COMBINATION PRODUCTS CONTAINING POLYMYXIN</b>	69
<b>V.3.8 OTHER ANTIBIOTICS</b>	72
<b>V.4 PRESCRIPTION DRUGS: SYSTEMIC ANTIBIOTICS FOR OCCULAR DISEASE</b>	76
<b>V.4.1 SPARFLOXACIN</b>	77



<i>V.4.2</i>	<i>TEMAFLOXACIN</i>	78
<i>V.4.3</i>	<i>LEVOFLOXACIN</i>	80
<i>V.4.4</i>	<i>TROVAFLOXACIN</i>	81
<i>V.4.5</i>	<i>GATIFLOXACIN</i>	84
<b>V.4.6</b>	<b>COMBINATION SYSTEMIC THERAPY</b>	86
<b>VI.</b>	<b>ADVANCE IN OPHTHALMIC DRUG DELIVERY SYSTEM</b>	89
<b>VI.1</b>	<b>FACTORS AFFECTING ABSORPTION</b>	89
<b>VI.1.1</b>	<b>DRUG CONCENTRATION</b>	89
<i>VI.1.2</i>	<i>SOLUBILITY IN LIPIDS AND WATER</i>	90
<i>VI.1.3</i>	<i>PH</i>	90
<b>VI.1.4</b>	<b>VISCOSITY</b>	90
<i>VI.1.5</i>	<i>SURFACTANTS</i>	90
<b>VI.2</b>	<b>FACTORS AFFECTING ROUTE OF DELIVERY</b>	91
<b>VI.2.1</b>	<b>DROPS</b>	91
<b>VI.2.2</b>	<b>OINTMENT</b>	91
<b>VI.2.3</b>	<b>PERI-OCULAR / INTRAVITREAL INJECTION</b>	91
<b>VI.2.4</b>	<b>SYSTEMIC</b>	92
<b>VI.2</b>	<b>TYPES OF FORMULATION</b>	92
<i>VI.2.1</i>	<i>SOLUTIONS</i>	92
<i>VI.2.2</i>	<i>SUSPENSIONS</i>	93

<i>VI.2.3 OINTMENTS</i>	93
<i>VI.2.4 POWDERS</i>	93
<b>VI.3 VEHICLES OF PREPARATIONS AND HOW THEY AFFECT CONTACT TIME</b>	93
<b>VI.4 CURRENT DRUG DELIVERY SYSTEMS FOR THE EYE</b>	95
<b>VII. INTRODUCTION TO THE PHARMACY HANDBOOK</b>	100
<b>VIII. CONCLUSION</b>	102
<b>IX. REFERENCES</b>	108
<b>X. APPENDIX 1</b>	128

## **C) FIGURES AND TABLES**

**Figure 1:** Schematic diagram of the human eye

**Figure 2:** Medial wall of left orbit

**Figure 3:** Use of non-commercially available topical antibiotics

**Table 1:** Cells and molecules of the innate and adaptive immune systems

**Table 2:** Relationship between MHC and Ocular cell types

**Table 3:** Putative host defense components of human tears and their functions

**Table 4:** Major eye infections caused by bacteria

**Table 5:** Pathogen identification methods

**Table 6:** Ophthalmic preparations classified as pharmacy medicines

**Table 7:** Commercially available topical ophthalmic preparation containing antibiotics

**Table 8:** Comparison of Quinolone Generations

**Table 9:** Susceptibilities of ocular pathogens to polymyxin-containing mixtures

## **D) ABSTRACT:**

Eye disease can cause discomfort and anxiety in patients, with the ultimate risk of loss of vision or even facial disfigurement. The unique structure of the human eye as well as exposure of the eye directly to the environment renders it vulnerable to a number of uncommon infectious diseases caused by bacteria, fungi and parasites.

The driving force for the development of newer anti-infectives is almost always the inevitable emergence of bacterial resistance to antibiotics following widespread clinical, veterinary, and agricultural (growth promoter in chickens, pigs, and feedlot cattle) usage.

The pharmaceutical industry has continuously met this need by modifying existing antibiotics and developing newer antibiotics. These successful efforts have produced the wide variety of currently available drug classes of antibiotics [beta lactams (penicillins, carbapenems, cephalosporins), glycopeptides, macrolides, ketolides, aminoglycosides, fluoroquinolones, oxazolidinones, and others].

There are, however, still several serious and potentially blinding eye diseases that lack adequate and effective treatment. Despite coverage with broad-spectrum antibiotics, visual loss remains a common result (1, 2). The outcome of the most severe infections is determined by several factors, such as the responsible pathogen, the patient's age, the therapy chosen, or the condition of the eye upon presentation (3). The most important factor, however, seems to be the duration between infection and treatment. Clinical and experimental studies have firmly established that delay in therapy increases the risk of poor visual outcome, especially in severe cases.

Early and accurate diagnosis of the responsible pathogen is, therefore, essential for effective treatment. However, when ocular infection is suspected, the pathogen is typically not known, so the choice of antimicrobial agent must be made empirically. Unfortunately, clinical features of infection and culture results do frequently not correlate adequately to guide the choice of antibiotics upon presentation (4).

The objective of the present work was therefore to compile and review the available information on bacterial eye diseases as well as the current drugs and therapies and their limitations. It is hoped that this may assist both clinicians and research scientists in improving the diagnosis and treatment of these diseases.

To this end, the present study:

- 1- presents an overview of the eye's physiology and of the current knowledge of microbes infecting the eye;
- 2- reviews the currently available therapies for eye infections;
- 3- introduces a handbook for ophthalmologists on antimicrobial drugs including dosage, ingredient and possible drug-drug interaction
- 4- examines two promising avenues for overcoming the present medical challenges posed by eye infections: more sensitive tools for early and more accurate diagnosis of microbial infections and better delivery systems for drug targeting.

## **E) INTRODUCTION**

### **I ANATOMY OF THE EYE AND ITS RELATIONSHIP TO INFECTIOUS PROCESSES**

The eyes of vertebrates differ in some details, yet they are all built to a common plan. The works of Beard and Quickert (5), Snell and Lemp (6) and Clyde Oyster (7) consulted as references concerning the anatomy of the eye.

Protecting the eyeball is a bony socket called the orbit. Each eye is suspended within its orbit and is surrounded by a cushion of fat and blood vessels and motor and sensory nerves, including the optic nerve. There are six small muscles attached to each eye to allow coordinated movement of the pair. The eyelids provide some protection in the front and also serve to keep the cornea lubricated by spreading the tear fluid with each blink, as well as an oily fluid produced by Meibomian glands in the lid.

The tear fluid is produced by the lacrimal glands near the outer portion of each eyebrow and is collected and drained through tiny canals within the upper and lower lids near the nose. The tears eventually flow into the nasal passages and are swallowed.

The adult human eye is a hollow globe with a diameter of approximately 2.5 cm (1 inch). The wall of the globe is composed of three coats. The outer coat, called the fibrous tunic, supplies the basic support of the eye and gives it shape. The fibrous tunic is divided into the cornea, which is the transparent, exposed membrane in front of the lens, and the sclera, the firm, white coat of the eye to which is attached the muscles that move the eyeball. The middle, or vascular, coat is composed of three regions. The choroid layer is pigmented black and carries blood vessels to and from the eye. In mammals other than

humans, it has an iridescent layer that increases the retina's sensitivity to low-intensity light. The ciliary body consists of a ring-shaped muscle, which can change the lens shape, and ciliary processes to which the lens is attached. The iris, which contains an opening, the pupil, is colored and has a sphincter and a dilator muscle, called a contractile diaphragm. The innermost coat is the retina, which lies behind the lens. It contains the optic disc, or blind spot, which is the junction of nerve fibers passing to the brain. The retina also contains rods and cones, light-sensitive cells. The lens is a biconvex, transparent structure (7).

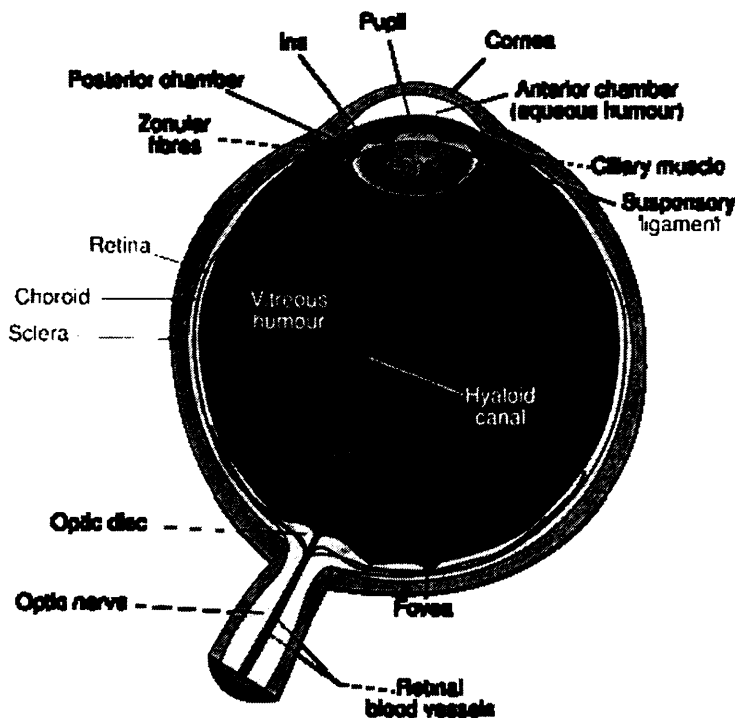


Figure 1: Schematic diagram of the human eye (adopted from Wikipedia)

## **I.1 STRUCTURE OF THE EYE**

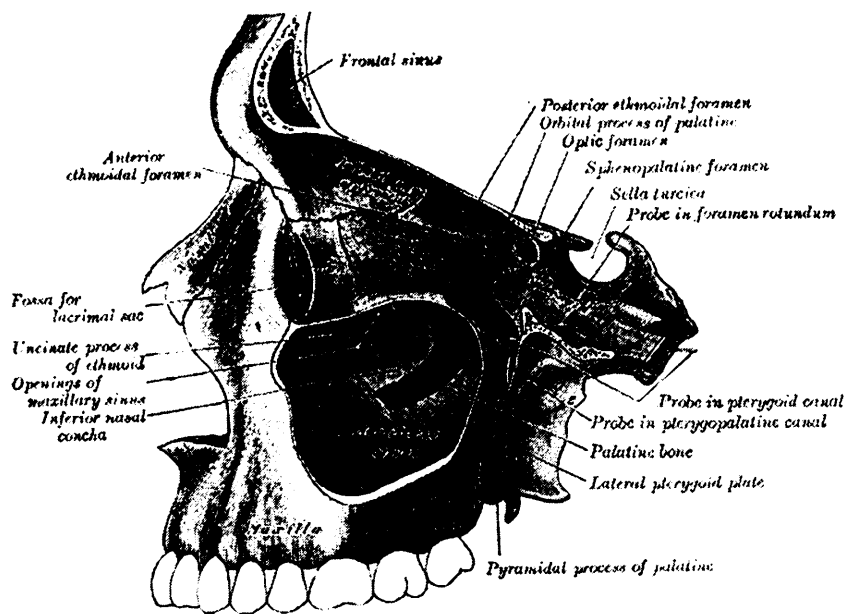
### *I.1.1 ORBITS, THEIR SOFT TISSUE CONTENTS, AND ADJACENT STRUCTURES*

The orbits are pear-shaped bony cavities that contain the globes, extraocular muscles, nerves, fat and blood vessels (Fig.2). The walls of the orbit are comprised of seven bones. The periosteal covering of the orbital bony cavity fuses anteriorly with the orbital septum and posteriorly with the duramater. Abscesses can localize in the subperiosteal space. The roof, medial wall, and floor of the orbit separate it from adjacent paranasal sinuses, including the maxillary, frontal, ethmoid, and sphenoid sinuses. The paranasal sinuses arise from and drain into the nasal cavity. Thus, an intimate anatomical relationship exists between the orbit and the adjacent paranasal sinuses, and the latter may be the source of an orbital infection.

The thinnest bony walls of the orbit are the lamina papyracea, which cover the ethmoid sinuses. They are commonly involved in any fracture of the orbit from force to the periorbital area. As a result of fracture, sinus microbiota has direct ingress to the orbital tissues. Infections of the ethmoid sinus in children commonly extend through the lamina papyracea (without fracture), causing orbital cellulitis. The lateral wall of the sphenoid is also the medial wall of the optic canal. Therefore, infections of the sphenoid sinus may impinge on the optic nerve, resulting in visual loss or visual field abnormalities.

There are several important communications through apertures in the bony orbit to adjacent structures, including the superior and inferior orbital fissures, the lacrimal fossa and nasolacrimal duct, and the optic canal. These apertures may serve as a direct passage for an infectious process between the orbit and surrounding structures (5).





**Figure 2:** Medial wall of left orbit (adopted from Wikipedia)

### 1.1.2 BLOOD SUPPLY OF THE ORBITS

The blood supply to the orbit is primarily through the ophthalmic artery and its branches. The majority of orbital venous drainage is via the superior ophthalmic vein, which courses through the superior fissure to the cavernous sinus. The cavernous sinus is a venous plexus located posterior to the apex of the orbit. As the primary venous system receiving orbital drainage, the cavernous sinus is susceptible to venous thrombosis secondary to direct intravascular extension of infection. Veins from the face and many anterior orbital veins anastomose and become tributaries of the superior orbital vein. Thus, facial infections may lead through these communications to infection of the cavernous sinus, which may be a lethal complication.

### *1.1.3 EYELIDS AND LACRIMAL SYSTEM*

The eyelids possess two protective anatomical barriers preventing the penetration of pathogens beyond the anterior surface of the globe. The first is the orbital septum, a thin multilayer fibrous tissue that divides the orbit from the eyelid into preseptal and postseptal spaces and serves as a physical barrier to prevent infections from spreading posteriorly into orbital fat. The second is the conjunctiva that is reflected back on itself. This prevents material on the anterior surface of the globe from freely moving posteriorly along its surface.

The lacrimal system is comprised of the lacrimal gland, accessory glands, and the excretory system. The lacrimal gland secretes tears that pass down over the cornea and enter the lacrimal excretory system at the puncta. The puncta drains tears into the canalicular system that leads to the lacrimal sac.

Tears in the lacrimal sac drain to the nose. The lacrimal system thus forms a direct passage from the anterior ocular adnexa to the nasal cavity. With total nasolacrimal duct obstruction, infected material in the sac may reflux onto the ocular surface.

### *1.1.4 THE GLOBE, INCLUDING THE SCLERA AND CHOROID*

The adult human eye is approximately 24 mm in anteriorposterior length and is 6 mm<sup>3</sup> in volume. The basic structure of the globe consists of three concentric layers or tunics. The outermost tunic is comprised of the cornea and sclera.

The middle tunic is the uveal tract. It consists of the choroid, ciliary body, and iris. The innermost tunic is the retina (Fig. 2).

The posterior outer layer of the globe is the sclera, which is comprised of collagen and ground substance. The scleral width ranges from 0.3 to 1.0 mm. The sclera is essentially avascular superficial but there are and deep episcleral vascular plexuses. The choroid is a vascular tunic that comprises the posterior portion of the uveal tract. The purpose of this highly vascularized tissue is to provide nutritive support to the outer layer of the retina. The blood flow and oxygenation of the choroid are very high compared to the other tissues in the body. Because of these qualities, the choroid may serve as a fertile site for the proliferation of hematogenously spread pathogens.

#### *1.1.5 ANTERIOR CHAMBER, AQUEOUS HUMOR, CORNEA, AND IRIS*

The anterior chamber is a space bordered anteriorly by the cornea and posteriorly by the iris diaphragm and pupil and is filled with aqueous humor (Fig. 1). The aqueous humor, produced by nonpigmented ciliary epithelium in the posterior chamber, passes through the pupillary aperture into the anterior chamber, where it exits. The cornea is a vascular, and its stroma is composed of highly organized collagen fibrils. A tear film comprised of three layers covers the anterior surface of the cornea.

The iris is the anterior extension of the ciliary body that forms a contractile diaphragm in front of the anterior surface of the lens. It separates the anterior and posterior chambers.

The central aperture in the iris is the pupil, which constantly changes size in response to light intensity.

### *1.1.6 POSTERIOR CHAMBER, LENS, AND VITREOUS HUMOR*

The posterior chamber is bordered anteriorly by the iris diaphragm and pupil and posteriorly by the lens and zonules (Fig. 1). The lens is a vascular biconcave crystalline structure centrally located in the posterior chamber. It continues to grow throughout life, receiving nutrition from the aqueous and vitreous humors.

The vitreous is a gel-like substance occupying the posterior segment of the eye. It consists of a collagen framework interspersed with hyaluronic acid. In its normal state, it is optically clear, whereas during intraocular inflammation it may become hazy.

### *1.1.7 RETINA AND OPTIC NERVE*

The retina is the inner most coat of the ocular tunics. It is a thin, transparent, net-like membrane that captures light energy.

The retina is comprised of 10 layers, with the layer nearest the interior of the globe containing the photoreceptors called rods and cones. The inner half of the retina receives its blood supply from the central retinal artery, and the outer half receives its blood from the choroid.

The inner cell layer axons in the retina exit the globe to make up the optic nerve (Fig. 1). This nerve is surrounded by pia mater, arachnoid, and dura mater meningeal coverings, which are direct extensions from the cranial vault. The optic nerves are vulnerable to infectious processes originating both within the cranial vault and within the orbits.

## II. PATHOGENESIS OF INFECTION AND THE OCULAR IMMUNE RESPONSE

### II.1 IMMUNE SYSTEM

#### *II.1.1 INNATE & ADAPTIVE IMMUNE SYSTEMS*

The immune system can be thought of as having two “lines of defence”: the first, representing a non-specific (no memory) response to antigen (substance to which the body regards as foreign or potentially harmful) known as the innate immune system; and the second, the adaptive immune system, which displays a high degree of memory and specificity. The innate system represents the first line of defence to an intruding pathogen. The response evolved is therefore rapid, and is unable to “memorise” the same said pathogen should the body be exposed to it in the future. Although the cells and molecules of the adaptive system possess slower temporal dynamics, they possess a high degree of specificity and evoke a more potent response on secondary exposure to the pathogen. The adaptive immune system frequently incorporates cells and molecules of the innate system in its fight against harmful pathogens (8).

**Table 1:** Cells and molecules of the innate and adaptive immune systems

<b>Immunity</b>	<b>Cells</b>	<b>Molecules</b>
<b>Innate</b>	Natural Killer (NK) Cells	Cytokines
	Mast Cells	Complement
	Dendritic Cells	Acute Phase Proteins
	Phagocytes	
<b>Adaptive</b>	T and B Cells	Cytokines
		Antibodies

For example, complement (molecules of the innate system) may be activated by antibodies (molecules of the adaptive system) thus providing a useful addition to the adaptive system's armamentaria.

### *II.1.2 CENTRAL AND PERIPHERAL TOLERANCE*

Since various cells of the immune system are capable of reacting with self-antigens, it is therefore essential that the human body has mechanisms to suppress/eliminate autoreactive cells. Failure to do so, can in some cases, lead to the development of autoimmune diseases.

#### **II.1.2a Central tolerance**

Central tolerance refers to the process whereby both immature B and T cell lymphocytes, which react against normal, healthy cells (self-antigens), are eliminated via apoptosis.

#### **II.1.2b Peripheral tolerance**

This involves the removal of mature lymphocytes, which are not tolerant to healthy cells.

There are numerous sites in the body whereby tissue may be grafted with minimal risk of rejection. Such regions include, inter alia, the testis, thyroid lens, anterior chamber, cornea, iris and ciliary body.

It is important that immune privilege is not simply interpreted as the host's inability to initiate an immune response to a transplanted tissue. Rather, it is an area of the body in which there exists a paucity of various elements of the human immune system in response to an antigen.

### *II.1.3 FACTORS*

The factors purported by investigators (13-15) that contribute to the phenomenon of ocular immune privilege include:

- Isolation from a vascular supply
- Isolation from a lymphatic supply
- Presence of a vascular barrier
- Ability to suppress the immune response
- Anterior chamber associated immune deviation (ACAID)

#### **II.1.3a Vascular supply**

The healthy cornea is a good example of an ocular site devoid of a vascular network. The evidence to support the role a vascular network has to play in the mechanism of graft rejection is unequivocal since the risk of failure correlates positively with the degree of host vascularisation.

#### **II.1.3b Vascular barrier**

There is a plethora of evidence in the ophthalmic literature to support the existence of a blood-ocular barrier. Furthermore, the same said barrier encompasses different elements including tight junctions between retinal endothelial cells and the presence of junctional complexes linking retinal pigment epithelial cells.

#### **II.1.3c Lymphatic role**

The fact that skin allografts were not rejected following lymph node removal led investigators to hypothesise that immune privilege was solely due to the absence of the

same said system at a particular anatomical site. However, although certain immune privileged sites do indeed lack lymphatic drainage, others such as the testes and eye do possess such a system. It appears that a proportion of the aqueous humour drains via the uveoscleral pathway into the lymphatic vessels in the head and neck.

#### **II.1.3d The eye, APCs & MHCs**

APCs, through their ability to express MHC class II molecules, are potent progenitors of the immune response. Moreover, such cells are capable of activating T cells within the tissue itself. It is therefore not unreasonable to assume that a paucity of APCs may play an important role in immune privilege. In addition, failure to express MHC class I molecule would make a tissue immune against the lytic action of the cytotoxic T cells (16, 17).

Although the aforementioned mechanisms are theoretically plausible, cells expressing both MHC class I and II molecules have been detected in the eye. Table 2 illustrates the relationship between histocompatibility class and ocular cell type.

It is noteworthy that the epithelial cells of the crystalline lens are devoid of class I expression and that the Langerhans' cells (class II expression) are absent from the central cornea.

It is interesting that not all cells, which express MHC class II act as professional APCs in the eye. Indeed, it has been shown that such cells reside in the iris and ciliary body and not only fail to present alloantigens to T cells, but have the ability to suppress mixed lymphocyte reactions.



**Table 2:** Relationship between MHC and Ocular cell types

Ocular cell type	MHC class I	MHC class II
Corneal epithelium	•	
Corneal stroma	•	
Corneal endothelium	•	
Trabecular meshwork	•	
Pigmented and non pigmented cells of ciliary body	•	
Anterior iris	•	
RPE cells	•	
Corneal limbus		•
Iris and ciliary body		•
Uveoscleral pathway		•
Ora serrata		•

The failure to incite the inflammatory response has attracted a great deal of interest amongst ophthalmologists and immunologists alike. It appears such suppression is achieved by various factors present in the aqueous humour (e.g. transforming growth factor -  $\beta$ ).

### **II.1.3e Anterior chamber associated immune deviation (ACAID)**

As a result of experiments with rats, investigators (22-24) discovered that antigens placed in the anterior chamber resulted in systemic inhibition of delayed type hypersensitivity (DTH or type IV hypersensitivity) reactions to the same said antigens. This phenomenon has been coined anterior chamber associated immune deviation (ACAID). The anterior chamber is thus able to suppress delayed type hypersensitivity reactions and inhibit the production of complement fixing antibodies. However, it has no inhibitory effect on cytotoxic T cell activity and has a minimal influence on the production of non-complement fixing antibodies.

With respect to the endothelium, two adaptations prevent it from immunological injury: first, avoidance of cytotoxic T lymphocyte (CTL)-mediated lysis; and second, inhibition of DTH responses in the anterior chamber. It achieves the former through the cells inability to express MHC class I molecules. The corollary of this, however, is that virally infected cells may persist in this region.

ACAID is beneficial in reducing the incidence of stromal keratitis in herpes simplex virus infection. It therefore seems reasonable to assume that such an unwanted corneal side effect occurs as a result of a DTH response rather than the toxic effect of the virus per se.

Corneal graft rejection may be due, in part, to failure to invoke ACAID. Streilein et al (25) not only discovered that the immunosuppressive effects of the cornea were abolished in corneas that had ACAID removed via cauterisation or keratoplasty but also abolished in corneas that had been denervated.

## **II.2 OCULAR DEFENSE MECHANISMS**

### **II.2.1 Anatomic Defenses**

The surface of the eye is armed with mechanical and immunologic functions to defend itself against a hostile environment.

The defense mechanisms are native and acquired, both generalized and specific (26). It is manifestly obvious that exposed portions of the eye possess a remarkable defense against microorganisms. To breach this defense, trauma in some form is usually required.

The eyelids provide mechanical protection of the ocular surface. The lashes initiate the blink reflex to protect against airborne particles or trauma. The cornea is exquisitely

sensitive, and tactile stimulation of its surface will also initiate the blink reflex. The lids sweep over the anterior surface of the globe directing tears, debris, microbes, and allergens to the lacrimal excretory system. Lipids secreted by the meibomian glands maintain the stability of the tear film.

**Table 3:** Putative host defense components of human tears and their functions

<b>Tear component(s)</b>	<b>Function</b>
<b>Lactoferrin</b>	Protein synthesized by the lacrimal gland; direct bacteriostatic action on bacteria
<b>Lysozyme</b>	Protein that targets the cell wall and causes bacteriolysis of gram-positive bacteria
<b>b-Lysin</b>	Causes cytolysis of bacteria resistant to lysozyme by targeting the cell membrane
<b>Ceruloplasmin</b>	Regulates damage to ocular tissue during inflammation
<b>Immunoglobulins</b>	Human tears possess IgG, IgM, IgE, and IgA; IgA prevents the adherence of bacteria, modulates the normal flora, agglutinates bacteria, and can neutralize toxins

The eyelids provide mechanical protection of the ocular surface. The lashes initiate the blink reflex to protect against airborne particles or trauma. The cornea is exquisitely sensitive, and tactile stimulation of its surface will also initiate the blink reflex. The lids sweep over the anterior surface of the globe directing tears, debris, microbes, and allergens to the lacrimal excretory system. Lipids secreted by the meibomian glands maintain the stability of the tear film.

The non-keratinized squamous epithelium of the conjunctiva and cornea serves as a protective anatomic barrier against pathogens. The basement membrane and cellular junctional complexes of the cornea contribute to its impermeability (27).

Indigenous ocular flora of the lids and mucosal ocular surface serve a protective function by limiting the opportunity for pathogenic organisms to colonize the surface (28).

The vascular supply to the surface of the eye is a major conduit of the immune defenses. The ocular inflammatory response involves vascular dilation and exudation of immunologically active substances and cells, including macrophages, polymorphonuclear leukocytes, and lymphocytes (29).

### **II.2.2 Defenses of the Tear Film**

The tear film is comprised of three layers: oil, aqueous, and mucous. These layers are produced by the meibomian glands, the lacrimal glands, and the goblet cells of the conjunctiva, respectively. The aqueous layer comprises the majority of the 7-mm-thick tear film. It is produced at a rate of 1 ml per min.

The tear pH, 7.14 to 7.82, likely contributes to the neutralization of toxic substances (29). Tear flow mechanically bathes the anterior surface of the eye, preventing the adherence of microorganisms, and flushes allergens and foreign particles into the lacrimal excretory system. The mucous layer of the tear film entraps foreign material, which facilitates its removal (30). For example, the mucin contained in tears prevents *Candida* spp. from adhering to contact lenses, likely by entrapping the microorganisms (31). The tear film contains several immunologically active substances that participate in both general and specific ocular defense (Table 3).

### **II.2.3 Conjunctival Defense**

Beneath the protective epithelium of the conjunctiva lie a vascular network and lymphoid structures. The conjunctiva associated lymphoid tissue is subepithelial tissue packed with B and T lymphocytes. B-cell precursors mature when exposed to local antigen proceed to

regional lymph nodes where they transform into plasma cells, and then return via the bloodstream to the conjunctiva, where they produce their specific immunoglobulin A (IgA). Similarly, T-cell precursors are locally sensitized, travel to regional nodes, and then hematogenously return to the conjunctiva to provide cellular defense (32).

#### **II.2.4 Corneal Response**

The cornea is a vascular and possesses limited immune defenses. The two main components are the Langerhans cells (dendritic cells), which modulate B and T lymphocyte activity in the cornea, and immunoglobulins, which are concentrated in the corneal stroma (29). The corneal surface is covered by a glycocalyx associated with a layer of mucous glycoprotein.

A subtype of the IgA cross-links with the mucous glycoprotein to cover and protect the anterior surface of the cornea (27).

Upon injury, the corneal epithelium may release a thymocyteactivating factor that incites a local immune response to include polymorphonuclear cells, lymphocytes, and fibroblasts (27).

#### **II.2.5 Cellular Immune Response**

Langerhans cells are concentrated in the epithelium of the peripheral cornea and conjunctiva but sparse in the central cornea (27). Like macrophages, they possess receptors for immunoglobulins, complement, and antigen. The Langerhans cell recognizes, phagocytizes, and processes certain antigens for presentation via the epithelial surface and stroma (29).

Langerhans cells stimulate helper T and B cells that collaborate with other lymphocytes (killer, suppressor T cells) to enlist a strong cellular immune response. During

inflammation Langerhans cells migrate toward the center of the cornea and may participate in the secretion or release of inflammatory mediator substances (33). T cells are mainly present in the conjunctival substantia propria, whereas B cells are more concentrated in the lacrimal gland (29).

### **II.2.6 Leukocyte Defense**

Polymorphonuclear leukocytes possess the ability to ingest and kill microorganisms by two main pathways. The absence of polymorphonuclear leukocytes is associated with fungemia with *Candida*, *Aspergillus*, and *Fusarium* spp. The oxygen-dependent pathway is based on postphagocytic intracellular production of oxygen radicals (oxidants). The oxygen-independent pathway is based mainly on the function of antimicrobial proteins called defensins. Defensins are peptides that possess broad-spectrum antimicrobial activity in vitro, killing a variety of gram-positive and gram-negative bacteria and some fungi (29), including a wide range of ocular pathogens (34).

### **III. BIOLOGY OF THE INFECTIOUS AGENTS RELEVANT TO OCULAR DISEASE**

#### **III.1 VIRUSES**

Viruses are minute, infectious particles ranging in diameter from 20–300 nm (1 nm =  $10^{-9}$  m). They do not have a cellular structure and consist only of genes surrounded by protein. A virus particle, called a virion, consists of nucleic acid (either DNA or RNA) surrounded by a protein coat called a capsid. Some viruses are more complex in that they possess an additional 'envelope' of glycoprotein (protein with attached sugar chains) around the capsid. Since viruses possess nucleic acid they are able to reproduce, but they possess none of the structures normally associated with living cells such as a nucleus or an energy generating system. Hence, viruses have to invade living cells to reproduce and the result of viral reproduction is often the death of the host cells.

Individual types of virus have a preferred site of entry into the body, e.g. some strains of *Adenovirus* attack cells of the conjunctiva, *Orthomyxovirus* and *Picornavirus* the respiratory tract, and *Herpesvirus* the skin. Once within the body, the virus may either cause a local inflammation or it becomes more widely disseminated. Many viruses have a preferred 'target cell' in which to reproduce, e.g. the polio virus attacks the motor neurons of the anterior horn of the spinal cord. Replication of the polio virus takes place within the spinal cord and death of the motor neurons results in paralysis. Once within the body, however, the virus is attacked by the immune system. The immune system may

ultimately overcome the virus, but some virions can remain in the body in an inactive state and result in a series of further infections.

The most important viral organisms involving the eye are the DNA viruses herpes simplex, varicella-zoster, cytomegalovirus, adenovirus, and vaccinia virus (35). All of these agents except CMV may cause acute epithelial infection, sterile trophic ulceration due to basement membrane damage, deep corneal stromal immune reaction, and iritis. Although there are three excellent antiviral drugs commercially available, only HSV and vaccinia virus are highly sensitive to therapy with these antimetabolites; varicella-zoster virus and CMV are equivocally responsive and adenovirus has not been shown to be susceptible to these agents (37). In selected situations, topical or systemic corticosteroids are useful for managing any associated immune reactions in the eyes, but patients on these drugs should be monitored carefully both for superinfections and for interference with tissue healing that might ultimately threaten the integrity of the globe (35-36).

The effects of adenoviruses are usually transient and may be regarded as a nuisance. Infection with herpes simplex or varicella-zoster may lead to prolonged activity of the disease and life-long treatment with occasional loss of useful vision. An episode of herpes simplex infection of the eye often clears without any permanent problem. However, in some cases the infection causes scarring to the cornea. This can lead to permanent loss of vision. Prompt treatment with antiviral eye ointment or drops helps to prevent corneal scarring. The cornea is the transparent 'window' of the eye. Infection of the cornea is called keratitis. In most cases the infection is just in the top layer (superficial layer) of the cornea. This is called epithelial keratitis. Less commonly the



deeper layers of the cornea are involved. This is called stromal keratitis. This is more serious as it is more likely to cause scarring of the cornea (38).

It is apparent that our understanding of the clinical behavior of the major viruses has increased in recent years. Therapeutic criteria and modalities have also improved for some of the complications of the viruses. Much work needs to be done for some of the other manifestations, i.e., failure of re-epithelialisation, stromal melting, scarring, vascularization, and inflammation.

### **III.2 FUNGI**

Fungi are eukaryotic organisms and therefore, possess a cell membrane which encloses several types of discrete cell organelle. The genetic material is in the form of chromosomes which are located within a distinct nucleus. Mitochondria are responsible for the energy requirements of the cell while vesicles and the Golgi apparatus package and transport cellular constituents. Carbohydrates such as trehalose are stored within fungal cells and the cell wall itself is composed of chitin, a substance common in the insect world. Hence, although sometimes classified with plants, fungi are a unique and distinct group of organisms.

Ophthalmologists and optometrists, in particular, and clinicians, in general, must be knowledgeable of the pathogenesis of fungal eye infections. Mycotic eye infections are commonplace. For example, the yeast *Candida albicans* is the most common cause of endogenous endophthalmitis. Filamentous fungi, such as *Fusarium solani* and *Aspergillus flavus*, may constitute up to one-third of all cases of traumatic infectious keratitis (39).

In fungal eye disease, the pathogenesis of the infections is inextricably linked to the epidemiology. Therefore, it is worthwhile at the outset to state several proposed pathogenetic principles of fungal eye disease. (i) It is likely that sustained fungemia with even saprophytic fungi will lead to endophthalmitis. (ii) At the time of initial infection with some of the dimorphic, pathogenic fungi, such as *Histoplasma capsulatum* and *Coccidioides immitis*, an unrecognized fungemia occurs and often leads to endophthalmitis. (iii) The paranasal sinuses, because of their direct communication with the ambient air, harbor saprophytic fungi, which may erode the bony walls of the sinus and invade the eye in certain circumstances, e.g., in a patient with neutropenia. (iv) Trauma, either from vegetable matter or surgery, may introduce saprophytic fungi into the cornea and/or adjacent tissue, giving rise to invasive disease (40).

*Candida* endogenous endophthalmitis occurs as a direct result of the success of modern medical practice that sustains patients' lives with broad-spectrum antibiotics, indwelling central venous lines, parenteral nutrition, abdominal surgery, and cytotoxic chemotherapy. The recent origin of this disease is established by the fact that *Candida* endophthalmitis was first recognized clinically in 1958 (41). *Candida* and *Aspergillus* spp. also cause endophthalmitis in intravenous drug users. Virtually any intravascular prosthesis or device may become contaminated by bloodborne opportunistic fungi, and fungemia arising from such infection may lead to endogenous endophthalmitis (40).

Endogenous endophthalmitis occurring as part of disseminated disease with the dimorphic fungi *H. capsulatum*, *Blastomyces dermatitidis*, and *C. immitis* is uncommon. Patients with disease from these fungi have resided in or traveled through the respective areas of endemicity.

Exogenous endophthalmitis, on the other hand, results from trauma to the globe or preceding keratitis. It may also occur as a postoperative complication of lens removal, prosthetic lens implantation, or corneal transplantation. The vast majority of postoperative eye infections are due to coagulase-negative *Staphylococcus*; however, outbreaks of fungal exogenous endophthalmitis continue to occur episodically. These have been due to perioperative contamination of lens prostheses (43) or contamination of fluids used for irrigation (44) of the perioperative and postoperative eye. *Candida* species are particularly likely to occur in this setting, and infection may be enhanced by the pre- and postoperative use of topical corticosteroids and antibacterial agents.

Mycotic keratitis is usually caused by filamentous fungi and occurs in conjunction with trauma to the cornea with vegetable matter. In the tropics it is common in male agricultural workers. The fungal genera causing keratitis in the tropics are more diverse and include some, such as *Lasiodiplodia theobromae*, that do not grow in temperate regions. Eye trauma is the cause of fungal keratitis in temperate areas as well, but the common fungal genera involved are *Fusarium*, *Alternaria*, and *Aspergillus* (45, 46). Keratitis caused by yeasts such as the *Candida* spp. almost always occur in previously abnormal eyes, e.g., in patients with dry eye, chronic corneal ulceration, or corneal scarring.

A combination of surgery and antifungal drugs is the usual therapeutic approach to most fungal eye infections. For example, *Candida* endogenous endophthalmitis can not be treated with intravenous amphotericin B alone (47). Amphotericin B even in lipid form doesn't get adequately in the eye. The concomitant use of oral 5-flucytosine has been tried with success. Intravitreal injections of 5 to 10µg of amphotericin B may be used

adjunctively, but the intravenous administration of amphotericin B or an oral azole is required, as the endophthalmitis is just one of the many manifestations of disseminated candidiasis. Oral fluconazole, 100 to 200 mg/day for several months, has successfully treated endophthalmitis as well as disseminated disease (48, 49). Keratitis is usually treated with a topical antifungal, sometimes in conjunction with subconjunctival injections of the same drug and/or oral antifungals (50, 51).

### **III.3 PROTOZOA**

Infections of the eye can also be caused by eukaryotic, unicellular protozoa; organisms which are classified within the animal kingdom. The most important organisms in this group to cause ocular infection are *Toxoplasma* and *Acanthamoeba*. *Toxoplasma* is a crescent-shaped protozoan carried by many wild and domestic animals including dogs and cats. By contrast, *Acanthamoeba* is a small free-living amoebic protozoan which is found throughout the world in water, soil and dust.

Infection by *Toxoplasma gondii* (Toxoplasmosis) occurs in all parts of the world with 25–50% of the world's population believed to be affected (52). The primary host, usually a domestic animal, becomes infected by eating mice, birds or the faeces of other animals. Within the animal, the organism reproduces sexually resulting in the formation of cysts. The cysts are shed in the faeces and may remain viable outside the body for up to a year. Once ingested by a human host, however, the cyst releases its infectious trophozoites. The organism is unable to reproduce sexually within the human host but the trophozoites proliferate by cell division and may become disseminated throughout the body. In many cases, toxoplasmosis is a mild disease and self-limiting, but it can cause a severe

infection in AIDS patients and in individuals with a compromised immune system (53, 54, 55).

*Acanthamoeba* moves by amoeboid action, i.e. a section of cytoplasm is extended and the remainder of the cytoplasm flows into this extension. The cyst stage is infectious and the trophozoite stage does not survive outside the body. Once inside the body, however, the trophozoites proliferate and in cases of *Acanthamoeba* keratitis, active trophozoites can be removed from the anterior chamber (56).

First-line therapy of *T gondii*-related chorioretinitis includes the use of pyrimethamine with sulfadiazine (58). Alternative regimens include the use of pyrimethamine with clindamycin, clarithromycin, or azithromycin. Atovaquone has been used alone with success as well (59). Patients infected with HIV and who show signs of previous infection as demonstrated by serologic testing and show evidence of CD4 depletion (CD4 count of  $<100$  cells/mm<sup>3</sup>) should receive primary prophylaxis with trimethoprim-sulfamethoxazole (57). In patients with AIDS who have demonstrated toxoplasmic chorioretinitis, chronic suppressive therapy with sulfadiazine, pyrimethamine, and folic acid should continue indefinitely following initial therapy.

As with fungal infections, the epidemiology of parasitic ocular disease also reflects the habitats of causative parasites as well as the habits and health status of the patient. Additionally, congenital infections may pose diagnostic and treatment challenges. The classes of infection are varied and include protozoa, nematodes, cestodes, trematodes, and ectoparasites. Like fungal endophthalmitis, the geographic location is an important

determining factor in the development of parasitic infections. Additional considerations must include local sanitation and the presence of a vector for transmission as well as the more-complicated life cycles of the parasites and definitive hosts (40).

### **III.4 BACTERIA**

Unlike viruses, bacteria possess a cellular structure and the metabolic systems necessary to derive energy from exogenous sources of nutrients. Bacterial cells, however, differ fundamentally from most other cells including human cells. The chromosomes are not enclosed in a nucleus, the cell wall is composed of peptidoglycan (sugars and amino acids) and not cellulose or chitin, and cellular structures such as mitochondria and chloroplasts are absent. Such cells are classified as prokaryotes whereas all remaining organisms are classified as eukaryotes. There are two types of cell wall in bacteria. Gram positive bacteria have a thick, rigid cell wall whereas Gram- bacteria have a thinner cell wall covered with a lipo-protein layer. The Gram stain reaction is used to distinguish the two types and involves staining bacterial cells with a violet-iodine dye and then extracting the stain with alcohol. The Chlamydiae are an unusual group of Gram- bacteria important in eye disease. They lack the ability to make ATP and are unique among prokaryotes because they reproduce within living cells (61, 62).

Bacteria utilise a variety of extracellular substances to grow and reproduce. First, a wide range of sugars and amino acids are required for growth but individual species may be able to use only a limited range of these substances. Second, some bacteria require oxygen (aerobes) while others can grow only in environments lacking oxygen

(anaerobes). For example, the Gram positive non-spore forming bacterium *Actinomyces*, is an anaerobe which has been isolated from the intraocular fluid in cases of delayed postoperative endophthalmitis (63,65). Third, water is essential for bacterial growth and hence, rapid growth occurs in materials which have high water content. Fourth, growth is temperature dependent with individual species having an optimum between 20–45°C. Fifth, most bacteria grow best at neutral pH conditions although a few species are known to prefer extremes of acidity and alkalinity. Sixth, all bacteria require inorganic ions such as magnesium, iron and chloride.

As bacteria grow, new components are synthesised and incorporated into the bacterial cell wall. When the bacterial cell reaches a certain size, DNA replication occurs and the cell divides into two. An important statistic for a bacterial population is the 'doubling time', i.e. the length of time taken for the population to double in size. For the bacterium *E. coli*, this may be as short as 20 min under ideal conditions and as a result, a large bacterial population can be built up very rapidly. Some bacteria produce spores during their life cycle usually as a response to diminishing levels of nutrients in the environment. Spores survive for a long time in a dormant condition and are resistant to extremes of temperature, pH, desiccation and chemical agents. Thus, it can be difficult to kill bacterial spores and hence, sterilise materials completely (64).

Species commonly present on the surface of the eye include diphtheroids, *Moraxella*, *Staphylococcus*, and *Streptococcus*. The presence of a commensal flora, together with the physical action of the lids and the chemical effect of tears, normally prevent colonization by pathogenic bacteria (67,68).

Nevertheless, infections of the external structures of the eye are common and result from either the acquisition of a particularly virulent microorganism or uncontrolled growth of an existing bacterium due to lowered host resistance.

**Table 4:** Major eye infections caused by bacteria

<b>Lids, Lacrimal apparatus</b>	<i>Staphylococcus</i> blepharitis, esp. <i>S. epidermidis</i> . May develop into a sty or meibomian gland cyst. Syphilis ( <i>Treponema</i> ). Erysipelas caused by haemolytic <i>Streptococcus</i> .
<b>Conjunctiva</b>	Acute conjunctivitis caused by <i>Pneumococcus</i> , <i>Streptococcus</i> , <i>Staphylococcus</i> , or <i>Gonococcus</i> . Granulomatous inflammation associated with tuberculosis and syphilis. Conjunctivitis in infants caused by <i>Haemophilus influenzae</i> , <i>Streptococcus pneumoniae</i> , <i>Klebsiella pneumoniae</i> , <i>Neisseria</i> , or <i>Chlamydia</i> .
<b>Cornea</b>	Keratitis and corneal ulceration caused by <i>Staphylococcus aureus</i> , <i>Streptococcus pneumoniae</i> , <i>Pseudomonas</i> , <i>Mycobacterium</i> , <i>Flavobacterium indologenes</i> , or <i>Serratia</i> .
<b>Uvea</b>	Endophthalmitis caused by <i>Propionibacterium acnes</i> , <i>Staphylococcus epidermidis</i> , <i>Actinomyces</i> and <i>Corynebacterium</i> . Purulent uveitis caused by <i>Staphylococcus</i> . Endogenous granulomatous uveitis associated with leprosy and tuberculosis.
<b>Vitreous Retina</b>	Inflammation and abscess formation. Acute septic retinitis. Chronic bacterial retinitis associated with tuberculosis, leprosy, or syphilis. Papillitis and optic neuritis caused by <i>Staphylococcus</i>
<b>Optic disc/nerve</b>	<i>Pneumococcus</i> , <i>Meningococcus</i> , or <i>Mycobacterium</i> . Orbital cellulitis caused by <i>Staphylococcus aureus</i> , <i>Haemophilus</i>
<b>Orbit</b>	<i>Influenzae</i> , or <i>Streptococcus</i> . <i>Actinomyces</i> infection.



In addition, the globe of the eye is relatively impermeable to microorganisms, but if breached by trauma or surgery, the contents of the eye, such as the aqueous and vitreous, also provide an excellent medium for the growth of bacteria and subsequent infection.

Furthermore, an infection within the eye may be 'endogenous', i.e., a consequence of a systemic disease transmitted to the eye via the blood stream or lymphatic system.

Infection of the eye is very complicated and in most cases patient will face loss of their vision. The following chapters in this thesis will focus on possible solutions to improve this devastating case. Thesis will cover the usefulness of early diagnostics, knowledge of drugs available for eye treatment and their limitation. Finally this thesis will introduce usefulness of drug delivery system to overcome some of short falling treatment for ocular infections (69, 70).

#### **IV. DETECTION OF BACTERIA BY PCR**

The predominant techniques currently used to identify microbial pathogens rely upon conventional clinical microbiology monitoring approaches that are well established suffer from a number of considerable drawbacks. Endophthalmitis is a term referring to severe intraocular inflammation centered around the vitreous cavity and/or anterior chamber of the eye and may be of infectious origin (caused by bacteria or fungi). The challenges presented by this condition to the clinician are considerable, as the severity of the clinical signs varies greatly according to the time to presentation, the inoculum size, and the species of the infecting organism(s) (71, 72). Also, low-grade infections can be difficult to distinguish from purely inflammatory ocular disease. Ideally, all cases of infectious endophthalmitis would be culture proven, but the number of culture-proven cases with typical signs of infectious endophthalmitis varies greatly from center to center (73,71,72). It is important to establish a diagnosis and identify the infecting organism, not only because this decides the further management of the patient but also because it justifies the treatment given. Confirmation of the diagnosis is made more difficult by the small volumes of the ocular samples available for analysis (aqueous, 100 to 150  $\mu$ l; vitreous, 200 to 400  $\mu$ l). The numbers of organisms required to establish an infection can also be small and may be as low as 14 (74), and often only a few colonies are cultured by routine microbiological methods (usually 40 to 50 CFU). A delay of 24 to 48 h is usual for routine microbiological processing of the specimens, although it may take up to 12 days in the case of fastidious organisms (75). In the absence of a definitive identification of the causal organism, the clinician must commence therapy on an empirical basis, using

broad-spectrum antimicrobial agents, because a delay in treatment is often associated with a worse clinical outcome (76).

Clinical cases which are culture negative and respond to antibiotic therapy are considered infectious despite the lack of definitive culture identification. Cultures prove to be negative for a variety of reasons, such as small sample size, sequestration of bacteria on solid surfaces (e.g. intraocular lens, lens remnants, and capsule) leading to low numbers in the liquid sample, the use of antibiotics prior to sampling, and the fastidious nature of some of the organisms which cause intraocular infection (77,78,79).

**Table 5:** Pathogen identification methods

<b>Traditional methods for pathogen identification</b>	<ul style="list-style-type: none"> <li>• Cultivation of organism in laboratory, and subsequent characterization.</li> <li>• Detection of host immune response (e.g., antibodies) to known organism.</li> <li>• Visual detection of "typical" microbial form in host.</li> </ul>
<b>Problems with traditional methods</b>	<ul style="list-style-type: none"> <li>• Cultivation-based methods insensitive for detecting some organisms.</li> <li>• Cultivation-based methods limited to pathogens with known growth requirements.</li> <li>• Poor discrimination between microbes with common behavioral features.</li> <li>• Failure to detect infections caused by uncultivated (e.g., novel) organisms, or organisms that fail to elicit a detectable host immune response.</li> <li>• Visual appearance of microorganisms is nonspecific.</li> </ul>
<b>Examples of failures with traditional approaches</b>	<ul style="list-style-type: none"> <li>• Detection and speciation of slow-growing organisms takes weeks (e.g., <i>M. tuberculosis</i>).</li> <li>• A number of visible microorganisms cannot be cultivated (e.g., Whipple bacillus).</li> <li>• Diseases presumed to be infectious remain ill-defined with no detected microorganism (e.g., abrupt fever after tick bite).</li> </ul>
<b>New molecular methods</b>	<ul style="list-style-type: none"> <li>• Use of genetic (DNA or RNA) sequences to identify microorganisms plus DNA amplification procedures (e.g., polymerase chain reaction, PCR) leads to development of specific and consensus PCR methods.</li> <li>• Other experimental sequence-based molecular methods for detection of novel microorganisms (e.g., "representation difference analysis").</li> </ul>
<b>Advantages of PCR</b>	<ul style="list-style-type: none"> <li>• Rapid (hours).</li> <li>• Specific (can distinguish among different strains of same species).</li> <li>• Sensitive (can detect one microorganism in some cases).</li> <li>• Can be automated</li> </ul>
<b>Disadvantages of PCR</b>	<ul style="list-style-type: none"> <li>• Technically demanding</li> <li>• Risk of contamination</li> <li>• Can be expensive</li> <li>• Need rigid QC</li> </ul>

At Moorfields Eye Hospital, the institute of Ophthalmology, the Group of Professor Lightman have demonstrated that the efficient elimination of this DNA from participation in the amplification reaction is reliably achieved by pretreatment of the polymerase with a restriction endonuclease, before first-round PCR amplification (80-83).

In their studies they applied molecular biologic techniques to the detection and identification of bacteria in ocular samples. Bacterial DNA was successfully detected using PCR and identified using RFLP, DNA sequencing, and cloning techniques. Their study has demonstrated that by using PCR-based techniques, bacterial DNA can be found in 100% of samples from patients with typical clinical signs of bacterial endophthalmitis, whereas routine microbiologic analysis yielded positive results in only 68% of eyes. Vitreous was shown to be the sample of choice for both PCR and microbiologic analysis. Although PCR techniques cannot recover organisms for subsequent analysis (e.g., antibiotic testing), the molecular diagnosis of antibiotic resistance is increasingly becoming a reality (84). Also, in the analysis of culture-negative samples it is only by the use of PCR that a microbiologic diagnosis can be obtained.

The work done at the Institute demonstrated that the presence of infection was associated with a higher sample protein level suggestive of a reactive immune response. The higher protein levels in samples from eyes with gram-negative infection reflected the greater inflammatory response triggered by these organisms and the greater degree of ocular inflammation seen clinically in these patients. The higher protein levels in infected eyes and the similarity of protein levels between culture-positive and culture-negative samples containing similar bacterial sequences suggests that the bacterial sequences identified by PCR are significant markers of infection and not indicators of colonization. The protein

assay was not only useful in assessing the relevance of detected bacterial sequences but also demonstrated prognostic significance for visual outcome. Similar results have reported in the study by Druel et al. (85), in which cerebrospinal fluid (CSF) obtained from all patients after craniotomy, who showed clinical signs of meningitis, was compared with CSF from patients who underwent craniotomy and had no clinical evidence of infection. PCR confirmed the clinical suspicion, and results indicated that the inflammatory markers in the CSF were similar in all PCR-positive patients (whether culture positive or negative) and greater than for all PCR-negative patients, suggesting a true correlation with clinical disease.

It is important to establish a diagnosis and identify the infecting organism, not only because this decides the further management of the patient but also because it justifies the treatment given.

Correct treatment requires knowledge and understanding of the properties of drugs available for ocular treatment. The next chapter we will review current available drugs for treatment of eye infection with focus on topical application of eye drugs as the most drugs use for patient is topical. The chapter will complete by presentation for the first time the effort we have put at Moorfields Eye Hospital, Pharmacy department, in creating a hand out for physicians on ocular products.

## **V. DISPOSITIONS OF OPHTHALMIC DRUGS**

The appropriate use of antibiotics to treat ocular infection requires an understanding of the disease processes being treated and knowledge of the pharmacology and pharmacokinetics of the drugs used. The prompt use of the appropriate antibiotics is essential to preserving vision in the presence of severe eye infection such as bacterial keratitis or endophthalmitis. We will review antibiotic therapy for various ocular infections.

### **V.1 GENERAL PRINCIPLES OF ANTIBIOTIC THERAPY**

Antibiotic therapy may result in killing the microorganism (bactericidal drugs) or inhibiting bacterial growth (bacteriostatic drugs). When bacteriostatic drugs are used to treat ocular infection, the host defense mechanisms are ultimately responsible for clearing and eradicating the infective organism. In bacterial keratitis, the infection develops in the vascular cornea, and in endophthalmitis it develops in the fluid-filled aqueous or vitreous cavity. In either case, the immune system may be unable to control the organism fast enough to prevent sight-threatening sequel.

Within the first 24 hours pathogens may multiply and release toxins and degradative enzymes that destroy the function and integrity of ocular tissues. Thus, bactericidal drugs are preferred for the treatment of severe ocular infection. The penicillin, cephalosporins, aminoglycosides, and fluoroquinolones are bactericidal agents and are generally used to treat ocular infection. Tetracycline, erythromycin, chloramphenicol, and sulfonamide are

bacteriostatic and are often reserved for less severe infections or where there is a specific benefit such as tetracycline in the treatment of ocular rosacea.

Antimicrobial resistance is a constant concern to physicians, and resistance is found to ampicillin, gentamicin, tobramycin, newer cephalosporins, and fluoroquinolones (86,87,88,89).

In general, it is thought that with frequent and persistent long-term use of a given antibiotic, there is a greater chance of bacterial strains developing with resistance to that drug. To date, there have been no studies documenting increased resistance of bacteria following the treatment of acute bacterial conjunctivitis or following the short-term use of prophylactic topical antibiotics (90, 91).

It may be that increased antibiotic resistance for a given drug is related to the total area of the body treated or the systemic concentrations of the drug. Thus, antibiotics administered topically to the eye may not affect bacterial resistance to a substantial degree. On the other hand, there remains legitimate concern that drug resistance will occur when topical antibiotics (particularly bacteriostatic agents) are used for prolonged periods.

Topically applied antibiotics are capable of delivering high concentrations of antibiotics to the site of infection in most cases. With conjunctivitis and keratitis, the antibiotic is directly applied (by topical drops or ointments) to the area of infection. With endophthalmitis, topical antibiotics must transit the cornea, and therapeutic concentrations may not be achieved within the eye (92). The factors that influence the intraocular penetration of antibiotics include the charge of the drug, the status of the

corneal epithelium, the degree of ocular inflammation, the formulation and concentration of the drug, and the dosage regimen employed (93).

The chemical properties of a drug influence its intraocular penetration through its ability to diffuse across the layers of the cornea. The outer epithelial layer is rich in lipids, whereas the inner stroma of the cornea is composed primarily of water (about 70%). Biphasic solubility is necessary for a molecule to diffuse across both the epithelium and the stroma. The pH and buffering system of an antibiotic's formulation can profoundly influence its ocular penetration, as can the molecular size of the drug (93).

Most commonly used ophthalmic antibiotics are molecularly small enough to diffuse through biologic membranes without difficulty, but bacitracin and colistin and other polymyxins are higher-molecular-weight antibiotics that penetrate the cornea poorly.

## **V.2 OVER-THE-COUNTER OPHTHALMIC PREPARATIONS**

Medicinal products promoted, recommended or marketed for use as eye-drops or eye ointments are not available for general sale they are all classified as pharmacy medicines (93). Although ophthalmic complaints did not feature as one of the top 10 ailments for self-treatment recently described by Huw and Noyce (94) there are a number of eye disorders which may be treated by over-the-counter (OTC) preparations. Conjunctivitis is the first condition discussed in this article. This disorder is an inflammation of the mucous membrane that lines the eyelids and covers the anterior surface of the eye (excluding the cornea). Conjunctivitis may result from microbial infection or be allergic in origin. Both types are amenable to treatment with OTC preparations. The OTC treatment of dry eye conditions is also discussed in this article. Table 6 describes the



preparations available for OTC treatment of conjunctivitis, dry eye conditions and other minor eye irritations.

**Table 6:** Ophthalmic preparations classified as pharmacy medicines

<b>Drug category</b>	<b>Drug</b>	<b>Products containing drug</b>
Antihistamines	Antazoline	Otrivine-Antistin*
	Levocabastine	Livostin Direct*
Antimicrobials	Dibromopropamide isethionate	Brolene, Golden Eye ointment
	Propamide isethionate	Brolene*, Golden Eye drops*
Artificial tears	Carbomer 940 (polyacrylic acid)	GelTears*, Viscotears
	Dextran 70	Tears Naturale*
	Hydroxyethylcellulose	Minims Artificial Tears
	Hypromellose	Artelac, Isopto Alkaline*, Isopto Plain*, Moisture-eyes*, Tears Naturale*, Hypromellose eye-drops*
	Liquid paraffin	Lacri-Lube, Lubri-Tears, Simple eye ointment BP
	Polyvinyl alcohol	Hypotears*, Liquifilm Tears*, Liquifilm Tears preservative-free, Refresh, Sno Tears*
	Povidone	
Astringents	Sodium chloride	Minims Sodium Chloride
	Distilled witch hazel	Eye Dew Blue*, Eye Dew Clear*, Optrex drops*, lotion*, I-Doc, Optrex Clear Eyes*, Optrex Fresh Eyes*
	Zinc sulphate	Zinc Sulphate eye-drops BPC*
Mast cell stabilisers	Sodium cromoglicate	Boots Hayfever Relief Allergy eye-drops*, Clariteyes*, Hay-Crom Hayfever eye-drops*, Lloyds Hayfever Allergy eye-drops*, Optrex Allergy eye-drops*, Opticrom Allergy eye-drops*
Stains	Fluorescein	Minims fluorescein sodium

	Rose bengal	Minims rose bengal
Sympathomimetics	Adrenaline	Adrenaline eye-drops, neutral BPC*
	Naphazoline	Eye Dew Blue*, Eye Dew Clear*, Murine*, Optrex Clear Eyes*
	Phenylephrine	Isopto Frin, Minims phenylephrine hydrochloride
	Xylometazoline	Otrivine-Antistin*
*Contains benzalkonium chloride and should not be used while wearing soft contact lenses		

### **V.2.1 Infective conjunctivitis**

Infective conjunctivitis can be bacterial, viral, chlamydial or fungal in origin. *Staphylococcus* species are the most common infecting bacteria in the United Kingdom, but others include *streptococcus* and haemophilus species (95).

Infective conjunctivitis is characterised by a diffuse redness of the conjunctiva with a purulent (bacterial) or watery (viral) discharge. Viral infections are commonly associated with upper respiratory tract infections and swollen pre-auricular nodes. Most cases of infective conjunctivitis are self-limiting but can be treated with the antimicrobial diamidines propamide isethionate or dibromopropamide isethionate. Antimicrobials Historically, Golden Eye ointment contained mercuric oxide. This product was discontinued because of concerns about absorption and the adverse effects of inorganic mercury. In 1992, the brand name was used again when Golden Eye drops and ointment were reintroduced. These new products contain a diamidine as an antimicrobial and are an alternative to the well-established brand Brolene.

Brolene and Golden Eye drops contain the diamidine propamide isethionate which has antibacterial, trypanocidal and fungicidal activity and is active against *Staphylococcus*

aureus, *Streptococcus pyogenes* and certain other *streptococci* and *clostridia*. The ointment preparations contain dibromopropamide isethionate which has antibacterial and antifungal properties. It is active against *S. pyogenic Cocci*, *Staphylococcus aureus*, and certain Gram-negative bacteria, including *Escherichia coli*, *Proteus vulgaris* and some strains of *Pseudomonas aeruginosa*. Fungi susceptible to the drug include *Aspergillus niger* and *Candida albicans*. The antibacterial activity of these diamidines is not reduced in the presence of organic matter, such as tissue fluids, pus and serum. Both drops and ointment are licensed as "an anti-infective for use in local infections of the superficial structures of the eye due to micro-organisms sensitive to its action." The products may be used in adults and children at a frequency of up to four times a day for the drops and once or twice a day for the ointment.

If no improvement is seen within two days, medical opinion should be sought. The aim of antimicrobial therapy is to achieve a concentration of the antimicrobial agent at the site of infection high enough to kill or stop the growth of the infecting organism. It is doubtful that the licensed frequency of administration will achieve this, and Edwards and Stillman suggest hourly use of propamide isethionate eye-drops (96).

Combining this intensive therapy during the day with the longer-acting eye ointment at night will increase the possibility of resolving the infection. Propamide isethionate, in combination with a wide range of agents, has been used in the treatment of *Acanthamoeba keratitis* (97). This use of the product is outside its current product licence.

### **V.2.2. Allergic conjunctivitis**

Several types of hypersensitivity reactions in the eye are recognised. Those amenable to treatment with OTC medicines are of the immediate hypersensitivity type and include acute allergic conjunctivitis, seasonal or hay fever conjunctivitis and vernal keratoconjunctivitis.

In all cases, the disease process is thought to be initiated by allergens combining with immunoglobulin E which is bound to conjunctival mast cells. This interaction causes mast cell degranulation leading to the release of numerous chemical mediators, such as histamine (98). These mediators trigger the inflammatory cascade, resulting in vasodilatation, increased vascular permeability and oedema and give rise to the classical symptoms of allergic conjunctivitis.

Preparations used to treat allergic conjunctivitis contain mast cell stabilisers, antihistamines, sympathomimetics and astringents.

### **V.2.3 Dry eye conditions**

The term "dry eye" refers to a group of ocular disorders related to deficiencies in the quantity and/or quality of the tear film. Dry eye may result from dysfunction or absence of the meibomian glands which secrete the lipid component of the tears, deficiency of the basal mucin layer of the tears or aqueous tear film deficiency. A decreased blink rate or defective spreading of the tear film may also result in a dry eye. Dry eye is most frequently encountered in menopausal and postmenopausal women, but can affect individuals at any age and of either sex. Non-pharmacological measures, such as the use of room humidifiers, may offer the patient a degree of relief but the mainstay of pharmacological treatment is artificial tears, many of which are available OTC (99).

### **V.3 PRESCRIPTION DRUG: TOPICAL OCULAR ANTIBIOTICS**

Fifteen antibiotics are listed in the section relating to topical ocular antimicrobials in the British National Formulary (see Table 7). Eady and Cove (100) suggest that an ideal topical antibiotic should not be related to an oral drug and should be restricted to topical use only. It should not select for cross-resistance or, more importantly, for multiple-resistance to unrelated antibiotics and it should have a broad enough spectrum of activity to be used as a single agent. Of the currently available topical ocular antibiotics, none fulfill all of these criteria.

**Table 7:** Commercially available topical ophthalmic preparation containing antibiotics

<b>Antibiotic</b>	<b>Formulation</b>	<b>Combination antibiotic preparations</b>	<b>Other combinations</b>
Bacitracin		Polyfax eye ointment	
Chloramphenicol	Eye-drops 0.5 per cent Unit dose eye drops 0.5 per cent Eye ointment 1 per cent		
Chlortetracycline	Eye ointment 1 per cent		
Ciprofloxacin	Eye-drops 0.3 per cent		
Dibromopropamide isethionate	Eye ointment 0.15 per cent		
Framycetin	Eye-drops 0.5 per cent Eye ointment 0.5 per cent		Sofradex eye ointment Sofradex eye-drops
Fusidic acid	Eye-drops 1 per cent		
Gentamicin	Eye-drops 0.3 per cent.		

	Unit dose eye-drops 0.3 per cent		
Gramicidin		Neosporin eye-drops	
Lomefloxacin	Eye-drops 0.3 per cent		
Neomycin	Eye-drops 0.5 per cent (3500 units/ml) Eye ointment 0.5 per cent (3500 units/g) Single dose eye-drops 0.5 per cent	Neosporin eye-drops	Betnesol-N eye ointment Vistamethasone-N eye-drops Betnesol-N eye-drops FML-Neo eye-drops Maxitrol eye-drops and ointment Neo-Cortef eye-drops and ointment Predsol-N eye drops
Ofloxacin	Eye-drops 0.3 per cent		
Polymyxin B		Neosporin eye-drops Polyfax eye ointment Polytrim eye-drops and ointment	Maxitrol eye-drops and ointment
Propamide isethionate	Eye-drops 0.1 per cent		
Trimethoprim		Polytrim eye-drops and ointment	

Topical antibiotics are used to treat bacterial conjunctivitis, blepharitis, keratitis and external hordeola (styes). They are also used as adjunctive treatment in cases of endophthalmitis (inflammation within the eyeball) and prophylactically to prevent infection before and after ophthalmic surgery.

Treatment is usually empirical and topical agents should be active against the most likely pathogens, namely *Staphylococcus aureus*, coagulase negative *staphylococci*, *streptococci*, *Haemophilus influenzae* and coliforms. Infection with *Pseudomonas*

*aeruginosa* is less common. However, *P. aeruginosa* was found to be responsible for almost half the bacterial resistance to chloramphenicol encountered in a total of 334 strains isolated from bacterial infection of the eye (95).

### V.3.1 AMINOGLYCOSIDES

Three aminoglycosides are used as topical ocular agent neomycin, its isomer framycetin which is derived from *Streptomyces*, and gentamicin derived from *Micromonospora* of these, gentamicin has the broadest antibacterial spectrum, with activity against *Pseudomonas aeruginosa*, although aminoglycosides are not generally active against *streptococci*. Neomycin also has activity against the protozoa *Acanthamoeba*.

Neomycin is the oldest of the ocular aminoglycosides. It is rarely used alone, but is widely used as prophylaxis in combination with corticosteroids following ocular surgery. Neomycin possesses antiprotozoal activity and is sometimes used in the treatment of *Acanthamoeba* keratitis; however, because of poor cysticidal activity (101), it is normally used in combination with other agents. When neomycin is combined with a diamidine, it has an additive effect (102, 103).

Topical ocular application of neomycin frequently results in sensitisation to the drug, which can lead to contact dermatitis in approximately 4 per cent of patients.

Framycetin has been in clinical use since the 1950s but there is little information in the literature about its use as a topical ocular agent. Brunette (104) reported a clinical study of the drops and ointment in 93 cases of ocular infection and 68 cases where the drug was used as prophylaxis against infection. He described framycetin as an excellent antibiotic for topical use. The study demonstrated a broad spectrum of antibacterial activity for

framycetin, together with a very low rate of patient sensitivity. However, the antibiotic has been shown to be less effective than fusidic acid in a more recent open randomised trial in Tanzania (105). Dirdal compared fusidic acid administered four times a day for the first day, then twice daily, with framycetin given eight times daily on the first day, then four times a day, for a period of seven to 14 days. Seventy-three children under six months of age with suspected bacterial conjunctivitis were assessed and both clinical and microbiological success rates were significantly higher in the fusidic acid group.

In the past, gentamicin was often used for the treatment of bacterial conjunctivitis as an alternative to chloramphenicol in patients allergic to chloramphenicol. However, the availability of newer, less toxic agents (106), increasing resistance to the aminoglycosides (107), poor ocular penetration (108, 109), and the discontinuation of the ointment form, thought by certain authors to be a more effective drug delivery system (110), has reduced its use. Nevertheless, in specialist centres, gentamicin is still widely used in a fortified form (1.5 per cent), normally at a concentration of 1.5 per cent in combination with a beta-lactam antibiotic in the treatment of bacterial corneal ulcers (111).

### V.3.2 CHLORAMPHENICOL

Chloramphenicol, an antibiotic originally isolated from *Streptomyces venezuelae*, but now mainly produced synthetically, was introduced into clinical use in 1948. It is highly active against most Gram-negative and Gram-positive pathogens, *Rickettsia* and *Mycoplasma*. Enterobacteria show variable resistance and *Pseudomonas aeruginosa* and *Mycobacteria* are usually resistant.



Chloramphenicol is, in many ways, an ideal drug for topical use. It is the gold standard for the treatment of conjunctivitis against which other topical treatments are tested. Chloramphenicol's spectrum of activity covers the majority of ocular pathogens. In a study of 738 patients with acute bacterial infections of the external eye, Seal *et al* (95) found an overall resistance rate of only 6 per cent to chloramphenicol, compared with 9 per cent to tetracycline and around 20 per cent to the aminoglycosides tested. Chloramphenicol penetrates well into the aqueous humour after topical application (112), has low ocular surface toxicity, and low rates of development of resistance. In May, 1995, a controversial article in the *British Medical Journal* opened a debate about a link between use of topical chloramphenicol and blood dyscrasias. Doona and Walsh (113) recommended that the use of chloramphenicol should be restricted and that framycetin and fusidic acid were safer and equally effective alternatives. A large number of ophthalmologists and haematologists countered this view and highlighted the extremely large number of prescriptions of chloramphenicol dispensed, the small number of blood dyscrasias reported and the lack of proof of causality in these cases. The evidence for and against this association has been reviewed (114).

Since this review, three papers have helped clarify the situation. One group of workers investigated serum levels of chloramphenicol following topical application and two groups reported the results of observations in cases of aplastic anaemia.

Walker *et al* (115) reported that the more common form of chloramphenicol toxicity, reversible marrow suppression, occurs in a dose-dependent manner with sustained serum levels greater than 25mg/L. The researchers measured serum levels of chloramphenicol in subjects after one to two weeks of treatment with four times daily instillation. They found

that serum levels did not accumulate to detectable levels of 1mg/L and concluded that topical chloramphenicol did not present a risk of inducing dose-related bone marrow toxicity.

Lancaster *et al* (116) used the general practice research database to describe prescribing patterns of chloramphenicol eye-drops and to estimate the risk of aplastic anaemia after their use. Three patients with serious haematological toxicity and one who developed mild, transient leucopenia that was not considered serious were identified among the 442 patients who received 148 prescriptions for chloramphenicol eye-drops. The researchers concluded that, even in the unlikely event that all three cases were caused by chloramphenicol eye-drops, these data indicated that the risk of serious haematological toxicity after treatment with ocular chloramphenicol was small. They added that chloramphenicol eye-drops were cheap and effective and that their continued use for eye infections seemed to be a safe clinical strategy.

Wilholm *et al* (117) conducted two population-based studies using virtually identical protocols, representing about 185m person years of observation in industrialised and developing countries. Among more than 400 cases of aplastic anaemia, there was no use of chloramphenicol eye-drops, although associations were found for several other previously suspected drugs.

The authors concluded that their data provided no support for the claim that chloramphenicol eye-drops increased the risk of aplastic anaemia and that the recommendation that the eye-drops should be avoided because of an increased risk of aplastic anaemia was not well founded. This opinion is echoed in the current edition of

the BNF. However in the USA, chloramphenicol drops are not used because of the potential blood dyscrasia problem.

### V.3.3 CHLORTETRACYCLINE

Since the discontinuation of tetracycline eye-drops and ointment, chlortetracycline eye ointment is the only tetracycline available for topical ocular use. Chlortetracycline ointment is licensed for the treatment of superficial eye infections, including trachoma, caused by organisms sensitive to the drug. The ointment is applied up to three times a day, or more frequently if required.

Chlortetracycline is a broad spectrum, bacteriostatic antibiotic, isolated in the 1940s from *Streptomyces aureofaciens*. It exhibits in vitro activity against *Staphylococci*, *Streptococci* and all other common Gram-positive pathogens. It also inhibits coliforms, Haemophilus species, Neisseria species and most other Gram-negative organisms, with the exception of *Pseudomonas aeruginosa*. Tetracyclines are actively concentrated within phagocytes and are therefore useful against intracellular pathogens such as Chlamydia (118). Resistance of some of the more common microbial pathogens, such as *Staphylococcus aureus*, has led to a decline in its use (119).

Ophthalmia neonatorum, a notifiable disease, is a purulent discharge from the eyes of an infant during the first 28 days of life. Although chloramphenicol is probably the most effective antibiotic to use first-line, chlortetracycline should be used if chlamydial infection is detected (120).

Topical tetracyclines have been shown to be as effective as the more toxic silver nitrate (formerly used as a 1 per cent solution) as prophylaxis in gonococcal and chlamydial

disease (121). However, despite the in vitro activity of tetracyclines, in practice topical application may not be highly effective against *Chlamydia trachomatis* eye infections in neonates. In one study, Rettig *et al* (122) found a higher rate of chlamydial conjunctivitis in babies treated with 1 per cent tetracycline ointment than in those treated with intramuscular penicillin.

In addition, topical tetracyclines will not eradicate systemic chlamydial infection. In practice, topical therapy is combined with oral erythromycin.

A small single-masked study by Tabbara *et al* (123) found similar rates of resolution (63 to 65 per cent) when active trachoma was treated with a seven-week course of a topical tetracycline or a single, oral dose of azithromycin.

#### V.3.4 FUSIDIC ACID

Fusidic acid is a steroid-like antibiotic first isolated from the fermentation products of the fungus *Fusidium coccineum* in 1962. It has the greatest anti-*staphylococcal* activity (both coagulase positive and negative) of any topical ocular antibiotic currently available (124). Fusidic acid is formulated as a microcrystalline suspension in a carbomer gel. The drug penetrates well into the eye following topical application, giving a median level of 0.8mg/ml in the aqueous humour 12 hours after the last dose, a level comparable to, or higher than, that seen after systemic administration (125). Tear fluid concentrations of fusidic acid fall from 15.7mg/ml one hour after instillation to 5.6mg/ml at 12 hours (126). The high tear fluid levels of the drug maintained during the 12-hour dosing interval help to explain why several trials of fusidic acid in the treatment of conjunctivitis have shown

it to be as effective as chloramphenicol. In theory, chloramphenicol has a much broader spectrum of activity than fusidic acid.

Sinclair and Leigh (127) compared 12-hourly application of 1 per cent fusidic acid eye-drops and three-hourly administration of 1 per cent chloramphenicol ointment in 489 domiciliary patients with acute conjunctivitis. Both treatments were equally effective clinically, with 83 per cent of the patients given fusidic acid and 84 per cent of the patients given chloramphenicol becoming asymptomatic after five days of treatment. Similar numbers of patients (9 per cent) in each group improved but were symptomatic, and there were equal numbers of failures (7 per cent) in each group. Pathogens were isolated in 25.8 per cent of patients treated with fusidic acid and in 28 per cent of the chloramphenicol group. These included *S aureus*, *Streptococcus spp*, *Haemophilus spp*, *Neisseria sp* and *Moraxella sp*. One isolate (of 14) of *Streptococcus pneumoniae* was resistant to the antibiotic in each group, three isolates (of 13) of *Haemophilus parainfluenzae* and one isolate of *Moraxella* (of 2) were resistant to fusidic acid. Adverse effects were reported by 14.8 per cent of patients using fusidic acid and 10.7 per cent of patients using chloramphenicol, but withdrawal from the chloramphenicol group was higher (4.3 per cent) than that in the fusidic acid group (0.8 per cent). The most common adverse effect in the fusidic acid group was "smarting/irritation/stinging," reported by 9.7 per cent of patients. The authors concluded that the sustained release formulation of fusidic acid enables a twice daily dosage regimen to be employed, without any loss of efficacy, and with high patient acceptability.

The patient acceptability of fusidic acid was confirmed in a study (unpublished), presented by Murray and Evans at the annual conference of the British Association of

Accident and Emergency Medicine, in 1992. The researchers compared fusidic acid with chloramphenicol eye-drops in a randomised crossover trial of 41 accident and emergency patients with clinically diagnosed acute conjunctivitis. Adverse effects of local discomfort, itching and stinging with chloramphenicol were reported by 12 per cent of patients, while only one patient (2 per cent) complained of stinging with fusidic acid. Of 29 respondents questioned about ease of application, compliance and treatment preference, only two patients found chloramphenicol easier to apply than fusidic acid, and only one patient preferred chloramphenicol to fusidic acid.

Although the proprietary product Fucithalmic is only licensed for the treatment of bacterial conjunctivitis, a number of publications have reported its successful use for other unlicensed indications. These include twice daily instillation as prophylaxis following squint surgery (128), four times daily instillation for seven days to reduce bacterial load on the lids and conjunctiva prior to cataract surgery (124), and a single dose as prophylaxis following corneal abrasion (129). Seal *et al* suggest that the efficacy of fusidic acid applied twice daily to the inferior fornix and eye lid margins in patients with recurrent blepharitis associated with rosacea (130) may be due not only to the antistaphylococcal action of the antibiotic but also to its immunosuppressive action which has been compared to that of cyclosporin A (131).

#### V.3.5 DIAMIDINES

The antibacterial activity of diamidine compounds has been covered in a previous article (132). However, these compounds have also been used in the treatment of *Acanthamoeba keratitis* since the mid 1980s (133). Propamidine alone, or more usually in combination

with other agents, has been the mainstay of medical therapy in this protozoal infection of the cornea, which is frequently associated with the use of contact lenses (134). An in vitro study has shown that propamidine is more effective than pentamidine against *Acanthamoeba hatchetti*, equally potent against *A polyphaga* but less effective against *A castellani*. The commercial product, Brolene, had a lower minimal amoebicidal concentration against *A polyphaga* and *A castellani* than propamidine and pentamidine, but a concentration for *A hatchetti* was not determined. Both drugs were relatively non-toxic after short-term contact with cell cultures (135).

Propamidine 0.1 per cent has been successfully used in the treatment of *Acanthamoeba keratitis* in combination with neomycin and polyhexamethylene biguanide (PHMB) (136), with neomycin (137), with polyhexamethylene biguanide (138), and with chlorhexidine (139). In a retrospective multicentre study of 218 patients with confirmed or presumed *Acanthamoeba keratitis*, Radford *et al* (140) reported that all patients had received treatment with propamidine. The drug was rarely used alone (2 per cent of cases), but was combined with: PHMB (50 per cent), neomycin and PHMB (14 per cent), neomycin (7 per cent), chlorhexidine (7 per cent), neomycin and chlorhexidine (6 per cent), PHMB and chlorhexidine (4 per cent), neomycin, PHMB and chlorhexidine (3 per cent), or PHMB and a topical antifungal (3 per cent). The proportion of patients retaining good visual acuity was highest in the propamidine plus PHMB and propamidine plus chlorhexidine groups. The authors believe that the cationic antiseptics, chlorhexidine and PHMB, facilitate entry of the aromatic diamidine propamidine into the protozoan cell.

### V.3.6 FLUOROQUINOLONES

Three topical ocular fluoroquinolone antibiotics are available in the United Kingdom - ciprofloxacin, ofloxacin and lomefloxacin. A fourth product, norfloxacin, was discontinued by the manufacturer in 1996 for commercial reasons.

Although the spectrum of activity of the three antibiotics is broadly similar, one review compared the MIC<sub>90</sub> (minimum inhibitory concentrations of antibiotic at which the growth of 90 per cent of isolates is inhibited) of seven quinolones, including ciprofloxacin and ofloxacin, in clinical isolates of 19 species (141). The author reported superior activity of ciprofloxacin in 13 species, equal activity in five species and greater ofloxacin activity in one species, *Bacteroides fragilis*.

A similar review (142) of the in vitro activity of eight quinolone antibiotics, including ciprofloxacin, lomefloxacin and ofloxacin, against 37 species, also confirmed superior activity of ofloxacin against *Bacteroides fragilis* and listed *Peptostreptococcus* spp as more susceptible to ofloxacin. Lomefloxacin was recorded as the most active of the three quinolones against *Enterococci* sp, *Brucella* sp and *Chlamydia trachomatis*. The MIC was lowest with ciprofloxacin for 17 species, lower with ciprofloxacin and ofloxacin in 13 species and lower with ciprofloxacin and lomefloxacin in two species.

Uchida (143) used clinical isolates of 1,197 strains of 78 species and showed that both lomefloxacin and ofloxacin had broad antibacterial spectra but that ofloxacin was more potent than lomefloxacin. Lewin and Smith (144) proposed that the equipotence of ciprofloxacin and ofloxacin against certain *Staphylococci* is because of a second mechanism of action by ofloxacin, not seen with ciprofloxacin against these isolates.



Clinical efficacy, however, does not depend solely upon the *in vitro* measurement of the MIC. One study compared the penetration of topically applied ciprofloxacin, norfloxacin and ofloxacin to the aqueous humour in patients undergoing cataract extraction (145). The authors concluded that the intraocular penetration of ofloxacin was significantly better than that of ciprofloxacin and norfloxacin.

The superior penetration of ofloxacin has been confirmed in a similar, recently published study where levels of ofloxacin in the aqueous humour were found to be four times higher than those of ciprofloxacin (146). Moreover, levels of ofloxacin in the tear film four hours after topical administration exceed the MIC<sub>90</sub> for a wide range of ocular isolates (147).

Topical lomefloxacin also penetrates well into the aqueous humour, according to one study. However, in this study the author did not compare the penetration of lomefloxacin against that of other quinolones (148).

Ciprofloxacin eye-drops are indicated for the treatment of corneal ulcers and superficial infections of the eye and adnexa (accessory parts or appendages) caused by susceptible organisms. A maximum duration of therapy of 21 days is recommended. The safety and efficacy of ciprofloxacin eye-drops in children under the age of one year has not been established.

Ciprofloxacin has been compared with chloramphenicol and tobramycin in the treatment of conjunctivitis and blepharitis. Power *et al* investigated the efficacy of ciprofloxacin and chloramphenicol in 57 culture-positive patients and reported that the difference between the groups was not significant (149). Safety was also similar, with only one patient from each treatment group suffering an adverse event. Liebowitz (150) compared

ciprofloxacin with tobramycin in a placebo controlled trial of 288 culture-positive patients with bacterial conjunctivitis. Both antibiotics were highly effective and significantly superior to placebo.

In a prospective, multicentre clinical study, the same author compared the clinical and antibacterial efficacy of ciprofloxacin 0.3 per cent with that of standard dual therapy in 148 culture proven cases of bacterial keratitis (ie, bacteria had been cultured) (151). Most patients in the standard dual therapy group received cefazolin 3.3 per cent with gentamicin or tobramycin 1.4 per cent. Success rates were similar at 92 per cent for ciprofloxacin and 88 per cent for the dual therapy. The most frequently noted untoward ocular event associated with ciprofloxacin therapy was a white crystalline precipitate, commonly located in the superficial portion of the corneal defect (ie, the area of inflammation). This problem was encountered in 35 (16.6 per cent) of patients. A group of ophthalmologists involved in the multicentre study noted the appearance of the white precipitate as the only potentially adverse effect in the ciprofloxacin group (152). Although the precipitate resolved in all patients and did not appear to cause any scarring, they saw it as a disadvantage because it caused a temporary decrease in vision and prevented adequate evaluation of the corneal infiltrate. Precipitation of ciprofloxacin occurs as a result of a change in the pH of the eye-drop as it mixes with the tear film (153).

Lomefloxacin is indicated for the treatment of acute bacterial conjunctivitis. Following a loading dose of one drop in the affected eye every five minutes for 20 minutes, the drug is instilled twice daily. Lomefloxacin's twice daily dosage is advantageous compared with the more frequent instillation of ciprofloxacin and ofloxacin. A seven to nine day

course of treatment is recommended and there are no age restrictions to the use of lomefloxacin.

Several clinical trials have demonstrated the efficacy of lomefloxacin in acute bacterial conjunctivitis. Malmiemi *et al* (154) compared lomefloxacin and fusidic acid eye-drops in the treatment of 45 patients with presumed acute bacterial conjunctivitis, 31 of whom were culture-positive. Following a loading dose, both antibiotics were instilled twice daily. A significant decrease in clinical symptoms was achieved by both treatments, with a gradual improvement over the treatment period of seven to nine days. There was no significant difference between the general successes of therapy in the two groups; however, bacteriological recovery was superior in the lomefloxacin group. An adverse reaction of burning was described in significantly more patients in the fusidic acid group.

In a trial involving 191 subjects with clinically diagnosed bacterial conjunctivitis, Agius-Fernandez *et al* compared lomefloxacin administered twice daily with chloramphenicol instilled five times a day (155). Both treatments significantly reduced the conjunctival bacterial colony count score with no difference between the two treatment groups in the 96 patients with bacteriological confirmation of conjunctivitis. The two drugs were equally well tolerated, with no serious systemic or local adverse drug reactions reported. The authors concluded that lomefloxacin 0.3 per cent eye drops instilled twice daily were as effective and well tolerated as chloramphenicol 0.5 per cent eye drops instilled five times daily.

Other trials have compared gentamicin 0.3 per cent, tobramycin 0.3 per cent and norfloxacin 0.3 per cent, administered four times a day with lomefloxacin administered twice daily. Jauch *et al* have carried out a meta-analysis of all these trials (156). The

authors concluded that lomefloxacin eye-drops, used with a loading dose followed by a twice daily regimen, proved as effective, safe and well tolerated as five established standard treatments used twice, four times or five times times daily. In addition, lomefloxacin caused less discomfort than the other antibiotics upon instillation.

Pooled results comparing in vitro resistance rates for 710 conjunctival isolates to between six and 10 antibiotics was also reported in the meta-analysis. Lomefloxacin showed the lowest rate of resistance at 5.4 per cent, followed by chloramphenicol (9.2 per cent) and norfloxacin (9.7 per cent). The resistance rate for other antibiotics rose from 18.3 per cent with gentamicin to 73.1 per cent with polymyxin (an antibiotic that is not used as a single agent). Fusidic acid, the other antibiotic licensed for twice daily instillation in the treatment of acute bacterial conjunctivitis, was reported as having a resistance rate of 29 per cent. As the authors reported only one partial loss of sensitivity in the lomefloxacin group among surviving bacteria, compared with seven losses (one partial, six complete) in the combined control group, they concluded that lomefloxacin showed a lower risk of generating or selecting new resistant strains.

Ofloxacin is indicated for the topical treatment in adults and children of external ocular infections, such as conjunctivitis and kerato-conjunctivitis, caused by sensitive organisms. Although the summary of product characteristics does not exclude use in neonates, it states that safety and efficacy in the treatment of ophthalmia neonatorum has not been established. A maximum length of treatment of 10 days is recommended.

Ofloxacin has been shown to be as effective as chloramphenicol (157) and gentamicin (158) in 153 and 191 patients, respectively, diagnosed as having external ocular infection. Adverse reactions were reported to be less with ofloxacin in both studies.

Ofloxacin has also been compared with dual antibiotic therapy in the treatment of microbial keratitis. O'Brien *et al* studied 140 patients with a positive bacterial corneal culture (without fungal or viral infection) to determine the comparative efficacy of ofloxacin eye-drops as a single agent and a combination of cefazolin 10 per cent and gentamicin 1.5 per cent (159). Results indicated equivalent efficacy between the two groups; however, patients receiving fortified antibiotics reported more severe burning and/or stinging with application of the drops. In a similar study of 118 patients where the comparator was a combination of gentamicin 1.5 per cent and cefuroxime 5 per cent (160), again the authors found equivalence between the two groups with less toxicity in the ofloxacin group.

There have been several reports in Japanese journals of the successful use of ofloxacin 0.3 per cent ointment in the treatment of chlamydial infection (161-165). An *in vitro* study showed that the action of ofloxacin was completely lethal when chlamydia-infected cell monolayers were exposed to a concentration of 1g/ml throughout one chlamydial developmental cycle; in contrast, tetracycline inhibited inclusion development at 0.3mg/ml but was only lethal at 2.4mg/ml (166).

Despite the publication of several trials reporting the efficacy of fluoroquinolones in the treatment of microbial keratitis, a debate continues as to whether monotherapy with a fluoroquinolone is appropriate.

Bower *et al* (167), having determined the *in vitro* antibiotic susceptibilities for 153 isolates, predicted *in vitro* susceptibility of 98.7 per cent to a fluoroquinolone-cefazolin combination, 97.4 per cent to a fluoroquinolone-gentamicin combination, 88.2 per cent to ofloxacin and 82.3 per cent to ciprofloxacin. On the basis of these *in vitro* results, they

recommend that single-agent therapy is not advisable for vision-threatening bacterial corneal ulcers.

Allan and Dart (168) observed that monotherapy might be most appropriate in the developed world where contact-lens related *Pseudomonas keratitis* was increasingly predominant and pseudomonal resistance to aminoglycosides has become a significant problem. They suggested that a form of combined therapy (eg, fortified penicillin with ofloxacin) might be preferable in developing countries where trauma-related *Streptococcal keratitis* predominated, despite reports of successful treatment of *Streptococcal* infection with fluoroquinolones (151, 159).

Goldstein *et al* (159) also listed the gaps in fluoroquinolone coverage for *Streptococcus* and coagulase-negative *Staphylococcus* species as a concern over the use of monotherapy in treating bacterial keratitis. In addition, they found a significant increase in the rate of in vitro resistance of *Staphylococcus aureus* to ciprofloxacin and ofloxacin, from less than 6 per cent in 1993 to 35 per cent in 1997.

The relevance of in vitro resistance to clinical response has been questioned because, as Neu (142) points out, fluoroquinolone ophthalmic solutions containing 3,000mg/ml are instilled into an eye infected with organisms for which the MICs are commonly of the order of 0.5mg/ml. However, a recently published study from India has shown a link between in vitro resistance and clinical failure to respond in patients with keratitis caused by *Pseudomonas* isolates. Garg *et al* (170) reported that of 141 culture-proven cases of *Pseudomonas keratitis*, 22 cases were caused by isolates resistant to ciprofloxacin (mean MIC 43mg/ml). Of the 19 (of 22) cases treated initially with ciprofloxacin, 15 (76.7 per cent) worsened or showed no clinical improvement after three days of intensive therapy

and required modification of antibiotic therapy, corneal grafting or evisceration (surgical removal of the contents of the eyeball).

Studies directly comparing the efficacy of the quinolones are sparse. Both ciprofloxacin and ofloxacin were as effective as cefazolin 5 per cent (a standard treatment) in experimental keratitis in the rabbit produced by intrastromal injection of *Streptococcus pneumoniae* (an organism against which the efficacy of the fluoroquinolones has been questioned) (171). Lu *et al* reported a randomised trial involving 217 patients with culture-positive bacterial keratitis in India. They concluded that the efficacy and toxicity of ofloxacin solution in treating bacterial keratitis was equivalent to that of ciprofloxacin solution (172).

Uchida (143) reported a multicentre, double-blind trial of lomefloxacin vs ofloxacin in the treatment of bacterial infections of the external eye. He concluded that the results suggest both preparations are outstanding in terms of safety and utility and that neither could be ranked below the other. There was no significant difference in the efficacy of lomefloxacin and ofloxacin measured in terms of clinical signs and symptoms and bacterial eradication in a double-blind study of 100 patients with bacterial conjunctivitis reported by Huguet (173).

New developments in the field of topical ocular antibiotic therapy are currently concentrated on the fluoroquinolone group. In 1996, Herrin (153) stated that it was likely that the indications for ofloxacin would be extended to include the treatment of corneal ulcers. However, although this has happened in the United States, this indication is still not included in the product licence for the UK market. Herrin also mentioned the imminent introduction of a new formulation of ciprofloxacin, an eye ointment. Markets

on both sides of the Atlantic are awaiting this innovation. Newer fluoroquinolones, such as enoxacin, fleroxacin, levofloxacin, perfloxacin and sparfloxacin, are currently being developed as ocular agents (174). Table 8 shows the classification of the quinolones into "generations" on the basis of microbiological activity is controversial, but is useful for practising clinicians.

**Table 8:** Comparison of Quinolone Generations

Quinolone generations	Microbiologic activity	Administration and characteristics	Indications
<b>First generation</b>			
Nalidixic acid (NegGram) Cinoxacin (Cinobac)	Enterobacteriaceae	Oral administration Low serum and tissue drug concentrations Narrow gram-negative coverage	Uncomplicated urinary tract infections Not for use in systemic infections
<b>Second generation</b>			
Class I Lomefloxacin (Maxaquin) Norfloxacin (Noroxin) Enoxacin (Penetrex)	Enterobacteriaceae	Oral administration Low serum and tissue drug concentrations Improved gram-negative coverage compared with first-generation quinolones Limited gram-positive coverage	Uncomplicated urinary tract infections Not for use in systemic infections
Class II Ofloxacin (Floxin) Ciprofloxacin (Cipro)	Enterobacteriaceae, atypical pathogens; <i>Pseudomonas aeruginosa</i> (ciprofloxacin only)	Oral and intravenous administration Higher serum, tissue, and intracellular drug concentrations compared with class I agents Coverage of atypical pathogens	Complicated urinary tract and catheter-related infections Gastroenteritis with severe diarrhea Prostatitis Nosocomial infections Sexually transmitted diseases Not for use in community-acquired pneumonia because of associations with pneumococcal bacteremia and meningeal seeding due to poor pneumococcal susceptibility)
<b>Third generation</b>			
Levofloxacin (Levaquin) Sparfloxacin (Zagam)* Gatifloxacin (Tequin)	Enterobacteriaceae, atypical pathogens, streptococci	Oral and intravenous administration Similar to class II second-generation quinolones but with modest streptococcal coverage	Similar indications as for second-generation quinolones Community-acquired pneumonia in hospitalized patients or if atypical pathogens are strongly



Moxifloxacin (Avelox)		Increased hepatic metabolism (sparfloxacin and moxifloxacin)	suspected Community-acquired pneumonia in nonhospitalized patients with risk factors for resistant pneumococcal infection†
<b>Fourth generation</b>			
Trovafloxacin (Trovan)*	Enterobacteriaceae, <i>P. aeruginosa</i> (reduced or absent), atypical pathogens, methicillin-susceptible <i>Staphylococcus aureus</i> , streptococci, anaerobes	Oral and intravenous administration Similar to third-generation quinolones but with improved gram-positive coverage and added anaerobic coverage	Consider for treatment of intra-abdominal infections
<p>*--Sparfloxacin and trovafloxacin have significant nonrenal elimination pathways; these agents should not be used to treat urinary tract infections.</p> <p>†--Risk factors for penicillin-resistant pneumococcal infection include age younger than five years or older than 65 years, recent course of antibiotics, comorbid disease or alcohol abuse, immunodeficiency state or human immunodeficiency virus infection, day-care attendance, recent hospitalization, and institutionalization (e.g., long-term care facility, prison).</p> <p>Adapted from Owens RC Jr, Ambrose PG. Clinical use of the fluoroquinolones. <i>Med Clin North Am</i> 2000;84:1447-69</p>			

### V.3.7 COMBINATION PRODUCTS CONTAINING POLYMYXIN

Polymyxin B sulphate is used with trimethoprim in Polytrim eye-drops and ointment, with neomycin and gramicidin in Neosporin eye-drops and with bacitracin in Polyfax eye ointment to provide a very broad antibacterial spectrum.

Polymyxin B is active only against Gram-negative aerobic bacteria and is used rarely as a systemic agent because of toxicity.

Trimethoprim has a broad range of antibacterial activity including *Staphylococci*, *Streptococci*, most *Enterobacteriaceae* and *H influenzae*. *Ps aeruginosa* is resistant due to its permeability barrier. The drug is in widespread clinical use as an oral preparation,

predominantly for the treatment of urinary tract infection. Gramicidin and bacitracin are effective against Gram-positive bacteria and the latter is also effective against *Neisseria*.

Synergistic or additive interaction has been consistently demonstrated between polymyxin and trimethoprim against *Enterobacter* spp, *Klebsiella* spp, *Serratia* spp and *Proteus* spp, but additive and antagonistic effects were observed with equal frequency against *P. aeruginosa* (175).

Tirado *et al* tested Polytrim eye-drops and eye ointment, chloramphenicol eye-drops and eye ointment and fusidic acid eye-drops against 35 bacterial strains including 24 ocular isolates. As eye-drops or ointment, trimethoprim plus polymyxin B had a wider spectrum of activity against clinical isolates than chloramphenicol or fusidic acid. It was the only preparation with anti-pseudomonal activity (176).

Gibson reported the success rate of combinations of polymyxin and other antibiotics in treating 230 patients with bacterial conjunctivitis in a double-blind, randomised trial (177). Trimethoprim plus polymyxin B was similar to that of a combination of polymyxin, gramicidin and neomycin (Neosporin) and significantly better than chloramphenicol in treating the conjunctivitis. In this trial, only one patient had a pre-treatment isolate of *Pseudomonas* spp. Behrens-Baumann *et al* (178) reported a smaller trial comparing the efficacy of trimethoprim-polymyxin B and chloramphenicol ophthalmic ointments in the treatment of bacterial conjunctivitis. They found no significant differences between them with regard to eradication of organisms or clinical improvement.

Neosporin eye ointment applied four times a day was compared with fusidic acid 1 per cent eye-drops twice a day in a trial involving 68 patients with external eye infections

(179). Clinical cure rate was equal in both groups at 88-89 per cent, but four patients (16 per cent) in the Neosporin group reported discomfort, while good tolerability was reported in all patients in the fusidic acid group.

Ophthalmic preparations containing polymyxin appear to be well tolerated. Stinging encountered with Polytrim led to the withdrawal of four patients (3.3 per cent) from Gibson's trial (177). Three patients (7 per cent) in the Polytrim group withdrew from Behrens-Baumann's trial because of stinging, increased transient grittiness, conjunctival hyperaemia and periorbital oedema (178). Adverse reactions to Neosporin were similarly small, with only one patient in 52 (1.9 per cent) treated withdrawing from Gibson's trial due to the development of bilateral periorbital oedema.

There are some differences in the antibacterial spectra of the three combinations (see Table 9). Polytrim has the broadest spectrum of activity but is ineffective against *Neisseria* and *Corynebacterium* species.

Combination eye-drops containing polymyxin are preserved with thiomersal, allowing use in patients allergic to the more commonly used preservative benzalkonium chloride.

**Table 9:** Susceptibilities of ocular pathogens to polymyxin-containing mixtures

Bacterial species	Neosporin*	Polytrim†	Polyfax‡
<i>Staphylococcus aureus</i>	+	+	+
<i>Staphylococcus epidermidis</i>	+	+	+
<i>Streptococcus pneumoniae</i>	+	+	+
<i>Streptococcus pyogenes</i>	+	+	+

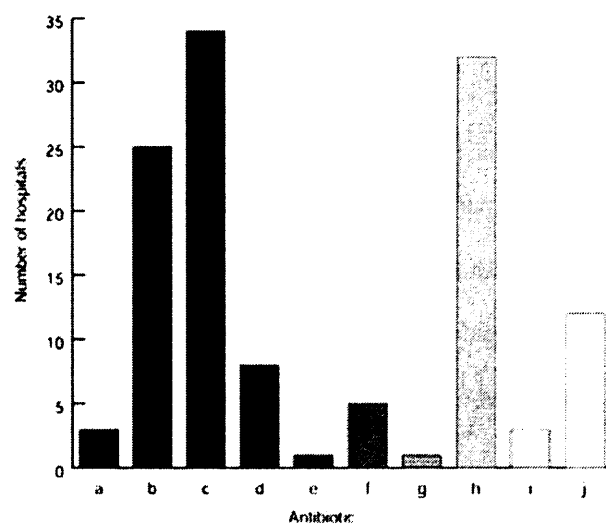
<i>Streptococcus faecalis</i>	+	+	-
<i>Streptococcus viridans</i>	+	+	-
<i>Enterobacter</i> spp	+	+	+
<i>Escherichia coli</i>	+	+	+
<i>Haemophilus</i> spp	+	+	+
<i>Klebsiella</i> spp	+	+	+
<i>Neisseria</i> sp	+	-	+
<i>Pseudomonas</i> spp (including <i>Ps aeruginosa</i> )	+	+	+
<i>Proteus</i> spp	+	+	-
<i>Corynebacterium</i> spp	-	-	+
<i>Salmonella</i> spp	-	+	+
<i>Shigella</i> spp	-	+	-
<i>Moraxella</i> spp	-	+	-
<i>Bacillus</i> spp	-	+	-
<i>Micrococcus</i> spp	-	+	-
<i>Citrobacter</i> spp	-	+	-
+ = sensitive; - = resistant; *polymyxin 5,000 units, neomycin 1,700 units, gramicidin 25 units/ml; †polymyxin 10,000 units, trimethoprim 1mg/ml; ‡polymyxin 10,000 units, bacitracin 500 units/g			

### V.3.8 OTHER ANTIBIOTICS

Despite the range of commercially available topical ocular antibiotics available, ophthalmologists frequently request topical formulations of other antibiotics. A survey conducted in 1999 by the author of 37 ophthalmic centres in the United Kingdom showed that the majority used antibiotics that are not commercially available. Those used are

shown in Figure 3. Fortified gentamicin (1.4 or 1.5 per cent) is frequently combined with cefuroxime in the treatment of bacterial keratitis, while benzylpenicillin is used in the treatment of infections caused by *Neisseria gonorrhoea* and *Streptococcus pneumoniae*. Vancomycin and teicoplanin are useful agents against Gram-positive bacteria while ceftazidime is used as an anti-pseudomonal. Erythromycin, used in the form of an eye ointment, is an alternative to ocular tetracycline in the treatment of infections caused by Gram-positive organisms. Ocular erythromycin is also used in combination with systemic tetracycline therapy for chlamydia. Amikacin has been shown to be a useful antibiotic when *Pseudomonas* with multiple drug resistance is isolated (170).

**Figure 3:** Use of non-commercially available topical antibiotics



**Key:** a = amikacin, b = benzylpenicillin, c = cefuroxime, d = ceftazidime, e = cefazolin, f = ciprofloxacin (preservative free), g = erythromycin, h = gentamicin (forte), i = teicoplanin, j = vancomycin

A request for a preservative-free presentation is another reason for in-house preparation.

Unfortunately, it is unlikely that these agents will become commercially available because usage is low, many of these antibiotics are unstable in solution, and preservative-free formulations require the use of expensive single dose presentations.

Another reason play a role on slowing these agents become commercially available is issues around preservative free drugs.

Though preservative-free drugs may avoid some toxic side effects, they have disadvantages. While it's true that a preservative may be the cause of an allergic reaction, it's difficult to determine if the problem is caused by the preservative, the drug, the drug delivery system or the buffers and stabilizers.

Non-preserved preparations may still hold some risk, therefore.

Non-preserved drugs are only available in unit-dose vials, which may be more difficult for a patient to use correctly, affecting compliance. Poor compliance may hinder a non-preserved drug's effectiveness, even if it's more comfortable to use.

This can be especially important when it's used concomitantly with multidose glaucoma medications, for which compliance is vital. Unit-dose vials are also more expensive than multidose containers.

In addition, patients with advanced rheumatoid arthritis may find it difficult to squeeze the drops from the single-use vials. They may be tempted, then, to use the vial for more than one application.

In the future, manufacturers may reformulate existing products with less-toxic preservatives, offer less concentrated forms of current preservatives or develop new ones. Several pharmaceutical ad campaigns encourage the elderly to inform their pharmacists about all of the medications they're currently taking in order to avoid harmful drug interactions. This is good advice for ophthalmologists and their patients, as well.

No physician wants to prescribe an ocular medication that, though effective, would cause adverse effects over time due to its preservative. That scenario can occur, however, if an ophthalmologist doesn't pay close attention to a medication's ingredients and possible adverse effects. Knowing exactly what's contained in even the most common ophthalmic preparations, and how these different ingredients could potentially act separately or in combination in a particular patient, are keys to treating ophthalmic disease successfully.

#### **V.4 PRESCRIPTION DRUGS: SYSTEMIC ANTIBIOTICS FOR OCCULAR DISEASE**

Topical routes are mainly useful in treating conditions affecting either the exterior surface of the eye or tissues in the front of the eye, but in most cases cannot penetrate to the back of the eye for treatment of various diseases.

The prognosis for patients with bacterial endophthalmitis remains extremely poor. Irreversible eye damage, especially to the retina, occurs during the first few hours of infection.

The causative pathogens are varied: gram-positive cocci are the most frequent (190), but gram-negative bacilli can also induce fulminant endophthalmitis. The vitreous is a key compartment, since the infection can develop within it, but neither systemic nor topical antibiotics penetrate into it.

Direct intravitreal injections are thus used, but they cannot be repeated (at least 48 hours apart) because of their retinal toxicity. There is still a need for systemic antibiotics with broad antibacterial spectra of activity and good intraocular penetration.

New systemic quinolones like pefloxacin, ofloxacin, and ciprofloxacin have been shown to reach high levels in the aqueous and vitreous humors (183,184,185, 187, 194, 197, 199, 200), but their efficacies against *Streptococci* are limited (186, 201, 202).

Sparfloxacin and temafloxacin, even newer quinolones with enhanced antistreptococcal activity in vitro (180, 181, 186,201), may thus be of interest in this setting.



#### V.4.1 SPARFLOXACIN

New quinolones like pefloxacin, ofloxacin, and ciprofloxacin have greater intraocular penetration than conventional antibiotics (4-6, 8, 15, 18, 20, 21). Although they are active against a wide range of bacteria, their efficacies against *Streptococci* are limited (7, 22, 23). In contrast, even more recent quinolones like sparfloxacin and temafloxacin have been shown to be effective in vitro against *Streptococci* (180, 181, 202).

The *Antistreptococcal* efficacy of sparfloxacin was demonstrated in vivo when administered directly into the infected rabbit vitreous; sparfloxacin significantly reduced the bacterial counts, whereas the same dose of pefloxacin did not. The same efficacy with sparfloxacin was also seen with 800 µg of temafloxacin administered intravitreally (188) used under the same conditions; the bacterial count ( $4.6 \pm 1.5 \log_{10}$  CFU. ml<sup>-1</sup>) was also significantly reduced relative to those in the control eyes ( $P < 0.01$ ) and the eyes treated with pefloxacin ( $P < 0.01$ ). The injected doses were high in terms of the MIC of these drugs for the test organism: 0.5 µg/ml for sparfloxacin, 1 µg/ml for temafloxacin, and 8 µg/ml for pefloxacin. The inefficacy of pefloxacin was surprising since the injected dose was several dilutions greater than the MIC. These results emphasize the diversity of factors involved in antibacterial activity in vivo and stress the importance of animal models in this setting. For the kinetic study, we used pooled data from a population of rabbits was used to determine the complete distribution of the drugs in every eye structure. Serial samples from individual rabbits could not be obtained, since this approach allows the determination of kinetics in the humors, but not in the tissues (195).

The half-life of sparfloxacin in serum is long in rabbits. In humans, the half-life of sparfloxacin administered orally is 18.2 h, permitting once-a-day dosing (196). Although the penetration of sparfloxacin into the aqueous humor was only moderate, its penetration into the vitreous was remarkably good. This discrepancy is surprising since the blood-aqueous barrier is known to be of the leaky type, in contrast to the blood-retinal barrier. The low levels and long half-life of sparfloxacin in the aqueous humor could be explained by an ability to penetrate into the neighboring cornea, lens, and iris, as attested to by the high penetration ratios in these tissues and the subsequent slow release from these three compartments into the aqueous humor. All these findings suggest a high cellular affinity of sparfloxacin. Indeed, sparfloxacin shows penetration into tissues, epithelial cells, and fibroblasts significantly greater than that of ofloxacin (198). It also enters easily into polymorphonuclear leukocytes (191), where it should retain its antibacterial activity. This might be related to its biophysical properties; its partition coefficient is several times greater than that of ofloxacin (191) and its molecular weight (392) is low. Sparfloxacin might, like pefloxacin (187), gentamicin, and clindamycin (182), bind to the pigmentary apparatus. These points to the need to use pigmented rabbits for the evaluation of antibiotic tolerability, kinetics, and efficacy.

#### *V.4.2 TEMAFLOXACIN*

A new quinolone that is similar to sparfloxacin but that has different kinetics. Compared with sparfloxacin, temafloxacin has a higher serum  $C_m$  and a shorter half-life when given under the same conditions (188). This difference is also found in humans, since the  $C_m$  of sparfloxacin and temafloxacin after administration of 400 mg orally are 1.2 and 3.6  $\mu\text{g/ml}$ , respectively, while the half-lives are 18.2 and 10.6 h, respectively (192, 196).

Sparfloxacin shows better ocular penetration ratios than temafloxacin, especially in the vitreous (54 versus 6%), cornea (76 versus 35%), and lens (36 versus 0.5%). Gram-positive cocci are the most common pathogens in human endophthalmitis (190). In rabbits, sparfloxacin given at 50 mg. kg<sup>-1</sup> intramuscularly maintained vitreal levels superior to the MICs for both *Staphylococci* and *Streptococci* for up to 18 h. In humans, the validity of sparfloxacin administered orally at a conventional dose (400 mg) must be confirmed by kinetic studies of the aqueous and vitreous humors, since the serum C<sub>m</sub> is lower (1.2 versus 3.6,ug/ml) but the serum half-life is longer (18.2 versus 7.3 h) in humans than in rabbits, resulting in similar AUCs. The main in vitro criterion used to predict antibacterial activity remains the inhibitory index, defined as the ratio between the absolute concentration of the antibiotic at the site of action and the MICs. However, this system shows limits, as attested to by the discrepancy between the antibacterial activities of sparfloxacin and pefloxacin. Other factors can also interfere, stressing the need for experimental endophthalmitis models to determine the real in vivo activities of drugs. In conclusion, when administered by the intravitreal route, sparfloxacin was effective against rabbit *Streptococcal* endophthalmitis, while pefloxacin was not. By the systemic route, sparfloxacin showed good penetration into the eye, especially the vitreous. Further studies are required to assess the efficacy of sparfloxacin administered by the systemic route in the curative and/or preventive therapy of bacterial endophthalmitis. Indeed, systemic sparfloxacin might be of interest as adjuvant therapy for bacterial endophthalmitis in humans.

### V.4.3 LEVOFLOXACIN

The fluoroquinolones have high oral availability, approximately 99% for levofloxacin, and are absorbed rapidly (203). Food does not significantly affect absorption. Maximum serum concentrations are achieved after 1 hour when fasted or 2 hours unfasted (204, 207) Experimental results are confirmed that levofloxacin reaches the vitreous of uninflamed phakic eyes within 2.5 hours of a single oral dose. The peak concentration measured (1.6 µg/ml) was less than half the highest reported MIC<sub>90</sub> for *Staphylococcus epidermidis*, the commonest organism isolated in post-cataract endophthalmitis. It is well recognised that sensitivities to most antibiotics for *S epidermidis* are very variable and resistance widespread. The MIC<sub>90</sub> values quoted may not be representative of organisms encountered in endophthalmitis as they include isolates obtained from blood cultures in cancer patients, many of whom had received recent antimicrobial therapy. Susceptibility data obtained from ocular isolates would provide the most relevant reference point, but none is presently published for levofloxacin. The small number of isolates available makes calculation of meaningful MIC<sub>90</sub> values difficult.

Higher vitreous levels may be achieved when treating endophthalmitis or following trauma due to a breakdown in the blood-ocular barrier. In a rabbit model inflammation increased both the penetration of systemic ofloxacin in to vitreous and prolonged its elimination half life. Fiscella *et al* (207) found a repeat 500 mg dose of levofloxacin 12 hours after the first produced higher vitreous levels compared to a single dose alone (mean level of 2.48 µg/ml v 0.59 µg/ml sampled greater than 2 hours after last dose), exceeding most of the MIC<sub>90</sub> values they quoted.

As far as ocular penetration of fluoroquinolones is concerned, levofloxacin was shown to present appropriate diffusion in aqueous humor after either topical and/or oral administration (204, 207, 208, 214,215), achieving concentrations higher than ciprofloxacin (205,209, 213) or ofloxacin (206, 210, 211).

The role of systemic antibiotics in therapy or as prevention for endophthalmitis has not been fully established. Direct intravitreal treatment remains the mainstay of treatment. Systemic agents with adequate vitreous penetration and an appropriate antimicrobial spectrum may have a valuable role. The penetration of levofloxacin and newer fluoroquinolones into the infected eye and their effect on outcome require further investigation.

#### V.4.4 TROVAFLOXACIN

Trovafloxacin is a novel fluoronaphthyridone quinolone characterized as having significantly greater activity against gram-positive *Cocci* and *Anaerobes* than existing quinolones while retaining good activity against gram-negative organisms. It is particularly active against coagulase-negative *Staphylococci* and *S aureus* (including methicillin-resistant strains that remain susceptible to ciprofloxacin), *S pneumoniae*, and *H influenzae* (216,217).

In study performed by Eugene *et al* (218), were used a rabbit model of *S epidermidis* endophthalmitis to evaluate the ocular pharmacokinetics and efficacy of trovafloxacin in treating intraocular *Staphylococcal* infection. Their results show that trovafloxacin administered orally achieves excellent penetration into infected eyes (36% for vitreous humor, 72% for aqueous humor). These data support trovafloxacin as a potential oral

agent for treatment or prophylaxis of *S epidermidis* endophthalmitis, although retinal alterations that occur over the period required for vitreous sterilization suggest that it will not replace intravitreal therapy in established endophthalmitis. This is comparable to the vitreous penetration of ofloxacin (31%) (219, 220) and is superior to the vitreous penetration of fleroxacin (9.6%) and ciprofloxacin (5.45%) (221). These data concur with previous studies showing that the ocular penetration of systemically administered quinolones is correlated with lipophilicity (222, 223).

Maximal aqueous and vitreous trovafloxacin levels were achieved from 4 to 12 hours and were greater than 30 and greater than 15 times above the MIC of this study's strain of *S epidermidis*, respectively. The levels achieved are also well above the MIC<sub>90</sub> of most clinically important ocular isolates, including methicillin-sensitive *Staphylococci* (both coagulase-negative and coagulase-positive), *S pneumoniae*, and *H influenzae*. However, vitreous levels did not reach the MIC<sub>90</sub> of methicillin-resistant *Staphylococci* or *Pseudomonas* species. Ocular penetration, particularly into the anterior chamber, was increased by the presence of active infection. Consistent with other studies on the ocular pharmacokinetics of quinolones, penetration of trovafloxacin was greater into the aqueous humor than into the vitreous humor (224, 225).

Although the dose of trovafloxacin on a mg/kg basis used in this study is well above that of human studies, peak serum levels achieved were within the therapeutic range for human clinical trials, (226) thus reflecting an absorption idiosyncrasy of the species of animal employed. Oral dosing of trovafloxacin was well tolerated by all animals for the duration of the experiments.

When therapeutic efficacy was assessed with respect to quantitative culture of the

vitreal, it was shown that one of three treated eyes was rendered sterile after 4 days of treatment, and all treated eyes were successfully sterilized after 5 days of therapy. Control eyes demonstrated significantly higher bacterial counts at corresponding times and still had a considerable intraocular bacterial burden at 1 week. The gradual decline in colony counts in control eyes reflects autosterilization that occurs in the endophthalmitis model used in this study. Clinical examination revealed that anterior segment inflammation was significantly ameliorated with 6 days of antibiotic therapy, particularly of the cornea and iris. Antibiotic therapy also delayed the progression of vitritis. Treated eyes demonstrated moderate vitritis after 2 days of therapy compared to control eyes, which had loss of red reflex in all eyes by this time. Treated eyes progressed to loss of red reflex in all eyes by 6 days of therapy.

Histologic examination revealed that despite successful ocular sterilization, substantial destruction of the posterior segment ensued. In two of three treated eyes, retinas were totally necrotic after 6 days of antibiotics. Anterior segment inflammation was significantly ameliorated in eyes treated with 6 days of trovafloxacin compared to control eyes. This presumably reflects the higher antibiotic levels that were achieved in aqueous humor compared to the vitreal cavity, or perhaps increased sensitivity of the retina to bacterial toxins and enzymes.

These data suggest that administration of oral trovafloxacin alone for the treatment of endophthalmitis may not be feasible; however, trovafloxacin may be beneficial adjunctively. The reason that sole oral trovafloxacin was unsuccessful at preventing significant retinal destruction in this study is probably because vitreal drug levels attained were inadequate to cause sufficiently rapid sterilization of infected eyes. In

addition, trovafloxacin displays high protein binding in vivo (227). The effect of this on the intraocular efficacy of this agent requires further examination. The data in this study also suggest that other factors, such as inflammation, may contribute to continuing ocular injury despite successful sterilization of infection and that the coupling of immunomodulatory therapy to systemic antibiotics may improve outcome. Indeed, a case series by O'Day and associates (228) found that successful antibiotic treatment of postoperative *S epidermidis* endophthalmitis without intravitreal injection was possible by combining multiple routes of antibiotic delivery (systemic and periocular) with systemic corticosteroids.

In conclusion, in this experimental model, orally administered trovafloxacin achieves intraocular levels sufficient to inhibit most organisms commonly implicated in bacterial endophthalmitis and may be a useful adjunct in the treatment or prophylaxis of *S epidermidis* endophthalmitis. Trovafloxacin displays improved activity against *Staphylococci* and *Streptococci* compared with existing quinolones and therefore may be a potentially superior agent for systemic administration or may represent a suitable alternative to existing antibiotics in clinical use.

#### V.4.5 GATIFLOXACIN

Mather et al (229) have described the fourth generation fluoroquinolones as “new weapons in the arsenal of ophthalmic antibiotics.” They performed an in vitro study determining the differences in susceptibility patterns and potencies of second, third, and fourth generation fluoroquinolones to 93 bacterial endophthalmitis isolates. They demonstrated that coagulase-negative *Staphylococci* that were resistant to second-



generation fluoroquinolones (eg, ciprofloxacin and ofloxacin) were statistically most susceptible to fourth-generation fluoroquinolones, specifically gatifloxacin and moxifloxacin. Additionally, *Streptococcus viridans* and *Streptococcus pneumoniae* were least susceptible to older-generation fluoroquinolones. Overall, fourth-generation fluoroquinolones retained equivalent potencies to gram-negative bacteria as compared with older-generation fluoroquinolones, such as levofloxacin and ciprofloxacin, while also demonstrating enhanced potencies for gram-positive bacteria.

In another recent study, Garcia-Saenz et al (230) investigated the penetration of orally administered moxifloxacin into the human aqueous humor for potential use as a prophylactic agent against bacterial endophthalmitis in cataract surgery. They found that moxifloxacin achieved a mean aqueous concentration of  $2.3 \pm 0.9 \mu\text{g/mL}$ ; however, their reported  $\text{MIC}_{90}$  for *Staphylococcus epidermidis* was  $2.00 \mu\text{g/mL}$ . The concentration achieved is border line for the most common causative organism in postoperative endophthalmitis. This is not the case with gatifloxacin because intraocular concentrations after oral administration were found to be several times higher than the  $\text{MIC}_{90}$  for *S epidermidis*. Additionally, penetration of moxifloxacin into the vitreous was not investigated; therefore, no conclusions can be made regarding its use in open-globe trauma involving the posterior segment or its use as an adjunctive therapy for endophthalmitis treatment.

Gatifloxacin is very well tolerated, and most adverse reactions are described as mild in nature. The most common adverse reactions include nausea, vaginitis, diarrhea, headache, and dizziness. In our series, one patient complained of mild gastrointestinal discomfort, and another patient vomited 30 minutes after taking the second gatifloxacin dose. The

concentrations of gatifloxacin in serum and vitreous in this patient were above the mean level for the rest of the group. The dosage of gatifloxacin recommended by Bristol-Myers Squibb Co (New York, NY) is one 400-mg tablet every 24 hours. In our study design, we chose to use a loading dose of one 400-mg tablet twice a day before sample collection to achieve peak plasma concentrations more rapidly. In the appropriate clinical setting, one may consider using a loading dose of gatifloxacin followed by one 400-mg tablet a day thereafter. Because gatifloxacin is eliminated primarily by renal excretion, a dosage modification is recommended for patients with a creatinine clearance of less than 40 mL/min (<0.07 mL/s). Gatifloxacin should be avoided in patients receiving a class IA (quinidine or procainamide) or class III (amiodarone or sotalol) antiarrhythmic agent because gatifloxacin may have the potential to prolong the QTc interval of the electrocardiogram in some patients.

In summary, orally administered gatifloxacin achieves therapeutic aqueous and vitreous levels in the noninflamed human eye, and the activity spectrum appears to appropriately encompass the bacterial species most often involved in the various causes of endophthalmitis. Because of its broad spectrum of coverage, low MIC<sub>90</sub> levels for the organisms of concern, good tolerability, and excellent bioavailability with oral administration, gatifloxacin may represent a major advance in the prophylaxis or treatment of postoperative, posttraumatic, and bleb-associated bacterial endophthalmitis

#### *V.4.6 COMBINATION SYSTEMIC THERAPY*

The visual outcome after postoperative endophthalmitis depends on virulence of the infecting organism and the time point of diagnosis and initiation of antibiotic treatment,

combined with vitrectomy if indicated. Because bacterial culture and sensitivity testing usually take 24–48h, the initial treatment requires broad-spectrum antibiotics. Intravitreal antibiotics are the treatment of choice for postoperative endophthalmitis in patients in whom visual acuity is perception of hand motion or better at the time of presentation (231). The infection can be due to a wide variety of bacterial strains, although *Staphylococcus* species are the cause in more than 50% of the cases. Intravitreal vancomycin is considered to be the treatment of choice for Gram-positive organisms. It is nontoxic in the recommended clinical dosage and is active against almost all Gram-positive organisms, including methicillin-resistant *Staphylococcus aureus* (232, 233, 234). To combat infection by Gram-negative organisms, a combination of intravitreal vancomycin and aminoglycosides, such as amikacin or gentamicin, have been used commonly (233, 235, 236). However, macular infarction has been reported after intravitreal injection of aminoglycosides (235). Substitution with other antibiotics has therefore been advocated (236, 237, 238). Ceftazidime (237), a cephalosporin with broad-spectrum antibacterial action, is now frequently administered together with vancomycin (239). Its antibacterial action is as effective as that of the aminoglycosides and it poses low risk for macular infarction (234, 240). Physicochemical incompatibility of vancomycin and ceftazidime is known to lead to precipitation, but this combination has been a widely accepted treatment regimen for years, without clinical drawback (238, 241). It has been thought that precipitation can be avoided by using separate syringes to inject the two antibiotics (236).

However, a recent report described the formation of whitish microprecipitates after the two drugs were injected into the eye intravitreally through separate syringes (242). The

precipitates were presumed to be formed by an amalgamation of the compounds. So far, there is no evidence as to whether the precipitation disrupts the therapeutic effects of the antibiotics, nor is it clear whether it is a consistent event.

## **VI. ADVANCE IN OPHTHALMIC DRUG DELIVERY SYSTEM**

The poor accessibility of a number of ocular regions to systemic circulation makes local delivery via topical administration the preferred route for the treatment of ocular diseases. Typical conditions that require ocular administration include eye infections (i.e, conjunctivitis) and corneal disorders (i.e, glaucoma). The biological barriers involved for ocular delivery are the permeability barriers posed by cornea and other regions, as well as the tear washout and blinking reflexes designed to remove foreign substances from the eye. Furthermore, the ocular region is very sensitive and cannot withstand high local concentrations of drugs or vehicles without irritation. Because of these limitations, designing formulations and delivery systems for topically applied ophthalmic drugs is challenging. It requires thorough understanding of physiological basis of the protective mechanism designed by the eye which allows only 1-10% of topically applied dose to be absorbed locally.

### **VI.1 Factors affecting absorption**

#### *VI.1.1 DRUG CONCENTRATION*

The drug concentrations achievable by topical applications are frequently much higher than those achievable by systemic dosing. The concentrations must be as high as possible without causing toxicity, irritation to the eye (reflex tearing will dilute the drug and reduce contact time with the cornea), and resulting in insolubility.

### *VI.1.2 SOLUBILITY IN LIPIDS AND WATER*

Corneal epithelial cells are joined together with tight junctions. In order for a drug to pass through the cornea into the aqueous chamber, it needs to pass through two lipid bilayers (belonging to the corneal epithelial cell membranes) for every cell. It has been shown that lipid solubility is more important in drug penetration than water solubility.

### *VI.1.3 PH*

Changing the pH of the drug solution to one more alkaline will allow more of the drug to exist in an uncharged lipid soluble form. This enhances penetration.

### *VI.1.4 VISCOSITY*

The addition of methylcellulose and polyvinyl alcohol, increases the viscosity of the carrier and hence increases contact time with the cornea.

### *VI.1.5 SURFACTANTS*

The presence of preservative agents in ophthalmic medications helps to prevent bacterial contamination. These agents alter cell membrane characteristics of both bacteria (prevent viability) and corneal epithelium (increase permeability). For example the same miotic response is evident when a 0.1% solution of carbachol is used with benzalcoholium chloride as a 2% concentration without.

## **VI.2 FACTORS AFFECTING ROUTE OF DELIVERY**

### *VI.2.1 DROPS*

These have a short transit time. Patients should be instructed to wait 10min. between instillation of different eye drops, as rapid instillation will result in the first being washed out by the second.

### *VI.2.2 OINTMENT*

Oil-based ointments contain petrolatum to dissolve lipids and mineral oil which allows the ointment to melt at body temperature. Slower release of drug occurs, with an increased transit time which allows more time for absorption to occur. The best drugs suitable for this form of delivery are those which are highly lipid soluble (eg. Chloramphenicol) but which have in addition some water solubility, to aid their passage through the tears. Chloramphenicol and tetracycline achieve much higher aqueous levels when used as ointments as opposed to drops.

### *VI.2.3 PERI-OCULAR / INTRAVITREAL INJECTION*

These methods allow a high concentration of drug to be reached in the posterior segment of the eye. Penicillin which is poorly lipid soluble can not be administered in this way. Sub-conjunctival injections of antibiotic may be used to provide a peak concentration of the drug to the cornea and anterior segment. These are, however, rarely used because of the high concentration of drugs achievable by high frequency topical regimens.

#### *VI.2.4 SYSTEMIC*

The access of drugs to the eye is hampered by the Blood-Retina (BR) and Blood-Aqueous barriers (BAB). These blood vessels have endothelial cells like those in the brain which have tight junctions and are non-fenestrated. Blood vessels in the choroid and ciliary body, however, are fenestrated, but passage of substances is impeded at the level of the retinal pigment epithelium and non-pigmented epithelium of the ciliary body respectively. Drug penetration requires high lipid solubility (chloramphenicol cf penicillin), and only that portion of the drug unbound to plasma proteins may cross. Sulphonamides are highly lipid soluble but also highly protein bound, therefore have little penetration into the eye. Bolus injections of antibiotics are used to saturate the plasma protein binding capacity, and thus allow more ocular penetration (than when the drug is administered as a slow intravenous infusion.)

### **VI.2 TYPES OF FORMULATION**

#### *VI.2.1 SOLUTIONS*

These are the least irritating, but have the shortest contact time. They must be given frequently. As with anything placed in the eye, healing of incisions or corneal ulcers is slowed, but not as much as with ointments.



### *VI.2.2 SUSPENSIONS*

Similar to solutions. Their disadvantages are that they must be shaken well before use and they should not be used in lavage systems because of the potential for clogging tubes.

### *VI.2.3 OINTMENTS*

These tend to last longer than solutions or suspensions, but, for external disease, this usually is not significant. They tend to slow healing more than do solutions or suspensions.

### *VI.2.4 POWDERS*

These can be quite irritating and should not be used in the eye.

## **VI.3 VEHICLES OF PREPARATIONS AND HOW THEY AFFECT CONTACT TIME**

### **Aqueous**

Readily mixes and flows away with tears. Aqueous solutions may increase the rate of tear evaporation from the eye by washing away the outer oily layer of the tear film.

**Methylcellulose:**

Provides lubrication and greater contact time than aqueous vehicles.

**Hydroxyethylcellulose:**

Similar to, but more effective than methylcellulose.

**Polyvinyl alcohol:**

Similar to methylcellulose.

**Polyvinylpyrrolidone:**

When used with ethylene glycol polymers, produces a viscous 'artificial mucus' - has the greatest contact time of all the liquids.

**Oily bases (lanolin, mineral oil, peanut oil, petrolatum):**

In solutions or ointments. Although oil bases compete with the epithelium for fat soluble drugs, this is of little clinical significance. Ointments are preferred immediately after surgery due to reduction in eyelid motility (this allows lubrication and moisturizing of the cornea and conjunctiva until spontaneous blinking recurs).

All oil bases are extremely damaging if given intraocularly, such as during an intraocular procedure. Therefore, they should not be used before or during an intraocular procedure.

Attempts to improve ocular bioavailability have been focused on overcoming pre-corneal solution drainage through manipulation of solution viscosity with polymers, use of mucoadhesive polymers, collagen shields, gels, nanoparticles, liposomes, latex systems, iontophoresis.etc. These ocular drug delivery systems, while limited in providing ideal bioavailability profiles, do provide opportunities for improvement. A better approach of ocular product behaviour coupled with formulation optimization can lead the way to development of newer ocular drug delivery systems (1).

#### **VI.4 CURRENT DRUG DELIVERY SYSTEMS FOR THE EYE**

The most common method of ocular drug delivery is the instillation of drops into the lower cul-de-sac. Such drops are usually drained quickly, aided by the linking reflex, and the precorneal region returns to the normal resident volume of around 7  $\mu$ l (243). The concentration of drug in the precorneal area provides the driving force for its transport across the cornea via passive diffusion. Thus, efficient ocular drug absorption requires good corneal penetration as well as prolonged contact time with the corneal tissue.

Iontophoresis, prodrugs, ion pair formation and cyclodextrins have all been used as means of enhancing ocular drug absorption. An ideal topical ophthalmic formulation would enhance bioavailability by sustaining drug release, while remaining in contact with the front of the eye for prolonged periods of time (244,245); modern formulations attempt to achieve this.

There are a wide variety of ophthalmic drug delivery systems on the market (246). Nevertheless, about 70% of prescriptions for eye medication are for conventional eye

drops. This is due to factors including expense, difficulty in bulk manufacture, patient compliance, efficacy and stability. The various types of ocular drug delivery vehicle in existence are discussed in the following sections. In all cases, one key requirement is that the formulation must be capable of being sterilized or produced in a sterile environment.

It has been reported (247) that an increase in the corneal penetration of a drug is at a maximum if the viscosity of the eye drop solution is about 15 to 150 mPaS (cP). Any further increase in viscosity would have less effect on the drainage rate and tear film thickness and has been implicated with interference of vision and resisting movement of the eyelids (247).

Colloidal systems, encompassing liposomes and micro and nanoparticles, have been studied as drug carriers in ophthalmic drug delivery over many years.

Colloidal particles are subjected to the same clearance mechanisms as other foreign bodies that may come into contact with the ocular surface, and tend to be washed away by reflex tearing. Larger particles are more likely to be entrapped under the eyelids or in the inner canthus and so remain in contact with the corneal and conjunctival epithelia for extended periods. For patient comfort, it is considered that solid particles intended for ophthalmic use should not exceed 5-10  $\mu\text{m}$  diameter.

The use of a bioadhesive polymer (e.g. a polyacrylic acid, chitosan, hyaluronic acid) that prolongs the residence time in the precorneal region may confer an advantage (248,249).

One interesting approach involves the use of lectins to selectively bind particulates to the required area of the precorneal region for extended periods (250).

Liposomes (251) are membrane-like vesicles, consisting of phospholipid bi-layers surrounding an aqueous compartment. They are classified as either small unilamellar vesicles (SUV) (10-100 nm), large unilamellar vesicles (LUV) (100-3000 nm) or, if a number of bi-layers are present, multilamellar vesicles (MLV). The potential of liposomes as a topical ophthalmic drug delivery system is restricted by their stability and limited drug loading capability. In addition, large-scale manufacture of liposomes is expensive and technically challenging.

Microparticles have an average particle size greater than 1  $\mu\text{m}$  and may be microcapsules or microspheres. Microspheres are monolithic particles, perhaps of insoluble drug or drug dispersed in a polymer matrix, whereas microcapsules consist of a polymeric membrane surrounding a solid or liquid drug reservoir. Upon topical instillation, the particles reside in the ocular cul-de-sac, and the drug is released from the particles through diffusion or polymer degradation (252). Techniques for the manufacture of particles include: denaturation or cross-linking of macromolecules in emulsion; interfacial polymerisation; formation of emulsions and solvent removal; solution enhanced dispersion by supercritical fluids and spray drying.

Nanoparticles are solid colloidal drug carriers ranging from 10 to 1000 nm. These may also be made from the insoluble drug, or the drug may be entrapped within the particle or adsorbed onto its surface. The payload (the dose of drug delivered) is comparatively small and represents a limiting factor for the use of nanoparticles in drug delivery. A wide range of polymers has been used in the manufacture of micro- and nanoparticles for ophthalmic drug delivery including poly(alkyl)cyanoacrylate, polylactic acid and albumin.

### **Solid matrices and devices**

A number of solid polymeric inserts and discs have been developed as ophthalmic drug delivery systems. Inserts allow for accurate dosing, reduced systemic absorption and in some cases, better patient compliance resulting from a reduced frequency of administration and a lower incidence of visual and systemic side effects. Inserts are affected to a lesser extent by nasolachrymal drainage and tear flow than the more conventional dosage forms, and are associated with reliable drug release and longer residence times in the conjunctival cul-de-sac (253). However, patient resistance to placing a solid object in the precorneal region is an issue of some significance. A number of inserts are currently available on the market or in the latter stages of development. These inserts have been classified as degradable or non-degradable (i.e. those that have to be removed on completion of therapy). Various materials have been utilised in the development of degradable inserts, including polyvinyl alcohol, hydroxypropylcellulose, polyvinylpyrrolidone and hyaluronic acid. Non-degradable inserts have been shown to provide more predictable release rates than soluble inserts (254) and are prepared from insoluble materials such as ethylene vinyl acetate copolymers and styrene-isoprene-styrene block copolymers.

Given the problems associated with their use, it may be considered surprising after so many years that eye drops are still the drug delivery system of choice in ophthalmic drug delivery. The formulation of a delivery system that is readily sterilised, economic and patient friendly, while allowing controlled drug delivery and optimum bioavailability, remains a challenge to pharmaceutical scientists.

Both this chapter and previous one aimed to review current limitation and current research studies on treatment of ocular infection. Knowledge and transferring our understanding is a key to success of improve patient case. To do so as a pharmacist specializing in eye problems at the pharmacy department at Moorfields Eye Hospital we designed a formulary to transfer our knowledge on ocular drugs to physicians and health care professionals who work in this area.

## **VII. INTRODUCTION TO THE PHARMACY HANDBOOK**

Books containing an official list of medicinal drugs together with articles on their preparation and use date back to the 1600s. From the London Pharmacopoeia in 1618, Edinburgh and Vienna Pharmacopoeia's in the 1700s to today's British National Formulary (BNF). Somewhat surprisingly neither of the earlier pharmacopoeias had any mention of eye medicaments with no reference to substances such as belladonna.

With reference to the 'Spoonful of Sugar' (2001) report and the 'Clinical Pharmacy in the Hospital Pharmaceutical Service' (1996) report both mention the development and maintenance of a local formulary, which can be used in conjunction with the BNF in its current format. Formularies can be useful tools in solving some of these problems of drug therapy as they can:

- Provide impartial drug information to counteract biased promotional activities or fill the gap where access to accurate and up-to-date information is limited
- Promote the appropriate use of safe, effective and good quality medicines
- Help in the elimination of unsafe, ineffective or poor quality medicinal products by identifying effective and safe medications
- Support cost-effective utilisation of drug budgets and improve access to essential medicines.

The main aim of this handbook is to promote safe, effective and economic prescribing in both hospital and general practice. The medicines included provide appropriate treatment for the vast majority of patients.



The Moorfields Eye Hospital NHS Foundation Trust handbook provides information on drugs. In turn, this will achieve two objectives; firstly, as a selective list this will lead to greater familiarity with a limited range of medicines and thus help to reduce prescribing errors and second, with agreement across the interface between primary and secondary care, the handbook will promote a seamless approach to prescribing which will benefit all patients who require medicines.

This handbook stems from a history of informed bulletins to its current format as presented in the 1992 version. The handbook is designed to provide users with clinical management guidelines, to encourage and promote safe, rational and cost-effective prescribing, and to advise prescribers of the drugs stocked within Moorfields Eye

Hospital NHS Foundation Trust. The drugs included in the Moorfields Eye Hospital NHS Foundation Trust handbook have been chosen following extensive consultation with medical, surgical and pharmacy staff. Prescribing drugs outside of the formulary is not promoted as this may forfeit this aim.

This handbook is intended for the guidance of medical practitioners, nurses and pharmacists who have the necessary knowledge and experience to interpret the information it provides. It is intended as a pocket reference book for use as a guide of ophthalmic items which are not commercially available and need to be manufactured as specials at the request of medical staff (See Appendix I). Additionally, a limited selection of proprietary products is included, representing drugs which are in use at Moorfields Eye Hospital NHS Foundation Trust. This reflects local current clinical practice. The purpose is to continually develop forthcoming publications of the handbook.

## **VIII. CONCLUSION**

The eye is a very delicate and sensitive organ and if its structure or integrity is affected, for instance if the front of the eye is scratched, infection can take hold. In addition, the eye and its surrounding tissues are prone to a wide range of non-infectious inflammatory disorders. If either the outside or inside of the eye becomes infected or inflamed, immediate treatment is necessary to avoid irreparable damage which can, in severe cases, permanently affect sight.

Infection is one of the most feared complications after sight restoring intraocular surgery, such as cataract extraction, because the onset and damage can occur so rapidly.

One of the key problems with intraocular infection is that it is difficult to identify the organism responsible. This may delay correct treatment, as a result of which the infection has more time to take hold and the chance of irreparable damage increases.

Equally important is to have effective treatment once the type of infection has been identified.

Currently, the most effective way to determine the best treatment for an eye infection is to identify the infecting organism and then to test different antibiotics on it. A biopsy or sample of infected fluids is taken from the eye so that the infectious organism can be grown in the laboratory. The organism can then be identified and sensitivity-tested with antibiotics. The process takes about 24 hours and is fraught with problems, as it is often very difficult to grow the organism.

The detection and identification of microorganisms in patient specimens is an important role of a microbiology laboratory. Most bacteria and fungi can be grown in artificial culture and examined for a variety of key identifying characteristics within a couple of

days. Most viruses can be cultured and identified by specific antibodies or through the use of nucleic acid probes. However, these processes may take several days. Detection can be especially difficult if the number or frequency of infected cells is very low or if the organism is particularly difficult to culture in the laboratory.

Molecular diagnostic techniques have been made available for the diagnosis of infection pathogens. With the development of recombinant DNA technology, these techniques are mainly based on identification of unique sequences called signature sequences of the pathogen. During the Eighties, polymerase chain reaction (PCR) was described for the first time. It is a powerful and remarkable technique for amplifying specific DNA sequences even if they are present at extremely low levels. In eyes with suspected endophthalmitis, early diagnosis and appropriate treatment have been noted to be associated with a better visual outcome. Currently in clinical practice, however, confirmation of the diagnosis of endophthalmitis (bacterial and/or fungal) is dependent on conventional techniques for microbiological isolation of organisms, which require between one and twelve days. Furthermore, many samples prove to be culture-negative.

In order to improve the rate of microbiological diagnosis, PCR technology has been successfully applied to the detection of bacteria and fungi in ocular samples. Specific oligonucleotide primers have been used to detect the presence of pathogens, which have been subsequently identified using RFLP analysis, DNA sequencing, and/or cloning techniques. Results demonstrated that PCR-based methods are rapidly able to confirm the presence of pathogens with high specificity and sensitivity. PCR-based techniques have also been used to rule out with confidence the presence of pathogens, a unique advantage

of this methodology. The use of molecular methods has significantly increased the number of intraocular samples from which a confirmed diagnosis is made and has reduced the time for laboratory diagnosis. PCR-based methods promise to be useful diagnostic tools in the management patients from whom ocular samples prove to be culture-negative.

Having said that, a good DNA extraction method is critical for PCR detection to avoid the possibility of false-negative results. Several investigators have reported the use of panbacterial PCR in the analysis of ocular samples from clinical cases with suspected intraocular infection. The main drawback of studies using nested PCR for the detection of bacteria using panbacterial 16S rDNA gene primers has been the coamplification of small amounts of the bacterial DNA that contaminate even the purest commercial preparations of *Taq* DNA polymerase. The group of Susan Lightman at the UCL Institute of Ophthalmology has demonstrated that the efficient elimination of this DNA from participation in the amplification reaction is reliably achieved by pretreatment of the polymerase with a restriction endonuclease, before first-round PCR amplification.

The treatment of ocular infections poses other challenges. Current methods for ocular delivery include topical administration (eye drops), subconjunctival injections, periocular injections, intravitreal injections, surgical implants, and systemic routes. However, all of these methods have limitations. Therapeutic levels of many drugs may be difficult to achieve in ocular tissues and systemic toxicities are of concern when the oral and intravenous routes of administration are used. Intravitreal injections, periocular injections, and sustained-release implants can be used to achieve therapeutic levels of

drugs in ocular tissues, but invasive methods have increased risks due to the potential for bleeding, infection, retinal detachment, and other local injuries.

Given the problems associated with their use, it may be surprising that eye drops are still the drug delivery system of choice in ophthalmic drug delivery.

Topical administration of drugs for different eye segment diseases is limited by several factors: the precorneal tear film, a limited volume that can be accommodated by the cul de sac, the lachrymal drainage system, reflex tearing, and biophysiological properties of the cornea. Although investigators continue to develop new antibiotics, all attempts to gain satisfactory therapeutic drug levels in the posterior segments have failed. So in recent years, the focus has changed from finding new antibiotics to strategies that could provide better penetration levels with the same drugs. Direct administration of medication to the subconjunctival space may have advantages over topical therapy for anterior segment disorders but it has not proven to achieve effective therapeutic drug concentrations in the posterior segments. Because of the difficulties in delivering drugs to the posterior segment of the eye, the development of intraocular delivery systems that allow the delivery of therapeutic drug concentrations for long periods are being studied. These systems offer many advantages, such as increased drug bioavailability, constant and sustained drug release, elevated local drug concentrations without systemic side effects, specific tissue or cell type targeting, and reduced frequency of intraocular injections. These advantages can improve the comfort of the patient and reduce the complications observed with intraocular injections.

A number of such drug delivery systems are being developed. They employ polymer-based micro- or nano-particles, or liposomes, or iontophoresis, which is based on the

application of an electric current. However, the formulation of a delivery system that is readily sterilised, economic and patient friendly, while allowing controlled drug delivery and optimum bioavailability, remains a challenge to pharmaceutical scientists.

Bacterial, fungal, viral, and parasitic pathogens all cause systemic infection and can spread to the eye. Dissemination of pathogens via the bloodstream can lead to direct involvement of the eye. Visual loss is common in bacterial or fungal endophthalmitis, and toxoplasmosis is a major cause of ocular morbidity and poor vision after congenital or acquired infection. Some infections cause intraocular damage by indirect mechanisms (eg, HIV-mediated immunosuppression), leading to opportunistic infections such as cytomegalovirus infection, periocular nerve involvement due to leprosy, and hypersensitivity reactions in tuberculosis. Eye symptoms might indicate an underlying infection, such as the development of retinal ischaemia in severe malaria, which is associated with a poor prognosis.

A successful outcome for patients with ocular infection depends on close collaboration between clinicians identifying and treating the underlying disease, specialist ophthalmic drug review, increased understanding of advanced systems for delivery of ophthalmic drugs, and ophthalmic interventional skills.

To this end, this thesis aimed to review the current state of the diagnosis and treatment of bacterial ocular infections. It has highlighted the importance of early detection and the need for better delivery systems for eye treatment. It has examined the existing data for the penetration of antibiotics into the eye during severe ocular infections and has presented a guide to the most effective drugs or drug combinations for the treatment of

the more common types of ocular infections with particular attention to the most commonly used antibiotics.

Finally, this thesis has, for the first time, presented a formulary created by the Pharmacy Department of Moorfields Eye Hospital as a guideline to clinicians and ophthalmic specialists for the most commonly used ophthalmic drugs. It is hoped that this may benefit both researchers and clinicians in their efforts to overcome the existing challenges for the treatment of eye diseases.

## **IX. REFERENCES**

- 1- **Driebe, W. T., S. Mandelbaum, R. K. Forster, L. K. Schwartz, and W. W. Culbertson.** 1986. Pseudophakic endophthalmitis. Diagnosis and management. *Ophthalmology* 93:442–448
- 2- **Okhravi, N., H. M. A. Towler, P. Hykin, M. Matheson, and S. Lightman.** 1997. Assessment of a standard treatment protocol on visual outcome following presumed bacterial endophthalmitis. *Br. J. Ophthalmol.* 81:719–725.
- 3- **Foster, R. E., J. A. Martinez, T. G. Murray, P. E. Rubsamen, H. W. Flynn, and R. K. Forster.** 1996. Useful visual outcomes after treatment of *Bacillus cereus* endophthalmitis. *Ophthalmology* 103:390–397
- 4- **Johnson, M. W., B. H. Doft, S. F. Kelsey, M. Barza, L. A. Wilson, C. C. Barr, S. R. Wisniewski, and the Endophthalmitis Vitrectomy Study Group.** 1997. The Endophthalmitis Vitrectomy Study: relationship between clinical presentation and microbiologic spectrum. *Ophthalmology* 104:261–272.
- 5- **Beard, C., and M. H. Quickert.** 1988. *Anatomy of the orbit: a dissection manual.* Aesculapius Publishing Co., Birmingham, Ala
- 6- **Snell, R. S., and M. A. Lemp.** 1989. *Clinical anatomy of the eye.* Blackwell Scientific Publications, Boston, Mass
- 7- **Clyde W. Oyste.** 1999. *The Human Eye: Structure and Function (Hardcover),* 1st edition
- 8- **Li XY, D'Orazio LT, and Niederkorn JY,** 1996, Role of Th1 and Th2 cells in anterior chamber-associated immune deviation. *Immunology.* Sep;89(1):34-40
- 9- **Foster CS, Power WJ.** 1996. Basic Ocular Immunology. In: Seminar in Ophthalmology, Uveitis and Ocular Inflammation; (Friberg TR, Wu HK, eds.) W.B. Saunders, Philadelphia, PA. 11(1):3-9
- 13- **Streilein, J. W.** Ocular Immune Privilege, 2001. Protection That Preserves Sight. *Karger Gazette* 64: 5-8
- 14- **Stein-Streilein, J., and Streilein, J.W.** 2002. Anterior chamber associated immune deviation (ACAIID): regulation, biological relevance, and implications for therapy. *International Reviews of Immunology: The Eye Immunity and Autoimmunity* 21: 123-152
- 15- **Nassif, K. F.** 1996. Ocular surface defense mechanisms. *Infections of the eye.* Little, Brown and Company, New York, N.Y.



- 16- **Streilein JW**. 1999. Immune Response and the Eye. Chem Immunol. Basel, Karger, vol 73.
- 17- **Streilein JW**. 1999. Regional immunity and ocular immune privilege. Chem Immunol. Basel, Karger, vol 73, pp 11-38.
- 18- **Streilein JW**. 1999. Immunobiology and immunopathology of corneal transplantation. Chem Immunol. Basel, Karger, vol 73, pp 186-206.
- 19- **Taylor AW**. 1999. Ocular immunosuppressive microenvironment. Chem Immunol. Basel, Karger, vol 73, pp 72-89.
- 20- **Sonoda KH, Exley M, Snapper S, Balk SP, Stein-Streilein**. 1999: CD1-reactive natural killer T cells are required for development of systemic tolerance through an immune-privileged site. J Exp Med,190:1215-1226.
- 21- **Streilein JW, Stein-Streilein J**. 2000. Does innate immune privilege exist? J Leukoc Biol;67:479-487.
- 22- **TA Ferguson and JM Herndon**. 1994. The immune response and the eye: the ACAID inducing signal is dependent on the nature of the antigen, Investigative Ophthalmology & Visual Science, Vol 35, 3085-3093,
- 23- **Ferguson TA, Kaplan HJ**. 1987. The immune response and the eye: I: The effects of monoclonal antibodies to T suppressor factors in anterior chamber associated immune deviation (ACAID). / Immunol.;39:346-351.
- 24- **Wilbanks GA, Mammolenti M, Streilein JW**. 1992. Studies on the induction of anterior chamber-associated immune deviation (ACAID): III: Induction of ACAID depends upon intraocular transforming growth factor beta. EurJ Immunol. 22:165-173.
- 25- **Streilein JW, Atherton SS, Vann V. A**. 1987. critical role for ACAID in the distinctive pattern of retinitis that follows anterior chamber inoculation of HSV-1. Curr Eye Res. 6:127-131.
- 26- **Allansmith, M. R**. 1982. The eye and immunology. Mosby, St. Louis, Mo
- 27- **Nassif, K. F**. 1996. Ocular surface defense mechanisms. Infections of the eye. Little, Brown and Company, New York, N.Y
- 28- **Fredrickson, A. B**. 1969. Behavior of mixed culture of microorganisms. Annu. Rev. Microbiol. 31:63
- 29- **Mannis, M. J., and G. Smolin**. 1996. Natural defense mechanism of the ocular surface. Ocular infection and immunity. Mosby, St. Louis, Mo

- 30- **Adams, A. D.** 1979. The morphology of human conjunctival mucus. *Arch. Ophthalmol.* **97**:730-734
- 31- **Butrus, S. I., and S. A. Klotz.** 1986. Blocking Candida adherence to contact lenses. *Curr. Eye Res.* **5**:745-750
- 32- **Chandler, J. W., and T. E. Gillette.** 1983. Immunologic defense mechanism of the ocular surface. *Ophthalmology* **90**:583-591
- 33- **Gillette, T. E., J. W. Chandler, and J. V. Greiner.** 1982. Langerhans cells of the ocular surface. *Ophthalmology* **89**:700-711
- 34- **Cullor, J., M. J. Mannis, C. J. Murphy, W. L. Smith, M. E. Selsted, and T. W. Reid.** 1990. In vitro antimicrobial activity of defensins against ocular pathogens. *Arch. Ophthalmol.* **108**:861-864
- 35- **Chu W, Pavan-Langston D.** 1979. Ocular surface manifestations of the major viruses. *Int Ophthalmol Clin.* Summer;19(2):135-67.
- 36- **Kaufman HE.** 2000. Treatment of viral diseases of the cornea and external eye, *Prog Retin Eye Res.* Jan;19(1):69-85
- 37- **Pavan-Langston D.** 1980. Ocular antiviral therapy, *Int Ophthalmol Clin.* Fall;20(3):149-61
- 38- **Mader TH, Stulting RD.** 1992. Viral Keratitis, : *Infect Dis Clin North Am.* Dec;6(4):831-49
- 39- **Liesegang, T. J., and R. F. Forster.** 1980. Spectrum of microbial keratitis in South Florida. *Am. J. Ophthalmol.* **90**:80
- 40- **Stephen A. Klotz, Christopher C. Penn, Gerald J. Negvesky, and Salim I. Butrus.** 2000. Fungal and Parasitic Infections of the Eye, *Clinical Microbiology Reviews*, October, p. 662-685, Vol. 13, No. 4
- 41- **Van Buren, J. M.** 1958. Septic retinitis due to *Candida albicans*. *Arch. Pathol.* **65**:137
- 42- **Hughes D S, Hill R J.** 1994. Infectious endophthalmitis after cataract surgery. *Br J Ophthalmol.* **78**:227-232
- 43- **Pettit, T. H., R. J. Olson, R. Y. Foos, and W. J. Martin.** 1980. Fungal endophthalmitis following intraocular lens implantation. A surgical epidemic. *Arch. Ophthalmol.* **98**:1025-1039

- 44- **Stern, W. H., E. Tamura, R. A. Jacobs.** 1985. Epidemic postsurgical *Candida parapsilosis* endophthalmitis. *Ophthalmology* 92:1701-1709
- 45- **Wong, T., K. S. Fong, and D. T. Tan.** 1997. Clinical and microbial spectrum of fungal keratitis in Singapore: a 5-year retrospective study. *Int. Ophthalmol.* 21:127-130
- 46- **Doughman, D., N. M. Leavenworth, R. C. Campbell, and R. L. Lindstrom.** 1982. Fungal keratitis at the University of Minnesota: 1971-1981. *Trans. Am. Ophthalmol. Soc.* 80:235-247
- 47- **Baum, J., and M. Barza.** 1998. Infections of the eye, p. 1355-1373. In S. L. Gorbach, J. G. Bartlett, and N. R. Blacklow (ed.), *Infectious diseases*. W.B. Saunders Company, Philadelphia, Pa
- 48- **Akler, M., H. Vellend, D. M. McNeely, S. L. Walmsley, and W. L. Gold.** 1995. Use of fluconazole in the treatment of candidal endophthalmitis. *Clin. Infect. Dis.* 20:657-664
- 49- **Luttrull, J., W. L. Wan, B. M. Kubak, M. D. Smith, and H. A. Oster.** 1995. Treatment of ocular fungal infections with oral fluconazole. *Am. J. Ophthalmol.* 119:477-481
- 50- **Pleyer, U., J. Grammer, J. H. Pleyer, P. Kosmidis, D. Fries, K. H. Schmidt, and H. J. Thiel.** 1995. Amphotericin B—bioavailability in the cornea. Studies with local administration of liposome incorporated amphotericin B. *Ophthalmogenetics* 92:469-475
- 51- **Rahman, M., D. C. Minassian, M. Srinivasan, M. J. Martin, and G. J. Johnson.** 1997. Trial of chlorhexidine gluconate for fungal corneal ulcers. *Ophthalmic Epidemiol.* 4:141-149
- 52- **Frenkel, J.** 1971. Toxoplasmosis, p. 254-290. In R. Marcial-Rojas (ed.), *Pathology of protozoal and helminthic diseases*. Williams and Wilkins, Baltimore, Md
- 53- **O'Connor, G.** 1974. Manifestations and management of ocular toxoplasmosis. *Bull. N.Y. Acad. Med.* 50:192-210
- 54- **Feldman, H.** 1982. Epidemiology of toxoplasma infections. *Epidemiol. Rev.* 4:204-213
- 55- **Kean, B., T. Sun, and R. Ellsworth.** 1991. *Color atlas/text of ophthalmologic parasitology*, 1st ed. Igaku-Shoin, New York, N.Y
- 56- **Amoils SP, Heney C.** 1999, *Acanthamoeba* keratitis with live isolates treated with cryosurgery and fluconazole. *Am J Ophthalmol.* 1999 Jun;127(6):718-20

- 57- **Behbahani, R., M. Moshfeghi, and J. Baxter.** 1995. Therapeutic approaches for AIDS-related toxoplasmosis. *Ann. Pharmacother.* 29:760-768
- 58- **Engstrom, R. J., G. Holland, R. Nussenblatt, and D. Jabs.** 1991. Current practices in the management of ocular toxoplasmosis. *Am. J.Ophthalmol.* 111:601-610
- 59- **Schimkat, M., C. Althaus, C. Armbrecht, H. Jablonowski, and R. Sundmacher.** 1995. Treatment of toxoplasmosis retinochoroiditis with atovaquone in an AIDS patient. *Klin. Monatsbl. Augenheilkd.* 206:173-177
- 60- **Amoils SP, , Heney C.** 1999, Acanthamoeba keratitis with live isolates treated with cryosurgery and fluconazole. *Am J Ophthalmol.* Jun;127(6):718-20
- 61- **Oehme A, Musholt PB, Dreesbach K.** 1991, Chlamydiae as pathogens, an overview of diagnostic techniques, clinical features, and therapy of human infections. *Klin Wochenschr.* Aug 1;69(11):463-73
- 62- **Leeming, J.P.** 1991, Treatment of ocular infections with topical antibacterials. *Clin Pharmacokinet.* Nov;37(5):351-60.
- 63- **Donahue, S P, Schwartz, G.** 1998, Preseptal and orbital cellulitis in childhood. A changing microbiologic spectrum. *Ophthalmology*, 105(10), 1902-5
- 64- **Ben-Tovim, T., Eylan, E., Romano, A. and Stein, R.**1974, Gram-negative bacteria isolated from external eye infections. *Infection* 2,162–165
- 65- **Callegan MC, O'Callaghan RJ, Hill JM.** 1994,Pharmacokinetic considerations in the treatment of bacterial keratitis. *Clin Pharmacokinet.* Aug;27(2):129-49
- 66- **Baum J.** 1986, Therapy for ocular bacterial infection. *Trans Ophthalmol Soc U K.* 1986;105 ( Pt 1):69-77
- 67- **Daniell M.** 2003, Overview: Initial antimicrobial therapy for microbial keratitis. *Br J Ophthalmol.* Sep;87(9):1172-4.
- 68- **Lemp MA, Blackman HJ, Koffler BH.** 1980, Therapy for bacterial and fungal infections. *Int Ophthalmol Clin.* Fall;20(3):135-47.
- 69- **Steinert RF.** 1991, Current therapy for bacterial keratitis and bacterial conjunctivitis. *Am J Ophthalmol.* Oct;112(4 Suppl):10S-14S.
- 70- **McCabe WR.** 1974, Gram-negative bacteremia. *Adv Intern Med.*;19:135-58. Review
- 71- **Boxerbaum B.** 1974 Antimicrobial drugs for treatment of infections caused by aerobic gram-negative bacilli. *Med Clin North Am.* May;58(3):519-3271

- 72- **Okhravi N, Towler H M A, Hykin P, Matheson M M, Lightman S.** 1997. Assessment of a standard treatment protocol on visual outcome following presumed bacterial endophthalmitis. *Br J Ophthalmol.* 81:719–725
- 73- **Bazra M, Pavan P R, Doft B H, Wisniewski S R, Wilson L A, Han D P, Kelsey S F.** 1997. Evaluation of microbiological diagnostic techniques in postoperative endophthalmitis in the endophthalmitis vitrectomy study. *Arch Ophthalmol.* 115:1142–1150.
- 74- **Records R E, Iwen P C.** 1989. Experimental bacterial endophthalmitis following extracapsular lens extraction. *Exp Eye Res.* 49:729–737.
- 75- **Rogers N K, Fox P D, Noble B A, Kerr K, Inglis T.** 1994. Aggressive management of an epidemic of chronic pseudophakic endophthalmitis: results and literature survey. *Br J Ophthalmol.* 78:115–119.
- 76- **Doft B H, Kelsey S F, Wisniewski S, Metz D J, Lobes L, Rinkoff J, Davis M, Kassof A.** 1994. Treatment of endophthalmitis after cataract extraction. *Retina.* 14(4):297–304.
- 77- **Busin M, Cusumano A, Spitznas M.** 1995. Intraocular lens removal from eyes with chronic low-grade endophthalmitis. *J Cataract Refract Surg.* 21:679–684.
- 78- **Kalicharan D, Jongebloed W L, Los L I, Worst J G F.** 1992. (Anaerobic bacteria found in the secondary-cataract material. A SEM/TEM study. *Doc Ophthalmol.* 82:125–133.
- 79- **Okhravi N, Towler H M A, Hykin P, Matheson M M, Lightman S.** 1997. Assessment of a standard treatment protocol on visual outcome following presumed bacterial endophthalmitis. *Br J Ophthalmol.* 81:719–725.
- 80- **Okhravi, N, Adamson, P, Matheson, MM, Towler, HMA, Lightman, S.** 2000. PCR/RFLP based detection and speciation of bacteria causing endophthalmitis *Invest Ophthalmol Vis Sci* 41,1438-1447
- 81- **Carroll, N, Adamson, P, Okhravi, N.** 1999. Elimination of contaminating bacterial DNA in Taq polymerase *J Clin Microbiol* 37,3402-3404
- 82- **Okhravi, N, Adamson, P, Lightman, S.** 1999. Polymerase chain reaction in the diagnosis of bacterial endophthalmitis (letter) *Br J Ophthalmol* 83,378-380
- 83- **Carroll, NM, Jaeger, EEM, Choudhury, S.** 2000. Detection of and discrimination between Gram positive/Gram negative bacteria in intraocular samples using nested PCR *J Clin Microbiol* 38,1753-1757

- 84- **Li, Z, Deguchi, T, Yasuda, M.** 1998. Alteration in the GyrA subunit of DNA gyrase and the ParC subunit of DNA topoisomerase IV in quinolone-resistant clinical isolates of *Staphylococcus epidermidis* Antimicrob Agents Chemother 42:3293-3295
- 85- **Druel, B, Vandenesch, F, Greenland, T.** 1996. Aseptic meningitis after neurosurgery: a demonstration of bacterial involvement Clin Microbiol Infect 1,230-234
- 86- **Betts RF, Valenti WM, Chapman SW.** 1984. Five-year surveillance of aminoglycoside usage in a university hospital. Ann Intern Med 100:219-222
- 87- **Duncan IBR, Cheung EY, Haldane EV.** 1981. Resistance to aminoglycoside antibiotics of gram-negative bacilli isolated in Canadian hospitals. Can Med Assoc J 124:1165-1 167
- 88- **Moellering RC Jr, Wennersten C, Kunz U, Poitras JW.** 1977. Resistance to gentamicin, tobramycin, and amikacin among clinical isolates of bacteria. Am J Med 62:873-881
- 89- **Ristuccia AM, Cunha BA.** 1982. The aminoglycosides. Med Clin North Am 66:303-312
- 90- **Benson H.** 1974. Permeability of the cornea to topically applied drugs. Arch Ophthalmol 91:313-327
- 91- **Shell JW.** 1982. Pharmacokinetics of topically applied ophthalmic drugs. Surv Ophthalmol 26:207-218
- 92- **Davis SD, Sarff LD, Hyndiuk RA.** 1978. Topical tobramycin therapy of experimental *Pseudomonas keratitis*: An evaluation of some factors that potentially enhance efficacy. Arch Ophthalmol 96:123-125
- 93- **Baum J.** 1982. Treatment of bacterial ulcers of the cornea in the rabbit: A comparison of administration by eye drops and subconjunctival injections. Trans Am Ophthalmol Soc 80:369-390
- 94- Medicines, Ethics and Practice. A guide for pharmacists. Number 22. London: The Royal Pharmaceutical Society of Great Britain, 1999
- 95- **Seal DV, Barrett SP, McGill JI.** 1982. Aetiology and treatment of acute bacterial infection of the external eye. Br J Ophthalmol 66:57-60.
- 96- **Edwards C, Stillman P.** 1993. Minor illness or major disease? Eye disorders. Pharm J 250:839-43.
- 97- National Acanthamoeba Keratitis Study Group. Acanthamoeba keratitis: multicentre survey on England 1992-6. Br J Ophthalmol 1998; 82:1387-92.

- 98- **Rowley S.** 1997. Conjunctivitis: causes, diagnosis and management. *Prescriber* 8:33-44.
- 99- **Woolard E, Frank M.** 1991. Management of dry eye. *On Continuing Practice* ;18:41-5.
- 100- **Eady EA, Cove JH.** 1990. Topical antibiotic therapy: current status and future prospects. *Drugs Exp Clin Res* 16:423-33
- 101- **Elder MJ, Kilvington S, Dart JKG.** 1994. A clinicopathologic study of in vitro sensitivity testing and *Acanthamoeba* keratitis. *Invest Ophthalmol Vis Sci*;35:1059-64
- 102- **Varga JH, Wolf TC, Jensen HG, Parmley VC, Rowsey JJ.** 1993. Combined treatment of *Acanthamoeba* keratitis with propamidine, neomycin and polyhexamethylene biguanide. *Am J Ophthalmol* 115:466-70.
- 103- **Hay J, Kirkness CM, Seal DV, Wright P.** 1994. Drug resistance and *Acanthamoeba* keratitis: the quest for alternative antiprotozoal chemotherapy. *Eye* 8:555-63.
- 104- **Brunette JR, Bernier G, Amyot M, Lefebvre M.** 1967 Clinical study of framycetin ophthalmic preparations. *Can J Ophthalmol* ;2:216-21.
- 105- **Dirdal M.** 1987. Fucithalamic in acute conjunctivitis. Open, randomized comparison of fusidic acid, chloramphenicol and framycetin eye-drops. *Acta Ophthalmol* 65:129-33.
- 106- **Gwon A.** 1992. Topical ofloxacin compared with gentamicin in the treatment of external ocular infection. *Br J Ophthalmol* 76:714-8.
- 107- **Mehta NJ, Webb RM, Krohel GB, Smith RS.** 1984. Clinical inefficacy of tobramycin and gentamicin sulphate in the treatment of ocular infections. *Cornea*;3:228.
- 108- **Ellerhost B, Golden B, Jarudi N.** 1975. Ocular penetration of topically applied gentamicin. *Arch Ophthalmol*;93:371.
- 109- **Lesar TS, Fiscella RG.** 1985 Antimicrobial drug delivery to the eye. *Drug Intell Clin Pharm* 19:642-54.
- 110- **Timewell RM, Rosenthal AL, Smith JP, Cagle GD.** 1983. Safety and efficacy of tobramycin and gentamicin sulfate in the treatment of external ocular infections of children. *J Pediatr Ophthalmol Strabismus* 20:22-6
- 111- **Allan BDS, Dart JKG.** 1995. Strategies for the management of microbial keratitis. *Br J Ophthalmol* 79:777-86.

- 112- **Beasley H, Boltralik JJ, Baldwin HA.** 1975. Chloramphenicol in aqueous humour after topical application. *Arch Ophthalmol* 93:184-185.
- 113- **Doona M, Walsh JB.** 1995. Use of chloramphenicol as topical eye medication: time to cry halt. *BMJ* 310:1217-8.
- 114- **Titcomb LC.** 1997. Ophthalmic chloramphenicol and blood dyscrasias - a review. *Pharm J* 258:28-35.
- 115- **Walker S, Diaper CJM, Bowman R, Sweeney G, Seal DV, Kirkness CM.** 1998. Lack of evidence for systemic toxicity following topical chloramphenicol use. *Eye* 12:875-9.
- 116- **Lancaster T, Swart AM, Jick H.** 1998. Risk of serious haematological toxicity with use of chloramphenicol eye-drops in a British general practice database. *BMJ* 316:667.
- 117- **Wilholm B, Kelly JP, Kaufman D, Issaragrisil S, Levy M, Anderson T.** 1998. Relation of aplastic anaemia to use of chloramphenicol eye-drops in two international case-control studies. *Ibid* 316:666.
- 118- **Barrett S.** 1994. Tetracyclines: their role today in general practice. *Prescriber* 5:41-6.
- 119- **Neu HC.** 1978. Symposium on the tetracyclines: a major appraisal. *Bull New York Acad Med* 54:141-55.
- 120- **Taylor D.** 1983. The sticky eyed infant. *BMJ* 286:1770-1.
- 121- **Laga M, Plummer FA, Piot P, Datta P, Namaara W, Ndinya-Achola JO.** 1988. Prophylaxis of gonococcal and chlamydial ophthalmia neonatorum: silver nitrate versus tetracycline. *N Engl J Med* 318:653-7.
- 122- **Rettig PJ, Patamasucon P, Siegel JD.** 1981. Post-natal prophylaxis of chlamydial conjunctivitis. *JAMA* 246:2321-2.
- 123- **Tabbara K, Abu El-Asrar, Al-Omar A, Choudhury A, Al Faisal Z.** 1996. Single-dose azithromycin in the treatment of trachoma. *Ophthalmology* 103:842-6.
- 124- **Gray TB, Keenan JI, Clemett RS, Allardyce RA.** 1992. Fusidic acid prophylaxis before cataract surgery: patient self-administration. *Aust New Zealand J Ophthalmol* 21:99-103.
- 125- **Hansen S.** 1985. Intraocular penetration of fusidic acid with topical Fucithalamic. *Eur J Drug Metab Pharmacokinet* 10:329-31.



- 126-**Thorn P, Johansen S.** 1997. Pharmacokinetic investigation of fusidic acid 1 per cent viscous eye-drops in healthy volunteers. *Eur J Ophthalmol* 7:9-12.
- 127-**Sinclair NM, Leigh DA.** 1988. A comparison of fusidic acid viscous eye-drops and chloramphenicol eye ointment in acute conjunctivitis. *Curr Ther Res* 44:468-74.
- 128-**Kearns PP, Cullen JF.** 1992. Fucithalamic, chloramphenicol or no treatment after squint surgery in children. A single blind randomised study. *Acta Ophthalmologica* 70:132-4.
- 129-**Boberg-Ans G, Nissen KR.** 1998. Comparison of Fucithalamic viscous eye-drops and chloramphenicol eye ointment as a single treatment in corneal abrasion. *Acta Ophthalmol Scand* 76:108-11.
- 130-**Seal DV, Wright P, Ficker L, Hagan K, Troski M, Menday P.** 1995. Placebo controlled trial of fusidic acid gel and oxytetracycline for recurrent blepharitis and rosacea. *Br J Ophthalmol* 79:42-5.
- 131-**Bendtzen K, Diamant M, Faber V.** 1990. Fusidic acid, an immunosuppressive drug with functions similar to cyclosporin A. *Cytokine* 2:423-9.
- 132- **Titcomb LC.** 2000. Over-the-counter ophthalmic preparations. *Pharm J* 264:212-8.
- 133- **Wright P, Warhurst D, Jones BR.** 1985. Acanthamoeba keratitis successfully treated medically. *Br J Ophthalmol* ;69:778-82.
- 134- **Lindquist TD.** 1998. Treatment of Acanthamoeba keratitis. *Cornea* 17:11-6.
- 135- **Alizadeh H, Silvany RE, Meyer DR, Dougherty JM, McCulley JP.** 1997. In vitro amoebicidal activity of propamidine and pentamidine isethionate against Acanthamoeba species and toxicity to corneal tissues. *Cornea* 16:94-100.
- 136-**Varga JH, Wolf TC, Jensen HG, Parmley VC, Rowsey JJ.** 1993. Combined treatment of Acanthamoeba keratitis with propamidine, neomycin and polyhexamethyl biguanide. *Am J Ophthalmol* 115:466-70.
- 137-**Hargrave SL, McCulley JP, Hussein Z.** 1999. For the Brolene Study Group. Results of a trial of combined propamidine isethionate and neomycin therapy for acanthamoeba keratitis. *Ophthalmology* 106:952-7.
- 138-**Duguid IGM, Dart JKG, Morlet N, Allan BDS, Matheson M, Ficker L.** 1997. Outcome of acanthamoeba keratitis treated with polyhexamethyl biguanide and propamidine. *Ophthalmology* 104:1587-92.

- 139-**Seal DV, HAY J, Kirkness CM, Morrell A, Booth A, Tullo A.** 1996. Successful medical therapy of Acanthamoeba keratitis with topical chlorhexidine and propamidine. *Eye* 10:13-21.
- 140-**Radford CF, Lehmann OJ, Dart JKG.** 1998. For the National Acanthamoeba Keratitis Study Group. Acanthamoeba keratitis: multicentre survey in England 1992-6. *Br J Ophthalmol* 82:1387-92.
- 141-**Janknegt R.** 1986. Fluorinated quinolones: a review of their mode of action, antimicrobial activity, pharmacokinetics and clinical efficacy. *Pharmaceutisch Weekblad Scientific Edition* 8:1-21.
- 142-**Neu HC.** 1991. Microbiologic aspects of fluoroquinolones. *Am J Ophthalmol* 112:15S-24S.
- 143-**Uchida Y;** 1991. Clinical efficacy of topical lomefloxacin (NY-198) in bacterial infections of the external eye. *Folia Ophthalmol Jap* 42:59-70.
- 144-**Lewin CS, Smith JT.** 1988. Bactericidal mechanisms of ofloxacin. *J Antimicrob Chemother*;22:SupplC1-8.
- 145-**Donnenfield ED, Schrier A, Perry HD, Aulicino T, Gombert ME, Snyder R.** 1994. Penetration of topically applied ciprofloxacin, norfloxacin and ofloxacin into the aqueous humor. *Ophthalmology* 101:902-5.
- 146-**Çekiç O, Batman C, Totan Y, Yasar Ü, Basci NE, Bozkurt A.** 1999. Aqueous humour levels of topically applied ciprofloxacin and ofloxacin in the same subjects, *Eye* 13:656-9.
- 147-**Borrman L, Tang-Liu D, Kann J, Nista J, Lin ET, Frank J.** 1992. Ofloxacin in human serum, urine and tear film following topical application. *Cornea* 11:226-30.
- 148-**Kodama T;** 1991. NY 198 (lomefloxacin): penetration of lomefloxacin ophthalmic solution into the aqueous. *Jap Rev Clin Ophthalmol* 85:493-5.
- 149-**Power WJ, Collum LMT, Easty DL, Bloom PA, Laidlaw DAH, Libert J.** 1993. Evaluation of efficacy and safety of ciprofloxacin ophthalmic solution versus chloramphenicol. *Eur J Ophthalmol* 3:77-82.
- 150-**Liebowitz HM.** 1991. Antibacterial effectiveness of ciprofloxacin 0.3 per cent ophthalmic solution in the treatment of bacterial conjunctivitis. *Am J Ophthalmol* 112:29S-33S.
- 151-**Wilhelmus KR, Hyndiuk RA, Caldwell DR, Abshire RL, Folkens AT, Godio LB.** 1993. 0.3% ciprofloxacin ophthalmic ointment in the treatment of bacterial keratitis. The Ciprofloxacin Ointment/Bacterial Keratitis Study Group. *Arch Ophthalmol.* ep;111(9):1210-8.

- 152- **Parks DJ, Abrams DA, Sarfarazi FA, Katz HR.** 1993. Comparison of topical ciprofloxacin to conventional antibiotic therapy in the treatment of ulcerative keratitis. *Am J Ophthalmol* 115:471-7.
- 153- **Herrin S.** 1996 What's new in antibiotics: Ciloxan vs Ocuflax: The debate continues. *Rev Ophthalmol* 3:106-7.
- 154- **Malminiemi K, Kari O, Latvala ML, Voutilainen R, Miettinen A, Jauch A.** 1996. Topical lomefloxacin twice daily compared with fusidic acid in acute bacterial conjunctivitis. *Acta Ophthalmol Scand* 74:280-4.
- 155- **Agius-Fernandez A, Patterson A, Fsadni M, Jauch A, Sunder Raj P.** 1998. Topical lomefloxacin versus topical chloramphenicol in the treatment of acute bacterial conjunctivitis. *Clin Drug Invest* 15:263-9.
- 156- **Jauch A, Fsadnin M, Gamba G.** 1999. Meta-analysis of six clinical phase III studies comparing lomefloxacin 0.3 per cent eye- drops twice daily to five standard antibiotics in patients with acute bacterial conjunctivitis. *Greafe's Arch Clin Exp Ophthalmol* 237:705-13.
- 157- **Bron AJ, Leber G, Rizk SNM, Baig H, Elkington AR, Kirkby GR.** 1991. Ofloxacin compared with chloramphenicol in the management of external ocular infection. *Br J Ophthalmol* 75:675-9.
- 158- **Gwon A.** 1992. Topical ofloxacin compared with gentamicin in the treatment of external ocular infection. *Br J Ophthalmol* 76:714-8.
- 159- **O'Brien TP, Maguire MG, Fink NE, Alfonso E, McDonnell P.** 1995. Efficacy of ofloxacin vs cefazolin and tobramycin in the therapy of bacterial keratitis. *Arch Ophthalmol.* 113:1257-65.
- 160- **O'Brien TP, Maguire MG.** 1997. Ofloxacin monotherapy for the primary treatment of microbial keratitis. A double-masked, randomized, controlled trial with conventional dual therapy. *Ophthalmology* 104:1902-9.
- 161- **Aoki K, Moroboski ST.** 1986. Clinical effect of ofloxacin ointment for chlamydial conjunctivitis. *Jap J Clin Ophthalmol* 40:985-8.
- 162- **Inoue S.** 1986. Diagnosis of neonatal chlamydial infection by fluorescent antibody technique and its treatment with a new quinolone derivative. *Acta Soc Ophthalmol Jap* 90:1081-4.
- 163- **Shiota H, Kusujima K, Mimura Y.** 1986. Chlamydial conjunctivitis in adults. *Acta Soc Ophthalmol Jap* 90:1085-9.

- 164-**Matsumura K, Inoue S.** 1986. A study on diagnosis and treatment of chlamydial infection of conjunctiva. *Acta Soc Ophthalmol Jap* 1986;90:1090-3.
- 165-**Tamura O, Abe M.** 1986.. Neonatal ophthalmia due to chlamydial infection. *Acta Soc Ophthalmol Jap* 90:1094-6.
- 166-**Bailey JMG, Heppleston C, Richmond SJ.** 1984. Comparison of the in vitro activities of ofloxacin and tetracycline against *Chlamydia trachomatis* as assessed by indirect immunofluorescence. *Antimicrob Agents Chemother* 26:13-6.
- 167-**Bower K, Kowalski R, Gordon M.** 1996. Fluoroquinolones in the treatment of bacterial keratitis. *Am J Ophthalmol* 121:712-5.
- 168-**Allan BDS, Dart JKG.** 1995. Strategies for the management of microbial keratitis. *Br J Ophthalmol* 79:777-86.
- 169-**Goldstein MH, Kowalski RP, Gordon YJ;** 1999. Emerging fluoroquinolone resistance in bacterial keratitis. A 5-year review. *Ophthalmology* 106:1313-8.
- 170-**Garg P, Sharma S, Rao GN.** 1999. Ciprofloxacin-resistant *Pseudomonas* keratitis. *Ophthalmology* 106:1319-23.
- 171-**Campen TJ, Vij NK, Steen DW.** 1995. Comparison of ofloxacin and ciprofloxacin in the treatment of *Streptococcus pneumoniae* keratitis in the rabbit. *Invest Ophthalmol Vis Sci* 36:S1019.
- 172-**Lu KL, Prajna NV, McDonnell PJ.** 1998. Comparison of ofloxacin and ciprofloxacin in the therapy of bacterial keratitis. *Invest Ophthalmol Vis Sci* 39:S140.
- 173-**Huguet P.** 1992. clinical study with topically applied lomefloxacin 0.3 per cent (DR 1303) in comparison with ofloxacin 0.3 per cent in the treatment of bacterial conjunctivitis. Brussels, Belgium: Proceedings of the IX International Congress of the European Society of Ophthalmology, 23-28
- 174-**Ogawa GSH, Hyndiuk RA.** 1993. The fluoroquinolones: new antibiotics in ophthalmology. *Int Ophthalmol Clin* 33:59-68.
- 175-**Rosenblatt JE, Stewart PR.** 1974. Combined activity of sulphamethoxazole, trimethoprim and polymyxin B against Gram-negative bacilli. *Antimicrob Agents Chemother* 6:84-92.
- 176-**Tirado M, Borrás T, Bergamini MVW.** 1995. Antimicrobial activity of topical anti-infective eye preparations. *Eur J Clin Res* 7:169-75.
- 177-**Gibson JR.** 1983. Trimethoprim-polymyxin B ophthalmic solution in the treatment of presumptive bacterial conjunctivitis - a multicentre trial of its efficacy versus

neomycin-polymyxin B, gramicidin and chloramphenicol ophthalmic solutions. *J Antimicrob Chemother* 11:217-21.

**178-Behrens-Baumann W, Quentin CD, Gibson JR, Calthrop JG, Harvey SG, Booth K.** 1988. Trimethoprim-polymyxin B sulphate ophthalmic ointment in the treatment of bacterial conjunctivitis: a double-blind study versus chloramphenicol ophthalmic ointment. *Curr Med Res Opinion* 11:227-31.

**179-Dy-Liacco JU, Cruz-Nievera LF, Thorn P.** 1991. A comparison of fusidic acid 1 per cent viscous eye drops (Fucithalmic, Leo) and Neosporin eye ointment (Wellcome) in patients with external eye infections. *Int J Clin Prac* 7:81-3.

**180-Barry, A. L., P. C. Fuchs.** 1991. In vitro activities of sparfloxacin, tosufloxacin, ciprofloxacin and fleroxacin. *Antimicrob. Agents Chemother.* 35:955-960.

**181-Barry, A. L., R. N. Jones.** 1989. In-vitro activities of temafloxacin, tosufloxacin (A-61827) and five other fluoroquinolone agents. *J. Antimicrob. Chemother.* 23:527-535.

**182-Barza, M., J. Baum;** 1982. Marked differences between pigmented and albino rabbits in the concentration of clindamycin in iris and in choroid-retina. *J. Infect. Dis.* 139:203-208.

**183-Behrens-Baumann, W., J. Martell;** 1987. Ciprofloxacin concentrations in human aqueous humor following intravenous administration. *Chemotherapy (Basel)* 33:328-330.

**184-Bron, A., D. Talon, B. Delbosc, J. M. Estavoyer, G. Kaya, J.Royer;** 1987. La penetration intracamerulaire de l'ofloxacin chez l'homme. *J. Fr. Ophtalmol.* 10:443-446.

**185-Bron, A., D. Talon, B. Delbosc, J. M. Estavoyer, F. Prost, M. Montard.** 1986. La penetration intracamerulaire de la pefloxacin chez l'homme. *J. Fr. Ophtalmol.* 9:317-321.

**186-Canton, E., J. Peman, M. T. Jimenez, M. S. Ramon, and M. Gobernado.** 1992. In vitro activity of sparfloxacin compared with those of five other quinolones. *Antimicrob. Agents Chemother.* 36:558-565.

**187-Cochereau-Massin, I., J. Bauchet, F. Faurisson, J. M. Vallois, P.Lacombe, and J. J. Pocardalo.** 1991. Ocular kinetics of pefloxacin after intramuscular administration in albino and pigmented rabbits. *Antimicrob. Agents Chemother.* 35:1112-1115.

**188-Cochereau-Massin I, Marrakchi-Benjaafar S, Bauchet J, Vallois JM, Faurisson F, D'Hermies F, Pocardalo JJ.** 1994. Kinetics and tolerability of intravitreal pefloxacin in rabbits. *J Antimicrob Chemother.* Feb;33(2):231-42

**189-Cunha-Vaz, J.** 1980. Sites and functions of the blood-retinal barriers, p. 101-117. In J. Cunha-Vaz (ed.), *Blood-retinal barrier*. Plenum Press, New York.

- 190-**Fisch, A., A. Salvanet, T. Prazuck, F. Forestier, L. Gerbaud, G. Coscas, C. Lafaix.** 1991. Epidemiology of infective endophthalmitis in France. *Lancet* 338:1373-1376.
- 191-**Garcia, I., A. Pascual, C. Guzman, E. J. Perea.**1992. Uptake and intracellular activity of sparfloxacin in human polymorphonuclear and tissue culture cells. *Antimicrob. Agents Chemother.* 36:1053-1056.
- 192-**Granneman, G. R., R. Braeckman, J. Kraut, S. Shupien, J. C. Craft.** 1991. Pharmacokinetics of temafloxacin in humans after single oral doses. *Antimicrob. Agents Chemother.* 35:436-441.
- 193- **Iliadis, A., A. C. Brown, and M. L. Huggins.** Apis: a software for model identification, simulation and dosage regimen calculations in clinical and experimental pharmacokinetics. *Comput.Method Program. Biomed.*, in press.
- 194-**Keren, G., A. Alhalel, B. Bartov, R. Kitzes-Cohen, E. Rubinstein, S. Segev, G. Treister.** 1991. The intravitreal penetration of orally administered ciprofloxacin in humans. *Invest.Ophthalmol. Vis. Sci.* 32:2388-2392.
- 195-**Miller, M. H., A. Madu, G. Samanthanam, D. Rush, C. M. Madu, K. Mathisson, M. Mayers.** 1992. Fleroxacin pharmacokinetics in aqueous humor and vitreous humors determined by using complete concentration-time data from individual rabbits. *Antimicrob. Agents Chemother.* 36:32-37.
- 196-**Montay, G., R. Bruno, J. J. Thebault, J. C. Vergniol, D.Chassard, H. Ebmeier, J. Gaillot.** 1990. Dose-dependent pharmacokinetic study of sparfloxacin in healthy young volunteers. *Program Abstr. 30th Intersci. Conf. Antimicrob. Agents Chemother.*, abstr. 1248.
- 197-**Mounier, M., J. P. Adenis, F. Denis.** 1986. Intraocular penetration of ciprofloxacin after infusion and oral administration. *Pathol. Biol. (Paris)* 36:724-726.
- 198-**Pascual, A., I. Garcia, E. J. Perea.** 1989. Uptake and intracellular activity of an optically active ofloxacin isomer in human neutrophils and tissue culture cells. *Antimicrob. Agents Chemother.* 34:277-280.
- 199-**Salvanet, A., A. Fisch, C. Lafaix, G. Montay, P. Dubayle, F. Forestier.** 1986. Pefloxacin concentrations in human aqueous humor and lens. *J. Antimicrob. Chemother.* 18:199-201.
- 200-**Skoutelis, A. T., S. P. Gartaganis, C. J. Chrysanthopoulos, D.Beermann, C. Papachristou, H. P. Bassaris.** 1988. Aqueous humor penetration of ciprofloxacin in the human eye. *Arch. Ophthalmol.* 106:404-405.

- 201-**Spangler, S. K., M. R. Jacobs, P. C. Appelbaum.** 1992. Susceptibilities of penicillin-susceptible and -resistant strains of *Streptococcus pneumoniae* to RP 59500, vancomycin, erythromycin PD 161628, sparfloxacin, temafloxacin, Win 57273, ofloxacin, and ciprofloxacin. *Antimicrob. Agents Chemother.* 36: 856-859.
- 202-**Visser, M. R., M. Rozenberg-Arska, H. Beumer, I. M. Hoepelman, J. Verhoef.** 1991. Comparative in vitro antibacterial activity of sparfloxacin (AT-4140; RP 64206), a new quinolone. *Antimicrob. Agents Chemother.* 35:858-868.
- 203-**Pea, F., F. Pavan, E. Nascimben, C. Benetton, P. G. Scotton, A. Vaglia, M. Furlanut.** 2003. Levofloxacin disposition in cerebrospinal fluid in patients with external ventriculostomy. *Antimicrob. Agents Chemother.* 47:3104-3108
- 204- **Bucci, F. A., Jr.** 2004. An in vivo study comparing the ocular absorption of levofloxacin and ciprofloxacin prior to phacoemulsification. *Am. J. Ophthalmol.* 137:308-312.
- 205- **Colin, J., S. Simonpoli, K. Geldsetzer, A. Ropo.** 2003. Corneal penetration of levofloxacin into the human aqueous humor: a comparison with ciprofloxacin. *Acta Ophthalmol. Scand.* 81:611-613.
- 206- **Donnenfeld, E. D., H. D. Perry, R. W. Snyder, R. Moadel, M. Elsky, H. Jones.** 1997. Intracorneal, aqueous humor, and vitreous humor penetration of topical and oral ofloxacin. *Arch. Ophthalmol.* 115:173-176.
- 207-**Fiscella, R. G., T. K. Nguyen, M. J. Cwik, B. A. Phillipotts, S. M. Friedlander, D. C. Alter, M. J. Shapiro, N. P. Blair, and J. P. Gieser.** 1999. Aqueous and vitreous penetration of levofloxacin after oral administration. *Ophthalmology* 106:2286-2290
- 208-**Fukuda, M., A. Inoue, K. Sasaki, N. Takahashi.** 2004. The effect of the corneal epithelium on the intraocular penetration of fluoroquinolone ophthalmic solution. *Jpn. J. Ophthalmol.* 48:93-96.
- 209-**Garcia-Saenz, M. C., A. Arias-Puente, M. J. Fresnadillo-Martinez, C. Carrasco-Font.** 2001. Human aqueous humor levels of oral ciprofloxacin, levofloxacin, and moxifloxacin. *J. Cataract Refract. Surg.* 27:1969-1974.
- 210- **Hanioglu-Kargi, S., N. Basci, H. Soysal, A. Bozkurt, E. Gursel, O. Kayaalp.** 1998. The penetration of ofloxacin into human aqueous humor given by various routes. *Eur. J. Ophthalmol.* 8:33-36.
- 211- **Healy, D. P., E. J. Holland, M. L. Nordlund, S. Dunn, C. Chow, R. L. Lindstrom, D. Hardten, E. Davis.** 2004. Concentrations of levofloxacin, ofloxacin, and ciprofloxacin in human corneal stromal tissue and aqueous humor after topical administration. *Cornea* 23:255-263.

- 212- **Kobayakawa, S., T. Tochikubo, A. Tsuji.** 2003. Penetration of levofloxacin into human aqueous humor. *Ophthalmic Res.* 35:97-101.
- 213- **Morlet, N., G. G. Graham, B. Gatus, A. J. McLachlan, C. Salonikas, D. Naidoo, I. Goldberg, C. M. Lam.** 2000. Pharmacokinetics of ciprofloxacin in the human eye: a clinical study and population pharmacokinetic analysis. *Antimicrob. Agents Chemother.* 44:1674-1679
- 214- **Yamada, M., H. Mochizuki, K. Yamada, M. Kawai, Y. Mashima.** 2002. Aqueous humor levels of topically applied levofloxacin in human eyes. *Curr. Eye Res.* 24:403-406.
- 215- **Yamada, M., H. Mochizuki, K. Yamada, M. Kawai, Y. Mashima.** 2003. Aqueous humor levels of topically applied levofloxacin, norfloxacin, and lomefloxacin in the same human eyes. *J. Cataract Refract. Surg.* 29:1771-1775.
- 216- **Neu HC, Chin NX.** 1994. In vitro activity of the new fluoroquinolone trovafloxacin. *Antimicrob Agents Chemother* 38:2615-2622.
- 217- **Gooding BB, Jones RN.** 1993. In vitro antimicrobial activity of CP-99,219, a novel azabicyclo-naphthyridone. *Antimicrob Agents Chemother* 37:349-353.
- 218- **Ng, EW; Samiy,N; Ruoff,KL; Cousins,FV; Hooper,DC; von Gunten,S; D'Amico,DJ; Baker,AS.** 1998, Treatment of experimental Staphylococcus epidermidis endophthalmitis with oral trovafloxacin. *American Journal of Ophthalmology*, 126 (2) 278- 87
- 219- **Perkins RJ, Liu W, Drusano G.** 1995. Pharmacokinetics of ofloxacin in serum and vitreous humor of albino and pigmented rabbits. *Antimicrob Agents Chemother;* 39:1493-1498.
- 220- **Miller MH, Agocha-Madu A, Samathanam G.** 1992. Aqueous and vitreous humor fleroxacin pharmacokinetics using complete concentration-time data from individual rabbits. *Antimicrob Agents Chemother* 36:32-38
- 221- **Mayers M, Madu A, Schwartz E.** 1993 Aqueous and vitreous pharmacokinetics of ciprofloxacin and fleroxacin. ARVO abstracts. *Invest Ophthalmol Vis Sci;* 34 (4,suppl) :S1257.
- 222- **Liu W, Liu Q, Madu A.** 1997. Effects of inflammation on the ocular pharmacokinetics of quinolones with different lipophilicity in vitreous humor of rabbits. ARVO abstracts. *Invest Ophthalmol Vis Sci;*38(4,suppl):S146.
- 223- **Liu Q, Drusano G, Madu A.** 1996. Mechanisms of efflux for fluoroquinolone antibiotics from the vitreous humor of rabbits. ARVO abstracts. *Invest Ophthalmol Vis Sci* 37(3,suppl):S777.



- 224-**Lesk MR, Anlmann H, Marcil G.** 1993. The penetration of oral ciprofloxacin into the aqueous humor, vitreous, and subretinal fluid of humans. *Am J Ophthalmol* 115: 623-628
- 225-**Gatti G, Panozzo G.** 1995 Effect of inflammation on intraocular penetration of intravenous ofloxacin in albino rabbits. *Antimicrob Agents Chemother* 39:549-552
- 226-**Teng R, Liston TE, Harris SC.** 1996. Multiple-dose pharmacokinetics and safety of trovafloxacin in healthy volunteers. *J Antimicrob Chemother* 37:955-963.
- 227-**Liu W, Liu Q, Madu A,** 1997. Effects of inflammation on the ocular pharmacokinetics of quinolones with different lipophilicity in vitreous humor of rabbits. ARVO abstracts. *Invest Ophthalmol Vis Sci* 38(4,suppl):S146.
- 228-**O'Day DM, Jones DB, Patrinely J, Elliott JH.** 1982. Staphylococcus epidermidis endophthalmitis: visual outcome following noninvasive therapy. *Ophthalmology* 89:354-360.
- 229- **Mather R, Karenchak LM, Romanowski EG, Kowalski RP.** 2002, Fourth generation fluoroquinolones: new weapons in the arsenal of ophthalmic antibiotics. *Am J Ophthalmol* Apr;133(4):463-6
- 230- **Garcia-Saenz MC, Arias-Puente A, Fresnadillo-Martinez MJ, Carrasco-Font C.** 2001 Human aqueous humor levels of oral ciprofloxacin, levofloxacin, and moxifloxacin. *J Cataract Refract Surg.* Dec;27(12):1969-74
- 231- **Engelbert M, Mino de Kaspar H, Mette M, Thiel M, Ta CN, Grasbon T, Schulze-Schwering M, Klauss V, Kampik A.** 2003. Intravenous treatment of experimental Staphylococcus aureus endophthalmitis: imipenem versus the combination of ceftazidime and amikacin. *Graefes Arch Clin Exp Ophthalmol.* Dec;241(12):1029-36.
- 232- **Pflugfelder, SC, Hernandez, E, Fliesler, SJ.** 1987. Intravitreal vancomycin: retinal toxicity, clearance, and interaction with gentamicin *Arch Ophthalmol* 105,831-837
- 233- **Hanscom T.** 1995. Results of the Endophthalmitis Vitrectomy Study: a randomized trial of immediate vitrectomy and of intravenous antibiotics for the treatment of postoperative bacterial endophthalmitis *Arch Ophthalmol* 113,1479-1496[Abstr
- 234- **Han, DP, Wisniewski, SR, Wilson, LA.** 1996. Spectrum and susceptibilities of microbiologic isolates in the Endophthalmitis Vitrectomy Study *Am J Ophthalmol* 122,1-17
- 235- **Campochiaro, PA, Lim, JI.** 1994. Aminoglycoside toxicity in the treatment of endophthalmitis: The Aminoglycoside Toxicity Study Group *Arch Ophthalmol* 112,48-53

- 236-**Aaberg, TM, Flynn, HW, Murray, TG.** 1994. Intraocular ceftazidime as an alternative to the aminoglycosides in the treatment of endophthalmitis Arch Ophthalmol 112,18-19
- 237-**Lim, JI, Campochiaro, PA.** 1992. Successful treatment of gram-negative endophthalmitis with intravitreal ceftazidime Arch Ophthalmol 110,1686
- 238-**Roth, DB, Flynn, HW.** 1997 Antibiotic selection in the treatment of endophthalmitis: the significance of drug combinations and synergy Surv Ophthalmol 41,395-401
- 239-**Campochiaro, PA, Green, WR.** 1992. Toxicity of intravitreal ceftazidime in primate retina Arch Ophthalmol 110,1625-1629
- 240-**Irvine, WD, Flynn, HW, Miller, D, Pflugfelder, SC.** 1992. Endophthalmitis caused by gram-negative organisms Arch Ophthalmol 110,1450-1454
- 241-**Fiscella, RG.** 1993. Physical incompatibility of vancomycin and ceftazidime for intravitreal injection Arch Ophthalmol 111,730
- 242-**Lifshitz, T, Lapid-Gortzak, R, Finkelman, Y, Klemperer, I.** 2000. Vancomycin and ceftazidime incompatibility upon intravitreal injection Br J Ophthalmol 84,117-118
- 243-**Le Broulais C, Chevanne F, Ropert P, Bretagne G, Acar L, Zia H, Sado PA, Needham T, Leverage R.** 1996. Release kinetics of liposome-encapsulated ganciclovir after intravitreal injection in rabbits. J Microencapsul. Jul-Aug;13(4):473-80.
- 244-**Kaur IP, Kanwar M.** 2002. Ocular preparations: the formulation approach. Drug Dev Ind Pharm. May;28(5):473-93
- 245-**Le Broulais CA, Treupel-Acar L, Rhodes CT, Sado PA, Leverage R.** 1995. New ophthalmic drug delivery systems. Drug Development and Industrial Pharmacy,21:19-59.
- 246-**Lang JC.** 1995. Ocular drug delivery conventional ocular formulations. Advanced Drug Delivery Reviews16:39-43.
- 247-**Patton TF, Robinson JR.** 1975. Ocular evaluation of polyvinyl alcohol vehicle in rabbits. Journal of Pharmaceutical Sciences, 64:1312-1315
- 248-**Robinson JR.** 1990. Mucoadhesive ocular drug delivery systems. In: Gurny R and Junginger HE (eds),Bioadhesion Possibilities and Future Trends. Wissenschaftliche Verlagsgesellschaft mbH:Stuttgart,Germany, 109-123.
- 249-**Zimmer AK, Chetoni P, Saettone MF, Zerbe H, Kreuter J.** 1995. Evaluation of pilocarpine-loaded albumin particles as controlled drug delivery systems for the eye. II.

Co-administration with bioadhesive and viscous polymers. *Journal of Controlled Release*, 33:31–46.

250-**Nicholls TJ, Cook DJ, Rogers DJ, Green KL, Smart JD.** 1997. Lectins in ocular drug delivery , An in vivo study of lectin retention on ocular surfaces. *Pharmaceutical Sciences*, 3:1–5.

251-**Nagarsenker MS, Londhe VY, Nadkarni G.** 1999. Preparation and evaluation of liposomal formulations of tropicamide for ocular drug delivery. *International Journal of Pharmaceutics*, 190:63–71

252-**Ding S.** 1998. Recent developments in ophthalmic drug delivery. *PSTT*, 1:328–335.

253-**Sasaki H, Yamamura K, Mukai T, Nishida K, Nakamura M.** 1999. Enhancement of ocular drug penetration *Critical Reviews in Therapeutic Drug Carrier Systems*, 16:85–146.

254- **Patton TF, Robinson JR.** 1975. Ocular evaluation of polyvinyl alcohol vehicle in rabbits. *Journal of Pharmaceutical Sciences*, 64:1312–1315

## **X. APPENDIX 1**

**Moorfields Eye Hospital, Hand out (Page 61-71)**

### **EXTERNAL EYE DISEASE**

*Moiz Hameed*

*Ali Safiee*

*David S. Gartry*

### **BLEPHARITIS 1,7,8,10,11**

Infection and/or inflammation of the eyelid margin. The condition is usually bilateral, symmetrical and chronic in nature.

#### *Anterior blepharitis*

- Can be seborrhoeic and/or staphylococcal in nature. Staphylococci known to produce inflammatory exotoxins.

#### *Posterior blepharitis*

- Obstruction of Meibomian glands.

#### *Treatment*

- Lid hygiene: reduces seborrhoea and staphylococcal load.
- Antibiotic: Chloramphenicol 0.5% – 1 drop QDS for 7–14 days.
- Fucidic acid 1% (Fucithalmic ) OD–BD for 7–14 days.

#### *Oral therapy:*

- Doxycycline: 100 mg OD reduced to 50 mg daily.
- Tetracycline: 250 mg BD–QDS.
- Duration typically 2–3 months.

#### *Tear supplements*

Weak topical steroids may be indicated at a later stage:

- e.g. Prednisolone 0.1% drops QDS, reducing to zero over 2 weeks (if marginal keratitis present).
- Hydrocortisone ointment BD–QDS for one month (if marked lid margin hyperaemia).

### **SIMPLE BACTERIAL CONJUNCTIVITIS 1,7,8,10**

Self-limiting commonly seen in childhood. Care should be taken not to spread the disease. Causative organisms include:

- Gram-positive: *Staphylococcus aureus*, *Staphylococcus epidermis*, *Streptococcus pneumoniae*
- Gram-negative: *Haemophilus influenzae*.

#### *Treatment*

Broad-spectrum topical antibiotics are used as the mainstay of treatment and help to shorten the course of the disease.

- Antibiotic drops:
  - Chloramphenicol 0.5% QDS
  - Fucidic acid 1% (Fucithalmic; Leo Pharma) OD–BD

- Ofloxacin 0.3% (Exocin; Allergan Ltd), Ciprofloxacin 0.3% (Ciloxan; Alcon Laboratories UK Ltd) – where Gram negative infection suspected
- Antibiotic ointments:
  - Chloramphenicol 0.5% OD-QDS.

## MICROBIAL KERATITIS

### A. Bacterial keratitis<sup>1,3,4,5,6</sup>

Bacterial infection of the cornea that is commonly attributed to contact lens wear, poor lens hygiene, prolonged topical steroid use and corneal abrasion. Common causative agents include *Pseudomonas aeruginosa*, *Staphylococcus aureus* and Streptococci.

#### Treatment

- Broad-spectrum antibacterial therapy:
  - **Monotherapy:** Ofloxacin 0.3% (Exocin; Allergan Ltd) or Ciprofloxacin 0.3% (Ciloxan; Alcon Laboratories UK Ltd)
  - **Dual Therapy:** Ofloxacin 0.3% (Exocin; Allergan Ltd) or Gentamicin Forte 1.5% (Moorfields Eye Hospital NHS Foundation Trust) and Cefuroxime 5% (Moorfields Eye Hospital NHS Foundation Trust).
    - *Gram-positive bacteria:* Cefuroxime 5% (Moorfields Eye Hospital NHS Foundation Trust).
    - *Gram-negative bacteria:* Gentamicin Forte 1.5% (Moorfields Eye Hospital NHS Foundation Trust), Ofloxacin 0.3% (Exocin; Allergan Ltd), Ciprofloxacin 0.3% (Ciloxan; Alcon Laboratories UK Ltd).  
Frequency: hourly for 48 hours, then 2 hourly for 72 hours, then 4 hourly for 7 days, then stop. Review antibacterials at 48 hours. Change according to microbiological investigations as appropriate.
- Steroids:
  - May be added after a clinical improvement is noted
  - Prednisolone 0.3% (Moorfields Eye Hospital NHS Foundation Trust) QDS
  - May reduce inflammation and in turn lessen degree of scarring and epithelial defects.

### B. Fungal keratitis<sup>1,5</sup>

Fungal infection of the cornea that can be very difficult to treat. Common infective organisms include *Aspergillus*, *Fusarium* (filamentous) and *Candida albicans* (yeast). Causative factors include long-term use of topical steroids, history of ocular surface disease and trauma.

#### Treatment

- Microbiological confirmation of a fungal infection is important, but can take several weeks. Local epidemiological data can be used in deciding treatment. Combination of topical and oral anti-fungals is often used.
- Drops: (Moorfields Eye Hospital NHS Foundation Trust)
    - Imidazoles: econazole 1%, miconazole 1%, clotrimazole 1%
    - Polyenes: Amphotericin B 0.15%.

- Frequency: hourly for 48 hours, then 2 hourly for 72 hours.
- Oral:
  - Triazole: fluconazole, itraconazole, voriconazole
  - Itraconazole 200 mg daily, reduced to 100 mg daily.

### **C Acanthamoeba keratitis<sup>1,2,5</sup>**

Ubiquitous free-living protozoan that can infect the cornea. Exists in two forms, active form (trophozoite) and a resilient dormant form (cyst).

Risk factors: Contact lens usage, poor lens hygiene, agricultural trauma, exposure to pool/spa water e.g. swimming with lenses.

#### *Treatment*

Treatment requires expert ophthalmological management.

Cease contact lens use immediately in both eyes.

Diamidines Propamidine isethionate (Brolene; Aventis Pharma)

Hexamidine di-isethionate 0.1% (Desomedine; Chauvin Pharmaceuticals)

Biguanides Polyhexamethyl biguanide (PHMB) 0.02% (Moorfields Eye Hospital NHS Foundation Trust) – Polihexanide

Chlorhexidine 0.02% (Moorfields Eye Hospital NHS Foundation Trust)

After positive microbiological investigations, initial treatment is with combination of anti-amoebic and trophozoicidal drugs, administered hourly day and night for 2 days then by day only for three days. Toxicity is common if dosage at this intensity is maintained. It is common for doses to be reduced to 3 hourly and then adjusted according to the patient response.

#### Toxicity:

Propamidine can cause indolent corneal ulceration. If toxicity is suspected, Propamidine or Hexamidine can be stopped for 3 days or reduced to four times daily for 7 days. Toxicity with PHMB is rare.

#### Steroids:

The use of steroids is debatable. Steroid treatment may not be required in cases that respond rapidly to anti-amoebic drugs. Persistent inflammation can be treated with Prednisolone 0.5% QDS after two weeks of anti-amoebic therapy.

Severe inflammation can be treated with higher dose steroids used at any time during the course of the disease, dexamethasone 0.1% may be required for control of intraocular inflammation.

### **HERPES SIMPLEX KERATITIS (DENDRITIC ULCER) 1,7,9**

Dendritic ulcers are a secondary manifestation of herpes simplex infection resulting from reactivation of a dormant virus in the cell bodies of corneal sensory neurones<sup>1</sup>.

#### *Treatment*

##### • Topical therapy

- Aciclovir 3% (Zovirax; GlaxoSmithKline) ointment 5 times daily for 5–7 days
- Trifluorothymidine 1% (F3T) drops 5 times daily for 5–7 days (Dose can be

increased to 1 drop every 2 hours – max 9 drops/24 hours)

– Review by clinician in clinic after this period.

- Oral Therapy

– Prophylaxis with Aciclovir 400 mg BD – after clinician review (Consult external eye disease clinic for specialist cases).

- Debridement – as indicated.

## **HERPES ZOSTER OPHTHALMICUS (HZO) – SHINGLES 1,7,10**

This virus can cause irreversible and widespread damage to ocular and periocular tissues. Long-term complications include nerve damage, scarring, persistent inflammation and a dry eye.

### *Treatment*

- Advice:

– Warn patient of infectious nature of disease. Inform patient not to come into contact with those who are pregnant, have not had chickenpox or who have not been immunised against it.

- Oral antivirals

– Indicated within first 72 hours of onset of rash

– Treatment: Aciclovir 800 mg five times daily for 7 days followed by clinician review

– If intolerated:

- Valaciclovir: 1 g TDS for 7 days

- Famaciclovir: 250 mg TDS (750 mg OD) for 7 days.

- Topical antivirals may be indicated but specialist advice may need to be sought

- Aciclovir 3% (Zovirax; GlaxoSmithKline) eye ointment 5 times daily for 7 days.

## **ADENOVIRAL KERATOCONJUNCTIVITIS 1,7,8,11**

A highly contagious protean disease that is self-limiting. Spread is via ocular or respiratory secretions, mainly contact with infected surfaces e.g. towels, tissues and tonometry prisms.

### *Treatment*

- Treat symptoms and provide support.

- Resolution can occur within 2 weeks. Antiviral agents are mostly ineffective and the use of topical steroids for pain relief is debated.

- Care must be taken to prevent spread of the infection, which is highly contagious.

Wiping surfaces with alcohol wipes where appropriate is a suitable method of preventing dissemination of the virus. Tissues should be used instead of handkerchiefs and separate towels should be used in the home.

- Oral non-steroidal anti-inflammatory drugs can provide adequate pain relief where required.

- Hot compress

## BACTERIAL ENDOPHTHALMITIS

Endophthalmitis is infection inside the eye. It is caused by organisms that have travelled through the bloodstream into the eye or have entered the eye through a surgical incision or an injury.

All suspected cases should be investigated by microscopy and culture of aqueous and vitreous biopsies where possible. The microbiological biopsies are usually followed by the administration of broad spectrum intravitreal antibiotics, i.e. **vancomycin** together with **amikacin** or **ceftazidime**. Intravenous and topical fortified antibiotic administration may also be indicated.

### *Treatment*

- Intravitreal antibiotics: vancomycin 2.0 mg in 0.1 ml and amikacin 0.4 mg in 0.1 ml. Amphotericin 5–10 mcg in 0.1 ml if fungi suspected.
- Oral moxifloxacin 400 mg once daily for 10 days. If the patient is less than 12 years old the potential benefits of the treatment need to be balanced against the risks, alternatively we may use ciprofloxacin in children.
- Arrange for base line bloods, weight, blood sugar and blood pressure measurements as patients with presumed bacterial endophthalmitis will need oral prednisolone 1 mg per kg/day to start the next day unless contraindicated systemically (with ranitidine cover). Patients with fungal endophthalmitis should not be given prednisolone.

### **Intravitreal antibiotics for endophthalmitis**

#### **Organism required**

Post surgical *Staphylococcus epidermidis*

*Staphylococcus aureus*

*Streptococci*

Other Gram positives i.e. *Propionobacterium*

Gram negatives

Fungi i.e. *Candida* and *Aspergillus*

Bleb-associated *Streptococci*

*Haemophilus*

Traumatic *Staphylococcus epidermidis*

Polymicrobial

*Bacillus spp.*

Endogenous *Candida*

*Aspergillus*

Gram positives

### **Antibiotics Intravitreal dosage Activity**

Amikacin 0.4 mg Gram negatives and *Pseudomonas*

Ceftazidime 2 mg Gram positive and negatives and

*Pseudomonas*

Gentamicin 0.1–0.2mg Gram negatives and *Pseudomonas*

Vancomycin 1–2mg Gram positives (methicillin resistant).

*Bacillus sp.* Not Gram negatives



Amphotericin 0.005 mg Fungi

Voriconazole 0.05 mg Fungi

### **Suggested intravitreal therapy**

Post-surgical

Early: Amikacin + vancomycin

Bleb associated: IV therapy is mandatory in addition to intravitreal therapy as above

Late: Consider amphotericin for fungus

Post-traumatic Amikacin + vancomycin

Endogenous Consider amphotericin for fungus

### **Pharmacokinetics**

**Route:** Moxifloxacin and ciprofloxacin may achieve adequate levels given systemically, intravitreal route is mandatory for the others.

**Excretion:** Aminoglycosides, and possibly vancomycin, via anterior route (aqueous outflow) half-life approximately 36 hours, but reduced by inflammation and in aphakic vitrectomised eyes. Cephalosporins via posterior route (active transport across retina) half life approximately 10 hours – increased by probenecid and inflammation.

Consequently, the half-life of all of these is about 24 hours in endophthalmitis. This is decreased for gentamicin and vancomycin in aphakic and vitrectomised eyes for which the higher doses should be given.

**Repeated doses:** Little is known of the toxicity. Consider a half dose after the halflife (approximately 24 hours) or a full dose after 3 to 4 half lives (approximately 3 to 4 days).

### **Making up intravitreal injections**

#### **Gentamicin Dose: 0.1–0.2mg in 0.05–0.1 ml**

1. Take 0.5 ml from an ampoule/vial of non preserved gentamicin at 40 mg/ml. (Contains disodium edetate and sodium metabisulphite.)
2. Make up to 10 ml with normal saline in a syringe = 2.0 mg/ml.
3. 0.1 ml of this solution = 0.2 mg.

#### **Amikacin Dose: 0.4 mg in 0.1 ml**

1. Take 2.0 ml from a vial of non preserved amikacin at 250 mg/ml. (Contains sodium citrate and bisulphite).
2. Make up to 10 ml with normal saline = 50 mg/ml.
3. Discard 9 ml and make up remaining ml to 12.5 ml with normal saline = 4 mg/ml.
4. 0.1 ml of this solution = 0.4 mg.

#### **Ceftazidime Dose: 2 mg in 0.1 ml**

1. Reconstitute a 1 g vial with 8 ml of normal saline.
2. Withdraw entire contents and make up to 10 ml with normal saline 10 ml with normal saline = 100 mg/ml.
3. Inject 2 ml back into the vial and add 8 ml of normal saline = 20 mg/ml.
4. 0.1 ml of this solution = 2 mg.

#### **Vancomycin Dose: 1–2 mg in 0.05–0.1 ml**

1. Reconstitute a 500 mg vial with 8 ml of normal saline.
2. Withdraw entire contents and make up to 10 ml with normal saline = 50 mg/ml.
3. Inject 2 ml back into the vial and add 3 ml of normal saline = 20 mg/ml.

4. 0.1 ml of this solution = 2 mg.

**Amphotericin Dose: 0.005 mg in 0.1 ml**

1. Reconstitute a 50 mg vial with 10 ml of water for injection.
2. Withdraw 1 ml and make up to 10 ml with water for injection = 0.5 mg/ml.  
Discard 9 ml.

3. Make up remaining 1 ml of this to 10 ml in Dextrose 5% = 0.05 mg/ml.

4. 0.1 ml of this solution = 0.005 mg.

**Voriconazole Dose: 0.05 mg in 0.1 ml**

1. Reconstitute a 200 mg vial with 19 ml of water for injection.
2. Withdraw 1 ml and make up to 20 ml of water for injection = 0.5 mg/ml
3. 0.1 ml of this solution = 50 mcg.

For intravitreal and subconjunctival doses, see Appendix 1

## NEONATAL CONJUNCTIVITIS

*Jill Bloom – Medicines Information Pharmacist*

*Dr Beng Goh Consultant Physician GUM clinic (Reviewed)*

## CHLAMYDIA TRACHOMATIS

- Initially erythromycin eye ointment three times a day for one month.
- Baby and parents must be referred to a genito-urinary physician.
- Ointment must be followed up by a course of oral erythromycin suspension 50 mg/kg body weight in four divided-doses for two weeks. Treatment of chlamydia conjunctivitis must be aimed not only at the ocular colonisation, but also toward eradication of the naso-pharyngeal carriage and possible development of chlamydia pneumonitis.

## NEISSERIA GONORRHOEAE

Cefuroxime 5% eye drops every two hours and systemic third or fourth generation cephalosporins against penicillin-resistant *Neisseria gonorrhoeae*, chromosomal mediated or plasmid mediated penicillinase-producing *Neisseria gonorrhoeae* (PPNG) IM daily for three days. If unknown sensitivity: IM ceftriaxone 25–50 mg/kg (not to exceed 125 mg) daily for 3 days. (Although this drug is usually only indicated for 1 day, the genitourinary medicine clinic at Moorfields Eye Hospital NHS Foundation Trust advises that it is used for longer.)

If penicillin sensitive, IM Procaine Penicillin 50,000 IU/kg body weight daily for three days. i.e 150,000–300,000 IU. Co-infection with *chlamydia trachomatis* should be excluded.

## PROPHYLAXIS

The value of topical prophylaxis is not established, although it is customary to use topical antibiotics 4 times a day pre-operatively, post-operatively and in the presence of epithelial defects. Pre-operative administration of some subconjunctival antibiotics has been shown to result in therapeutic levels of antibiotics in the aqueous humour, for most of the commonly used prophylactic regimes. **Povidone iodine 5% eye drops** are used in theatres, prior to surgery.

## ADVERSE EFFECTS OF ANTIBACTERIALS

Although not stated in the adverse effects section, it should be noted that all topical antibiotics can cause contact sensitivity.

### ANTI INFECTIVES

#### Cost

#### Product Cost for one month

Amikacin 2.5% sp £££££  
Ampicillin 5% sp £££££  
Ceftazidime 5% sp £££££  
Cefuroxime 5% sp £££££  
Chloramphenicol 0.5% £  
Chloramphenicol 0.5% sp ££££  
Chloramphenicol 0.5% Minims sp (20 units)\* ££££  
Chloramphenicol 1% eye ointment sp £  
Ciloxan 0.3% ££££  
Ciprofloxacin 0.2% sp ££  
Ciprofloxacin 0.3% eye ointment sp ££  
Clarithromycin 2% sp £££££  
Framycetin (Soframycin) 0.5% ££  
Framycetin 0.5% for donor eyes sp £££££  
Fusidic acid (Fucithalmic) 1% viscous eye drops £  
Gentacin 0.3% eye drops £  
Gentamicin 0.3% sp £££££  
Gentamicin 0.3% Minims sp (20 units)\* ££££  
Gentamicin 1.5% ££££  
Gentamicin 1.5% sp £££££  
Neosporin ££  
Ofloxacin (Exocin) 0.3% £  
Penicillin 0.3% sp ££££  
Penicillin buffer solution sp £££££  
Polyfax eye ointment sp £  
Povidine iodine 5% sp £££  
Povidine iodine 5% solution sp ££££  
Vancomycin 5% eye drops sp £££££

*All products are multidose eye drops unless otherwise stated.*

*Prices for multidose, preserved drops are calculated as 1 bottle per month, multidose preservative-free (sp) as*

*4 bottles per month and single use units for use 4 daily for one month.*

*\*Single use*

*£=>£5 ££=£5-10 £££=£10-20 ££££=£20-50 £££££=>£50*

## ANTIBACTERIALS

### AMIKACIN 2.5% EYE DROPS

**Preservative:** None.

**Dose:** Depends on severity of condition.

Severe infections: 1 drop 0.5 to 2 hourly.

Minor infections: 1 drop 4 times a day.

**Uses:** Infections due to *Mycobacteria*.

**Adverse reactions:** Toxic keratoconjunctivitis.

**Other information:** Not commercially available.

### CEFTAZIDIME 5% EYE DROPS

**Preservative:** None.

**Dose:** Depends on severity of condition.

Severe infections: 1 drop 0.5 to 2 hourly.

Minor infections: 1 drop 4 times a day.

**Uses:** Broad spectrum antibiotic, usually effective against *Pseudomonas aeruginosa*.

**Adverse reactions:** –

**Other information:** Expiry is 7 days when stored in a refrigerator and 24 hours at room temperature. Can be kept frozen at  $-20^{\circ}\text{C}$  for 6 months, but expiry is 7 days for the thawed product when stored in a refrigerator. The degradation product is pyridine which is toxic. The eye drops must not be defrosted in a microwave or by artificially warming the solution. Ceftazidime is a third generation cephalosporin and is considered less active against Gram positive organisms than second generation cephalosporins e.g. cefuroxime. Not commercially available.

### CEFUROXIME 5% EYE DROPS

**Preservative:** None.

**Dose:** Depends on severity of condition.

Severe infections: 1 drop 0.5 to 2 hourly.

Minor infections: 1 drop 4 times a day.

**Uses:** Broad spectrum antibiotic, usually effective against

*Staphylococcus*.

**Adverse reactions:** –

**Other information:** *Pseudomonas* resistant.

Expiry is 14 days when stored in a refrigerator, and 24 hours at room temperature. It can be kept frozen for 12 months. Frozen solutions should be thawed at room temperature and shaken thoroughly to redisperse the cefuroxime evenly. The eye drops must not be defrosted in a microwave or by artificially warming the solution.

Once thawed, the eye drops should not be refrozen.

After thawing, the eye drops are stable for a further 14 days in the refrigerator.

Cefuroxime is a second generation cephalosporin.

Not commercially available.

**CHLORAMPHENICOL 0.5% EYE DROPS (CHLOROMYCETIN, MINIMS)  
1% EYE OINTMENT (CHLOROMYCETIN)**

**Preservative:** Phenylmercuric acetate/nitrate, thiomersal or chlorhexidine in drops.

Also available preservative-free.

**Dose:** Depends on severity of condition.

Severe infections: 1 drop 0.5 to 2 hourly.

Pre and Post-operatively: 1 drop 4 times a day.

Minor infections: Drops or ointment 4 times a day.

**Indications:** Broad spectrum antibiotic.

**Adverse reactions:** Extremely rare, aplastic anaemia.

**Other information:** Store drops in a refrigerator. *Pseudomonas* resistant.

All drops contains borax and boric acid.

**CIPROFLOXACIN 0.2% EYE DROPS**

**Preservative:** None.

**Dose:** Depends on severity of condition.

Severe infections: 1 drop 0.5 to 2 hourly.

Minor infections: 1 drop 4 times a day.

**Uses:** Broad spectrum antibiotic, usually effective against *Pseudomonas aeruginosa*.

**Adverse reactions:** –

**Other information:** White precipitates have appeared on ulcer margin during intensive administration. Do not refrigerate as ciprofloxacin precipitates out of solution. Discard 24 hours after opening.

A preserved preparation of ciprofloxacin 0.3% is commercially available.

Ciprofloxacin 0.2% unpreserved is not commercially available.

**CIPROFLOXACIN EYE OINTMENT (CILOXAN)**

**Preservative:** None.

**Dose:** Corneal ulcers: Apply every 1–2 hours for 2 days, then every 4 hours for further 12 days.

Conjunctivitis and blepharitis: Apply 3 times a day for 2 days then twice daily for a further 5 days.

**Indications:** Corneal ulcers, conjunctivitis and blepharitis.

**Adverse effects:** –

**Other information:** Contains liquid paraffin and white soft paraffin.

**CLARITHROMYCIN 2% EYE DROPS**

**Preservative:** None.

**Dose:** Depends on severity of condition.

Severe infections: 1 drop 0.5 to 2 hourly.

Minor infections: 1 drop 4 times a day.

**Uses:** Infections due to *Mycobacteria*.

**Adverse reactions:** Toxic keratoconjunctivitis.

**Other information:** Store in a refrigerator.

Not commercially available.

#### **ERYTHROMYCIN 0.5% EYE OINTMENT**

**Preservative:** None.

**Dose:** Apply 1 to 3 times a day.

**Uses:** Superficial ocular infections. Broad spectrum antibiotic, usually effective against *Streptococcus* and *Chlamydia*.

**Adverse reactions:** –

**Other information:** Contains cholesterol, liquid paraffin and white soft paraffin.

Not commercially available.

#### **FRAMYCETIN 0.5% EYE DROPS (SOFRAMYCIN)**

**Preservative:** 0.012% benzalkonium chloride.

**Dose:** Depends on severity of condition.

Severe infections: 1 drop 1 to 2 hourly.

Minor infections: 1 drop 3 to 4 times a day.

**Indications:** Broad spectrum antibiotic, particularly effective against Gram negative bacteria.

**Adverse reactions:** –

**Other information:** Store drops in a refrigerator.

Contains citric acid, sodium citrate, sodium chloride, sodium hydroxide or hydrochloric acid.

#### **FRAMYCETIN 0.5% FOR DONOR EYES**

**Preservative:** None.

**Procedure:** Donor eyes: Pour into a gallipot and soak donor eye for between 3 and 5 minutes.

Sclera: Soak for about 5 minutes.

**Uses:** Preparation of donor eyes and sclera prior to use.

**Adverse reactions:** –

**Other information:** Contains sodium chloride, sodium citrate and citric acid monohydrate.

Not commercially available.

#### **FUSIDIC ACID 1% VISCOUS EYE DROPS (FUCITHALMIC)**

**Preservative:** 0.01% w/w benzalkonium chloride.

**Dose:** 1 drop twice a day.

**Indications:** Infections due to *Staphylococcus*.

**Adverse reactions:** –

**Other information:** Contains disodium edetate, mannitol, carbomer and sodium hydroxide.

#### **GENTAMICIN 0.3% (GENTICIN, MINIMS)**

##### **1.5% FORTE EYE DROPS**

**Preservative:** 0.3% drops: 0.02% benzalkonium chloride - Genticin

Also available preservative free

1.5% Forte drops: 0.005% Thiomersal

Also available preservative free

**Dose:** Depends on severity of condition.

Severe infections: 1 drop 0.5 to 2 hourly.

Minor infections: 1 drop 4 times a day.

**Indications:** Broad spectrum antibiotic which is effective against Gram negative infections, including *Pseudomonas aeruginosa*.

**Adverse reactions:** Epithelial toxicity. Non-healing erosions.

**Other information:** 1.5% drops not commercially available.

*Streptococcus* usually resistant.

Genticin contains borax and sodium chloride.

Minims Gentamicin contains sodium chloride, borax and sodium hydroxide.

Moorfields Eye Hospital NHS Foundation Trust formulation contains borax and boric acid.

#### **'NEOSPORIN' - POLYMYXIN 5,000 units/ml WITH NEOMYCIN 1,700 units/ml AND GRAMICIDIN 25 units/ml EYE DROPS**

**Preservative:** 0.005% benzalkonium chloride.

**Dose:** Depends on severity of condition.

Severe infections: 1 drop every 15 to 30 minutes and decrease as condition improves.

Moderate infections: 1 drop 2 to 4 times a day.

**Indications:** Broad spectrum antibiotic.

**Adverse reactions:** Epithelial toxicity.

**Other information:** Contains ethanol, propylene glycol, poloxamer 188, sodium chloride, sulphuric acid and sodium hydroxide.

#### **OFLOXACIN 0.3% EYE DROPS (EXOCIN)**

**Preservative:** 0.005% benzalkonium chloride.

**Dose:** Depends on severity of condition.

1 drop every 2 to 4 hours for the first 2 days and then reduce to 4 times a day

**Indications:** Broad spectrum antibiotic which is effective against Gram negative infections including *Pseudomonas aeruginosa*.

**Adverse reactions:** –

**Other information:** Not particularly effective against *Streptococcus*. Contains sodium chloride.

#### **PENICILLIN G 5,000 units/ml (0.3%) EYE DROPS - BENZYL PENICILLIN**

**Preservative:** None.

**Dose:** Depends on severity of condition.

Severe infections: 1 drop 0.5 to 2 hourly.

**Uses:** Infections due to *Streptococcus*. Treatment of ophthalmia neonatorum.

**Adverse reactions:** –

**Other information:** Store in a refrigerator.

Contains sodium citrate and citric acid monohydrate.

Not commercially available.

**'POLYFAX' - POLYMYXIN 10,000 units/g WITH BACITRACIN 500 units/g EYE OINTMENT**

**Preservative:** None.

**Dose:** Apply twice a day. The dose may be increased in more severe conditions.

**Indications:** Broad spectrum, particularly effective against Gram negatives and *coliforms*.

**Adverse reactions:** –

**Other information:** Contains white petrolatum.

**POVIDONE IODINE 5% EYE DROPS**

**Preservative:** None.

**Dose:** 1 drop when required.

**Uses:** Antiseptic and disinfectant used prior to surgical procedures.

**Adverse reactions:** –

**Other information:** Do not use in iodine hypersensitivity.

**POVIDONE IODINE 5% SOLUTION**

**Preservative:** None.

**Procedure:** Globes are fully immersed in povidone iodine 5% for 2 minutes, then rinsed with normal saline.

**Uses:** Preparation of corneas for transplantation.

**Adverse reactions:** –

**Other information:** Do not use in iodine hypersensitivity.

**VANCOMYCIN 5% EYE DROPS**

**Preservative:** None.

**Dose:** Depends on severity of condition.

Severe infections: 1 drop 1 to 2 hourly.

Moderate infections: 1 drop 4 times a day.

**Uses:** Infections due to *Staphylococcus*, *Clostridium*, *Nocardia*.

**Adverse reactions:** Not established due to limited use.

**Other information:** Store in a refrigerator.

Incompatible with topical steroids forming a white precipitate. Do not use drops within 15 minutes of a topical steroid.

Not commercially available.

**ANTIFUNGALS**

All suspected fungal infections, either keratitis or endophthalmitis, should be investigated microbiologically by examination of smears (using appropriate stains) and cultures of appropriate biopsies.

In endophthalmitis, the imidazoles have been less frequently used and **amphotericin** remains the drug of first choice for intravitreal injection.

For intravitreal doses see Appendix 1

None of the topical products are commercially available in the UK.



## Cost

### Product Cost for one month

Amphotericin 0.15% sp £££££

Clotrimazole 1% sp ££££

Econazole 1% sp £££

Miconazole 1% sp ££££

Natamycin 5% sp £££££

*All products are multidose eye drops unless otherwise stated.*

*Prices for multidose, preserved drops are calculated as 1 bottle per month, multidose preservative-free (sp) as*

*4 bottles per month.*

*£=>£5 ££=£5-10 £££=£10-20 ££££=£20-50 £££££=>£50*

## ANTIFUNGALS

### AMPHOTERICIN 0.15% EYE DROPS

**Preservative:** None.

**Dose:** Depends on severity of infection.

Topically 0.5 to 1 hourly and reduce as condition improves.

Continue treating until healing is complete (may be months).

**Uses:** Normally active against *Candida*.

**Adverse reactions:** Epithelial toxicity as concentration increases.

**Other information:** A 0.15% solution is stable for 1 week, when refrigerated.

Not commercially available.

### CLOTRIMAZOLE 1% IN ARACHIS OIL EYE DROPS

**Preservative:** None.

**Dose:** Depends on severity of infection.

Topically 0.5 to 1 hourly and reduce as condition improves.

Continue treating until healing complete (may be months).

**Uses:** Normally active against *Aspergillus*, *Candida* and *Acanthamoeba*.

**Adverse reactions:** –

**Other information:** Store in a refrigerator.

Broad spectrum antifungal with good ocular penetration. A good first-line treatment until organism is identified.

Not commercially available.

### ECONAZOLE 1% IN ARACHIS OIL EYE DROPS

**Preservative:** None.

**Dose:** Depends on severity of infection.

Topically 0.5 to 1 hourly and reduce as condition improves.

Continue treating until healing complete (may be months).

**Uses:** Normally active against filamentous fungi especially *Fusarium*, *Aspergillus* and *Penicillium*.

**Adverse reactions:** –

**Other information:** Store in a refrigerator.

Not commercially available.

### **MICONAZOLE 1% IN ARACHIS OIL EYE DROPS**

**Preservative:** None.

**Dose:** Depends on severity of infection.

Topically 0.5 to 1 hourly and reduce as condition improves.

Continue treating until healing complete (may be months).

**Uses:** Normally active against *Candida* and some Gram positive bacteria.

**Adverse reactions:** –

**Other information:** Store in a refrigerator.

Not commercially available.

### **NATAMYCIN 5% EYE DROPS AQUEOUS SUSPENSION**

**Preservative:** 0.01% benzalkonium chloride.

**Dose:** Depends on severity of infection.

Topically 0.5 to 1 hourly and reduce as condition improves.

Continue treating until healing complete (may be months).

**Uses:** Broad spectrum antifungal, normally active against *Aspergillus*, *Candida* and *Fusarium* for superficial infections.

**Adverse reactions:** –

**Other information:** Store in a refrigerator. Shake well before using. Poor penetration limits its use to superficial fungal infections. The natamycin tends to collect and adhere to the sides of the ulcer margin.

Contains sodium hydroxide and hydrochloric acid.

Not commercially available.

### **ANTIVIRALS**

**Cost**

**Product Cost for one month**

**Aciclovir (Zovirax; GlaxoSmithKline) 3% eye ointment** £££

**Ganciclovir (Virgan; Chauvin Pharmaceuticals) 0.15%** £££

**Trifluorothymidine 1% (F3T)** £££££

**Trifluorothymidine (F3T) 1% sp** ££££

*All products are multidose eye drops unless otherwise stated.*

*Prices for multidose, preserved drops are calculated as 1 bottle per month, multidose preservative-free (sp) as*

*4 bottles per month.*

*£=>£5 ££=£5-10 £££=£10-20 ££££=£20-50 £££££=>£50*

### **ANTIVIRALS**

#### **ACICLOVIR 3% EYE OINTMENT (ZOVIRAX)**

**Preservative:** None

**Dose:** Apply 5 times a day (at 4 hour intervals).

**Indications:** *Herpes simplex* keratitis.

**Other uses:** *Varicella zoster* keratitis.

**Adverse reactions:** –

**Other information:** Treatment should continue for at least 3 days after re-epithelialisation. Contains white petrolatum.

**GANCICLOVIR 0.15% EYE GEL (VIRGAN).**

**Preservative:** 0.0075% benzalkonium chloride.

**Dose:** 1 drop 5 times a day until complete re-epithelialisation, then 3 times a day for 7 days. Maximum treatment period is 21 days.

**Indications:** *Herpes simplex* keratitis.

**Adverse reactions:** Superficial punctate keratitis.

Contains carbomer 974P, mannitol, and sodium hydroxide.

**TRIFLUOROTHYIMIDINE 1% EYE DROPS – TRIFLURIDINE - F3T**

**Preservative:** 0.01% benzalkonium chloride.

Also available preservative free.

**Dose:** 1 drop 5 times a day (at 4 hour intervals).

This may be increased to 1 drop every 2 hours.

Maximum daily dose is 9 drops.

**Uses:** *Herpes simplex* keratitis. Stromal *Herpes simplex* keratitis.

**Adverse reactions:** Toxic epithelial and stromal keratitis.

**Other information:** Store in a refrigerator.

Contains sodium chloride.

Not commercially available.

**ANTI AMOEBICS**

Amoebic infections in the eye are rare in the UK, but there has been a significant increase in infections due to *Acanthamoeba* in contact lens users.

*Acanthamoeba* is resistant to most antimicrobials. The following drugs have been used in the management of patients infected with this organism.

**Cost**

**Product Cost for one month**

**Chlorhexidine digluconate 0.02% sp** £££

**Hexamidine (Desomedine) 0.1%** £££

**Polihexanide - Polyhexamethylene biguanide (PHMB) 0.02% sp** £££££

**Polihexanide - Polyhexamethylene biguanide (PHMB) 0.06% sp** £££££

**Propamidine isetionate (Brolene; Aventis Pharma, Golden eye; Typharm Ltd) 0.1%** £

**Propamidine isetionate (Brolene, Golden eye) 0.1% eye ointment** £

*All products are multidose eye drops unless otherwise stated.*

*Prices for multidose, preserved drops are calculated as 1 bottle per month, multidose preservative-free (sp) as*

*4 bottles per month and single use units for use 4 daily for one month.*

*\*Single use*

*£=>£5 ££=£5-10 £££=£10-20 ££££=£20-50 £££££ =>£50*

**CHLORHEXIDINE DIGLUCONATE 0.02% EYE DROPS**

**Preservative:** None.

**Dose:** Depends on severity of condition.

1 drop every hour day and night for 2 days, then every hour day only for 3 days. Intensive treatment is used at an early stage, while organisms are susceptible and before cysts have fully matured. Reduced to 3 hourly, then tailor thereafter according to the course of the disease.

*Uses:* *Acanthamoeba* keratitis.

*Adverse reactions:* –

*Other information:* Used in combination with propamidine 0.1% or hexamidine 0.1% eye drops.

Treatment must be prolonged in order to eradicate cysts.

Not commercially available.

### **HEXAMIDINE 0.1% EYE DROPS (DESOMEDINE)**

*Preservative:* None

*Dose:* Depends on severity of condition.

1 drop every hour day and night for 2 days, then every hour day only for 3 days. Intensive treatment is used at an early stage, while organisms are susceptible and before cysts have fully matured. Reduced to 3 hourly, then tailor thereafter according to the course of the disease. If toxicity is suspected then stop for 3 days or reduced to 4 times a day for a week.

*Uses:* *Acanthamoeba* keratitis.

*Adverse reactions:* –

*Other information:* Used in combination with PHMB 0.02% or chlorhexidine 0.02% eye drops.

Treatment must be prolonged in order to eradicate cysts.

Contains sodium chloride, borax and boric acid.

Not commercially available.

### **POLIHEXANIDE 0.02%,0.06% EYE DROPS – POLYHEXAMETHYLENE BIGUANIDE – PHMB**

*Preservative:* None.

*Dose:* Depends on severity of condition.

1 drop every hour day and night for 2 days, then every hour day only for 3 days. Intensive treatment is used at an early stage, while organisms are susceptible and before cysts have fully matured. Reduced to 3 hourly, then tailor thereafter according to the course of the disease.

*Uses:* *Acanthamoeba* keratitis.

*Adverse reactions:* –

*Other information:* Store in a refrigerator.

Used in combination with propamidine 0.1% or hexamidine 0.1% eye drops.

Treatment must be prolonged in order to eradicate cysts.

Also known as polyhexanide biguanide.

Not commercially available.

### **PROPAMIDINE 0.1% EYE DROPS (BROLENE, GOLDEN EYE) DIBROMOPROPAMIDINE 0.15% EYE OINTMENT (BROLENE, GOLDEN EYE)**

**Preservative:** 0.01% benzalkonium chloride in drops.  
0.5% phenylethanol in ointment.

**Dose:** Depends on severity of condition.

1 drop every hour day and night for 2 days, then every hour day only for 3 days. Intensive treatment is used at an early stage, while organisms are susceptible and before cysts have fully matured. Reduced to 3 hourly, then tailor thereafter according to the course of the disease. If toxicity is suspected then stop for 3 days or reduce to 4 times a day for a week.

**Uses:** *Acanthamoeba* keratitis.

**Adverse reactions:** Epithelial toxicity with frequent usage, leading to indolent corneal ulceration.

**Other information:** Used in combination with PHMB 0.02% or chlorhexidine 0.02% eye drops.

Treatment must be prolonged in order to eradicate cysts.

Eye drops contain ammonium chloride, sodium chloride and sodium hydroxide.

Eye ointment contains yellow soft paraffin, liquid paraffin and lanolin.

**References:**

1. Bruce AS and Loughnan MS. *Anterior Eye Disease and Therapeutics A–Z*. London: Butterworth Heinemann; 2003.
2. Dart J. *Acanthamoeba Keratitis, Moorfields Eye Hospital NHS Foundation Trust Guidelines* 1996.
3. Ofloxacin Study Group. Ofloxacin monotherapy for the primary treatment of microbial keratitis. *Ophthalmology* 1997;104:1902–1909.
4. Daniell M. Overview: Initial antimicrobial therapy for microbial keratitis. *Br J Ophthalmol* 2003;87:1172–1174.
5. Tuft SJ. Management of Infectious keratitis, Moorfields Eye Hospital NHS Foundation Trust Guidelines, 1997.
6. Tuft SJ and Matheson M. In vitro antibiotic resistance in bacterial keratitis in London. *Br J Ophthalmol* 2000;84:687–691.
7. Seal DV, Bron AJ and Thomas P. *Ocular Infection Investigation and Treatment in Practice*. London: Martin Dunitz; 1998.
8. Kanski JJ. *Clinical Ophthalmology – A synopsis*. London: Butterworth Heinemann; 2004.
9. Moorfields Eye Hospital NHS Foundation Trust Formulary, 1992.
10. British National Formulary 50, September 2005. BMJ Publishing Group Ltd and Royal Pharmaceutical Society of Great Britain 2005.
11. Primary Care and Accident And Emergency Services – Guidelines for referral and management protocols. *Moorfields Eye Hospital NHS Foundation Trust City Road And Outreach Clinics*.