

Automated Extracellular Volume Fraction Mapping Provides Insights Into the Pathophysiology of Left Ventricular Remodeling Post-Reperused ST-Elevation Myocardial Infarction

Heerajnarain Bulluck, MBBS; Stefania Rosmini, PhD; Amna Abdel-Gadir, MBBS; Steven K. White, MBChB; Anish N. Bhuva, MBBS; Thomas A. Treibel, MBBS; Marianna Fontana, PhD; Esther Gonzalez-Lopez, PhD; Patricia Reant, PhD; Manish Ramlall, MBChB; Ashraf Hamarneh, MBBS; Alex Sirker, PhD; Anna S. Herrey, PhD; Charlotte Manisty, PhD; Derek M. Yellon, PhD; Peter Kellman, PhD; James C. Moon, MD; Derek J. Hausenloy, PhD

Background—Whether the remote myocardium of reperused ST-segment elevation myocardial infarction (STEMI) patients plays a part in adverse left ventricular (LV) remodeling remains unclear. We aimed to use automated extracellular volume fraction (ECV) mapping to investigate whether changes in the ECV of the remote (ECV_{Remote}) and infarcted myocardium (ECV_{Infarct}) impacted LV remodeling.

Methods and Results—Forty-eight of 50 prospectively recruited reperused STEMI patients completed a cardiovascular magnetic resonance at 4±2 days and 40 had a follow-up scan at 5±2 months. Twenty healthy volunteers served as controls. Mean segmental values for native T1, T2, and ECV were obtained. Adverse LV remodeling was defined as ≥20% increase in LV end-diastolic volume. ECV_{Remote} was higher on the acute scan when compared to control (27.9±2.1% vs 26.4±2.1%; *P*=0.01). Eight patients developed adverse LV remodeling and had higher ECV_{Remote} acutely (29.5±1.4% vs 27.4±2.0%; *P*=0.01) and remained higher at follow-up (28.6±1.5% vs 26.6±2.1%; *P*=0.02) compared to those without. Patients with a higher ECV_{Remote} and a lower myocardial salvage index (MSI) acutely were significantly associated with adverse LV remodeling, independent of T1_{Remote}, T1_{Core} and microvascular obstruction, whereas a higher ECV_{Infarct} was significantly associated with worse wall motion recovery.

Conclusions—ECV_{Remote} was increased acutely in reperused STEMI patients. Those with adverse LV remodeling had higher ECV_{Remote} acutely, and this remained higher at follow-up than those without adverse LV remodeling. A higher ECV_{Remote} and a lower MSI acutely were significantly associated with adverse LV remodeling whereas segments with higher ECV_{Infarct} were less likely to recover wall motion. (*J Am Heart Assoc.* 2016;5:e003555 doi: 10.1161/JAHA.116.003555)

Key Words: extracellular volume fraction • left ventricular remodeling • ST-segment elevation myocardial infarction • T1 mapping • T2 mapping

Although mortality after an acute ST-elevation myocardial infarction (STEMI) is in decline, the onset of post-myocardial infarct (MI) heart failure is still significant.^{1–3} MI size,^{4,5} presence of microvascular obstruction (MVO),^{6,7} and myocardial salvage^{8,9} assessed by cardiovascular magnetic resonance (CMR) performed in the first few days after

reperfusion in STEMI patients have all been shown to be strong predictors of adverse left ventricular (LV) remodeling and development of heart failure.

Whether changes in the extracellular matrix (ECM) in the noninfarcted remote myocardium in STEMI patients reperused by primary percutaneous coronary intervention (PPCI) is

From the Hatter Cardiovascular Institute, Institute of Cardiovascular Science, University College London, London, United Kingdom (H.B., S.K.W., M.R., A.H., D.M.Y., D.J.H.); The National Institute of Health Research University College London Hospitals Biomedical Research Center, London, United Kingdom (H.B., S.K.W., M.R., A.H., A.S., D.M.Y., J.C.M., D.J.H.); Barts Heart Center, St Bartholomew's Hospital, London, United Kingdom (H.B., S.R., A.A.-G., S.K.W., A.N.B., T.A.T., M.F., M.R., A.H., A.S., A.S.H., C.M., J.C.M., D.J.H.); Hospital Universitario Puerta de Hierro Majadahonda, Madrid, Spain (E.G.-L.); CHU de Bordeaux, University of Bordeaux, France (P.R.); National Heart, Lung and Blood Institute, National Institutes of Health, Bethesda, MD (P.K.); Cardiovascular and Metabolic Disorders Program, Duke–National University of Singapore, Singapore (D.J.H.); National Heart Research Institute Singapore, National Heart Center Singapore, Singapore (D.J.H.).

Correspondence to: Derek J. Hausenloy, PhD, Cardiovascular & Metabolic Diseases Program, Duke–NUS Graduate Medical School Singapore, 8 College Rd, Singapore 169857. E-mail derek.hausenloy@duke-nus.edu.sg

Received April 20, 2016; accepted May 28, 2016.

© 2016 The Authors. Published on behalf of the American Heart Association, Inc., by Wiley Blackwell. This is an open access article under the terms of the Creative Commons Attribution-NonCommercial-NoDerivs License, which permits use and distribution in any medium, provided the original work is properly cited, the use is non-commercial and no modifications or adaptations are made.

linked to adverse LV remodeling remains incompletely understood.^{10–14} Although native T1 mapping¹⁴ and postcontrast T1 mapping¹³ CMR have been used to interrogate remote myocardial ECM, the availability of automated extracellular volume fraction (ECV) mapping CMR provides a more robust method for quantifying not only focal fibrosis, but also diffuse interstitial expansion in the myocardium^{15,16} given that native and postcontrast T1 maps are coregistered and motion corrected, thereby improving the quality of the generated automated maps.¹⁷

Using the latest coregistered and motion-corrected T1 mapping technology to create accurate automated ECV maps, we set out to investigate, first, whether changes in ECV in the remote myocardium occurred in the current era and whether they were associated with adverse LV remodeling and, second, whether ECV of the infarct zone was a better predictor of wall motion recovery than transmural extent of the infarct after reperfused STEMI.

Methods

Study Population

This was a prospective, single-center study of acute STEMI patients reperfused by PPCI. Fifty patients were recruited over a 12-month period, and 20 age- and sex-matched healthy volunteers served as control (all free of cardiovascular disease). All participants were scanned at the same center and on the same scanner. Diagnosis and treatment of STEMI were as per current guidelines.^{18,19} Study exclusion criteria were previous MI and standard recognized contraindications to CMR (eg, ferromagnetic implants, claustrophobia, and estimated glomerular filtration rate <30 mL/min). All patients provided informed written consent. The UK National Research Ethics Service approved this study.

Imaging Acquisition

All CMR scans were performed on a 1.5 Tesla scanner (MAGNETOM Avanto; Siemens Medical Solutions, Malvern, PA) using a 32-channel phased-array cardiac coil.

Imaging protocol

In the STEMI cohort, all patients had T2 maps acquired from base to apex during the acute scan. As for native T1 and postcontrast T1 maps, 30 patients had whole LV short-axis coverage and the remaining 10 had 3 (basal, mid, and apical) LV short-axis T1 maps acquired during both scans. The 20 healthy volunteers had 1 midventricular short-axis native T1, T2, and postcontrast T1 maps acquired. All participants had whole heart coverage LV short-axis cines and late gadolinium enhancement (LGE) acquired.

Native T1 mapping

T1 maps (Work In Progress 448B; Siemens Healthcare, Erlangen, Germany) were acquired using a steady state free precession (SSFP)-based modified look-locker inversion recovery (MOLLI) sequence. A 5s(3s)3s modified MOLLI sampling protocol was used to ensure more-complete recovery of the inversion pulse at higher heart rates by acquiring a set of images for at least 5 seconds after the first inversion pulse, followed by a 3-second pause and then acquiring a set of images after the second inversion pulse for at least 3 seconds.²⁰ The acquisition parameters were: pixel bandwidth, 977 Hz/pixel; echo time=1.1 ms; flip angle=35 degrees; matrix=256×144; and slice thickness=6 mm. Motion correction and a nonlinear least-square curve fitting were performed with the set of images acquired at different inversion times to generate a pixel-wise colored T1 map by the scanner.

T2 mapping

T2 maps (Work In Progress 448B; Siemens Healthcare, Erlangen, Germany) were acquired as previously described.²¹ In brief, 3 single-shot images at different T2 preparation times (0, 24, and 55 ms, respectively) using the following parameters were acquired: pixel bandwidth, 930 Hz/pixel; echo time=1.1 ms; repetition time=3× R-R interval; flip angle=70 degrees; acquisition matrix=116×192; and slice thickness=6 mm. A colored T2 map consisting of pixel-wise T2 values was generated after fitting to estimate T2 relaxation times and motion correction by the scanner.

Late gadolinium enhancement

LGE imaging was acquired with a standard segmented “fast low-angle shot” 2-dimensional inversion-recovery gradient echo sequence or a respiratory motion-corrected, free-breathing, single-shot, SSFP-averaged, phase-sensitive inversion recovery sequence^{22,23} at 10 to 15 minutes after the injection of 0.1 mmol/kg of gadoterate meglumine (Gd-DOTA marketed as Dotarem; Guerbet S.A., Paris, France).

Postcontrast T1 mapping

Postcontrast T1 maps (Work In Progress 448B; Siemens Healthcare, Erlangen, Germany) were obtained using the 4s (1s)3s(1s)2s sampling protocol (to improve the accuracy of T1s in the 200- to 600-ms range as previously described²⁰) 15 minutes after contrast injection (0.1 mmol/kg of Dotarem) using similar acquisition parameters as for native T1 maps.

ECV maps

The previously described and validated automated method for producing a pixel-wise ECV map was used.¹⁷ In brief, this method corrects for respiratory motion attributed to poor

breath holding as well as patient movement between breath holds and relies on coregistration of the native and postcontrast T1 pixel maps. Each patient had hematocrit checked at the time of the scan and the ECV was estimated using the following formula²⁴:

$$\text{ECV} = (1 - \text{hematocrit}) \times \frac{(1/T1_{\text{myocardium post}}) - (1/T1_{\text{myocardium pre}})}{(1/T1_{\text{blood post}}) - (1/T1_{\text{blood pre}})}$$

An offline software (ECV Mapping Tool, Version 1.1) subsequently generated pixel-wise ECV maps using a variety of postprocessing steps as recently described.¹⁷

Imaging Analysis

All imaging analysis was performed using CVI42 software (version 5.1.2[303]; Circle Cardiovascular Imaging, Calgary, Alberta, Canada).

Wall motion analysis

Segmental wall motion on the short-axis cine images were visually scored by 2 experienced investigators (H.B., S.R.) as “0” for normal; “1” for mild/moderate hypokinesis; “2” for severe hypokinesis; “3” for akinesis; and “4” dyskinesis²⁵ and displayed as per the 16-segment American Heart Association (AHA) classification.²⁶ Wall motion recovery was defined as an improvement in wall motion score by 1. Segmental wall end-diastolic and end-systolic wall thickness, wall thickening, and wall motion were derived from averaging the mean thicknesses from 100 chords for each short-axis slice, covering the whole LV, and also displayed as per the modified 16-segment AHA model.

MI and area-at-risk quantification

MI size was quantified using a threshold of 5 SDs²⁷ above the mean remote myocardium and expressed as a percentage of the LV. The area-at-risk (AAR) was assessed from the T2 maps using a threshold of 2 SDs above the mean remote myocardium and expressed a percentage of the whole LV.^{28,29} Areas of hypointense core of MVO were included as part of the MI zone, and AAR and MVO from the LGE images were quantified and expressed in grams. Transmural extent of LGE was expressed by averaging the values from 100 chords from each short-axis slice to obtain the mean transmural extent of LGE for each of the 16 AHA segments. Figure 1 shows an example of a mid-LV short-axis ECV map of an acute anterior STEMI with MVO and the corresponding follow-up ECV map.

Analysis of the T1, T2, and ECV maps

Endocardial and epicardial borders were manually delineated on the native T1 maps and T2 maps and copied on the ECV

maps. The left ventricular outflow track and apical LV short-axis slices were excluded, and a 10% erosion of the wall thickness was applied to the endocardial and epicardial borders to minimize partial volume effects. Mean segmental T1, T2, and ECV values were then generated and displayed as bull’s-eye plots using the 16 AHA segments (Figure 2). For assessing intermethod agreement, manual regions of interest (ROIs) were also drawn with care to avoid partial volume effects in the remote myocardium and infarcted segments of 10 patients for comparison with mean segmental values for ECV. The remote myocardium was defined as the AHA segment 180 degrees from the infarct territory with normal wall motion and no LGE. T1, T2, and ECV values in the remote myocardium were represented by T1_{Remote}, T2_{Remote}, and ECV_{Remote}. T1 values of the core (T1_{Core}) of the infarct was obtained by manually drawing the ROI within the hypo-enhanced regions inside areas of hyperenhancement within 2 SDs of the remote myocardium on the T1 maps and are represented as T1_{Core}. Mean segmental ECV of the infarcted segments is represented as ECV_{Infarct}. Adverse LV remodeling was defined as a ≥20% increase in end-diastolic volume (EDV) between the acute and follow-up scans.¹⁴

Statistical Analysis

Statistical analysis was performed using SPSS software (version 22; IBM Corp, Chicago, IL). Test for normality was performed using the Shapiro–Wilk Test. Continuous data are expressed as mean±SD or median (interquartile range) and compared with the paired Student *t* test/Wilcoxon signed-rank test or unpaired Student *t* test/Mann–Whitney *U* test, where appropriate. Categorical data are reported as frequencies and percentages. Interobserver and intraobserver variability for ECV_{Remote} and ECV_{Infarct} was assessed in 10 patients and expressed as intraclass correlation coefficient (ICC) and 95% CI and bias ±2 SDs (for limits of agreement) using Bland–Altman analysis. Receiver operating characteristic (ROC) analyses were performed to assess the diagnostic performance for LGE, T1, T2, and ECV on the acute scan for predicting segmental wall motion recovery for the AHA segments with LGE, and this was repeated for segments with LGE, but without MVO. Univariable and multivariable linear regression analyses were also performed to identify associates of adverse remodeling. To take into consideration potential within-subject interaction of some segments with the independent variables, R software (version 3.2.3; R Foundation for Statistical Computing, Vienna, Austria; available at: <http://www.R-project.org/>) was used for clustered ROC analysis by the method described by Obuchowski³⁰ to assess the performance of T1, T2, ECV, and LGE to predict wall motion recovery, and a linear mixed-effects model was used to identify predictors of segmental wall motion recovery

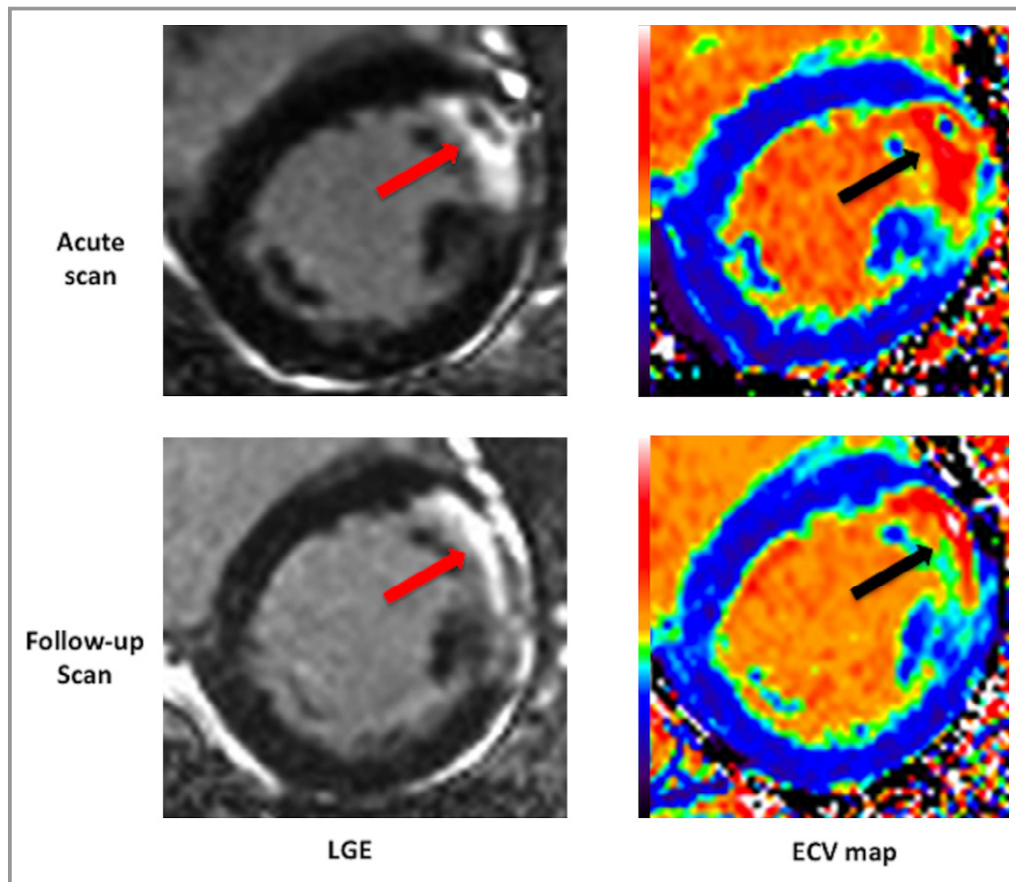


Figure 1. Example of LGE images and ECV maps of an acute and follow-up scan of a patient with an anterior STEMI. The arrows show the area of LGE with a core of MVO on the acute scan and the corresponding chronic LGE and ECV. ECV indicates extracellular volume fraction; LGE, late gadolinium enhancement; MVO, microvascular obstruction; STEMI, ST-segment elevation myocardial infarction.

after adjusting interaction among segments within the same patients. All statistical tests were 2-tailed, and $P < 0.05$ was considered statistically significant.

Results

Figure 3 illustrates the STEMI patients' screening and recruitment process. Of 50 STEMI patients recruited into the study, 48 completed the first CMR at 4 ± 2 days post-PPCI and 40 had a follow-up scan at 5 ± 2 months (2 patients did not complete the scan because of unexpected claustrophobia, 8 were lost to follow-up). There was no difference in the main acute CMR characteristics apart from a higher EDV between the 40 patients who had paired acute and follow-up scans and those who only had the acute scan, as shown in Table 1. Mean age of STEMI patients was 59 ± 13 years, and 88% were male. Further details regarding patient characteristics are listed in Table 2. Mean age of healthy volunteers was 60 ± 10 years, and 90% were male. A total of 10% of the T1, T2, and ECV maps had to be excluded from the analysis

because of artifacts, partial volume effects, and/or being nondiagnostic, as previously described.¹⁷

As expected, LV EDV and end-systolic volume (ESV) were significantly higher for STEMI patients (on both the acute and follow-up scans) when compared to the controls (Table 3), although there was no significant difference in LV mass. Mean MI size in STEMI patients was $27.4 \pm 14.6\%$ of the LV, and mean AAR was $42.0 \pm 12.0\%$ of the LV, giving a mean myocardial salvage index (MSI) of 0.37 ± 0.27 of the LV. As expected, there was a significant regression in MI size between the acute scan and the follow-up scan ($27.4 \pm 14.6\%$ to $19.5 \pm 10.5\%$; $P < 0.001$). Twenty-six of 40 (65%) of the included patients had MVO.

Intraobserver and Interobserver Variability for ECV Measurements

There was less intraobserver and interobserver variability when ECV_{Remote} and $ECV_{Infarct}$ were assessed by mean segmental analysis when compared to manual ROI (Table 4).

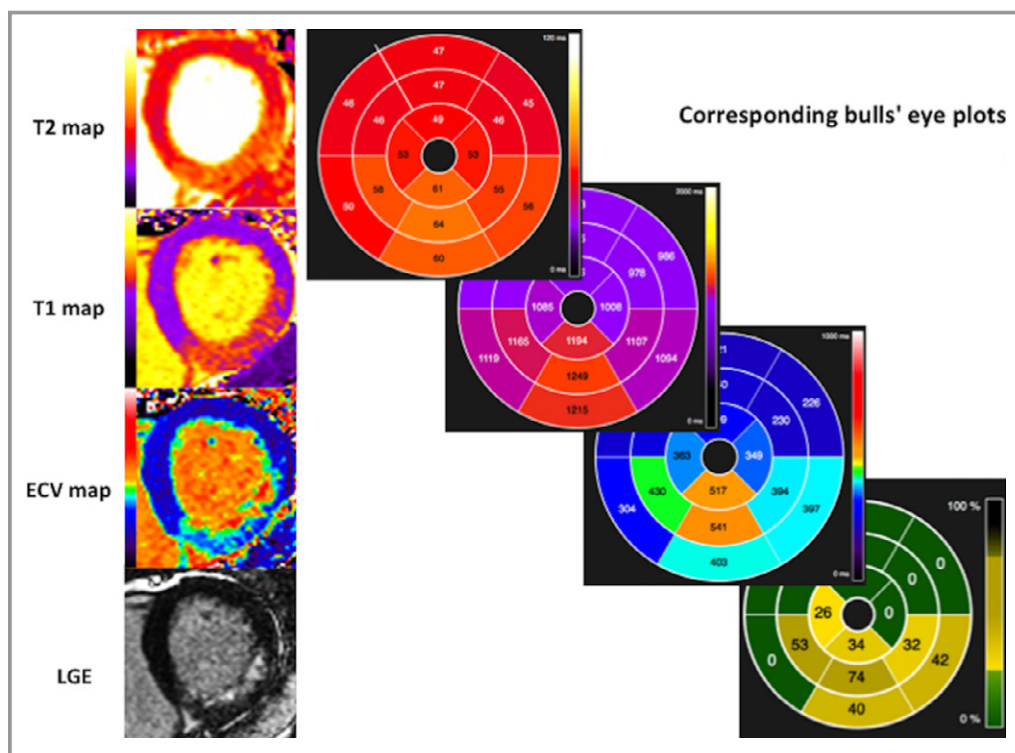


Figure 2. Example of generated bull's eye plots with AHA segments from the maps and LGE images. AHA indicates American Heart Association; ECV, extracellular volume fraction; LGE, late gadolinium enhancement.

For intraobserver measurements, the limits of agreement for ECV_{Remote} were $\pm 1.22\%$ when using mean segmental values compared to $\pm 1.59\%$ when using manual ROI. For interobserver measurements, the limits of agreement for ECV_{Remote} were $\pm 0.99\%$ when using mean segmental values compared to $\pm 1.40\%$ when using manual ROI. The limits of agreement for the two techniques were even wider for $ECV_{Infarct}$ (Table 4).

Changes in the Remote Myocardium

For both the acute and follow-up scans, there were no differences in LV diastolic and systolic wall thickness and LV wall thickening in the remote myocardium between STEMI patients and controls (Table 3). However, on the acute scan, LV wall motion in the remote myocardium was higher in STEMI patients when compared to controls (9.2 ± 2.6 vs 7.7 ± 2.5 mm; $P=0.04$), but there was no statistically significant difference between them on the follow-up scan (8.9 ± 2.6 vs 7.7 ± 2.5 mm; $P=0.10$; Table 4).

There were no significant differences in the $T2_{Remote}$ values between STEMI patients and controls on either the acute scan or the follow-up scans. Native $T1_{Remote}$ and ECV_{Remote} were both significantly higher in STEMI patients when compared to controls on the acute scan ($T1$: 1032 ± 51 vs 1000 ± 25 ms;

$P=0.001$; ECV : $27.9 \pm 2.1\%$ vs $26.4 \pm 2.1\%$; $P=0.01$), but this difference was not present on the follow-up scan ($T1$: 1004 ± 39 vs 1000 ± 25 ms; $P=0.66$; ECV : $27.0 \pm 2.1\%$ vs $26.4 \pm 2.1\%$; $P=0.30$; Table 3).

LV Remodeling

Of 40 STEMI patients who had a follow-up scan, 8 (20%) patients had adverse LV remodeling. In these 8 patients, the ECV_{Remote} was higher acutely when compared to those 32 without adverse LV remodeling ($29.5 \pm 1.4\%$ vs $27.4 \pm 2.0\%$; $P=0.01$), and this difference in ECV_{Remote} persisted on the follow-up scan ($28.6 \pm 1.5\%$ vs $26.6 \pm 2.1\%$; $P=0.02$). There were no significant differences in $T2_{Remote}$ between those with and without adverse LV remodeling both on the acute and follow-up scans (Figure 4).

Multiparametric CMR Prediction of Remodeling

A percentage increase in LV EDV as a continuous variable was used as a surrogate for adverse LV remodeling for univariable and multivariable linear regression analysis. MI size quantified by LGE ($R^2=0.36$; coefficient, 0.64; 95% CI, 0.37–0.9; $P=0.0001$) was the single most significant predictor of adverse LV remodeling after adjusting for remote myocardial

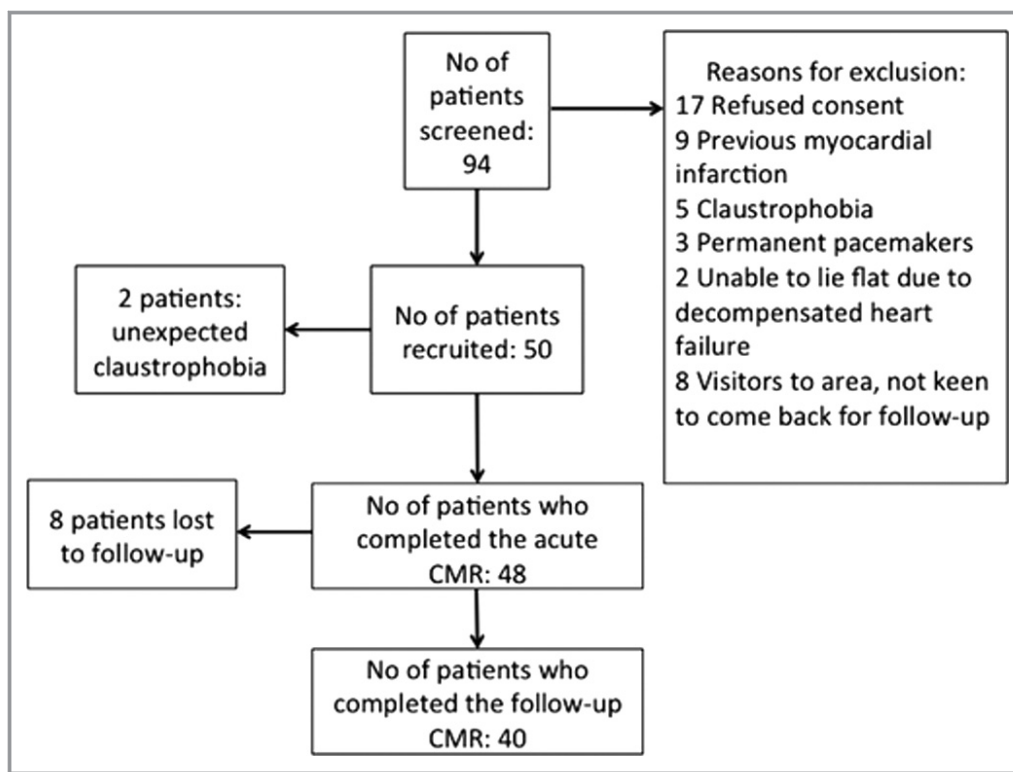


Figure 3. STEMI patients screening and recruitment flow chart. CMR indicates cardiovascular magnetic resonance imaging; STEMI, ST-segment elevation myocardial infarction.

T1, MVO, and LV EDV on the acute scan in a multivariable analysis. In order to account for both MI size and AAR, MSI was used in the regression model instead of MI size. $T1_{Remote}$ and ECV_{Remote} , $T1_{Core}$, MSI, and MVO on the acute scan were significantly associated with adverse LV remodeling on univariable analysis, and these were then included in a multivariable analysis. MSI and then ECV_{Remote} were most associated with adverse LV remodeling after adjusting for $T1_{Remote}$, $T1_{Core}$ and MVO on the acute scan (Table 5).

ECV and Segmental Recovery of LV Systolic Function

Two hundred sixty-three of 640 segments had LGE and abnormal wall motion. The mean $ECV_{Infarct}$ of all segments with LGE on the acute scan was $50.5 \pm 9.4\%$. MVO was present in 77 of these 263 segments, and it was negatively associated with segmental LV wall motion recovery after adjusting for transmural extent of LGE and for the interaction between segments with MVO and patients (77 segments; only 24% recovered; $P < 0.001$; $R^2 = 0.80$). Because gadolinium contrast failed to reach pseudoequilibrium in areas of MVO, analysis for segmental LV wall motion recovery was performed with and without segments containing MVO. $ECV_{Infarct}$ was performed as well as transmural extent of LGE on clustered ROC curve

analysis (area under the curve [AUC], 0.68; 95% CI, 0.59–0.77 vs 0.72; 95% CI, 0.64–0.80; $P = 0.23$ for comparison of both ROC curves), whereas mean segmental T1 and T2 were not good tests to predict improvement in segmental LV wall motion (T1: AUC, 0.45; 95% CI, 0.37–0.54; $P = 0.60$; T2: AUC, 0.54; 95% CI, 0.44–0.64; $P = 0.15$). After excluding segments with MVO (77 segments), this relationship was maintained between $ECV_{Infarct}$ and transmural extent of LGE (AUC, 0.63; 95% CI, 0.52–0.73 vs 0.63; 95% CI, 0.53–0.73; $P = 0.89$ for ROC curve comparison). A lower $ECV_{Infarct}$ was found to be a significant predictor of wall motion recovery after adjusting for transmural extent of LGE and interaction among segments within the same patients ($P = 0.039$; $R^2 = 0.48$).

Discussion

The major findings of this study were as follows: (1) We showed that ECV_{Remote} in STEMI patients is acutely elevated, and this elevation persisted in those STEMI patients that developed adverse remodeling at 5 months; (2) MSI and ECV_{Remote} in the remote myocardium were most associated with adverse LV remodeling after adjusting for $T1_{Remote}$, $T1_{Core}$, and MVO on the acute scan; and (3) $ECV_{Infarct}$ was found to be a significant predictor of LV wall motion recovery after adjusting for transmural extent of LGE.

Table 1. Acute CMR Characteristics Between Patients Who Completed Paired Acute and Follow-up Scans (n=40) and Patients Who Only Had the Acute Scan (n=8)

	Patients With Paired CMR (n=40)	Patients With Acute CMR Only (n=8)	P Value
Acute LV EDV, mL	172±38	135±28	0.01*
Acute indexed LV EDV, mL/m ²	87±13	73±13	0.01*
Acute LV ESV, mL	90±30	66±20	0.04*
Acute indexed LV ESV, mL/m ²	45±13	36±11	0.07
Acute LV EF, %	49±8	52±8	0.32
Acute LV mass, g	111 (92–124)	137 (86–154)	0.28
Acute MI size, % of LV	28 (14.8–38.0)	24.0 (23.0–25.8)	0.52
AAR, % of LV	42.0±12.0	46.4±10.9	0.34
MVO, %	26 (65%)	5 (63%)	0.60
Acute T _{2Remote} , ms	50 (48–52)	49 (48–54)	0.78
Acute T _{1Remote} , ms	1026 (990–1077)	1043 (963–1095)	0.80
Acute ECV _{Remote} , %	28.1 (26.2–29.7)	27.6 (26.2–31.2)	0.73

AAR indicates area-at-risk; CMR, cardiovascular magnetic resonance imaging; EDV, end diastolic volume; EF, ejection fraction; ESV, end systolic volume; LV, left ventricle; MVO, microvascular obstruction.

*Denotes statistical significance at P<0.05.

There was no statistical difference in T₂ values that were observed in the remote myocardium of STEMI patients when compared to controls, suggesting that the increased ECV was probably not attributed to myocardial edema, although there was a trend toward the T_{2Remote} values of STEMI patients being higher. There is a possibility that it may have been attributed to an expansion of the intravascular compartment from increased myocardial blood flow associated with the compensatory increase in LV wall motion observed in the remote myocardium.

Of note, this increase in ECV_{Remote} only persisted in those STEMI patients who went on to develop adverse LV remodeling. In a murine model of acute MI, Tsuda et al.¹¹ found molecular and immune-histochemical evidence of interstitial fibrosis in the remote myocardium as early as 72 hours post-MI. Volders et al.¹⁰ provided postmortem histological evidence of an increase in interstitial collagen in the remote myocardium of infarcted patients when compared to control. It may be possible that the increase in ECV_{Remote} in this subset of patients represent early interstitial fibrosis. However, Marijianowski et al.¹² showed that post-MI LV remodeling in patients with end-stage heart failure undergoing transplant was not associated with interstitial fibrosis in the remote myocardium.

Table 2. Clinical Characteristics of STEMI Patients (n=40)

Details	No.
No. of patients	40
Male (%)	35 (88)
Age, y	59±13
Diabetes mellitus (%)	8 (20)
Hypertension (%)	14 (35)
Smoking (%)	12 (30)
Dyslipidemia (%)	14 (35)
Chest pain onset to PPCI time, min	267 [122–330]
Infarct artery (%)	
LAD	24 (60)
RCA	14 (35)
Cx	2 (5)
Pre-PPCI TIMI flow (%)	
0	33 (83)
1	0 (0)
2	3 (8)
3	4 (10)
Post-PPCI TIMI flow (%)	
0	1 (3)
1	0 (0)
2	8 (20)
3	31 (77)
Treatment—during PPCI (%)	
Aspirin	100 (100)
Clopidogrel	24 (60)
Ticagrelor	16 (40)
Heparin	36 (90)
Bivalirudin	11 (28)
Glycoprotein IIb/IIIa inhibitors	11 (28)
Treatment—on discharge (%)	
Dual antiplatelet therapy	40 (100)
Beta-blockers	40 (100)
ACEI/ARB	40 (100)
Statin	39 (98)
MRA	10 (25)

ACEI/ARB indicates angiotensin-converting enzyme inhibitor/angiotensin receptor blocker; Cx, circumflex artery; LAD, left anterior descending artery; MRA, mineralocorticoid receptor antagonist; PPCI, primary percutaneous coronary intervention; RCA, right coronary artery; STEMI, ST-segment elevation myocardial infarction; TIMI, thrombolysis in myocardial infarction.

Chan et al.¹³ used postcontrast T₁ in 25 acute STEMI patients and found evidence of early remote systolic dysfunction and expansion of the ECM, which persisted in

Table 3. CMR Findings (n=40 STEMI Patients and n=20 Controls)

	Controls (n=20)	Acute Scan (n=40)	Follow-up Scan (n=40)	Change Between Acute and Follow-up	P Value
LV EDV, mL	148±34	172±38	182±49	−9±25	0.02* 0.01 [†]
LV ESV, mL	55±16	90±30	88±38	2±24	0.001* 0.001 [†]
LV EF, %	63±5	49±8	53±10	−5±8	0.001* 0.001 [†]
LV mass, g	108±21	112±35	104±26	8±27	NS
LV wall thickness in remote myocardium—diastole, mm	7.2±0.7	7.1±1.3	6.7±1.3	0.4±1.3	NS
LV wall thickness in remote myocardium—systole, mm	12.0±1.3	12.0±1.8	11.2±1.8	0.8±2.3	NS
LV wall thickening in remote myocardium, %	66±14	77±40	75±26	2±43	NS
LV wall motion in remote myocardium, mm	7.7±2.5	9.2±2.6	8.9±2.6	0.3±2.9	0.04* 0.10 [†]
Infarct size, % of LV	NA	27.4±14.6	19.5±10.5	7.9±7.2	0.0001
Infarct size, g	NA	20.2±13.6	14.4±9.4	5.8±5.9	0.0001
AAR, % of LV	NA	42.0±12.0	NA	NA	
T2 _{Remote} , ms	50±4	50±3	48±2	1±3	0.94* 0.001 [†]
T2 _{Infarct} , ms	NA	65±5	57±5	9±7	0.0001
T2 _{Core} , ms	NA	51±5	47±3	4±5	0.001
T1 _{Remote} , ms	1000±25	1032±51	1004±39	29±52	0.001* 0.66 [†]
T1 _{Infarct} , ms	NA	1245±75	1141±53	104±88	0.0001
T1 _{Core} , ms	NA	1025±89	1029±52	−5±79	0.74
ECV _{Remote} , %					
Whole cohort (n=40)	26.4±2.1	27.9±2.1	27.0±2.1	0.9±1.9	0.01* 0.30 [†]
With adverse LV remodeling (n=8)	NA	29.5±1.4	28.6±1.5	0.9±2.2	0.27
Without adverse LV remodeling (n=32)	NA	27.4±2.0	26.6±2.1	0.9±1.9	0.02
ECV _{Infarct} , %	NA	69.2±9.6	70.4±19.9	−1.2±18.3	0.71

AAR indicates area-at-risk; CMR, cardiovascular magnetic resonance imaging; ECV, extracellular volume fraction; EDV, end diastolic volume; EF, ejection fraction; ESV, end systolic volume; LV, left ventricle; MVO, microvascular obstruction; NA, not applicable; NS, not statistically significant; STEMI, ST-segment elevation myocardial infarction.

*Control vs acute scan.

[†]Control vs follow-up scan.

the chronic stage, and their findings partly differ from ours. We did not find evidence of systolic dysfunction in the remote myocardium, but, paradoxically, found an increase in wall motion in the remote myocardium in the acute scan only. These differences may partly be attributed to the smaller number of patients and methodology used in their study (definition of a remote sector: any segment without LGE as defined in their study may potentially include adjacent segments with edema and stunning; they only analyzed base, mid, and an apical cine compared to whole-LV short-axis analysis and using averaged values of the midventricular segments in our study). Furthermore, not all STEMI patients

showed persistence of ECV_{Remote} expansion at follow-up when using automated ECV maps and may be attributed to the fact that we included more patients with a wider range of MI size as a percentage of the LV (acute MI size in our study 27.4±14.6% vs 19.2±10.5% in their study) and the higher use of angiotensin-converting enzyme inhibitors/angiotensin receptor blockers (ACEI/ARB) and mineralocorticoid receptor antagonist (MRA) in our study (ACEI/ARB, 92% vs 100%; MRA, 16% vs 25%).

Carrick et al.¹⁴ demonstrated that increased native T1 values in remote myocardium of reperfused STEMI patients were independently associated with adverse LV remodeling

Table 4. Intraobserver and Interobserver Variability for ECV Using 2 Different Techniques (Mean Segmental Values and Manual ROI; n=10)

	Intraclass Correlation Coefficient (95% CI)	Bias±Limits of Agreement (%)
Intraobserver variability (n=10)		
ECV _{Remote}		
Mean segmental values	0.994 (0.976–0.998)	0.11±1.22
Manual ROI	0.981 (0.922–0.995)	0.42±1.59
ECV _{Infarct}		
Mean segmental values	0.992 (0.967–0.998)	0.53±2.44
Manual ROI	0.972 (0.886–0.993)	0.13±5.02
Interobserver variability (n=10)		
ECV _{Remote}		
Mean segmental values	0.996 (0.984–0.999)	0.10±0.99
Manual ROI	0.989 (0.958–0.997)	0.18±1.40
ECV _{Infarct}		
Mean segmental values	0.991 (0.949–0.998)	0.81±2.21
Manual ROI	0.963 (0.850–0.991)	0.10±5.96

ECV indicates extracellular volume fraction; ROI, region of interest.

after adjusting for LV EDV, MI size, and MVO on the acute scan. In a separate publication, Carrick et al.³¹ also showed that native T1 of the hypointense infarct core was inversely associated with the risk of all-cause mortality or hospitalization for heart failure in the same cohort of patients, although they did not adjust for native T1 of the remote myocardium. In contrast, in our cohort, we showed that MI size was the single most significant predictor of adverse LV remodeling after adjusting for similar parameters, including native T1 of the remote myocardium. Although MI size is known to be a strong predictor of outcome,^{4,5} MSI is a more-sensitive marker to assess the effectiveness of a reperfusion strategy^{32,33} in randomized, controlled trials and it was recently shown that MSI significantly reduced sample size.³⁴ Therefore, we opted to use MSI instead of MI size expressed as a percentage of the LV. We found that acute ECV_{Remote} together with MSI were also strongly associated with LV remodeling after adjusting for both T1_{Remote} and T1_{Core} and MVO. There was no evidence of edema of the remote myocardium by T2 mapping, even in those patients who subsequently developed LV remodeling.

Although the sample size was smaller in our study, our findings may also differ from the studies by Carrick et al.,^{14,31} given that we used mean segmental values for T1, T2, and ECV rather than manual ROI (the ICC for reliability of remote T1 in Carrick et al.¹⁴ was 0.92 and had quite a wide 95% CI [0.80, 0.97]). Furthermore, the majority of our patients (>70%) had whole LV coverage for the T1 maps, and ECV maps and

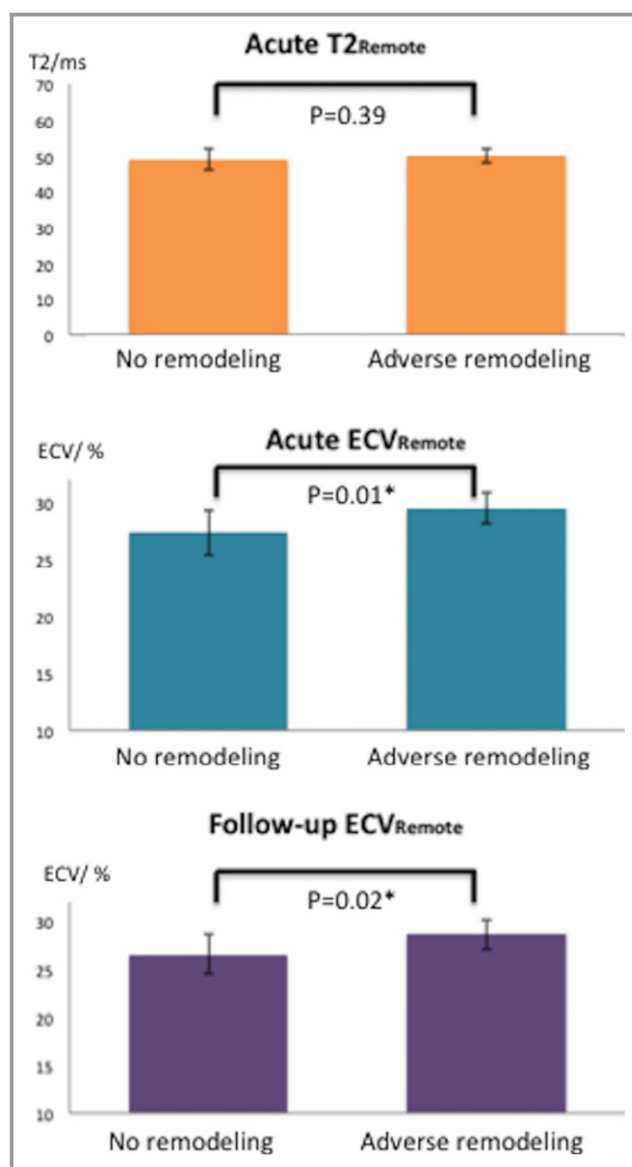


Figure 4. T2 and ECV of the remote myocardium in STEMI patients with (n=8) and without LV remodeling (n=32). ECV indicates extracellular volume fraction; LV, left ventricular; STEMI, ST-segment elevation myocardial infarction. *Denotes statistical significance at $P<0.05$.

were averaged to derive the AHA segmental values and therefore were more likely to be a better representation of the changes in the remote myocardium.

For myocardial segments with LGE, ECV_{Infarct} was as good a predictor as transmural LGE for LV wall motion recovery. For segments without MVO, ECV_{Infarct} was a significant predictor of segmental LV systolic recovery after adjusting for LGE. Given the heterogeneity of LGE, we chose to use mean segmental ECV values to minimize sampling errors and partial volume effects, and this approach may be a better reflection of the ECV matching the corresponding transmural extent of LGE per segment on both the acute and follow-up scan. The

Table 5. Univariable and Multivariable Associates of LV Remodeling (n=40)

	Univariable Analysis			Multivariable Analysis	
	Regression Slope	R ²	P Value	Regression Slope	P Value
MSI	-29	0.25	0.001	-25	0.008
ECV remote	3.5	0.24	0.001	2.6	0.03
MVO, g	2.7	0.26	0.001		NS
T1 remote	0.13	0.20	0.03		NS
T1 _{Core}	-0.06	0.14	0.001		NS

ECV indicates extracellular volume fraction; LV, left ventricle; MSI, myocardial salvage index; MVO, microvascular obstruction; NS, not statistically significant.

availability of ECV maps could provide further quantification of the infarct severity and complement transmural extent of LGE to predict wall motion recovery.

Limitations

To our knowledge, this is the first study to use automated ECV maps in this setting, which is more accurate to assess changes in myocardial extracellular volume¹⁷ and also the first study to investigate the changes occurring in the remote and infarct-related segments by ECV in paired CMR scans of STEMI patients performed acutely and after a follow-up of 5 months. However, our study is not without limitations. We only included a relatively small number of patients, and therefore we were unable to determine the impact of changes in extracellular volume on major adverse cardiovascular events. We did not collect biochemical markers for inflammation, remodeling, and fibrosis to correlate with CMR findings.

Summary and Conclusions

ECV_{Remote} was increased acutely in STEMI patients reperfused by PPCI when compared to healthy controls. For those patients who developed adverse LV remodeling, ECV_{Remote} acutely was higher than those who did not develop adverse LV remodeling and remained persistently higher at follow-up. Patients with higher ECV_{Remote} and lower MSI acutely were more likely to develop adverse LV remodeling, whereas segments with higher ECV_{Infarct} were less likely to have wall motion recovery.

Acknowledgments

We express our gratitude to the staff and patients at the UCLH Heart Hospital and Peter Weale for providing us with the *Work In Progress* investigational sequences under a research collaboration agreement with Siemens Healthcare.

Sources of Funding

This work was supported by the British Heart Foundation (FS/10/039/28270), the Rosetrees Trust, and the National Institute for Health Research University College London Hospitals Biomedical Research Center

Disclosures

None.

References

- Torabi A, Cleland JG, Khan NK, Loh PH, Clark AL, Alamgir F, Caplin JL, Rigby AS, Goode K. The timing of development and subsequent clinical course of heart failure after a myocardial infarction. *Eur Heart J*. 2008;29:859–870.
- Ezekowitz JA, Kaul P, Bakal JA, Armstrong PW, Welsh RC, McAlister FA. Declining in-hospital mortality and increasing heart failure incidence in elderly patients with first myocardial infarction. *J Am Coll Cardiol*. 2009;53:13–20.
- Levi F, Lucchini F, Negri E, La Vecchia C. Trends in mortality from cardiovascular and cerebrovascular diseases in Europe and other areas of the world. *Heart*. 2002;88:119–124.
- Wu E, Ortiz JT, Tejedor P, Lee DC, Bucciarelli-Ducci C, Kansal P, Carr JC, Holly TA, Lloyd-Jones D, Klocke FJ, Bonow RO. Infarct size by contrast enhanced cardiac magnetic resonance is a stronger predictor of outcomes than left ventricular ejection fraction or end-systolic volume index: prospective cohort study. *Heart*. 2008;94:730–736.
- Roes SD, Kelle S, Kaandorp TA, Kokocinski T, Poldermans D, Lamb HJ, Boersma E, van der Wall EE, Fleck E, de Roos A, Nagel E, Bax JJ. Comparison of myocardial infarct size assessed with contrast-enhanced magnetic resonance imaging and left ventricular function and volumes to predict mortality in patients with healed myocardial infarction. *Am J Cardiol*. 2007;100:930–936.
- Hamrani YS, Wong A, Kramer CM, Salerno M. Effect of microvascular obstruction and intramyocardial hemorrhage by CMR on LV remodeling and outcomes after myocardial infarction: a systematic review and meta-analysis. *JACC Cardiovasc Imaging*. 2014;7:940–952.
- van Kranenburg M, Magro M, Thiele H, de Waha S, Eitel I, Cochet A, Cottin Y, Atar D, Buser P, Wu E, Lee D, Bodi V, Klug G, Metzler B, Delewi R, Bernhardt P, Rottbauer W, Boersma E, Zijlstra F, van Geuns RJ. Prognostic value of microvascular obstruction and infarct size, as measured by CMR in STEMI patients. *JACC Cardiovasc Imaging*. 2014;7:930–939.
- Eitel I, Desch S, Fuernau G, Hildebrand L, Gutberlet M, Schuler G, Thiele H. Prognostic significance and determinants of myocardial salvage assessed by cardiovascular magnetic resonance in acute reperfused myocardial infarction. *J Am Coll Cardiol*. 2010;55:2470–2479.
- Masci PG, Ganame J, Strata E, Desmet W, Aquaro GD, Dymarkowski S, Valenti V, Janssens S, Lombardi M, Van de Werf F, L'Abbate A, Bogaert J. Myocardial salvage by CMR correlates with LV remodeling and early ST-segment resolution in acute myocardial infarction. *JACC Cardiovasc Imaging*. 2010;3:45–51.
- Volders PG, Willems IE, Cleutjens JP, Arends JW, Havenith MG, Daemen MJ. Interstitial collagen is increased in the non-infarcted human myocardium after myocardial infarction. *J Mol Cell Cardiol*. 1993;25:1317–1323.
- Tsuda T, Gao E, Evangelisti L, Markova D, Ma X, Chu ML. Post-ischemic myocardial fibrosis occurs independent of hemodynamic changes. *Cardiovasc Res*. 2003;59:926–933.
- Marijjanowski MM, Teeling P, Becker AE. Remodeling after myocardial infarction in humans is not associated with interstitial fibrosis of noninfarcted myocardium. *J Am Coll Cardiol*. 1997;30:76–82.
- Chan W, Duffy SJ, White DA, Gao XM, Du XJ, Ellims AH, Dart AM, Taylor AJ. Acute left ventricular remodeling following myocardial infarction: coupling of regional healing with remote extracellular matrix expansion. *JACC Cardiovasc Imaging*. 2012;5:884–893.
- Carrick D, Haig C, Rauhalampi S, Ahmed N, Mordi I, McEntegart M, Petrie MC, Eteiba H, Lindsay M, Watkins S, Hood S, Davie A, Mahrous A, Sattar N, Welsh P, Tzemos N, Radjenovic A, Ford I, Oldroyd KG, Berry C. Pathophysiology of LV remodeling in survivors of STEMI: inflammation, remote myocardium, and prognosis. *JACC Cardiovasc Imaging*. 2015;8:779–789.
- Ugander M, Oki AJ, Hsu LY, Kellman P, Greiser A, Aletras AH, Sibley CT, Chen MY, Bandettini WP, Arai AE. Extracellular volume imaging by magnetic

- resonance imaging provides insights into overt and sub-clinical myocardial pathology. *Eur Heart J*. 2012;33:1268–1278.
16. Kellman P, Wilson JR, Xue H, Bandettini WP, Shanbhag SM, Druey KM, Ugander M, Arai AE. Extracellular volume fraction mapping in the myocardium, part 2: initial clinical experience. *J Cardiovasc Magn Reson*. 2012;14:64.
 17. Kellman P, Wilson JR, Xue H, Ugander M, Arai AE. Extracellular volume fraction mapping in the myocardium, part 1: evaluation of an automated method. *J Cardiovasc Magn Reson*. 2012;14:63.
 18. O'Gara PT, Kushner FG, Ascheim DD, Casey DE Jr, Chung MK, de Lemos JA, Ettinger SM, Fang JC, Fesmire FM, Franklin BA, Granger CB, Krumholz HM, Linderbaum JA, Morrow DA, Newby LK, Ornato JP, Ou N, Radford MJ, Tamis-Holland JE, Tommaso CL, Tracy CM, Woo YJ, Zhao DX; American College of Cardiology F, American Heart Association Task Force on Practice G, American College of Emergency P, Society for Cardiovascular A and Interventions. 2013 ACCF/AHA guideline for the management of ST-elevation myocardial infarction: executive summary: a report of the American College of Cardiology Foundation/American Heart Association Task Force on Practice Guidelines: developed in collaboration with the American College of Emergency Physicians and Society for Cardiovascular Angiography and Interventions. *Catheter Cardiovasc Interv*. 2013;82:E1–E27.
 19. Steg PG, James SK, Atar D, Badano LP, Blomstrom-Lundqvist C, Borger MA, Di Mario C, Dickstein K, Ducrocq G, Fernandez-Aviles F, Gershlick AH, Giannuzzi P, Halvorsen S, Huber K, Juni P, Kastrati A, Knuuti J, Lenzen MJ, Mahaffey KW, Valgimigli M, van 't Hof A, Widimsky P, Zahger D. ESC guidelines for the management of acute myocardial infarction in patients presenting with ST-segment elevation. *Eur Heart J*. 2012;33:2569–2619.
 20. Kellman P, Hansen MS. T1-mapping in the heart: accuracy and precision. *J Cardiovasc Magn Reson*. 2014;16:2.
 21. Giri S, Chung YC, Merchant A, Mihai G, Rajagopalan S, Raman SV, Simonetti OP. T2 quantification for improved detection of myocardial edema. *J Cardiovasc Magn Reson*. 2009;11:56.
 22. Ledesma-Carbayo MJ, Kellman P, Hsu LY, Arai AE, McVeigh ER. Motion corrected free-breathing delayed-enhancement imaging of myocardial infarction using nonrigid registration. *J Magn Reson Imaging*. 2007;26:184–190.
 23. Kellman P, Arai AE. Cardiac imaging techniques for physicians: late enhancement. *J Magn Reson Imaging*. 2012;36:529–542.
 24. Arheden H, Saeed M, Higgins CB, Gao DW, Bremerich J, Wyttenbach R, Dae MW, Wendland MF. Measurement of the distribution volume of gadopentetate dimeglumine at echo-planar MR imaging to quantify myocardial infarction: comparison with 99mTc-DTPA autoradiography in rats. *Radiology*. 1999;211:698–708.
 25. Kim RJ, Wu E, Rafael A, Chen EL, Parker MA, Simonetti O, Klocke FJ, Bonow RO, Judd RM. The use of contrast-enhanced magnetic resonance imaging to identify reversible myocardial dysfunction. *N Engl J Med*. 2000;343:1445–1453.
 26. Cerqueira MD, Weissman NJ, Dilsizian V, Jacobs AK, Kaul S, Laskey WK, Pennell DJ, Rumberger JA, Ryan T, Verani MS; American Heart Association Writing Group on Myocardial S, Registration for Cardiac I. Standardized myocardial segmentation and nomenclature for tomographic imaging of the heart. A statement for healthcare professionals from the Cardiac Imaging Committee of the Council on Clinical Cardiology of the American Heart Association. *Int J Cardiovasc Imaging*. 2002;18:539–542.
 27. Schulz-Menger J, Bluemke DA, Bremerich J, Flamm SD, Fogel MA, Friedrich MG, Kim RJ, von Knobelsdorff-Brenkenhoff F, Kramer CM, Pennell DJ, Plein S, Nagel E. Standardized image interpretation and post processing in cardiovascular magnetic resonance: Society for Cardiovascular Magnetic Resonance (SCMR) board of trustees task force on standardized post processing. *J Cardiovasc Magn Reson*. 2013;15:35.
 28. Ugander M, Bagi PS, Oki AJ, Chen B, Hsu LY, Aletras AH, Shah S, Greiser A, Kellman P, Arai AE. Myocardial edema as detected by pre-contrast T1 and T2 CMR delineates area at risk associated with acute myocardial infarction. *JACC Cardiovasc Imaging*. 2012;5:596–603.
 29. Verhaert D, Thavendirathan P, Giri S, Mihai G, Rajagopalan S, Simonetti OP, Raman SV. Direct T2 quantification of myocardial edema in acute ischemic injury. *JACC Cardiovasc Imaging*. 2011;4:269–278.
 30. Obuchowski NA. Nonparametric analysis of clustered ROC curve data. *Biometrics*. 1997;53:567–578.
 31. Carrick D, Haig C, Rauhalmi S, Ahmed N, Mordi I, McEntegart M, Petrie MC, Eteiba H, Hood S, Watkins S, Lindsay M, Mahrous A, Ford I, Tzemos N, Sattar N, Welsh P, Radjenovic A, Oldroyd KG, Berry C. Prognostic significance of infarct core pathology revealed by quantitative non-contrast in comparison with contrast cardiac magnetic resonance imaging in reperfused ST-elevation myocardial infarction survivors. *Eur Heart J*. 2016;37:1044–1059.
 32. Pennell D. Myocardial salvage: retrospection, resolution, and radio waves. *Circulation*. 2006;113:1821–1823.
 33. Botker HE, Kalltoft AK, Pedersen SF, Kim WY. Measuring myocardial salvage. *Cardiovasc Res*. 2012;94:266–275.
 34. Engblom H, Heiberg E, Erlinge D, Jensen SE, Nordrehaug JE, Dubois-Rande JL, Halvorsen S, Hoffmann P, Koul S, Carlsson M, Atar D, Arheden H. Sample size in clinical cardioprotection trials using myocardial salvage index, infarct size, or biochemical markers as endpoint. *J Am Heart Assoc*. 2016;4:e002708 doi: 10.1161/JAHA.115.002708.



Automated Extracellular Volume Fraction Mapping Provides Insights Into the Pathophysiology of Left Ventricular Remodeling Post –Reperfused ST–Elevation Myocardial Infarction

Heerajnarain Bulluck, Stefania Rosmini, Amna Abdel-Gadir, Steven K. White, Anish N. Bhuva, Thomas A. Treibel, Marianna Fontana, Esther Gonzalez-Lopez, Patricia Reant, Manish Ramlall, Ashraf Hamarneh, Alex Sirker, Anna S. Herrey, Charlotte Manisty, Derek M. Yellon, Peter Kellman, James C. Moon and Derek J. Hausenloy

J Am Heart Assoc. 2016;5:e003555; originally published July 11, 2016;
doi: 10.1161/JAHA.116.003555

The *Journal of the American Heart Association* is published by the American Heart Association, 7272 Greenville Avenue, Dallas, TX 75231
Online ISSN: 2047-9980

The online version of this article, along with updated information and services, is located on the World Wide Web at:

<http://jaha.ahajournals.org/content/5/7/e003555>

Subscriptions, Permissions, and Reprints: The *Journal of the American Heart Association* is an online only Open Access publication. Visit the Journal at <http://jaha.ahajournals.org> for more information.