

Ventral tegmental area deep brain stimulation in refractory short-lasting unilateral neuralgiform headache attacks

¹Sarah Miller MRCP, ^{2,3}Harith Akram MRCS, ¹Susie Lagrata BSc, ²Marwan Hariz, ^{2,3,*}Ludvic Zrinzo MD PhD FRCSEd and ^{1,*}Manjit Matharu FRCP, PhD

* Both senior authors contributed equally to this paper

¹Headache Group, Institute of Neurology, University College London and National Hospital for Neurology and Neurosurgery, London, United Kingdom; ²Unit of Functional Neurosurgery, Sobell Department of Motor Neuroscience and Movement Disorders, Institute of Neurology, University College London ;³Department of Neurosurgery, National Hospital for Neurology and Neurosurgery, London, United Kingdom

Prepared For: Brain
Abstract: 304
Body Word Count: 3962
Tables: 5
Figures: 3
Supplementary Tables:4
References: 32

Correspondence:
Dr MS Matharu
Senior Lecturer and Honorary Consultant Neurologist
Headache Group, Institute of Neurology and The National Hospital for Neurology and Neurosurgery, Queen Square, London WC1N 3BG

Email: m.matharu@uclmail.net
Tel: +447595900535
Fax: +44 7092120797

Running Title: DBS SUNCT/SUNA

Keywords: Short lasting unilateral neuralgiform headache attacks, SUNCT, SUNA, Trigeminal autonomic cephalalgia, Neuromodulation, Deep Brain Stimulation

Abbreviations:

ICHD3-beta: International Classification of Headache Disorders 3-beta

SUNCT: Short lasting unilateral neuralgiform headache attacks with conjunctival injection and tearing

SUNA: Short lasting unilateral neuralgiform headache attacks with autonomic features

ONS: Occipital nerve stimulation

VTA: Ventral tegmental area

DBS: Deep brain stimulation

NHS: National Health Service

HAL: Headache load

VRS: Verbal rating scale

MIDAS: Migraine Disability Assessment Scores

HIT-6: Headache Impact Test Scores

BDI-II: Beck Depression Inventory II Score

HAD-A: Hospital Anxiety and Depression Score, Anxiety component

HAD-D: Hospital Anxiety and Depression Score, Depression component

EQ-5D: EuroQoL Score

Running Title: DBS SUNCT/SUNA

SF36: Short-Form 36 Score (SF36P – physical component, SF36M – mental component)

IPG: Implantable pulse generator

IQR: Interquartile range

CCH: chronic cluster headache

ABSTRACT

Short-lasting unilateral neuralgiform headache attacks are primary headache conditions characterized by short lasting attacks of unilateral pain accompanied by autonomic features. A small minority are refractory to medical treatment. Neuroimaging studies have suggested a role of the posterior hypothalamic region in their pathogenesis. Previous case reports on deep brain stimulation of this region, now understood to be the ventral tegmental area, for this condition are limited to a total of three patients. We present outcomes on a cohort of 11 new patients treated with ventral tegmental area deep brain stimulation in an uncontrolled open-label prospective study.

Eleven patients with refractory short-lasting unilateral neuralgiform headache attacks underwent ipsilateral ventral tegmental area deep brain stimulation in a specialist unit. All patients had failed, or been denied access to, occipital nerve stimulation within the United Kingdom's National Health Service. Primary endpoint was change in mean daily attack frequency at final follow-up. Secondary outcomes included attack severity, attack duration, headache load, quality of life measures, disability and affective scores. Information was also collected on adverse events.

Eleven patients (seven male) with a median age of 50 years (range 26-67) were implanted between 2009 and 2014. Median follow-up was 29 months (range 7-63). At final follow-up the median improvement in daily attack frequency was 78% (IQR 33%). Response rate (defined as at least a 50% improvement in daily attack frequency) was 82% and four patients were rendered pain free for prolonged periods of time. Headache load (a composite score of attack frequency, severity and duration) improved by 99% (IQR 52%). Improvements were observed in a number of quality of life, disability and affect measures. Adverse events included mild incision site pain, subcutaneous displacement of the implantable pulse generator, transient oscillopsia and minor wound infection. One patient required removal of the system due to wound infection.

Running Title: DBS SUNCT/SUNA

Ventral tegmental area deep brain stimulation may be an effective treatment option for refractory short-lasting unilateral neuralgiform headache attack patients who have failed other therapies.

INTRODUCTION

Short-lasting unilateral neuralgiform headache attacks are a rare form of primary headache characterised by frequent attacks of excruciating unilateral pain occurring in the trigeminal distribution, centred on the eye and temple, with associated autonomic features. They are included in the group known as the trigeminal autonomic cephalalgias and The International Classification of Headache Disorders (ICHD3-beta) describes two subtypes (Table 1): short-lasting unilateral neuralgiform headache attacks with conjunctival injection and tearing (SUNCT) and short-lasting unilateral neuralgiform headache attacks with cranial autonomic features (SUNA) (Headache Classification Committee of the International Headache, 2013). The condition is said to be chronic when it occurs for more than a year with remission periods lasting less than one-month. Short-lasting unilateral neuralgiform headache attacks can be difficult to treat medically. In the past, intractable patients have been subjected to destructive procedures of the trigeminal nerve with poor long-term results (Black and Dodick, 2002). Peripheral (occipital nerve stimulation [ONS]) and central (ventral tegmental area [VTA] deep brain stimulation [DBS]) neuromodulation techniques have been carried out with more promising results (Leone *et al.*, 2005, Lyons *et al.*, 2009, Bartsch *et al.*, 2011, Lambru *et al.*, 2014).

To date there are three published case reports of DBS for short-lasting unilateral neuralgiform headache attacks (Leone *et al.*, 2005, Lyons *et al.*, 2009, Bartsch *et al.*, 2011). We present a consecutive series of 11 patients with intractable chronic short-lasting unilateral neuralgiform headache attacks treated with VTA-DBS as a humanitarian intervention reporting on changes in attack characteristics, quality of life, headache disability, affect scores and adverse events.

PATIENTS AND METHODS

Running Title: DBS SUNCT/SUNA

This was an observational study based on a prospective, open label cohort initiated in 2009. Under the supervision of our institution's Clinical Effectiveness Supervisory Committee with arrangements for clinical governance, consent and audit, we offered VTA-DBS to medically intractable short-lasting unilateral neuralgiform headache attacks who had failed ONS or had been declined NHS funding for ONS. The procedure was provided on the basis of a "humanitarian intervention". In addition, ethic board approval for data collection and publication was granted by Northwick Park Hospital Research Ethics Committee, Hampstead, London, UK.

All patients were seen by a single specialist headache team at the National Hospital for Neurology and Neurosurgery, Queen Square, London UK and referred to a single multidisciplinary DBS team at the same centre. All patients fulfilled the International Classification of Headache Disorders-2 criteria at diagnosis but also met revised ICHD-3beta criteria (Headache Classification Subcommittee of the International Headache Society., 2004, Headache Classification Committee of the International Headache, 2013). Patients with prolonged attacks had a trial of Indometacin (oral or intramuscular) to rule out Indometacin-sensitive headaches (Antonaci *et al.*, 2003). Unlike chronic cluster headache or chronic migraine, intractability is not defined for short-lasting unilateral neuralgiform headache attacks (Goadsby *et al.*, 2006). Patients were considered suitable for VTA-DBS if they had had disabling, medically intractable chronic short-lasting unilateral neuralgiform headache attacks for at least two years and had failed adequate trials of lamotrigine, topiramate, gabapentin, pregabalin and at least one of either carbamazepine or oxcarbazepine (Lambru *et al.*, 2014). Agents were selected on the basis of reported efficacy in this condition and local experience (Cohen *et al.*, 2006, Williams and Broadley, 2008). A failed trial was defined as lack of response, intolerable side effects or contradiction to the use of the drug. One patient (P9) did not meet the criteria for medical intractability as they had not trialled carbamazepine or

oxcarbazepine but this patient was implanted primarily for co-existent intractable chronic cluster headache. All patients were considered for ONS prior to VTA-DBS and had either been declined funding or failed to respond. Microvascular decompression of the trigeminal nerve was not being offered to this patient group during the study period. Neuropsychological evaluations and MRI brain scans were performed to exclude possible contraindications to surgery such as significant cognitive impairment, brain lesion or significant brain atrophy.

Outcomes

The two primary outcome measures were the change in median daily attack frequency from baseline to final follow-up and clinical response to VTA-DBS defined as an at least 50% reduction in daily attack frequency. Secondary outcomes included reduction in the daily attack severity and frequency, headache specific disability scores, quality of life and affect scores.

Outcome data was collected and recorded prospectively. Patients were seen at three monthly intervals post implant over the first year and six monthly thereafter. Timing of additional appointments was dependent on clinical condition. Data collected included demographics, diagnosis, previous and current treatments, attack frequency, attack severity, headache load, headache disability scores, quality of life scales, affective scores, DBS settings and complications.

Headache load (HAL) is a composite score defined as $\Sigma(\text{severity [verbal rating scale]} \times \text{duration [hours]})$ of all attacks over a two week period (Levy *et al.*, 2004). Patients were asked to record these data in a headache diary completed for at least two weeks before every assessment. Headache severity was measured on a verbal rating scale (VRS; 0=no pain – 10=excruciating pain). Patients with multiple headache types were able to differentiate their phenotypes and kept a separate diary for each headache syndrome.

Although specific tools for measuring the associated disability of trigeminal autonomic cephalalgias have yet to be validated, Migraine Disability Assessment Scores (MIDAS) and Headache Impact Test-6 Scores (HIT-6) were recorded pre and post-DBS to monitor disability. These scores have been widely used in the assessment of primary headache disorders and have previously been used to monitor response to cluster headache, hemicrania continua and short-lasting unilateral neuralgiform disorders in ONS (Schwedt *et al.*, 2007, Burns *et al.*, 2009, Lambru *et al.*, 2014). Beck Depression Inventory II Score (BDI-II), Hospital Anxiety (HAD-A) and Depression (HAD-D) Scores were used to monitor mental state pre- and post-ONS implant and quality of life was assessed using the EuroQoL (EQ-5D) and Short-Form 36 (SF36).

Data were collected prospectively and entered onto a clinical database (Microsoft Excel, Microsoft Corporation, Redmond, WA, USA).

Surgical Procedure

Deep brain stimulation surgery was performed with the Leksell frame (model G, Elekta Instrument AB, Stockholm, Sweden), using an MRI-guided and MRI-verified approach without microelectrode recording. This approach has previously been described for alternative DBS targets (Holl *et al.*, 2010, Foltynie *et al.*, 2011). Surgery was performed under local anaesthesia for patients one to four and under general anaesthesia for all others (P5-11). The anatomical target was the VTA ipsilateral to the side of attacks. The location of the deepest contact of the Medtronic 3389 lead was defined on an axial 1.5T T2-weighted stereotactic MRI image at a level immediately above the mammillary bodies, anteromedial to the hypointense red nucleus and posterolateral to the hypointense mammillothalamic tract. Postoperatively, electrode position was verified using a stereotactic MRI (or CT in patient 8 with ONS in situ) (Fig 1). MRI in patients with implanted ONS or DBS hardware was obtained using a low

energy protocol (Zrinzo *et al.*, 2011). All DBS leads were implanted within 1mm of the intended target point. The lead was then connected to a Medtronic implantable pulse generator (IPG) located in the infra-clavicular region.

DBS Programming

Prior to hospital discharge all patients underwent initial programming to define optimal stimulation parameters. The contact point that produced typical patient complaints of transient vertical diplopia, vertigo, oscillopsia and ophthalmoplegia at the lowest amplitudes was chosen as the initial stimulation contact. Four patients had stimulation started immediately and all remaining patients had a delay of four to seven weeks before stimulation was started. This delay was due to patients exhibiting a stun effect post-operatively where attacks transiently improved without use of stimulation. In those with a stun effect, DBS was not initiated until attacks returned to normal pre-surgical frequency. All devices were programmed with frequency of 185Hz and a 60 μ s pulse width. Voltage was adjusted according to patient reported side effects (see above) aiming for a maximum of 4.0V. Adjustments in voltage were undertaken in single or multiple steps dependent on patient tolerability. Stimulation parameters remained constant for three months after each re-programming session. Adjustments in stimulation parameters were made depending on clinical response.

Statistics

All statistical analyses were conducted using IBM SPSS Statistics version 22 (IBM Corp. Int.). In descriptive analysis, continuous variables were summarized using median and interquartile range and categorical variable using percentages. Wilcoxon signed-rank tests were used to measure changes in baseline values. A last observation carried forward technique was used in the case of missing data. All statistical tests were two-sided with a significance level of 5%.

RESULTS

Patient demographics

Eleven patients (six male) with short-lasting unilateral neuralgiform headache attacks underwent VTA-DBS between October 2009 and September 2014. Patient demographics and baseline headache characteristics are shown in Table 2. Median age at implant was 50 years (range 26-67). Three patients were diagnosed with SUNA and eight SUNCT. Nine patients had been chronic since onset. Median duration of the chronic phase was 9 years (range 4-20). Five patients had additional headache syndromes including chronic migraine (three patients), chronic cluster headache (three patients) (Table 2). In those with cluster headache, attacks of short-lasting unilateral neuralgiform headache attacks were ipsilateral to their cluster attacks in all but one patient (P9) who had left sided cluster attacks and unilateral but side variable SUNCT attacks (more common on the left). Eight patients had unilateral DBS electrodes implanted and three had bilateral implants (P9 and P10) for side variable attacks (Supplementary Table 4). Two patients (P5 and P9) had previously undergone ONS implantation with little (P9) or no effect (P5) on their SUNCT. Patient 5 had had the ONS device removed prior to VTA-DBS and Patient 10 still had the ONS in-situ given its partial effect on their cluster headaches.

All patients had undergone MRI brain scans prior to VTA-DBS of which two showed evidence of neurovascular conflict of the ipsilateral trigeminal nerve.

Patients had tried a median of 11 treatments (IQR 3) including oral preventative drugs and injectable treatments (Supplementary Table 1 and 2). Nine of ten patients that received lidocaine infusions reported transient benefit and ten patients failed to receive any benefit from greater occipital nerve blocks.

Follow up and Final outcome

Post-operative follow-up ranged from seven to 63 months with a median of 29 months (IQR 20). One patient had her DBS system removed at time of follow-up.

At final follow up, median attack frequency had reduced by 78% (IQR 33) from 45 (IQR 10) to 2 (IQR 180) attacks per day ($p=0.003$) (Fig 2 and Table 3). A positive clinical response, defined as at least a 50% reduction in attack frequency, was seen in 82% (9 patients).

Of the two who failed to respond, one (P5) had the stimulator switched off for around 12 months during the 32-month follow-up due to tolerability issues but still obtained a more than 30% reduction in attacks. The other (P6), reporting a 25% reduction in attack frequency at follow-up did not have an implant in-situ having had the DBS system removed 17 months into her 24 month follow-up due to a wound infection. Previous to implant removal, the patient was reporting a 90% reduction in daily attack frequency.

Patient estimate of improvement was 70% (IQR 95%) (Table 3) and all patients said they would recommend the treatment to others. The median time to reach a 50% improvement was 1 month (range 1-2 months). Only one responder had the system switched off for any period of time (P6) and attack frequency returned to baseline within 1 month of DBS removal.

In those with co-existent headache conditions, cluster headache attacks decreased in two patients (P3 and P9) by 72% and 25% respectively. Migrainous headaches failed to respond in the three patients (P3, P6 and P10) reporting them.

Attack severity, duration and headache load

At final follow-up, median attack severity reduced by 50% from 10 (IQR 2) to 5 (IQR 10) points on VRS ($p=0.020$). Median attack duration reduced by 99% (IQR 100) from 7200 to 30 seconds but this change was not statistically significant ($p=0.066$). Headache load showed a

median reduction of 99% (IQR 52) ($p=0.026$). Neither of the patients categorized as clinical non-responders (P5 and P6) showed a more than 50% reduction in HAL. One patient (P9) who recorded a 66% reduction in attack frequency failed to show a matching response to HAL (48% reduction) (Table 3).

Headache associated disability scores, quality of life and affect measures

Baseline median MIDAS and HIT-6 scores were 81 (IQR 254) and 70 (IQR 12) respectively, both scores being within the severely affected range (Table 4). At final follow-up statistically significant reductions were seen in HIT-6 but not MIDAS. Median HIT-6 fell by 15 points ($p=0.015$) well above the three point minimally important change (Smelt *et al.*, 2014). MIDAS fell by 39 points ($p=0.678$) which although not statistically significant is above the nine-point difference separating moderate from severe disability.

Summary measures of the physical (SF-36P) and mental (SF-36M) SF-36 scale showed a non-significant improvement (Table 3). No significant change was seen in the separate domain scores of SF-36 scale (Figure 3). Euro-QoL 5D and EuroScale scores did not show any significant change post implant (Table 4). Prior to implant all affective scores indicated the presence of moderate mood disorders. Post treatment, both HAD-A and BDI-II scales indicated mild disorder scores but HAD-D continued to indicate moderate levels of depression (Table 4). Despite this clinical change, there was no statistically significant change in affective scores at follow-up.

Adverse Events

Adverse events were recorded if any issues had arisen during the time of treatment. Events were classified as “hardware related” if they involved a malfunction of any device component, “biological” if they involved pain or other biological reactions related to the device or the surgical procedure to implant it and “stimulation-related” if they were thought to be related to

stimulation. One hardware related event was noted with a patient requiring surgical revision of their IPG due to the IPG moving or “flipping”. Biological adverse events included mild to moderate neck stiffness in three patients, keloid scar in one patient and persistent pain over wound sites in two patients. One patient suffered a small wound dehiscence in the first three weeks post-operatively with no evidence of wound infection. One patient suffered a wound infection at the lead/cable connector site 17 months post-implant (P6). Due to the risk of spread of infection, the whole DBS system was removed. All patients reported transient stimulation related adverse effects (described in DBS programming section above) related to DBS programming resolving within minutes to hours. One patient complained of symptoms compatible with oscillopsia on reading for six weeks after their initial programming session that resolved spontaneously. One patient (P5) complained of intolerable worsening of chronic nausea with any change in stimulation, however, with blinded changes in stimulation and in a 12-month period without stimulation there was no change in the nausea and it was judged that this complaint was not related to stimulation. A total of two surgical interventions were required during follow-up (Table 5).

Concomitant drug use

Nine patients were taking preventative medications for short lasting unilateral neuralgiform headache attacks at time of implant (Supplementary Table 3). At final follow-up, four patients had stopped all preventatives for their SUNCT/SUNA and a further two had been able to reduce their doses of one or more medications.

Stimulation parameters

A summary of stimulation parameters is given in Supplementary Table 4. Median stimulation amplitude at follow-up was 3.0V. Subjects had a median of 6 changes to stimulation parameters during follow-up.

DISCUSSION

Previous case reports of VTA-DBS treatment in short lasting unilateral neuralgiform headache attacks have suggested a benefit in three patients (Leone *et al.*, 2005, Lyons *et al.*, 2009, Bartsch *et al.*, 2011). Our open-label prospective series of eleven patients suggests that VTA-DBS may be an effective and safe treatment in patients with intractable short lasting unilateral neuralgiform headache attacks who have proved refractory to all other available treatment modalities. In our group of eleven patients there was a significant reduction in daily attack frequency of 78% with four patients remaining pain free for prolonged periods of time. Overall nine patients had a positive response to VTA-DBS with a 50% or more reduction in attack frequency. Improvement was seen in headache specific disability scores (HIT-6) but not in quality of life scales or measures of depression.

Deep brain stimulation for another trigeminal autonomic cephalalgia chronic cluster headache (CCH) was first undertaken by Leone *et al* in 2001 (Leone *et al.*, 2001). This procedure was based on the findings of a 1998 study which showed increased activation on positron emission tomography in the posterior hypothalamic region during cluster headache attacks (May *et al.*, 1998). To date, there is now published data on over 70 patients with intractable CCH treated with DBS. One series which pools 58 of these patients reports that 62% showed a 50% or greater reduction in attack frequency (Magis and Schoenen, 2012). Similar findings of

activation of the ipsilateral inferior posterior hypothalamic region was also observed during SUNCT attacks and therefore the same DBS target was proposed to be potentially beneficial in the treatment of short lasting unilateral neuralgiform headache attacks (May *et al.*, 1999). Only three case reports have been published, all showing substantial and sustained reductions in attack frequency without any serious adverse events (Leone *et al.*, 2005, Lyons *et al.*, 2009, Bartsch *et al.*, 2011). Since the initial work of May and Leone, further anatomical clarification of the surgical target has been undertaken and the target has been shown to be in the ventral tegmental area of the midbrain rather than the posterior hypothalamic region (Fontaine *et al.*, 2010, Matharu and Zrinzo, 2010).

Our series shows improvements in both attack frequency (78%) and severity (50%) with VTA-DBS. This finding has been described in CCH cases treated with VTA-DBS but not short lasting unilateral neuralgiform headache attack cases (Magis and Schoenen, 2012). This series also reports the headache load (HAL) as an outcome measure for the group. This composite score reflects all three domains of headache burden (frequency, severity and duration). Attack frequency has always been the focus of previous outcome reports for VTA-DBS for headache. However, the use of a single outcome may not represent the actual benefit perceived by the patient. Headache load showed a significant improvement (99%) at final follow-up. In our group, only one patient showed a discrepancy between attack frequency and HAL response (P9). This patient exhibited a 66% reduction in attack frequency (and so a positive response to VTA-DBS) but a 48% reduction in HAL. It is interesting to note that this patient stated they had not perceived any benefit from the treatment. The clinical usefulness of HAL as a primary outcome measure needs validation in larger cohorts in the future.

As in previous VTA-DBS for primary headache series our subjects reported a delay in clinical response. In CCH this delay is several months long but in the short lasting unilateral neuralgiform headache cases ranged from days to a maximum of three months (Leone *et al.*,

2005, Burns *et al.*, 2009, Lyons *et al.*, 2009, Bartsch *et al.*, 2011, Magis *et al.*, 2011, Magis and Schoenen, 2012). In our series, the time taken to see positive clinical response was 1 month (range 1-2 months). This delay likely reflects the neuroplastic response underlying successful VTA-DBS treatment.

Clinically and statistically important differences were seen in HIT-6 scores following VTA-DBS but no significant improvement was seen in quality of life measures. Factors to consider in this observation include the small sample size, the long duration of chronic pain (9 years) and co-morbidities in these patients all of which may have resulted in psychosocial issues unlikely to improve with change in symptoms. Similar observations have been made in VTA-DBS for CCH (Bartsch *et al.*, 2008). Little has been published regarding quality of life data in the trigeminal autonomic cephalalgias including short lasting unilateral neuralgiform attack disorders and no specific headache disability or quality of life scales exist for these conditions. It has been suggested that in headache conditions, generic scales (such as SF36) may not be useful in measuring changes over time and that condition specific measures (such as HIT-6) may be more representative (Solomon, 1997). Until such scales have been developed the quality of life tools available may not accurately reflect the headache groups they are applied to.

Only one serious adverse event of subcutaneous infection leading to system removal was seen in our series. Infection of the DBS system has been reported by two other CCH series (4/19 and 1/11 patients) (Fontaine *et al.*, 2010, Leone *et al.*, 2013), although their operative technique differed from our unit. The death of a patient from an intracerebral haemorrhage following microelectrode (MER) guided DBS for CCH has raised serious safety concerns regards this procedure. However, there is no recognised neuronal firing pattern or “signature” for the VTA, casting doubt on the clinical utility of MER for this anatomical target. Moreover, the use of an MRI-verified surgical technique without the use of MER is associated with a significantly

lower risk of haemorrhage during DBS procedures (Zrinzo *et al.*, 2012). The stimulation induced ophthalmic side effects reported by our patients have all been documented in CCH series and, much like our series, have all been transient. It is likely that this transient vertical diplopia is due to stimulation of the nearby rostral interstitial nucleus of the medial longitudinal fasciculus that forms part of the vertical gaze center (Buttner-Ennever *et al.*, 1982).

The main limitation of this study is the lack of placebo control. Although there is undoubtedly a placebo effect for headache treatments it is unlikely our findings can be explained by this alone. Placebo response rates for ONS in migraine are low (below 20%) and there is no reason to expect this not to be true in this condition or procedure (Lipton *et al.*, 2009, Saper *et al.*, 2011, Silberstein *et al.*, 2012). Likewise, the intractable nature of the group, the sustained response and the re-emergence of attacks when stimulation was stopped all argue against a placebo response. Although a previous randomized controlled trial of DBS in CCH failed to show a difference between sham and active stimulation this was likely due to methodological issues with a too short 1-month crossover periods. Unfortunately, given the rarity of short lasting unilateral neuralgiform headache attacks it seems unlikely that high quality, properly powered randomised control trials of VTA-DBS will ever be performed.

Microvascular decompression, occipital nerve stimulation and deep brain stimulation have all been found to be effective in open-label series with response rates of over 75% (Leone *et al.*, 2005, Bartsch *et al.*, 2011, Sebastian *et al.*, 2013, Lambru *et al.*, 2014). The invasiveness of surgery, associated risks, the need for implanted hardware and the cost of treatment will all influence individual patient options. With these in mind, we may in the future recommend that patients with intractable short lasting unilateral neuralgiform headache attacks first undergo microvascular decompression if they have ipsilateral neurovascular compression of the trigeminal nerve, that ONS be reserved for those without neurovascular compression or failing

Running Title: DBS SUNCT/SUNA

microvascular decompression and DBS (as the most invasive neuromodulation option) be left as an option when patients have failed all other procedures.

This study suggests that VTA-DBS may provide an effective and sustained benefit in intractable short lasting unilateral neuralgiform headache attacks. However, MRI-verified VTA-DBS should be reserved for those patients having failed all other medical and surgical options available to them.

Acknowledgements:

We would like to thank our Headache Specialist nurses and the surgical teams for their involvement with the patients. We also thank the patients and their families for their help with this project.

Supplementary Material

Supplementary Tables 1-4

Disclosure

SM reports an educational grant from St Jude Medical and honoraria and travel expenses from Medtronic to attend meetings.

HA reports no disclosures

SL reports no disclosures

MH has received honoraria and travel expenses from Medtronic and St Jude Medical for speaking at meetings

Running Title: DBS SUNCT/SUNA

LZ has received honoraria and travel expenses from Medtronic for speaking at meetings

MSM serves on the advisory board for Allergan, St Jude Medical and Medtronic and has received payment for the development of educational presentations from Allergan, Merck Sharpe and Dohme Ltd., Medtronic and electroCore

Author contributions

SM: collection, interpretation and statistical analysis of data, drafting of manuscript and revision

HA: manuscript revision

SL: collection of data

MH: manuscript critical suggestions and suggested revisions

LZ: study concept and manuscript revision

MSM: study concept, collection of data and manuscript revision

References

- Antonaci F, Costa A, Ghirmai S, Sances G, Sjaastad O, Nappi G. Parenteral indomethacin (the INDOTEST) in cluster headache. *Cephalalgia : an international journal of headache*. 2003;23(3):193-6.
- Bartsch T, Falk D, Knudsen K, Reese R, Raethjen J, Mehdorn HM, et al. Deep brain stimulation of the posterior hypothalamic area in intractable short-lasting unilateral neuralgiform headache with conjunctival injection and tearing (SUNCT). *Cephalalgia : an international journal of headache*. 2011;31(13):1405-8.
- Bartsch T, Pinsker MO, Rasche D, et al. Hypothalamic deep brain stimulation for cluster headache: experience from a new multicase series. *Cephalalgia : an international journal of headache*. 2008;28:285-95.
- Black DF, Dodick DW. Two cases of medically and surgically intractable SUNCT: a reason for caution and an argument for a central mechanism. *Cephalalgia : an international journal of headache*. 2002;22(3):201-4.
- Burns B, Watkins L, Goadsby PJ. Treatment of intractable chronic cluster headache by occipital nerve stimulation in 14 patients. *Neurology*. 2009;72(4):341-5.
- Buttner-Ennever JA, Buttner U, Cohen B, Baumgartner G. Vertical glaze paralysis and the rostral interstitial nucleus of the medial longitudinal fasciculus. *Brain : a journal of neurology*. 1982;105(Pt 1):125-49.
- Cohen AS, Matharu MS, Goadsby PJ. Short-lasting unilateral neuralgiform headache attacks with conjunctival injection and tearing (SUNCT) or cranial autonomic features (SUNA)--a prospective clinical study of SUNCT and SUNA. *Brain : a journal of neurology*. 2006;129(Pt 10):2746-60.
- Foltynie T, Zrinzo L, Martinez-Torres I, Tripoliti E, Petersen E, Holl E, et al. MRI-guided STN DBS in Parkinson's disease without microelectrode recording: efficacy and safety. *Journal of neurology, neurosurgery, and psychiatry*. 2011;82(4):358-63.
- Fontaine D, Lanteri-Minet M, Ouchchane L, Lazorthes Y, Mertens P, Blond S, et al. Anatomical location of effective deep brain stimulation electrodes in chronic cluster headache. *Brain : a journal of neurology*. 2010;133(Pt 4):1214-23.
- Fontaine D, Lazorthes Y, Mertens P, Blond S, Geraud G, Fabre N, et al. Safety and efficacy of deep brain stimulation in refractory cluster headache: a randomized placebo-controlled double-

blind trial followed by a 1-year open extension. The journal of headache and pain. 2010;11(1):23-31.

Goadsby PJ, Schoenen J, Ferrari MD, Silberstein SD, Dodick D. Towards a definition of intractable headache for use in clinical practice and trials. Cephalalgia : an international journal of headache. 2006;26(9):1168-70.

Headache Classification Committee of the International Headache S. The International Classification of Headache Disorders, 3rd edition (beta version). Cephalalgia : an international journal of headache. 2013;33(9):629-808.

Headache Classification Subcommittee of the International Headache Society. The International Classification of Headache Disorders, 2nd edn. Cephalalgia : an international journal of headache. 2004;24(Suppl 1):1-160.

Holl EM, Petersen EA, Foltynie T, Martinez-Torres I, Limousin P, Hariz MI, et al. Improving targeting in image-guided frame-based deep brain stimulation. Neurosurgery. 2010;67(2 Suppl Operative):437-47.

Lambru G, Shanahan P, Watkins L, Matharu MS. Occipital Nerve Stimulation in the Treatment of Medically Intractable SUNCT and SUNA. Pain physician. 2014;17(1):29-41.

Leone M, Franzini A, Bussone G. Stereotactic stimulation of posterior hypothalamic gray matter in a patient with intractable cluster headache. N Engl J Med. 2001;345(1428-1429).

Leone M, Franzini A, D'Andrea G, Broggi G, Casucci G, Bussone G. Deep brain stimulation to relieve drug-resistant SUNCT. Annals of Neurology. 2005;57(6):924-7.

Leone M, Franzini A, Proietti Cecchini A, Bussone G. Success, failure, and putative mechanisms in hypothalamic stimulation for drug-resistant chronic cluster headache. Pain. 2013;154(1):89-94.

Levy MJ, Jager HR, Powell M, Matharu MS, Meeran K, Goadsby PJ. Pituitary volume and headache: size is not everything. Arch Neurol. 2004;61(5):721-5.

Lipton R, Goadsby PJ, Cady R, Aurora SK, Grosberg BM, Freitag F, et al. PRISM study: Occipital nerve stimulation for treatment-refractory migraine. Cephalalgia. 2009;29(Suppl 1):30.

Lyons MK, Dodick DW, Evidente VG. Responsiveness of short-lasting unilateral neuralgiform headache with conjunctival injection and tearing to hypothalamic deep brain stimulation. J Neurosurg. 2009;110(2):279-81.

Magis D, Gerardy PY, Remacle JM, Schoenen J. Sustained effectiveness of occipital nerve stimulation in drug-resistant chronic cluster headache. Headache. 2011;51(8):1191-201.

Magis D, Schoenen J. Advances and challenges in neurostimulation for headaches. *The Lancet Neurology*. 2012;11(8):708-19.

Matharu MS, Zrinzo L. Deep brain stimulation in cluster headache: hypothalamus or midbrain tegmentum? *Current pain and headache reports*. 2010;14(2):151-9.

May A, Bahra A, Büchel C, et al. Hypothalamic activation in cluster headache attacks. *Lancet*. 1998;352:275-8.

May A, Bahra A, Buchel C, Turner R, Goadsby PJ. Functional magnetic resonance imaging in spontaneous attacks of SUNCT: short-lasting neuralgiform headache with conjunctival injection and tearing. *Annals of neurology*. 1999;46(5):791-4.

Saper JR, Dodick DW, Silberstein SD, McCarville S, Sun M, Goadsby PJ. Occipital nerve stimulation for the treatment of intractable chronic migraine headache: ONSTIM feasibility study. *Cephalalgia : an international journal of headache*. 2011;31(3):271-85.

Schwedt TJ, Dodick DW, Hentz J, Trentman TL, Zimmerman RS. Occipital nerve stimulation for chronic headache--long-term safety and efficacy. *Cephalalgia : an international journal of headache*. 2007;27(2):153-7.

Sebastian S, Schweitzer D, Tan L, Broadley SA. Role of trigeminal microvascular decompression in the treatment of SUNCT and SUNA. *Current pain and headache reports*. 2013;17(5):332.

Silberstein SD, Dodick DW, Saper J, Huh B, Slavin KV, Sharan A, et al. Safety and efficacy of peripheral nerve stimulation of the occipital nerves for the management of chronic migraine: results from a randomized, multicenter, double-blinded, controlled study. *Cephalalgia : an international journal of headache*. 2012;32(16):1165-79.

Smelt AF, Assendelft WJ, Terwee CB, Ferrari MD, Blom JW. What is a clinically relevant change on the HIT-6 questionnaire? An estimation in a primary-care population of migraine patients. *Cephalalgia : an international journal of headache*. 2014;34(1):29-36.

Solomon GD. Evolution of the measurement of quality of life in migraine. *Neurology*. 1997;48(3 Suppl 3):10S-5S.

Williams MH, Broadley SA. SUNCT and SUNA: clinical features and medical treatment. *J Clin Neurosci*. 2008;15(5):526-34.

Zrinzo L, Foltynie T, Limousin P, Hariz MI. Reducing hemorrhagic complications in functional neurosurgery: a large case series and systematic literature review. *Journal of neurosurgery*. 2012;116(1):84-94.

Running Title: DBS SUNCT/SUNA

Zrinzo L, Yoshida F, Hariz MI, Thornton J, Foltynie T, Yousry TA, et al. Clinical safety of brain magnetic resonance imaging with implanted deep brain stimulation hardware: large case series and review of the literature. *World Neurosurg.* 2011;76(1-2):164-72; discussion 69-73.

| |
|--|
| <p>Short lasting unilateral neuralgiform headache attacks</p> <ul style="list-style-type: none"> • At least 20 attacks suffered • Moderate to severe unilateral head pain with trigeminal distribution, lasting 1-600 seconds and occurring as single stabs, series of stabs or in a saw-tooth pattern • At least one cranial autonomic symptom or sign ipsilateral to the pain: • Conjunctival injection and/or lacrimation <ol style="list-style-type: none"> 1. nasal congestion and/or lacrimation 2. eyelid oedema 3. facial sweating 4. facial flushing 5. fullness in the ear 6. ptosis and/or miosis • Attacks occur at least once a day for more than half the time the disorder is active |
| <p>Short lasting unilateral neuralgiform headache attacks with conjunctival injection and tearing</p> <ul style="list-style-type: none"> • As short lasting unilateral neuralgiform headache attacks • Autonomic symptoms of both conjunctival injection and lacrimation |
| <p>Short lasting unilateral neuralgiform headache attacks with autonomic features</p> <ul style="list-style-type: none"> • As short lasting unilateral neuralgiform headache attacks • Autonomic symptoms include only one of or neither of conjunctival injection and lacrimation |

Table 1: International Classification of Headache Disorders diagnostic criteria for short lasting unilateral neuralgiform headache attacks.

| | Age/ years | Sex | SUNCT/SUNA | Chronic duration | Side | Other Headaches | Attack Frequency/ Day | Average Attack duration | Triggered attacks/ Spontaneous attacks/Both* | MRI for neurovascular conflict** |
|-------------------------|---------------|----------|-------------------|---------------------|----------------------|--------------------|-----------------------------|-------------------------------|--|--|
| 1 | 56 | M | SUNCT | 14 | R | NIL | 20 | 5min | Spontaneous | NIL |
| 2 | 63 | M | SUNCT | 16 | R | NIL | 360 | 10 sec | Both-touch/wind | Right |
| 3 | 39 | M | SUNCT | 9 | R | CCH (R) CM | 20 | 15 sec | Spontaneous | NIL |
| 4 | 67 | M | SUNCT | 13 | L | CCH (L) | 40 | 10min | Spontaneous | NIL |
| 5 | 64 | F | SUNCT | 9 | R | NIL | 6 | 3min | Spontaneous | NIL |
| 6 | 55 | F | SUNCT | 20 | L | CM | 120 | 2 min | BOTH – touch/chewing/ wind | NIL |
| 7 | 41 | F | SUNCT | 4 | L 90% R 10% | NIL | 200 | 3 min | Spontaneous | NIL |
| 8 | 26 | F | SUNA | 8 | R | NIL | 800 | 2 sec | BOTH – talking/touch/ eating/wind | NIL |
| 9 | 50 | M | SUNCT | 6 | L 70% R 30% | CCH (L) | 3 | 5min | Spontaneous | NIL |
| 10 | 42 | M | SUNA | 19 | L 40% R 60% | CM | 95 | 2min | Spontaneous | NIL |
| 11 | 46 | M | SUNA | 9 | R | NIL | 45 | 30 sec | Spontaneous | Right |
| Median (IQR) | 50 (22) | 7M 3F | 8 SUNCT 3 SUNA | 9 (7) | 6 R 2 L 3L/R | 3 CCH 3 CM | 45 (20) | 2 min (5) | 8 Spontaneous 3 Both | 2 Ipsilateral neurovascular conflict |

Running Title: DBS SUNCT/SUNA

*In case of triggered attacks, typical triggers are listed

** Neurovascular conflict of trigeminal nerve at level of root entry zone seen on MRI

M, male; F, female; SUNCT, short lasting unilateral neuralgiform headache attacks with conjunctival injection and tearing; SUNA, short lasting unilateral neuralgiform headache attacks with autonomic features; R, right; L, left; L/R, left or right; CCH, chronic cluster headache; CM, chronic migraine; MO, medication overuse

Table 2: Patient demographics

| | Follow Up/ months | DAILY ATTACK FREQUENCY | | | ATTACK SEVERITY | | | HEADACHE LOAD | | | ATTACK DURATION (seconds) | | | Estimated Improvement [‡] | Patient recommend ^{‡‡} |
|---------------------|----------------------|------------------------|----------|----------|-----------------|----------|-----------|---------------|----------|----------|---------------------------|-----------|----------|------------------------------------|---------------------------------|
| | | Pre DBS | Post DBS | % Change | Pre DBS | Post DBS | % Change | Pre DBS | Post DBS | % Change | Pre DBS | Post DBS | % Change | | |
| 1 | 63 | 20 | 6 | 70 | 8 | 2 | 75 | 69 | 3 | 96 | 18000 | 30 | 99 | 95 | Yes |
| 2 | 40 | 360 | 0 | 100 | 7 | 0 | 100 | 14 | 0 | 100 | 10 | 0 | 100 | 100 | Yes |
| 3 | 33 | 10 | 0 | 100 | 10 | 0 | 100 | 7 | 0 | 100 | 15 | 0 | 100 | 100 | Yes |
| 4 | 41 | 40 | 2 | 95 | 7 | 7 | 0 | 94 | 1 | 99 | 36000 | 1 | 100 | 70 | Yes |
| 5 | 32 | 6 | 4 | 33 | 10 | 10 | 0 | 42 | 35 | 17 | 10800 | 7200 | 33 | 5 | Yes |
| 6 ≠ | 29 | 120 | 90 | 25 | 9 | 10 | 0 | 225 | 304 | 0 | 7200 | 7200 | 0 | 0 | Yes |
| 7 | 23 | 200 | 58 | 71 | 10 | 5 | 50 | 1400 | 304 | 78 | 10800 | 60 | 99 | 70 | Yes |
| 8 | 14 | 800 | 0 | 100 | 10 | 0 | 100 | 62 | 0 | 100 | 2 | 0 | 100 | 100 | Yes |
| 9 | 7 | 3 | 1 | 66 | 10 | 10 | 0 | 23 | 12 | 48 | 18000 | 18000 | 0 | 0 | Yes |
| 10 | 29 | 95 | 0 | 100 | 10 | 0 | 100 | 44 | 0 | 100 | 7200 | 0 | 100 | 100 | Yes |
| 11 | 28 | 45 | 5 | 89 | 8 | 8 | 0 | 56 | 12 | 79 | 2160 | 18000 | -7 | 58 | Yes |
| MEDIAN (IQR) | 29 (20) | 45 (20) | 2 (10) | 78* (33) | 10 (2) | 5 (10) | 50* (100) | 62 (202) | 3 (35) | 99* (52) | 7200 (17985) | 30 (7200) | 99 (100) | 70 (95) | |

*p<0.05

‡ Patient estimate of improvement at final follow-up

‡‡ Patient asked if they would recommend the procedure to another person with short lasting unilateral neuralgiform headache attacks

≠ Deep brain stimulation system removed at time of follow-up

DBS, Deep brain stimulation

Table 3: Headache characteristics before and after treatment

The average daily attack frequency and severity is listed before and after treatment. Headache load, a composite score reflecting attack frequency, severity and duration is also shown. Patient satisfaction is shown using their estimated level of improvement and their recommendation of treatment to other patients.

| | Pre-DBS Median (IQR) | Post-DBS Median (IQR) | Median % Change % (IQR) | P-value |
|-----------------------|---------------------------------|----------------------------------|------------------------------------|----------------|
| MIDAS | 81 (254) | 65 (12) | 0 (63) | 0.678 |
| HIT-6 | 70 (12) | 65 (14) | 8 (19) | 0.015* |
| HAD-A | 12 (11) | 8 (13) | 17 (28) | 0.035* |
| HAD-D | 12 (8) | 11 (10) | 0 (42) | 0.721 |
| BDI-II | 23 (23) | 16 (29) | 0 (24) | 0.929 |
| SF-36 Physical | 23 (26) | 29 (18) | 0 (24) | 0.594 |
| SF-36 Mental | 30 (27) | 46 (27) | 23 (39) | 0.208 |
| Euro-QoL | 0.63 (0.18) | 0.64 (0.18) | 0 (1.0) | 0.208 |
| Euro-Scale | 30 (50) | 32 (50) | 0 (45) | 0.483 |

Table 4: Headache specific disability, affect and quality of life score changes with deep brain stimulation

IQR, Interquartile range; MIDAS, Migraine Disability Assessment Scale; HIT-6, Headache Impact Test; HAD-A, Hospital Anxiety and Depression scores-anxiety specific; HAD-D, Hospital Anxiety and Depression scores – depression specific; BDI-II, Becks Depression Inventory; SF-36, Short Form 36.

| Adverse Event (n) | Resolution (surgical/medical/spontaneous/no intervention) |
|---|--|
| Hardware Related | |
| IPG “flips” or moves in chest skin pocket (1) | Surgical intervention – repositioning of IPG |
| Biological | |
| Neck stiffness (3) | No intervention |
| Pain over wound site (2) | No intervention |
| Keloid scar over IPG site (1) | No intervention |
| Wound infection (1) | Surgical intervention – removal of system |
| Wound dehiscence, no infection (1) | Medical |
| Stimulation Related | |
| Diplopia, nausea, vertigo, ophthalmoplegia with changes of programming (11) | Spontaneous |
| Possible worsening of nausea (1) | Medical – DBS switched off with no change in symptoms. <i>Decision made symptoms not related to DBS</i> |
| Oscillopsia when reading (1) | Spontaneous resolution after 6 weeks |
| | TOTAL SURGICAL INTERVENTIONS = 2 |

IPG, implantable pulse generator; DBS, deep brain stimulation

Table 5: Adverse events related to deep brain stimulation

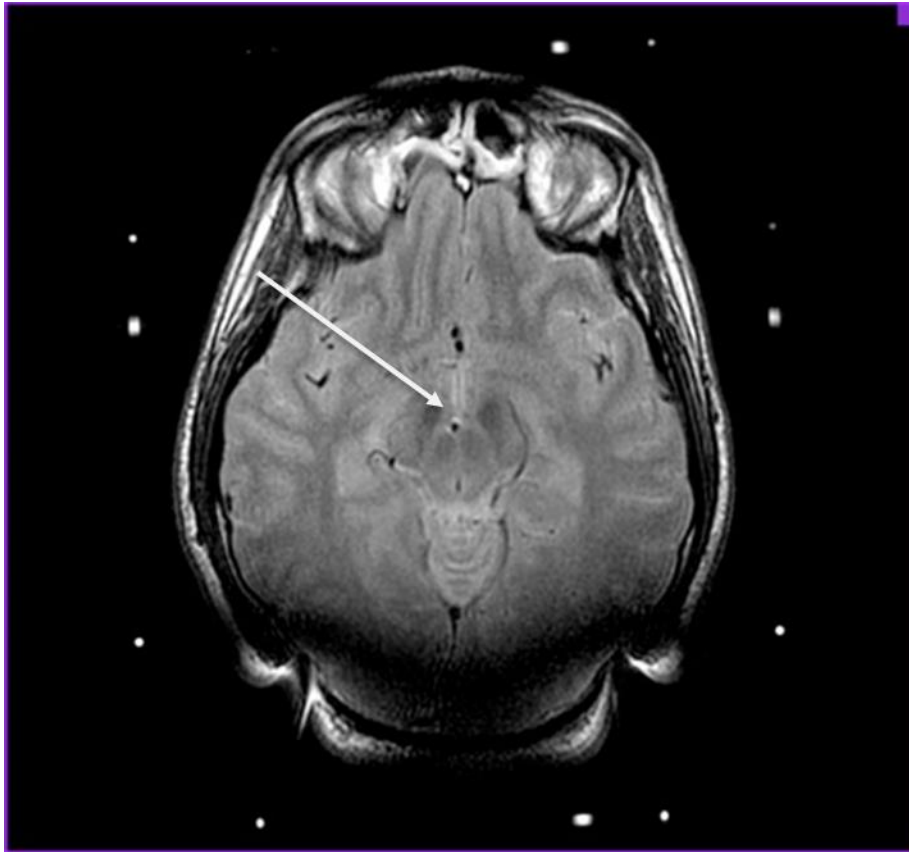
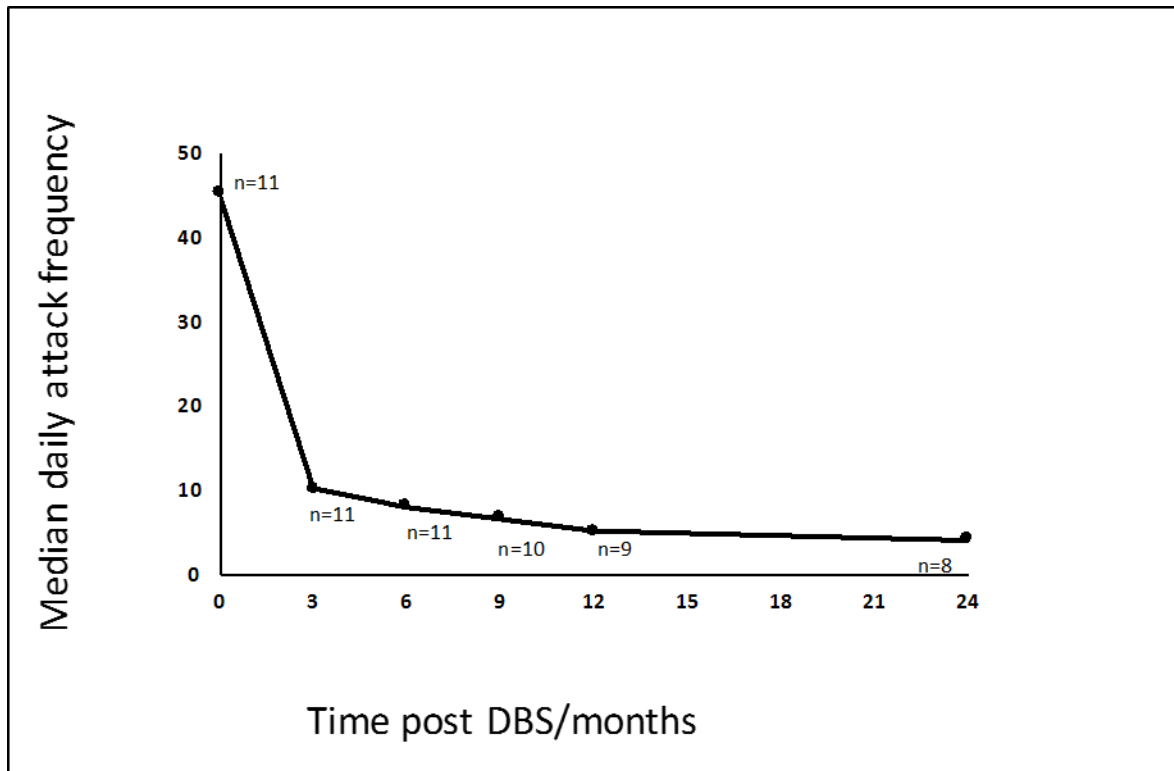


Figure 1: 1.5T MRI scan showing DBS lead placement

Post-operative 1.5T T2-weighted, 2mm-thick, axial stereotactic MRI immediately after implant shows the DBS lead positioned in the right ventral tegmental area of the midbrain (white arrow)



DBS, deep brain stimulation

Figure 2: Reduction in daily attack frequency following deep brain stimulation

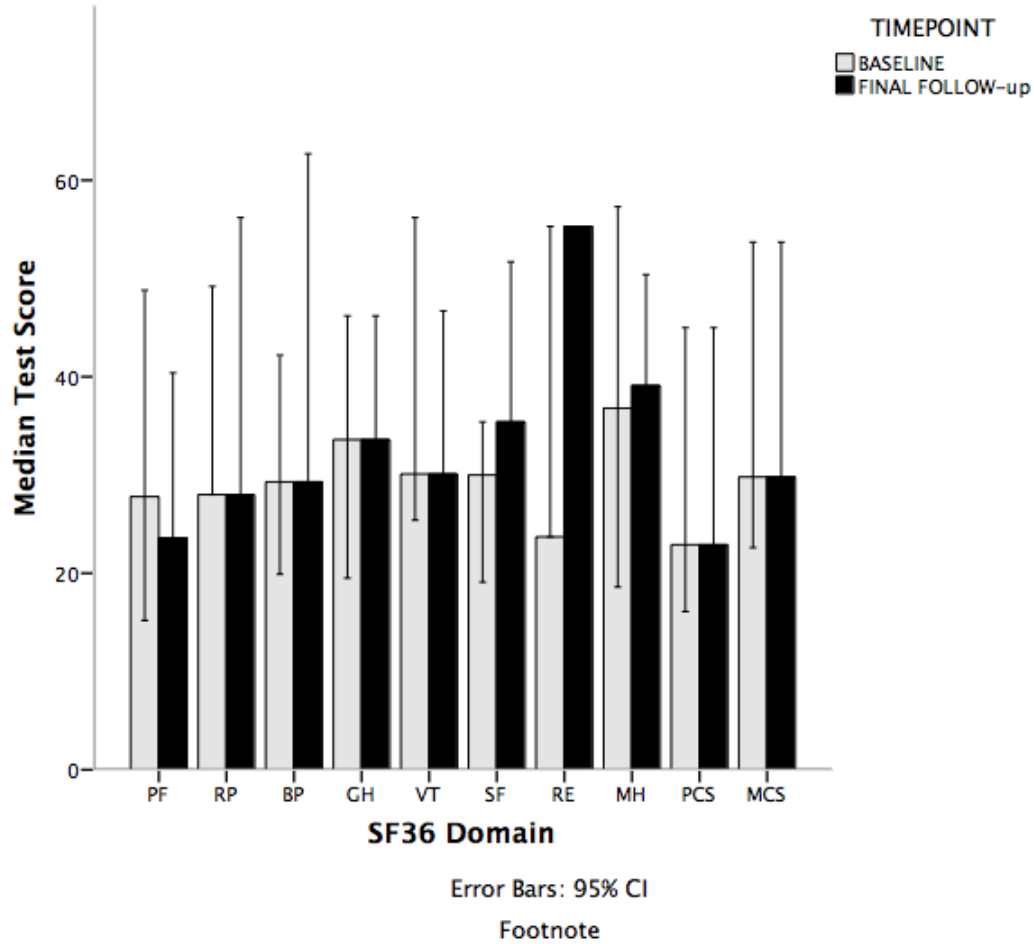


Figure 3: SF36 domain scores pre and post-DBS PF, physical functioning; RP, role-physical; BP, bodily pain; GH, general health; VT, vitality; SF, social functioning; RE, role-emotional; MH, mental health; PCS, physical composite score; MCS, mental health composite score

| | Lamotrigine | Topiramate | Gabapentin | Pregabalin | Carbamazepine | Oxcarbazepine | Other |
|-----------|-------------|------------|------------|------------|---------------|---------------|--|
| 1 | 600mg | 350mg | 3600mg | 600mg | 1600mg | NT | <i>Melatonin Indometacin</i> |
| 2 | 400mg | 400mg | DUK | DUK | 800 | 300 | <i>Melatonin, Baclofen, Phenytoin</i> |
| 3 | 600mg | 1000mg | 3600mg | 600mg | DUK | NT | <i>Duloxetine, Melatonin, Venlafaxine</i> |
| 4 | 200mg | 200mg | 3600mg | 300mg | NT | 1500mg | <i>Duloxetine, Melatonin</i> |
| 5 | 600mg | 400mg | DUK | DUK | 900mg | 300mg | <i>Duloxetine, Mexiletine, Melatonin, ONS</i> |
| 6 | 200mg | 450mg | 2400mg | 50mg | 1200mg | 1200mg | <i>Duloxetine, Lacosamide, Phenytoin, Baclofen, Zonisamide</i> |
| 7 | 400mg | 300mg | 2700mg | 300mg | DUK | 2400mg | <i>Duloxetine, Indometacin</i> |
| 8 | 1200mg | 400mg | 1800mg | 300mg | 1200mg | 1200mg | <i>Duloxetine, Baclofen, Lacosamide, VNS</i> |
| 9 | 400mg | 200mg | 600mg | 600mg | NT | NT | |
| 10 | 400mg | 200mg | 900mg | 600mg | DUK | 2100mg | <i>Duloxetine, Mexiletine, Lacosamide, Ketamine</i> |
| 11 | 200mg | 25mg | 300mg | 1200mg | NT | 1500mg | <i>Duloxetine, Indometacin</i> |

NT, drug not tried; DUK, dose unknown; ONS, occipital nerve stimulation; VNS, non-invasive vagal nerve stimulation (GammaCore)

Supplementary Table 1: Preventative medications previously tried by patients undergoing deep brain stimulation

Table Legend: The daily dose of the preventative medications with stated efficacy in short lasting unilateral neuralgiform headache attacks taken by each patient prior to undergoing deep brain stimulation. A list of additional medications trialled for the condition is also shown.

| | Lidocaine Infusion (7-10 days) | | | Greater Occipital Nerve Injection (lidocaine and steroid) | | |
|----|--------------------------------|----------------------|--------------------------------|---|-------------------|-----------------------------|
| | Response* | Number of treatments | Duration of response (days) | Response** | Side of injection | Duration of response (days) |
| 1 | Yes | 1 | 10 days | No | Right | 3 days |
| 2 | Yes | 1 | On infusion only ⁺⁺ | No | Right | 0 days |
| 3 | Yes | 1 | On infusion only ⁺⁺ | No | Right | 0 days |
| 4 | Yes | 1 | On infusion only ⁺⁺ | No | Left | 0 days |
| 5 | Yes | 2 | On infusion only ⁺⁺ | No | Right | 0 days |
| 6 | No | 1 | Nil | No | Left | 0 days |
| 7 | Yes | 7 | 1 month | No | Left | 0 days |
| 8 | Yes | 1 | On infusion only ⁺⁺ | No | Right | 0 days |
| 9 | N/A | - | - | No | Bilateral | 0 days |
| 10 | Yes | 4 | 10 days | Yes | Bilateral | 2 weeks |
| 11 | Yes | 2 | Infusion only ⁺⁺ | No | Bilateral | 5 days |

*Response defined by at least 50% reduction in daily attack frequency

** Response defined by at least a 50% reduction in attack frequency for at least one week post procedure

⁺⁺ Patient reported response only during time on treatment and which stopped as soon as infusion ended

N/A, patient not tried treatment

Supplementary table 2: Injectable transitional treatments given for short lasting unilateral neuralgiform headache attacks prior to deep brain stimulation.

| | Medication Prior to DBS | Medication Post DBS | Reduction in Dose |
|-----------|--|--|-----------------------------|
| 1 | Pregabalin 600mg Lamotrigine 600mg | Pregabalin 600mg Lamotrigine 600mg | No No |
| 2 | Lamotrigine 700mg Carbamazepine 800mg | Lamotrigine 400mg Oxcarbazepine 300mg | Yes Yes (relative doses) |
| 3 | Lamotrigine 600mg | Nil | Yes |
| 4 | Nil | Nil | N/A |
| 5 | Lamotrigine 600mg Topiramate 400mg | Lamotrigine 600mg Lacosamide 50mg | No No |
| 6 | Zonisamide 100mg Lamotrigine 200mg | Zonisamide 100mg Lamotrigine 200mg | No No |
| 7 | Oxcarbazepine 1800mg Topiramate 300mg | Nil | Yes Yes |
| 8 | Lamotrigine 600mg Lacosamide 300mg | Lamotrigine 600mg Lacosamide 300mg | No No |
| 9 | Lamotrigine 400mg | Nil | Yes |
| 10 | Topiramate 200mg | Nil | Yes |
| 11 | Nil | Nil | N/A |

DBS, deep brain stimulation; N/A, not applicable as patient not on medication

Supplementary table 3: Summary of changes in preventative medications following deep brain stimulation

| | Implant Location | Amplitude Range (V) | Frequency (Hertz) | Pulse width (μs) | Contact points settings* |
|---------------------|----------------------------------|---------------------|-------------------|------------------|---|
| 1 | Right | 1.3-3.0 | 185 | 60 | C+/1- |
| 2 | Right | 1.5-3.0 | 185 | 60 | C+/1- |
| 3 | Right | 2.4-3.0 | 185 | 60 | C+/0-, C+/0-1- |
| 4 | Left | 1.3-3.5 | 185 | 60 | C+/1-, C+/1-2- |
| 5 | Right | 0-2.6 | 185 | 60 | C+/0-, C+/1- |
| 6 | Left | 0.0-3.0 | 185 | 60 | C+/0-, C+/0-1- |
| 7 | Bilateral | 2.2-3.0 | 185 | 60 | C+/1-, C+/0-1- |
| 8 | Right | 3.0-3.5 | 185 | 60 | C+1-, C+/0-1- |
| 9 | Bilateral | 3.0 | 185 | 60 | Left: C+/0-, C+/1-, C+/0-1- |
| 10 | Bilateral | 3.0-3.5 | 185 | 60 | Left: C+/0-, C+/0-1- Right: C+/9-, C+/8-9- |
| 11 | Right | 1.5-2.8 | 185 | 60 | C+/1-, C+/0- |
| Median (IQR) | 6 Right 2 Left 3 Bilateral | 1.5 (2.7)-3 (0.5) | 185 | 60 | |

*Lead set as cathode and contact point as anode

Supplementary Table 4: Summary of deep brain stimulator settings for each patient