



Special issue: Research report

Ownership illusions in patients with body delusions: Different neural profiles of visual capture and disownership



Olivier Martinaud ^{a,b,1}, Sahba Besharati ^{b,c,1,2}, Paul M. Jenkinson ^d and Aikaterini Fotopoulou ^{b,*}

^a Department of Neurology, Rouen University Hospital, France

^b Clinical, Educational & Health Psychology Research Department, Division of Psychology & Language Sciences, University College London, UK

^c Academic Unit of Neuropsychiatry, King's College London, UK

^d School of Life and Medical Sciences, University of Hertfordshire, UK

ARTICLE INFO

Article history:

Received 9 April 2016

Reviewed 24 May 2016

Revised 22 July 2016

Accepted 25 September 2016

Published online 19 October 2016

Keywords:

Anosognosia for hemiplegia

Asomatognosia

Motor awareness

Sense of body ownership

Rubber hand illusion

Visual capture

Interoception

Proprioception

Insula

Premotor cortex

ABSTRACT

The various neurocognitive processes contributing to the sense of body ownership have been investigated extensively in healthy participants, but studies in neurological patients can shed unique light into such phenomena. Here, we aimed to investigate whether visual capture by a fake hand (without any synchronous or asynchronous tactile stimulation) affects body ownership in a group of hemiplegic patients with or without disturbed sensation of limb ownership (DSO) following damage to the right hemisphere. We recruited 31 consecutive patients, including seven patients with DSO. The majority of our patients (64.5% overall and up to 86% of the patients with DSO) experienced strong feelings of ownership over a rubber hand within 15 sec following mere visual exposure, which correlated with the degree of proprioceptive deficits across groups and in the DSO group. Using voxel-based lesion-symptom mapping analysis, we were able to identify lesions associated with this pathological visual capture effect in a selective fronto-parietal network, including significant voxels ($p < .05$) in the frontal operculum and the inferior frontal gyrus. By contrast, lesions associated with DSO involved more posterior lesions, including the right temporoparietal junction and a large area of the supramarginal gyrus, and to a lesser degree the middle frontal gyrus. Thus, this study suggests that our sense of ownership includes dissociable mechanisms of multisensory integration.

© 2016 The Authors. Published by Elsevier Ltd. This is an open access article under the CC BY-NC-ND license (<http://creativecommons.org/licenses/by-nc-nd/4.0/>).

* Corresponding author. Clinical, Educational and Health Psychology Research Department, 1-19 Torrington Place, London, WC1E 7HJ, UK.

E-mail address: a.fotopoulou@ucl.ac.uk (A. Fotopoulou).

¹ Joint first authors.

² Now at Department of Psychology, University of Cape Town, South Africa.

<http://dx.doi.org/10.1016/j.cortex.2016.09.025>

0010-9452/© 2016 The Authors. Published by Elsevier Ltd. This is an open access article under the CC BY-NC-ND license (<http://creativecommons.org/licenses/by-nc-nd/4.0/>).

1. Introduction

The term confabulation typically refers to the production of false memories in the context of neurological pathology. However, it has also been used more broadly to describe the production of unintentionally false statements about one's self or the world, beyond the domain of memory (DeLuca, 2000; Feinberg & Roane, 1997; Hirstein, 2005). In this broader sense, a clear conceptual distinction between confabulation, delusion and anosognosia (unawareness of illness) becomes harder. While maintaining these separate terms therefore has conceptual advantages (Kopelman, 1999), considering confabulation in parallel to other similar symptoms allows for cross-fertilisation between studies on such phenomena (see Fotopoulou, 2010; Hirstein, 2005; Langdon & Turner, 2010).

In the present article, we focus on certain 'somatic delusions', as they typically occur following right hemisphere stroke. First, patients may show 'disturbed sensation of limb ownership' (DSO; Baier & Karnath, 2008), including 'asomatognosia', when ownership, or even the existence of a limb is denied. Some patients further present with a positive (in the Jacksonian sense; 1932) variant termed somatoparaphrenia, whereby disownership is accompanied by delusional beliefs, such as personification of the affected limb and/or attributing it to someone else (Gerstmann, 1942; see also Feinberg & Venneri, 2014; Vallar & Ronchi, 2009, for reviews). Furthermore, DSO can co-occur with an apparent inability to acknowledge or recognise one's contralesional paralysis, so-called anosognosia for hemiplegia (AHP; Babinski, 1914; see Fotopoulou, 2014, 2015 for reviews). Whether anosognosia and body ownership disturbances are caused by common underlying neural and psychological deficits or whether they represent independent disorders, remains debated (e.g., compare Baier & Karnath, 2008 and Gandola et al., 2012).

Importantly, these disorders offer a unique window of insight into the neurophysiological mechanisms by which the body is consciously experienced (body awareness). These mechanisms have received significant scientific interest in recent decades, including the development of several psychophysical and virtual reality paradigms that can generate subjective, somatic illusions in healthy volunteers (see Kilteni, Maselli, Kording, & Slater, 2015 for a review). For instance, pioneering work on illusory ownership of a fake hand, i.e., the rubber-hand illusion (RHI; Botvinik & Cohen, 1998), has emphasised the contribution of multisensory integration, i.e., the integration of sensory signals from different modalities, to the sense of body ownership (Holmes & Spence, 2005; Stein & Stanford, 2008).

Vision has been one of the most studied modalities in this paradigm (Kilteni et al., 2015), however, these effects tend to be considered in the context of visuo-tactile integration. Only a few RHI studies have measured subjective feelings of hand ownership following mere visual exposure to a fake hand, i.e., independently of tactile manipulations. Some of these studies reported no effects (e.g., Longo, Schüür, Kammers, Tsakiris, & Haggard, 2008; see also Rohde, Di Luca, & Ernst, 2011 for anecdotal evidence), while others found that 'mere vision'

conditions can change feelings of ownership for the fake hand (Pavani, Spence, & Driver, 2000; Farnè, Pavani, Meneghello, & Ladavas, 2000; Guimmarra, Georgiou-Karistianis, Nicholls, Gibson, & Bradshaw, 2010; Tieri, Tidoni, Pavone, & Aglioti, 2015a, 2015b). It should be stressed that the conclusions of these studies are based on mere 'visual' conditions, rather than on negative findings from the comparison of synchronous versus asynchronous tactile stimulation; a comparison whose interpretation seems more complex than initially thought (e.g., Rohde et al., 2011). Moreover, while it is well-established that under certain circumstances, conflicting visual feedback from fake, or virtual, or visually misplaced hands via mirrors and wedge prisms (see Holmes & Spence, 2006 for review), can override proprioception (the so-called visual capture of proprioception), recent studies have established that position sense recalibrations can be dissociated from the sense of body ownership during the RHI (Abdulkarim & Ehrsson, 2016; Rohde et al., 2011; see also Makin, Holmes, & Ehrsson, 2008 for an early review). Thus, the relation between visual capture of proprioception and subjective ownership feelings remains unclear during 'mere vision' conditions. We will heuristically call this possibility, 'visual capture of ownership' (hereafter referred to as VOC; 'visual ownership capture' for brevity).

To this end, the present study will focus on VOC by a fake hand (independently of any synchronous or asynchronous tactile stimulation). To the best of our knowledge, the neural mechanisms of VOC remain unexplored in healthy participants, as existing functional neuroimaging studies have not included 'mere vision' conditions (see Makin et al., 2008; Tsakiris, 2010 for reviews). Moreover, such functional neuroimaging studies can only establish correlations, while studies in brain damaged patients can be informative regarding the causal role of some brain areas and their connections. Unfortunately, the relation between experimentally-induced conditions of VOC and neuropsychological DSO has not been systematically explored. Moreover, comparisons between the few existing studies are hindered by the vast differences in the conceptualisation and measurement of the observed phenomena.

Indeed, in a series of studies, Berti and her colleagues, have proposed that some right hemisphere patients show what they describe as 'a monothematic delusion of body ownership', which relies on observing another person's hand in one's contralesional (affected) side and in egocentric, body-congruent perspective (Garbarini et al., 2013, 2014). However, the phenomenon may be more general and complex than these studies suggest. In a previous study involving eight hemiplegic patients with right hemisphere lesions, including one patient with DSO (Fotopoulou et al., 2008), all patients immediately accepted as their own a stationary rubber hand placed congruently with their own left hand. Thus, VOC may be a pervasive phenomenon following right hemisphere damage and it may also be dissociable from DSO (see also Zeller, Gross, Bartsch, Johansen-Berg, & Classen, 2011; Jenkinson, Haggard, Ferreira, & Fotopoulou, 2013; Bolognini, Ronchi, Casati, Fortis, & Vallar, 2014 for further dissociations between DSO and the classic RHI). Indeed, this possibility is supported by the only case study in the literature that applied

the classic RHI paradigm to the affected (left) hand of a patient with DSO following damage to the right-hemisphere (van Stralen, van Zandvoort, Kappelle, & Dijkerman, 2013). Even though a ‘mere vision’ condition was not tested, the patient experienced feelings of ownership over the affected hand, in conditions of both synchronous and asynchronous tactile stimulation.

Importantly, this possibility raises a paradox, which to our knowledge has not been addressed in the literature: if patients with DSO are willing to accept as theirs a realistic hand that is visually presented in a congruent position as their own hand, why do they deny the ownership of their own hand when viewed under similar conditions? Such results could only be explained if some other bottom-up deficits (e.g., hypoesthesia), or damage to top-down mechanisms that would normally allow the integration of such signals with pre-existing models of the body (see Tsakiris, 2010), prevented the patient's own hand from being recognised as one's own.

Although we could not quantify and examine all these possibilities in the present study, our main aim was to systematically assess for the first time whether patients with right-hemisphere damage and DSO show VOC by a fake hand (without any synchronous or asynchronous tactile stimulation). To this end, we recruited 31 patients with recent right-hemisphere strokes, including seven patients with DSO. Furthermore, using lesion mapping procedures (i.e., the voxel-based lesion-symptom mapping (VLSM) approach; Bates et al., 2003), we examined the lesions associated with (1) VOC versus failure of VOC and (2) proprioceptive deficits in our sample, as a way to characterise the relation between such deficits, own hand ownership and rubber hand ownership.

Based on previous case reports (Fotopoulou et al., 2008; van Stralen et al., 2013), we expected that (1) visual capture would elicit ownership of the rubber hand in the majority of our patients (irrespective of diagnostic group) and particularly those with greater proprioceptive deficits. As far as neural mechanisms are concerned, we expected: (a) proprioceptive deficits to be associated with lesions in primary somatosensory areas in the parietal cortex; (b) VOC to be associated with the involvement of further, multi-modal areas in the posterior parietal cortex and mostly in the ventral premotor cortex and the posterior insular cortex, as these brain regions have been linked to ownership feelings of fake hands in previous functional imaging studies on the RHI (Ehrsson, Spence, & Passingham, 2004; Tsakiris, Hesse, Boy, Haggard, & Fink, 2007); (c) By contrast, failures of VOC should be associated with sparing of such cortical areas (see also Zeller et al., 2011 who only found lesions in the white matter connections of this area), in the sense that these patients would show either less proprioceptive deficits, and/or greater monitoring of proprioceptive errors during multisensory integration conditions. Finally, (d) DSO was expected to be selectively associated, with additional cortical lesions to the parietal cortex, such as the temporoparietal junction (TPJ) that can be linked with ‘filtering’ signals from the body in relation to pre-existing body models (Tsakiris, 2010).

2. Materials and methods

2.1. Participants

Thirty-one patients with right hemisphere lesions due to an ischaemic or haemorrhagic stroke were consecutively recruited from three acute stroke units in London, UK, using the following criteria: (1) unilateral right-hemisphere lesion as confirmed by clinical neuroimaging (CT or MRI), (2) contralateral hemiplegia, (3) <4 months from symptom onset, (4) no previous history of neurological or psychiatric illness, (5) >7 years of education, (6) no medication with severe cognitive or mood side-effects, (7) no severe language impairment that precluded completion of the study assessments; (8) willingness and availability to participate in the study.

DSO were evaluated using a modified version of the Cutting questionnaire (Cutting, 1978). The assessment began by distracting the patient, placing their left arm in their right visual field and asking “What is this?”, “Is this your hand?” and “Does it feel like it belongs to you?”. If the patient denied ownership of the arm, they were then asked, “Does it feel like it belongs to anyone else?” and “Anyone in particular?”. The questionnaire was scored on a 3-point scale (2 = asomatognosia and/or somatoparaphrenia; 1 = partial acknowledgment of body ownership; 0 = full acknowledgment). Patients with a score of 2 on the modified Cutting questionnaire were categorised as DSO.

Patients were examined for AHP via a method previously described (Besharati et al., 2014; Fotopoulou et al., 2008), based on the Berti interview (Berti, Ladavas, & Della Corte, 1996) and the Feinberg scale (Feinberg, Roane, & Ali, 2000). The Berti interview, which includes specific questions regarding motor ability (e.g., “Can you move your left arm?”) and ‘confrontation’ questions (e.g., “Please touch my hand with your left hand; have you done it?”), is scored on a 3-point scale (2 = denial of motor impairment and failure to reach examiner hand; 1 = denial of motor impairment but admits failure to reach examiner hand; 0 = full acknowledgment of motor impairment). The Feinberg scale, used as a secondary measure of awareness, consists of 10 items including general self-report items (e.g., “Do you have any weakness anywhere?”) and task-related items (e.g., “Please try and move your left arm for me; did you move it”). Each item was scored on a 3-point scale (1 = complete unawareness; .5 = partially unaware; 0 = completely aware) to produce an overall score out of 10 (10 = completely unaware; 0 = completely aware). Patients scoring 1 or 2 on the Berti interview and at least 4 on the Feinberg scale were categorised as AHP. DSO and AHP assessments were conducted during the general clinical and cognitive assessment (see below) and directly before the experimental testing to make certain the clinical phenomena were present during the experimental assessment.

Using these methods, we identified seven right brain injured patients with AHP and DSO (AHP + DSO group; 4 women; mean age \pm SD: 67.6 \pm 12.5 years, range 41–78; mean education \pm SD: 11.7 \pm 1.9 years, range 9–14; mean lesion – test interval \pm SD: 7.4 \pm 5.6 days, range 1–16), nine right brain injured patients with AHP, but without DSO (AHP group; 6 women; mean age \pm SD: 70.6 \pm 16.5 years, range 36–88; mean

education \pm SD: 11.8 \pm 2.2 years, range 9–15; mean lesion – test interval \pm SD: 14.7 \pm 11.6 days, range 4–35), and fifteen right brain injured control patients without AHP or DSO (HP group; 6 women; mean age \pm SD: 66.9 \pm 13.1 years, range 47–88; mean education \pm SD: 12.6 \pm 2.6 years, range 9–18; mean lesion – test interval \pm SD: 17.5 \pm 14.1 days, range 3–42). All patients were right handed according to the Edinburgh inventory (Oldfield, 1971), except one ambidextrous control patient. All participants provided written informed consent and the study was approved by the local NHS Ethics committee.

2.2. Clinical and cognitive assessment

In addition to the DSO and AHP scales, each patient underwent a standard neurological and neuropsychological examination. Motor deficits of the upper and the lower limbs were assessed using the Medical Research Council scale (MRC; Guarantors of Brain, 1986). Proprioception was assessed with eyes closed by applying a small vertical movement to three joints (middle finger, wrist and elbow), at three time intervals, according to a method previously described (Vocat, Staub, Stroppini, & Vuilleumier, 2010), scored on a 10-point scale (0 = severe proprioceptive deficit; 9 = no deficit). The customary ‘confrontation’ technique (Bisiach, Vallar, Perani, Papagno, & Berti, 1986) was administered to test visual fields (upper and lower quadrants) and tactile extinction (upper and lower limbs).

Patients were also assessed using the following standardised tests: (a) the Mini Mental State Examination (MMSE; Folstein, Folstein, & McHugh, 1975) and the Montreal Cognitive Assessment (MoCA; Nasreddine et al., 2005) as a measure of global intellectual ability, as well as the Wechsler Test of Adult Reading (Wechsler, 2001) as a measure of premorbid intelligence; (b) the 5-item test from the MoCA (Nasreddine et al., 2005) to assess long-term verbal recall and the verbal digit-span task from the Wechsler Adult Intelligence Scale III (Wechsler, 1998) to assess verbal working memory; (c) five subtests of the Behavioural Inattention Test (BIT; Wilson, Cockburn, & Halligan, 1987; star cancellation, line bisection, line crossing, copy, and representational drawing of the clock) as a measure of visuospatial neglect, as well as the ‘One-item test’ (Bisiach et al., 1986) and the ‘Comb/razor test’ (McIntosh, Brodie, Beschin, & Roberston, 2000) to assess personal neglect; (d) a clinical assessment of left/right disorientation was additionally conducted; (e) the Frontal Assessment Battery (FAB; Dubois, Slachevsky, Litvan, & Pillon, 2000) and the Cognitive Estimates test (Shallice & Evans, 1978) to assess executive and reasoning abilities; and (f) the Hospital Anxiety and Depression Scale (HADS; Zigmond & Snaith, 1983) to assess anxiety and depression.

2.3. Experimental study design

The main experiment assessed whether visual capture of a visible, motionless rubber hand influenced body ownership (VOC) in three groups of patients: AHP versus AHP + DSO versus HP. There were two rubber hand ownership questions: “Is this [pointing to the rubber hand] your left hand?” (YES/NO response) and “To what extent do you feel this is your left hand?”

(scale out of 10; not at all = 0, completely = 10). The YES/NO ownership answers were analysed qualitatively only, while the ownership answers based on the scale were used as our primary dependent variable VOC and analysed quantitatively in both behavioural and lesion comparisons. Subsequently, to test the strength of the effect, patients were instructed to try to move their left hand and we provided congruent visual feedback of rubber hand movement by moving it according to the instruction (as in Fotopoulou et al., 2008). The same two rubber hand ownership questions were repeated and an ‘Ownership Change’ score was calculated as the difference between the ownership scores before and after the movement of the rubber hand by the experimenter.

2.4. Materials and procedure

A life-sized rubber model of a left hand was used to create visual capture. A suitable rubber hand was selected for each patient in order to resemble their own real hand in terms of size, shape, and skin tone. The procedure of the experiment was similar to the one used by Fotopoulou et al. (2008) as follows. Patients were tested on the stroke ward while sitting upright in their bed or a comfortable chair. At the beginning of the experiment, the main experimenter distracted the patient's attention with general questions (e.g., about past history), and an assisting experimenter sat to the left and slightly behind the patient, holding the proximal end of the rubber hand covered by a pillow. While the patient was distracted, the assisting experimenter placed the rubber hand on a second pillow in front of the patient close to their midline, such that the distal end of the rubber hand could be seen protruding from in between the two pillows, in a natural (canonical) position and orientation (Fig. 1). The patient's own left hand was positioned out of sight beneath the pillow and the rubber hand, also at the patient's midline (i.e., at the same orientation as the rubber hand). Once the rubber hand was in position, the main experimenter instructed the patient to look at the hand (i.e., the rubber hand) in front of them for 15 sec and then tested for ownership of the rubber hand as described above (i.e., visual capture effect). Any spontaneous comments or relevant behaviours were noted by the examiner.

In the movement condition, the main experimenter asked the patient to slightly raise his/her left hand immediately following a tap on a table in front of them, and the assisting experimenter lifted the rubber hand accordingly. Immediately after the visual feedback of movement, patients had to answer the rubber hand ownership questions described above, as well as a question serving as a manipulation check, namely a movement detection question (“Did the arm move?” YES/NO response). Owing to paralysis (see inclusion criteria), there was of course no movement of the patient's actual left hand in any conditions. After the experiment, patients were debriefed to explain the aim of the experiment and any questions were addressed.

2.5. Statistical analysis

All analyses were conducted using STATISTICA 7.1 software. Preliminary checks via visual inspection of histograms and

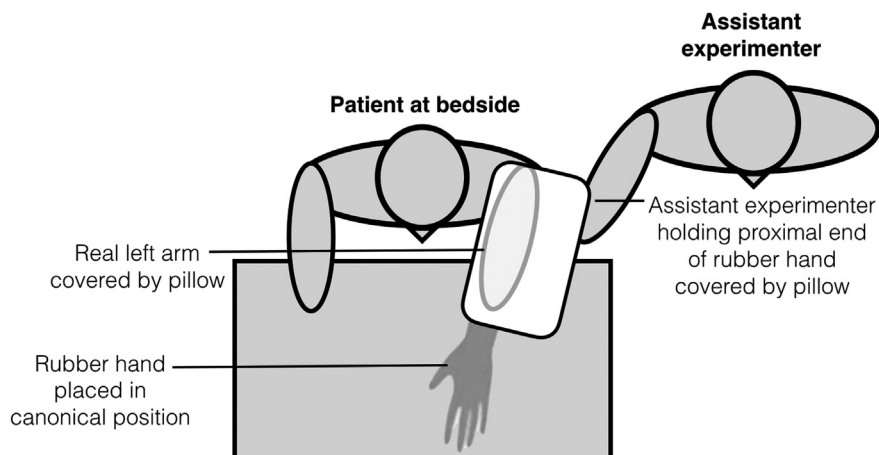


Fig. 1 – Schematic representation of experimental set-up. The patient was tested at the bedside, with the assistant experimenter sitting to the left and slightly behind the patient. The experimenter distracted the patient by asking a series of general questions (e.g., about past history), while the assistant experimenter (1) positioned the patients real left hand out of sight beneath a pillow; and (2) placed the rubber hand beneath a second pillow, so that the distal end of the rubber hand could be seen protruding from the pillow. The assistant experimenter held the proximal end of the rubber hand covered by the pillow, allowing them to move the rubber hand when necessary.

the Shapiro–Wilk tests indicated that the data were not normally distributed in the majority of cases ($p < .05$). Therefore, we performed group analyses on the epidemiologic data, standardised neuropsychological tests, the experimental measures of VOC, and a correlational analysis based on our prediction regarding the relation between VOC and proprioceptive deficits, using non-parametric tests and corrections for multiple comparisons, as appropriate (detailed below).

2.6. Lesion analysis methods

The location and extent of brain lesions was mapped in each patient, based on a CT-scan (or a 1.5T MRI-scan for 5 patients) obtained within the first week of admission. The scans of three hemiplegic patients (in the HP group) were unavailable and these patients were therefore excluded from further imaging analyses. The native structural scan of each patient was not normalised, but reoriented and aligned to match the stereotaxic space of the T1-weighted MRI scan template from the MNI (Montreal Neurological Institute), provided within the MRICron software (<http://www.mccauslandcenter.sc.edu/mricro/mricron/>; Rorden & Brett, 2000). The quality of normalisation when working with a sample such as ours of elderly stroke patients presents a range of problems (e.g., larger ventricles) and can greatly disrupt the normalisation process leading to inaccurate spatial normalisation (Brett, Leff, Rorden, & Ashburner, 2001; Rorden & Karnath, 2004). Although techniques have been introduced to help improve the accuracy of automated spatial normalisation of individuals with brain injury (see Brett et al., 2001), the quality and accuracy of the normalisation is still compromised, with the lesion location often shifting during the normalisation process. Therefore,

manual lesion demarcation using a normalised brain template is often considered as the preferred method, as it more accurately identifies the lesion location, especially in cases of older patients with brain injury (Rorden & Karnath, 2004). Thus, all the lesions were drawn onto the MNI template, whilst using all available scans to guide the delineation, by a researcher (SB) who was blind to the patient grouping and hypothesis of the study. Percentage lesion overlay maps for the three groups, AHP, AHP + DSO, and HP, were computed and lesion volume was obtained.

The VLSM approach (Bates et al., 2003) identifies voxels significantly associated with a cognitive deficit in a group of patients, and involves running a t-test for continuous data, comparing patients' scores on a neuropsychological test in those patients with versus without a lesion at every voxel. This technique as implemented in the software package NPM (non-parametric mapping; <http://www.mccauslandcenter.sc.edu/mricro/npm/>; Rorden, Karnath, & Bonilha, 2007) was used to identify anatomical regions associated with (1) the baseline sense of body ownership using a binomial classification (0 = DSO, 1 = normal) based on the Cutting questionnaire (Cutting, 1978) $N = 28$; (2) Proprioceptive deficits, using the scale out of 9, in the three groups ($N = 28$); (3) Visual Capture of Ownership, using the 11-point scale, in the three groups ($N = 28$); (4) Failures in the Visual Capture of Ownership using the reversed 11-point scale in the three groups ($N = 28$). The analyses were restricted to the voxels in which at least two patients had lesions (8% and 13% of the sample, respectively). Owing to the relatively small sample size, results were calculated with the permuted non-parametric Brunel–Menzel test to correct for multiple comparison and small sample size (Rorden et al., 2007). Permutation testing is appropriate here because it preserves power, relative to Bonferroni correction (Rorden et al., 2007).

3. Results

3.1. Demographic, diagnostic and neuropsychological results

Table 1 shows the demographic characteristics (age, education, gender and delay between stroke and assessment) and the neuropsychological performances of the three groups. As expected, AHP + DSO showed more DSO than both other groups, namely AHP and HP ($Z = 3.3$ and 3.7 respectively, $p's < .001$), as tested by the modified Cutting questionnaire. Similarly, Mann–Whitney U tests revealed that AHP ($Z = 3.9$ and 4 respectively, $p's < .001$) and AHP + DSO ($Z = 3.6$ and 3.7 respectively, $p's < .001$) were significantly worse than HP on the Berti and Feinberg scales.

Kruskal–Wallis tests revealed that the delay, age and educational differences between the three groups (AHP, AHP + DSO and HP) were not significant ($p's > .1$). All three groups showed a similar

profile of neuropsychological impairments in global intellectual ability, memory, executive functions and mood, with no significant differences between groups ($p's > .05$; see Table 1). However, Kruskal–Wallis tests revealed significant differences between the three groups in personal neglect [$\chi^2(2) = 7.4, p = .02$], visuo-spatial neglect (see Table 1), and a trend effect in the clock drawing task [$\chi^2(2) = 6.1, p = .05$]. Bonferroni-corrected post-hoc tests indicated that AHP and AHP + DSO patients showed significantly greater visuospatial (but not personal) neglect compared with HP (see Table 1). Performance of the AHP and AHP + DSO patients was equivalent ($p's > .017$). The groups also differed significantly in proprioception [$\chi^2(2) = 12.7, p = .002$], but not in tactile extinction on the left side, especially on the left upper limb ($p's > .1$). Post-hoc comparisons were carried out using Mann–Whitney U tests (Bonferroni-corrected critical $\alpha = .017$). There was no difference between the AHP (mean = 4.3 ± 2.5) and AHP + DSO (mean = 4.1 ± 1.7) groups ($p = .84$), but both were more impaired than the HP group (mean = 7.4 ± 1 ; $Z = -2.3, p = .017$ and $Z = -3.2, p = .0004$, respectively).

Table 1 – Demographic characteristics and neuropsychological findings in 31 patients.

	AHP			AHP + DSO			HP			p
	n	Mean	SD	n	Mean	SD	n	Mean	SD	
Age (years)	9	70.56	16.48	7	67.57	12.55	15	66.93	13.11	NS
Education (years)	9	11.78	2.17	7	11.71	1.89	15	12.6	2.59	NS
Male/female	9	3/6	–	7	2/5	–	15	10/5	–	–
Days from onset	9	14.67	11.6	7	7.43	5.56	15	17.47	14.12	NS
Berti awareness	9	1.67	.5	7	1.86	.38	15	.07	.26	*.#
Feinberg awareness	9	6.33	2.03	7	7.14	1.95	15	.36	.72	*.#
Self-body ownership	9	0	0	7	2	0	15	0	0	†.#
MMSE	6	22.17	5.49	3	24.67	4.93	3	26.67	2.31	NS
MoCA 5-item	9	3.89	.93	6	4	.89	10	4.2	1.62	NS
WTAR	6	36.5	9.2	4	34.5	14.08	5	34	6.63	NS
Digit span Forwards	9	5.78	.97	7	6.14	.69	12	6.25	1.29	NS
Digit span Backwards	9	2.89	.93	7	2.86	.9	12	3.33	1.3	NS
L/R disorientation	9	11.56	2.19	6	9.83	1.83	12	12.42	1.83	NS
Comb/Razor test L	9	4.67	4	7	3.71	2.81	13	6.38	4.09	NS
Comb/Razor test R	9	12.56	5.66	7	14.43	6.88	13	11.61	3.07	NS
Comb/Razor test ambiguous	9	5.33	2.6	7	8.14	5.3	13	5.69	3.4	NS
Comb/Razor test bias	9	–.33	.29	7	–.44	.2	13	–.24	.24	NS
One item test	9	.67	.5	7	1.57	.79	15	.73	.8	NS
Star Cancellation omission L	9	21.44	10.34	7	26.86	.38	13	14.38	12.18	NS
Star Cancellation omission R	9	15.33	4.97	7	15.14	4.41	13	7.38	6.9	*.#
Line crossing L	9	.22	.44	7	.14	.38	15	.6	.51	NS
Line crossing centre	9	.33	.5	7	.29	.49	15	.93	.7	NS
Line crossing R	9	.22	.44	7	.29	.49	15	.87	.74	NS
Line cancellation L	9	4	6.71	7	3.29	5.06	15	13.6	6.95	*.#
Line cancellation R	9	11.22	6.55	7	11.86	4.95	15	15.87	5.15	*
Copy BIT	9	.33	.5	7	.43	.79	15	1.4	1.18	NS
Drawing (clock)	9	.11	.33	7	.29	.49	15	.6	.51	NS
FAB	7	10.57	1.99	3	12	1.73	10	13.7	2.63	NS
Cognitive estimates	8	16.25	4.53	4	18.5	5.2	7	12.43	4.35	NS
HADS anxiety	9	6.33	4.09	5	8.6	4.77	10	8.1	5.78	NS
HADS depression	9	4.89	4.11	5	6	2.91	10	7.7	3.27	NS

NS = not significant for all comparisons (with post-hoc Bonferroni corrected Mann–Whitney U tests), $p > .017$.

* Significant differences between the AHP and the HP groups, $p < .017$.

† Significant differences between the AHP and the AHP + DSO groups, $p < .017$.

Significant differences between the AHP + DSO and the HP groups, $p < .017$.

AHP = Anosognosia for hemiplegia; DSO = Disturbed sensation of limb ownership; HP = Hemiplegic patients; n = number of patients; SD = standard deviation; MMSE = Mini Mental State Examination; MoCA = Montreal Cognitive Assessment; WTAR = Wechsler Test of Adult Reading; L = left; R = right; BIT = Behavioural Inattention Test; FAB = Frontal Assessment Battery; HADS = Hospital Anxiety and Depression scale.

3.2. Visual capture of ownership

The majority of patients (64.5%) experienced an immediate feeling that the motionless rubber hand was their own and responded ‘Yes’ to the initial rubber hand ownership question, even in the absence of any tactile stimulation or movement. Specifically, 6/7 patients in the AHP + DSO group (86%), 6/9 patients in the AHP group (67%), and 8/15 patients in the HP group (53%) experienced ownership of the rubber hand from visual capture alone. Although these percentages were higher in the two groups with delusions compared with the control group, a Kruskal–Wallis test showed that there were no significant differences between the three groups in VOC using the 11-point scale measure described above [$\chi^2(2) = 1.5$, $p = .47$]. Additionally, no significant differences between the three groups were found on ‘Movement Ownership Change’ scores [$\chi^2(2) = 1.1$, $p = .6$], as expected from the fact that only two out of 31 patients changed their responses, with 6/7 patients in the AHP + DSO group (86%), 7/9 patients in the AHP group (77.8%), and 7/15 patients in the HP group (46.7%) experienced ownership of the rubber hand following the movement condition. Moreover, all AHP + DSO patients, all but one of the AHP patients and the majority (11/15, 73.3%) of the HP patients noticed the rubber hand movement during this condition.

Using the Spearman's rank correlation coefficient, we found a significant negative correlation between visual capture of ownership and the proprioception scores in the three groups together ($r = -.47$, $p = .02$). This correlation remains significant in the AHP + DSO group alone ($r = -.85$, $p = .03$), but not for the other two groups (p 's $> .05$), indicating that greater proprioceptive impairment was associated with greater rubber hand ownership, particularly in the group with body ownership delusions.

3.3. Lesion analysis

All lesions resulted from a first-ever unilateral stroke within the right middle cerebral artery territory. Group-level lesion overlay maps for the AHP group ($n = 9$), AHP + DSO group ($n = 7$) and HP group ($n = 12$) are illustrated in Fig. 2A–C. Lesion volume (i.e., total number of voxels) was not significantly different between the group who experienced ownership of the rubber hand (VOC) ($n = 17$, mean = 66068 ± 59666) and the group who did not ($n = 11$, mean = 40224 ± 49637 , $p = .06$). VLSM analysis, looking at brain areas associated with VOC (Fig. 3B), identified significant voxels ($p < .05$) involving the right superior temporal gyrus (STG) in the anterior part, the frontal operculum (fOp), the inferior frontal gyrus (IFG) and the supramarginal gyrus (SMG). By contrast, VLSM analysis, looking at brain areas associated with greater VOC failure (Fig. 4), identified significant voxels ($p < .05$) involving the posterior part of the insula (pIns), a small area of the putamen (Put), and the posterior limb of the internal capsule.

Furthermore, VLSM analysis, looking at brain areas associated with greater proprioceptive deficit (Fig. 3C), identified significant voxels ($p < .05$) involving the right superior temporal gyrus (STG) in the anterior part, the pallidum (Pal), the insula (Ins), and the somatosensory cortex, primary (SI) and secondary (SII). Finally, lesion volume (i.e., total number of voxels) was not significantly different between the AHP + DSO group ($n = 7$, mean = 85087 ± 60320) and the group without DSO (AHP and HP groups; $n = 21$, mean = 46191 ± 53050 , $p = .09$). VLSM analysis, looking at brain areas associated with worse performance on the DSO assessment (Fig. 3A), identified significant voxels ($p < .05$) involving the right superior temporal gyrus (STG), the TPJ, the middle frontal gyrus (MFG) and the supramarginal gyrus (SMG).

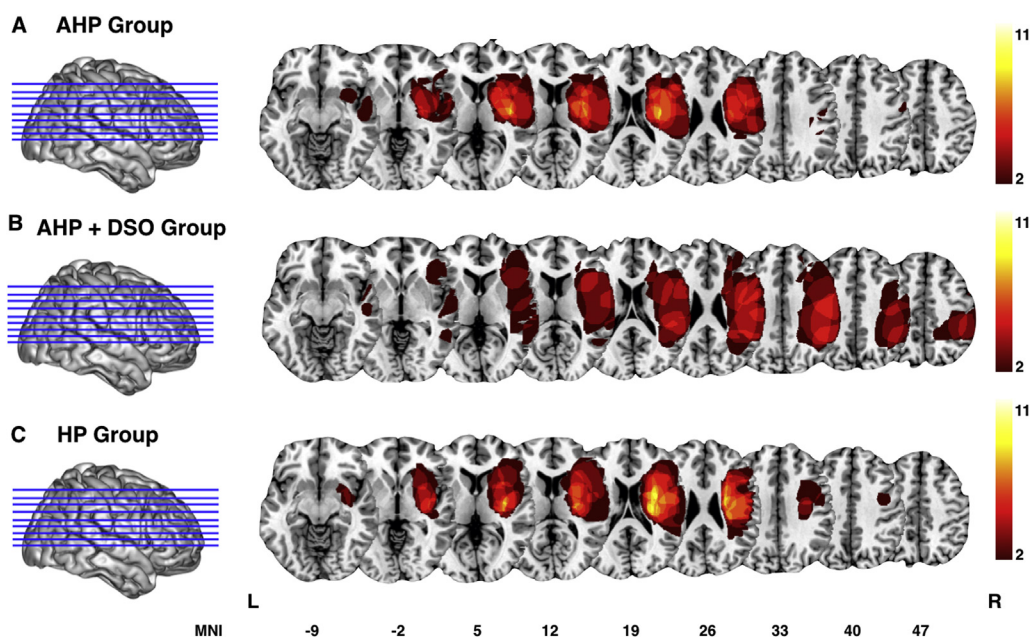


Fig. 2 – Group-level lesion overlay maps in MNI space for **A.** patients with anosognosia for hemiplegia (AHP; $n = 9$), **B.** patients with AHP and disturbed sensation of limb ownership (AHP + DSO; $n = 7$), and **C.** hemiplegic patients (HP; $n = 12$). The number of overlapping lesions is illustrated by colour, from dark red ($n = 2$) to white ($n = 11$). L = left; R = right.

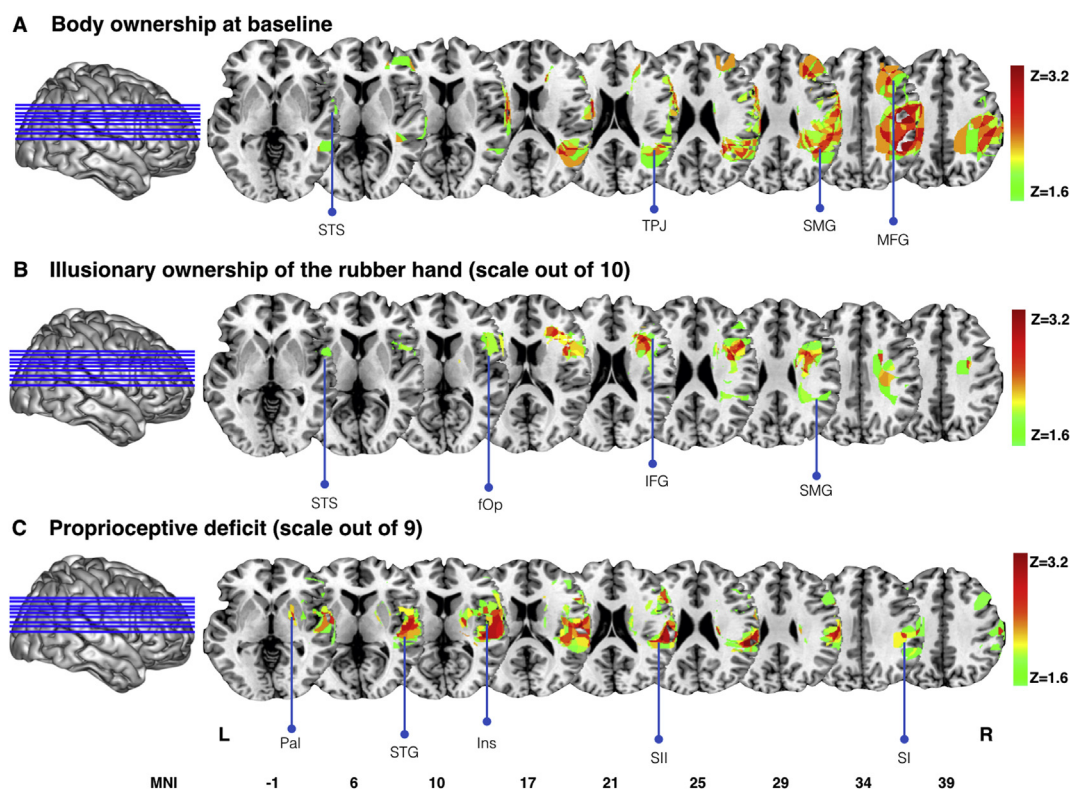


Fig. 3 – Voxel-based lesion-symptom mapping. A. Damaged MNI voxels predicting a disturbed sensation of limb ownership (DSO) at the baseline in the 3 groups ($n = 28$), $p < .05$ for $Z > 1.6449$. B. Damaged MNI voxels predicting the illusory ownership of the rubber hand in the 3 groups ($n = 28$), $p < .05$ for $Z > 1.6449$. C. Damaged MNI voxels predicting a proprioceptive deficit in the 3 groups ($n = 24$), $p < .05$ for $Z > 1.6449$. L = left; R = right; STG = superior temporal gyrus; TPJ = temporoparietal junction; SMG = supramarginal gyrus; MFG = middle frontal gyrus; fOp = frontal operculum; IFG = inferior frontal gyrus; pal = pallidum; Ins = insula; SII = secondary somatosensory cortex; SI = primary somatosensory cortex.

4. Discussion

The majority of our patients with damage to the right hemisphere (64.5% overall and up to 86% of the patients with DSO) experienced strong feelings of ownership over a motionless rubber hand just seconds after seeing it and without any tactile stimulation VOC, in accordance with previous reports (Fotopoulou et al., 2008). Moreover, VOC was maintained even

when the rubber hand was moved in space by the experimenter. In the few studies on healthy controls that have tested similar ‘mere vision’ conditions, the percentage of people experiencing VOC tends to be much lower (Guimmarra et al., 2010; Longo et al., 2008; see also Rohde et al., 2011 for anecdotal evidence). Indeed, in previous published (Crucianelli, Metcalf, Fotopoulou, & Jenkinson, 2013) and unpublished data (Crucianelli et al., in preparation) from our

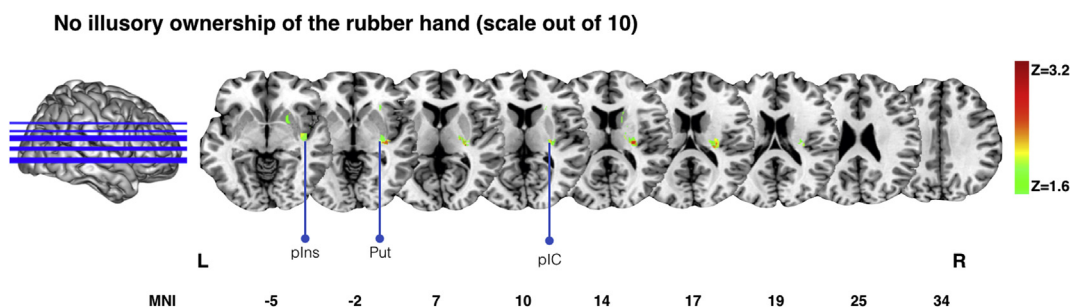


Fig. 4 – Voxel-based lesion-symptom mapping. Damaged MNI voxels predicting no illusory ownership of the rubber hand in the 3 groups ($n = 28$), $p < .05$ for $Z > 1.6449$. L = left; R = right; plns = posterior part of the insula; put = putamen; pIC = posterior limb of the internal capsule.

group, we found that VOC occurred in 13/70 (18%) of healthy individuals. However, VOC tends to increase in virtual reality paradigms that can achieve spatial coincidence between visual and proprioceptive cues rather than mere spatial congruency and plausibility (Maselli & Slater, 2013; see also Kilteni et al., 2015 for review). Our data are consistent with these findings, in that we found a positive association between proprioceptive deficits and VOC across our patient groups and particularly in the DSO group. Thus, taken together, these results suggest that when information from proprioception is not available due to damage, or it is not informative (e.g., there is no mismatch in the spatial location of the seen and felt body parts), visual cues from a realistic body part can be sufficient to generate not only recalibration of hand position (Holmes & Spence, 2006 for review), but also feelings of fake hand ownership.

In our patients, this pathologically exaggerated VOC effect occurred when proprioception was impaired by lesions to areas including the primary and secondary somatosensory cortex (see Fig. 3C). However, it also appears that such damage is not sufficient for the pathological VOC effect, as lesions to cortical areas further up the neurocognitive hierarchy were selectively associated with the VOC effect. Specifically, VOC scores were primarily associated with lesions to the frontal operculum and the inferior frontal gyrus, and to a lesser degree parietal areas (see Fig. 3B). Interestingly, in functional imaging studies on the RHI, the onset of subjective feelings of ownership for the fake hand and its vividness correlated with activation of similar areas in the frontal operculum and the premotor cortex (Ehrsson et al., 2004, 2005). Thus, when damage to the central, parietal representation of proprioceptive signals is also accompanied by damage to such frontal areas, there is a pathological dominance of vision over proprioception and body ownership feelings of the rubber hand.

By contrast, failures of VOC were associated mostly with subcortical lesions (see also Zeller et al., 2011) and with the posterior part of the insula. We had expected this area to be instead associated by greater pathological VOC in our patients as in the case of frontal operculum, given the association of both of these areas with feelings of ownership during the classic conditions of the RHI (Ehrsson et al., 2004; Tsakiris et al., 2007). The fact that neurological patients can present with both deficits in body ownership (failures of VOC) and pathological exaggerations of such feelings (VOC), however, suggests a potential separation between the role of these two areas in body ownership. The frontal operculum and the premotor cortex may contribute to feelings of body ownership by monitoring mismatches in multisensory integration in a forward way, i.e., in a way analogous to how efferent motor signals (Berti et al., 2005; Frith, Blakemore, & Wolpert, 2000) or, proprioceptive predictions (Fotopoulou, 2015) dominate motor awareness in AHP due to the selective involvement of these areas (see Berti et al., 2005; Fotopoulou, Pernigo, Maeda, Rudd, & Kopelman, 2010). By contrast, the posterior insular cortex may instead be related to more fundamental aspects of the sense of ownership, integrating and monitoring different aspects of somatosensation, including interoceptive modalities (Critchley, Wiens, Rotshtein, Ohman, & Dolan, 2004). However, further specification of this role would be speculative based

on the current data, particularly given the small number of patients in this analysis and the intrinsic limitations of lesion analyses as regards this area (Kodumuri et al., 2016).

Although patients with DSO had more proprioceptive deficits than control patients, and showed more VOC than the control group, the latter difference was not statistically significant. Interestingly, as mentioned in the introduction, it remains paradoxical why patients with DSO would deny the ownership of their own arm when they see it, while they are willing to accept as theirs a realistic, congruently placed, fake hand. Indeed, our lesion analyses reveals a dissociation between pathological VOC and DSO, with the latter being selectively associated with more posterior lesions, including the right temporoparietal junction and a large area of the supramarginal gyrus, and to a lesser degree the middle frontal gyrus (see Fig. 3A). Lesions of the right middle frontal gyrus have previously been correlated with somatoparaphrenia (Feinberg & Venneri, 2014; Gandola et al., 2012). Interestingly, regions close to the medial frontal cortex have also been involved in several self-related functions, such as the sense of an integrated self and the differentiation between the self and the external world (Feinberg, 2013). In our study, the frontal network differs between the sense of body ownership and the rubber hand ownership, involving more the middle frontal gyrus for the former (Fig. 3A), and the inferior frontal gyrus for the latter (Fig. 3B). The contribution of the right temporoparietal junction (including the supramarginal gyrus) in body ownership has been recognised as an early ‘test-of-fit mechanism’ (Tsakiris, 2010), comparing expectations about the state of the body, with current sensory events. One possibility is therefore that information about the affected arm from a modality other than vision (as it is their own hand they are visually not recognising) is generating error signals that cannot be predicted by existing top-down, expectations of selfhood (for the wider theoretical context of this hypothesis see Fotopoulou, 2015). We have not been able to test the various candidate modalities in this study, and hence we merely put forward some possible hypotheses for further examination. Although the role of defective proprioception is unlikely to be sufficient to explain DSO (as many patients with proprioceptive deficits do not show DSO), and in the present study many patients with proprioceptive deficits were likely to feel ownership for a rubber hand placed congruently with their own, it remains possible that patients with DSO are unable to generate appropriate proprioceptive predictions about their own arm and these affect their ownership. For example, they may experience their own arm to be in a different position than the one tested and hence they may deny its ownership when they are asked to look at this familiar arm (rather than a rubber hand) in a different position. More generally, a recent RHI study in paralysed patients has argued that any alteration of the normal flow of signals present during movements may affect feelings of body ownership (Burin et al., 2015). In addition, although the rubber hand was placed in a position congruent and similar to the patients’ own arms, it remains possible, particularly given the frequent deficits in personal neglect in DSO patients, that patients deny an arm they see in personal space (i.e., their own arm) more often than an arm they see in proximity but in peripersonal space (i.e., the rubber hand). Finally, although we did not find any evidence for this

hypothesis based on limited bedside assessments of tactile extinction in the current study, a candidate modality would be somatosensation, including exteroceptive (tactile perception impairment or hypoesthesia) and interoceptive variants (e.g., pain). Despite their DSO, patients are known to complain of left arm ‘heaviness’, ‘numbness’, ‘coldness’ and other similar sensations. It is thus possible that damage to the rTPJ, does not allow these new sensations to be integrated in patients’ body representation. This hypothesis would need to be tested in future studies, but it is compatible with anecdotal evidence in the field, as captured by this quote from the existing literature; “I know they [left arm and leg] look like mine, but I can feel they are not, and I can’t believe my eyes” (C. W. Olson, 1937, cited in [Feinberg, 2001](#)).

4.1. Limitations and future directions

The current study has shown that a fake hand can capture ownership in patients with right-hemisphere damage. However, future studies should manipulate the visuo-semantic and visuo-spatial properties of the presented hand in order to establish the constraints of this phenomenon (see [Tsakiris, 2010](#); [Kilteni et al., 2015](#) for discussions). Measurements and manipulations of exteroceptive and interoceptive domains of contralateral somatosensation can further add specificity to our neuroanatomical findings. Moreover, although we did not find significant differences in VOC between our three groups, larger samples are necessary to exclude a relationship between VOC and somatic delusions. Moreover, such future studies with larger samples could investigate such factors in groups fully balanced for neuropsychological performance, or with statistical tests allowing for co-variation of various neuropsychological functions that was not possible in the current study. For instance, our lesions analysis included activations in the anterior region of the right superior temporal gyrus that have been elicited in visual-orienting and alertness tasks ([Sturm & Willmes, 2001](#)), demonstrating a general attention function rather than a specific role in terms of self-processing ([Apps & Tsakiris, 2014](#)). Actually, the same region of the right superior temporal gyrus was found in our three lesion analyses ([Fig. 3](#)). Furthermore, future studies should include a left-hemisphere damage patient group allowing for greater interpretation regarding laterality.

Lastly, it is important to recognise that interpretation of the neuroanatomical correlates are limited by our relatively small sample size and inherit limitations to our lesion mapping approach ([Geva, Baron, Jones, Price, & Warburton, 2012](#); [Rorden et al., 2007](#)). Our interpretations do not take into account the structural and functional connectivity between areas and related functional networks. Contrary to some functional neuroimaging methods, current voxel-based lesion analyses methods also do not allow for correlations between function and neural activity at the whole brain level. Instead, they focus on the most frequently lesioned voxels in a sample of patients with behavioural deficits. This has the advantage of pointing to certain areas that may have a necessary functional role in a network, but it does not tell us much more about that network and its connections. In addition, lesion analyses methods are limited by the fact that certain areas may simply be more frequently damaged following certain types of stroke

([tKodumuri et al., 2016](#)). Nevertheless, all previous lesion mapping studies in such disorders are subject to comparable limitations, with our study being one of the few that has directly compared experimental scores with lesion data. Future studies will have to use better structural lesion data and functional MRI paradigms to be able to more accurately identify brain areas and importantly also white matter connections related to VOC and somatic delusions of ownership.

5. Conclusion

Overall, the present data highlight three important findings. First, the majority of patients with right perisylvian fissure lesions experience feelings of ownership over a rubber hand, without any tactile stimulation. Second, this ‘visual capture of ownership’ is associated with proprioceptive deficits and lesions mostly in the frontal operculum and the premotor motor cortex. Third, this mechanism seems behaviourally and neurally dissociated from the feelings of disownership experienced by somatoparaphrenic patients. It seems that in the latter patients, feelings of disownership dominate vision in the case of their own arm, while vision dominates their feeling of ownership in the case of others arms.

Funding

This work was funded by an European Research Council (ERC) Starting Investigator Award for the project ‘The Bodily Self’ N°313755 to A.F., a Neuropsychanalysis Foundation Fellowship to P.M.J., and a Commonwealth Scholarship, an Oppenheimer Memorial Trust Fellowship, and a Neuropsychology International Fellowship Award from the British Psychological Society in conjunction with the British Neuropsychological Society to S.B.

Acknowledgements

We thank the patients and their relatives for their kindness and willingness to take part in the study, and to the staff and PACS office at participating hospital sites for their kind assistance with this study. We are also very grateful to Cristina Papadaki for help with patient recruitment and testing. This work was done when Dr Besharati was based at the Academic Unit of Neuropsychiatry, King’s College London, located at St Thomas’s Hospital. No conflicts of interest were reported.

REFERENCES

- [Abdulkarim, Z., & Ehrsson, H. H. \(2016\). No causal link between changes in hand position sense and feeling of limb ownership in the rubber hand illusion. *Attention, Perception & Psychophysics*, 78, 707–720.](#)
- [Apps, M. A. J., & Tsakiris, M. \(2014\). The free-energy self: A predictive coding account of self-recognition. *Neuroscience and Biobehavioral Reviews*, 41, 85–97.](#)

- Babinski, J. (1914). Contribution à l'étude des troubles mentaux dans l'hémiplégie organique cérébrale. *Revista de Neurologia*, 27, 845–848.
- Baier, B., & Karnath, O. H. (2008). Tight link between our sense of limb ownership and self-awareness of actions. *Stroke*, 39, 486–488.
- Bates, E., Wilson, S. M., Saygin, A. P., Dick, F., Sereno, M. I., Knight, R. T., et al. (2003). Voxel-based lesion-symptom mapping. *Nature Neuroscience*, 6, 448–450.
- Berti, A., Bottini, G., Gandola, M., Pia, L., Smania, N., Stracciari, A., et al. (2005). Shared cortical anatomy for motor awareness and motor control. *Science*, 309, 488–491.
- Berti, A., Ladavas, E., & Della Corte, D. (1996). Anosognosia for hemiplegia, neglect, dyslexia, and drawing neglect: Clinical findings and theoretical considerations. *Neuropsychological Society*, 2, 426–440.
- Besharati, S., Forkel, S. J., Kopelman, M., Solms, M., Jenkinson, P. M., & Fotopoulou, A. (2014). The affective modulation of motor awareness in anosognosia for hemiplegia: Behavioural and lesion evidence. *Cortex*, 61, 127–140.
- Bisiach, E., Vallar, G., Perani, D., Papagno, C., & Berti, A. (1986). Unawareness of disease following lesions of the right hemisphere: Anosognosia for hemiplegia and anosognosia for hemianopia. *Neuropsychologia*, 24, 471–482.
- Bolognini, N., Ronchi, R., Casati, C., Fortis, P., & Vallar, G. (2014). Multisensory remission of somatoparaphrenic delusion. My hand is back! *Neurology: Clinical Practice*, 4, 216–225.
- Botvinik, M., & Cohen, J. (1998). Rubber hands “feel” touch that eyes see. *Nature*, 391, 756.
- Brett, M., Leff, A. P., Rorden, C., & Ashburner, J. (2001). Spatial normalization of brain images with focal lesions using cost function masking. *NeuroImage*, 14, 486–500.
- Burin, D., Livelli, A., Garbarini, F., Fossataro, C., Folegatti, A., Gindri, P., et al. (2015). Are movements necessary for the sense of body ownership? Evidence from the rubber hand illusion in pure hemiplegic patients. *PLoS One*, 10, e0117155.
- Critchley, H. D., Wiens, S., Rotshtein, P., Ohman, A., & Dolan, R. J. (2004). Neural systems supporting interoceptive awareness. *Nature Neuroscience*, 7, 189–195.
- Crucianelli, L., Metcalfe, N. K., Fotopoulou, A., & Jenkinson, P. M. (2013). Bodily pleasure matters: Velocity of touch modulates body ownership during the rubber hand illusion. *Frontiers in Psychology*, 4, 703.
- Cutting, J. (1978). Study of anosognosia. *Journal of Neurology, Neurosurgery & Psychiatry*, 41, 548–555.
- DeLuca, J. (2000). A cognitive perspective on confabulation. *Neuropsychology*, 2, 119–132.
- Dubois, B., Slachevsky, A., Litvan, I., & Pillon, B. (2000). The FAB – A Frontal Assessment Battery at bedside. *Neurology*, 55, 1621–1626.
- Ehrsson, H. H., Holmes, N. P., & Passingham, R. E. (2005). Touching a rubber hand: Feeling of body ownership is associated with activity in multisensory brain areas. *The Journal of Neuroscience*, 25, 10564–10573.
- Ehrsson, H. H., Spence, C., & Passingham, R. E. (2004). That's my hand! Activity in premotor cortex reflects feeling of ownership of a limb. *Science*, 305, 875–877.
- Farnè, A., Pavani, F., Meneghello, F., & Ladavas, E. (2000). Left tactile extinction following visual stimulation of a rubber hand. *Brain*, 123, 2350–2360.
- Feinberg, T. (2001). *Altered egos: How the brain causes the self*. Oxford: Oxford University Press.
- Feinberg, T. E. (2013). Neuropathologies of the self and the right hemisphere: A window into productive personal pathologies. *Frontiers in Human Neuroscience*, 7, 472.
- Feinberg, T. E., & Roane, D. M. (1997). Anosognosia, completion and confabulation: The neutral-personal dichotomy. *Neurocase*, 3, 73–85.
- Feinberg, T. E., Roane, D. M., & Ali, J. (2000). Illusory limb movements in anosognosia for hemiplegia. *Journal of Neurology, Neurosurgery & Psychiatry*, 69, 511–513.
- Feinberg, T. E., & Venneri, A. (2014). Somatoparaphrenia: Evolving theories and concepts. *Cortex*, 61, 74–80.
- Folstein, M., Folstein, S., & McHugh, P. (1975). Mini-mental state: A practical method for grading the cognitive state of patients for the clinician. *Journal of Psychiatric Research*, 12, 189–198.
- Fotopoulou, A. (2010). The affective neuropsychology of confabulation and delusion. *Cognitive Neuropsychiatry*, 15, 38–63.
- Fotopoulou, A. (2014). Time to get rid of the ‘modular’ in neuropsychology: A unified theory of anosognosia as aberrant predictive coding. *Journal of Neuropsychology*, 8, 1–19.
- Fotopoulou, A. (2015). The virtual bodily self: Mentalisation of the body as revealed in anosognosia for hemiplegia. *Consciousness and Cognition*, 33, 500–510.
- Fotopoulou, A., Pernigo, S., Maeda, R., Rudd, A., & Kopelman, M. A. (2010). Implicit awareness in anosognosia for hemiplegia: Unconscious interference without conscious re-representation. *Brain*, 133, 3564–3577.
- Fotopoulou, A., Tsakiris, M., Haggard, P., Vagopoulou, A., Rudd, A., & Kopelman, M. (2008). The role of motor intention in motor awareness: An experimental study on anosognosia for hemiplegia. *Brain*, 131, 3432–3442.
- Frith, C. D., Blakemore, S. J., & Wolpert, D. M. (2000). Abnormalities in the awareness and control of action. *Philosophical Transactions of the Royal Society B: Biological Science*, 355, 1771–1788.
- Gandola, M., Invernizzi, P., Sedda, A., Ferré, E. R., Sterzi, R., Sberna, M., et al. (2012). An anatomical account of somatoparaphrenia. *Cortex*, 48, 1165–1178.
- Garbarini, F., Fornia, L., Fossataro, C., Pia, L., Gindri, P., & Berti, A. (2014). Embodiment of others' hands elicits arousal response similar to one's own hands. *Current Biology: CB*, 24, 738–739.
- Garbarini, F., Pia, L., Piedimonte, A., Rabuffetti, M., Gindri, P., & Berti, A. (2013). Embodiment of an alien hand interferes with intact-hand movements. *Current Biology: CB*, 21, 57–58.
- Gerstmann, J. (1942). Problem of imperception of disease and of impaired body territories with organic lesions. *Archives of Neurology and Psychiatry*, 48, 890–913.
- Geva, S., Baron, J. C., Jones, P. C., Price, C. J., & Warburton, E. A. (2012). A comparison of VLSM and VBM in a cohort of patients with post-stroke aphasia. *NeuroImage: Clinical*, 1, 37–47.
- Guarantors of Brain. (1986). *Aids to the examination of the peripheral nervous system*. London: W.B. Saunders.
- Guimmarra, M. J., Georgiou-Karistianis, N., Nicholls, M. E., Gibson, S. J., & Bradshaw, J. L. (2010). The phantom in the mirror: A modified rubber-hand illusion in amputees and normals. *Perception*, 39, 103–118.
- Hirstein, W. (2005). *Brain fiction: Self-deception and the riddle of confabulation*. Cambridge, MA: MIT Press.
- Holmes, N. P., & Spence, C. (2005). Multisensory integration: Space, time, and superadditivity. *Current Biology: CB*, 15, 762–764.
- Holmes, N. P., & Spence, C. (2006). Beyond the body schema: Visual, prosthetic, and technological contributions to bodily perception and awareness. In G. Knoblich, I. M. Thornton, M. Grosjean, & M. Shiffrar (Eds.), *Human body perception from the inside out* (pp. 15–64). Oxford University Press.
- Jackson, J. H. (1932). Evolution and dissolution of the nervous system. In J. Taylor (Ed.), *Selected writings of John Hughlings Jackson* (pp. 45–75). London: Staples Press.
- Jenkinson, P. M., Haggard, P., Ferreira, N. C., & Fotopoulou, A. (2013). Body ownership and attention in the mirror: Insights from somatoparaphrenia and the rubber hand illusion. *Neuropsychologia*, 51, 1453–1462.

- Kilteni, K., Maselli, A., Kording, K. P., & Slater, M. (2015). Over my fake body: Body ownership illusions for studying the multisensory basis of own-body perception. *Frontiers in Human Neuroscience*, 9, 141.
- Kodumuri, N., Sebastian, R., Davis, C., Posner, J., Kim, E. H., Tippett, D. C., et al. (2016). The association of insular stroke with lesion volume. *Neuroimage: Clinical*, 11, 41–45.
- Kopelman, M. D. (1999). Varieties in false memory. *Cognitive Neuropsychology*, 16, 197–214.
- Langdon, R., & Turner, M. (2010). Delusion and confabulation: Overlapping or distinct distortions of reality? *Cognitive Neuropsychiatry*, 15, 1–13.
- Longo, M. R., Schüür, F., Kammers, M. P. M., Tsakiris, M., & Haggard, P. (2008). What is embodiment? A psychometric approach. *Cognition*, 107, 978–998.
- Makin, T. R., Holmes, N. P., & Ehrsson, H. H. (2008). On the other hand: Dummy hands and peripersonal space. *Behavioural Brain Research*, 191, 1–10.
- Maselli, A., & Slater, M. (2013). The building blocks of the full body ownership illusion. *Frontiers in Human Neuroscience*, 7, 83.
- McIntosh, R. D., Brodie, E. E., Beschin, N., & Roberston, I. H. (2000). Improving the clinical diagnosis of personal neglect. *Cortex*, 36, 289–292.
- Nasreddine, Z. S., Phillips, N. A., Bédirian, V., Charbonneau, S., Whitehead, V., Collin, I., et al. (2005). The Montreal Cognitive Assessment, MoCA: A brief screening tool for mild cognitive impairment. *Journal of the American Geriatrics Society*, 53, 695–699.
- Oldfield, R. C. (1971). The assessment and analysis of handedness: The Edinburgh inventory. *Neuropsychologia*, 9, 97–113.
- Pavani, F., Spence, C., & Driver, J. (2000). Visual capture of touch: Out-of-the-body experiences with rubber gloves. *Psychological Science*, 11, 353–359.
- Rohde, M., Di Luca, M., & Ernst, M. O. (2011). The rubber hand illusion: Feeling of ownership and proprioceptive drift do not go hand in hand. *PLoS One*, 6, e21659.
- Rorden, C., & Brett, M. (2000). Stereotaxic display of brain lesions. *Behavioural Neurology*, 12, 191–200.
- Rorden, C., & Karnath, H. O. (2004). Using human brain lesions to infer function: A relic from a past era in the fMRI age? *Nature Reviews Neuroscience*, 5(10), 812–819.
- Rorden, C., Karnath, H. O., & Bonilha, L. (2007). Improving lesion-symptom mapping. *Journal of Cognitive Neuroscience*, 19, 1081–1088.
- Shallice, T., & Evans, M. E. (1978). The involvement of the frontal lobes in cognitive estimation. *Cortex*, 14, 294–303.
- Stein, B. E., & Stanford, T. R. (2008). Multisensory integration: Current issues from the perspective of the single neuron. *Nature Reviews Neuroscience*, 9, 255–266.
- van Stralen, H. E., van Zandvoort, M. J., Kappelle, L. J., & Dijkerman, H. C. (2013). The rubber hand illusion in a patient with hand disownership. *Perception*, 42, 991–993.
- Sturm, W., & Willmes, K. (2001). On the functional neuroanatomy of intrinsic and phasic alertness. *NeuroImage*, 14, S76–S84.
- Tieri, G., Tidoni, E., Pavone, E. F., & Aglioti, S. M. (2015a). Mere observation of body discontinuity affects perceived ownership and vicarious agency over a virtual hand. *Experimental Brain Research*, 233, 1247–1259.
- Tieri, G., Tidoni, E., Pavone, E. F., & Aglioti, S. M. (2015b). Body visual discontinuity affects feeling of ownership and skin conductance responses. *Scientific Reports*, 25, 17139.
- Tsakiris, M. (2010). My body in the brain: A neurocognitive model of body-ownership. *Neuropsychologia*, 48, 703–712.
- Tsakiris, M., Hesse, M. D., Boy, C., Haggard, P., & Fink, G. R. (2007). Neural signatures of body ownership: A sensory network for bodily self-consciousness. *Cerebral Cortex*, 17, 2235–2244.
- Vallar, G., & Ronchi, R. (2009). Somatoparaphrenia: A body delusion. A review of the neuropsychological literature. *Experimental Brain Research*, 192, 533–551.
- Vocat, R., Staub, F., Stroppini, T., & Vuilleumier, P. (2010). Anosognosia for hemiplegia: A clinical-anatomical prospective study. *Brain*, 133, 3578–3597.
- Wechsler, D. (1998). *Wechsler Adult Intelligence Scale (WAIS-III)*. London: The Psychological Corporation.
- Wechsler, D. (2001). *Wechsler Test of Adult Reading (WTAR)*. San Antonio TX: The Psychological Corporation.
- Wilson, B. A., Cockburn, J., & Halligan, P. W. (1987). *Behavioural Inattention Test (BIT)*. Bury St Edmunds: Thames Valley Test Company.
- Zeller, D., Gross, C., Bartsch, A., Johansen-Berg, H., & Classen, J. (2011). Ventral premotor cortex may be required for dynamic changes in the feeling of limb ownership: A lesion study. *The Journal of Neuroscience*, 31, 4852–4857.
- Zigmond, A. S., & Snaith, R. P. (1983). The Hospital Anxiety and Depression Scale (HADS). *Acta Psychiatrica Scandinavica*, 67, 361–370.