
Variant Creutzfeldt–Jakob Disease in a Patient with Heterozygosity at *PRNP* Codon 129

TO THE EDITOR: Prions cause lethal neurodegenerative diseases in mammals and are composed of multichain assemblies of misfolded host-encoded cellular prion protein (PrP). A common polymorphism at codon 129 of the PrP gene (*PRNP*), where either methionine (M) or valine (V) is encoded, affects the susceptibility to prion disease, as well as the incubation period¹ and clinical phenotype of prion disease. Human in-

fection with the epizootic prion disease bovine spongiform encephalopathy resulted in variant Creutzfeldt–Jakob disease, which provoked a public health crisis in the United Kingdom and other regions. All definite cases of variant Creutzfeldt–Jakob disease to date have occurred in patients with the MM genotype at *PRNP* codon 129.¹

A 36-year-old man was referred to the United

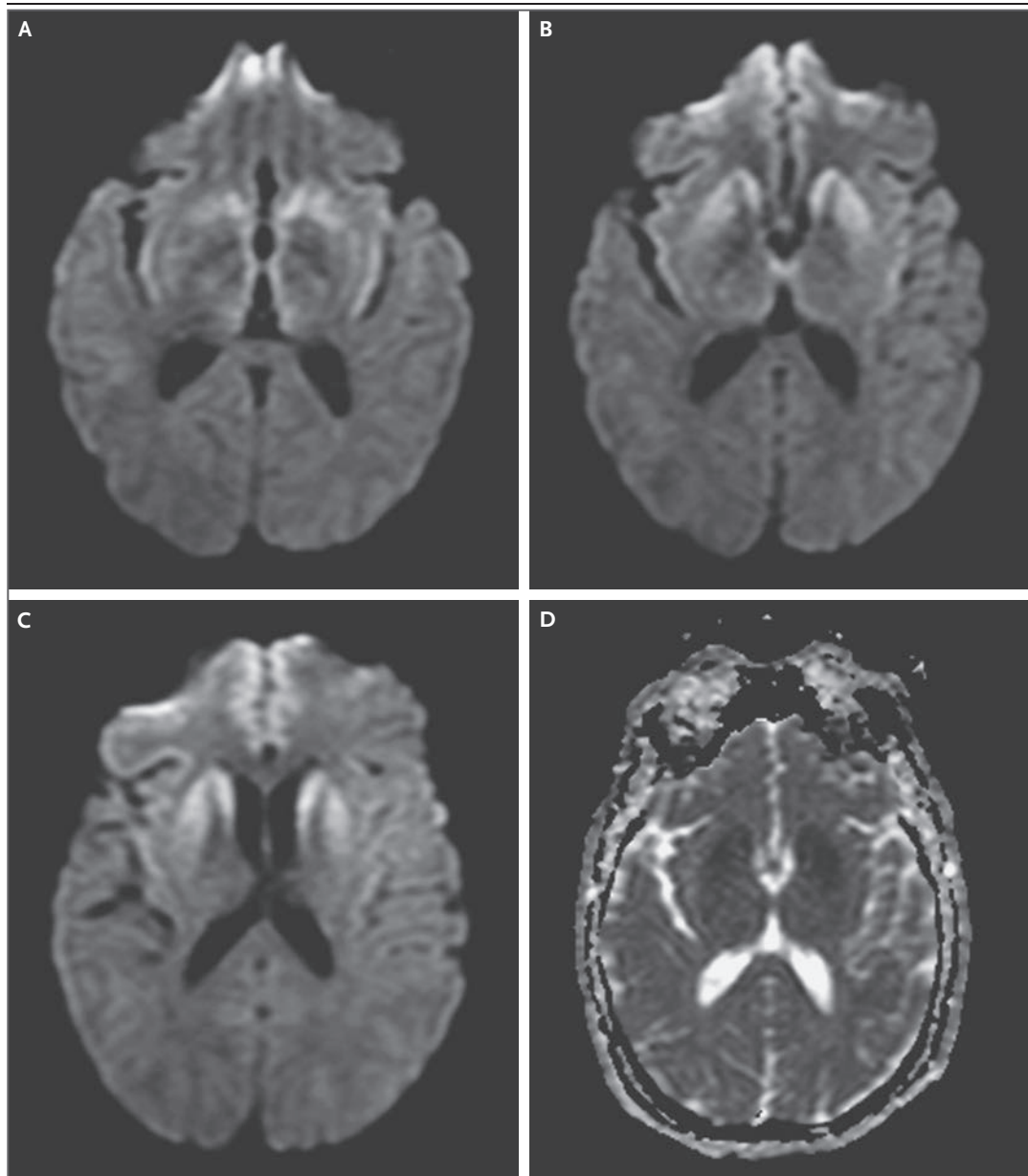


Figure 1. MRI of the Brain.

Trace-weighted diffusion-weighted images (Panels A, B, and C) show high signal intensity in the basal ganglia, hypothalamus, and medial thalamus but not in the pulvinar nuclei. These structures appear dark on the apparent diffusion coefficient map (Panel D), thus confirming the presence of restricted diffusion.

Kingdom National Prion Clinic in August 2015 with personality change. Over a period of 9 months, he had become uncharacteristically irascible and had progressive episodic memory impairment, gait ataxia, and myoclonus. His score on the Mini-Mental State Examination was 25 (with scores ranging from 0 to 30 and higher scores indicating less impairment); clini-

cal examination revealed extraocular eye-movement abnormalities, pyramidal and cerebellar signs, and multifocal myoclonus. Magnetic resonance imaging of the brain (Fig. 1) revealed restricted diffusion in the basal ganglia, hypothalamus, insular cortexes, and medial thalamus but not in the pulvinar nuclei.² Examination of the cerebrospinal fluid for protein 14-3-3 was nega-

tive, as was a real-time quaking-induced conversion assay, although these two tests are known to have low sensitivity for variant Creutzfeldt–Jakob disease.³ His genotype at *PRNP* codon 129 was MV. During the following 6 months, the patient's condition declined progressively, and severe dysphagia and agitation occurred shortly before his death in February 2016.

At autopsy, histologic examination of the brain revealed frequent florid and cluster plaques in cerebral and cerebellar cortexes, microvacuolar degeneration in neuropil, and immunostaining for abnormal PrP in a stellate pericellular and perivascular distribution. Minute amounts of protease-resistant PrP (PrP^{Sc}) were seen in lymphoid tissue of the spleen. Immunoblotting of brain homogenate revealed type 4 PrP^{Sc} (according to the London classification system), which is pathognomonic of variant Creutzfeldt–Jakob disease.⁴ (For more details, see the Supplementary Appendix, available with the full text of this letter at NEJM.org.)

This patient's clinical features differed from those of typical variant Creutzfeldt–Jakob disease, and his neuroimaging features suggested a diagnosis of sporadic Creutzfeldt–Jakob disease. He did not meet the epidemiologic diagnostic criteria for probable or possible variant Creutzfeldt–Jakob disease,⁵ yet the results of the neuropathological examination and molecular strain typing were consistent with variant Creutzfeldt–Jakob disease. It remains uncertain whether this case marks the start of a second wave of variant Creutzfeldt–Jakob disease in persons with the MV genotype at *PRNP* codon 129 (the most common genotype in the United Kingdom), mirroring the long incubation periods seen in persons with the MV genotype who have other acquired prion diseases, notably kuru.¹ This case emphasizes the importance of performing an autopsy and molecular strain typing in cases of prion disease to ascertain the prevalence of human prion disease related to bovine spongiform encephalopathy.

Tzehow Mok, M.R.C.P.

University College London Institute of Neurology
London, United Kingdom

Zane Jaunmuktane, F.R.C.Path.

University College London Hospitals NHS Foundation Trust
London, United Kingdom

Susan Joiner, M.Sc.

Tracy Campbell, B.Sc.

University College London Institute of Neurology
London, United Kingdom

Catherine Morgan, M.D.

Benjamin Wakerley, M.D.

Farhad Golestani, M.D.

Gloucestershire Hospitals NHS Foundation Trust
Gloucester, United Kingdom

Peter Rudge, F.R.C.P.

Simon Mead, M.D.

H. Rolf Jäger, M.D.

Jonathan D.F. Wadsworth, Ph.D.

Sebastian Brandner, F.R.C.Path.

John Collinge, F.R.S.

University College London Institute of Neurology
London, United Kingdom
jc@prion.ucl.ac.uk

Supported by the National Institute of Health Research Biomedical Research Centre at University College London Hospitals NHS Foundation Trust and the Medical Research Council (United Kingdom).

Disclosure forms provided by the authors are available with the full text of this letter at NEJM.org.

- Collinge J, Whitfield J, McKintosh E, et al. Kuru in the 21st century — an acquired human prion disease with very long incubation periods. *Lancet* 2006;367:2068-74.
- Zeidler M, Sellar RJ, Collie DA, et al. The pulvinar sign on magnetic resonance imaging in variant Creutzfeldt-Jakob disease. *Lancet* 2000;355:1412-8.
- Peden AH, McGuire LI, Appleford NE, et al. Sensitive and specific detection of sporadic Creutzfeldt-Jakob disease brain prion protein using real-time quaking-induced conversion. *J Gen Virol* 2012;93:438-49.
- Hill AF, Joiner S, Wadsworth JD, et al. Molecular classification of sporadic Creutzfeldt-Jakob disease. *Brain* 2003;126:1333-46.
- Heath CA, Cooper SA, Murray K, et al. Validation of diagnostic criteria for variant Creutzfeldt-Jakob disease. *Ann Neurol* 2010; 67:761-70.

DOI: 10.1056/NEJMc1610003

Correspondence Copyright © 2017 Massachusetts Medical Society.

INSTRUCTIONS FOR LETTERS TO THE EDITOR

Letters to the Editor are considered for publication, subject to editing and abridgment, provided they do not contain material that has been submitted or published elsewhere.

Letters accepted for publication will appear in print, on our website at NEJM.org, or both.

Please note the following:

- Letters in reference to a *Journal* article must not exceed 175 words (excluding references) and must be received within 3 weeks after publication of the article.
- Letters not related to a *Journal* article must not exceed 400 words.