

Identification of a Potential Molecular Diagnostic Biomarker in Keloid Disease: Syndecan-1 (CD138) Is Overexpressed in Keloid Scar Tissue



JID Open

Journal of Investigative Dermatology (2016) **136**, 2319–2323; doi:10.1016/j.jid.2016.06.623

TO THE EDITOR

The diagnosis between different forms of raised dermal scarring such as

hypertrophic (HTS) and keloid scars (KS) can be difficult in the absence of a specific biomarker (Atiyeh, 2007; Lee

et al., 2004). Importantly, the differentiation can be critical before initiation of treatment, as misdiagnosis followed by inappropriate therapy may result in worsening of the outcome by increasing rate of recurrence in keloids (Viera et al., 2012). Therefore, the aim here was to identify a molecular diagnostic biomarker capable of distinguishing KS from other forms of

Abbreviations: DFSP, dermatofibrosarcoma protuberan; HTS, hypertrophic scars; KS, keloid scars; NS, normal scar

Accepted manuscript published online 14 July 2016; corrected proof published online 18 August 2016

© 2016 The Authors. Published by Elsevier, Inc. on behalf of the Society for Investigative Dermatology. This is an open access article under the CC BY-NC-ND license (<http://creativecommons.org/licenses/by-nc-nd/4.0/>).

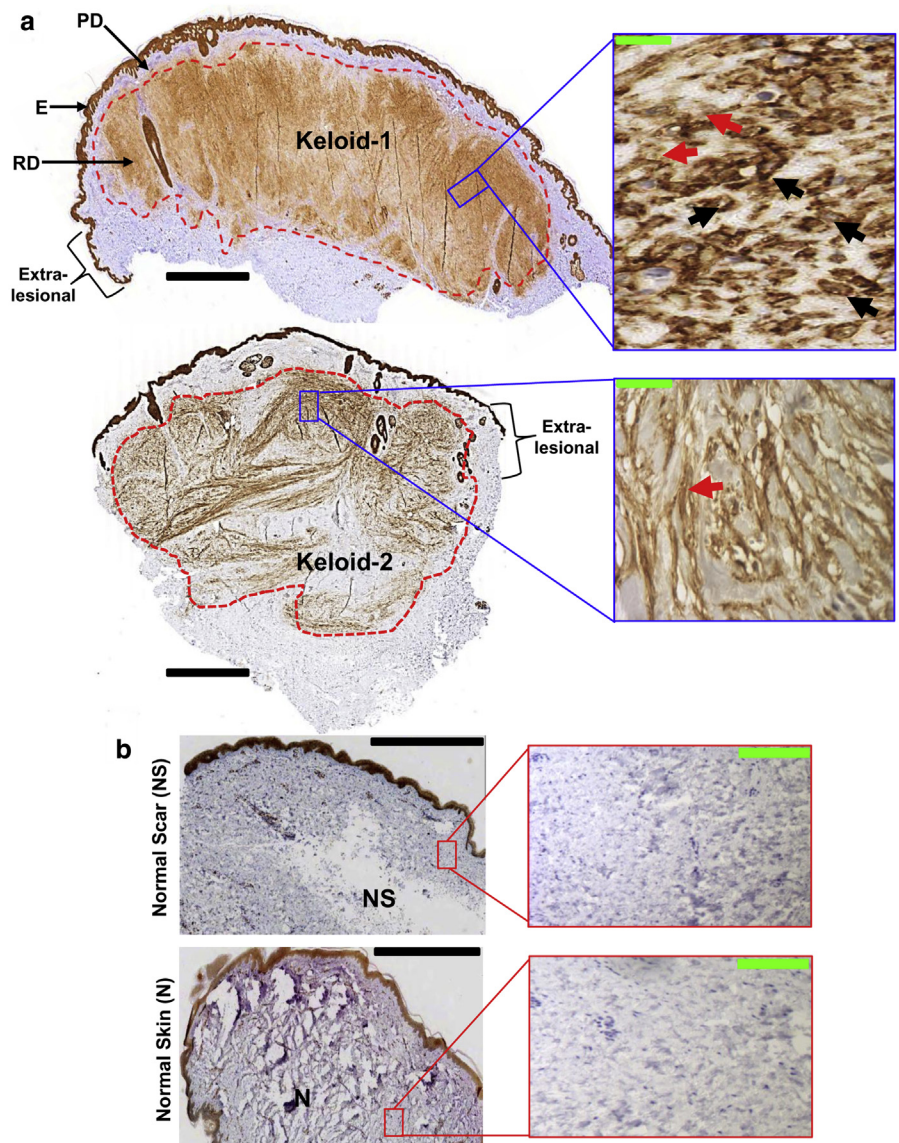


Figure 1. Representative immunohistochemical micrographs of syndecan-1 (CD138) overexpression in keloid compared with normal scar and normal skin tissue. There is overexpression of syndecan-1 immunoreactivity within keloid reticular dermis, sparing papillary dermis; scale bar (black) = 1 mm and scale bar (green) = 50 μ m (a), relative to NS and normal skin; scale bar (black) = 500 μ m and scale bar (green) = 100 μ m (b). Expression is observed on cells (black arrows) and to some extent in extracellular matrix (red arrows). Paraffin-embedded tissues for 65 keloid samples, 11 NS, and 11 normal skins were sectioned at 5 μ m. Then, they were dewaxed, dehydrated, and labeled with a syndecan-1 antibody and detected using chromogen. Slides were scanned using ScanScope (Aperio Technology, Oxford, UK). Micrographs were captured at 8 magnifications, and inserts were captured at 200 and 400 magnifications. E, epidermis; KS, keloid scar; N, normal skin; NS, normal Scar; PD, papillary dermis; RD, reticular dermis.

dermal scarring specially HTS and also dermatofibrosarcoma protuberans (DFSPs)—an uncommon progressive, reticular dermal neoplasm with high recurrence. Often, keloid and/or DFSP are misdiagnosed (Kimura et al., 2014, Nguyen et al., 2002, Nicholas and Stodell, 2014, Suarez et al., 2015). We have demonstrated immune upregulation and the presence of lymphoid

aggregates while investigating the presence of plasma cells in 63 KS tissue samples (Bagabir et al., 2012) using immunohistochemistry, and serendipity that led to the identification of abundant expression of CD138 in KS. Localized abundant expression of CD138 within the keloid lesion had drawn our attention to further understand the link between CD138 and keloid.

CD138 (syndecan-1) is a cell surface proteoglycan, which is shed by the expressing cells into the extracellular matrix (Szatmári et al., 2015). Syndecan-1 is present in neonatal scars, while its lack of expression in scar-less fetal wound healing (Gallo et al., 1996) suggests a potential functional role for syndecan-1 in fibrosis in scar formation. Interestingly, syndecan-1 binds to the collagens and fibronectin deposited during tissue repair, as a consequence of which the tissue reverts to a quiescent state (Szatmári et al., 2015). It modulates cell proliferation, migration, and tumor progression in cancer cells (Szatmári et al., 2015), and regulates keratinocyte proliferation and the proteolytic balance in healing wounds (Stepp et al., 2015).

To follow up the overexpression of syndecan-1 in keloid and to probe the hypothesis that it may be a unique, previously unreported, biomarker, its expression in KS was compared with HTS, DFSP tumor, normal scar (NS), and normal skin. For all the tissue samples used in this study, ethical approval was obtained from NHS Ethical Committee, Manchester, UK. All cases recruited gave full informed verbal and written consent to take part in the study (ethical reference number 11/NW/0638). The in situ staining of keloid (n = 65), NS (n = 11), DFSP (n = 10), HTS (n = 3) (see [Supplementary Material and Methods](#) online for details), and normal skins (n = 11) showed a clear overexpression of syndecan-1 in keloid when compared to HTS, DFSP, NS, and normal skin. Keloid cross-sections revealed an intensive immune reactivity of syndecan-1 within keloid reticular dermis (Figure 1a and [Supplementary Figure S1](#) online), whereas perilesional skin lacked its expression. Surprisingly, in situ syndecan-1 expression was mild to absent in HTS and NS, respectively, and completely absent in healthy skin and in DFSP tumors when compared with keloid (Figures 1b and 2a and [Supplementary Figures S1–S5](#) online). However, the expression pattern of syndecan-1 was variable in between the keloid samples from different patients and/or different anatomical sites ([Supplementary Figure S1](#) and [Table S1](#) online). Minimal to no expression of syndecan-1 was detected in HTS

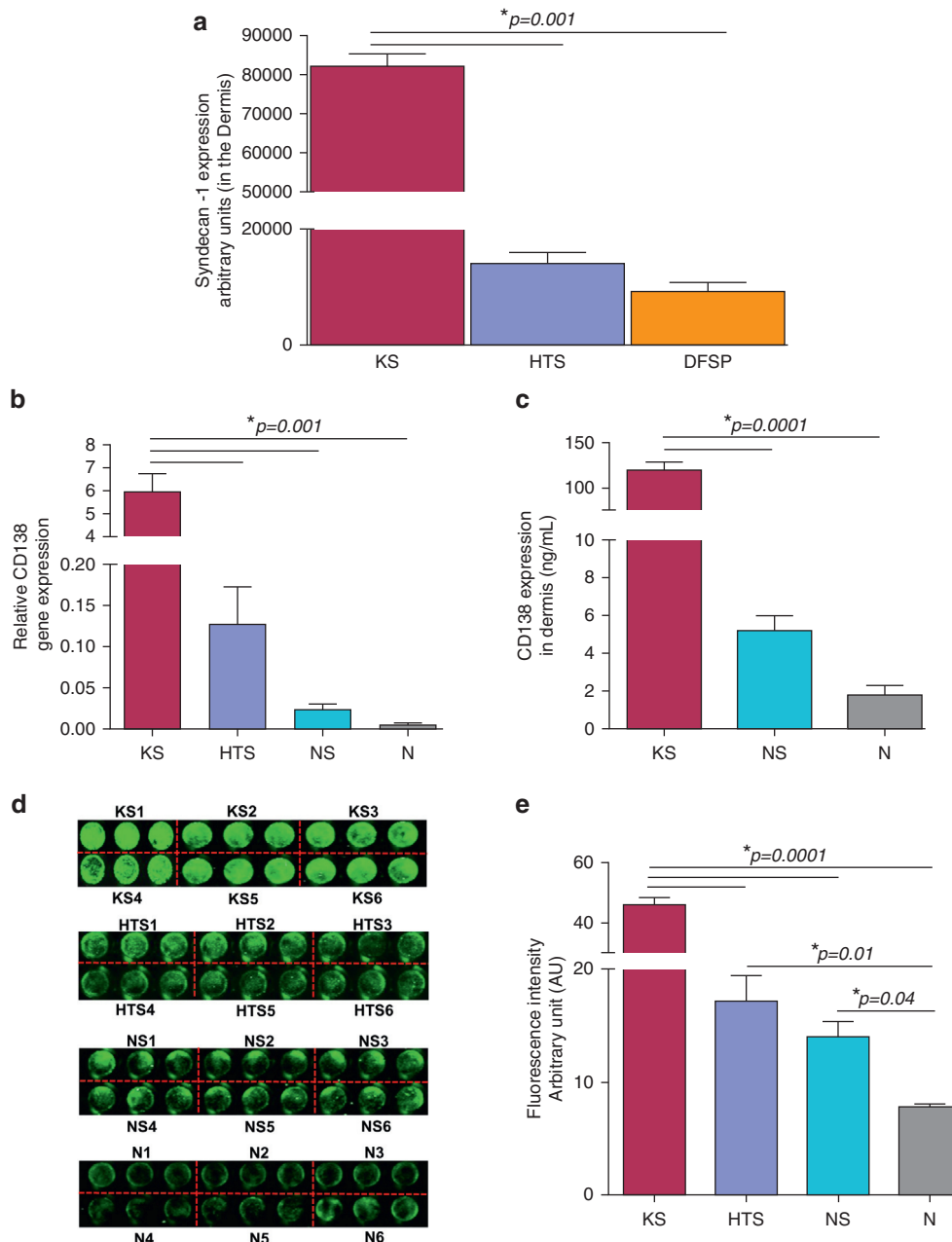


Figure 2. Significant overexpression of syndecan-1 (CD138) at transcriptional and translational level in keloid tumor compared with normal scar and normal skin. (a) Bar graphs represent the immunomorphometric quantitative analysis of CD138 expression in keloid (KS, n = 9), hypertrophic scars (HTS, n = 3), and in DFSP (n = 10) tumor tissue samples. A significant increase in syndecan-1 protein expression ($*P = 0.001$) was detected in keloid as compared with HTS and DFSP tumor tissue. (b) Overexpression of mRNA in keloid intralesional tissue compared with hypertrophic scar (HTS), normal scar (NS), and normal skin (N) dermal tissue. Fold change of syndecan-1 mRNA in the KS-defined lesional site relative to HTS, NS, and normal skin. Primers for syndecan-1 were designed (Supplementary Table S5 online). mRNA was extracted from full-thickness tissue derived from defined KS site intralesion (n = 9), HTS (n = 4), NS dermis (n = 8), and normal skin dermis (n = 7). Two micrograms of mRNA was reverse transcribed and the quantitative real-time RT-PCR reaction was carried out. The cycle threshold (Ct) values were normalized to the geometric mean of two housekeeping genes (SDHA: succinate dehydrogenase complex subunit A and RPL32: 60S ribosomal protein L32) and analyzed by fold change ($2^{-\Delta\Delta CT}$) relative to NS and normal skin. Error bars represent mean \pm SEM. (c) Ex vivo quantitative measurement of syndecan-1 in keloid, NS, and normal skin dermal lysates. Syndecan-1 protein was extracted from keloid (n = 8) intralesional site (core of the keloid tissue) and dermis of NS (n = 6) and normal skin (n = 6), using modified radioimmunoprecipitation assay buffer. ELISA was performed in triplicate as described in Supplementary Material and Methods. Results are presented as mean \pm SEM. (d) Syndecan-1 expression profile in keloid (core region of keloid), HTS, NS, and normal skin primary fibroblasts isolated from the dermis. Serum-starved keloid fibroblasts were seeded in 96-well plates (1.0×10^4 cells/well) and grown up to 24 hours. The cells were then fixed with 4% formaldehyde/phosphate-buffered saline. After blocking, syndecan-1 was detected by incubation with anti-CD138, followed by incubation with an IRDye 800-labeled secondary antibody. The representative output infrared image of a 96-well plate shows the syndecan-1 expression pattern across different fibroblast cell lines. (e) Bar graphs represent the quantification of mean syndecan-1 protein expression in KS, HTS, NS, and normal skin primary fibroblast cell lines. Results are presented as mean \pm SEM of triplicates (n = 6). HTS, hypertrophic scars; KS, keloid scar; N, normal skin; NS, normal scar; SEM, standard error of the mean.

and NS dermis, but consistent higher expression was seen in keratinocytes and endothelial cells in all the tissue samples including DFSP (Supplementary Figures S2–S5). Interestingly, syndecan-1 immunoreactivity was localized within the keloid tumor mass, keloid stroma, and epidermis, sparing papillary dermis. Its expression was both cellular and in the extracellular matrix. However, the expression of syndecan-1 was absent in the dermis in normal skin adjacent to keloid tissue (extralesional) (Figure 1a and Supplementary Figure S1).

To further corroborate the above findings and to compare CD138 expression between KS and HTS, we assessed its mRNA and protein expression in KS (n = 13), HTS (n = 10), NS tissue (n = 9), and healthy skin (n = 8) by quantitative RT-PCR, ELISA, and in-cell western blotting (see Supplementary Material and Methods for details, and Supplementary Tables S1–S4 online for patient demographic data). The results corresponded with a significant increase in syndecan-1 gene expression ($P = 0.001$) in keloid relative to NS, normal skin, as well as HTS (Figure 2b). Despite the increased expression of CD138 at mRNA level in HTS compared with controls, there was no statistically significant difference ($P > 0.05$). Therefore, quantitative protein analysis was also conducted in keloid, HTS, NS, and normal skin. Syndecan-1 protein level was significantly overexpressed ($P = 0.001$) in keloid dermis using anti-human syndecan-1 ELISA and in cultured keloid fibroblasts using the in-cell western blotting technique (see Supplementary Material and Methods for details), relative to NS and normal skin (Figure 2c–e). Although there was a significant increase in the expression of syndecan-1 in HTS and NS tissue compared with normal skin ($P < 0.05$), this could also reflect endogenous syndecan-1 from either immune cells and/or epithelial cells from adnexal structures/sweat glands in HTS and NS dermis, which was also detected in the tissue staining (Supplementary Figures S2–S4).

Syndecan-1 plays an important role as a cell adhesion and growth factor-binding molecule not only during embryogenesis but also during tissue

regeneration in mature tissues. Overexpression of syndecan-1 in basal keratinocytes promotes proliferation during epidermal development, but restricts proliferation during wound healing (Stepp et al., 2015). Currently, the mechanism behind high expression of syndecan-1 in epidermis across all the tissue samples used in this study remains unclear. Based on increasing insight into the role of syndecan-1 in the pathobiology of fibrotic diseases and cancer, to our knowledge previously unreported, our findings encourage one to follow up, next, whether syndecan-1 is functionally involved in the progression of fibrogenesis and the maintenance of chronic, fibrogenic inflammation in KS (Bagabir et al., 2012). It has previously been shown that microRNA-143 is downregulated in melanoma and negatively regulates overexpressed syndecan-1 (Li et al., 2014). Interestingly, a comparative study of microRNA profiling in fibroblast also showed that microRNA-143 is downregulated in keloid (Li et al., 2013). This may be investigated most instructively in the KS organ culture, using previously published in situ gene knockdown techniques (Syed et al., 2013). The distinction between DFSP tumor and scar tissue surrounding the tumor in the DFSP sample is quite interesting in terms of syndecan-1 expression and needs further elucidation. Histologically, scar tissue consists of fascicles of fibroblasts/myofibroblasts that have relatively plump nuclei as opposed to the slender nuclei of DFSP. Moreover, the fascicles in scar tissue are longer and have horizontal orientation as opposed to DFSPs that in typical cases have short fascicles arranged in a prominent storiform pattern. CD34 also helps to distinguish scar tissue from DFSPs. The former is generally negative, whereas DFSPs show strong and diffuse staining. Furthermore, the lesional cells that constitute DFSPs are fibrohistiocytic cells or cells related to dermal dendritic cells and not pure fibroblasts, whereas in scar tissue surrounding to DFSP tumor may have a keloid-like environment or may have mainly myofibroblasts, hence the difference in expression of CD138, which need to be further investigated in future. In summary, one can use a combination

of morphological analysis and CD34 immunostaining to distinguish scar tissue from DFSP (Prieto et al., 1994). It can however be difficult in some cases; therefore, CD138 may add to the ancillary studies used in solving this dilemma.

In conclusion, we have shown, previously unreported, that syndecan-1 is significantly overexpressed in keloid compared with HTS and NS, and completely absent in DFSP. Beyond its potential value as a biomarker, to our knowledge previously unreported, to distinguish between keloid and HTS, syndecan-1 can also be used as a vital diagnostic marker to distinguish misdiagnosis between keloid and DFSP, as it has been clearly shown in the tumor tissue samples in this study and in the previous studies, corroborating our findings, that DFSPs do not express syndecan-1 in dermis (O'Connell et al., 2004; Orosz and Kopper, 2000).

CONFLICT OF INTEREST

The authors state no conflict of interest.

ACKNOWLEDGMENTS

We thank Dr Iskander Chaudhry for his expert advice. This study was partially supported by a grant from the Ministry of Higher Education in Saudi Arabia.

Rania A. Bagabir^{1,2,3},
Farhatullah Syed^{1,2,4},
Patrick Shenjere⁵, **Ralf Paus**² and
Ardeshir Bayat^{1,2,*}

¹Plastic and Reconstructive Surgery Research, University of Manchester, Manchester, UK;

²The Dermatology Centre, Institute of Inflammation and Repair, Faculty of Medical and Human Sciences, University of Manchester, Manchester Academic Health Science Centre, Manchester, UK; ³Department of Hematology and Immunology, Medical Faculty, Umm Al-Qura University, Mecca, Saudi Arabia; ⁴Institute of Child Health, Molecular and Cellular Immunology Unit, UCL, London, UK; and ⁵Department of Histopathology, the Christie NHS Foundation Trust, Christie Hospital, Manchester, UK

*Corresponding author e-mail: ardeshir.bayat@manchester.ac.uk

SUPPLEMENTARY MATERIAL

Supplementary material is linked to the online version of the paper at www.jidonline.org, and at <http://dx.doi.org/10.1016/j.jid.2016.06.623>.

REFERENCES

Atiyeh BS. Nonsurgical management of hypertrophic scars: evidence-based therapies, standard practices, and emerging methods. *Aesthetic Plast Surg* 2007;31:468–92.

- Bagabir R, Byers R, Chaudhry I, Müller W, Paus R, Bayat A. Site-specific immunophenotyping of keloid disease demonstrates immune upregulation and the presence of lymphoid aggregates. *Br J Dermatol* 2012;167:1053–66.
- Gallo R, Kim C, Kokenyesi R, Adzick NS, Bernfield M. Syndecans-1 and -4 are induced during wound repair of neonatal but not fetal skin. *J Invest Dermatol* 1996;107:676–83.
- Kimura K, Yamauchi W, Kashimura T. Dermatofibrosarcoma protuberans on the chest with a variety of clinical features masquerading as a keloid: is the disease really protuberant? *Ann Dermatol* 2014;26:643–5.
- Lee JY-Y, Yang C-C, Chao S-C, Wong T-W. Histopathological differential diagnosis of keloid and hypertrophic scar. *Am J Dermatopathol* 2004;26:379–84.
- Li C, Bai Y, Liu H, Zuo X, Yao H, Xu Y, et al. Comparative study of microRNA profiling in keloid fibroblast and annotation of differential expressed microRNAs. *Acta Biochim Biophys Sin (Shanghai)* 2013;45:692–9.
- Li R, Zhang L, Jia L, Duan Y, Li Y, Wang J, et al. MicroRNA-143 targets syndecan-1 to repress cell growth in melanoma. *PLoS One* 2014;9:e94855.
- Nguyen CM, Burch JM, Fitzpatrick JE, Peterson SL, Weston WL. Giant cell fibroblastoma in a child misdiagnosed as a dermatofibroma. *Pediatr Dermatol* 2002;19:28–32.
- Nicholas RS, Stodell M. An important case of misdiagnosis: keloid scar or high-grade soft-tissue sarcoma? *BMJ Case Rep* 2014;2014:1–2. pii: bcr2014203600.
- O'Connell FP, Pinkus JL, Pinkus GS. CD138 (syndecan-1), a plasma cell marker immunohistochemical profile in hematopoietic and nonhematopoietic neoplasms. *Am J Clin Pathol* 2004;121:254–63.
- Orosz Z, Kopper L. Syndecan-1 expression in different soft tissue tumours. *Anticancer Res* 2000;21:733–7.
- Prieto VG, Reed JA, Shea CR. CD34 immunoreactivity distinguishes between scar tissue and residual tumor in re-excisional specimens of dermatofibrosarcoma protuberans. *J Cutan Pathol* 1994;4:324–9.
- Stepp MA, Pal-Ghosh S, Tadvalkar G, Pajoohesh-Ganji A. Syndecan-1 and its expanding list of contacts. *Adv Wound Care (New Rochelle)* 2015;4:235–49.
- Suarez E, Syed F, Alonso-Rasgado T, Bayat A. Identification of biomarkers involved in differential profiling of hypertrophic and keloid scars versus normal skin. *Arch Dermatol Res* 2015;307:115–33.
- Syed F, Bagabir RA, Paus R, Bayat A. Ex vivo evaluation of antifibrotic compounds in skin scarring: EGCG and silencing of PAI-1 independently inhibit growth and induce keloid shrinkage. *Lab Invest* 2013;93:946–60.
- Szatmári T, Otvos R, Hjerpe A, Dobra K. Syndecan-1 in cancer: implications for cell signaling, differentiation, and prognostication. *Disease Markers* 2015;2015:796052.
- Viera MH, Vivas AC, Berman B. Update on keloid management: clinical and basic science advances. *Adv Wound Care (New Rochelle)* 2012;1:200–6.



This work is licensed under a Creative Commons Attribution-NonCommercial-NoDerivatives 4.0 International License. To view a copy of this license, visit <http://creativecommons.org/licenses/by-nc-nd/4.0/>