



Three-dimensional surface scanners compared with standard anthropometric measurements for head shape



Caroline A.A. Beaumont^{a,b,*}, Paul G.M. Knoops^a, Alessandro Borghi^a,
N.U. Owase Jeelani^a, Maarten J. Koudstaal^{a,b}, Silvia Schievano^a, David J. Dunaway^a,
Naiara Rodriguez-Florez^a

^a UCL Great Ormond Street Institute of Child Health, London, United Kingdom & Craniofacial Unit, Great Ormond Street Hospital for Children, London, United Kingdom

^b Erasmus University Medical Center, Rotterdam, The Netherlands

ARTICLE INFO

Article history:

Paper received 30 October 2016

Accepted 15 March 2017

Available online 29 March 2017

Keywords:

Three-dimensional imaging

Three-dimensional surface scanning

Anthropometry

Craniofacial surgery

Maxillofacial surgery

ABSTRACT

Three-dimensional (3D) surface imaging devices designed to capture and quantify craniofacial surface morphology are becoming more common in clinical environments. Such scanners overcome the limitations of two-dimensional photographs while avoiding the ionizing radiation of computed tomography. The purpose of this study was to compare standard anthropometric cranial measurements with measurements taken from images acquired with 3D surface scanners.

Two 3D scanners of different cost were used to acquire head shape data from thirteen adult volunteers: M4D scan and Structure Sensor. Head circumference and cephalic index were measured directly on the patients as well as on 3D scans acquired with the two scanners. To compare head volume measurements with a gold standard, magnetic resonance imaging scans were used. Repeatability and accuracy of both devices were evaluated.

Intra-rater repeatability for both scanners was excellent (intraclass correlation coefficients > 0.99, $p < 0.001$). Direct and digital measures of head circumference, cephalic index and head volume were strongly correlated ($0.85 < r < 0.91$, $p < 0.001$). Compared to direct measurements, accuracy was highest for M4D scan.

Both 3D scanners provide reproducible data of head circumference, cephalic index and head volume and show a strong correlation with traditional measurements. However, care must be taken when using absolute values.

© 2017 The Authors. Published by Elsevier Ltd on behalf of European Association for Cranio-Maxillo-Facial Surgery. This is an open access article under the CC BY license (<http://creativecommons.org/licenses/by/4.0/>).

1. Introduction

Until recently, capturing head shape had been limited to measurements using traditional instruments (e.g. spreading calipers and measurement tapes) during examination (Farkas, 1996). These “direct” measurements are simple and inexpensive to make. Nevertheless, there are several limitations to the use of direct anthropometry, including training on live subjects, and the time-consuming nature of performing multiple direct measurements during clinics (Wong et al., 2008; Schaaf et al., 2010). Also, previous

studies have questioned the reliability of using calipers as diagnostic devices in cranial measurements (McGarry et al., 2008). Care is required to accurately locate bony landmarks and to prevent inconsistent measurements due to the displacement of soft tissue (Schaaf et al., 2010).

There is growing interest in overcoming the limitations of direct anthropometry by using computer-based techniques to capture craniofacial surface images. Two-dimensional (2D) photographs are commonly used to facilitate visualization, assessment, and treatment of facial abnormalities in craniofacial care. However, these images are subject to errors because of perspective, projection and lack of metric and three-dimensional (3D) information (Enciso et al., 2004).

3D surface imaging devices designed to capture and quantify craniofacial surface morphology are becoming more common in

* Corresponding author. Department of Oral and Maxillofacial Surgery, Erasmus University Medical Center, Sophia Children's Hospital Rotterdam, 's Gravendijkwal 230, 3015 CE Rotterdam, The Netherlands.

E-mail address: c.beaumont@erasmusmc.nl (C.A.A. Beaumont).

clinical and research environments (Da Silveira et al., 2003; Fourie et al., 2011; Knoops et al., 2017; Plooij et al., 2011). To address limitations of the two-dimensional imaging systems, a variety of noninvasive methods are now available to generate 3D surface craniofacial images such as laser scans, stereo-photogrammetry, and infrared imaging (Enciso et al., 2004; Weinberg et al., 2006; Tzou et al., 2014). These techniques could contribute to objective evaluation of head shape for effective treatment planning (Heller et al., 2008; Plooij et al., 2011), postoperative assessment (Rodriguez-Florez et al., 2017; Tenhagen et al., 2016), and describing patterns of craniofacial growth and variation (Ifflaender et al., 2013; Meyer-Marcotty et al., 2014). However, in the context of 3D anthropometry, different aspects of measurement error should be considered, including repeatability, accuracy, and bias.

Anthropometric measurements of head shape, including head circumference (HC), cephalic index (CI), and head volume (HV), are commonly used in clinic (Farkas, 1996; Kamdar et al., 2009; Ifflaender et al., 2013; Jayaratne and Zwahlen, 2014). HC, CI, and HV are useful parameters for monitoring growth of the head in healthy children (Kamdar et al., 2009; Meyer-Marcotty et al., 2014). Also, in patients with craniosynostosis who undergo cranial surgery, anthropometry is a valuable method for pre- and post-operative evaluation and follow-up (Heller et al., 2008; Wilbrand et al., 2011, 2012; Skolnick et al., 2015).

3D surface scans are widely used to acquire head shape data; however, their price ranges vary highly (Weinberg et al., 2006; Skolnick et al., 2015). New technologies such as hand-held scanners have gained popularity because of their user-friendliness and substantial lower price and therefore would be an appealing option for cross-center studies (McKay et al., 2010; Fourie et al., 2011). However, a systematic comparison of capturing the head shape to measure HC, CI, and HV with different noninvasive 3D imaging techniques has not yet been done.

The aim of this study is to assess the use of different noninvasive portable 3D digital systems to measure anthropometric parameters typically used in clinics to evaluate head shape. This is achieved by capturing the head shape with two 3D cameras of different costs and comparing anthropometric measurements inferred from these scans with traditional methods: HC and CI are compared with direct caliper measurements, whereas HV is compared with volumes measured from magnetic resonance imaging (MRI) head scans.

2. Materials and methods

2.1. Subjects and procedures

The study group consisted of 13 healthy adults, six males and seven females, aged 23–37 years (mean 31 ± 4 years). All volunteers gave informed written consent for participation in this study. The project was approved by the UCL GOS Institute of Child Health research ethics committee under the title 'Changing Heads, Changing Faces' (R&D ref: 14DS25).

Direct anthropometry was performed to measure head circumference (HC) and cephalic index (CI). A single rater was trained in direct anthropometric techniques by reviewing Farkas' (1994) atlas of anthropometry and accompanying instructional videos. HC, which included the glabella and opisthocranium (Farkas, 1996), was measured with a standardized fabric measuring tape. CI was defined as the ratio between head width and length, which were measured directly from the subject using a caliper (Moore & Wright, Sheffield, England). Width was measured from the left euryon to the right euryon; length was measured from the glabella to the opisthocranium. These landmarks are widely used and originally defined by Farkas (Farkas and Posnick, 1992).

Besides direct anthropometry, 3D head scans were obtained using the following two noninvasive hand-held scanning devices:

1. The M4D Scan provided by Rodin 4D (Pessac, Aquitaine, France) is based on white LED structured light. The manufacturer-given scan accuracy of the M4D Scan is 0.5 mm and the resolution 1 mm. M4D scanner data were acquired by one well-trained operator. The volunteer sat still with a neutral head position, while the operator moved the scanner around the head of the volunteer.
2. The Structure Sensor (Occipital Inc., San Francisco, CA, USA) is an iPad accessory based on infrared structured light (Structure Sensor, 2016). The manufacturer-given scan accuracy of the Structure Sensor is 4 mm and the resolution 0.5 mm. The Structure Sensor data collection was performed by the same operator in the same way as for the M4D Scanner.

We calculated the average scanning for each device to make a complete scan of the head based on our scans.

Each volunteer was fitted with a tight nylon cap when scans with both scanners were taken to avoid artifacts due to hair on the head and to better capture the head shape.

Stereolithography (STL) files extracted from the cameras were imported in Rhinoceros 5 (64-bit). The same linear measurements as performed directly on the volunteer's heads (HC and CI) were performed on the 3D scans. A plane cut through the glabella and opisthocranium was made to calculate HC (Fig. 1). For head width and length, which were used to calculate CI, the same landmarks were used as for direct measurement (Fig. 2).

Magnetic resonance imaging (MRI) was used as the gold standard for volume measurements, as it is a well-accepted technique for capturing head volumes (Sgouros et al., 1999). Scans were obtained using a 1.5T clinical MR Avanto scanner (Siemens Healthcare, Erlangen, Germany) with a slice thickness of 1 mm. Data were exported as digital imaging and communications in medicine (DICOM) files. Mimics (Materialise, Leuven, Belgium) was used to acquire 3D reconstructions from DICOM files, using skin threshold values (lower threshold of 80, upper threshold maximum value). Eventually the images were saved as STL files. In Rhinoceros, a plane cut was made using the sellion and both tragions as landmarks (Ifflaender et al., 2013; McKay et al., 2010) to measure head volume (Fig. 3).

2.2. Data analysis

Repeatability of the imaging and postprocessing steps was determined by acquiring and measuring five different scans of the same participant with both the M4D scanner and Structure Sensor,

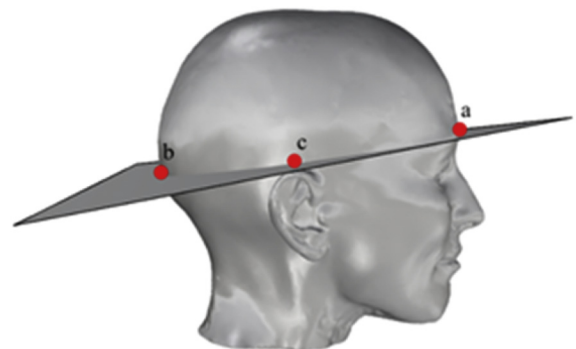


Fig. 1. Plane cut used to measure head circumference. The red dots display the landmarks glabella (a), opisthocranium (b), and right euryon (c).

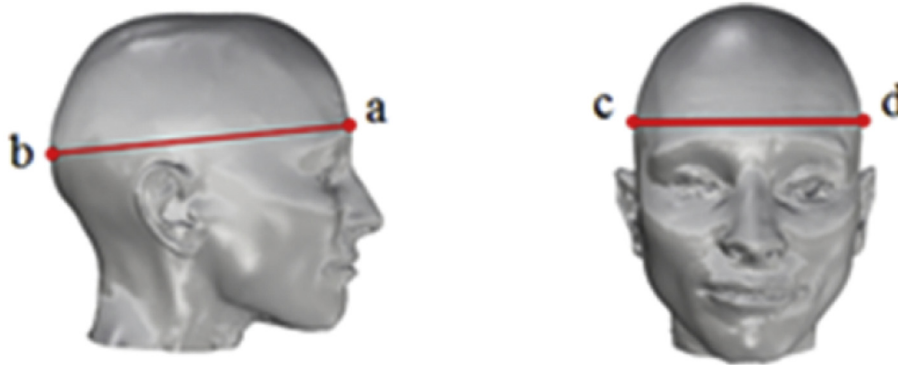


Fig. 2. Landmarks to measure head length and width. The red dots display the glabella (a) and opisthocranium (b) for length, and the right euryon (c) and left euryon (d) for width.

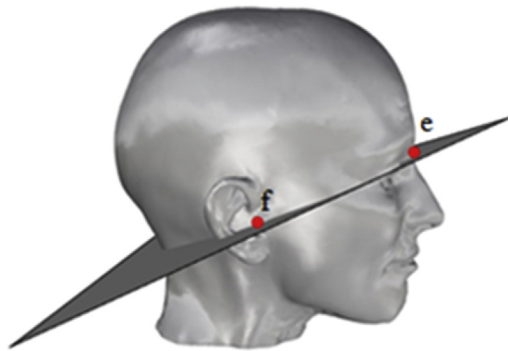


Fig. 3. Plane cut to measure head volume. The red dots display the landmarks sellion (e) and right tragion (f).

with time intervals of at least 12 h. Repeatability was defined by intraclass coefficient (ICC) as well as by the maximum error.

Pearson r correlations between direct and digital measurements were calculated. The accuracy of the M4D scanner and Structure Sensor was determined by the degree of congruence between the different 3D devices and direct anthropometry (for HC and CI) and MRI (for HV), determined by subtracting 3D measurements from standard measurements. Accuracy was evaluated with Bland–Altman plots (Bland and Altman, 1986) as well as by calculating bias.

Statistical tests were performed with IBM SPSS Statistics 23 and were considered significant if $p < 0.05$.

Table 1

Measurements of head circumference using a measuring tape (Direct Measurement) and indirectly from scans acquired with the M4D and Structure Sensor scanners.

Patient	Direct Measurement (cm)	M4D Scanner (cm)	Structure Scanner (cm)
1	57.4	58.1	59.8
2	54.1	54.8	56.9
3	58.0	58.8	59.6
4	55.5	56.0	57.1
5	54.8	55.5	57.0
6	55.1	55.9	56.9
7	58.0	59.5	61.2
8	57.2	58.9	61.3
9	55.4	58.0	58.3
10	58.2	58.7	59.5
11	57.0	57.6	61.2
12	58.9	59.7	61.0
13	58.7	59.1	62.3

3. Results

Digital and direct measures for HC, CI, and HV are shown in Tables 1–3.

Repeatability measurements for the M4D scanner and Structure Sensor are shown in Tables 4 and 5. ICC for the five different measuring times was 0.998 ($p < 0.001$) for the M4D scanner and 0.990 ($p < 0.001$) for Structure Sensor. For the M4D scanner, the repeatability error for HC measurements was <0.5%, for CI 0.9%, and for HV 5.9%. For the Structure Sensor, the repeatability error for HC measurements was 0.8%, for CI 1.2%, and for HV 12.9%.

Table 2

Measurements of cephalic index using a caliper (Direct Measurement) and indirectly from scans acquired with the M4D and Structure Sensor scanners.

Patient	Direct Measurement (%)	M4D Scanner (%)	Structure Scanner (%)
1	81.3	79.4	82.3
2	75.7	75.4	76.8
3	75.9	78.2	79.7
4	72.8	77.0	76.1
5	84.2	81.3	86.5
6	75.0	75.4	77.6
7	69.9	72.2	73.3
8	79.7	82.3	80.7
9	76.2	77.8	79.2
10	73.4	71.4	75.2
11	70.8	71.9	74.0
12	77.0	77.8	75.0
13	76.5	78.9	77.1

Table 3

Measurements of head volume inferred from magnetic resonance imaging (MRI) and M4D and Structure Sensor scanners.

Patient	MRI (cm ³)	M4D Scanner (cm ³)	Structure Scanner (cm ³)
1	2342	2338	2659
2	1981	2086	2327
3	2093	2404	2553
4	2020	2214	2379
5	1960	2086	2109
6	1914	1950	1958
7	2494	2567	2747
8	2178	2346	2443
9	1897	2003	1800
10	2376	2359	2635
11	2175	2245	2545
12	2406	2302	2371
13	2418	2482	2790

Table 4
Measurements of head circumference, width, length, cephalic index (CI), and volume on five different scans of the same subject, acquired with the M4D scanner, as well as the mean measurement and standard deviation (SD).

Scan	Circumference (cm)	Width (mm)	Length (mm)	CI (%)	Volume (cm ³)
1	59.1	153	209	73.2	2266
2	59.0	153	209	73.2	2074
3	59.0	152	208	73.1	2055
4	58.8	154	208	74.0	2130
5	59.3	153	209	73.2	2170
Mean (SD)	59 (0.2)	153 (0.7)	208.6 (0.5)	73.2 (0.4)	2139 (84.3)

Table 5
Measurements of head circumference, width, length, cephalic index (CI), and volume on five different scans of the same subject, acquired with the Structure Sensor, as well as the mean measurement and standard deviation (SD).

Scan	Circumference (cm)	Width (mm)	Length (mm)	CI (%)	Volume (cm ³)
1	59.9	156	214	72.9	2134
2	60.0	158	213	74.2	2624
3	60.2	156	213	74.2	2375
4	60.4	155	212	73.1	2387
5	60.8	158	218	72.5	2738
Mean (SD)	60.3 (0.4)	156.6 (1.3)	214 (2.3)	73.4 (0.8)	2451.6 (235.9)

Figs. 4 and 5 display Pearson r correlations and Bland–Altman plots of direct and digital HC and CI measurements. Correlations of the direct measurements to their 3D scanner counterparts yielded Pearson r correlations of 0.89 ($p < 0.001$; M4D scanner) and 0.87 ($p < 0.001$; Structure Sensor) for HC and 0.85 ($p < 0.001$; M4D scanner) and 0.91 ($p < 0.001$; Structure Sensor) for CI. M4D scanner

and Structure Sensor measurements for HC and CI were consistently larger than direct measurements, with larger deviations for Structure Sensor than M4D scanner. The maximum error for the M4D scanner and Structure Sensor when measuring HC was 5% and 11%, respectively. For CI, the maximum error was 5.7% for the M4D scanner and 5% for Structure Sensor.

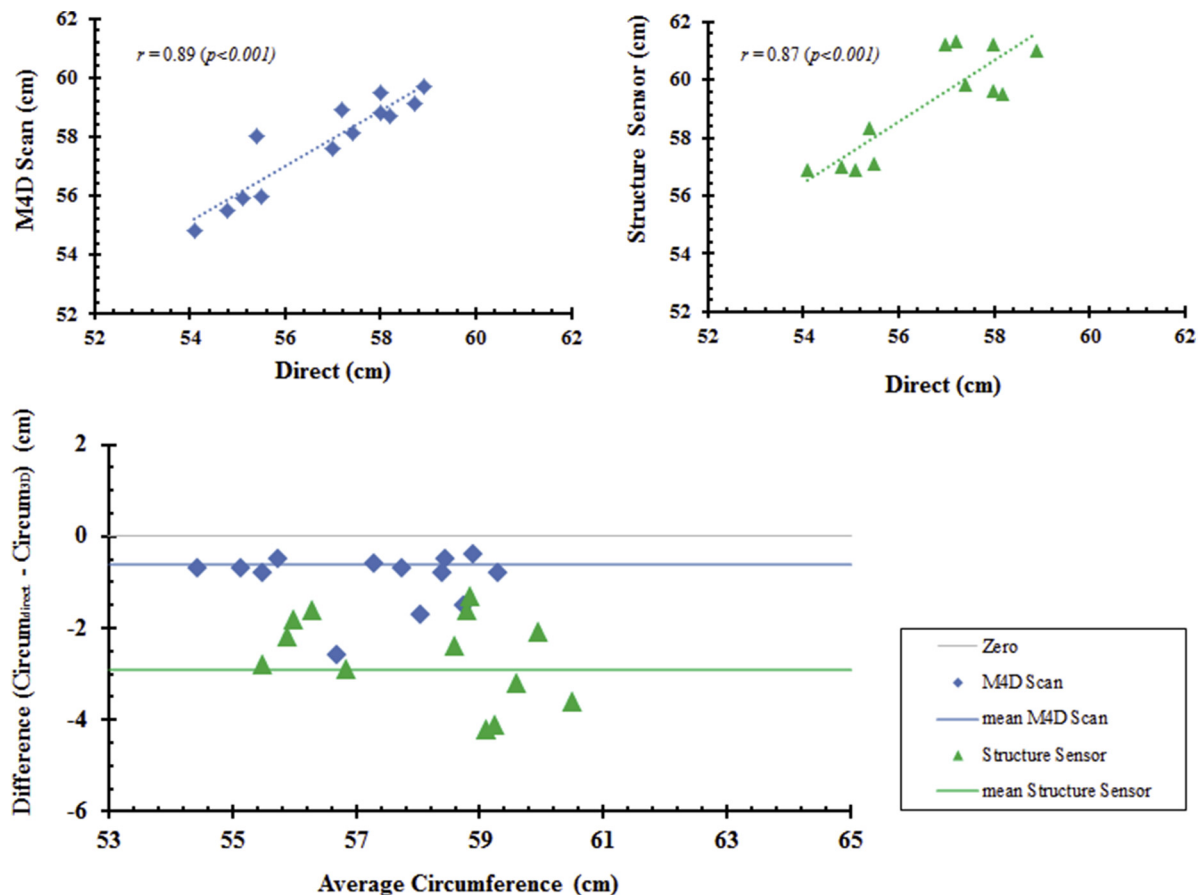


Fig. 4. Comparison of head circumference (HC) measured directly with a tape or with hand-held scanners. The upper two graphs show correlations between direct HC measurements and both 3D scanners, the lower two Bland–Altman plots show differences of HC plotted over the averages of the two different 3D scanning systems (M4D scanner and Structure Sensor) compared to direct measurements. Indicated are a zero line and two mean lines.

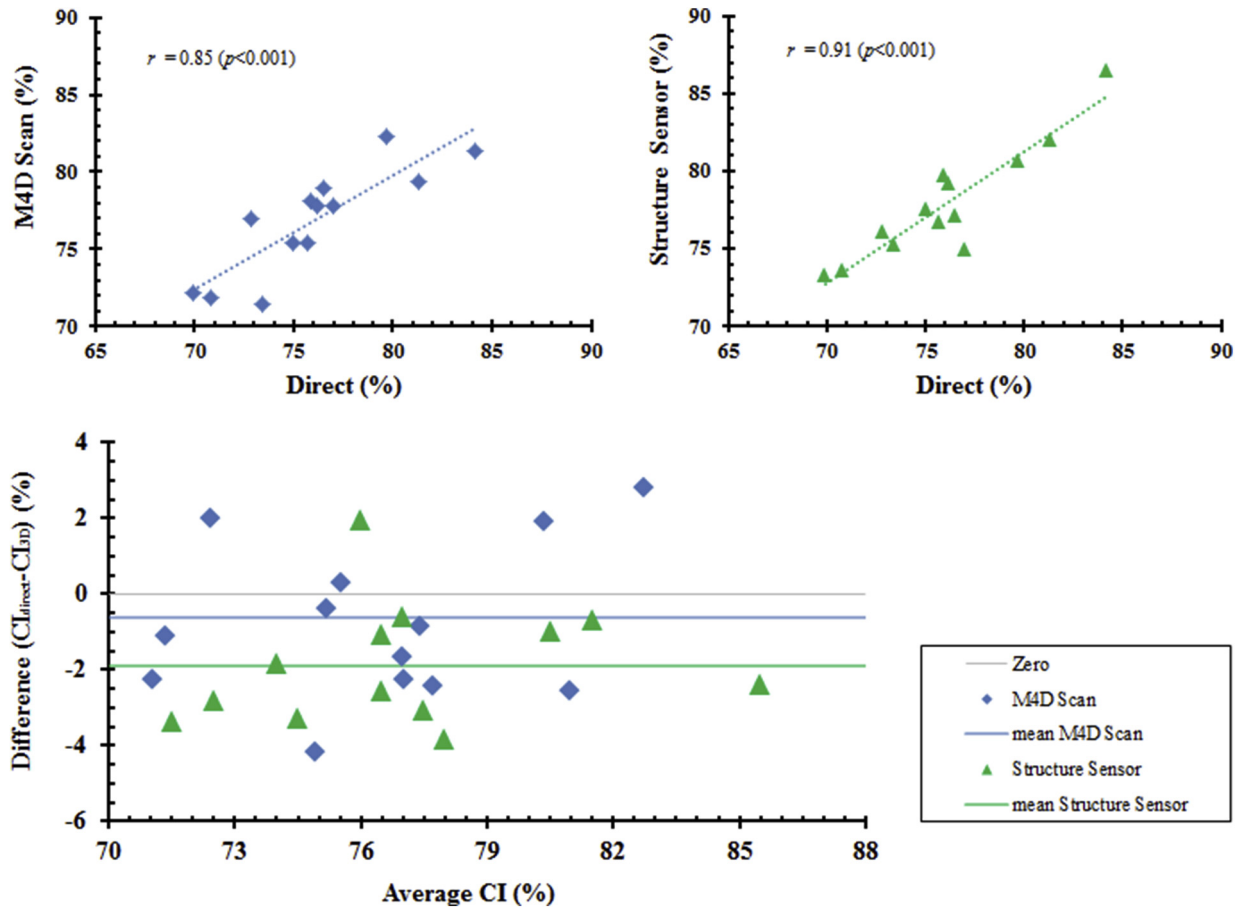


Fig. 5. Comparison of cephalic index (CI) measured directly with a calliper or with hand-held scanners. The upper two graphs show correlations between direct CI measurements and both 3D scanners. Below displays a Bland-Altman-Plot showing the differences of CI plotted over the averages of the two different 3D scanning systems (M4D scanner and Structure Sensor) compared to direct measurements.

Volume measurements of images taken by M4D scanner and Structure Sensor with MRI as a reference are shown in the Bland-Altman plot in Fig. 6. Pearson r correlations for cranial volume outcomes were 0.87 (MRI vs M4D scanner) and 0.83 (MRI vs Structure Sensor) ($p < 0.001$). Volumes measured by Structure Sensor yielded consistently larger values than M4D scanner differences, as is shown by the means of the two data sets. The maximum error for HV measurements with the M4D scanner was 15% and with the Structure Sensor 22%. Altogether, this displays a relative overestimation of Structure Sensor values compared to the M4D scanner and MRI.

Average scanning time for a complete scan of the head was 84 ± 12 s for the M4D Scan and 48 ± 18 s for the Structure Sensor.

4. Discussion

Analysis of 3D head shape is common in plastic and reconstructive cranio-maxillofacial surgery for diagnosis (Schaaf et al., 2010; Skolnick et al., 2015), surgical planning and evaluation (Plooj et al., 2011), and follow-up (Heller et al., 2008). Although linear and volumetric analysis of head shape using computed tomography (CT) have been used and allow great precision, accuracy, and reproducibility, the radiation exposure and the need for sedation make this modality less attractive when studying, for example, an infant's head and face (Posnick et al., 1993). 3D surface scanning circumvents these risks. Also, surface scans may

be obtained in out-patient clinics, thereby avoiding trips to other specialist departments and improving patient convenience. This study evaluated the use of such portable and noninvasive 3D cameras to measure head shape parameters by comparing head circumference (HC), cephalic index (CI) and head volume (HV) taken from 3D scans with traditional measurements.

HC, CI, and HV measurements on 3D scans showed excellent intrarater repeatability. Digital measurements were highly correlated with traditional techniques. However, both scanners gave consistently higher values than direct and MRI measurements. Overall, the M4D scanner measurements were the closest to direct (for HC and CI) and MRI (for HV) measurements.

The higher values can be explained by factors. First, whether a subject has hair on the head or not plays an important role. Our study group contained two bald subjects (numbers 6 and 10). Their results showed consistently smaller differences between digital and direct measurements than subjects with hair. Hair is indeed one of the limitations of surface scanners when compared to systems such as MRI or CT. An effort was made to minimize the effect of the hair by fitting all volunteers with a nylon cap while scans were taken. While small children do not pose a big challenge in this respect, using surface scanners on patients with thick hair might not always be feasible.

Another source of error when measuring head volume on 3D surface scans is the difficulty of identifying landmarks on the scans, particularly the Structure Sensor, as the meshes on the scans are coarse (Fig. 7). Therefore, it is important that the examiner can

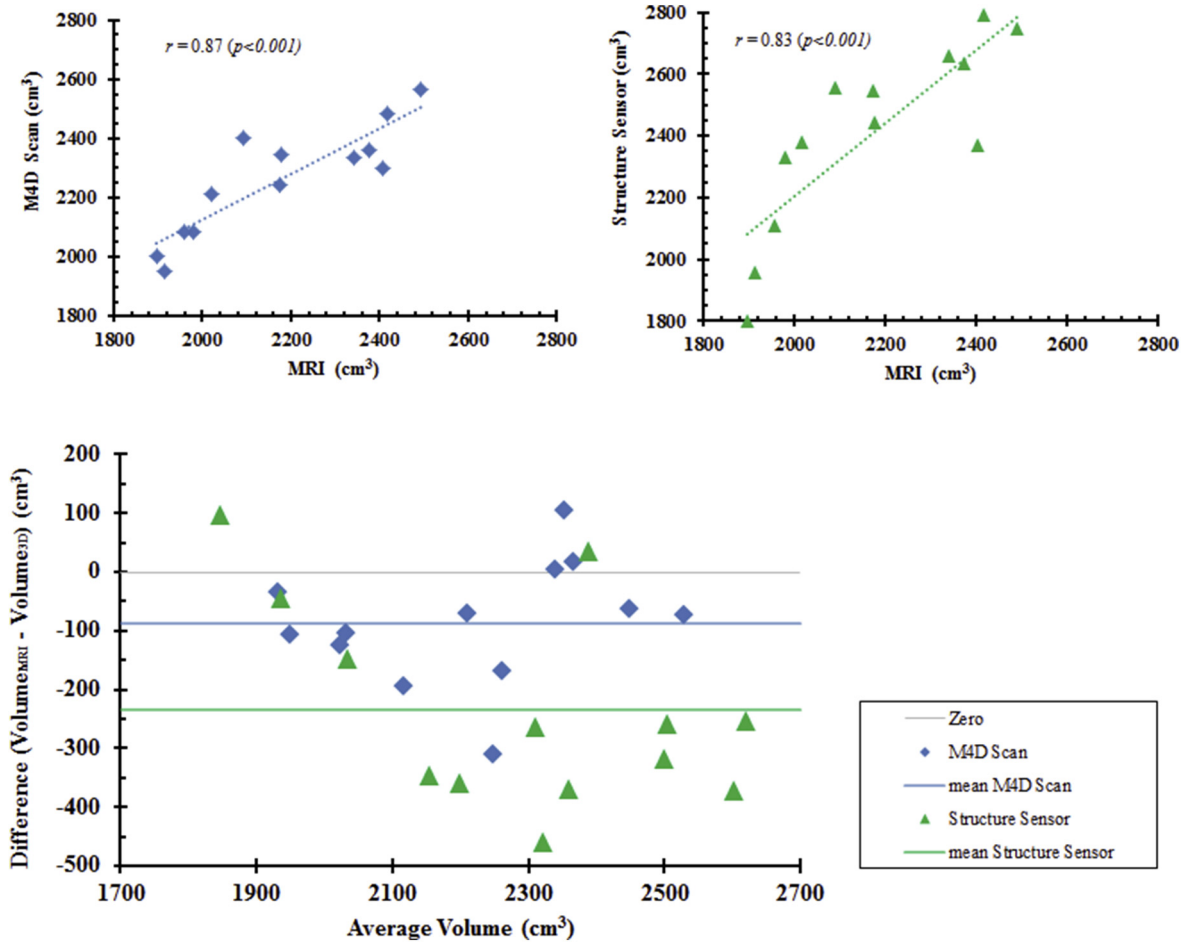


Fig. 6. Comparison of head volume (HV) measured from magnetic resonance imaging (MRI) or with hand-held scanners. The upper two graphs show correlations between MRI HV measurements and both 3D scanners. The plot below displays a Bland-Altman-Plot showing the differences of HV plotted over the averages of the two different 3D scanning systems (hand-held scanner and Structure Sensor) compared to direct measurements.

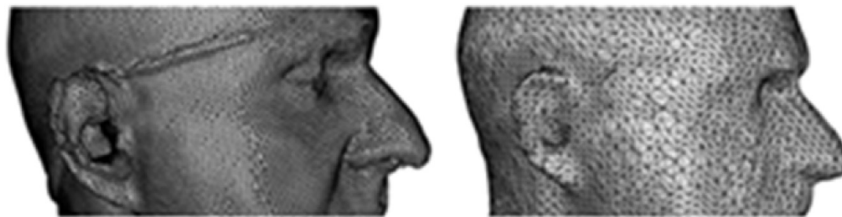


Fig. 7. Differences in mesh between M4D Scan (left) and Structure Sensor (right).

accurately place landmarks and to check intra-repeatability. Future multicenter studies should also take into consideration the possible inter-observer variabilities before comparing results.

In the craniofacial field, differences in head shape play an important role. In growing children, for example, the head shows an average increment of growth in head circumference of 6–7% between the age of 6 and 12 months (Meyer-Marcotty et al., 2014). In this study, both scanners showed an error of less than 1.5% for HC measurements, which means that both scanners can reliably be used for HC measurements in growing children. Cephalic index is a commonly used measurement to evaluate patients with cranial deformities (Schaaf et al., 2010). For example, in sagittal synostosis patients (aged 3–96 months) CI increases about 10% after surgery (Heller et al., 2008). The error for CI measured in this

study showed that both scanners are capable of capturing a change in CI of such order of magnitude. Head volume is commonly measured to illustrate head shape changes after cranial vault correction (Wilbrand et al., 2012; Freudlsperger et al., 2015). In patients (aged 7–12 months) with metopic synostosis, for example, measurements of total cranial volume revealed a significant increase from 1362 to 1519 cm³ after fronto-orbital advancement (Freudlsperger et al., 2015). This is an increase of 11.5%, which means that the M4D scanner would give adequate outcomes, while the error of Structure Sensor was 12.9% and thus has to be considered as not useful for capturing such head volume changes.

In summary, the M4D scanner is able to capture reliable head circumference, cephalic index, and head volume measurements.

The Structure Sensor is useful for both circumference and cephalic index, but one should be careful when measuring head volume with this device because it has shown to give a maximum error of nearly 13%.

One important consideration that has to be taken into account when evaluating the scanners is that in this study, only healthy adults participated. Both scanners need a certain patient compliance, because motion artifacts are easily made. This can be sometimes challenging in, especially, pediatric patients.

5. Conclusion

3D surface scanning devices represent a promising method to provide reproducible data of head circumference, cephalic index, and head volume. The results of the present study validate the use of the M4D Scan 3D Scanner and Structure Sensor for indirect head shape measurements. Both 3D systems showed a strong correlation with traditional measurements, but, compared to direct measurements the scanners yield to consistently higher values, the M4D Scanner providing values closest to traditional measurements. This means that when the same system is used, accurate measurements can be acquired; however, care must be taken to ensure the precision of these measurements, especially with head volumes.

Conflict of interest

None.

Acknowledgements

This research was supported by GOSH charity through the FaceValue programme grant (no. 508847) and The Engineering and Physical Sciences Research Council award (EP/N02124X/1). This report incorporates independent research from the National Institute for Health Research Biomedical Research Centre Funding Scheme. The views expressed in this publication are those of the author(s) and not necessarily those of the NHS, the National Institute for Health Research, or the Department of Health.

References

- Bland JM, Altman DG: Statistical methods for assessing agreement between two methods of clinical measurement. *Lancet* 1(8476): 307–310, 1986
- Da Silveira AC, Daw JL, Kusnoto B, Evans C, Cohen M: Craniofacial applications of three-dimensional laser surface scanning. *J Craniofac Surg* 14(4): 449–456, 2003
- Enciso R, Alexandroni ES, Benyamein K, Keim RA, Mah J: Precision, repeatability and validation of indirect 3D anthropometric measurements with light-based imaging techniques. *Biomed Imaging* 2: 1119–1122, 2004
- Farkas LG: Accuracy of anthropometric measurements: past, present, and future. *Cleft Palate Craniofac J* 33(1): 10–18, 1996 discussion 19–22
- Farkas LG, Posnick JC: Growth and development of regional units in the head and face based on anthropometric measurements. *Cleft Palate Craniofac J* 29(4): 301–302, 1992
- Fourie ZJ, Damstra J, Gerrits PO, Ren Y: Evaluation of anthropometric accuracy and reliability using different three-dimensional scanning systems. *Forensic Sci Int* 207(1–3): 127–134, 2011
- Freudlsperger C, Steinmacher S, Bachli H, Somlo E, Hoffmann J, Engel M: Metopic synostosis: measuring intracranial volume change following fronto-orbital advancement using three-dimensional photogrammetry. *J Craniomaxillofac Surg* 43(5): 593–598, 2015
- Heller JB, Heller MM, Knoll B, Gabbay JS, Duncan C, Persing JA: Intracranial volume and cephalic index outcomes for total calvarial reconstruction among non-syndromic sagittal synostosis patients. *Plast Reconstr Surg* 121(1): 187–195, 2008
- Ifflaender S, Rudiger M, Koch A, Burkhardt W: Three-dimensional digital capture of head size in neonates—a method evaluation. *PLoS One* 8(4): e61274, 2013
- Jayarathne YS, Zwahlen RA: Application of digital anthropometry for craniofacial assessment. *Craniofacial Trauma Reconstr* 7(2): 101–107, 2014
- Kamdar MR, Gomez RA, Ascherman JA: Intracranial volumes in a large series of healthy children. *Plast Reconstr Surg* 124(6): 2072–2075, 2009
- Knoops PG, Beaumont CA, Borghi A, Rodriguez-Florez N, Breakey W, Rodgers W, et al: Comparison of three-dimensional scanner systems for craniomaxillofacial imaging. *J Plast Reconstr Aesthet Surg*. <http://dx.doi.org/10.1016/j.bjps.2016.12.015>, 2017
- McGarry A, Dixon MT, Greig RJ, Hamilton DR, Sexton S, Smart H: Head shape measurement standards and cranial orthoses in the treatment of infants with deformational plagiocephaly. *Dev Med Child Neurol* 50(8): 568–576, 2008
- McKay DR, Davidge KM, Williams SK, Ellis LA, Chong DK, Teixeira RP, et al: Measuring cranial vault volume with three-dimensional photography: a method of measurement comparable to the gold standard. *J Craniofac Surg* 21(5): 1419–1422, 2010
- Meyer-Marcotty P, Bohm H, Linz C, Kochel J, Stellzig-Eisenhauer A, Schweitzer T: Three-dimensional analysis of cranial growth from 6 to 12 months of age. *Eur J Orthod* 36(5): 489–496, 2014
- Plooi JM, Maal TJ, Haers P, Borstlap WA, Kuijpers-Jagtman AM, Berge SJ: Digital three-dimensional image fusion processes for planning and evaluating orthodontics and orthognathic surgery. A systematic review. *Int J Oral Maxillofac Surg* 40(4): 341–352, 2011
- Posnick JC, Waitzman AA, Pron G, Armstrong DC: Craniofacial skeletal measurements based on computed tomography. *Cleft Palate Craniofac J* 30(2): 251–252, 1993
- Rodriguez-Florez N, Göktekin ÖK, Bruse JL, Borghi A, Angullia F, Knoops PG, et al: Quantifying the effect of corrective surgery for trigonocephaly: a non-invasive, non-ionizing method using three-dimensional handheld scanning and statistical shape modelling. *J Craniomaxillofac Surg* 45(3): 387–394, 2017
- Schaaf H, Wilbrand JF, Boedeker RH, Howaldt HP: Accuracy of photographic assessment compared with standard anthropometric measurements in nonsynostotic cranial deformities. *Cleft Palate Craniofac J* 47(5): 447–453, 2010
- Sgouros S, Goldin JH, Hockley AD, Wake MJ, Natarajan K: Intracranial volume change in childhood. *J Neurosurg* 91(4): 610–616, 1999
- Skolnick GB, Naidoo SD, Nguyen DC, Patel KB, Woo AS: Comparison of direct and digital measures of cranial vault asymmetry for assessment of plagiocephaly. *J Craniofac Surg* 26(6): 1900–1903, 2015
- Tenhagen M, Bruse JL, Rodriguez-Florez N, Angullia F, Borghi A, Koudstaal MJ, et al: 3D-handheld scanning to quantify head shape changes in spring assisted surgery for sagittal craniosynostosis. *J Craniofac Surg*. <http://dx.doi.org/10.1097/SCS.0000000000003108>, 2016
- Tzou CH, Artner NM, Pona I, Hold A, Placheta E, Kropatsch WG, et al: Comparison of three-dimensional surface-imaging systems. *J Plast Reconstr Aesthet Surg* 67(4): 489–497, 2014
- Weinberg SM, Naidoo S, Govier DP, Martin RA, Kane AA, Marazita ML: Anthropometric precision and accuracy of digital three-dimensional photogrammetry: comparing the Genex and 3dMD imaging systems with one another and with direct anthropometry. *J Craniofac Surg* 17(3): 477–483, 2006
- Wilbrand JF, Szczukowski A, Blecher JC, Pons-Kuehnemann J, Christophis P, Howaldt HP, et al: Objectification of cranial vault correction for craniosynostosis by three-dimensional photography. *J Craniomaxillofac Surg* 40(8): 726–730, 2012
- Wilbrand JF, Wilbrand M, Pons-Kuehnemann J, Blecher JC, Christophis P, Howaldt HP, et al: Value and reliability of anthropometric measurements of cranial deformity in early childhood. *J Craniomaxillofac Surg* 39(1): 24–29, 2011
- Wong JY, Oh AK, Ohta E, Hunt AT, Rogers GF, Mulliken JB, Deutsch CK: Validity and reliability of craniofacial anthropometric measurement of 3D digital photogrammetric images. *Cleft Palate Craniofac J* 45(3): 232–239, 2008