

Focal injury causing tongue hemiasthesia, dysguesia, dysarthria and dysphagia: a case report

AS Carr¹, MRB Evans¹, S Shah², S Catania³, JD Warren⁴, MJ Gleeson⁵, MM Reilly¹

1. MRC Centre for Neuromuscular Diseases, National Hospital of Neurology and Neurosurgery, Queen Square, London.
2. Department of Neuroradiology, National Hospital of Neurology and Neurosurgery, Queen Square, London
3. Department of Neurophysiology, National Hospital of Neurology and Neurosurgery, Queen Square, London.
4. National Hospital of Neurology and Neurosurgery, Queen Square, London
5. Department of Neurology, National Hospital of Neurology and Neurosurgery, Queen Square, London

Corresponding author: Dr Aisling Carr, MRC Centre for Neuromuscular Diseases, 8-11 Queen Square, National Hospital for Neurology and Neurosurgery, London, WC1N 3BG

Email: aisling.carr@uclh.nhs.uk

Tel: +44 (0)20 3448 8013

Word count: 1597

Figures: 1 (a-e)

References: 11

Keywords: Trigeminal nerve, styloglossus, neuroanatomy, oral medicine

Abstract

The combination of tongue hemiasthesia, dysguesia, dysarthria and dysphagia suggests the involvement of multiple cranial nerves. Here we present a case with sudden onset of these symptoms immediately following wisdom tooth extraction and highlight the clinical features allowing for localisation of the lesion to a focal, iatrogenic injury of the lingual nerve and adjacent styloglossus muscle.

Introduction

The combination of tongue hemiasthesia, dysguesia, dysarthria and dysphagia suggests the involvement of multiple cranial nerves. Namely, the trigeminal nerve (CN V₃), which predominantly carries somatic sensory afferents from the tongue, oral and nasal cavities and the face. The facial nerve (CN VII), providing special sensory taste afferents from the anterior 2/3 of the tongue. The glossopharyngeal nerve (CN IX) which carries special sensory taste fibres from the posterior 1/3 of the tongue and somatic sensory information from the pharynx. The vagus nerve (CN X) which contributes sensory and motor innervation to the palate facilitating swallow and the hypoglossal nerve (CN XII) which is the somatic motor supply to all the intrinsic and extrinsic muscle of the tongue, except palatoglossus. In the anatomical localisation of multiple cranial nerve lesions extensive investigations are required considering skull base disease, brainstem or supranuclear pathology. Here we present a case with sudden onset of these symptoms immediately following wisdom tooth extraction and highlight the clinical features allowing for localisation of the lesion and discuss features which exclude alternative diagnoses.

Case report

A 22-year-old female had removal of right lower 3rd molar under local anaesthetic without complication. One month later, due to discomfort and anxiety, she had the same procedure performed under general anaesthetic on the contralateral side. Prior to the procedure she was well other than a history of polycystic ovarian syndrome and was slightly overweight (BMI=28). She was not on any regular medications, drank no alcohol and did not smoke. There was no family history of neurological disease. She was married with one son and worked in telesales. Immediately post-operatively, she described numbness affecting her left cheek, tongue, lower lip and jaw and her speech was unclear. Within 24 hours the sensory disturbance had regressed to the left half of the tongue and lower gum but she remained dysarthric, describing a “sticking of her tongue” when speaking. She had bitten the side of her tongue while chewing on a number

of occasions and swallowing was difficult although there was no regurgitation, aspiration or significant weight loss. Taste was abnormal, with decreased intensity on the left side. She denied immediate perioperative pain, any symptoms on the right side of her mouth or face or any neurological disturbance in her limbs. Approximately one month later, she developed short bursts of severe pain radiating from the angle of the jaw towards her ear on chewing food around the operative area. This symptom settled with stimulus avoidance. Her symptoms have remained static for four years other than slight improvement in comprehensibility after speech and language therapy. However, she lost her telesales job as a result of the unclear speech. Neurological examination 4 years later was notable for dysarthric speech due to isolated difficulty with the production of linguopalatal fricatives: “ss” in pressure, “sh” in shoe, “ch” in machine and “z” in azure. Lingodental (“th” in math, think, father) and lingoalveolar (“s” in say, “ss” in class) fricatives, velar (“k” in cut, “g” in gut) and alveolar (“t” in toe, “d” in doe) plosive consonant sounds were normal as was timbre and volume of speech. Visual acuity, fundoscopy, pupillary light reflexes, visual fields and eye movements were normal. Corneal reflexes were intact bilaterally. Facial sensation in ophthalmic and maxillary branches of the trigeminal nerve were normal but on the left lower gum and left side of the tongue she had decreased perception of soft touch and a decreased ability to differentiate between tastes. All muscles of mastication and facial expression were strong, hearing and peri-aural sensation was normal bilaterally. The tongue sat asymmetrically in the mouth with a tendency to point toward the right without marked wasting or fasciculations (Figure 1a). The tongue was deviated towards the right on protrusion, but almost full protrusion could be achieved and tongue strength appeared normal. There was an improvement in ability to control tongue movement on looking in the mirror but the depressed position of the left posterolateral aspect of the tongue did not correct (Figure 1b and 1c). The uvula was central and the palate moved symmetrically on vocalisation (Figure 1d), but gag reflex was asymmetrical in that there was no response to tactile stimulation of the soft palate on the left but normal reaction to stimulation on the right; this finding was reproduced on

examination by independent examiners over an 18 month follow up period.

Sternocleidomastoid and trapezius strength were normal, there was no scapular winging.

Neurological examination of the limbs was normal.

Prior to assessment at the Peripheral Nerve clinic, a small post-traumatic neuroma/granuloma was documented at the left retromolar space by the ENT and oral maxillofacial surgeons, no other structural abnormality was found within the mouth. An extensive set of blood and CSF tests screening for infectious, inflammatory, vasculitic, infiltrative and paraneoplastic causes of basal meningitic and multiple cranial nerve pathologies were negative. An MRI brain with gadolinium, MR angiogram of head and neck vessels and dedicated cranial nerve imaging were performed and no abnormalities were seen. There was no clear fibro-fatty atrophy of the left styloglossus, but the small size of this muscle and the complex decussation of extrinsic and intrinsic lingual muscles makes the identification of individual lingual muscles very difficult. Neurophysiology revealed bilaterally normal blink reflexes (CNV₁ and CNVII intact) and no denervation on EMG of the tongue (CNXII intact) when needled centrally and anterolaterally.

Discussion

The deficits in this case can be explained by a focal insult at the angle of the mandible involving the lingual nerve and styloglossus muscle (Figure 1e). The lingual nerve (CNV) carries somatosensory afferents from the left side of tongue and lower jaw [1]. Palatine somatosensory branches of CNV₂ "hitchhike" with the lingual nerve [2], their involvement explains the reduction in soft palate sensation and unilaterally absent gag reflex. The normal palatal elevation on that side and central position of the uvula argue against glossopharyngeal nerve involvement. The styloglossus muscle lies just medial to the lingual nerve at the mandibular angle; this small muscle elevates the posterior border of tongue allowing lingopalatal opposition required for the production of "ss" and "sh" lingual fricatives. When working with its pair on the contralateral side, creates a trough which positions the food bolus facilitating swallow [3]. The absence of tongue hemi-atrophy, near normal range of tongue protrusion, full strength on left lateral

deviation and isolated phonetic deficit is not compatible with a significant hypoglossal nerve (CN XII) injury which would denervate all extrinsic and intrinsic tongue muscles except palatoglossus (Table 1).

There are a number of clinical features that are against a causative brainstem lesion. The somatotopic arrangement of fibres in the trigeminal sensory nucleus is such that brainstem lesions typically result in an “onion bulb” pattern of sensory deficit in contrast to the lingual nerve distribution seen here [1]. Although the longitudinally extensive trigeminal sensory nucleus runs from the upper dorsolateral pons to the cervical cord, a simultaneous lesion involving the nucleus oralis (subserving mouth sensation specifically) which is situated in the caudal pons, the nucleus solitarius (subserving taste) situated in the rostral medulla and the spinal segment of the nucleus ambiguus (subserving tongue proprioception) would be so extensive that multiple other, closely related, brainstem structures would also be involved but our patient lacked any further neurological deficits. Moreover, the dysarthria in common brainstem insults is different: an ataxic dysarthria with dysphonia occurs in the lateral medullary syndrome; where all vowels and consonants are imprecise, there is excess and equal stress and a slow rate of speech with poor control of pitch and loudness. Pontine lesions cause a flaccid dysarthria; where speech may be aphonic if severe and has a nasal quality coupled with nasal emission of air, continuous breathiness during phonation, and audible inhalation (stridor on inhalation) during recovery and generalised impairment in articulation [4]. The specific abnormalities in articulation, position, movement and symptomatic swallowing difficulties in this case are neatly explained by isolated styloglossus dysfunction. Although we often examine a variety of tongue movements and elements of articulation, the common innervation and decussating structure of tongue muscles means we do not commonly consider their individual functions. This case highlights the relevance of this rarely performed aspect of the clinical examination (Table 1).

Iatrogenic soft tissue and cranial nerve injury can complicate any general anaesthetic related to airway insertion and patient positioning; dental procedures increase this risk due to the potential for direct surgical trauma and chemical or physical insult from local nerve block [5].

The lingual nerve grooves the inner table of the mandible adjacent to the lower third molar. The lingual plate of the mandible at that site is very thin and fractures easily, either as a planned procedure to improve a path for extraction (a lingual split), in the process of mobilising the tooth or by pressure from a mandibular retractor [6]. The proximity of the tiny styloglossus muscle puts it at risk from any of these insults. Third molar extraction (wisdom tooth removal) is a common procedure in dental and maxillofacial practice with an incidence rate of 4/1000 persons in the UK making it one of the top 10 inpatient or daycase procedures in the NHS [7]. Between 0.5 and 5% of patients suffer an iatrogenic nerve injury post-procedure with the lingual and inferior alveolar nerves being most commonly affected [8]; up to 1% are permanent with functional and psychosocial implications for the individual [9, 10]. Such injuries can have significant medicolegal implications [11]. As neurologists, we should be able to interpret the clinical signs, accurately localise the insult to help appreciate the mechanism and exclude alternative, unrelated disease processes.

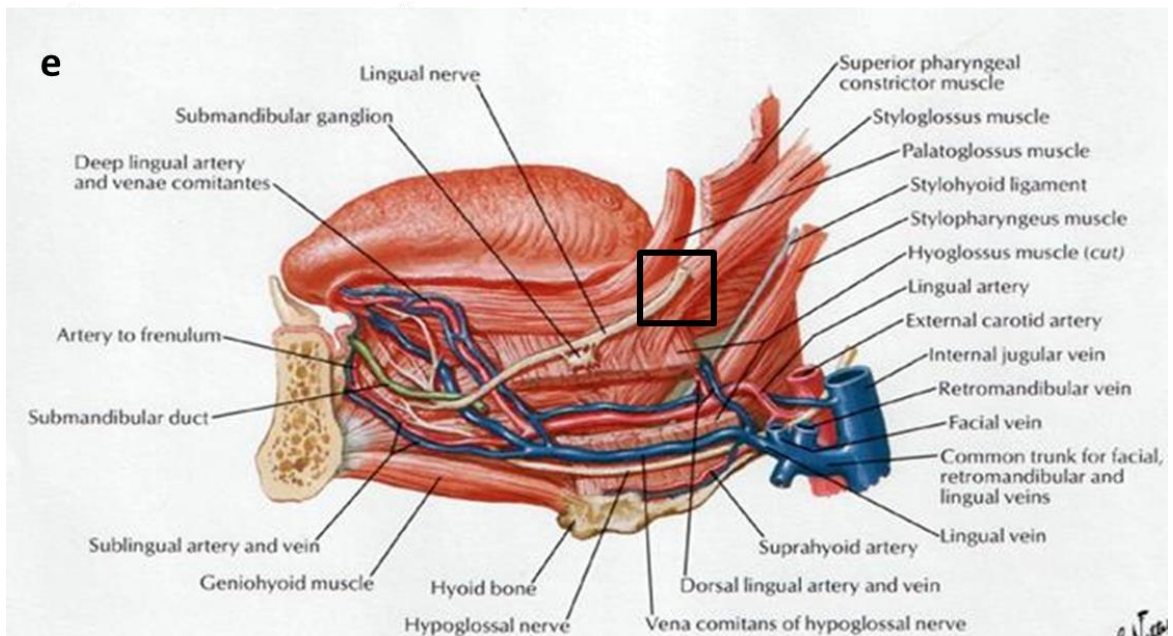
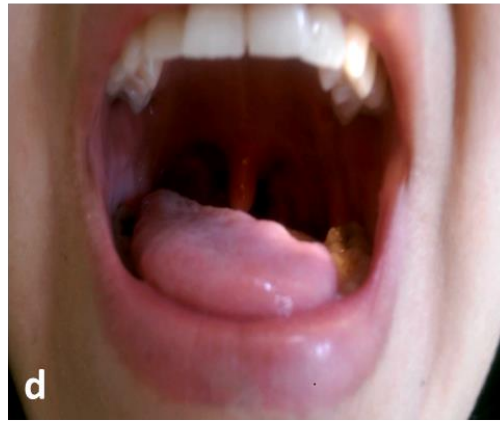
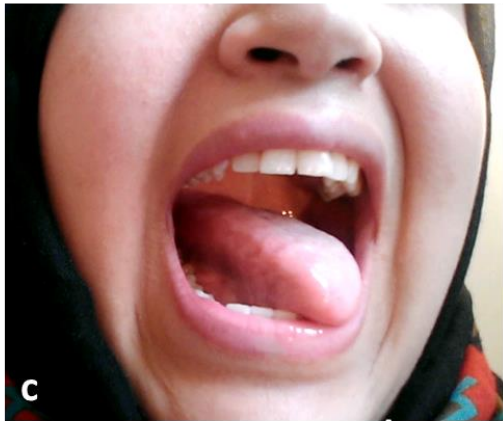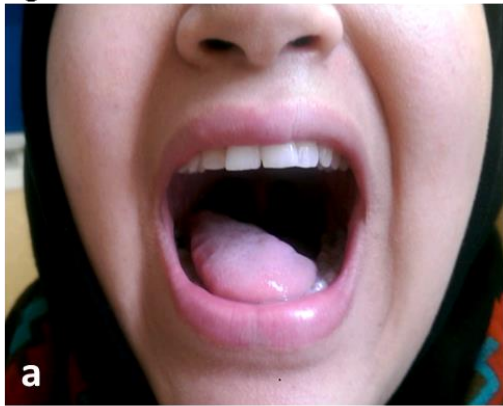References

1. PW Brazis, JC Masdeu, J Biller. *Localisation in Clinical Neurology*. 6th Ed.
2. E Tolu, MA Caria, ME Simula, P Lacana. Muscle spindle and periodontal trigeminal afferents modulate the hypoglossal motoneuronal activity. *Arch Ital Biol* 1994;132(2):93-104.
3. H Grey, WH Lewis. *Anatomy of the Human Body* (20th Edition) Lea & Febiger 1918.
4. P McCaffrey. The Neuroscience on the Web Series:CMSD 642 Neuropathologies of Swallowing and Speech. Chapter 12; Types of dysarthria: Upper motor neuron damage.
<http://www.csuchico.edu/~pmccaffrey//syllabi/SPPA342/342unit12.html>
5. DJ Du Toit. Nervus lingualis: applied anatomical relevance to dental practice and oral surgery. *SADJ*. 2003; 58(5):207, 210-212.
6. Coulthard P, Bailey E, Esposito M, Furness S, Renton TF, Worthington HV. Surgical techniques for the removal of mandibular wisdom teeth. *Cochrane Database of Systematic Reviews* 2014, Issue 7. Art. No.: CD004345. DOI: 10.1002/14651858.CD004345.pub2
7. ABG Tay, JR Zuniga. Clinical characteristics of trigeminal nerve injury referrals to a universal centre. *Int J. Oral Maxillofac. Surg.* 2007; 36: 922-927.
8. RC Robert, P Bacchetti, MA Pogrel. Frequency of trigeminal nerve injury following third molar removal. *J Oral Maxillofac Surg.* 2005; 63:732-735.
9. W Jerjes, T Upile, P Shah et al. Risk factors associated with injury to the inferior alveolar nerve and lingual nerves following third molar surgery. *Oral Surg Oral Med Oral Pathol Oral Radiol Endod.* 2010; 109:335-345.
10. HA Kiyak, BH Beach, P Worthington et al. Psychological impact of osseointegrated dental implants. *Int J Oral Maxillofac implants* 1990; 5: 61-69.
11. I Venta, C Lindqvist, P Ylipaavaniemi. Malpractice claims for permanent nerve injuries related to third molar removals. *Acta Odontol Scand* 1998; 56: 193-196.

Table 1. Tongue muscles innervation, function and clinical relevance [1, 3].

	Muscle	Innervation	Function	Clinical relevance
Extrinsic	Glenioglossus	Hypoglossal (CN XII)	Depresses and protrudes	Main muscle involved in protrusion Proxy for hypoglossal function Stabilises upper airway
	Styloglossus	Hypoglossal (CN XII)	Lateral elevation, retracts	Creates a trough to aid swallow
	Hypoglossus	Hypoglossal (CN XII)	Depresses and retracts	Closes oropharynx Initiates swallow
	Palatoglossus	Vagus (CN X)	Posterior elevation, retracts	
Intrinsic	Longitudinalis sup.	Hypoglossal (CN XII)	Retracts and contracts	Shortens, thickens
	Longitudinalis inf.	Hypoglossal (CN XII)		
	Transversus linguae	Hypoglossal (CN XII)	Protrudes	Narrows, elongates
	Verticalis linguae	Hypoglossal (CN XII)		Flattens, broadens

Figure 1



Legend: Figure 1

Figure 1a Asymmetrical position of tongue at rest. No wasting, no fasciculations.

Figure 1b Attempted tongue movement to right on looking in the mirror.

Figure 1c Attempted tongue movement to left on looking in the mirror, note head tilt implying effort.

Figure 1d Central uvula and normal, symmetrical palatal movements.

Figure 1e Injury (black square) to the small styloglossus muscle on the posterolateral aspect of the tongue and the adjacent lingual nerve explain the unusual combination of lingual nerve sensory loss, hitchhiking chorda tympani taste disturbance, specific lingual fricative dysarthria and subjective swallowing difficulty both due to loss of the posterolateral elevating function of the left styloglossus essential for the creation of “ss” and “sh” sounds and in the formation of a trough to position the food bolus in early swallow.