

Biomarkers and Surrogate Endpoints in Uveitis: The Impact of Quantitative Imaging

Alastair K. Denniston,¹⁻⁴ Pearse A. Keane,⁴ and Sunil K. Srivastava⁵

¹Department of Ophthalmology, University Hospitals Birmingham NHS Foundation Trust, Birmingham, United Kingdom

²Academic Unit of Ophthalmology, Institute of Inflammation & Ageing, University of Birmingham, United Kingdom

³Centre for Rare Diseases, Institute of Translational Medicine, Birmingham Health Partners, Birmingham, United Kingdom

⁴NIHR Biomedical Research Centre for Ophthalmology, Moorfields Eye Hospital NHS Foundation Trust and UCL Institute of Ophthalmology, London, United Kingdom

⁵Cleveland Clinic, Cole Eye Institute, Cleveland, Ohio, United States

Correspondence: Alastair K. Denniston, Academic Unit of Ophthalmology, Institute of Inflammation & Ageing, University of Birmingham, United Kingdom; a.denniston@bham.ac.uk.

Submitted: March 2, 2017

Accepted: April 1, 2017

Citation: Denniston AK, Keane PA, Srivastava SK. Biomarkers and surrogate endpoints in uveitis: the impact of quantitative imaging. *Invest Ophthalmol Vis Sci.* 2017;58:BI0131-BI0140. DOI:10.1167/iovs.17-21788

PURPOSE. Uveitis is a major cause of sight loss across the world. The reliable assessment of intraocular inflammation in uveitis ('disease activity') is essential in order to score disease severity and response to treatment. In this review, we describe how 'quantitative imaging', the approach of using automated analysis and measurement algorithms across both standard and emerging imaging modalities, can develop objective instrument-based measures of disease activity.

METHODS. This is a narrative review based on searches of the current world literature using terms related to quantitative imaging techniques in uveitis, supplemented by clinical trial registry data, and expert knowledge of surrogate endpoints and outcome measures in ophthalmology.

RESULTS. Current measures of disease activity are largely based on subjective clinical estimation, and are relatively insensitive, with poor discrimination and reliability. The development of quantitative imaging in uveitis is most established in the use of optical coherence tomographic (OCT) measurement of central macular thickness (CMT) to measure severity of macular edema (ME). The transformative effect of CMT in clinical assessment of patients with ME provides a paradigm for the development and impact of other forms of quantitative imaging. Quantitative imaging approaches are now being developed and validated for other key inflammatory parameters such as anterior chamber cells, vitreous haze, retinovascular leakage, and chorioretinal infiltrates.

CONCLUSIONS. As new forms of quantitative imaging in uveitis are proposed, the uveitis community will need to evaluate these tools against the current subjective clinical estimates and reach a new consensus for how disease activity in uveitis should be measured. The development, validation, and adoption of sensitive and discriminatory measures of disease activity is an unmet need that has the potential to transform both drug development and routine clinical care for the patient with uveitis.

Keywords: uveitis, endpoint, surrogate, outcome measure, optical coherence tomography, quantitative imaging

Uveitis, a group of conditions characterized by intraocular inflammation,^{1,2} is a major cause of blindness across the world.³ The annual incidence of uveitis is estimated at 17.4 to 52.4 per 100,000 with a prevalence of approximately 38 to 114.5 per 100,000 general population.³⁻⁶ Although uveitis may affect any age group, it peaks in the working-age population,³ and thus has a high impact in terms of years of visual loss, with some estimates of its socioeconomic impact being on a par with diabetic retinopathy.⁷ Uveitis accounts for approximately 10% to 15% of total blindness in the developed world^{4,6} and up to 25% of blindness in the developing world.⁸

The assessment of uveitis is a complex process. First, there are the generic challenges common to the assessment of all diseases, such as the choice of outcome, method of measurement, and whose perspective it is measured from. Second,

there are issues, which specifically hamper the reliable assessment of uveitis such as the heterogeneity of the range of syndromes within uveitis, the variable manifestations even within each syndrome (or within the same patient at different times), and the limitations of many of our methods of measuring outcomes. There has been increasing concern that these challenges have limited drug development in uveitis, with a number of high-profile late-phase clinical trials failing to meet their primary endpoints, amid concern that it was the endpoint that had 'failed' rather than the drug.⁹⁻¹²

In this review, we will consider the patient with uveitis holistically, but with specific consideration of how a quantitative approach to imaging may contribute to the assessment of uveitis and may provide sensitive objective surrogate measures for clinical trial purposes.



PRINCIPLES OF ENDPOINTS IN UVEITIS

How should we assess a disease? A systematic review of registered clinical trials identified 14 different types of outcomes used as primary trial endpoints across 104 prospective interventional clinical trials of posterior-segment involving uveitis.¹³ The authors proposed that outcome measures in uveitis can be classified according to the 'dimensions of the disease' they represent: disease activity, disease damage, observed visual function (e.g., visual acuity [VA]), patient-reported visual function, and quality of life. This series of dimensions reflect both the timeline of disease, and a shift in emphasis from the observed pathologic process to the subjective experience of the disease by the patient.

All these dimensions are important aspects of the disease. They are distinct and are not interchangeable. Different interventions will require consideration of outcome measures from the most appropriate dimension. For example, if an intervention has been developed to reduce inflammation (the dimension of disease activity), then its most immediate and direct effect should be detectable using outcome measures within that dimension. Efforts to evaluate such an intervention through a downstream endpoint, such as visual acuity or quality of life, however important these are, may be unsuccessful due to the weaker beneficial effect seen (the 'signal'), and the greater risk of confounding factors ('noise'). A relatively weak signal/noise ratio for a trial endpoint could be compensated for by evaluating larger numbers of patients, but this is particularly problematic in conditions, such as uveitis where recruitment is challenging.^{9,11}

There is an urgent need to develop better outcome measures for the assessment of uveitis for two reasons: first for use as trial endpoints in clinical studies with a view to drug development and licensing; second to inform treatment decisions in routine clinical practice. The US Food and Drug Administration (FDA) provides guidance as to what we are aiming for. They advise that a trial endpoint must be 'well-defined and reliable' and that treatment benefit should be a measure of how a patient 'survives, feels, or functions'.^{14,15} Accordingly, there has been an emphasis in ophthalmic licensing trials on visual acuity (as a measure of function), although it should be noted that other measures of visual function (such as visual field assessment) and patient-reported outcome measures (PROMs) are also acceptable as a direct trial endpoint. It will be evident however that most familiar assessments of uveitis (other than VA) fall outside this remit, and are therefore defined as surrogate measures of disease activity. In the few consensus reviews of outcomes in uveitis, measurement of inflammation was defined as an agreed outcome measure in uveitis.^{1,11,16}

The FDA requires a surrogate to be 'reasonably likely, based on epidemiologic, therapeutic, pathophysiologic, or other evidence to predict clinical benefit'.¹⁷ Putting this into the context of uveitis we would argue that any potential surrogate measure should meet two essential criteria: (1) the surrogate should be 'biologically relevant' given our understanding of the pathophysiology of the disease, and (2) the surrogate should be 'functionally relevant' with evidence of downstream effect on visual function, but recognizing that this effect may be delayed and indirect. Providing that a surrogate has met both these essential criteria, then it should be evaluated against desirable criteria such as objectivity, repeatability, and sensitivity.^{18,19}

CLINICALLY ASSESSED ENDPOINTS

The publication in 2005 of the recommendations of the Standardization of Uveitis Nomenclature (SUN) workshop was

a major step forward for the field, and remains the current paradigm in uveitis for both trials and routine clinical practice.¹ Among other areas of standardization, this consensus statement provided a single way of grading three aspects of disease activity in uveitis: anterior chamber (AC) cells, AC flare, and vitreous haze. The authors noted that prior to this date there were at least four systems for AC cells,²⁰⁻²³ three for AC flare²⁰⁻²³ and three for vitreous haze or debris.²³⁻²⁵ The SUN workshop did also consider other aspects of disease activity, but were unable to develop recommendations in these areas due to lack of consensus.¹ The role of visual acuity was considered and guidance issued as to how it should be reported in a trial context. The SUN recommendations have been the vital foundation for the last decade of progress in uveitis, but it should also be recognized that these guidelines were never intended to be comprehensive and that a wide range of outcomes are not covered by them. This includes many aspects of disease activity, any measures of disease damage, most aspects of measured visual function, and any patient reported outcomes or quality of life.

A major limitation of our current clinical measures of disease activity is that they are subjective. The National Eye Institute (NEI) vitreous haze scale has had a pre-eminent place as the uveitis activity measure preferred by the FDA for effectiveness trials in posterior segment-involving uveitis. It is based on the clinician's estimate of the clarity of the optic disc when viewed with the indirect ophthalmoscope and is compared against a standard set of photographs as published by Nussenblatt et al.²⁵ in 1985. Although it has had value, it does exemplify many of the problems typical of these clinical measures. First, it is subjective, leading to significant scoring variation between independent observers: Kempen et al.²⁶ noted an interobserver agreement of $k = 0.53$ (for exact agreement) and $k = 0.75$ (to be within 1 grade). Second, it is noncontinuous leading to very large steps in disease activity between categories. Third, it is poorly discriminatory at lower levels of vitreous haze. Most cases of active uveitis tend to fall within these lower levels, generally scoring +0.5 or +1 on the ordinal scale (+4 being the maximum).^{9,11,27}

The limitations are most starkly seen when considered in a clinical trial context. Due to expert concerns about the poor discrimination of the NEI vitreous haze score, a change of at least two steps is usually required to be considered significant (which means that important smaller effects may be overlooked), and inclusion criteria is usually set at a minimum of 2+ vitreous haze (which dramatically limits recruitment). Finally, the poor interobserver agreement has sometimes required two independent observers for such studies, and has required higher levels of recruitment to attempt to compensate for the poor 'signal:noise' ratio of this endpoint.^{11,27}

QUANTITATIVE IMAGING-BASED ENDPOINTS: OCT CHANGES THE PARADIGM

In the decade or so since the SUN report, the introduction and widespread adoption of high-resolution optical coherence tomography (OCT) has provided a way of quantifying disease processes through objective instrument-based measurements.²⁸ Optical coherence tomography measurements of structure provide noninvasive repeatable measures that are sensitive to change in important disease processes. The commonest examples in ophthalmology are the use of central macular thickness (CMT) to measure the onset, severity and resolution of macular edema (ME) or the use of retinal nerve fibre layer (RNFL) thickness to detect the presence and progression of thinning of that layer related to glaucomatous optic neuropathy.²⁹ There are a number of reasons why OCT has been particularly amenable to

this role of serial quantification compared with some other imaging modalities. First it is fast, noninvasive and well tolerated—so it can be easily repeated at multiple visits. Second, high contrast of different layers enables automated segmentation from which parameters can be calculated (such as the thickness of the retina or individual layers). Third, most commercial systems utilize eye-tracking or alignment software such that sequential scans can be overlain enabling precise calculation of differences in thickness, and digital subtraction that enables this to be visualized.

Interestingly OCT-derived parameters have become standard outcome measures in the clinic rather faster than they have become acceptable as trial endpoints by the regulatory authorities. Clinicians are comfortable with them as they self-evidently measure structural changes that are direct consequences of a pathologic process, but regulators such as the FDA have pointed out that while OCT-derived endpoints are ‘well-defined and reliable’ they do not directly measure how a patient ‘survives, feels or functions’. Demonstrating that these types of imaging-based endpoints are indeed appropriate surrogates for functional endpoints is a key step that has in the past been overlooked by investigators and device developers. It is however essential if we are going to move from the limitations of our current subjective endpoints to the ‘well-defined and reliable’ objective endpoints that could improve the sensitivity of clinical trials in uveitis.^{14,15,17}

For the remainder of this review we will focus on those aspects of intraocular inflammation that are generally regarded as the most important indicators of disease activity in uveitis. In the NEI-FDA Endpoint Workshop held in 2015, Holland and associates proposed a short-list of manifestations that should be regarded as the ‘fundamental signs of inflammation’: AC cells, vitreous haze, retinal vascular leakage, retinal infiltrates, and choroidal infiltrates.³⁰ The exclusion of uveitic ME from that list was based on advice from regulators that they regarded this as a complication of the inflammation (rather than a sign of disease activity per se), which could be multifactorial in origin (i.e., not exclusively a sign of disease activity).

In routine practice however uveitic ME deserves consideration in this list. There are good biological reasons to directly link the development of ME to the inflammatory process (e.g., in the same way as retinovascular leakage and vitreous haze), it associates with other measures of uveitis activity, and it responds to treatment of the underlying inflammatory process in a reversible way (unlike most other structural complications of the disease). Uveitic ME is of particular importance to the present discussion for two reasons: first, it is the single most important reversible cause of sight-loss in uveitis that is amenable to treatment with pharmacologic therapies (the focus of most clinical trials); second the measurement of ME by OCT is the prototypic demonstration of quantitative imaging in uveitis. It is a glimpse of where we are headed.

CENTRAL MACULAR THICKNESS: OCT MEASUREMENT OF MACULAR EDEMA

Macular edema is a leading cause of sight loss in uveitis. It accounts for approximately one-third of blindness caused by the disease.⁶ Prior to the advent of OCT, diagnosis depended on biomicroscopy supported by fluorescein angiography (FA). Detection by biomicroscopy is often difficult except in severe cases and is not quantifiable. Assessment by FA was more sensitive than biomicroscopy, but was again not easily quantifiable and had the disadvantage of requiring an invasive procedure which reduced serial assessments.¹⁰ By providing high-resolution, cross-sectional images of ocular tissues in a noninvasive manner, even early models of OCT showed the ability to provide

serial measurements of disease morphology (which could be automated), and thus provide objective markers for clinical care in a number of conditions including ME.²⁸ In 1995, Hee et al.²⁹ reported on a series of patients that included both diabetic retinopathy patients and 25 patients with ME secondary to retinal vein occlusion, uveitis, epiretinal membrane formation, or cataract extraction, and noted that ‘serial optical coherence tomographic examinations allowed tracking of both the longitudinal progression of macular thickening and the resolution of ME after laser photocoagulation’.²⁹

A number of studies have compared OCT and FA, highlighting the many advantages of OCT in the diagnosis of uveitic ME but also demarcating its limitations. In their analysis of the utility of these two investigations in the MUST trial, Kempen et al.³¹ noted that the rate of ‘usable information’ was higher for OCT (90%; vs. 77% for FA) but that the agreement in diagnosis was only moderate ($K = 0.44$). This is essentially due to the differences between anatomy and physiology: OCT measures structural changes—macular thickening; FA measures leakage of dye across the vessel wall. Although during active inflammation you will commonly observe both macular thickening on OCT and macular leakage on FA, it is perfectly possible to see either in isolation. Indeed, the authors noted that of those with no macular thickening on OCT, 40% cases demonstrated macular leakage by FA; conversely of those with no macular leakage on FA, 34% were shown to have macular thickening on OCT. It should be noted that both modalities performed significantly better than biomicroscopic evaluation alone.³¹

Importantly MUST is one of the few prospective uveitis datasets that connects OCT-measured structural changes to visual function, a vital step in its validation as a surrogate endpoint. Taylor et al.³² reported that the presence of ME was associated with both worse visual acuity and worse overall visual field sensitivity, and that qualitative differences in edema distribution was associated with differential impact on vision. In a quantitative analysis of actual CMT values, Sugar et al.³³ noted that each 100- μ m reduction in CMT equated to a 6.5 letter increase in VA. A sensitivity analysis suggested that a 20% reduction in macular thickness should be used as clinically meaningful improvement in VA (sensitivity 77%, specificity 75% for 10 letter improvement). Other smaller studies have also linked OCT changes to other functional outcomes such as reading VA, reading speed, and central retinal sensitivity.^{34,35}

Although CMT is the most widely used single OCT-derived measure of macular status, it should be recognized that it is not the only parameter available and that there is considerable variation in methods for OCT quantification and reporting. Trials using OCT estimation of ME include: (1) reporting ME as a binary outcome, that is present/absent based on whether CMT is greater or less than a prespecified threshold (which varies according to the trial)^{36,37}; the absolute change in CMT³⁸; the percentage change in CMT³³; the change in CMT as a log score (unpublished; clinicaltrials.gov number, NCT01314417); change in cystoid area and height³⁴; and estimation of retained area of retinal tissue at the plexiform layer.³⁹ It is also recognized that there is more going on in uveitic ME than is captured by CMT alone. Studies that assess the pattern of uveitic ME including presence of cystoid spaces, presence of diffuse thickening, and presence of subretinal fluid also have value and show the differential affects of these patterns, and their quantification and relative impact needs further exploration.^{32,40,41}

AC CELLS: QUANTIFICATION OF ANTERIOR INFLAMMATION THROUGH OCT

Measuring AC inflammation is required to assess the inflammatory activity of front of the eye. The current SUN grading

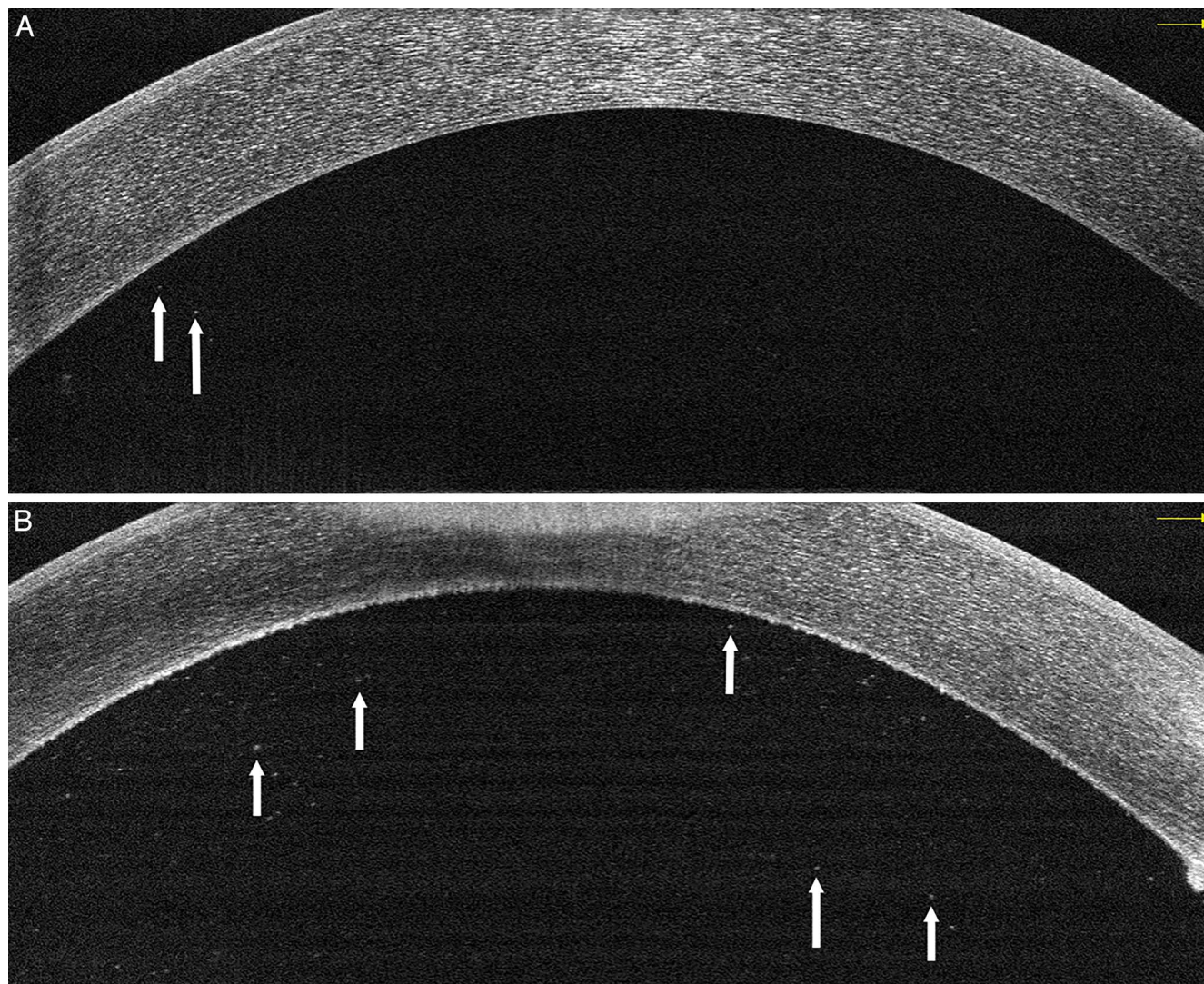


FIGURE 1. Optical coherence tomography line scans of two eyes, (A) with 2+ AC cell inflammation and (B) with 4+ AC cell inflammation. Arrows denote hyperreflective spots representing inflammatory cells.

system uses a slit-lamp microscope to count AC cells seen in a 1×1 mm beam of light.¹ The cell count is then placed into one of six ordinal grades. In the only study assessing this system, interobserver agreement rates ranged from 51.4% to 57% within the same grade at three different centers.²⁶ Within 1 step, the agreement level increases, but this highlights the imprecise feature of the current grading system—the high likelihood that three or more trained observers would grade the same patient at least two levels differently. Given this variation, there is a need for quantification techniques to measure AC inflammation that better separates different levels of activity.^{1,11,26} In theory, imaging of the AC with OCT would allow a consistent imaging method to determine the number of cells in the AC. The ability of OCT imaging to identify cells in the AC has been shown with both time-domain and spectral-domain systems (Fig. 1).^{19,42–44} Using a spectral-domain system, volume cube scans of the AC can be obtained. Automated software can then be used to identify and count the number of cells in this volumetric scan. Strict rules for identification of cells in the algorithm eliminate the variability of manual interpretation. Using this method, Sharma et al.¹⁹ published their experience in a prospective study of 76 patients. They defined a continuous measure of AC inflamma-

tion cells per millimeter cubed. High correlation between OCT measurements and slit-lamp grading was found. More importantly, the relative lack of precision of slit-lamp-based grading was highlighted with large ranges of the number of cells identified by OCT within the same grade. This preliminary data suggests that OCT automated quantification of AC cells may be superior to clinical grading systems, but still requires significant validation before becoming standard of care.

RETINOVASCULAR LEAKAGE: QUANTIFICATION OF FLUORESCEIN ANGIOGRAPHIC FINDINGS

In humans and experimental animal models of uveitis, posterior inflammation does not always reveal vitreous haze.^{22,45,46} In experimental animal models of uveitis, retinal vascular changes are almost universally observed, but vitreous haze does not occur often.^{22,47–49} Indeed, grading systems of experimental autoimmune uveitis (EAU) usually score for cellular infiltration and damage to the retina but not haze.^{47,48} The presence of retinal vascular leakage on fluorescein angiography is common finding in posterior segment inflammation in humans.^{46,50,51} Given the variability of posterior

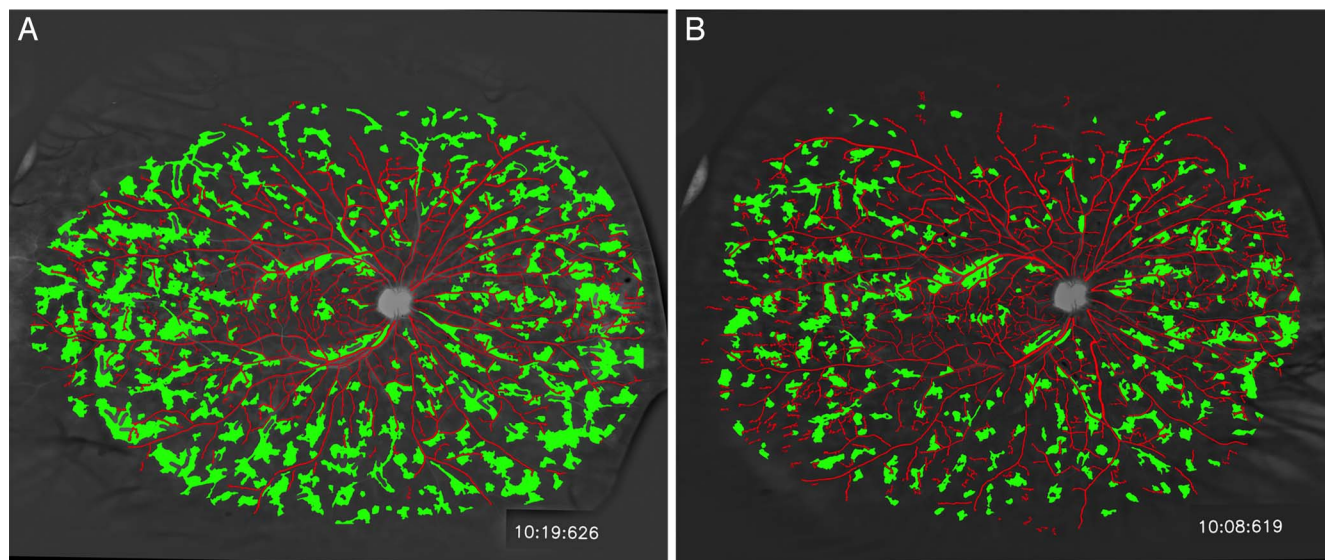


FIGURE 2. Ultra wide-field fluorescein images late frames with leakage measured with an automated algorithm at two separate time-points, pretreatment (*left*) and during treatment (*right*). Leakage identified in *green*, blood vessels in *red*. These images are dewarped eliminating the peripheral distortion. Leakage area measures, 22.8% (*left*) and 11.3% (*right*).

segment findings in different etiologies of uveitis, the ability to measure a variety of consequences of inflammation is warranted. In order to properly measure retinal vascular leakage, the use of ultra wide-field fundus fluorescein angiography (UWFFA) is needed to capture as much of the whole retina as possible. Using this technique a few studies have shown the correlation between retinal vascular leakage on wide-field fluorescein angiography and signs of activity. In one retrospective review, the authors identified a correlation between peripheral retinal vascular leakage and ME.⁵¹ In another retrospective review of the use of wide-field angiography in uveitis, the authors found the presence of leakage was a sensitive measure of clinical activity (95%) and the lack of leakage had high specificity for the absence of activity (93%).⁵² Correspondingly, the presence of retinal vascular leakage correlated with increased AC cell and vitreous haze. Quantification of leakage on UWFFA is needed to use this as a measure of inflammation. Both manual⁵¹ and automated quantification of leakage have been described (Ehlers et al., manuscript under review). Using an automated algorithm to identify leakage in uveitis patients has been shown to discriminate between small changes at different time points in the same patients.⁵² This highlights the potential for using automated analysis of UWFFA images in uveitis patients as another continuous measure of inflammation (Fig. 2).

VITREOUS INFLAMMATION: QUANTIFICATION OF VITREOUS HAZE THROUGH OCT

Vitreous haze is a valuable sign of inflammation but, as alluded to earlier, the clinical NEI Vitreous Haze score has a number of major problems, which limit its value in both clinical practice and as an endpoint for clinical trials. An objective instrument-based measure equivalent to the use of CMT to measure ME would have major advantages.

In 2014, Keane et al.⁵³ published a proof-of-concept study, which suggested that commercially available OCT could be used for this purpose. This study of 60 participants (uveitis patients and healthy controls) compared OCT derived vitreous reflectivity data with the NEI Vitreous Haze Score. Spectral-domain OCT images (Spectralis; Heidelberg Engineering,

Heidelberg, Germany) were taken using standard macular settings, and analyzed using custom segmentation software (“OCTOR”; Doheny Image Reading Center, Los Angeles, CA, USA) leading to measurements of the vitreous signal intensity and the RPE intensity (as internal reference value) from which could be calculated the optical density ratio: “VIT/RPE-Relative Intensity” (Fig. 3).

The key finding was that VIT/RPE-Relative Intensity was significantly higher in uveitic eyes with known vitreous haze than in uveitic eyes without haze or in healthy controls and positively correlated with clinical vitreous haze as measured by the NEI score. Other ocular characteristics of inflammation also correlated with VIT/RPE-Relative Intensity, including AC cells and AC flare. Critically, in the context of developing a tool that is objective and reliable, measurement of VIT/RPE-Relative Intensity showed a good degree of intergrader reproducibility (95% limits of agreement: -0.019 to 0.016).⁵³

Subsequent studies have validated this technique in a larger cohort using a different OCT device (Cirrus; Carl Zeiss Meditech, Dublin, CA, USA) and have developed an automated version of the technique demonstrating how it could be used in routine practice in a similar way to CMT (Fig. 3).^{54,55} More recently the capacity of the test to detect responsiveness to treatment was evaluated in a retrospective analysis of a cohort who were undergoing subtenon triamcinolone acetate for uveitic ME. Sreekantham, et al.¹⁸ reported that in their cohort of 22 eyes, mean VIT/RPE relative intensity improved from 0.139 to 0.053 with treatment and that this was highly statistically significant ($P = 3 \times 10^{-5}$). The authors noted that the absolute measures of vitreous activity showed similar improvement and that the reduction in the VIT/RPE relative intensity was not therefore an artifact arising from changes in the RPE visualization caused by resolution of the overlying fluid.¹⁸

While acknowledging that this was a retrospective analysis, the sensitivity of that small study to detect a change at a highly statistically significant level shows how the acceptance of OCT-derived objective indices would transform the landscape of clinical trials in uveitis, enabling them to be smaller, cheaper, and more efficient.

Treatment Response

Composite Timeline

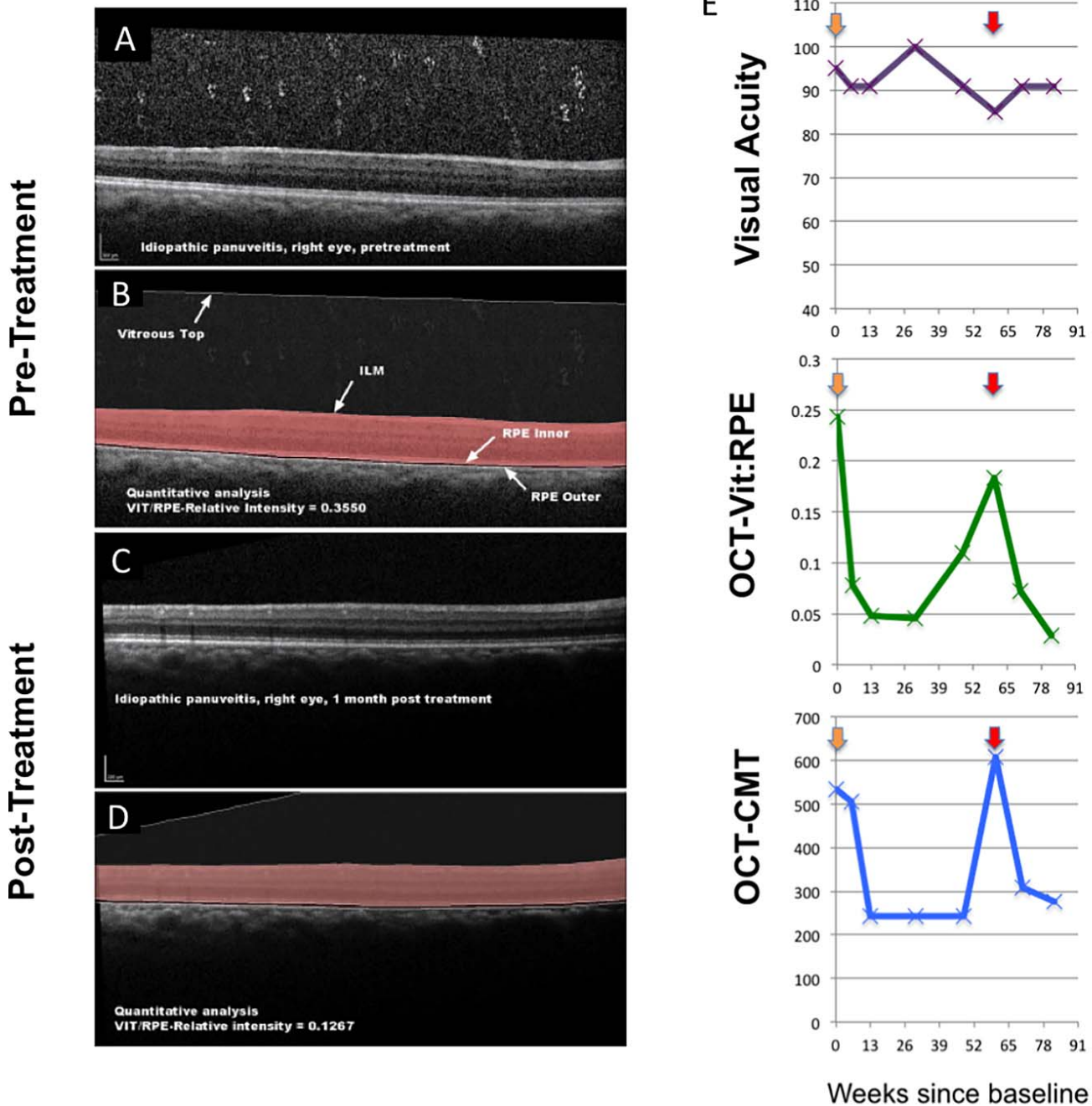
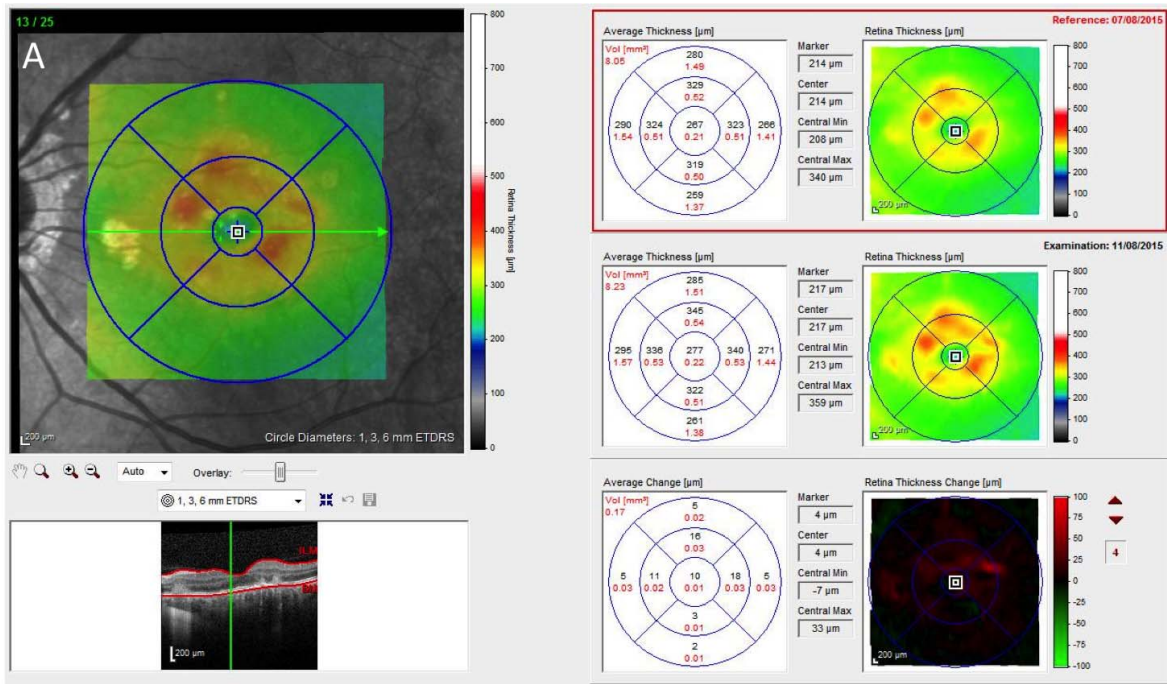


FIGURE 3. Quantitative assessment of the vitreous using OCT at initial presentation in a 57-year-old patient with idiopathic panuveitis and a clinical NEI Vitreous Haze Score of 2+. Pretreatment: (A) OCT-scan revealing widespread intravitreal cellular infiltrates and diffusely increased vitreous signal intensity. (B) Post segmentation of the vitreous compartment (boundaries: vitreous top to internal limiting membrane [ILM]) and the RPE (boundaries: RPE-inner to RPE-outer), with a resulting vitreous signal intensity: RPE relative intensity (OCT-VIT:RPE) of 0.355. Post treatment with oral corticosteroids: (C) OCT-scan revealing a significant reduction in both vitreous haze and inflammatory cells. (D) Post segmentation of the vitreous compartment, with OCT-VIT:RPE of 0.127. (E) Potential application to clinical practice. Monitoring of visual acuity (number of letters read), OCT-VIT:RPE (measuring vitreous inflammation) and CMT (measuring ME) over 84 weeks in the right eye of a 32-year-old patient with panuveitis secondary to sarcoidosis. At baseline he reported reduced vision, and had clinical evidence of active panuveitis with NEI vitreous haze score of 1+, and ME. He was treated with high-dose oral corticosteroids (orange arrow) with resolution of inflammation and CMT returning to a normal value of 240 μ m. A subsequent recurrence was treated with pulsed intravenous methylprednisolone (red arrow). It is noted that changes in OCT-VIT:RPE may anticipate other signs of inflammation including ME; in this example it is seen to be an early indicator both of response to treatment (week 6) and of loss of control of inflammation (week 48).

Pre-Treatment



Post-Treatment

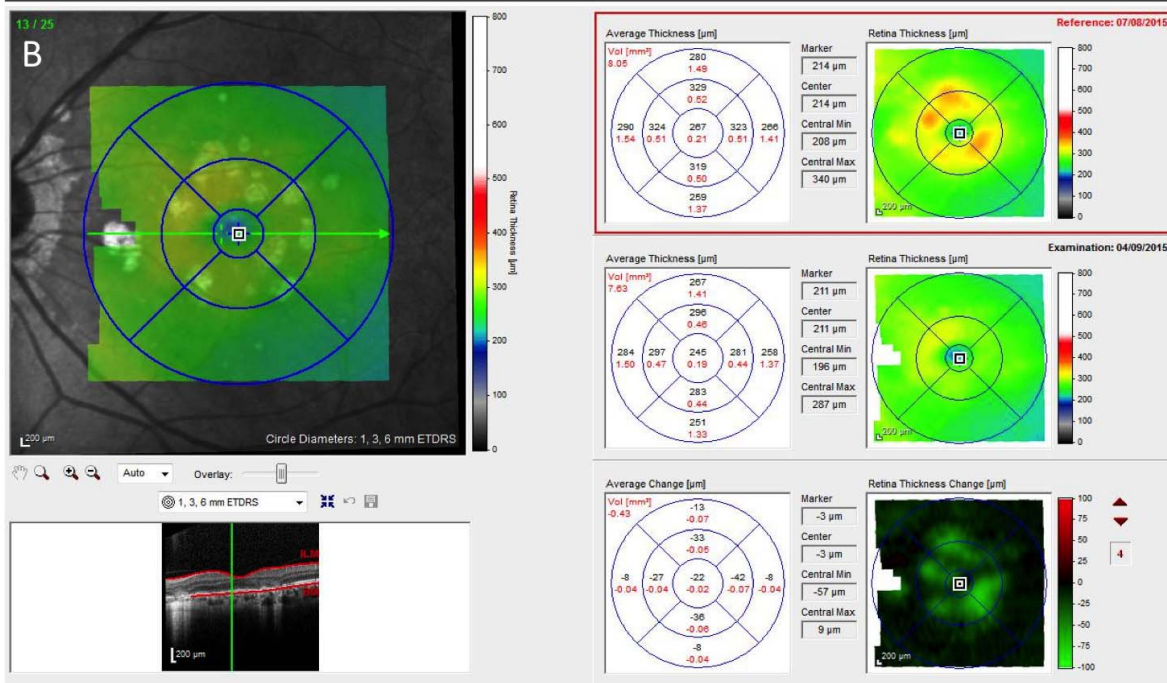


FIGURE 4. Comparative infrared, spectral-domain OCT images, and retinal thickness maps from the left eye of a 43-year-old female patient with active punctate inner choroidopathy taken with the Heidelberg Spectralis system. (A) Spectral-domain OCT during a symptomatic flare-up shows focal disruption of the RPE and ellipsoid zone associated with a dome-shaped hyperreflective area. Heidelberg Eye Explorer software provides retinal thickness maps showing increase in retinal thickness due to the number, size, and intensity of ‘hot spots’ compared with reference with automated quantitative analysis of average change in different subfields of the macular grid, and with operator-dependent measurement of point-change over individual lesions. Spectral-domain OCT repeated 23 days after intravitreal injection of triamcinolone acetonide shows involution of the active lesion and resolution of the ‘hot spots’ on the corresponding retinal thickness maps compared with the same reference scan, together with quantitative analysis of retinal thickness topography. Further details available at Madhusdhan et al.⁵⁸

CHORIORETINAL LESIONS: QUANTIFICATION OF ‘SPOTS’

Modern fundus cameras and ultra wide-field imaging such as the Optos system (Optos Plc, Dunfermline, Scotland, UK) enable rapid and reliable longitudinal documentation of chorioretinal lesions. For those forms of uveitis characterized by choroidal or

retinal infiltrates, this is a valuable tool for detecting disease activity.^{56,57} However, it is limited by being, for the most part, a subjective assessment based on the observer’s judgment in identifying new spots, change in spot area, or changes in the spot boundary. A system of automated quantification of lesion area and other lesion characteristics would be highly valuable.

For chorioretinal disease confined mainly to the posterior pole, quantitative OCT analysis of chorioretinal lesions using existing commercial software may be helpful. In their dedicated punctate inner choroidopathy (PIC) clinic, Madhusudhan et al.⁵⁸ use this technique as standard, demonstrating how even mild flares of disease could consistently be detected and quantitated on sequential thickness maps (Fig. 4).

Optical coherence tomography is also being increasingly used outside the posterior pole initially through eccentric fixation, such as the standardized extramacular approach described by Keane et al.,⁵⁹ and more recently through advances in hardware such as swept-source devices or the wide-field Heidelberg Spectralis lens system. As wide-field OCT becomes more widely adopted, it will be important that parallel development of software ensures that users are presented with easily interpretable data arising from the automated sequential tracking and measurement of these lesions. Ideally, this process will be undertaken across all imaging modalities, such that change can be presented multidimensionally whether based on three-dimensional OCT parameters or two-dimensional measures arising from wavelength-specific reflectance or autofluorescence. Ensuring that this wealth of data is easily and quickly interpretable will be key.

QUANTITATIVE IMAGING: VALIDATION AND ADOPTION

Although these automated measures appear to provide some superiority to the current grading systems, validation of these methods is needed prior to wide-scale acceptance. One may argue that the current grading systems lack the tenets to be considered gold standards,¹⁹ but as there are currently accepted ones, the burden will be on new grading systems to display reliability and validity. Several groups have published the requirements for a tool to be considered valid and reliable. The Outcome Measures in Rheumatology (OMERACT) initiative has worked to improve outcome measures within rheumatology.^{60,61} The crucial component in any outcome is establishing a validated and reliable measurement instrument test.⁶¹ OMERACT developed a filter that summarizes the qualities of an excellent valid instrument measure in three words: truth, discrimination, and feasibility. Truth—does a test measure what is intended? Discrimination—does the measure discriminate between situations of interest? Feasibility—can the measure be applied easily, given constraints of time, money, and interpretability?^{60,61}

Additionally, the COnsensus-based Standards for the selection of health Measurement INstruments (COSMIN) initiative developed standards for evaluating measurement properties of health measurement instruments.⁶²⁻⁶⁴ The three domains to examine include reliability, validity, and responsiveness. Reliability is measured using intra-observer agreement, inter-observer agreement, intraclass correlation, and measurement error. Validity is assessed by properties of content, construct, and criterion validity. Finally, responsiveness is judged by the ability to detect change over time in the construct to be measured.⁶²⁻⁶⁴

Having developed and validated appropriate outcome measures for use as endpoints in the assessment of uveitis, the remaining challenge will be to ensure widespread adoption. Inconsistent use of outcomes reduces the ability to compare trials and aggregate data, limits meta-analysis, and is a major cause of research waste. One way of tackling this, espoused by both OMERACT and the Core Outcome Measures in Effectiveness Trials (COMET) initiative, is to develop core outcome sets (COS).^{61,65} These are standardized sets of outcomes that represent the minimum that should be measured and reported in all clinical trials, other research, or

audits for a specific condition. The COS is not exclusive (other outcome measures can be added as appropriate per trial) and does not dictate which outcome should be the primary endpoint. The COS should engage all stakeholders from the outset. For example, the COS for posterior-segment involving uveitis currently in development will involve patients, carers, expert clinicians, and policy makers through an international Delphi process and consensus meeting to ensure that the final agreed COS has value to the whole community.⁶⁶ It is to be hoped that the rapid onward development and validation of automated imaging quantification systems would mean that they would be eligible for inclusion in future COS for uveitis, and thereby rapidly adopted as standard.

CONCLUSIONS

The use of quantitative imaging in uveitis, and the development of these parameters as endpoints, is for the most part still in a relatively early phase. The unmet need is recognized, and the path to adoption is becoming clearer. Just as these days it would seem absurd to estimate the severity of ME by biomicroscopy alone, so in a few years time it will seem bizarre and antiquated to try to quantify AC cells, vitreous haze, or any other aspect of inflammation by subjective clinical estimation. This move to objective instrument-based quantification does not mean that the patient with uveitis can be reduced to a few key indices. Central macular thickness is indeed only one parameter in the description of a patient with ME; it does not purport to be a holistic assessment of the functional, psychological, or societal consequences of the disease. But it is an extremely useful parameter, the use of which enables us to assess severity, progression and response to treatment at a tissue level, in a way that was never possible prior to the advent of OCT. In a similar way over the next few years we can expect quantitative imaging to replace current clinical estimates and provide the sensitive reliable objective outcome measures that will transform the practice of uveitis, the design of future trials, and the prospects of patients with sight-threatening inflammatory disease.

Acknowledgments

Supported by grants from the Department of Health's NIHR Biomedical Research Centre for Ophthalmology at Moorfields Eye Hospital and UCL Institute of Ophthalmology (PAK; London, UK; NIHR-CS-2014-14-023) and Fight for Sight/Birdshot Uveitis Society (AKD; London, UK; 24BU151). The views expressed in the publication are those of the author and not necessarily those of the Department of Health.

Disclosure: **A.K. Denniston**, None; **P.A. Keane**, Heidelberg (R), Topcon (R), Haag-Streit (R), Allergan (R), Novartis (R, S), Bayer (R, S), Deepmind (C), Optos (C); **S.K. Srivastava**, Santen (F), Optos (F), Zeiss (F), Clearside (F), Sanofi (F), Regeneron (F), Bausch & Lomb (F), Allergan (F)

References

1. Jabs DA, Nussenblatt RB, Rosenbaum JT. Standardization of uveitis nomenclature for reporting clinical data. Results of the First International Workshop. *Am J Ophthalmol*. 2005;140:509-516.
2. Bloch-Michel E, Nussenblatt RB. International Uveitis Study Group recommendations for the evaluation of intraocular inflammatory disease. *Am J Ophthalmol*. 1987;103:234-235.
3. Durrani O, Meads C, Murray P. Uveitis: a potentially blinding disease. *Ophthalmologica*. 2004;218:223-236.

4. Williams GJ, Brannan S, Forrester JV, et al. The prevalence of sight-threatening uveitis in Scotland. *Br J Ophthalmol*. 2007; 91:33-36.
5. Vadot E, Barth E, Billet P. Epidemiology of uveitis—preliminary results of a prospective study in Savoy. In: Sarri KM, ed. *Uveitis Update*. Amsterdam, the Netherlands: Elsevier; 1984; 36-40.
6. Rothova A, Suttorp-van Schulten M, Treffers WF, Kijlstra A. Causes and frequency of blindness in patients with intraocular inflammatory disease. *Br J Ophthalmol*. 1996;80:332-336.
7. Lardenoey CW, Van Kooij B, Rothova A. Impact of macular edema on visual acuity in uveitis. *Ophthalmology*. 2006;113: 1446-1449.
8. Rao NA. Uveitis in developing countries. *Indian J Ophthalmol*. 2013;61:253-254.
9. Denniston AK, Dick AD. Systemic therapies for inflammatory eye disease: past, present and future. *BMC Ophthalmol*. 2013; 24:13:18.
10. Herborg CP Jr, Tugal-Tutkun I, Neri P, Pavésio C, Onal S, LeHoang P. Failure to integrate quantitative measurement methods of ocular inflammation hampers clinical practice and trials on new therapies for posterior uveitis [published online ahead of print December 12, 2016]. *J Ocul Pharmacol Ther*. doi:10.1089/jop.2016.0089.
11. Barry RJ, Denniston AK. Controversies in the pharmacological treatment of uveitis. *Curr Pharm Des*. 2015;21:4682-4687.
12. Gower NJ, Barry RJ, Edmunds MR, Titcomb LC, Denniston AK. Drug discovery in ophthalmology: past success, present challenges, and future opportunities. *BMC Ophthalmol*. 2016;16:11.
13. Denniston AK, Holland GN, Kidess A, et al. Heterogeneity of primary outcome measures used in clinical trials of treatments for intermediate, posterior, and panuveitis. *Orphanet J Rare Dis*. 2015;10:97.
14. Food and Drug Administration. Applications for FDA Approval to Market a New Drug Section 314.126 [50FR7493, Feb 22, 1985, as amended at 50FR21238, May 23, 1985; 55FR11580, Mar 29, 1990; 64FR402, Jan 5, 1999; 67FR 9586, Mar 4, 2002]. Available at: <https://www.accessdata.fda.gov/scripts/cdrh/cfdocs/cfcfr/CFRSearch.cfm?fr=314.126>. Accessed February 28, 2017.
15. Food and Drug Administration. Drug Development Tools Qualification Programs. Available at: <https://www.fda.gov/Drugs/DevelopmentApprovalProcess/DrugDevelopmentToolsQualificationProgram/ucm370262.htm>. Accessed at February 28, 2017.
16. Heiligenhaus A, Foeldvari I, Edelsten C, et al; for the Multinational Interdisciplinary Working Group for Uveitis in Childhood. Proposed outcome measures for prospective clinical trials in juvenile idiopathic arthritis-associated uveitis: a consensus effort from the multinational interdisciplinary working group for uveitis in childhood. *Arthritis Care Res (Hoboken)*. 2012;64:1365-1372.
17. Food and Drug Administration. Guidance for Industry: Expedited Programs for Serious Conditions - Drugs and Biologics. Available at: <https://www.fda.gov/downloads/Drugs/GuidanceComplianceRegulatoryInformation/Guidances/UCM358301.pdf>. Accessed February 20, 2017.
18. Sreekantam S, Macdonald T, Keane PA, Sim DA, Murray PI, Denniston AK. Quantitative analysis of vitreous inflammation using optical coherence tomography in patients receiving sub-Tenon's triamcinolone acetonide for uveitic cystoid macular oedema. *Br J Ophthalmol*. 2017;101:175-179.
19. Sharma S, Lowder CY, Vasanji A, Baynes K, Kaiser PK, Srivastava SK. Automated analysis of anterior chamber inflammation by spectral-domain optical coherence tomography. *Ophthalmology*. 2015;122:1464-1470.
20. Hogan MJ, Kimura SJ, Thygeson P. Signs and symptoms of uveitis: I. Anterior uveitis. *Am J Ophthalmol*. 1964;47:155-170.
21. Schlaegel T. *Essentials of Uveitis*. Boston: Little Brown, Inc.; 1967.
22. Nussenblatt RB, Whitcup SM. Uveitis: *Fundamentals and Clinical Practice*. 3rd ed. Philadelphia: Mosby; 2004.
23. Foster CS, Vitale AT. *Diagnosis and Treatment of Uveitis*. Philadelphia: W.B. Saunders Company; 2002.
24. Kimura SJ, Hogan MJ. Signs and symptoms of uveitis: II. Classification of the posterior manifestations of uveitis. *Am J Ophthalmol*. 1964;47:171-176.
25. Nussenblatt RB, Palestine AG, Chan CC, Roberge F. Standardization of vitreal inflammatory activity in intermediate and posterior uveitis. *Ophthalmology*. 1985;92:467-471.
26. Kempen JH, Ganesh SK, Sangwan VS, Rathinam SR. Interobserver agreement in grading activity and site of inflammation in eyes of patients with uveitis. *Am J Ophthalmol*. 2008;146: 813-818.
27. Hornbeak DM, Payal A, Pistilli M, et al. Interobserver agreement in clinical grading of vitreous haze using alternative grading scales. *Ophthalmology*. 2014;121:1643-648.
28. Huang D, Swanson EA, Lin CP, et al. Optical coherence tomography. *Science*. 1991;254:1178-1181.
29. Hee MR, Puliafito CA, Wong C, et al. Quantitative assessment of macular edema with optical coherence tomography. *Arch Ophthalmol*. 1995;113:1019-1029.
30. Association for Research in Vision and Ophthalmology. *NEI/FDA Workshop in Clinical Trial End-points for Inflammatory Eye Diseases*. Bethesda, MD, March 26, 2015. Available at: http://www.arvo.org/uploadedFiles/ARVOORG/Conferences_and_Courses/Endpoints_Symposia/2015/FDA-NEI%20Workshop_Agenda-0213.pdf.
31. Kempen JH, Sugar EA, Jaffe GJ, et al.; for the Multicenter Uveitis Steroid Treatment (MUST) Trial Research Group. Fluorescein angiography versus optical coherence tomography for diagnosis of uveitic macular edema. *Ophthalmology*. 2013Sep;120:1852-1859.
32. Taylor SR, Lightman SL, Sugar EA, et al. The impact of macular edema on visual function in intermediate, posterior, and panuveitis. *Ocul Immunol Inflamm*. 2012;20:171-181.
33. Sugar EA, Jabs DA, Altaweel MM, et al.; for the Multicenter Uveitis Steroid Treatment (MUST) Trial Research Group. Identifying a clinically meaningful threshold for change in uveitic macular edema evaluated by optical coherence tomography. *Am J Ophthalmol*. 2011;152:1044-1052.e5.
34. Kiss CG, Barisani-Asenbauer T, Maca S, Richter-Mueksch S, Radner W. Reading performance of patients with uveitis-associated cystoid macular edema. *Am J Ophthalmol*. 2006; 142:620-624.
35. Munk M, Kiss C, Huf W, et al. Therapeutic interventions for macular diseases show characteristic effects on near and distance visual function. *Retina*. 2013;33:1915-1922.
36. Kempen JH, Altaweel MM, Holbrook JT, et al.; for the Multicenter Uveitis Steroid Treatment Trial Research Group. Randomized comparison of systemic anti-inflammatory therapy versus fluocinolone acetonide implant for intermediate, posterior, and panuveitis: the multicenter uveitis steroid treatment trial. *Ophthalmology*. 2011;118:1916-1926.
37. Belair ML, Kim SJ, Thorne JE, et al. Incidence of cystoid macular edema after cataract surgery in patients with and without uveitis using optical coherence tomography. *Am J Ophthalmol*. 2009;148:128-135.e2.
38. Lowder C, Belfort R Jr, Lightman S, et al. Dexamethasone intravitreal implant for noninfectious intermediate or posterior uveitis. *Arch Ophthalmol*. 2011;129:545-553.

39. Pelosini L, Hull CC, Boyce JF, et al. Optical coherence tomography may be used to predict visual acuity in patients with macular edema. *Invest Ophthalmol Vis Sci.* 2011;52:2741-2748.
40. Pelosini L, Hull CC, Boyce JF, et al. Optical coherence tomography may be used to predict visual acuity in patients with macular edema. *Invest Ophthalmol Vis Sci.* 2011;52:2741-2748.
41. Lehpamer B, Moshier E, Goldberg N, et al. Subretinal fluid in uveitic macular edema: effect on vision and response to therapy. *Am J Ophthalmol.* 2013;155:143-149.
42. Agarwal A, Ashokkumar D, Jacob S, Saravanan Y. High-speed optical coherence tomography for imaging anterior chamber inflammatory reaction in uveitis: clinical correlation and grading. *Am J Ophthalmol.* 2009;147:413-416.e3.
43. Li Y, Lowder C, Zhang X, Huang D. Anterior chamber cell grading by optical coherence tomography. *Invest Ophthalmol Vis Sci.* 2013;54:258-265.
44. Igbre AO, Rico MC, Garg SJ. High-speed optical coherence tomography as a reliable adjuvant tool to grade ocular anterior chamber inflammation. *Retina.* 2014;34:504-508.
45. Caspi RR, Roberge FG, Chan CC, et al. A new model of autoimmune disease. Experimental autoimmune uveoretinitis induced in mice with two different retinal antigens. *J Immunol.* 1988;140:1490-1495.
46. Leder HA, Campbell JP, Sepah YJ, et al. Ultra-wide-field retinal imaging in the management of non-infectious retinal vasculitis. *J Ophthalmic Inflamm Infect.* 2013;3:30.
47. Bharadwaj AS, Appukuttan B, Wilmarth PA, et al. Role of the retinal vascular endothelial cell in ocular disease. *Prog Retin Eye Res.* 2013;32:102-180.
48. Xu H, Koch P, Chen M, Lau A, Reid DM, Forrester JV. A clinical grading system for retinal inflammation in the chronic model of experimental autoimmune uveoretinitis using digital fundus images. *Exp Eye Res.* 2008;87:319-326.
49. Kerr EC, Copland DA, Dick AD, Nicholson LB. The dynamics of leukocyte infiltration in experimental autoimmune uveoretinitis. *Prog Retin Eye Res.* 2008;27:527-535.
50. Campbell JP, Leder HA, Sepah YJ, et al. Wide-field retinal imaging in the management of noninfectious posterior uveitis. *Am J Ophthalmol.* 2012;154:908-911.e2.
51. Karamelas M, Sim DA, Chu C, et al. Quantitative analysis of peripheral vasculitis, ischemia, and vascular leakage in uveitis using ultra-widefield fluorescein angiography. *Am J Ophthalmol.* 2015;159:1161-1168.e1.
52. Pecun P, Petro K, Baynes K, et al. Peripheral findings and retinal vascular leakage on ultra-widefield fluorescein angiography in patients with uveitis. *Ophthalmology Retina.* In press.
53. Keane PA, Karamelas M, Sim DA, et al. Objective measurement of vitreous inflammation using optical coherence tomography. *Ophthalmology.* 2014;121:1706-1714.
54. Zarranz-Ventura J, Keane PA, Sim DA, et al.; for the EQUATOR Study Group. Evaluation of objective vitritis grading method using optical coherence tomography: influence of phakic status and previous vitrectomy. *Am J Ophthalmol.* 2016;161:172-180.
55. Keane PA, Balaskas K, Sim DA, Aman K, Denniston AK, Aslam T; for the Equator Study Group. Automated analysis of vitreous inflammation using spectral-domain optical coherence tomography. *Trans Vis Sci Tech.* 2015;4(5):4.
56. Knickelbein JE, Hasan J, Nussenblatt RB, Sen HN. Delineation of choroidal and retinal lesions in posterior uveitis by multispectral wide-field scanning laser ophthalmoscopy. *Retina.* 2016;36:2213-2219.
57. Jack LS, Agarwal A, Sepah YJ, Nguyen QD. Spatial agreement between Goldmann visual field defects and fundus autofluorescence in patients with birdshot chorioretinopathy. *J Ophthalmic Inflamm Infect.* 2016;6:18.
58. Madhusudhan S, Keane PA, Denniston AK. Adjunctive use of systematic retinal thickness map analysis to monitor disease activity in punctate inner choroidopathy. *J Ophthalmic Inflamm Infect.* 2016;6:9.
59. Keane PA, Allie M, Turner SJ, et al. Characterization of birdshot chorioretinopathy using extramacular enhanced depth optical coherence tomography. *JAMA Ophthalmol.* 2013;131:341-350.
60. Boers M, Brooks P, Strand V, Tugwell P. The OMERACT Filter for outcome measures in rheumatology. *J Rheumatol.* 1998;25:198-199.
61. Boers M, Kirwan JR, Wells G, et al. Developing core outcome measurement sets for clinical trials: OMERACT filter 2.0. *J Clin Epidemiol.* 2014;67:745-753.
62. Mokkink LB, Terwee CB, Patrick DL, et al. The COSMIN checklist for assessing the methodological quality of studies on measurement properties of health status measurement instruments: an international Delphi study. *Qual Life Res.* 2010;19:539-549.
63. Mokkink LB, Terwee CB, Patrick DL, et al. International consensus on taxonomy, terminology, and definitions of measurement properties for health-related patient-reported outcomes: results of the COSMIN study. *J Clin Epidemiol.* 2010;63:737-745.
64. Terwee CB, Mokkink LB, Knol DL, et al. Rating the methodological quality in systematic reviews of studies on measurement properties: a scoring system for the COSMIN checklist. *Qual Life Res.* 2012;21:651-657.
65. Core Outcome Measures in Effectiveness Trials (COMET) Initiative. Available at: <http://www.comet-initiative.org>. Accessed February 28, 2017.
66. Denniston AK, Calvert M, Murray P, Moore D, Mathers J, Tallouzi M. Defining a core outcome set for efficacy trials in adult patients with posterior segment-involving uveitis. Core Outcome Measures in Effectiveness Trials (COMET) Initiative. Available at: <http://www.comet-initiative.org/studies/details/640>. Accessed February 28, 2017.