

Short-term follow up of right ventricular indices after intervention in pulmonary hypertension

Johannes P. Schwaiger¹, Daniel S. Knight¹, Thomas Kaier¹, Adele Gallimore¹, Christopher Denton², Benjamin E. Schreiber^{1,2}, Clive Handler¹, John G. Coghlan¹

(1) Department of Cardiology, Royal Free London NHS Foundation Trust, Pond Street, London, NW3 2QG

(2) Department of Rheumatology, Royal Free London NHS Foundation Trust, Pond Street, London, NW3 2QG

Address correspondence to:

- Dr. Johannes Schwaiger, johannesschwaiger1@gmail.com
Schuetzenweg 5, 6067 Absam, Austria

Short title: short term follow-up in pulmonary hypertension

Keywords: echocardiography, pulmonary hypertension, follow-up, Systemic Sclerosis

ABSTRACT

Data are scarce about short-term right ventricular changes after intervention for pulmonary hypertension, in particular about Systemic Sclerosis associated pulmonary arterial hypertension (PAH).

In this pilot study we have performed prospective short-term follow-up after intervention in 14 pulmonary hypertension patients using a novel echocardiography technique, 2D echocardiography knowledge based reconstruction (2DKBR) of the right ventricle. 12 patients had pulmonary arterial hypertension (PAH) and 2 had chronic thromboembolic pulmonary hypertension (CTEPH). The majority of the PAH patients had PAH associated with Systemic Sclerosis (n=8). Patients underwent either initiation of new targeted therapy (n=9) or escalation of targeted therapy for PAH (n=3) or pulmonary endarterectomy for CTEPH (n=2).

After a mean follow up of 4.8 +/- 2.6 months 2DKBR detected significant improvements in the right ventricular end-diastolic volume index (107 +/- 22 vs 89 +/- 20 ml/m²; p=0.015), end-systolic volume index (74 +/- 20 vs 55 +/- 17 ml/m²; p<0.001) and ejection fraction (30 +/- 9 vs 39 +/- 9%; p=0.011). These changes were accompanied by significant changes in NT-proBNP (Median 209, IQ 364 vs 63, IQ 87) pmol/L; p=0.004) and 6MWT levels (241 +/- 124 vs. 375 +/-118 m; p=0.005).

There were significant improvements of right ventricular volumes and ejection fraction shortly after intervention in a mixed pulmonary hypertension population which was dominated by systemic sclerosis associated PAH. 2D echocardiography using knowledge based reconstruction might be a useful alternative imaging modality to follow up patients with pulmonary hypertension.

Introduction

Pulmonary hypertension (PH) leads to pressure overload of the right ventricle which causes hypertrophy and eventual failure of the right ventricle (RV). In terms of symptoms and prognosis in this patient group right ventricular function is the main determinant (1, 2).

2D echocardiography, the most widely available cardiac imaging modality has significant limitations due to the unique crescent shape of the right ventricle(3). Both linear and RV area measurements can be challenging and can significantly underestimate true RV size(4). Also, parameters of systolic function assessed with 2D-echocardiography showed only moderate correlation in several studies (5, 6).

Cardiac magnetic resonance (CMR) imaging has evolved as the gold standard for imaging of the right ventricle(7) and studies have suggested that both changes in RV volume and ejection fraction (8-10) predict outcome in pulmonary hypertension. However CMR is costly, resource intensive and not widely available in low-income countries which makes it less suitable for serial follow, in particular short-term follow-up. Also, CMR is contraindicated in many patients with implanted ferromagnetic devices.

Commercially available 3D echocardiography has been compared to CMR, however this technique exhibits only moderate reproducibility of RV volumes and ejection fraction(11) and exhibits a negative bias in ejection fraction and RV volumes(12).

We and others have recently compared 2D echocardiography knowledge-based reconstruction (2DKBR) of the right ventricle to CMR for volumetric quantification in pulmonary hypertension demonstrating good inter- and intraobserver reproducibility (5, 13). Feasibility of this method was also demonstrated in other studies (14-16).

Data are scarce about short-term right ventricular changes after intervention in pulmonary hypertension, in particular in pulmonary arterial hypertension associated with Systemic Sclerosis. In this paper we describe the use of short-term serial 2DKBR to evaluate change in RV indices in a mixed PH population which was dominated by PAH associated with systemic sclerosis (SSc).

Methods

PATIENTS

In this prospective study 14 patients with pulmonary hypertension underwent baseline and short term follow-up 2DKBR of the right ventricle after intervention, mean follow-up was 4.8 +/- 2.6 months. 12 patients had pulmonary arterial hypertension (PAH) and 2 patients had chronic thromboembolic pulmonary hypertension (CTEPH). Table 1 shows baseline characteristics of all patients, the majority of the PAH patients had PAH associated with systemic sclerosis (n=8). All patients underwent clinical assessment including 6MWT (six minute walking test), NT-proBNP levels and assessment of their NYHA status at baseline and follow-up.

After baseline 2DKBR 9 PAH patients were newly initiated on disease-targeted therapy (4 on single targeted therapy, 5 on double combination therapy), 3 PAH patients were prescribed escalation of targeted therapies (all CTD-associated PAH) and 2 CTEPH patients underwent pulmonary endarterectomy (PEA) during follow up (table 1).

Escalation therapy was defined as change from single to double combination targeted therapy or from double combination to triple combination therapy including intravenous epoprostenol. Two CTD patients underwent additional therapy with intravenous cyclophosphamide during follow-up: one patient who was newly diagnosed with SLE-associated PAH and one patient who was escalated in targeted treatment for PAH associated with mixed connective tissue disease (MCTD).

ECHOCARDIOGRAPHY

All echocardiograms in this study were performed by the first author as part of routine patient assessment. Transthoracic echocardiographic images were acquired using standard ultrasound equipment (Philips iE33 and S5 transducer) following current guidelines (17, 18). For 2DKBR the VMS system was used (Ventripoint Diagnostics Ltd., Seattle, WA, US) as previously described (5). In brief, a 3D RV volume is generated from 2DE-acquired coordinates localised in 3D space that are then connected by reference to a library of disease-specific RV shapes (hybrid approach). A magnetic localiser was attached to the S5-1 probe which detects orthogonal magnetic fields from a generator hanging over the patient and allows localisation at the point of any 2D acquisition in 3D space.

Seven views were obtained, six of which were standard 2D echocardiographic views, one view an off-axis RV apical view. After visual identification of the end-diastolic and end-systolic frames in four-chamber view, predefined points were plotted for each end-diastolic and end-systolic data sets. The coordinates of these landmarks were then submitted via internet to a remote server for processing by a proprietary 2DKBR algorithm. The algorithm interpolates between the plotted points by referencing against a catalogue of RV shapes generated by CMR imaging from patients with a known diagnosis of pulmonary hypertension (Figure 1).

During post-processing intersections between the borders of the 3D model and the original 2D scan plane were checked for alignment, and in case of significant deviation either re-plotted or the algorithm re-run. A data set was excluded if more than one slice was unsuitable for analysis. A significant change in end-diastolic volume index (EDVI) was defined as a change of $> 14\%$, based on results of Bland-Altman-analysis of our previous work (twice the standard deviation of the bias)(5).

RIGHT HEART CATHETERIZATION

All incident patients and patients who had a change in disease targeted therapy underwent Right Heart Catheterization within 2 weeks of echocardiography (usually on the same day). The following pressures were obtained: right atrium (RA), pulmonary artery (PA), pulmonary capillary wedge pressure (PCWP). CO was determined with the Thermodilution Method. Mixed venous saturations were taken in Pulmonary artery and systemic oxygen saturation was obtained with finger oximetry.

LAB TESTING

For measurement of NT-proBNP venous blood samples were either collected at the end of right heart catheterization or during follow-up visits in outpatient clinic and processed at the Laboratory of the Royal Free Hospital.

Statistics

Statistical analysis was performed using SPSS 21.0 (IBM Corporation, Armonk, New York, USA). Kolmogorov-Smirnov tests (Lilliefors correction) were used to test for normal distribution of variables. Comparison of continuous variables at baseline and follow-up was performed by using paired t-tests or Related-Samples Wilcoxon Signed Rank Test in the case of non-normally distributed variables. Comparison of stable patients versus worsening patients was performed using unpaired t-tests or Wilcoxon

in the case of non-normally distributed variables. Pearson's correlations were performed to calculate correlation coefficients, Spearman's correlations were performed to test for correlations with non-normally distributed variables.

RESULTS

Two patients had to be excluded from analysis due to insufficient quality of reconstruction secondary to significant patient movement, one with portopulmonary hypertension (POPH) and the other with SSc-associated PAH.

With the exception of the right ventricular stroke volume index (RVSVI) and cardiac index (CI) there was significant improvement in all variables measured during 2DKBR and RHC (Table 2). Mean right ventricular end-diastolic volume index (RVEDVI) decreased by 18mls ($p=0.015$), mean right ventricular end-systolic volume index (RVESVI) decreased by 19 mls ($p<0.001$) and mean right ventricular ejection fraction (RVEF) increased by 9% ($p=0.011$). NT-proBNP levels fell by a median of 254 pmol/l ($p=0.004$) and 6 MWT results fell by a mean of 134m ($p=0.005$).

Eight out of twelve patients experienced improvement of more than 14% of their baseline EDVI during follow up. Worsening of EDVI occurred in two patients and two patient remained within 14% of their EDVI at baseline (Figure 2). The patients who increased their EDVI were one MCTD patient who was escalated therapy from double to triple combination targeted therapy and one SSc-patient who was newly started on Sildenafil. Of seven patients with SSc-PAH (where 2DKBR data was available) who were initiated or escalated in therapy five patients improved their EDVI by more than 14%.

In patients who improved their EDVI by more than 14% NT-proBNP levels consistently fell by a minimum of 73% of their baseline value (Figure 3).

Discussion

In this study we documented significant short-term changes of RV-indices in patients who underwent an intervention for PH during follow-up, either initiation, escalation of targeted therapy or pulmonary endarterectomy. The majority of our patients had PAH associated with SSc and despite the short follow up in our study and the known adverse prognosis of this group of PAH patients we documented both significant improvement of RV volumes and RV ejection fraction.

We have used a novel echocardiographic technique, namely knowledge-based 2D echocardiography reconstruction of the right ventricle to follow-up RV indices in a pulmonary hypertension patient population. This technique proved to be feasible in a busy clinical setting, all exams were done by one person using standard 2D echocardiography equipment plus the equipment needed for KBR. The majority of exams were done immediately after right heart catheterisation within the same unit or on the same day of their clinical follow-up.

Our study differs from previous imaging studies in PH. It is the first to offer an insight into short term right ventricular changes after intervention. Despite being clinically severely affected with significant RV dilatation at treatment initiation they exhibited a reduction in RV-EDVI to a similar degree to that documented in previous CTEPH/PEA studies(19). Secondly our study included mostly CTD-PAH patients, predominantly patients with SSc associated PAH. This group is recognised to have poor outcome and also might be predicted to have less favourable changes in right ventricular function compared with other types of PAH due to the potential additional burden of myocardial involvement from SSc.

This may explain why our results are only partly aligned with previous longitudinal imaging studies in PH. In CTEPH studies offering short term follow up are available and have demonstrated regression of RV remodelling after PEA or Balloon pulmonary angioplasty (19, 20). In IPAH or mixed PAH populations the situation is different, data is scarce on short-term follow less than 12 months after intervention.

One 2D-echo study demonstrated improvement of RV-dimensions and parameters of RV-function after one year of treatment with prostacyclin analogues in a mixed PAH population. In this study mean 2D RV dimensions were significantly dilated at baseline(21). Using MRI, van Wolferen et al. conducted a study in 64 incident IPAH

patients and observed a significant reduction in RV-EDVI after 12 months of PAH-targeted treatment (8). Mean EDVI in that study was mildly elevated at baseline and almost half of the patients received intravenous prostacyclins. Later the same group performed serial MRI scans in a population of 76 incident PAH patients, predominantly IPAH. In this second study there was no significant change in EDVI after 12 months, but mean EDVI was already normal at baseline (9). In that study 31% of patients were on combination therapy and 15% on prostacyclins. The recent Euro-MR study involved serial CMR studies in 91 patients with PAH (mostly IPAH) and found significant improvements in RV ejection fraction and RV stroke volume, but no significant change in RV-EDVI over a period of 12 months(10). The right ventricles in this study were mildly enlarged, and only a minority of patients were on prostanoid therapy (5%) or on combination therapy (9.9%).

Factors that may influence the ability to document remodelling of the RV include the presence of RV-dilatation at the time of the treatment initiation, the magnitude and effect of therapy, the chosen follow-up period or the characteristics of the pulmonary vascular disease itself. Our study differs from above mentioned studies that it included mostly SSc-patients, RV volumes were significantly dilated at baseline, more than half of our patients were on combination therapy and there was a significantly shorter period of follow-up.

CTD-associated PAH differs from IPAH in its clinical course (22, 23) and also in its histological appearance (24). CTD-associated PAH and in particular SSC-PAH have a poorer RV tolerance of pulmonary hypertension than other forms of PAH (25, 26) which could also favour a larger change in RV indices as a response to aggressive therapy, at least in the short-term.

Ventricular remodelling in PAH can be differentiated into two patterns (27): adaptive remodelling with concentric hypertrophy, preserved function and maladaptive remodelling with eccentric hypertrophy and worsening function. Our study shows that within several months a change from one pattern to the other can occur with medical therapy, even in Systemic Sclerosis.

STRENGTHS OF OUR STUDY

This study is the first to give insight into short-term changes of RV volumes after intervention in a SSc-PAH dominated population. Despite the poor long-term prognosis of this patient group we have seen that relevant EDVI changes can occur within a short period of time. Also this is the first study using 2DKBR to follow-up patients with PAH demonstrating that this technique is feasible and easy to perform in daily practice.

Our study has a number of limitations. This was an observational single-centre study with relatively few subjects enrolled. Larger studies, with longer periods of follow-up are needed, in particular in SSc to better define RV-geometry at baseline and responses to therapy in this unique subpopulation within the PAH subgroup. All echocardiograms were done by a single person which is rarely the case in daily clinical practice, however there was no significant intra- and interobserver test-retest variability for RV-volumes in a recent validation study of 2DKBR(5). Finally, this was an unblinded and observational study, with the investigator aware of the patient treatment status both at the time of performing the echocardiogram and during analysis.

CONCLUSION

In a short-term follow-up of a SSc dominated pulmonary hypertension patient population we have observed significant changes in RV volumes and RV ejection fraction in patients after intervention, either initiation or escalation of targeted therapy or pulmonary endarterectomy. 2D echocardiography knowledge based reconstruction might be a useful alternative to other imaging modalities under various circumstances, e.g. regular short-term follow up or use in lower income countries.

Table 1 – baseline characteristics of all patients (n = 14). +/- indicates standard deviation (SD). NT-proBNP presented as median and interquartile range

Age, years	57 +/- 12
Sex, females/males	11/3
PAH – associated with CTD/POPH	10/2
CTD-PAH (SSc, MCTD, Lupus)	8/1/1
CTEPH, n	2
Body surface area, m ²	1.7 +/- 0.2
New targeted therapy (Single/combination)	4/5
Escalation of targeted therapy	3
PEA for CTEPH	2

CTEPH (chronic thromboembolic pulmonary hypertension), CTD (connective tissue disease), MCTD (mixed connective tissue disease), PAH (pulmonary arterial hypertension), PEA (pulmonary endarterectomy), POPH (portopulmonary Hypertension), RVEDVI (right ventricular end-diastolic volume index), RVEF (right ventricular ejection fraction), RVESVI (right ventricular end-systolic volume index), RVSVI (stroke volume index), SSc (Systemic Sclerosis),

Table 2 – baseline and follow up variables

	Pre	Post	p-value
NYHA FC	3.2 +/- 0.4	2.1 +/- 0.5	0.004#
NT-pro BNP (pmol/l)	200; 364	83; 87	0.004#
6MWT (m)	241 +/- 124	375 +/- 118	0.005
PVR, (dyn)	720 +/- 280	435 +/- 159	0.002
CI (RHC) (l/min)	2.8 +/- 0.7	3.2 +/- 0.6	0.25
PAm (mmHg)	50 +/- 7	38 +/- 9	<0.001
RVEDVI (ml/m ²)	107 +/- 22	89 +/- 20	0.015
RVESVI (ml/m ²)	74 +/- 20	55 +/- 17	<0.001
RVSVI (ml/m ²)	32 +/- 12	34 +/- 12	0.6
RVEF (%)	30 +/- 9	39 +/- 9	0.011

Related-Samples Wilcoxon Signed Rank Test. NT-pro BNP given as median and interquartile range. 6MWT (six minute walking test), CI (cardiac index), RHC (right heart catheterization), Pam (mean pulmonary artery pressure), PVR (pulmonary vascular resistance)

Figure captions

Figure 1 – 3D model of both baseline and follow-up knowledge-based reconstruction of the right ventricle in a patient with newly diagnosed PAH associated with Systemic Sclerosis (female, 50 years). Patient was prescribed combination therapy (Tadalafil, Bosentan). (RVEDVI at baseline 123.5mls, RVEDVI at follow up 105.8mls. RVEF at baseline 22%, at follow up 42%)

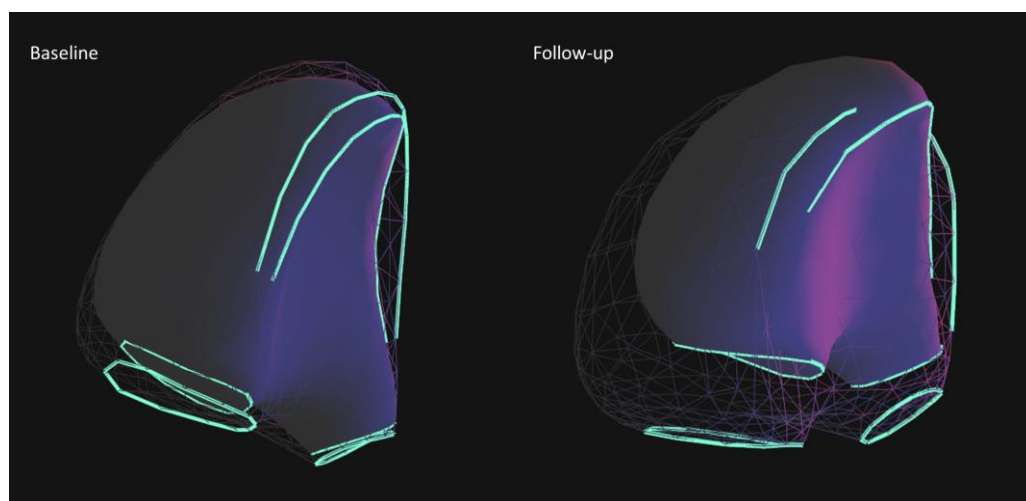


Figure 2 – EDVI at baseline and follow up of all patients. Continuous line: improvement of more than 14% of baseline EDVI. Dotted line: patients within 14% of baseline EDVI (stable). Dashed line: worsening of more than 14% of baseline EDVI

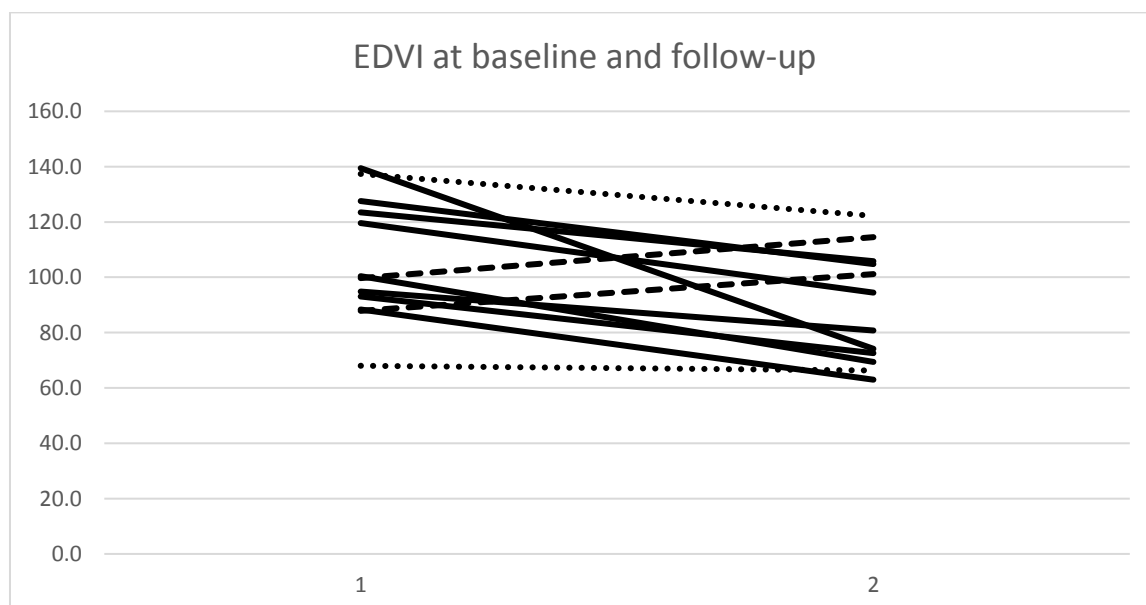
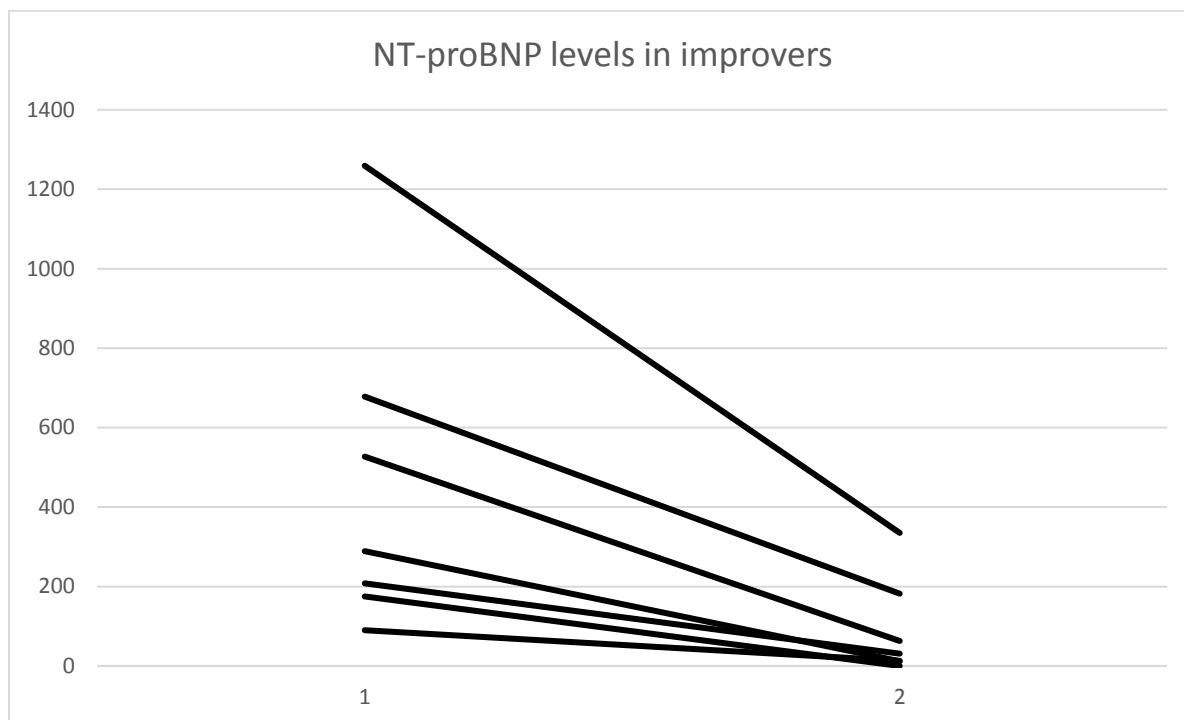


Figure 3 – NT-proBNP trend in all patients with EDVI improvement of more than 14%



Reference List

1. Galie N, Hoeper MM, Humbert M, Torbicki A, Vachiery JL, Barbera JA, Beghetti M, Corris P, Gaine S, Gibbs JS, Gomez-Sanchez MA, Jondeau G, Klepetko W, Opitz C, Peacock A, Rubin L, Zellweger M, Simonneau G. Guidelines for the diagnosis and treatment of pulmonary hypertension: the Task Force for the Diagnosis and Treatment of Pulmonary Hypertension of the European Society of Cardiology (ESC) and the European Respiratory Society (ERS), endorsed by the International Society of Heart and Lung Transplantation (ISHLT). *Eur Heart J* 2009;**30**(20):2493-2537.
2. Chin KM, Kim NH, Rubin LJ. The right ventricle in pulmonary hypertension. *Coron Artery Dis* 2005;**16**(1):13-18.
3. Ho SY, Nihoyannopoulos P. Anatomy, echocardiography, and normal right ventricular dimensions. *Heart* 2006;**92** Suppl 1:i2-13.
4. Grunig E, Biskupek J, D'Andrea A, Ehlken N, Egenlauf B, Weidenhammer J, Marra AM, Cittadini A, Fischer C, Bossone E. Reference Ranges for and Determinants of Right Ventricular Area in Healthy Adults by Two-Dimensional Echocardiography. *Respiration* 2015;**89**(4):284-93.
5. Knight DS, Schwaiger JP, Krupickova S, Davar J, Muthurangu V, Coghlan JG. Accuracy and Test-Retest Reproducibility of Two-Dimensional Knowledge-Based Volumetric Reconstruction of the Right Ventricle in Pulmonary Hypertension. *J Am Soc Echocardiogr* 2015;**28**(8):989-98.
6. Shiran H, Zamanian RT, McConnell MV, Liang DH, Dash R, Heidary S, Sudini NL, Wu JC, Haddad F, Yang PC. Relationship between echocardiographic and magnetic resonance derived measures of right ventricular size and function in patients with pulmonary hypertension. *J Am Soc Echocardiogr* 2014;**27**(4):405-412.
7. Peacock AJ, Vonk NA. Cardiac magnetic resonance imaging in pulmonary arterial hypertension. *Eur Respir Rev* 2013;**22**(130):526-534.
8. van Wolferen SA, Marcus JT, Boonstra A, Marques KM, Bronzwaer JG, Spreeuwenberg MD, Postmus PE, Vonk-Noordegraaf A. Prognostic value of right ventricular mass, volume, and function in idiopathic pulmonary arterial hypertension. *Eur Heart J* 2007;**28**(10):1250-1257.
9. van de Veerdonk MC, Kind T, Marcus JT, Mauritz GJ, Heymans MW, Bogaard HJ, Boonstra A, Marques KM, Westerhof N, Vonk-Noordegraaf A. Progressive right ventricular dysfunction in patients with pulmonary arterial hypertension responding to therapy. *J Am Coll Cardiol* 2011;**58**(24):2511-2519.
10. Peacock AJ, Crawley S, McLure L, Blyth K, Vizza CD, Poscia R, Francone M, Iacucci I, Olschewski H, Kovacs G, Vonk NA, Marcus JT, van de Veerdonk MC, Oosterveer FP. Changes in right ventricular function measured by cardiac magnetic resonance imaging in patients receiving pulmonary arterial hypertension-targeted therapy: the EURO-MR study. *Circ Cardiovasc Imaging* 2014;**7**(1):107-114.
11. Grapsa J, O'Regan DP, Pavlopoulos H, Durighel G, Dawson D, Nihoyannopoulos P. Right ventricular remodelling in pulmonary arterial hypertension with three-dimensional echocardiography: comparison with cardiac magnetic resonance imaging. *Eur J Echocardiogr* 2010;**11**(1):64-73.

12. Shimada YJ, Shiota M, Siegel RJ, Shiota T. Accuracy of right ventricular volumes and function determined by three-dimensional echocardiography in comparison with magnetic resonance imaging: a meta-analysis study. *J Am Soc Echocardiogr* 2010;**23**(9):943-953.
13. Bhawe NM, Patel AR, Weinert L, Yamat M, Freed BH, Mor-Avi V, Gomberg-Maitland M, Lang RM. Three-dimensional modeling of the right ventricle from two-dimensional transthoracic echocardiographic images: utility of knowledge-based reconstruction in pulmonary arterial hypertension. *J Am Soc Echocardiogr* 2013;**26**(8):860-867.
14. Trzebiatowska-Krzynska A, Driessen M, Sieswerda GT, Wallby L, Swahn E, Meijboom F. Knowledge-based 3D reconstruction of the right ventricle: comparison with cardiac magnetic resonance in adults with congenital heart disease. *Echo Research and Practice* 2014;**2**(4):109-116.
15. Kutty S, Li L, Polak A, Gribben P, Danford DA. Echocardiographic knowledge-based reconstruction for quantification of the systemic right ventricle in young adults with repaired D-transposition of great arteries. *Am J Cardiol* 2012;**109**(6):881-888.
16. Dragulescu A, Grosse-Wortmann L, Fackoury C, Riffle S, Waiss M, Jaeggi E, Yoo SJ, Friedberg MK, Mertens L. Echocardiographic assessment of right ventricular volumes after surgical repair of tetralogy of Fallot: clinical validation of a new echocardiographic method. *J Am Soc Echocardiogr* 2011;**24**(11):1191-1198.
17. Rudski LG, Lai WW, Afilalo J, Hua L, Handschumacher MD, Chandrasekaran K, Solomon SD, Louie EK, Schiller NB. Guidelines for the echocardiographic assessment of the right heart in adults: a report from the American Society of Echocardiography endorsed by the European Association of Echocardiography, a registered branch of the European Society of Cardiology, and the Canadian Society of Echocardiography. *J Am Soc Echocardiogr* 2010;**23**(7):685-713.
18. Lang RM, Bierig M, Devereux RB, Flachskampf FA, Foster E, Pellikka PA, Picard MH, Roman MJ, Seward J, Shanewise JS, Solomon SD, Spencer KT, Sutton MS, Stewart WJ. Recommendations for chamber quantification: a report from the American Society of Echocardiography's Guidelines and Standards Committee and the Chamber Quantification Writing Group, developed in conjunction with the European Association of Echocardiography, a branch of the European Society of Cardiology. *J Am Soc Echocardiogr* 2005;**18**(12):1440-1463.
19. Reesink HJ, Marcus JT, Tulevski II, Jamieson S, Kloek JJ, Vonk NA, Bresser P. Reverse right ventricular remodeling after pulmonary endarterectomy in patients with chronic thromboembolic pulmonary hypertension: utility of magnetic resonance imaging to demonstrate restoration of the right ventricle. *J Thorac Cardiovasc Surg* 2007;**133**(1):58-64.
20. Tsugu T, Murata M, Kawakami T, Yasuda R, Tokuda H, Minakata Y, Tamura Y, Kataoka M, Hayashida K, Tsuruta H, Maekawa Y, Inoue S, Fukuda K. Significance of echocardiographic assessment for right ventricular function after balloon pulmonary angioplasty in patients with chronic thromboembolic induced pulmonary hypertension. *Am J Cardiol* 2015;**115**(2):256-261.
21. Tonelli AR, Conci D, Tamarappoo BK, Newman J, Dweik RA. Prognostic value of echocardiographic changes in patients with pulmonary arterial hypertension receiving parenteral prostacyclin therapy. *J Am Soc Echocardiogr* 2014;**27**(7):733-741.
22. Condliffe R, Kiely DG, Peacock AJ, Corris PA, Gibbs JS, Vrapic F, Das C, Elliot CA, Johnson M, DeSoyza J, Torpy C, Goldsmith K, Hodgkins D, Hughes RJ, Pepke-Zaba J, Coghlan JG.

- Connective tissue disease-associated pulmonary arterial hypertension in the modern treatment era. *Am J Respir Crit Care Med* 2009;**179**(2):151-157.
23. Zhang R, Dai LZ, Xie WP, Yu ZX, Wu BX, Pan L, Yuan P, Jiang X, He J, Humbert M, Jing ZC. Survival of Chinese patients with pulmonary arterial hypertension in the modern treatment era. *Chest* 2011;**140**(2):301-309.
 24. Dorfmueller P, Humbert M, Perros F, Sanchez O, Simonneau G, Muller KM, Capron F. Fibrous remodeling of the pulmonary venous system in pulmonary arterial hypertension associated with connective tissue diseases. *Hum Pathol* 2007;**38**(6):893-902.
 25. Chung L, Liu J, Parsons L, Hassoun PM, McGoan M, Badesch DB, Miller DP, Nicolls MR, Zamanian RT. Characterization of connective tissue disease-associated pulmonary arterial hypertension from REVEAL: identifying systemic sclerosis as a unique phenotype. *Chest* 2010;**138**(6):1383-1394.
 26. Campo A, Mathai SC, Le PJ, Zaiman AL, Hummers LK, Boyce D, Houston T, Champion HC, Lechtzin N, Wigley FM, Girgis RE, Hassoun PM. Hemodynamic predictors of survival in scleroderma-related pulmonary arterial hypertension. *Am J Respir Crit Care Med* 2010;**182**(2):252-260.
 27. Vonk-Noordegraaf A, Haddad F, Chin KM, Forfia PR, Kawut SM, Lumens J, Naeije R, Newman J, Oudiz RJ, Provencher S, Torbicki A, Voelkel NF, Hassoun PM. Right heart adaptation to pulmonary arterial hypertension: physiology and pathobiology. *J Am Coll Cardiol* 2013;**62**(25 Suppl):D22-D33.
 28. Blyth KG, Groenning BA, Mark PB, Martin TN, Foster JE, Steedman T, Morton JJ, Dargie HJ, Peacock AJ. NT-proBNP can be used to detect right ventricular systolic dysfunction in pulmonary hypertension. *Eur Respir J* 2007;**29**(4):737-744.
 29. Fijalkowska A, Kurzyna M, Torbicki A, Szewczyk G, Florczyk M, Pruszczyk P, Szturmowicz M. Serum N-terminal brain natriuretic peptide as a prognostic parameter in patients with pulmonary hypertension. *Chest* 2006;**129**(5):1313-1321.
 30. Gan CT, McCann GP, Marcus JT, van Wolferen SA, Twisk JW, Boonstra A, Postmus PE, Vonk-Noordegraaf A. NT-proBNP reflects right ventricular structure and function in pulmonary hypertension. *Eur Respir J* 2006;**28**(6):1190-1194.
 31. Wiese S, Breyer T, Dragu A, Wakili R, Burkard T, Schmidt-Schweda S, Fuchtbauer EM, Dohrmann U, Beyersdorf F, Radicke D, Holubarsch CJ. Gene expression of brain natriuretic peptide in isolated atrial and ventricular human myocardium: influence of angiotensin II and diastolic fiber length. *Circulation* 2000;**102**(25):3074-3079.
 32. Vanderheyden M, Goethals M, Verstreken S, De BB, Muller K, Van SE, Bartunek J. Wall stress modulates brain natriuretic peptide production in pressure overload cardiomyopathy. *J Am Coll Cardiol* 2004;**44**(12):2349-2354.
 33. Ghio S, Pazzano AS, Klersy C, Scelsi L, Raineri C, Camporotondo R, D'Armini A, Visconti LO. Clinical and prognostic relevance of echocardiographic evaluation of right ventricular geometry in patients with idiopathic pulmonary arterial hypertension. *Am J Cardiol* 2011;**107**(4):628-632.