

# The management of radiologically indeterminate MRI signal in men at risk of prostate cancer

---

Esmée Coco Alyne van der Sar\* BSc,  
Veeru Kasivisvanathan\* MBBS  
Mrishta Brizmohun MD,  
Alex Freeman MD,  
Shonit Punwani PhD,  
Rifat Hamoudi PhD,  
Mark Emberton Professor of Interventional Oncology.

\*These authors share joint first authorship of this paper

## Affiliations

X. Faculty of Medical Science, University College London

Word count of text: 2429

Word count of abstract: 300

Key words: Indeterminate mp-MRI, likert-score, mp-MRI, prostate biopsy, prostate cancer.

# The management of radiologically indeterminate MRI signal in men at risk of prostate cancer

---

Esmée C.A. van der Sar\*, Veeru Kasivisvanathan\*, Mrishta Brizmohun, Alex Freeman, Shonit Punwani, Rifat Hamoudi, Mark Emberton (1)

## Affiliations

X. Faculty of Medical Science, University College London

\*These authors share joint first authorship of this paper

Contact information for corresponding author:

Esmée van der Sar  
Oudeschans 29E3  
1011KT Amsterdam  
[esmeevandersar@hotmail.com](mailto:esmeevandersar@hotmail.com)  
00316 18436533

Keywords: Indeterminate mp-MRI, likert-score, mp-MRI, prostate biopsy, prostate cancer.

Number of words: 2729

Abstract: 300

Introduction: 243

Methods: 578

Results: 492

Discussion: 1030

Conclusion: 86

## **Abstract**

### **Introduction:**

Multiparametric-MRI (mp-MRI) is becoming an increasingly important diagnostic tool for prostate cancer. So far there has been little focus on the management of the indeterminate mp-MRI result.

### **Objective:**

Describe the outcomes of a cohort of men who were rated as having an indeterminate mp-MRI result.

### **Design, setting, and participants:**

Patients were identified retrospectively from a single UK centre between October 2010 and January 2015. Patients were included if they had a Likert score of 3/5 on first MRI scan without any prior prostate biopsy. Patients were offered one of two initial management strategies. Strategy-One was an immediate targeted biopsy to the MRI lesion. Strategy-Two was a process of surveillance comprising of PSA (prostate specific antigen) monitoring and 6-12 months interval mp-MRI with biopsy on a for-cause basis. Cancer detection and treatment outcomes were compared between both strategies.

### **Results and limitations:**

Of 168 patients, 73 (43%) men chose Strategy-One and 95 (57%) men chose Strategy-Two. The overall proportion of men with clinically significant cancer detected was 14% (23/168). The risk profile of cancer identified in the initial surveillance group was similar to that identified in the immediate biopsy group. Limitations of the study include the short follow-up.

### **Conclusions:**

Men with an indeterminate mp-MRI were willing to forego immediate biopsy for a strategy of surveillance with PSA and interval mp-MRI. The risk profile of the cancers identified by both strategies appeared similar but many men avoided the risks, complications and costs of biopsy. Long-term results are awaited.

### **Patient summary:**

In this report two approaches for an uncertain MRI result for clinically important prostate cancer were compared; immediate biopsy versus the strategy of surveillance with delayed biopsy if required. Delayed biopsy did not result in cancer

with adverse features being identified and many men benefitted from avoiding a biopsy and its complications.

## **Introduction (2425 words)**

The increasingly important role of multiparametric-MRI (mp-MRI) in relation to prostate cancer diagnosis and staging is being supported by the growing literature over recent years [1-3]. However, the literature has mostly confined itself to exploring the consequences of the lower and upper extreme test outputs – in other words, the negative and the positive scans. The clinical consequences of these test results are important. A negative result that is associated with a high negative predictive value for clinically significant disease could avoid many unnecessary biopsies [4]. A positive result, through its ability to assist in locating where within the gland the biopsy needles are deployed, can result in a greater proportion of men diagnosed with clinically significant disease [5].

So far very little attention has focused on the indeterminate results (grey zones) – an mp-MRI result that is neither fully positive nor fully negative. Current recommendations adopt confidence rating for the likelihood of having clinically significant cancer in which it is possible to derive a midpoint on an ordinal scale of 1 through 5 corresponding to a 3/5 score - indeterminate for significant cancer [6-8]. Recent Level 1 evidence has shown that in a group of biopsy naïve men, a mp- MRI will have an indeterminate score in 28% of cases [3].

This cohort describes the outcome of men who were rated as having an indeterminate mp-MRI in order to better inform patients and clinicians for the shared decision-making process in the face of uncertainty.

## **Material and Methods**

### *Patient population and study design*

Patients were identified retrospectively from a single UK centre. All men referred with clinical suspicion of prostate cancer based on raised PSA and/or positive family history and/or abnormal digital rectal examination and who had an mp-MRI of the prostate (between October 2010 and January 2015) as a first time assessment of prostate cancer risk were eligible.

The mp-MRI scan was scored by one of three expert prostate uro-radiologists for the likelihood of the presence of significant prostate cancer using the Likert scale (Score 1, highly unlikely; score 2, unlikely; score 3, equivocal; score 4, likely to be present; score 5, highly likely to be present)[6, 7]). The radiologists had 10, 11 and 13 years of experience in prostate MRI reporting with each reporting >500 prostate mp-MRI scans per year. Likert scale was used as the study was designed prior to the latest Prostate Imaging Reporting and Data Systems (PI-RADS) publication [9] and previous studies have shown their performances to be comparable[8, 10]. Moreover, the Likert scale has been recently validated prospectively [3]. All men who had an mp-MRI score of 3/5 were included in the study.

These men, as part of routine care, were offered a choice between two management strategies that reflect the uncertainty associated with the indeterminate mp-MRI status. Strategy-One involved immediate targeted biopsy of the MRI lesion. Strategy-Two comprised close surveillance by means of PSA monitoring and 6-12 months interval mp-MRI. Within Strategy-Two, the trigger for targeted biopsy during follow-up was any of the following: PSA progression, mp-MRI progression, mp-MRI non-resolution or patient choice.

#### *MR equipment and image acquisition protocol*

An mp-MRI of the prostate was performed using a 3T magnet (MAGNETOM® Verio 3T, Siemens Healthcare, Erlangen, Germany) equipped with a pelvic phased-array coil. The mp-MRI included T2-weighted imaging, dynamic contrast enhanced sequences (DCE) and diffusion weighted imaging (DWI):

1. T2WI: axial and coronal planes; slice thickness, 3mm; TR, 5970ms; TE, 101ms; in plane resolution 0.625 x 0.625; matrix 320x320.
2. DCE: slice thickness, 3 mm; TR, 4.06ms; TE, 1.46ms; flip angle, 10 degrees in plane resolution 1 x 1 mm; matrix 256x256.
3. DWI sequences: slice thickness, 5 mm; TR, 4300ms; TE, 80ms; and b values of 0, 100, 300, 800 and 1000 s/mm<sup>2</sup> from which an apparent diffusion coefficient map

was generated. Also a high-b-value of 2000 s/mm<sup>2</sup> was acquired with slice thickness of, 5 mm; TR, 7500ms; and TE, 79ms.

### *Biopsy specifications and protocols*

Biopsy was performed in nearly all cases using a transperineal cognitive targeted sampling of the mp-MRI lesion +/- systematic transperineal template biopsy [11-14] by a single operator with an experience of >1000 cases.

Analysis of the biopsies was carried out by one of two pathologists with 10 and 20 years of experience. Clinically significant cancer was defined as any cancer with a Gleason score of 3+4 or greater or Gleason 6 with maximum cancer core length of ≥4mm, as previously described [13].

### *Comparison of groups*

Cancer detection and treatment outcomes were compared between men choosing Strategy-One and men choosing Strategy-Two. The Statistical Package for the Social Sciences (SPSS 12.0.0 for windows) was used for all the data analyses. Differences between the median values of the patient groups were tested using the Mann-Whitney's U test (Wilcoxon rank sum test) and for normally distributed data, an unpaired t-test was carried out. A p-value of less than 0.05 was considered to indicate a significant difference.

### *Ethics*

This work has the approval of the Institutional Medical Advisory Committee.

## Results

A total of 178 men had an mp-MRI score of 3/5, but 10 men were excluded due to their choice of completing their treatment elsewhere after the mp-MRI. From the total of 168 patients, 73 (43%) underwent immediate biopsy (Strategy-One) and 95 (57%) choose the more conservative approach of surveillance with PSA and/or interval mp-MRI with biopsy if required (Strategy-Two).

The median age of men at first mp-MRI was 60 years (range, 36-85). Time to follow-up ranged between 0-53 months in men within the surveillance group and 0-44 months in the immediate biopsy group. The median follow-up time was 4 months in the immediate biopsy group and 6 months in the surveillance group. Men who chose immediate biopsy had a mean PSA of 4.9ug/l and a prostate volume of 49ml compared to 5.1ug/l and 46ml respectively among the Strategy-Two counterparts. (Table 1).

In men who chose surveillance (Strategy-Two), just less than half (38/95, 40%) had one additional follow-up mp-MRI. Thirteen men underwent a second follow-up mp-MRI, 5 men a third and 2 men a fourth. The remainder of men (37/95, 39%) continued on PSA surveillance alone.

Ten men (10/95, 11%) who initially chose surveillance underwent biopsy during follow-up as a result of the triggers described above. Five men had progression on follow-up mp-MRI alone, 3 had a rise in PSA level alone and 2 had a combination of rising PSA level and progression on mp-MRI. Median time between the mp-MRI and biopsy in these 10 men was 12 months. The median time to diagnosis of cancer was 20 months in those men who chose initial surveillance compared to 1 month in men who chose immediate biopsy.

The biopsy results of men who chose immediate biopsy (Strategy-One) are shown in Table 2. Thirty-three men (33/73, 45%) were diagnosed with prostate cancer. Nineteen men (19/73, 26%) had clinically significant cancer and 14 men (14/73, 19%) had clinically insignificant cancer. None of the men had a dominant Gleason pattern 4 (>50% Gleason pattern 4) diagnosed and none had a maximum cancer



core length  $\geq 6$ mm. Of the remaining 40 men without cancer, 11 had biopsy tissue showing atrophy, 6 had atypical small acinar proliferation (ASAP), 9 had high-grade prostatic intraepithelial neoplasia (HGPIN) and 14 had acute or chronic inflammation. Figure 1 demonstrates MRI features of an indeterminate 3/5 score with inflammatory prostate tissue.

In men who chose initial surveillance (Strategy-Two), 4 men (4/95, 4%) were diagnosed with clinically significant cancer during follow-up, all with Gleason 3+4 prostate cancer. None of the men had dominant Gleason pattern 4 and none had a cancer core length  $\geq 6$ mm. Of the remaining 6 men who underwent biopsy, none had cancer. One had biopsy tissue showing atrophy, 1 had ASAP and 4 had HGPIN (Table 3).

Four of the 95 men (4%) in the surveillance group (Strategy-Two) had treatment with curative intent. Nine of the 73 men (12%) in the immediate biopsy group (Strategy-One) had treatment with curative intent (Figure 2).

## **Discussion**

### *Principal Findings*

In 168 men referred with clinical suspicion of prostate cancer (raised PSA and/or abnormal digital rectal examination and/or family history of prostate cancer) an indeterminate mp-MRI score resulted in 14% (23/168) of men with clinically significant cancer being identified. Of these 23 men, 19 were diagnosed in the immediate biopsy group (19/73, 26%) and 4 in the surveillance group (4/95, 4%) ( $p < 0.001$ ). No men had primary Gleason pattern 4 cancer or harboured high burden disease (maximum cancer core length  $\geq 6$ mm) nor was extra-prostatic disease detected. This highlights that the majority of men with an indeterminate mp-MRI score do not harbour features of high-risk cancer. Many, however, did have florid non-cancerous changes in their prostates.

When offered a choice of immediate biopsy (Strategy-One) or continued surveillance with PSA and/or interval MRI with delayed biopsy if required (Strategy-Two), the majority of men opted for surveillance and avoided biopsy. The minority of men who

underwent surveillance but required a delayed biopsy (10/95, 11%) were able to defer biopsy for 20 months and were diagnosed with cancers that were not dissimilar to the highest risk cancers in the immediate biopsy group, whilst still remaining eligible for curative treatment.

### *Clinical and research implications*

To our knowledge, this is the largest reported cohort of men exclusively with indeterminate mp-MRIs, in which we introduce alternative management strategies that other clinicians may wish to consider.

The majority of men with a mp-MRI score of 3/5 chose surveillance over immediate biopsy. This highlights that many men are willing to forego biopsy in the face of uncertainty and that surveillance in men with a 3/5 or “indeterminate” score is a feasible strategy choice for patients. This may be related to the invasiveness of the procedure, associated pain and complications and the option of a reasonable alternative. In the era of quinolone-resistant bacteria [15], avoiding biopsy where possible is a priority in the field of prostate cancer diagnosis. This may also reduce the burden of over-diagnosis and over-treatment which is a significant problem in prostate cancer management [16].

A strategy of surveillance avoided a biopsy in the majority of the group (85/95, 89%). Close monitoring allowed the progression of suspicious lesions being detected, determined by MRI or PSA rises, in which case a biopsy would subsequently be required. Those who eventually underwent biopsy, delayed this for 20 months. This is similar to a strategy that many institutions adopt for patients on active surveillance. The advantages also translate to men on active surveillance who could undergo biopsy on basis of one of these triggers rather than at routine time points.

When comparing the cancers detected in men undergoing the two strategies, those cancers identified in men undergoing surveillance and delayed biopsy were not dissimilar to the highest risk cancers in the immediate biopsy group. Delaying biopsy for a median of 20 months from initial MRI in the surveillance group did not render any of the 4 men with cancer ineligible for curative treatment.

The majority of men immediately undergoing biopsy had non-cancerous findings (40/73, 55%) such as atrophy, acute/chronic inflammation, HGPIN or ASAP, which may shed light on common histopathological features of lesions scored 3/5 on mp-MRI. Whether this inflammation is causally related to the cancer or independent needs to be the subject of future research. Correlation of the histopathological results of men with indeterminate MRI lesions is important in this respect.

This data can inform the shared decision-making process for how to manage men with indeterminate MRIs and clinicians may wish to consider these strategies for management of their patients. For an option of surveillance, patients should be made aware that regular PSAs (every 3-6 months) and a repeat MRI after 12 months are recommended in order to identify any progressive disease if present. It should be emphasised that the long-term outcomes of the results of such a strategy are needed before routine recommendations can be made but clinicians and patients should be aware of the possibility of alternative management strategies, which they could benefit from. Early results would suggest that men are not at risk when adopting a surveillance approach at first, since the cancers detected were not dissimilar to the highest risk cancers in the immediate biopsy group.

The conservative strategy has some advantages, namely an average delay in biopsy of 20 months in those who eventually underwent biopsy during follow-up and the avoidance of a biopsy in the majority of the group (85/95, 89%). This is a particularly important advantage for patients and healthcare economics.

Future work should focus on the long-term outcomes of these men and identify methods to cut-across the mid-point to score the MRI as normal (no biopsy required) or abnormal (biopsy required). Biomarkers may play a role [17] as will PSA density [18]. Developments in MRI, particularly in the diffusion [19], are also promising as these should improve both sensitivity and specificity for clinically significant disease.

### *Limitations*

A limitations of this study include its retrospective observational nature, short-term follow-up and small sample size. However, this is a unique 5-year data set in men

with no prior biopsy, reflecting real patient choice and subsequent outcomes for men with an indeterminate MRI. This may therefore offer value to clinicians in managing men referred with clinical suspicion of prostate cancer. Furthermore, given the increasing use of mp-MRI in the diagnosis of prostate cancer, discussion of the surveillance strategy is appropriate now, as it may be immediately beneficial to patients by avoiding the risks, discomfort and complications of biopsy. The long-term outcomes of men treated with this strategy, however, remain to be seen. We acknowledge the verification bias provided by not all men having a regimented universal biopsy regime but these data form the foundation for this strategy to be investigated in an interventional trial design.

We also acknowledge that mp-MRI conduct and reporting is subject to a learning curve [20] and that indeterminate scores may differ from experienced and less experienced radiologists. Other centres should be aware of this prior to considering such a strategy for men with indeterminate MRIs and we would advocate audit and publication of individual centre results to ensure that performance is similar to those published in the literature.

## **Conclusion**

Men with an indeterminate mp-MRI are willing to forego immediate biopsy for a strategy of close surveillance with MRI and regular PSAs. Men undergoing surveillance who ultimately have a biopsy during follow-up due to specific triggers, have cancer similar in risk profile to that identified in men undergoing immediate biopsy, for which they can still be treated with curative intent. This surveillance strategy will result in fewer men needing to undergo biopsy, benefiting both patients and healthcare systems. Long-term results of such a strategy are awaited.

## Figures and Tables

**Table 1. Patient's specifications divided by Strategy**

	<b>MRI Surveillance (n = 95, 57%)</b>	<b>Immediate Biopsy (n = 73, 43%)</b>	<b>p-value</b>
<b>Age, mean (SD), y</b>	60 (9.8)	60 (7.1)	0.811
<b>PSA, median (IQR), ug/l</b>	4.9 (0.2-34)	5.1 (0.7-22)	0.564
<b>Prostate volume, mean (SD), ml</b>	49 (24.3)	46 (21.6)	0.384
<b>Time between MRI and biopsy, median (IQR), m</b>	12 (3-35)	1 (0-6)	<0.001*
<b>Time between MRI and cancer diagnosis, median (IQR), m</b>	20 (3-35)	1 (0-2)	<0.001*
<b>Follow-up time, median (IQR), m</b>	6 (0-44)	4 (0-53)	0.157

PSA: Prostate specific antigen, SD: Standard deviation, \*significant outcome

**Table 2. Biopsy results of men who chose Strategy-One (Immediate biopsy)**

<b>Immediate Biopsy (n = 73)</b>	
Malignant:	
<b>Gleason 3+3 n (%)</b>	21 (29%)
<b>Gleason 3+4 n (%)</b>	12 (16%)
Benign:	
<b>Atrophy n (%)</b>	11 (15%)
<b>Acute (chronic) inflammation n (%)</b>	14 (19%)
<b>ASAP n (%)</b>	6 (8%)
<b>High grade PIN n (%)</b>	9 (12%)
<b>Maximum cancer core length, median (IQR), mm</b>	3.0 (0.5-6.0)
<b>Gleason 4 Pattern, median (IQR), %</b>	20 (10-40)
<b>Clinically significant cancer n (%)</b>	19 (26%)
<b>Treatment n (%)</b>	9 (12%)

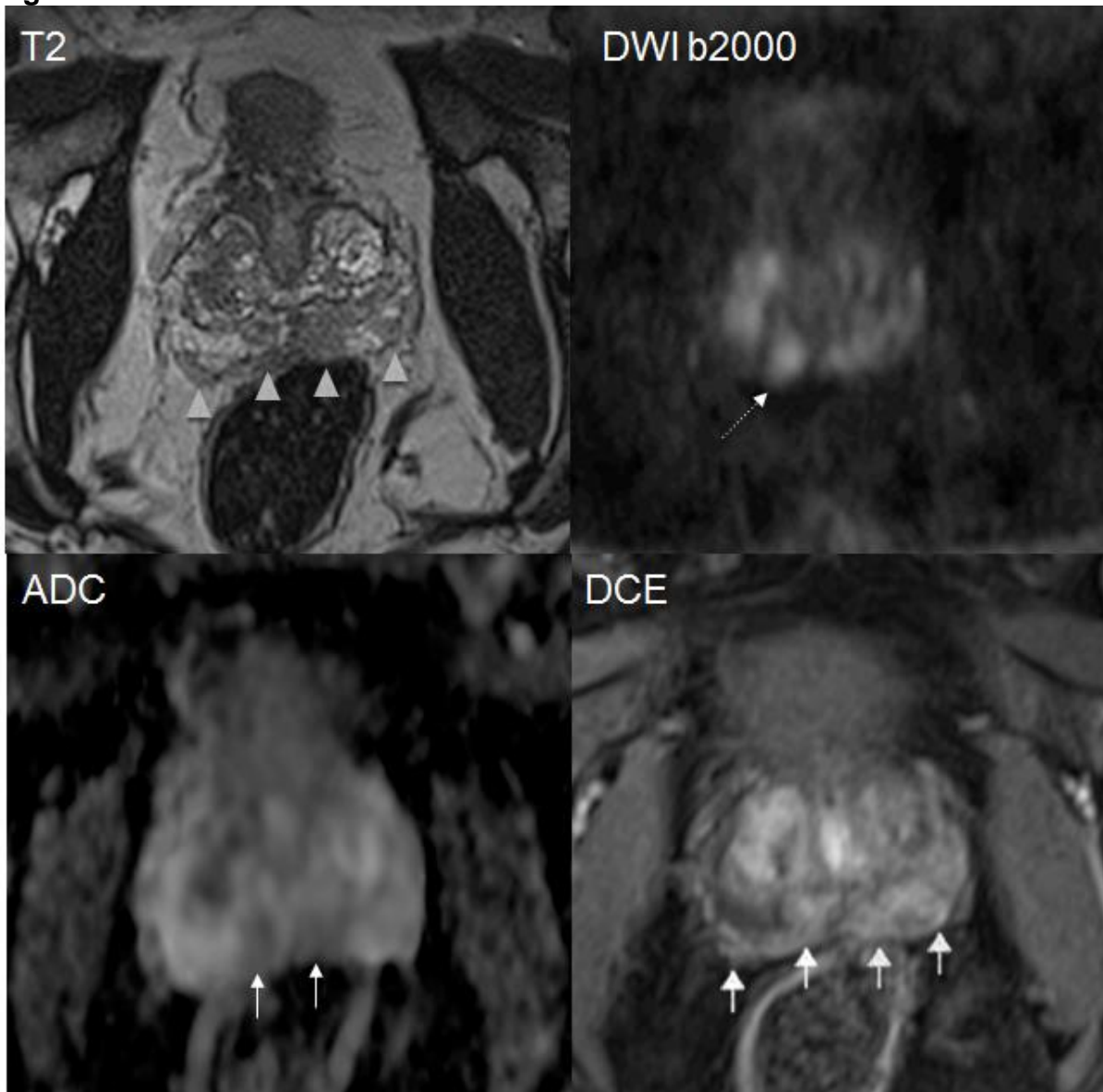
ASAP: Atypical small acinar proliferation, PIN: Prostatic intraepithelial neoplasia, PSA: Prostate specific antigen.

**Table 3. Biopsy results of men undergoing Strategy-Two (initial surveillance)**

<b>Initial surveillance (n = 10)</b>	
Malignant:	
<b>Gleason 3+3 n (%)</b>	0 (0%)
<b>Gleason 3+4 n (%)</b>	4 (40%)
Benign:	
<b>Atrophy n (%)</b>	1 (10%)
<b>Acute (chronic) inflammation n (%)</b>	0 (0%)
<b>ASAP n (%)</b>	1 (10%)
<b>High grade PIN n (%)</b>	4 (40%)
<b>Maximum cancer core length, median (IQR), mm</b>	8.5 (5.0-12.0)
<b>Gleason 4 Pattern, median (IQR), %</b>	20 (10-25)
<b>Clinically significant cancer n (%)</b>	4 (<1%)
<b>Treatment n (%)</b>	4 (<1%)

ASAP: Atypical small acinar proliferation, PIN: Prostatic intraepithelial neoplasia, PSA: Prostate specific antigen.

**Figure 1**



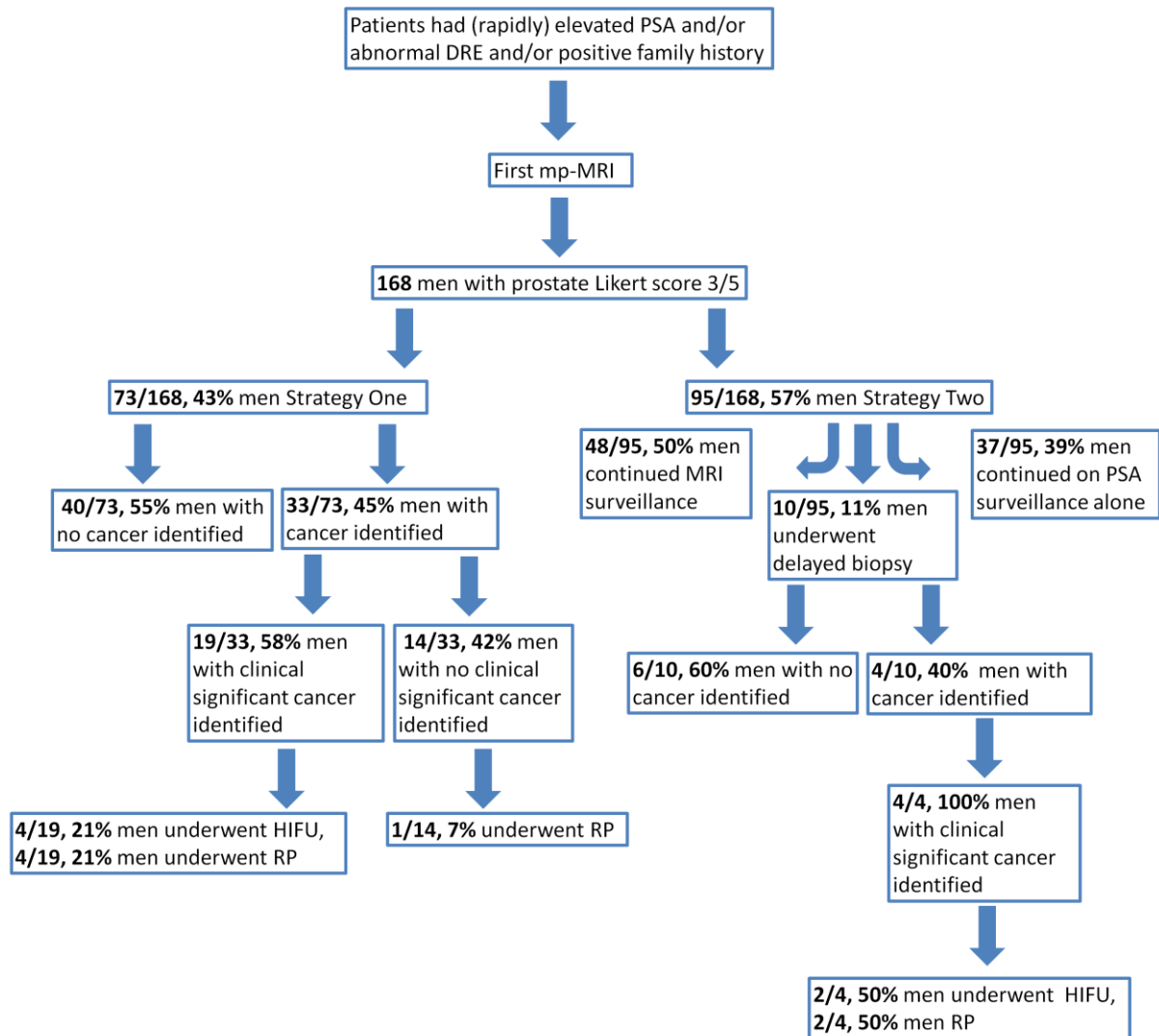
**Figure 1. Illustration of the peripheral zone of a 59 year old patient presenting a PSA of 7.4  $\mu\text{g/L}$  which was scored 3 out of 5 on the multiparametric MRI of the prostate.**

Diffuse low signal is seen in the PZ on **T2 weighted imaging** from 2 to 8 o'clock (arrowheads).

Two focal lesions with reduced ADC are seen on the **ADC map** as shown by the arrows, one of which shows a focus of restricted diffusion (high signal intensity) on **DWI b2000** at 7 o'clock as indicated (dotted-arrow).

On **DCE imaging**, diffuse and almost continuous enhancement is seen bilaterally from 1 to 10 o'clock along with some capsular enhancement. There is an equivocal focus of enhancement corresponding to the lesion with reduced ADC and high signal intensity on b2000 at 7 o'clock (dotted-arrow). This lesion was targeted at biopsy which showed inflammatory tissue.

**Figure 2**



**Figure 2. Flow chart of the outcomes from different strategies in the management of men with indeterminate mp-MRIs.**

This flow chart represents the clinical outcomes and type of treatment from patients who either underwent Strategy-One or Two. Strategy-One was associated with immediate targeted biopsy of the MRI lesion and Strategy-Two was associated with close surveillance comprising PSA monitoring and/or 6-12 month interval mp-MRI with biopsy if required.

DRE: Digital rectal examination, HIFU: High intensity focused ultrasound, PSA: Prostate specific antigen, RP: Radical Prostatectomy.



## **Acknowledgement**

Mark Emberton receives research support from the UK's National Institute of Health Research (NIHR) UCLH/UCL Biomedical Research Centre. He was awarded NIHR Senior Investigator status in 2015

Veeru Kasivisvanathan is funded by a Doctoral Research Fellowship from the National Institute for Health Research. The views expressed in this publication are those of the author(s) and not necessarily those of the NHS, the National Institute for Health Research or the Department of Health

## References

- [1] Fütterer JJ, Briganti A, De Visschere P, Emberton M, Giannarini G, Kirkham A, et al. Can Clinically Significant Prostate Cancer Be Detected with Multiparametric Magnetic Resonance Imaging? A Systematic Review of the Literature. *European Urology*. 2015;1-9.
- [2] Loffroy R, Chevallier O, Moulin M, Favelier S, Genson PY, Pottecher P, et al. Current role of multiparametric magnetic resonance imaging for prostate cancer. *Quant Imaging Med Surg*. 2015;5:754-64.
- [3] Ahmed HU, El-Shater Bosaily A, Brown LC, Gabe R, Kaplan R, Parmar MK, et al. Diagnostic accuracy of multi-parametric MRI and TRUS biopsy in prostate cancer (PROMIS): a paired validating confirmatory study. *Lancet*. 2017.
- [4] Panebianco V, Barchetti F, Sciarra A, Ciardi A, Indino EL, Papalia R, et al. Multiparametric magnetic resonance imaging vs. standard care in men being evaluated for prostate cancer: a randomized study. *Urol Oncol*. 2015;33:17.e1-7.
- [5] Siddiqui MM, Rais-Bahrami S, Turkbey B, George AK, Rothwax J, Shakir N, et al. Comparison of MR/ultrasound fusion-guided biopsy with ultrasound-guided biopsy for the diagnosis of prostate cancer. *JAMA*. United States 2015. p. 390-7.
- [6] Dickinson L, Ahmed HU, Allen C, Barentsz JO, Carey B, Fütterer JJ, et al. Magnetic resonance imaging for the detection, localisation, and characterisation of prostate cancer: Recommendations from a European consensus meeting. *European Urology*. 2011;59:477-94.
- [7] Barentsz JO, Richenberg J Fau - Clements R, Clements R Fau - Choyke P, Choyke P Fau - Verma S, Verma S Fau - Villeirs G, Villeirs G Fau - Rouviere O, et al. ESUR prostate MR guidelines 2012.
- [8] Rosenkrantz AB, Lim RP, Haghighi M, Somberg MB, Babb JS, Taneja SS. Comparison of interreader reproducibility of the prostate imaging reporting and data system and likert scales for evaluation of multiparametric prostate MRI. *AJR Am J Roentgenol*. 2013;201:W612-8.
- [9] Weinreb JC, Barentsz JO, Choyke PL, Cornud F, Haider MA, Macura KJ, et al. PI-RADS Prostate Imaging - Reporting and Data System: 2015, Version 2. *Eur Urol*. 2016;69:16-40.

- [10] Vache T, Bratan F, Mege-Lechevallier F, Roche S, Rabilloud M, Rouviere O. Characterization of prostate lesions as benign or malignant at multiparametric MR imaging: comparison of three scoring systems in patients treated with radical prostatectomy. *Radiology*. 2014;272:446-55.
- [11] Ahmed HU, Cathcart P, Chalasani V, Williams A, McCartan N, Freeman A, et al. Whole-gland salvage high-intensity focused ultrasound therapy for localized prostate cancer recurrence after external beam radiation therapy. *Cancer*. 2012;118:3071-8.
- [12] Crawford ED, Rove KO, Barqawi AB, Maroni PD, Werahera PN, Baer CA, et al. Clinical-pathologic correlation between transperineal mapping biopsies of the prostate and three-dimensional reconstruction of prostatectomy specimens. *Prostate*. 2013;73:778-87.
- [13] Ahmed HU, Hu Y, Carter T, Arumainayagam N, Lecornet E, Freeman A, et al. Characterizing Clinically Significant Prostate Cancer Using Template Prostate Mapping Biopsy. *The Journal of Urology*. 2011;186:458-64.
- [14] Barzell WE, Melamed MR. Appropriate patient selection in the focal treatment of prostate cancer: the role of transperineal 3-dimensional pathologic mapping of the prostate--a 4-year experience. *Urology*. 2007;70:27-35.
- [15] Song W, Choo SH, Sung HH, Han DH, Jeong BC, Seo SI, et al. Incidence and management of extended-spectrum beta-lactamase and quinolone-resistant *Escherichia coli* infections after prostate biopsy. *Urology*. 2014;84:1001-7.
- [16] Rosenkrantz AB, Taneja SS. Prostate MRI can reduce overdiagnosis and overtreatment of prostate cancer. *Acad Radiol*. 2015;22:1000-6.
- [17] Locke JA, Black PC. Next generation biomarkers in prostate cancer. *Front Biosci (Landmark Ed)*. 2016;21:328-42.
- [18] Rais-Bahrami S, Siddiqui MM, Vourganti S, Turkbey B, Rastinehad AR, Stamatakis L, et al. Diagnostic value of biparametric magnetic resonance imaging (MRI) as an adjunct to prostate-specific antigen (PSA)-based detection of prostate cancer in men without prior biopsies. *BJU Int*. 2015;115:381-8.
- [19] Bourne R, Panagiotaki E. Limitations and Prospects for Diffusion-Weighted MRI of the Prostate. *Diagnostics (Basel)*. 2016;6.

[20] Gaziev G, Wadhwa K, Barrett T, Koo BC, Gallagher FA, Serrao E, et al. Defining the learning curve for multiparametric magnetic resonance imaging (MRI) of the prostate using MRI-transrectal ultrasonography (TRUS) fusion-guided transperineal prostate biopsies as a validation tool. *BJU Int.* 2014.