

Residual angle closure one year after laser peripheral iridotomy in primary angle closure suspects

Authors:

Mani Baskaran DO DNB PhD,^{1,2}

Elizabeth Yang BM BCh,^{1,3}

Sameer Trikha BM BSc (Hons) FRCOphth,^{1,4}

Rajesh S Kumar MS,⁵

Hon Tym Wong FRCS(Ed),⁶

Mingguang He MD PhD,⁷

Paul TK Chew FRCS(Ed),⁸

Paul J Foster MD, PhD,⁹

David Friedman MD, MPH,¹⁰

Tin Aung FRCS(Ed), PhD (Lond)^{1,2,8}

1. Singapore Eye Research Institute and Singapore National Eye Center, Singapore.
2. Duke-NUS Medical School, Singapore
3. The Queen's College, Oxford University, UK
4. King's College, London, UK
5. Narayana Nethralaya, Bangalore, India
6. Tan Tock Seng Hospital, Singapore
7. Zhongshan Ophthalmic Centre, Guangzhou, China
8. National University Hospital, Singapore and the Yong Loo Lin School of Medicine, National University of Singapore, Singapore
9. National Biomedical Research Centre for Ophthalmology, UCL Institute of Ophthalmology and Moorfields Eye Hospital, London, United Kingdom
10. Dana Center for Preventive Ophthalmology, Wilmer Eye Institute and Johns Hopkins Bloomberg School of Public Health, Baltimore, Maryland

Address for Correspondence:

Professor Tin Aung

Singapore National Eye Centre

11 Third Hospital Avenue
Singapore 168751
65-62277255 (SNEC Main line)
65-62263395 (SNEC Fax)
e-mail address:
aung.tin@singhealth.com.sg

Abstract: Words - 251

Manuscript: Words – 2444; Figures – 2; Tables – 4; References – 18

Date of Revision: 22nd August 2017

All coauthors have seen and agreed with each of the changes made to this manuscript in the revision and to the way his or her name is listed.

Short Title: Predictors of residual angle closure after laser iridotomy

Abstract

Purpose. To determine the incidence and baseline clinical and anterior segment optical coherence tomography (AS-OCT) predictors associated with residual angle closure as assessed by gonioscopy 1 year after laser peripheral iridotomy (LPI) in primary angle closure suspects (PACS).

Design. Sub-analysis of randomized controlled trial data

Methods. AS-OCT images (Visante, Carl Zeiss Meditec, Dublin, CA) from 181 PACS subjects ≥ 50 years of age, were analyzed using customized software, prior to, and 1 year after LPI. Other parameters assessed were intraocular pressure (IOP) and axial length (Axl). Residual angle closure was defined as the inability to see the posterior trabecular meshwork for at least 2 quadrants on gonioscopy after LPI. Multivariate regression analysis determined the baseline predictors of residual angle closure 1 year after LPI.

Results. The mean age of participants was 62.4 (SD 9.9) years. The majority were female (137, 75.7%) and Chinese 174, 96.1%). At 1 year post LPI, 148 (81.8%) subjects had gonioscopic residual angle closure. Univariate analysis showed that baseline Axl, anterior chamber area, anterior chamber volume, angle opening distance at 750 microns from the scleral spur and angle recess area were smaller while baseline lens vault and iris curvature were larger in residual angle closure subjects (all $p < 0.05$). Multivariate analysis revealed that baseline iris volume ($B = -0.08$, $P = 0.035$) and baseline IOP ($B = 0.23$, $p = 0.032$) were predictors for residual angle closure.

Conclusions. One year after LPI, $>80\%$ of PACS had gonioscopic residual angle closure. Greater baseline iris volume and higher IOP at baseline are independent risk factors for residual gonioscopic angle closure.

Precis: High incidence of residual angle closure was noted at one year post laser iridotomy for primary angle closure suspects in a Singaporean population. Greater baseline iris volume and higher intraocular pressure were found to be risk factors.

The conventional first line treatment for primary angle closure suspects is laser peripheral iridotomy (LPI)^{1, 2} in order to relieve pupillary block.³ LPI widens the anterior chamber angle as evidenced by increase in angle opening distance (AOD), trabecular iris surface area (TISA) and angle recess area (ARA) in patients with angle closure.²⁻⁶ However, in some patients, LPI is unsuccessful in opening the drainage angle, and the persistent angle closure may result in a rise in IOP.^{7, 8} Ramani et al have investigated the risk factors for residual angle closure after LPI in a small sample of PACS subjects using ultrasound biomicroscopy (UBM).⁹ They found that those with residual angle closure after LPI tended to have a narrower angle, thicker peripheral iris, anteriorly positioned ciliary body, and reduced anterior chamber area at baseline. These findings suggest that once pupil block is removed, the anatomy of the iris and ciliary body may play a role in causing residual angle closure after LPI.

The purpose of this study was to determine the incidence and baseline clinical, biometric and anterior segment optical coherence tomography (AS-OCT) parameters associated with gonioscopic residual angle closure 1 year after LPI in a large sample of PACSs.

These data are clinically important as the long term outcome of the angle configuration after LPI has not been well studied. The identification of anatomical factors associated with residual angle closure may also help clinicians understand the underlying mechanism(s) of disease and alter management accordingly.

Methods

This study formed a sub-analysis of an on-going randomized controlled trial (ANALIS, NCT00347178, www.clinicaltrials.gov) involving subjects who were 50 years of age or older with bilateral PACS, who were recruited from glaucoma clinics at 3 Singapore hospitals. Subjects were randomized to undergo LPI in one eye, while the fellow eye was untreated and served as an internal control. Written informed consent was obtained from all participants, and the study had the approval of the hospitals' institutional review boards. The project was conducted in adherence to the tenets of the Declaration of Helsinki.

PACS was defined using the following criteria: the pigmented posterior trabecular meshwork (PTM) was not visible on non-indentation gonioscopy for at least 180 degrees in the primary position, intraocular pressure (IOP) ≤ 21 mm Hg using Goldmann applanation tonometry, with the absence of glaucomatous optic neuropathy, or peripheral anterior synechiae (PAS). Glaucomatous optic neuropathy was defined as the presence of vertical cup: disc ratio (CDR) ≥ 0.7 , disc asymmetry > 0.2 or focal notching (defined as reduction of neuroretinal rim width to less than 0.1 of CDR), coupled with visual field loss compatible with glaucoma. Peripheral anterior synechiae (PAS) were defined as abnormal adhesions of the iris to the angle that were at least half a clock hour in width on indentation gonioscopy, to the level of at least the anterior trabecular meshwork. Exclusion criteria for the study included the following; previous uveitis, ocular neovascularisation, ocular trauma or prior intraocular surgery, report of or evidence of acute primary angle closure episodes, and corneal diseases including corneal scars, dystrophy and extensive guttate changes (with endothelial cell count < 1000 cell/mm²).

All patients underwent standardized ocular slit lamp examination at baseline, including static and dynamic gonioscopy using a Sussman 4-mirror lens in dark room conditions (Ocular instruments Inc., Bellevue, WA, USA). Non-indentation gonioscopy was performed at high magnification (x16) with the eye aligned to the goniolens in the primary gaze position. Care was taken to avoid light falling on the

pupil. Minimal tilt was allowed to examine the angle recess and to exclude “over the hill” phenomenon. Indentation gonioscopy was performed to examine peripheral anterior synechiae. Gonioscopy was performed by two examiners (MB and RSK) during baseline and follow up. Kappa agreement for angle closure in two quadrants was 0.82 on a subset of 40 patients examined by both observers in a masked fashion. Patients also underwent IOP measurement with Goldmann applanation tonometry, and anterior segment imaging by AS-OCT taken under dark room conditions (Visante, Carl Zeiss Meditec, Dublin, CA). Anterior chamber depth, lens thickness and axial length (AxL)_measurements were performed by A-scan ultrasonography (Echo Scan, Nidek Co. Ltd, Gamagori, Japan) by a single observer. All patients were re-examined with repeat gonioscopy and AS-OCT at 1 year post-LPI.

The AS-OCT protocol incorporated 2 images of the anterior chamber angle of each eye, obtained in standardized dark conditions (0 lux) using the single-scan-mode protocol of one image scanning the angle at the 3- and 9-o’clock positions (horizontal meridian) and for 6 and 12 o’clock positions. Images acquired before and 1 year after LPI were obtained using the same AS-OCT device. Rarely, the examiner had to scan slightly away from these positions in order to avoid the areas of PAS. The imaging technician was masked to the clinical findings.

AS-OCT images were analyzed using the Zhongshan Angle Assessment Program (ZAAP, Guangzhou, China). All analyses were performed by a trained grader (EY), and measurements validated by a glaucoma fellowship trained ophthalmologist (MB). Angle measurements such as angle opening distance (AOD750), angle recess area (ARA) and trabecular-iris space area (TISA750) were documented. The mean of the nasal and temporal angles were used in the analysis. Iris parameters such as iris thickness (IT750 and 2000), iris area (IArea) and iris curvature (ICurv) were automatically calculated by the algorithm. IT750 and IT2000 were defined as the iris thickness measured at 750 and 2000 μm from the scleral spur, respectively. Anterior chamber area (ACA), anterior chamber volume (ACV), anterior chamber width (ACW), lens vault (LV), IT, I-area and I-Curv were calculated using specialized software as described previously (**Figure 1**).¹⁰ The iris cross-sectional area was calculated as the cumulative cross-sectional area of the entire (from SS to pupil) length of iris. Iris volume (I-Vol) calculations were based on the principal of centroid theorem. In brief, the centroid and its coordinate were identified as an average of all pixel coordinates within the cross-sectional area by the software. The distance from centroid to the AC axis was defined as the radius, and the I-Vol was then calculated by rotating the iris cross-sectional area along the radius.¹¹

The ACA was defined as the cross-sectional area of the anterior segment bounded by endothelium, anterior surface of iris and anterior surface of lens (within the pupil). A vertical axis through the midpoint of the ACA was plotted by the ZAAP program, and the ACV was calculated by rotating the ACA 360° around this vertical axis. Further, qualitative assessment of angle closure (defined as substantial iris trabecular contact beyond SS) on horizontal and vertical images of AS-OCT (i.e. 4 quadrants) was performed. Irido-trabecular contact beyond scleral spur was considered as angle closure in that quadrant.

The primary outcome measure was gonioscopic residual angle closure which was defined as inability to see the posterior trabecular meshwork for 2 quadrants or more on gonioscopy.

Data were analyzed using Statistical Package for Social Sciences version 11.5 (SPSS Inc, Chicago, Illinois), and statistical significance was assumed at $p < 0.05$ levels. Only the data from eyes that underwent LPI were included for analysis.

Comparison of mean values before and after LPI was assessed using the paired t-test for parametric data. Univariable linear regression analysis adjusted for age and gender were performed for all baseline AS-OCT and A scan parameters. Multivariable linear regression analysis was performed for the predictors of residual gonioscopic angle closure using baseline parameters which showed significance at $p=0.2$ level in univariate analysis, excluding those which showed multi collinearity (based on variation inflation factor ≥ 2.5). Based on this, ACD, ACA, ACV, I-curve, AOD750, TISA750 and ARA were removed from the multivariable model. As secondary analysis, percentage change in TISA 750 at 1 year from baseline was used as a continuous dependent variable for linear regression analysis.

Results

A total of 183 PACS subjects were enrolled in the study and underwent AS-OCT at baseline. Two subjects were lost to follow-up (one due to death and one subject had an uveitis related adverse event). The mean (\pm standard deviation) age of participants in the final analysis ($n=181$) was 62.4 ± 9.9 years. The majority of subjects were of Chinese ethnicity (174, 96.1%) and women (137, 75.7%).

Comparing AS-OCT and A-scan data at baseline and 1 year post LPI (**Table 1**) in all subjects, there were statistically significant differences in AOD-750 (0.39 vs. 0.65mm, $P < 0.001$), TISA-750 (0.28 vs. 0.43mm, $P < 0.001$), ARA (0.17 vs. 0.26 mm², $P < 0.001$), ACA (20.72 vs. 21.90mm², $P < 0.001$) and ACV (91.93 vs. 103.97mm³, $P < 0.001$). AS-OCT showed two quadrants angle closure in 38.1% (64/164 available AS-OCT data) at 1 year follow up compared to 79.8% (146/181) at baseline.

At 1 year post LPI, 148/181 (81.8%) subjects had residual gonioscopic angle closure in 2 or more quadrants closure till PTM (**Figure 1 and 2**). If we use stricter definitions (3 or more quadrants closure till PTM), 126/181 (69.6%) subjects had residual gonioscopic angle closure. Compared to those with open angles, subjects with 2 or more quadrants residual gonioscopic angle closure till PTM at 1 year after LPI had smaller baseline AxI (23.00 vs. 22.56mm, $P=0.03$), ACA (21.96 vs. 20.45 mm², $P=0.03$), ACV (99.84 vs. 91.21 μm^3 , $P=0.023$), AOD750 (0.45 vs. 0.37mm, $P=0.04$) and ARA (0.20 vs. 0.16mm², $P=0.02$). Furthermore, those with residual angle closure had larger baseline LV (882.54 vs. 991.87 μm , $P=0.04$, see **Table 2**). Using multivariable analysis, baseline larger I-Vol ($B=-0.08$, $P=0.04$) and baseline higher IOP ($B=0.23$, $P=0.03$) were risk factors for residual angle closure (**Table 3**).

In a separate analysis assessing change in OCT parameters at one year after LPI, percentage change in TISA750 was associated with baseline LV ($B=0.07$, $P=0.009$, see **Table 4**). The above associations of residual angle closure and percentage change in TISA750 were similar when data for Chinese ethnicity alone were analyzed separately (data not shown).

Discussion

We report a high incidence of residual gonioscopic angle closure (81.8%) one year after LPI in PACSs in a largely Chinese cohort from Singapore. The frequency of residual angle closure as reported by other studies in the literature varies across a fairly wide range, in part due to how angle closure was defined. The population-based Liwan eye study⁷ identified 72 subjects with PAS who underwent LPI, 14 of whom (19.4%) had residual angle closure on gonioscopy (defined as 3 or more quadrants of apposition up to level of the PTM) 2 weeks after LPI. In that same study ultrasound biomicroscopy (UBM) found that 59% (42/72 eyes) of eyes had irido-trabecular

contact in at least 1 quadrant after LPI. In another study from Korea, persistent gonioscopic closure (in the temporal quadrant only) was detected in 23.9% of 46 PACS by gonioscopy, and in 34.8% of eyes by AS-OCT imaging 4 weeks after LPI.¹¹ Interestingly, others have reported a significant decrease in angle opening after LPI between 2 weeks and 18 months.^{12, 13} Factors that may be responsible for a higher incidence noted in our study are longer follow up period, a more lenient definition of angle closure (ATM visibility and 2 quadrant closure), better use of dark room evaluation and variability in defining angle closure (not allowing much tilt of the goniolens in primary gaze).

The mechanism underlying angle closure in an individual (apart from classic pupillary block) appears to in part determine the variation in angle widening after LPI. A large lens, anteriorly rotated ciliary body, or a thick peripheral roll of iris, may be responsible for angle crowding.¹⁴ The association between residual gonioscopic angle closure and I-Vol shown in this study suggest the importance of iris morphology in determining angle configuration, especially after LPI. While iris volume was associated with residual angle closure, it is not clear if this parameter plays a role in the development of PAS or elevated IOP. Lee et al¹² have reported that thinner irides (IT750) were associated with larger angle opening (TISA500/750) after LPI, similar to our study results.

As have others, we found that smaller anterior chamber dimensions at baseline including Ax1, ACA, ACV, AOD 750 and ARA were associated with residual angle closure following LPI on univariate analysis (Figure 2). Several studies have investigated changes in anterior chamber morphology following LPI using AS-OCT or Scheimpflug imaging.^{5-9, 15-18} At 1 week post LPI, ACA and ACV increased, but no changes in ACD, ACW, LV, IT, or I-area were found in a study of the same cohort by How et al.⁵ This increase in ACA/ACV was mainly due to decreased I-curve after LPI. Greater baseline LV, a higher baseline IOP and larger baseline I-Vol were associated with residual angle closure in the multivariable analysis in the present study. The association of percentage change in TISA750 at year 1 with greater LV at baseline may partly explain a situation of increasing residual angle closure at year 1. Larger LV at baseline may predispose angles to progressively narrow with time, due to the growing lens pushing the peripheral iris towards the angle. As mentioned earlier, Lee and Jiang et al demonstrated a peak in angle widening following LPI at 2 weeks in PACS eyes, but a gradual decline in the width of the anterior chamber angle over 18 months.^{12, 13} Jiang et al also found an increase in LV over time, in eyes with and without LPI,¹³ however, we found no such difference in LV from baseline in this cohort.

Our study has limitations. The resolution of the posterior limit of the iris and scleral spur on AS-OCT is suboptimal when compared to ultrasound biomicroscopy (UBM), and this may affect iris and other anterior chamber parameter measurements. Furthermore, only the nasal and temporal angles were used in the quantitative AS-OCT measurements. The gonioscopic examination done by two observers is a source of possible error, but the graders had excellent agreement. The lower incidence of residual angle closure observed in AS-OCT scans compared to clinical gonioscopy after LPI, may be attributed to the cross-sectional nature of AS-OCT, and in some cases, a very convex iris configuration masquerading as narrow angles during gonioscopic examination. Finally, as repeat AS-OCT measurements were only conducted after 1 year, additional time points may have been useful to ascertain fluctuations in AS-OCT parameters in the interim but were not taken.

In summary, we found a high incidence of residual gonioscopic angle closure in PACS eyes at 1 year after LPI. Patients with residual angle closure after LPI tend to have greater baseline lens vault, a higher baseline IOP and larger baseline iris volume. Subtle abnormalities in the lens and iris dimensions can contribute to higher baseline IOP and residual angle closure one year after LPI in PACS eyes. However, further longitudinal studies are needed to determine the threshold levels of such parameters in order to predict individuals progressing to primary angle closure glaucoma.

Acknowledgements

Funding support: This study was conducted through funding support from NMRC/CIRG/1323/2012 and NMRC/STaR/0023/2014, Singapore

Financial Disclosures: No financial disclosures

Other acknowledgements: The authors would like to acknowledge Dr Tin Aung Tun from Singapore Eye Research Institute for his contribution in statistical analysis and imaging done for this study.

References

1. Pandav SS, Kaushik S, Jain R, et al. Laser peripheral iridotomy across the spectrum of primary angle closure. *Can J Ophthalmol* 2007;42(2):233-7.
2. Prum BE, Jr., Herndon LW, Jr., Moroi SE, et al. Primary Angle Closure Preferred Practice Pattern((R)) Guidelines. *Ophthalmology* 2016;123(1):P1-p40.
3. Caronia RM, Liebmann JM, Stegman Z, et al. Increase in iris-lens contact after laser iridotomy for pupillary block angle closure. *Am J Ophthalmol* 1996;122(1):53-7.
4. Saunders DC. Acute closed-angle glaucoma and Nd-YAG laser iridotomy. *Br J Ophthalmol* 1990;74(9):523-5.
5. How AC, Baskaran M, Kumar RS, et al. Changes in anterior segment morphology after laser peripheral iridotomy: an anterior segment optical coherence tomography study. *Ophthalmology* 2012;119(7):1383-7.
6. Ang GS, Wells AP. Factors influencing laser peripheral iridotomy outcomes in white eyes: an anterior segment optical coherence tomography study. *J Glaucoma* 2011;20(9):577-83.
7. He M, Friedman DS, Ge J, et al. Laser peripheral iridotomy in primary angle-closure suspects: biometric and gonioscopic outcomes: the Liwan Eye Study. *Ophthalmology* 2007;114(3):494-500.
8. Nolan WP, Foster PJ, Devereux JG, et al. YAG laser iridotomy treatment for primary angle closure in east Asian eyes. *Br J Ophthalmol* 2000;84(11):1255-9.
9. Ramani KK, Mani B, George RJ, Lingam V. Follow-up of primary angle closure suspects after laser peripheral iridotomy using ultrasound biomicroscopy and A-scan biometry for a period of 2 years. *J Glaucoma* 2009;18(7):521-7.
10. Console JW, Sakata LM, Aung T, et al. Quantitative analysis of anterior segment optical coherence tomography images: the Zhongshan Angle Assessment Program. *Br J Ophthalmol* 2008;92(12):1612-6.
11. Lee KS, Sung KR, Kang SY, et al. Residual anterior chamber angle closure in narrow-angle eyes following laser peripheral iridotomy: anterior segment optical coherence tomography quantitative study. *Jpn J Ophthalmol* 2011;55(3):213-9.
12. Lee KS, Sung KR, Shon K, et al. Longitudinal changes in anterior segment parameters after laser peripheral iridotomy assessed by anterior segment optical coherence tomography. *Invest Ophthalmol Vis Sci* 2013;54(5):3166-70.
13. Jiang Y, Chang DS, Zhu H, et al. Longitudinal changes of angle configuration in primary angle-closure suspects: the Zhongshan Angle-Closure Prevention Trial. *Ophthalmology* 2014;121(9):1699-705.
14. He M, Foster PJ, Johnson GJ, Khaw PT. Angle-closure glaucoma in East Asian and European people. Different diseases? *Eye (Lond)* 2006;20(1):3-12.
15. Acet Y, Yigit FU, Onur IU, et al. The Course of the Changes in Anterior Chamber Parameters After Laser Peripheral Iridotomy: Follow-up for 6 Months With a Scheimpflug-Placido Disc Topographer. *J Glaucoma* 2016;25(1):14-21.
16. Lopez-Caballero C, Puerto-Hernandez B, Munoz-Negrete FJ, et al. Quantitative evaluation of anterior chamber changes after iridotomy using Pentacam anterior segment analyzer. *Eur J Ophthalmol* 2010;20(2):327-32.
17. Talajic JC, Lesk MR, Nantel-Battista M, Harasymowycz PJ. Anterior segment changes after pilocarpine and laser iridotomy for primary angle-closure suspects with Scheimpflug photography. *J Glaucoma* 2013;22(9):776-9.

18. Antoniazzi E, Pezzotta S, Delfino A, Bianchi PE. Anterior chamber measurements taken with Pentacam: an objective tool in laser iridotomy. *Eur J Ophthalmol* 2010;20(3):517-22.

Figure legends

Figure 1: Opening of the anterior chamber angle after laser peripheral iridotomy

Upper left - Angle visualized as closed on examination

Upper right - Iris trabecular contact noted in AS-OCT image (see arrow)

Lower left - Angle visualized as open on examination

Lower right - Iris trabecular contact resolved in AS-OCT image (see arrow)

Figure 2: Residual angle closure 1 year after laser peripheral iridotomy

Upper left - Angle visualized as closed on examination

Upper right - Iris trabecular contact in AS-OCT image (see arrow)

Lower left - Angle visualized as closed on examination

Lower right - Residual iris trabecular contact in AS-OCT image (see arrow)

Figure 1

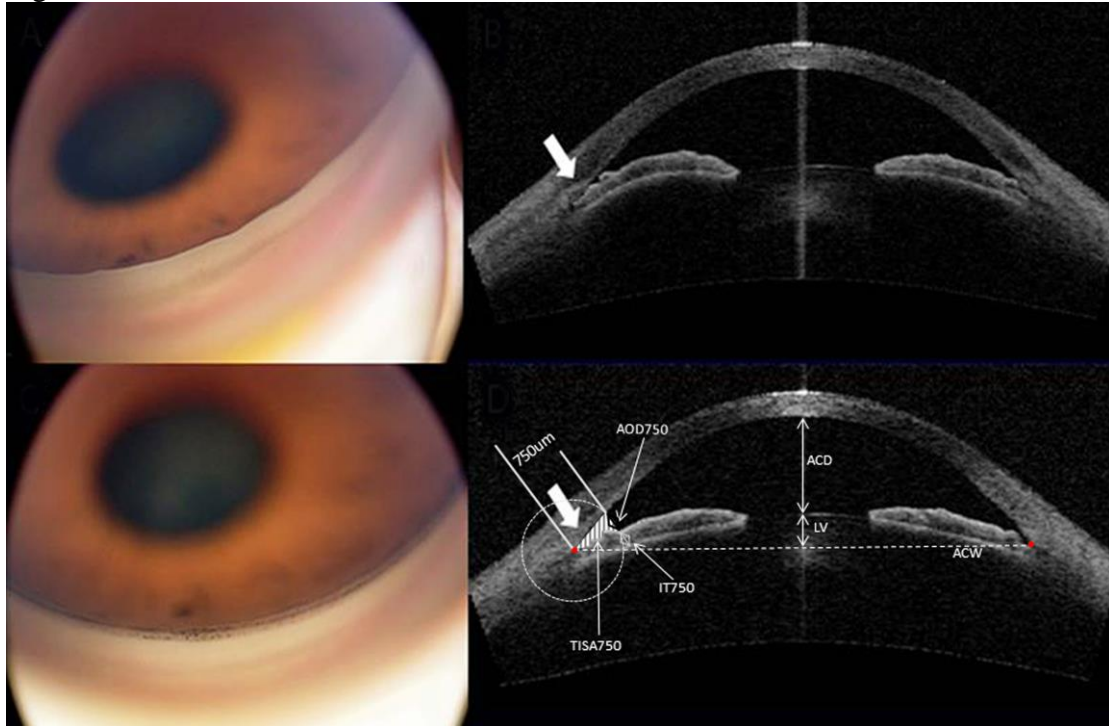


Figure 2

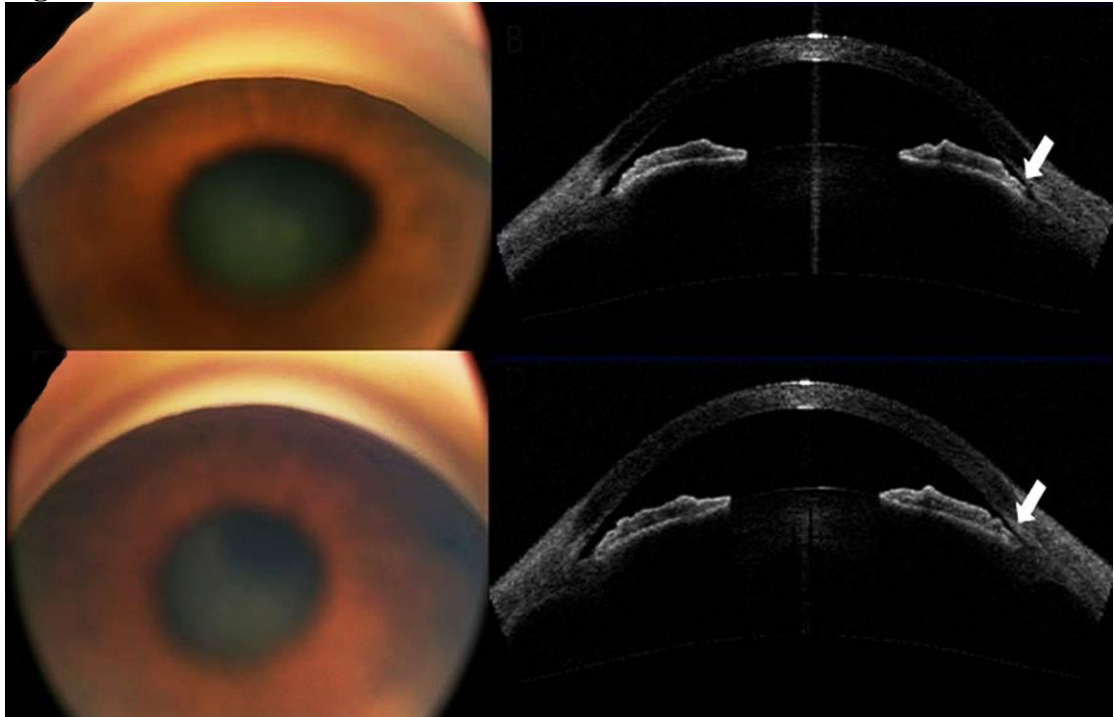


Table 1 Changes in mean anterior segment parameters before and 1 year after laser peripheral iridotomy (n=181)

Parameter	Pre-LPI Mean (SD)	Post-LPI Mean (SD)	<i>P</i> Value
AOD 750 (mm)	0.39 (0.21)	0.65 (0.25)	<0.001
TISA 750 (mm ²)	0.28 (0.13)	0.43 (0.14)	<0.001
IT 2000 (mm)	0.56 (0.11)	0.5 (0.09)	0.041
IT 750	0.56 (0.14)	0.55 (0.12)	0.356
I-area (mm ²)	2.19 (0.34)	2.18 (0.36)	0.854
I-curv (mm)	0.47 (0.14)	0.22 (0.11)	<0.001
I-vol (mm ³)	26.3 (4.97)	25.75 (4.16)	0.089
ARA(mm ²)	0.17 (0.09)	0.26 (0.11)	<0.001
ACD(mm)	2.54 (0.30)	2.53 (0.29)	0.6
ACW (mm)	13.22 (0.43)	13.19 (0.46)	0.274
ACA(mm ²)	20.72 (3.43)	21.9 (3.18)	<0.001
ACV (mm ³)	91.9 (19.40)	104 (18.27)	<0.001
LV (μm)	980.9 (259.4)	970.5 (274.9)	0.29
PCAL (mm)	15.48 (0.57)	15.45 (0.60)	0.429
PD (mm)	4.67 (1.03)	4.37 (1.03)	<0.001

LPI = laser peripheral iridotomy; SD = standard deviation; ACA = anterior chamber area; ACD = anterior chamber depth; ACV = anterior chamber volume; ACW = anterior chamber width; AOD = angle opening distance; ARA = angle recess area; PCAL = posterior corneal arc length; I-area = iris area; I-curv = iris curvature; IT = iris thickness; I-vol = iris volume; LV = lens vault; PD = pupil diameter; TISA = trabecular iris surface area.

Table 2 Comparison of baseline parameters between residual angle closure subjects and subjects with open angles 1 year after laser peripheral iridotomy (Angle closure was defined as two quadrants closure by gonioscopy)

Baseline parameters	Angle opened (n=33) Mean (SD)	Angle closed (n=148) Mean (SD)	P value
Age	62.67 (7.52)	62.35 (10.34)	0.87
CDR	0.45 (0.12)	0.43 (0.13)	0.4
IOP (mmHg)	13.40 (1.86)	14.18 (2.26)	0.07
IOP change after dilation (mmHg)	0.78 (1.73)	1.00 (2.11)	0.57
Axl (mm)	23 (1.05)	22.56 (1.03)	0.03
A-scan ACD (mm)	2.79 (0.39)	2.69 (0.41)	0.2
LT (mm)	4.13 (0.82)	4.16 (0.93)	0.84
AS-OCT ACD (mm)	2.63 (0.36)	2.52 (0.29)	0.07
ACW (mm)	13.27 (0.41)	13.20 (0.43)	0.39
ACA (mm ²)	21.96 (3.90)	20.45 (3.32)	0.03
ACV (μm ³)	99.84 (20.88)	91.21 (18.88)	0.03
LV (μm)	882.5 (266.7)	991.87 (271.7)	0.04
PCAL (mm)	15.51 (0.52)	15.46 (0.58)	0.67
PD (mm)	4.84 (0.98)	4.65 (1.02)	0.33
IT750 (mm)	0.57 (0.12)	0.57 (0.11)	0.9
IT2000 (mm)	0.58 (0.12)	0.56 (0.11)	0.48
I-area (mm ²)	2.17 (0.40)	2.22 (0.33)	0.45
I-curv (mm)	0.43 (0.11)	0.48 (0.15)	0.06
I-vol (mm ³)	28.15 (7.10)	26.31 (4.65)	0.17
AOD750 (mm)	0.45 (0.22)	0.37 (0.21)	0.04
TISA750 (mm)	0.32 (0.12)	0.28 (0.13)	0.09
ARA (mm ²)	0.2 (0.11)	0.16 (0.08)	0.02

SD = standard deviation; ACA = anterior chamber area; ACD = anterior chamber depth; ACV = anterior chamber volume; ACW = anterior chamber width; AOD = angle opening distance; ARA = angle recess area; Axl = Axial length; CDR = cup-disc ratio; IOP = intraocular pressure; PCAL = posterior corneal arc length; I-area = iris area; I-curv = iris curvature; IT = iris thickness; I-vol = iris volume; LV = lens vault; PD = pupil diameter; TISA = trabecular iris surface area.

Significant difference is noted at $P < 0.05$

Table 3 Univariable and multivariable analysis for predictors of residual angle closure at 1 year after laser peripheral iridotomy, using gonioscopy two quadrants closure definition (n=181)

Baseline parameters	Univariable (Age and Gender Adjusted)			Multivariable		
	B (SE)	β	P value	B (SE)	β	P value
CDR	-1.29 (1.50)	0.274	0.39			
IOP (mmHg)	0.17 (0.09)	1.184	0.07	0.23 (0.11)	1.257	0.03
IOP change after dilation (mmHg)	0.05 (0.10)	1.05	0.61			
Axl (mm)	-0.49 (0.20)	0.613	0.01	-0.32 (0.22)	0.723	0.14
A-scanACD (mm)	-0.55 (0.44)	0.577	0.21			
LT (mm)	0.05 (0.21)	1.054	0.80			
AS-OCT ACD (mm)	-1.30 (0.67)	0.274	0.05			
ACW (mm)	-0.46 (0.47)	0.631	0.32			
ACA (mm ²)	-0.15 (0.06)	0.863	0.02			
ACV (μm^3)	-0.02 (0.01)	0.974	0.02			
LV (μm)	0.002 (0.001)	1.002	0.03	0.001 (0.001)	1.001	0.09
PCAL (mm)	-0.18 (0.35)	0.837	0.61			
PD (mm)	-0.20 (0.19)	0.823	0.31			
IT750 (mm)	0.12 (1.39)	1.131	0.93			
IT2000 (mm)	-1.28 (1.65)	0.278	0.44			
I-area (mm ²)	0.44 (0.58)	1.55	0.45			
I-curv (mm)	3.28 (1.59)	26.68	0.04			
I-vol (mm ³)	-0.07 (0.04)	0.934	0.06	-0.08 (0.04)	0.923	0.04
AOD750 (mm)	-1.95 (0.91)	0.143	0.03			
TISA750 (mm)	-2.78 (1.56)	0.062	0.08			
ARA (mm ²)	-5.35 (2.24)	0.005	0.02			

B = unstandardised coefficient; SE = standard error; β = standardised coefficient; ACA = anterior chamber area; ACD = anterior chamber depth; ACV = anterior chamber volume; ACW = anterior chamber width; AOD = angle opening distance; ARA = angle recess area; Axl = Axial length; CCT = central corneal thickness; CDR = cup-disc ratio; IOP = intraocular pressure; PCAL = posterior corneal arc length; I-area = iris area; I-curv = iris curvature; IT = iris thickness; I-vol = iris volume; LV = lens vault; PD = pupil diameter; TISA = trabecular iris surface area.
 $R^2 = 0.17$; Significant difference is noted at $P < 0.05$

Table 4 Multivariable analysis for predictors of residual angle closure at 1 year after laser peripheral iridotomy, with percentage change in Trabecular Iris Space Area 750 as the dependent variable (n=181)

Baseline parameters	Multivariable linear regression		
	B (SE)	β	P value
Age	0.82 (0.61)	0.108	0.18
Sex	-10.06 (15.06)	-0.056	0.51
Race	20.88 (29.38)	0.056	0.48
Axl (mm)	-5.44 (6.71)	-0.077	0.42
LV (μm)	0.07 (0.03)	0.234	0.009
I-vol (mm^3)	0.06 (1.28)	0.004	0.96
IOP (mmHg)	2.62 (2.67)	0.077	0.33

B = unstandardised coefficient; SE = standard error; β = standardised coefficient; Axl = Axial length; IOP = intraocular pressure; I-vol = iris volume; LV = lens vault
 $R^2 = 0.11$; Significant difference is noted at $P < 0.05$