

The Journal of Laryngology & Otology

<http://journals.cambridge.org/JLO>


Additional services for *The Journal of Laryngology & Otology*:

Email alerts: [Click here](#)

Subscriptions: [Click here](#)

Commercial reprints: [Click here](#)

Terms of use : [Click here](#)



Management of thyroglossal tract disease after failed Sistrunk's procedure

N. N. Patel, B. E. J. Hartley and D. J. Howard

The Journal of Laryngology & Otology / Volume 117 / Issue 09 / September 2006, pp 710 - 712
DOI: 10.1258/002221503322334549, Published online: 08 March 2006

Link to this article: http://journals.cambridge.org/abstract_S0022215103001828

How to cite this article:

N. N. Patel, B. E. J. Hartley and D. J. Howard (2006). Management of thyroglossal tract disease after failed Sistrunk's procedure. The Journal of Laryngology & Otology, 117, pp 710-712
doi:10.1258/002221503322334549

Request Permissions : [Click here](#)

Management of thyroglossal tract disease after failed Sistrunk's procedure

N. N. PATEL, F.R.C.S., B. E. J. HARTLEY, F.R.C.S.* , D. J. HOWARD, F.R.C.S.†

Abstract

Sistrunk's procedure for thyroglossal duct remnants has a very high success rate, there remains the occasional patient, however, that will have recurrent disease despite a competently performed operation. Applied anatomy and embryology proffer a solution to this problem. Extending the Sistrunk operation, with an anterior wide local excision remaining within normal tissue, enables removal of the entire thyroglossal tract remnant.

A retrospective case note review was conducted to study our experience using this extended procedure to treat patients with thyroglossal tract disease that had recurred after a previous Sistrunk's operation.

Six patients aged from five to 33 years were included in the study. There was one recurrence and the complication rate was comparable to the standard operation.

It was concluded that a wide local excision is a valuable extension of the Sistrunk operation for the management of recurrent disease.

Key words: Thyroglossal Cyst; Thyroglossal Duct Cyst; Surgical Procedures, Operative

Introduction

The embryological and histological basis of thyroglossal duct disease is well described.^{1,2} Lying in, or adjacent to, the midline, the thyroglossal tract commences at the foramen caecum and passes through the tongue musculature, anterior to the hyoid bone hooking up at its inferior edge, before it descends anterior to the thyroid cartilage and ends at the thyroid isthmus on the trachea. It has been shown to branch like a Christmas tree in its descent (Figure 1).^{1,2}

Early surgery for the condition involved simple local excision. Due to unacceptably high recurrence rates (approximately 50 per cent),³ Schlange in 1893 recommended the removal of the central portion of the hyoid bone, reducing the chance of recurrence to 20 per cent.³ Sistrunk's procedure⁴ first described in 1920, involves two essential elements; (1) excision of a core of tissue from hyoid to foramen caecum with the deliberate aim of staying within normal tissue, (2) removal of a central portion of the hyoid bone.

Recurrence most often results from suprahyoid remnants or inadequate resection of the hyoid itself. When properly performed Sistrunk's procedure may achieve a recurrence rate of three to five per cent.^{4,5}

The technique employed in our unit to manage these unusual but difficult cases, where there has been recurrence even after Sistrunk's procedure is described.

Patients and methods

We reviewed the case notes of patients from 1989 to 1997 that had undergone an extended Sistrunk procedure for recurrence after a previous 'classical' Sistrunk's operation. Details of the patient's previous procedures, complications and follow-up were collected.

Operative procedure

An extended Sistrunk operation involves excision of an approximately 2 cm long core of tissue from below the hyoid to the foramen caecum remaining at all times in normal tissue. *In continuity* excision of the middle third of the hyoid bone is performed where this has not been excised adequately previously. Further anterior *in continuity* excision is carried caudally from the hyoid bone to the thyroid isthmus. The wide local excision includes a central 2–4 cm of strap muscle (proportionally smaller in the child). The extent of the resection compared with more traditional operations is outlined in Figure 2.

Tissue is removed down to the pretracheal fascial plane. Monopolar diathermy and a Colorado needle are particularly useful in the strap muscle cuts. A closed drainage system and a two-layer wound closure was employed.

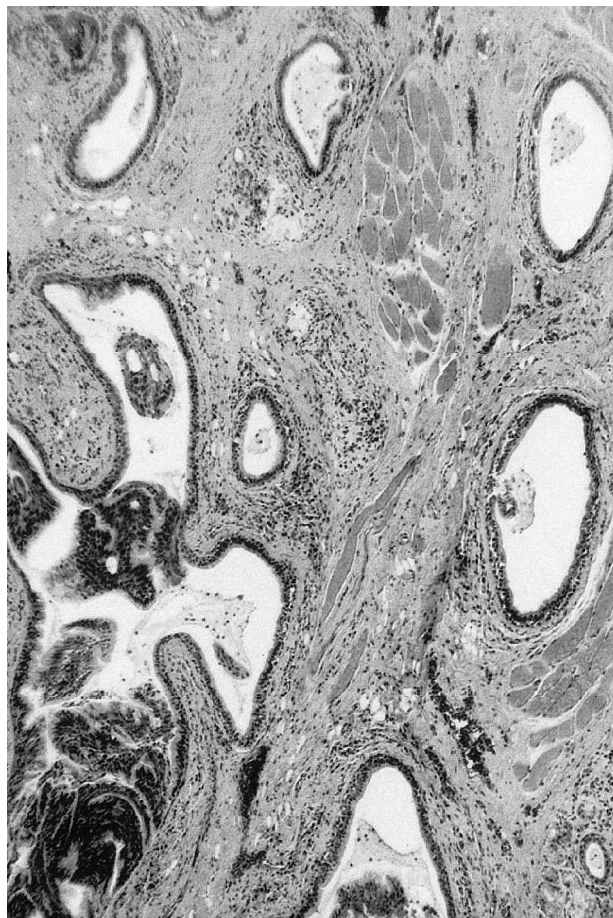


FIG. 1

Arborizing multiple tracts of a thyroglossal remnant specimen (H & E; ×200).

Results

Six patients were included in the study (Table I). Their ages ranged from five to 33 years, there were four male and two female patients. All had undergone a previous 'classical' Sistrunk's procedure that had failed. Five of the patients had had two or more procedures. There was one short-term complication. This was the development of a haematoma, which was drained. The patient subsequently made a complete recovery. Post-operatively the patients were followed up for at least six months (range six to 48 months). There was one recurrence in our series. The patient had a persistent small sinus, but his parents declined further surgery at that stage.

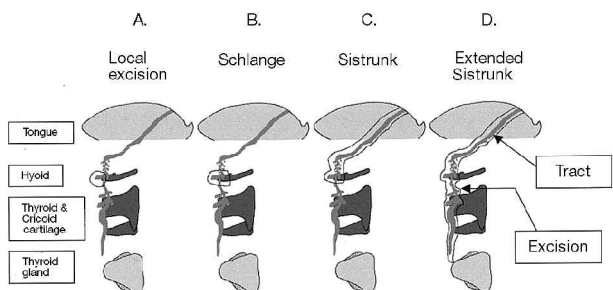


FIG. 2

The evolution of surgery for thyroglossal tract remnants.

TABLE I
PATIENTS UNDERGOING REVISION SURGERY AFTER FAILED 'CLASSICAL' SISTRUNK'S PROCEDURE

Age	Sex	Previous surgery	Complication	Follow up
33	M	3 Excisions 1 Classical Sistrunk	Haematoma Temporary tracheostomy	7 months
7	F	3 Excisions 2 Classical Sistrunk		36 months
5	M	4 Excisions 1 Classical Sistrunk	Recurrence	6 months
6	M	3 Excisions 1 Classical Sistrunk		48 months
21	F	1 Classical Sistrunk		12 months
5	M	1 Excisions 1 Classical Sistrunk		7 months

Discussion

Surgery for thyroglossal tract remnants has seen an evolution based upon basic and clinical scientific investigation, resulting in improved patient outcomes.

Recurrence after Sistrunk's procedure is uncommon. These patients represent a surgical challenge, not least because of scarring from previous infections and surgery. Anatomical, embryological, pathological and clinical studies^{1,2,6,7} bear out the flaws in the 'classical' Sistrunk operation. This procedure does not address two points; (1) thyroglossal tracts have an infrahyoid extension to thyroid isthmus, (2) the 'Christmas tree' branching pattern may continue inferior to the hyoid. The unusual recurrences may, therefore, be due to remnant tissue in the infrahyoid portion of the tract (Figure 3). Extending the operation with a wide local excision to remove a cuff of normal tissue around the arborising tract,

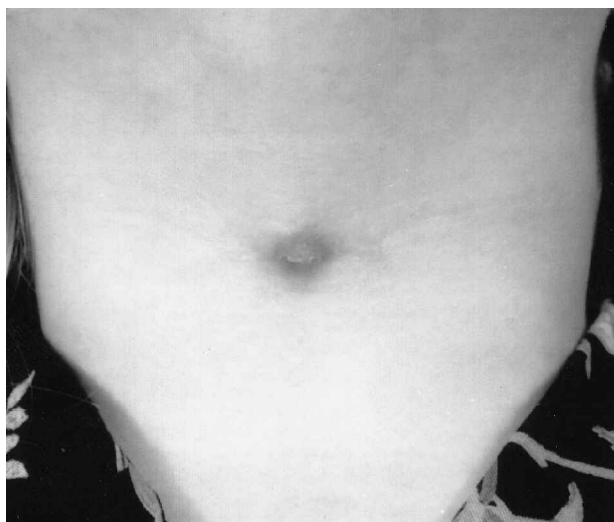


FIG. 3

Child with an infrahyoid thyroglossal fistula.

would seem to address these shortcomings. The evolution of surgery for thyroglossal tract remnants is shown in Figure 2.

- **This is a retrospective review of the outcome of wide surgical excision following a failed Sistrunk's operation for the treatment of thyroglossal duct remnants**
- **The study contains six patients who had recurrence, some of whom had had two or more procedures**
- **Of these cases one had a further recurrence**
- **This extended surgical approach has been previously advocated by others**
- **The present authors discuss this previous literature and the reasons for failure of the classical operation**

Our series of Sistrunk's failures suggests the extended operation is very effective in dealing with recurrence. However the extended operation may have a higher complication rate, due to the greater soft tissue dissection required.

This paper does not claim to be the first description of an extension to the Sistrunk operation. In 1986 the senior author reported his series of thyroglossal tract remnant procedures.² In that paper description was made of extending the 'classical' Sistrunk's operation to include a central portion of the strap muscles. A similar approach had been described in a series of four patients by Mickel and Cacaterra⁸ in 1983 with good results. Unfortunately this method was not widely adopted. In 1999 Kim *et al.*⁷ reported their use of Sistrunk's operation with an en bloc central neck dissection in five Sistrunk's failures, advocating the extended operation only in these circumstances. A recent survey of thyroglossal cyst management questioned the nature of the surgical procedure used by UK paediatric surgeons and ENT surgeons.⁹ This study showed 20 per cent of respondents to be practising simple cyst excision or Schlange's operation, despite the large body of evidence recommending the 'classical' Sistrunk operation as the minimal resection for the disease. None used the Sistrunk's operation with a wide local anterior excision. By reporting our management strategy of this series of unusual Sistrunk's failures, it is hoped that a central wide

local excision might be more widely adopted. Although the individual surgeon needs to determine whether it is justifiable to perform the extended operation in all patients with thyroglossal tract remnants, its use is recommended in the case of recurrent disease.

Conclusion

A well performed 'classical' Sistrunk operation has a success rate of 95–97 per cent, however we believe the extended operation addresses the embryology and histopathology of the disease more fully. Despite being described almost two decades ago, the extended Sistrunk procedure does not appear to be commonly practised. By presenting our experience with the technique in dealing with Sistrunk's failures we hope to promote its wider usage, particularly for this group of patients.

References

- 1 Ellis PDM, van Norstrand AWP. The applied anatomy of thyroglossal tract remnants. *Laryngoscope* 1977;**87**:765–70
- 2 Howard DJ, Lund VJ. Thyroglossal ducts, cysts and sinuses: a recurrent problem. *Ann R Coll Surg Engl* 1986;**68**:137–8
- 3 Pelousa EO, Forte V. Sistrunk revisited: a 10-year review of revision thyroglossal duct surgery at Toronto's Hospital for Sick Children. *J Otolaryngol* 1989;**18**:325–33
- 4 Sistrunk WE. The surgical treatment of cysts of the thyroglossal tract. *Ann Surg* 1920;**71**:121–4
- 5 el-Silimy OE, Bradley PJ. Thyroglossal tract anomalies. *Clin Otolaryngol* 1985;**10**:329–34
- 6 Ducic Y, Chou S, Drkulec J, Ouellette H, Lamothe A. Recurrent thyroglossal duct cysts: a clinical and pathologic analysis. *Int J Pediatr Otorhinolaryngol* 1998;**44**:47–50
- 7 Kim MK, Pawell BR, Isaacson G. Central neck dissection for the treatment of recurrent thyroglossal duct cysts in childhood. *Otolaryngol Head Neck Surg* 1999;**121**:543–7
- 8 Mickel RA, Cacaterra TC. Management of recurrent thyroglossal duct cysts. *Arch Otolaryngol* 1983;**109**:34–6
- 9 Brewis C, Mahadevan M, Bailey CM, Drake DP. Investigation and treatment of thyroglossal cysts in children. *J Roy Soc Med* 2000;**93**:18–21

Address for correspondence:

Mr N. N. Patel,
4a Hubbards Road,
Chorleywood,
Hertfordshire WD3 5JJ,
UK.

E-mail: nnpatel2000@hotmail.com

Mr N. Patel takes responsibility for the integrity of the content of the paper.

Competing interests: None declared
