

JCEM



THE JOURNAL
OF CLINICAL
ENDOCRINOLOGY
& METABOLISM

Nonclassic Lipoid Congenital Adrenal Hyperplasia Masquerading as Familial Glucocorticoid Deficiency

Louise A. Metherell, Danielle Naville, George Halaby, Martine Begeot, Angela Huebner, Gudrun Nürnberg, Peter Nürnberg, Jane Green, Jeremy W. Tomlinson, Nils P. Krone, Lin Lin, Michael Racine, Dan M. Berney, John C. Achermann, Wiebke Arlt and Adrian J. L. Clark

J. Clin. Endocrinol. Metab. 2009 94:3865-3871 originally published online Sep 22, 2009; , doi: 10.1210/jc.2009-0467

To subscribe to *Journal of Clinical Endocrinology & Metabolism* or any of the other journals published by The Endocrine Society please go to: <http://jcem.endojournals.org/subscriptions/>



Nonclassic Lipoid Congenital Adrenal Hyperplasia Masquerading as Familial Glucocorticoid Deficiency

Louise A. Metherell, Danielle Naville, George Halaby, Martine Begeot, Angela Huebner, Gudrun Nürnberg, Peter Nürnberg, Jane Green, Jeremy W. Tomlinson, Nils P. Krone, Lin Lin, Michael Racine, Dan M. Berney, John C. Achermann, Wiebke Arlt, and Adrian J. L. Clark

Centre for Endocrinology (L.A.M., A.J.L.C.), Queen Mary University of London, and The Orchid Tissue Laboratory, Institute of Cancer (D.M.B.), William Harvey Research Institute, Barts and the London School of Medicine, London EC1M 6BQ, United Kingdom; Institut National de la Santé et de la Recherche Médicale, Unité 855 (D.N., M.B.), Lyon F-69008, France; Department of Endocrinology (G.H.), Saint-Joseph University, Beirut, Lebanon; Children's Hospital (A.H.), Technical University Dresden, 01187 Dresden, Germany; Cologne Center for Genomics and Institute for Genetics (P.N., G.N.), University of Cologne, D-50674 Cologne, Germany; Discipline of Genetics (J.G.), Faculty of Medicine, Memorial Hospital, St. John's, NL Germany; Pediatric Endocrinology (M.R.), Helen DeVos Children's Hospital, Grand Rapids, Michigan 49503; Clinical and Molecular Genetics Unit (L.L., J.C.A.), Developmental Endocrinology Research Group, UCL Institute of Child Health, University College London, London WC1E 6BT, United Kingdom; and Centre for Endocrinology, Diabetes, and Metabolism (J.W.T., N.P.K., W.A.), School of Clinical and Experimental Medicine, University of Birmingham, Birmingham B15 2TT, United Kingdom

Context: Familial glucocorticoid deficiency (FGD) is an autosomal recessive disorder resulting from resistance to the action of ACTH on the adrenal cortex. Affected individuals are deficient in cortisol and, if untreated, are likely to succumb to hypoglycemia and/or overwhelming infection. Mutations of the ACTH receptor (*MC2R*) and the melanocortin 2 receptor accessory protein (*MRAP*), FGD types 1 and 2 respectively, account for approximately 45% of cases.

Objective: A locus on chromosome 8 has previously been linked to the disease in three families, but no underlying gene defect has to date been identified.

Design: The study design comprised single-nucleotide polymorphism genotyping and mutation detection.

Setting: The study was conducted at secondary and tertiary referral centers.

Patients: Eighty probands from families referred for investigation of the genetic cause of FGD participated in the study.

Interventions: There were no interventions.

Results: Analysis by single-nucleotide polymorphism array of the genotype of one individual with FGD previously linked to chromosome 8 revealed a large region of homozygosity encompassing the steroidogenic acute regulatory protein gene, *STAR*. We identified homozygous *STAR* mutations in this patient and his affected siblings. Screening of our total FGD patient cohort revealed homozygous *STAR* mutations in a further nine individuals from four other families.

Conclusions: Mutations in *STAR* usually cause lipoid congenital adrenal hyperplasia, a disorder characterized by both gonadal and adrenal steroid deficiency. Our results demonstrate that certain mutations in *STAR* (R192C and the previously reported R188C) can present with a phenotype indistinguishable from that seen in FGD. (*J Clin Endocrinol Metab* 94: 3865–3871, 2009)

Familial glucocorticoid deficiency (FGD), or hereditary unresponsiveness to ACTH (online Mendelian inheritance in man no. 202200), is an autosomal recessive disorder resulting from resistance to the action of ACTH to stimulate glucocorticoid production in the adrenal cortex. Affected individuals are deficient in cortisol and, if untreated, are likely to succumb to hypoglycemia or overwhelming infection in infancy or childhood. Mutations of the ACTH receptor (melanocortin 2 receptor, *MC2R*) (1–3) or the melanocortin 2 receptor accessory protein (*MRAP*) (3, 4) cause FGD types 1 and 2, respectively, and account for approximately 45% of all cases.

In an attempt to identify further genetic loci, we previously conducted a genome-wide linkage study using microsatellite markers. This provided evidence for a further locus on chromosome 8 (8q 12.1 to 8q21.2), in three (of 14) families (5). This locus was 26 Mb in size and contained more than 150 known or predicted genes, none of which were an obvious candidate for FGD. The multipoint limit of detection score in the index family was 3.01, and limit of detection scores of 1.28 and 1.20 were obtained for two other families, but linkage to this locus was excluded in a further five families, indicating that at least two more gene defects were responsible for FGD (5).

We reanalyzed this region by single-nucleotide polymorphism (SNP) genotyping in one of the three original 8q-linked families in the expectation of narrowing the size of the critical region and perhaps enabling a focused sequencing strategy. As we describe, it was the opposite effect of enlarging the critical region that enabled us to identify a strong candidate gene, the steroidogenic acute regulatory protein (StAR). More than 40 mutations in *STAR* have previously been described (6–13), mostly concentrated in the C-terminal half of the protein encoded by exons 5, 6, and 7 and causing lipoid congenital adrenal hyperplasia (LCAH; online Mendelian inheritance in man no. 201701). Patients with this condition usually present within the first few months of life with hyperpigmentation and high ACTH and renin levels coupled with low cortisol and aldosterone levels. In patients with a 46,XY karyotype, the absence of fetal testosterone/dihydrotestosterone production may lead to failure of androgenization and a female phenotype. Affected females undergo a normal puberty but have progressive hypergonadotropic hypogonadism (14, 15).

Examples of partial loss-of-function mutations of *STAR*, with a later onset have also been reported; the first such case described a Korean girl with mild disease who survived until 1 yr of age without hormonal replacement (16). Analysis of *STAR* revealed a splice donor site mutation, which resulted in the inclusion of intron 2 in most RNA transcripts, leading to a frameshift and truncation of

the protein, but the retention of some normally spliced transcript and hence StAR protein presumably allowed the development of a less severe phenotype. In 2006 Baker *et al.* (17) described FGD-like phenotypes in three patients with mutations in adjacent codons V187M, R188C. Structural modeling of these two residues, which are within the cholesterol-binding pocket of StAR, suggested that the R188C mutation would prevent the formation of a salt bridge normally present between residues E169 and R188 but result in a new weaker bond between residues T167 and R188 that may preserve the shape of the binding pocket well enough to transport cholesterol. Functional analysis of both V187M and R188C mutants revealed that they retained greater than 20% cholesterol binding activity (17). This residual activity may be the reason that these patients presented after the age of 2 yr with cortisol deficiency and mild hyperreninemia, thus resembling patients with FGD.

Patients and Methods

Probands from 80 families referred to us with a possible diagnosis of FGD were included in this study and their *STAR* genes sequenced. This cohort included patients from one family previously described by us (family 14 in Ref. 5). Criteria for inclusion in this patient cohort were low or absent cortisol production; high ACTH levels; and no report of severe hyponatremia, hyperreninemia, or aldosterone deficiency. Adrenal autoantibodies were negative, circulating 17α -hydroxyprogesterone and very long-chain fatty acids (in males) were within normal limits, and there was no clinical evidence of alacrima or achalasia or other features suggestive of triple A syndrome. In all cases *MC2R* and *MRAP* mutations had been excluded. This study was approved by the local research ethics committee, and individuals and/or their parents gave written informed consent to participate.

SNP genotype analysis

For the whole-genome scan, the GeneChip mapping 10 K array Xba142 (Affymetrix, Santa Clara, CA) was used in accordance with the manufacturer's guidelines. This version of the Mapping 10 K array comprises a total of 10,024 SNPs with a mean intermarker distance of 258 kb, equivalent to 0.36 cM. SNP genotypes were scanned for regions of homozygosity using IBDfinder from the Centre for Autozygosity (<http://autozygosity.org>).

Genetic analysis

Genomic DNA was extracted from peripheral blood leukocytes, and each exon of *STAR* including intronic boundaries was amplified by PCR using specific primers (supplemental Table S1, published as supplemental data on The Endocrine Society's Journals Online web site at <http://jcem.endojournals.org>). Cycling conditions were 95 C for 5 min (one cycle); 95 C for 30 sec, 55 C for 30 sec, and 72 C for 30 sec (30 cycles); and 72 C for 5 min. PCR products were visualized on 1% agarose gel and sequenced using the ABI Prism Big Dye sequencing kit and an ABI 3700

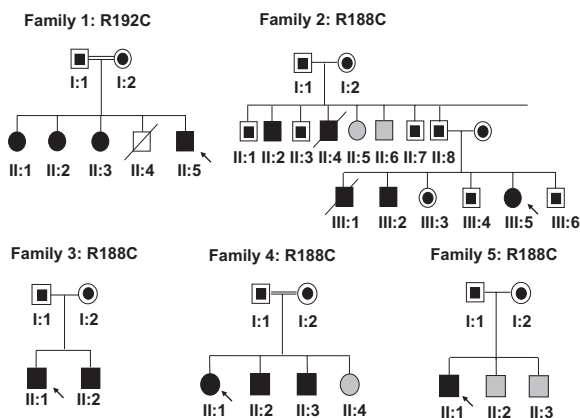


FIG. 1. Pedigrees of families 1–5 with *STAR* mutations. All affected individuals (black symbols) were homozygous for the indicated mutations, unaffected parents and siblings (where characterized) were all heterozygous (half-filled symbols), uncharacterized individuals are represented by gray symbols, and probands are indicated by arrows.

automated DNA sequencer (Applied Biosystems, Foster City, CA), in accordance with the manufacturer’s instructions.

Results

Genotype and sequencing analysis

Whole genome SNP analysis was undertaken on DNA from the proband of family 1 [Fig. 1; individual II:5 (14:3 from Ref. 5)]. Analysis of the genotype for this individual displayed a region of homozygosity on chromosome 8 from SNP rs1405535 to SNP rs372976 (25.1–82.6 Mb). This region encompasses the centromere and part of the short arm of chromosome 8 and is significantly larger than the region of homozygosity previously described (57.2–83.4 Mb) (Fig. 2).

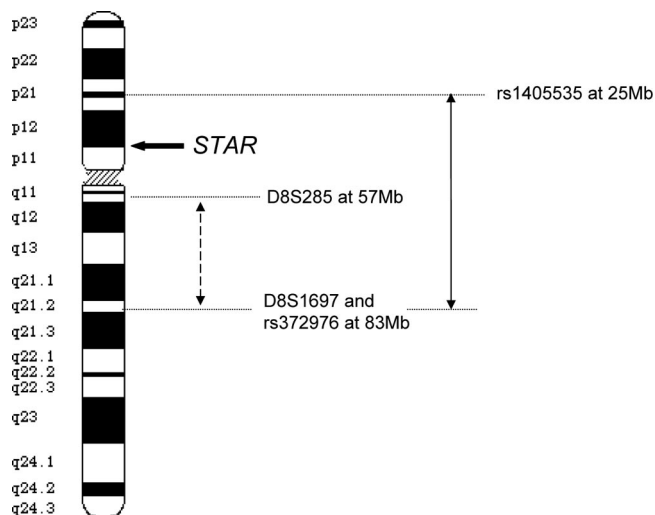


FIG. 2. Ideogram of chromosome 8 indicating the position of *STAR*, the original interval (broken arrow) mapped by microsatellites and limited by markers D8S285 and D8S1697 (57.2–83.4 Mb) and the region mapped by SNPs (solid arrow), extending from SNP rs1405535 to SNP rs372976 (25.1–82.6 Mb).

This revised critical interval extended to include the locus for the *STAR* gene at 38.1 Mb (chromosome 8p12). In view of the key role of StAR in early steroidogenesis, it makes a very plausible candidate gene for FGD, and thus, the gene was sequenced, revealing a novel homozygous mutation R192C in the four affected individuals in family 1 (Fig. 1). Both parents were heterozygous for this mutation.

To ascertain whether there were other *StAR* mutations presenting as FGD, screening of our total FGD patient cohort was undertaken. Sequencing of individuals from a further 79 families revealed the presence of *STAR* mutations as described below (Fig. 1). The parents in these families were heterozygous.

The clinical histories of the affected individuals are as follows.

Family 1

The male proband (II:5) in family I presented at 5 yr of age with pigmentation and episodes of diarrhea and vomiting. His parents are first cousins. In the absence of evidence of mineralocorticoid deficiency, he was treated with hydrocortisone replacement alone (10 mg twice daily) (Table 1). Three older sisters (II:1, II:2, and II:3) were screened and found to be similarly affected and thus also treated with the same dose of glucocorticoid. The proband was reassessed at 25 yr of age, and isolated glucocorticoid deficiency with elevated ACTH was confirmed. At this time testosterone was 550 ng per 100 ml, LH was 6.8 IU/ml, and FSH was 2.2 IU/ml. At age 36 yr, he was investigated for infertility and was found to have a testosterone level of 280 ng per 100 ml, with LH 12 IU/ml and FSH 24 IU/ml. A testicular biopsy at this time revealed partial atrophy, with interstitial fibrosis. Many Reinke crystalloids were seen (Fig. 3), confirming positive identification of Leydig cells. Reinke crystalloids are frequently difficult to see in testicular biopsies, and their prominent presence in this case is therefore interesting and may reflect Leydig cell hyperplasia. The remaining seminiferous tubules showed greatly reduced spermatogenesis, but occasional spermatozoa as well as many spermatocytes were identified. The Sertoli cells were unusual and showed a frequently vacuolated appearance, occasionally forming a signet ring-type appearance. The affected sisters have had an uncomplicated menstrual history (without pregnancies) and two are now postmenopausal at ages 49 and 50 yr, whereas the third is premenopausal at age 46 yr. Genetic analysis revealed a homozygous R192C mutation of *STAR* in all affected individuals.

Family 2

The female proband (III:5) was first seen at the age of 2 yr because of pigmentation and a previous diagnosis in

TABLE 1. Clinical and biochemical characteristics of patients with FGD type 3

| | Family 1 R192C | Family 2 R188C | Family 3 R188C | Family 4 R188C | Family 5 R188C |
|----------------------------------|-------------------|----------------------|----------------------|-------------------|-------------------|
| Individual | II:5 | III:5 | II:1 | II:1 | II:1 |
| Sex | M | F | M | F | M |
| Age at diagnosis (yr) | 5 | 2 | 7 | 1.5 | 3 |
| ACTH (NR 4–22 pmol/liter) | >50 | ND | 327 | 331 | >275 |
| Cortisol (NR >150 nmol/liter) | 17 | Undetectable | 70–140 | <30 | 43 |
| ALDO (NR 111–860 pmol/liter) | 33 | 32 | 108 | ND | 165 |
| PRA (NR 0.76–3.2 nmol/liter · h) | 4.48 | ND | 0.88 | 10 | 2.72 |
| LH (NR 4–12 mIU/ml in male) | 21.9 | ND | ND | ND | 15.7 |
| FSH (NR 4–10 mIU/ml in male) | 50.4 | ND | ND | ND | 9.5 |
| Country of origin | Lebanon | Newfoundland, Canada | Newfoundland, Canada | Jordan | India |

ALDO, Aldosterone; ND; not determined; NR, normal range; PRA, plasma renin activity.

her older brother (III:2) of Addison's disease. Biochemical investigation showed glucocorticoid deficiency without mineralocorticoid deficiency, and replacement with hydrocortisone alone was successful (Table 1). Their parents, from Newfoundland, are unrelated, but both had ancestors from Sheffield, UK. Another brother (III:1), who died at the age of 3 yr, was also suspected to be affected. In the previous generation, one paternal uncle (II:2) was reported to be dark complexioned and another (II:4) died aged 2–3 yr with suspected Addison's disease. The proband remains well and has two children, whereas her older brother (III:2) has one child. Genetic analysis revealed a homozygous R188C mutation of *STAR* in both affected individuals and their uncle (II:2), who has four children and who was both undiagnosed and untreated until he was

58 yr. Family members III:3, III:4, and III:6 and their parents were heterozygous for the mutation.

Family 3

Two brothers (II:1 and II:2), with nonconsanguineous parents, had become pigmented after the second year of life. The male proband (II:1) was well until age 6 yr when he had an episode of diarrhea and vomiting, resulting in coma. A diagnosis of possible Addison's disease was made. Both children were treated with cortisone acetate alone (15 mg/m² · d), did not have salt craving, and had no prior history of adrenal disorders. The endocrine findings were reassessed at age 15 yr (II:1) and 12 yr (II:2) and glucocorticoid deficiency, with cortisol levels of 70 and 140 nmol/liter for individuals II:1 and II:2, respectively, but with normal mineralocorticoid function was confirmed. Both boys underwent normal pubertal development: II:1 began his puberty age 12 yr and at 15 yr he had Tanner V pubic hair and 20 ml testes, and sibling II:2 had Tanner I pubic hair and 6 ml testes bilaterally at 12 yr. Genetic analysis revealed a homozygous R188C mutation of *STAR* in both affected individuals and their parents were heterozygotes.

Family 4

The female proband (II:1) presented at 18 months of age with hyperpigmentation of the lips; two younger male siblings (II:2, II:3) were diagnosed with glucocorticoid deficiency, with low cortisol and high ACTH levels, on screening before 1 yr of age because of prior diagnosis of their sister. Their parents are consanguineous and come from Jordan. All three affected children had high ACTH levels (ranging from 264 to 592 pmol/liter) and low cortisol levels (<30 nmol/liter for all three), with no clinical evidence of mineralocorticoid deficiency and are currently on hydrocortisone replacement (doses 9.3–10.1 mg/m² · d) alone (at ages 13, 11, and 8 yr). Sibling II:2 had bilateral cryptorchidism. Genetic analysis revealed a homozygous R188C mutation of *STAR* in all affected individuals.

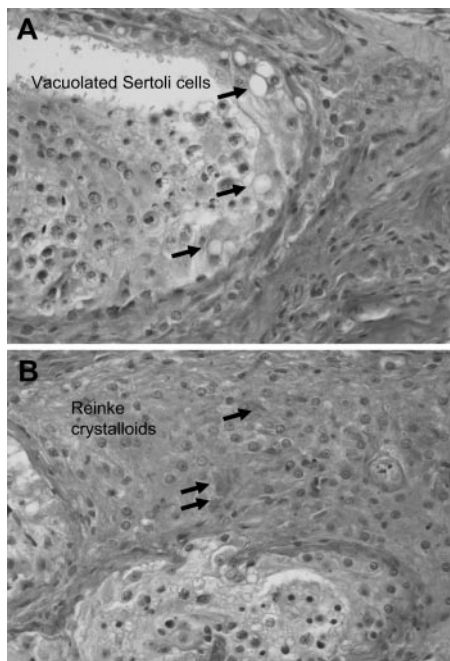


FIG. 3. Testis histology in patient I:5 showing reduced spermatogenesis and vacuolation of Sertoli cells (arrowed) (A) and Leydig cells with many Reinke crystalloids (arrowed) on a background of atrophy (B).

Family 5

The male proband (II:1), the first of three sons of non-consanguineous parents, had been repeatedly unwell from birth and was diagnosed with adrenal insufficiency at age 3 yr. Hyponatremia was documented at presentation; the patient was started on combined hydrocortisone and fludrocortisone replacement, but mineralocorticoid replacement was stopped at age 10 yr without problems. He underwent repair of a glandular hypospadias at age 4 yr. Pubertal development was normal. Endocrine reassessment at 18 yr revealed ACTH greater than 1250 ng/ml and a low baseline cortisol (43 nmol/liter) with inappropriate response to cosyntropin (268 nmol/liter). Plasma renin activity and serum aldosterone were normal. Because of complaints about lack of energy and increasing demands for hydrocortisone, he was initiated on fludrocortisone at age 26 yr, which yielded considerable clinical improvement. Assessment at age 28 yr revealed normal testosterone (11.8 nmol/liter, normal range 7.0–27.0) but up-regulated LH (15.7 IU/liter, normal range 1.7–8.6), indicating compensated hypogonadism. Testicular volume, sperm count, and motility testing results were entirely normal. Computed tomography imaging revealed markedly hypoplastic adrenals with spotty calcifications, suggestive of cirrhotic transformation. Genetic analysis revealed a homozygous R188C mutation of *STAR* in this patient.

Discussion

FGD is a rare autosomal recessive syndrome that represents a relatively pure model of hormone resistance with an absence of associated factors. As such it provides an excellent model for understanding the early molecular events in ACTH action at its primary target site, the adrenal cortex. Thus, the discovery that mutations in *MC2R* were associated with FGD provided strong supporting evidence that this receptor was the primary functional receptor for ACTH (1, 2). The subsequent discovery that mutations in *MRAP* were associated with FGD (4) revealed a fundamental role for this accessory protein in ACTH signaling. Mutations in these genes account for less than half of all cases of FGD, and there appear to be several further loci to be discovered, each of which may reveal important aspects of early ACTH action. There is some evidence of phenotypic variation within this group of FGD patients of unknown cause, exemplified by the recent report of FGD in the Irish Traveler population (18).

A genetic locus for FGD on chromosome 8 was identified several years ago (5), but it was only on reexamination of the data using alternative methodology that it became clear the original critical interval on chromosome 8q had been significantly underestimated. This probably re-

flects a miscalled microsatellite marker (D8S285), a not-unknown difficulty with this technique. Once the size of the true locus was clear, the possibility that *STAR* might be the causative gene seemed highly plausible.

StAR plays a critical early role in adrenal and gonadal steroidogenesis in facilitating the transport of cholesterol across the inner mitochondrial membrane, after which it is further metabolized along the steroidogenic pathways. However, up to 14% of a maximal StAR-induced level of steroidogenesis can persist in the absence of StAR (19). Mutations in *STAR* usually result in LCAH (online Mendelian inheritance in man no. 201701), a severe disorder characterized by both gonadal and adrenal steroid insufficiency. Miller's two-hit model (20) explains the clinical manifestations of LCAH. It suggests that, over time, lipid deposition in steroidogenic cells gradually destroys their function. Hence, the fetal testis is affected early in gestation due to stimulation with chorionic gonadotropin, and the fetal zone of the adrenal gland responsible for dehydroepiandrosterone secretion is similarly affected. Meanwhile, the definitive zone of the fetal adrenal, which develops into the adrenal zonae glomerulosa and fasciculata, is relatively preserved until birth but quickly accumulates cholesterol esters after birth and is destroyed. The fetal and childhood ovary, on the other hand, does not build up lipid deposits until after puberty when LH and FSH stimulate steroidogenesis (14, 15).

Our results highlight the fact that patients with partially inactivating mutations in *STAR* such as R188C and R192C can present a clinical phenotype that is compatible with a diagnosis of FGD. Such cases are more common than previously recognized and account for about 10% of our FGD cohort. The relative preservation of mineralocorticoid production probably reflects the lower production rate of aldosterone compared with cortisol which allows the adrenal zona glomerulosa to escape damage by lipid deposition. Furthermore, gonadal function allowed for normal male and female pubertal development, and interestingly, affected siblings in family 2, brother III:4 his sister III:7 and their affected uncle II:1, all have children. The adult phenotype, however, is indicative of potentially compromised fertility in a number of patients. Although the three affected women in family 1 reported regular menstrual cycles, none of them reported a pregnancy. Their brother, patient II:5, did not discover his gonadal dysfunction and azoospermia until 36 yr of age. A testicular biopsy in this patient shows reduced spermatogenesis and evidence of Leydig cell atrophy but no evidence of lipid deposition in steroidogenic cells. This phenotype is distinct from that reported by Aya *et al.* (21), who described the testicular histopathology in two male patients with LCAH who underwent orchiectomy at ages 7 and 12 yr, revealing

normal numbers of Leydig cells that were filled with lipid droplets. Similarly, the patient II:1 in family 5 had normal appearance of testicular tissue at ultrasound, and he currently has normal fertility potential as documented by sperm count and motility testing. However, endocrine assessment suggests compensated primary hypogonadism, and it is possible that at 10 yr onward, this might progress to manifest hypogonadism and azoospermia. Of note, both his adrenals were hypoplastic with calcifications, resembling a cirrhotic end stage of previous fat deposition, similar to imaging changes observed during progression from steatosis hepatis to liver cirrhosis.

It would be interesting to compare the adrenal histology of these patients in contrast to those with MC2R mutations and MRAP mutations. In the latter cases, there will be no action of ACTH on the zona fasciculata and reticularis cells, resulting in marked atrophy of these zones. In our patients with *STAR* mutations, it is probable that the nonsteroidogenic actions of ACTH will be preserved, at least for the early period of life, and adrenal atrophy may be absent.

In conclusion, it is clear that *STAR* mutations present with a spectrum of phenotypes. At one end of this spectrum is classic lipoid adrenal hyperplasia, seen in the majority of patients with *STAR* mutations, but it extends through a phenotype of adrenal dysfunction presenting like FGD [with or without disordered sex development (DSD)] and can even result in a phenotype that is so mild it remains unrecognized, as exemplified by individual II:2, who remained undiagnosed and untreated until the age of 58 yr. There are some important clinical implications of these findings. First, it is not adequate to make a clinical diagnosis of FGD and then to replace the patient with hydrocortisone with little or no follow-up. Ideally a genetic diagnosis should be made, but when this is not possible or when a genetic defect cannot be identified, the patients should remain under follow-up because their disorder may evolve. Second, we must consider the close connection between gonad and adrenal during human fetal development when investigating individuals with apparently isolated adrenal failure and apparently isolated DSD, respectively, because the obvious manifesting phenotype might not reveal the whole story. Disorders affecting both adrenal and gonadal development may present with isolated adrenal failure, as previously shown for dosage-sensitive sex reversal-adrenal hypoplasia congenita critical region on the X chromosome, gene 1 mutations (22), or with DSD only, as reported for steroidogenic factor 1 mutations (23). The five probands we describe here clearly presented clinically as FGD; however, if the full clinical picture had been taken into account for the proband in family 5, who underwent a hypospadias repair,

and the proband in family 4, whose brother had cryptorchidism, then mutations in *STAR* might have been suspected sooner. In the other three families, no DSD was apparent to raise the suspicion of a defect in *STAR*. In clinical practice it will be important to clearly label these patients as suffering from nonclassic LCAH to ensure that both adrenal and gonadal function is appropriately monitored and progression of phenotypic expression is caught early.

Acknowledgments

We thank Dr Gérard Abadjian, who undertook the original pathology of patient II:5 in family 1.

Address all correspondence and requests for reprints to: Dr. L. A. Metherell, Centre for Endocrinology, First Floor North, John Vane Science Centre, Charterhouse Square, London EC1M 6BQ, United Kingdom. E-mail: l.a.metherell@qmul.ac.uk.

This work was supported by the Wellcome Trust (senior research fellowship to J.C.A. and Research Grant 076430 to A.J.L.C.) and the Medical Research Council United Kingdom (Senior Clinical Fellowship G116/172 to W.A. and New Investigator Research Grant G0801265 to L.A.M.). D.M.B. is supported by The Orchid Appeal, and W.A. and J.C.A. are supported by the European Commission (FP7 EuroDSD Project).

Disclosure Summary: The authors have nothing to disclose.

References

- Clark AJ, McLoughlin L, Grossman A 1993 Familial glucocorticoid deficiency associated with point mutation in the adrenocorticotropic receptor. *Lancet* 341:461–462
- Tsigos C, Arai K, Hung W, Chrousos GP 1993 Hereditary isolated glucocorticoid deficiency is associated with abnormalities of the adrenocorticotropic receptor gene. *J Clin Invest* 92:2458–2461
- Cooray SN, Chan L, Metherell L, Storr H, Clark AJ 2008 Adrenocorticotropic resistance syndromes. *Endocr Dev* 13:99–116
- Metherell LA, Chapple JP, Cooray S, David A, Becker C, Rüschenendorf F, Naville D, Bégeot M, Khoo B, Nürnberg P, Huebner A, Cheetham ME, Clark AJ 2005 Mutations in MRAP, encoding a new interacting partner of the ACTH receptor, cause familial glucocorticoid deficiency type 2. *Nat Genet* 37:166–170
- Génin E, Huebner A, Jaillard C, Faure A, Halaby G, Saka N, Clark AJ, Durand P, Bégeot M, Naville D 2002 Linkage of one gene for familial glucocorticoid deficiency type 2 (FGD2) to chromosome 8q and further evidence of heterogeneity. *Hum Genet* 111:428–434
- Fujieda K, Okuhara K, Abe S, Tajima T, Mukai T, Nakae J 2003 Molecular pathogenesis of lipoid adrenal hyperplasia and adrenal hypoplasia congenita. *J Steroid Biochem Mol Biol* 85:483–489
- Stocco DM 2002 Clinical disorders associated with abnormal cholesterol transport: mutations in the steroidogenic acute regulatory protein. *Mol Cell Endocrinol* 191:19–25
- Bhargoo A, Gu WX, Pavlakis S, Anhalt H, Heier L, Ten S, Jameson JL 2005 Phenotypic features associated with mutations in steroidogenic acute regulatory protein. *J Clin Endocrinol Metab* 90:6303–6309
- Qiu WJ, Ye J, Han B, Han LS, Gu XF 2004 Molecular genetic analysis of congenital lipoid adrenal hyperplasia. *Zhonghua Er Ke Za Zhi* 42:585–588

10. Chen X, Baker BY, Abduljabbar MA, Miller WL 2005 A genetic isolate of congenital lipoid adrenal hyperplasia with atypical clinical findings. *J Clin Endocrinol Metab* 90:835–840
11. Nakae J, Tajima T, Sugawara T, Arakane F, Hanaki K, Hotsubo T, Igarashi N, Igarashi Y, Ishii T, Koda N, Kondo T, Kohno H, Nakagawa Y, Tachibana K, Takeshima Y, Tsubouchi K, Strauss 3rd JF, Fujieda K 1997 Analysis of the steroidogenic acute regulatory protein (StAR) gene in Japanese patients with congenital lipoid adrenal hyperplasia. *Hum Mol Genet* 6:571–576
12. Korsch E, Peter M, Hiort O, Sippell WG, Ure BM, Hauffa BP, Bergmann M 1999 Gonadal histology with testicular carcinoma in situ in a 15-year-old 46,XY female patient with a premature termination in the steroidogenic acute regulatory protein causing congenital lipoid adrenal hyperplasia. *J Clin Endocrinol Metab* 84:1628–1632
13. Flück CE, Maret A, Mallet D, Portrat-Doyen S, Achermann JC, Leheup B, Theintz GE, Mullis PE, Morel Y 2005 A novel mutation L260P of the steroidogenic acute regulatory protein gene in three unrelated patients of Swiss ancestry with congenital lipoid adrenal hyperplasia. *J Clin Endocrinol Metab* 90:5304–5308
14. Bose HS, Pescovitz OH, Miller WL 1997 Spontaneous feminization in a 46,XX female patient with congenital lipoid adrenal hyperplasia due to a homozygous frameshift mutation in the steroidogenic acute regulatory protein. *J Clin Endocrinol Metab* 82:1511–1515
15. Fujieda K, Tajima T, Nakae J, Sageshima S, Tachibana K, Suwa S, Sugawara T, Strauss 3rd JF 1997 Spontaneous puberty in 46,XX subjects with congenital lipoid adrenal hyperplasia. Ovarian steroidogenesis is spared to some extent despite inactivating mutations in the steroidogenic acute regulatory protein (StAR) gene. *J Clin Invest* 99:1265–1271.
16. Okuyama E, Nishi N, Onishi S, Itoh S, Ishii Y, Miyataka H, Fujita K, Ichikawa Y 1997 A novel splicing junction mutation in the gene for the steroidogenic acute regulatory protein causes congenital lipoid adrenal hyperplasia. *J Clin Endocrinol Metab* 82:2337–2342
17. Baker BY, Lin L, Kim CJ, Raza J, Smith CP, Miller WL, Achermann JC 2006 Nonclassic congenital lipoid adrenal hyperplasia: a new disorder of the steroidogenic acute regulatory protein with very late presentation and normal male genitalia. *J Clin Endocrinol Metab* 91:4781–4785
18. O’Riordan SM, Lynch SA, Hindmarsh PC, Chan LF, Clark AJ, Costigan C 2008 A novel variant of familial glucocorticoid deficiency prevalent amongst the Irish traveler population. *J Clin Endocrinol Metab* 93:2896–2899
19. Miller WL, Strauss 3rd JF 1999 Molecular pathology and mechanism of action of the steroidogenic acute regulatory protein, StAR. *J Steroid Biochem Mol Biol* 69:131–141
20. Miller WL 1995 Mitochondrial specificity of the early steps in steroidogenesis. *J Steroid Biochem Mol Biol* 55:607–616
21. Aya M, Ogata T, Sakaguchi A, Sato S, Matsuo N 1997 Testicular histopathology in congenital lipoid adrenal hyperplasia: a light and electron microscopic study. *Horm Res* 47:121–125
22. Lin L, Gu WX, Ozisik G, To WS, Owen CJ, Jameson JL, Achermann JC 2006 Analysis of DAX1 (NR0B1) and steroidogenic factor-1 (NR5A1) in children and adults with primary adrenal failure: ten years’ experience. *J Clin Endocrinol Metab* 91:3048–3054
23. Lin L, Philibert P, Ferraz-de-Souza B, Kelberman D, Homfray T, Albanese A, Molini V, Sebire NJ, Einaudi S, Conway GS, Hughes IA, Jameson JL, Sultan C, Dattani MT, Achermann JC 2007 Heterozygous missense mutations in steroidogenic factor 1 (SF1/Ad4BP, NR5A1) are associated with 46,XY disorders of sex development with normal adrenal function. *J Clin Endocrinol Metab* 92:991–999