

EEG-fMRI mapping of asymmetrical EEG slowing in a patient with refractory epilepsy reveals seizure onset zone concordant with gold standard intracranial EEG

H Laufs¹²³, K Hamandi¹²³, M. Walker¹², C. Scott², S. Smith¹², JS Duncan¹²³, L Lemieux¹³

¹Department of Clinical and Experimental Epilepsy, Institute of Neurology, Queen Square, London, UK, ²National Hospital for Neurology and Neurosurgery, Queen Square, London, UK, ³MRI Unit, National Society for Epilepsy, Chalfont St Peter, Buckinghamshire, UK;

2 figures, 1 table, 1478 words

Address for correspondence:

Helmut Laufs

MRI Unit, NSE

Chalfont St. Peter

Buckinghamshire SL9 0RJ

United Kingdom

Tel: +44 1494 874-646

Fax: +44 1494 875666

Email: helmut@laufs.com

Abstract

Using continuous EEG-correlated fMRI, we studied a patient with refractory epilepsy. Seizures were characterised by head turning to the left and clonic jerking of the left arm suggesting a right mesial frontal onset. Routine interictal EEG showed symmetrical post-central alpha rhythm and occasional runs of independent, non-lateralized slow activity in the delta band with right fronto-central dominance. Ictal scalp EEG had no lateralizing value. Structural MRI showed no abnormality. There were no clear EEG changes during simultaneous EEG-fMRI. We therefore modeled asymmetrical 1-3 Hz EEG slowing near fronto-central electrode positions. Significant Blood Oxygen-Level Dependent (BOLD) signal changes in the right superior frontal gyrus correlated with right frontal oscillations at 1-3 Hz but not at 4-7 Hz and neither of the two frequency bands when derived from contralateral or posterior electrode positions which served as controls. Motor fMRI activations with a finger tapping paradigm were asymmetrical, being anterior for the left hand compared to the right, and near the aforementioned EEG-correlated signal changes. A right fronto-central seizure onset was identified with subdural grid recording, and electrical stimulation of the adjacent contact produced stiffening of the left arm. The fMRI localization of the left hand motor and the detected BOLD activation to modeled slow activity suggest a role for seizure localization with EEG-fMRI even in the absence of clear interictal discharges.

Keywords: EEG, fMRI, intracranial, epilepsy, FFT

Introduction

EEG-fMRI can map interictal EEG activity in focal epilepsy [1, 2, 3, 4, 5]. An important methodological constraint is the dependency on the visualisation of unequivocal interictal epileptic activity during scanning to model the fMRI data [6]: Model-free analysis of fMRI independent of EEG may provide localizing information [7, 8, 9], however, caution against methodological confounds and careful validation with EEG is necessary [6]. In addition, there should be validation against a gold standard, invasive EEG monitoring, and surgical outcome where possible [3].

Here, we show how EEG-fMRI in the absence of clear epileptiform discharges may be helpful in identifying the seizure onset zone [10] as validated by intracranial EEG and supported by task-related fMRI.

Case report

We studied a 40 year old right-handed patient who experienced the first seizure at age 6.

Neurological examination revealed mild pyramidal weakness affecting the left arm. Medication at the time of the investigation consisted of Carbamazepine (1600 mg), Levetiracetam (2000 mg), Phenobarbitone (75mg), Phenytoin (350 mg), Lamotrigine (200mg), and Lorazepam (3mg).

Seizures were predominantly nocturnal beginning with altered facial expression, eye and head deviation to the left accompanied by tonic extension of the left arm and leg, with impaired consciousness and frequent secondary generalization. There had been one episode of left focal motor status epilepticus. Interictal EEG showed symmetrical post-central alpha rhythm and occasional runs of independent, non-lateralized slow activity with right fronto-central dominance. Ictal subdural EEG detected a right fronto-central seizure onset, stimulation at an adjacent contact lead to tonic extension of the left arm. One subdural 48 contact grid and two 8 contact strips were

placed (Figure 1A, 1B). During six days of video-telemetry three stereotyped seizures were captured. Subdural grid recordings identified the seizure onset zone (contact 20) anterior to the left hand motor area as identified by corticography (contacts 30,31, 38, 39, see Figure 1C and Table 1). Three Tesla structural MRI was normal. Resective surgery was not pursued in view of the close proximity of the seizure onset zone to eloquent motor cortex.

The patient gave written informed consent to this study which was approved by the joint ethics committee of the National Hospital for Neurology and Neurosurgery and Institute of Neurology (04/Q0512/77).

Methods

Imaging was performed on a 3T GE Horizon EchoSpeed system using a standard head coil. Two 20 minute eyes-closed rest and one 5 minute finger tap session were acquired with EEG-fMRI (T2*-weighted gradient-echo EPI sequence, TE=40ms; TR=3000ms; interleaved acquisition of 47x5mm slices; Field of View 24x24 cm²; 64x64matrix). The first 4 images/session were discarded to allow for T1-saturation effects. Finger tap was self-paced at around 2 Hz, alternating between left and right in 30-second blocks, modelled using a block design. Subject motion was modelled as confound using the rigid body motion parameters obtained during the realignment procedure [11, 12]. All fMRI data were pre-processed and analyzed using SPM2 (Statistical Parametric Mapping) (<http://www.fil.ion.ucl.ac.uk/spm/>). Structural imaging comprised coronal volumetric T1-weighted Inversion Recovery-prepared Spoiled Gradient Recalled (IR-SPGR), oblique coronal dual-echo proton density, T2-weighted, and oblique coronal fast fluid-attenuated inversion recovery (Fast-FLAIR) sequences. BOLD images were realigned, normalised (along with the T1 structural scan, based on the MNI template brain) and

spatially smoothed with a Gaussian Kernel of 8 mm full width at half maximum.

Using MR-compatible equipment, ten EEG channels (gold disk electrodes with 10 kOhm safety resistors) were recorded at electrode positions Fp2/Fp1, F8/F7, T4/T3, T6/T7, O2/O1, Fz (ground) and Pz as the reference (10-20 system), and bipolar ECG. In-house EEG recording equipment with a 5kHz sampling rate, 33.3 mV range at 2 μ V resolution was used, with online pulse and imaging artefact subtraction [13, 14, 15, 16, 17]. Further offline imaging and pulse artifact removal was performed using the Brain Vision Analyzer [18]. Remaining gross artifacts (motion, electrode contact) were marked semi-automatically. For each session, the EEG was segmented into 1 s epochs (50% overlap), and FFTs (10% hanning window, power) were performed interpolating at the artifact-marked epochs. For each of the bipolar channels F8-T4, F7-T3, T6-O2, T5-O1 one 1-3 Hz and one 4-7 Hz regressor was derived, convolved with the canonical haemodynamic response function and entered into a single general linear model alongside motion confounds (see above). F8-T4/F7-T3 and 1-3 Hz were picked as the band and channels of interest based on the routine EEG findings while the contralateral and posterior electrode positions served as controls. Similarly, another slow frequency band, 4-7 Hz, below background EEG activity was chosen to facilitate testing for band-specificity of the presumed 1-3 Hz asymmetrical slowing. An F-contrast was used to test for BOLD signal changes related to differences in 1-3 Hz power changes occurring in F8-T4 vs. F7/T3, but not at other electrode positions or at 4-7 Hz. fMRI activations were compared with ictal onset and corticography from the subdural grid recordings undertaken during presurgical workup.

Results

Left hand motor mapping by fMRI lead to a contralateral BOLD activation which was lateral and

anterior compared to the assumed normal functional anatomy as demonstrated for the right hand in the left precentral gyrus (Figure 1B). No coregistration of CT, MRI and the grid position was possible. Thus carefully stated, the right-sided fMRI motor activation lay at least in very close proximity to the corticographically identified hand area (Figure 1B, 1C). Slightly anterior and lateral to this, stimulation at contact 11 led to tonic posturing of the left arm. Neighbouring this electrode was contact 20, which was active at seizure onset (Figure 1C, Table 1, Figure 2).

Modelling 1-3 Hz EEG oscillations in right anterior temporal electrodes versus left revealed BOLD signal changes in the supramarginal gyrus (Figure 1B), anterior and medial to the motor hand area and medial to the seizure onset zone detected by intracranial EEG (Figure 1C). BOLD activations were specific for electrode position and frequency band.

Discussion

We used motor fMRI and EEG-fMRI to investigate a patient with refractory frontal lobe seizures. The absence of clear interictal discharges on scalp EEG recorded during fMRI lead us to develop a strategy for analysis of fMRI based on localised EEG frequency changes, in addition to a close inspection of motor fMRI employing a paradigm (finger tap) that was expected to activate cortex adjacent to the seizure onset zone.

Localized slowing in focal epilepsy is a lateralizing, and sometimes localizing, sign in temporal [19, 20] and extratemporal lobe epilepsy [21, 22]. The value of slow activity for localization in patients without lateralizing spikes has been demonstrated [23, 24]. In addition, cortical ictal and postictal EEG slowing has been proposed to signify physiologic impairment contributing to altered cerebral function [25]. This last aspect highlights another role of specific EEG frequency

bands as reflections of cognitive processes which when modeled in fMRI studies only indirectly reflect the neural sources of the observed EEG phenomena [18, 26, 27, 28].

Although no structural cortical lesion could be identified on MRI, motor cortex asymmetry with relative antero-lateral displacement of the left hand area compared to the right may suggest an underlying abnormality linked to the seizure onset zone. Previously, motor mapping and EEG-fMRI in a patient with grey matter heterotopia visible on structural MRI and close to the sensorimotor area found activations linked to interictal discharges in close proximity to the lesion, with displaced fMRI motor activation [29].

We demonstrate that in the absence of interictal epileptic discharges which are normally used to model fMRI data, automated EEG frequency analyses in EEG-fMRI may prove useful in mapping epileptogenic areas. As for any clinical work-up, information available from other investigations should be taken into account when designing and interpreting studies of individual patients.

Acknowledgements

HL is funded by the Deutsche Forschungsgemeinschaft (LA 1452/3-1), KH and LL by the Wellcome Trust (ref. # 067176). The National Society for Epilepsy supports the MRI Unit and JSD. Thanks to M. Symms, P. Bartlett and J. Burdett for programming and running of the MR scanner and to D. Carmichael for help with preparation of Figure 1. Finally, we thank our patient for participating in this study.

References

- [1] Warach, S., J. R. Ives, G. Schlaug, M. R. Patel, D. G. Darby, V. Thangaraj, R. R. Edelman and D. L. Schomer (1996). "EEG-triggered echo-planar functional MRI in epilepsy." *Neurology* 47(1): 89-93.
- [2] Krakow, K., F. G. Woermann, M. R. Symms, P. J. Allen, L. Lemieux, G. J. Barker, J. S. Duncan and D. R. Fish (1999). "EEG-triggered functional MRI of interictal epileptiform activity in patients with partial seizures." *Brain* 122 (Pt 9): 1679-88.
- [3] Al-Asmi, A., C. G. Benar, D. W. Gross, Y. A. Khani, F. Andermann, B. Pike, F. Dubeau and J. Gotman (2003). "fMRI activation in continuous and spike-triggered EEG-fMRI studies of epileptic spikes." *Epilepsia* 44(10): 1328-39.
- [4] Gotman, J., C. G. Benar and F. Dubeau (2004). "Combining EEG and FMRI in epilepsy: methodological challenges and clinical results." *J Clin Neurophysiol* 21(4): 229-40.
- [5] Hamandi, K., A. Salek-Haddadi, D. R. Fish and L. Lemieux (2004). "EEG/Functional MRI in Epilepsy: The Queen Square Experience." *J Clin Neurophysiol* 21(4): 241-248.
- [6] Hamandi, K., A. Salek Haddadi, A. Liston, H. Laufs, D. R. Fish and L. Lemieux (2005). "fMRI temporal clustering analysis in patients with frequent interictal epileptiform discharges: comparison with EEG-driven analysis." *Neuroimage* 26(1): 309-16.
- [7] Morgan, V. L., R. R. Price, A. Arain, P. Modur and B. Abou-Khalil (2004). "Resting functional MRI with temporal clustering analysis for localization of epileptic activity without EEG." *Neuroimage* 21(1): 473-81.
- [8] Ricci, G. B., D. De Carli, C. Colonnese, G. Di Gennaro, P. P. Quarato, G. Cantore, V. Esposito, G. Garreffa and B. Maraviglia (2004). "Hemodynamic response (BOLD/fMRI) in focal epilepsy with reference to benzodiazepine effect." *Magn Reson Imaging* 22(10): 1487-92.

- [9] Federico, P., D. F. Abbott, R. S. Briellmann, A. S. Harvey and G. D. Jackson (2005). "Functional MRI of the pre-ictal state." *Brain* 128(Pt 8): 1811-7.
- [10] Rosenow, F. and H. Luders (2001). "Presurgical evaluation of epilepsy." *Brain* 124(Pt 9): 1683-700.
- [11] Lund, T. E., M. D. Norgaard, E. Rostrup, J. B. Rowe and O. B. Paulson (2005). "Motion or activity: their role in intra- and inter-subject variation in fMRI." *Neuroimage* 26(3): 960-4.
- [12] Friston, K. J., S. Williams, R. Howard, R. S. Frackowiak and R. Turner (1996). "Movement-related effects in fMRI time-series." *Magn Reson Med* 35(3): 346-55.
- [13] Lemieux, L., P. J. Allen, F. Franconi, M. R. Symms and D. R. Fish (1997). "Recording of EEG during fMRI experiments: patient safety." *Magn Reson Med* 38(6): 943-52.
- [14] Allen, P. J., G. Polizzi, K. Krakow, D. R. Fish and L. Lemieux (1998). "Identification of EEG events in the MR scanner: the problem of pulse artifact and a method for its subtraction." *Neuroimage* 8(3): 229-39.
- [15] Allen, P. J., O. Josephs and R. Turner (2000). "A method for removing imaging artifact from continuous EEG recorded during functional MRI." *Neuroimage* 12(2): 230-9.
- [16] Krakow, K., P. J. Allen, L. Lemieux, M. R. Symms and D. R. Fish (2000). "Methodology: EEG-correlated fMRI." *Adv Neurol* 83: 187-201.
- [17] Lemieux, L., A. Salek-Haddadi, O. Josephs, P. Allen, N. Toms, C. Scott, K. Krakow, R. Turner and D. R. Fish (2001). "Event-related fMRI with simultaneous and continuous EEG: description of the method and initial case report." *Neuroimage* 14(3): 780-7.
- [18] Laufs, H., A. Kleinschmidt, A. Beyerle, E. Eger, A. Salek-Haddadi, C. Preibisch and K. Krakow (2003). "EEG-correlated fMRI of human alpha activity." *Neuroimage* 19(4): 1463-76.

- [19] Gambardella, A., J. Gotman, F. Cendes and F. Andermann (1995). "Focal intermittent delta activity in patients with mesiotemporal atrophy: a reliable marker of the epileptogenic focus." *Epilepsia* 36(2): 122-9.
- [20] Koutroumanidis, M., C. D. Binnie, R. D. Elwes, C. E. Polkey, P. Seed, G. Alarcon, T. Cox, S. Barrington, P. Marsden, M. N. Maisey and C. P. Panayiotopoulos (1998). "Interictal regional slow activity in temporal lobe epilepsy correlates with lateral temporal hypometabolism as imaged with 18FDG PET: neurophysiological and metabolic implications." *J Neurol Neurosurg Psychiatry* 65(2): 170-6.
- [21] Geyer, J. D., E. Bilir, R. E. Faught, R. Kuzniecky and F. Gilliam (1999). "Significance of interictal temporal lobe delta activity for localization of the primary epileptogenic region." *Neurology* 52(1): 202-5.
- [22] Koutroumanidis, M., C. Martin-Miguel, M. J. Hennessy, C. D. Binnie, R. D. Elwes and C. E. Polkey (1999). "Significance of interictal temporal lobe delta activity for localization of the primary epileptogenic region." *Neurology* 53(8): 1892.
- [23] Gallen, C. C., E. Tecoma, V. Iragui, D. F. Sobel, B. J. Schwartz and F. E. Bloom (1997). "Magnetic source imaging of abnormal low-frequency magnetic activity in presurgical evaluations of epilepsy." *Epilepsia* 38(4): 452-60.
- [24] Koutroumanidis, M., C. Martin-Miguel, M. J. Hennessy, N. Akanuma, A. Valentin, G. Alarcon, J. M. Jarosz and C. E. Polkey (2004). "Interictal temporal delta activity in temporal lobe epilepsy: correlations with pathology and outcome." *Epilepsia* 45(11): 1351-67.
- [25] Blumenfeld, H., M. Rivera, K. A. McNally, K. Davis, D. D. Spencer and S. S. Spencer (2004). "Ictal neocortical slowing in temporal lobe epilepsy." *Neurology* 63(6): 1015-21.

- [26] Laufs, H., K. Krakow, P. Sterzer, E. Eger, A. Beyerle, A. Salek-Haddadi and A. Kleinschmidt (2003). "Electroencephalographic signatures of attentional and cognitive default modes in spontaneous brain activity fluctuations at rest." *Proc Natl Acad Sci U S A* 100(19): 11053-8.
- [27] Laufs, H., U. Lengler, K. Hamandi, A. Kleinschmidt and K. Krakow (2005). "Linking generalized spike and wave discharges and resting state brain activity using EEG/fMRI in a patient with absence seizures." *Epilepsia* in press.
- [28] Kobayashi, E., A. P. Bagshaw, C. Grova, F. Dubeau and J. Gotman (2005). "Negative BOLD responses to epileptic spikes." *Hum Brain Mapp.*
- [29] Diehl, B., A. Salek-Haddadi, D. R. Fish and L. Lemieux (2003). "Mapping of spikes, slow waves, and motor tasks in a patient with malformation of cortical development using simultaneous EEG and fMRI." *Magn Reson Imaging* 21(10): 1167-73.

Table 1

Summary of electrocorticography and ictal EEG features (compare Figure 1C). Electrical stimulation was performed with 0.5 ms 1-3 mA bipolar stimuli at 50 Hz.

Grid contact number(s)	Clinical / EEG features
7, 8	no response (1-3 mA)
15, 16	no response (3 mA)
23, 24	no response (3 mA)
31, 32	slight sensation in left hand (3 mA) stronger sensation in left hand (3.5 mA)
39, 40	“weird feeling” in left hand (3.5 mA)
47, 48	strong discomfort in head (3.5 mA)
46, 47	strong discomfort in head (3 mA)
38, 39	motor response in left hand (3 mA)
30, 31	twitch in left index finger (2.5 mA)
22, 23	after discharges (twitch in left index finger)
20	<i>fast activity at seizure onset</i>
8, 12	<i>spread of fast activity following contact 20</i>
8, 11, 12	<i>low amplitude fast after seizure onset</i>

Figure 1

Position of the subdural grid and strips (A), their approximate relation to fMRI motor mapping and EEG/fMRI activations in response to right fronto-central 1-3 Hz slow activity (B), and electrocorticography results (C). A) Sagittal Computed Tomography (CT) localizer showing the position of the 48 contact subdural grid over the right anterior frontal lobe and one 8 contact subdural strip overlapping the grid and extending posteriorly. Another 8 contact strip was placed extending medially from contact 34 of the grid (compare C) into the interhemispheric fissure. The insert shows a CT slice reflecting the position of the grid in the axial plane. **B)** Overlay of fMRI activations onto a surface rendering of a template brain in normalized space, all corrected for multiple comparisons (family wise error, $P < 0.05$, extent threshold 30 voxels). Right finger tap fMRI activation is shown in blue (coordinates in Talairach space, maximum at $[XYZ] = [-25, -18, 61]$, left precentral gyrus), left tapping in green ($[40, -5, 63]$, right precentral gyrus and superior frontal gyrus). Indicated in red ($[26, 7, 65]$, right superior frontal gyrus) are fMRI signal changes in response to the difference of 1-3 Hz EEG activity recorded at F8-T4 versus F7-T3, masked by signal changes occurring in response to 1-3 Hz EEG slowing at contralateral and posterior electrode positions (T6-O2, T5-O1) and to 4-7 Hz oscillations recorded at F8-T4, F7-T3, T6-O2 and T5-O1. Dashed and dotted lines indicate positions of the subdural grid and strips, respectively. **C)** Schematic of 48 contact subdural grid with colour-coded electrocorticography results (see Table for details). Dark green indicates a motor response from the left hand, lighter green implies the border between motor and somatosensory cortex. Stimulation at contact 11 (green circle) provoked stiffening of the left arm. Pink indicates contacts at which seizure onset or early spreading was seen (compare Figure 2), and red circles mark contacts which by estimation overly the area of EEG-fMRI activation (compare B, red).

Figure 2

Bipolar montage of EEG recorded during seizure onset from the 48 contact subdural grid. An increase in background low amplitude fast activity is seen at contact G20 (pink arrow) evolving into higher amplitude fast activity interspersed with low amplitude (100 uV) spikes, before an underlying semi rhythmic slow activity occurs (near end of displayed trace). The discharge is maximal at contact G20, and there is some spread to G12. The bipolar derivations near the suspected area of slowing-associated fMRI activation (G42, G43, G44, red) have a very low amplitude signal implying synchronous activity at respective electrode pairs. The fast activity (green arrows) around G22, G23, G30, G31, G37, G38 (green) – reflects limb movement and is concordant with both motor mapping by cortical stimulation and fMRI (compare Figure 1B).

Figure 1

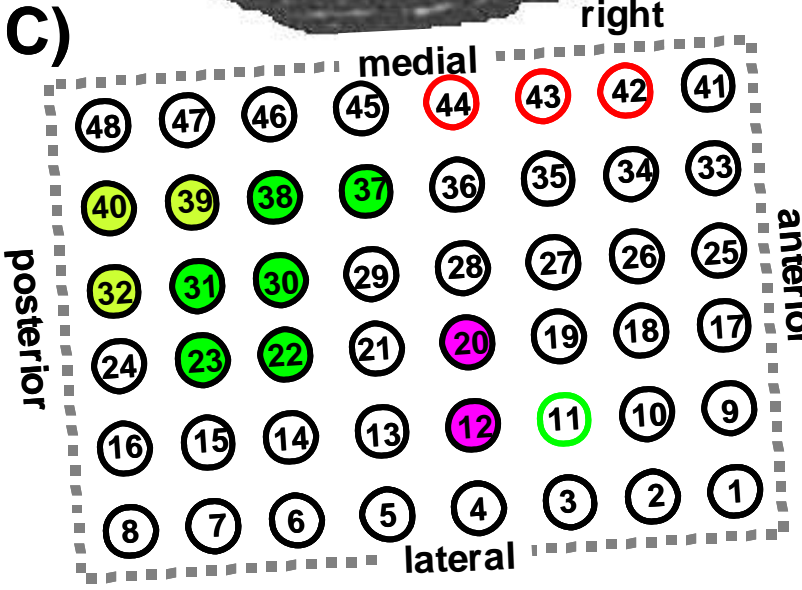
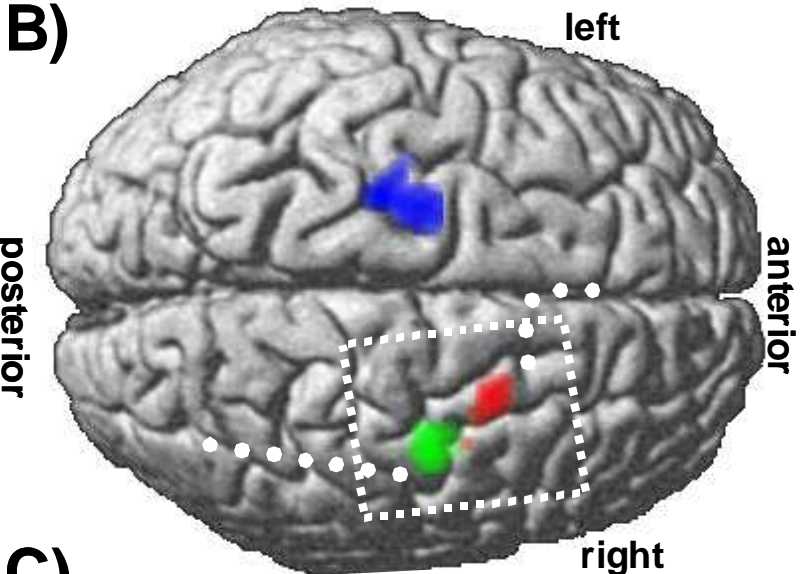
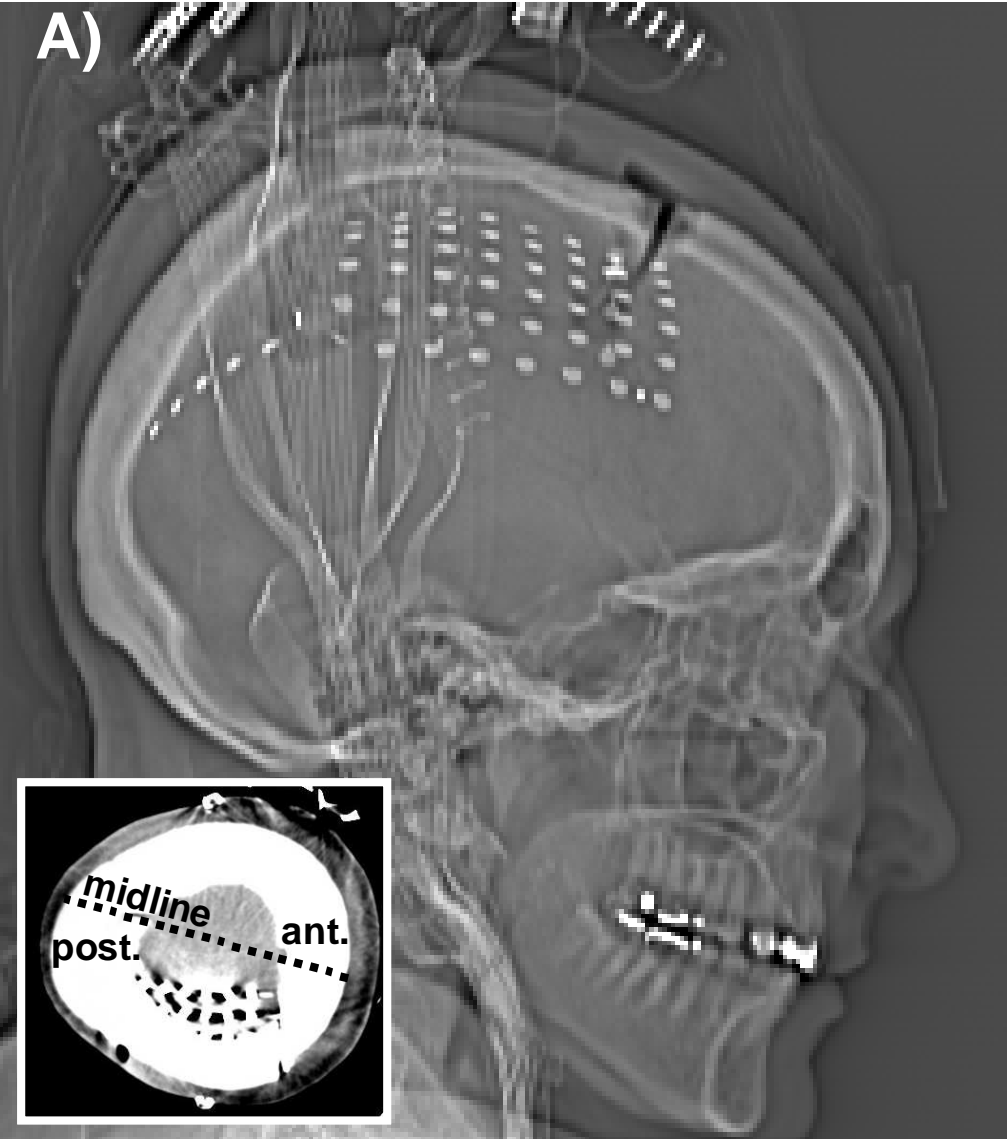


Figure 2

