

Journal of Laryngology & Otology

<http://journals.cambridge.org/JLO>

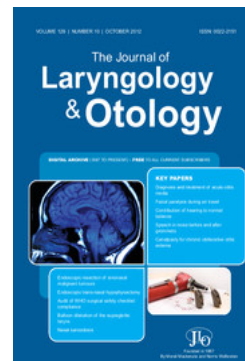Additional services for *Journal of Laryngology & Otology*:

Email alerts: [Click here](#)

Subscriptions: [Click here](#)

Commercial reprints: [Click here](#)

Terms of use : [Click here](#)



Optimum management of inverted papilloma

Valerie Lund

Journal of Laryngology & Otology / Volume 114 / Issue 03 / March 2000, pp 194 - 197
DOI: 10.1258/0022215001905319, Published online: 08 March 2006

Link to this article: http://journals.cambridge.org/abstract_S0022215100000578

How to cite this article:

Valerie Lund (2000). Optimum management of inverted papilloma. Journal of Laryngology & Otology, 114, pp 194-197 doi:10.1258/0022215001905319

Request Permissions : [Click here](#)

Optimum management of inverted papilloma

VALERIE J. LUND, M.S., F.R.C.S., F.R.C.S.(ED.)

Abstract

Surgery offers the optimum modality of treatment for inverted papilloma although a considerable range of operative approaches have been described. The results are presented in a cohort of 37 cases treated by both endoscopic and combined endoscopic and external approaches with a recurrence rate of eight and 21 per cent respectively. This series is compared with those in the literature and demonstrates that it is extent of disease which primarily determines the choice of surgical approach, with previous treatment, individual patient factors and surgical expertise as secondary determinants.

Key words: Papilloma, inverted; Surgical procedures, endoscopic; Paranasal sinuses

Introduction

In 1847 Kramer used the term 'papillae' to describe a cauliflower-like tumour of the mucous membrane.¹ In 1855 Ward² reported a case of nasal papilloma although Billroth³ is usually credited with the first description of a true papilloma of the nasal cavity. In 1938 Ringetz described the inverting nature of a lesion of cylindrical or transitional cell type and for many years the lesion bore his eponym.⁴ Further confusion was added by the term 'Schneiderian' after Victor Conrad Schneider described an epithelial tumour deriving from ectoderm. The term 'inverted' was coined by Lampertico *et al.* in 1963.⁵

Not only are inverted papillomas one of the commonest benign epithelial tumours of the nasal cavity but considerable interest has surrounded their ability to recur and undergo malignant transformation. In the literature recurrence rates of between zero and 75 per cent are quoted⁶ although the term 'recurrence' merely indicates residual disease in the majority of cases and is directly related to the surgical approach and the 'care' with which the papilloma is removed.

The issue of malignant transformation has also been exaggerated. Whilst a range of zero to 53 per cent is found in the literature⁶ it is clear on reviewing those papers claiming high rates of malignancy that well-differentiated squamous cell carcinoma was present *ab initio* in the majority of cases. In a study of 123 cases conducted at the Institute of Laryngology and Otology the proven malignant transformation rate was under two per cent.⁷ However, notwithstanding these remarks, it is important that an inverted papilloma is removed in

its entirety if only to ensure that patients are not subjected to repeated surgical interventions over a number of years.

Material and methods

All cases with inverted papilloma treated between 1992 and 1998 were reviewed for surgical outcome and recurrence. Pre-operative assessment included endoscopic evaluation and computed tomography (CT) scanning in all cases (Figures 1 and 2) together

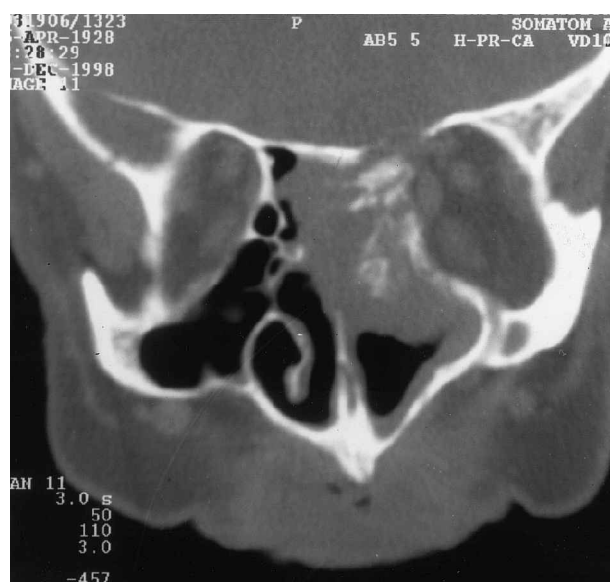

FIG. 1

Coronal CT showing extensive recurrent inverted papilloma following several previous lateral rhinotomies intimately involving orbital periosteum requiring combined surgical approaches.

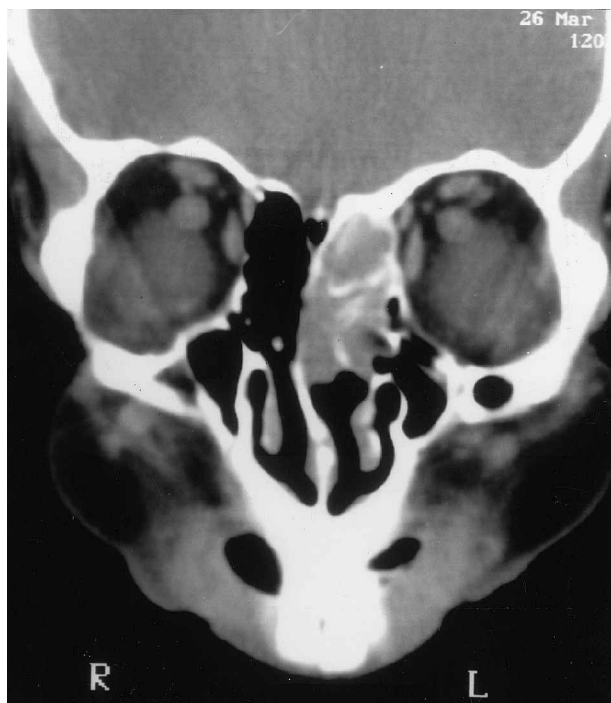

FIG. 2

Coronal CT showing inverted papilloma limited to middle meatus and ethmoids suitable for an endoscopic approach.

with review of previous histology where available. Magnetic resonance imaging (MRI) was performed in three cases to further elucidate the extent of tumour within the frontal sinus. No cases of

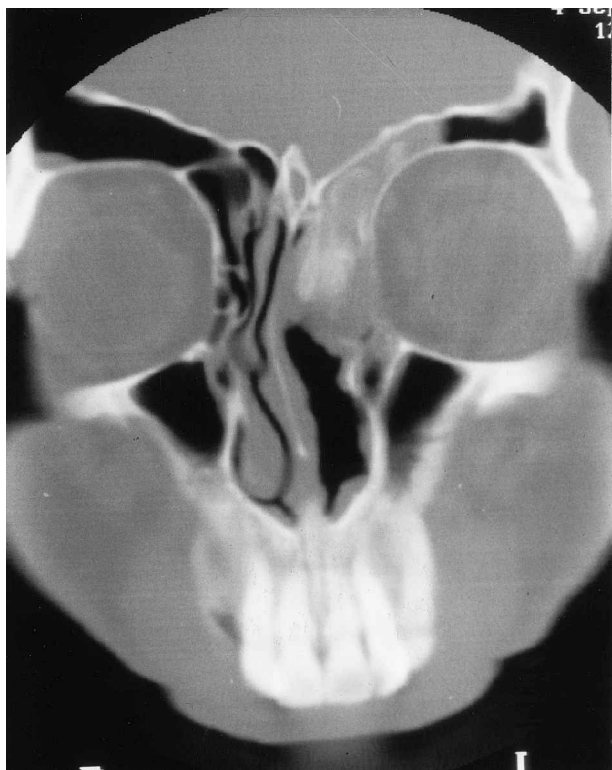


FIG. 3

Coronal CT showing inverted papilloma extending into frontal sinus necessitating combined endoscopic and external approach.

TABLE I

SURGICAL APPROACHES, PREVIOUS SURGERY AND RECURRENCE RATES IN PRESENT SERIES (1992–1998; n = 37)

Approach	n	Previous surgery	Recurrence
Endoscopic alone	13	–	1 (8%)
Endoscopic + external	24	14	5 (21%)
+ External fronto-ethmoidectomy	2		
+ Caldwell Luc	5		
+ Lateral rhinotomy	9		
+ Midfacial degloving	8		

concomitant squamous cell carcinoma were included. Only cases with greater than one year follow-up were included. Follow-up consisted of a formal examination under anaesthesia between four months and one year following the surgery in 30 out of 37 of the cases combined with endoscopic examination at regular outpatient review and CT scanning in any case where recurrence was suspected.

Results

Thirty-seven individuals with inverted papilloma were treated during this period. There were 26 men and 11 women, their ages ranged from 25 to 81 with a mean of 52 years. The follow-up ranged from 1–7.5 years with a mean of 45 months. The surgical approach is shown in Table I. Thirteen were treated by an exclusively endoscopic approach whilst 24, 14 of whom had undergone previous surgery, were treated by a combined endoscopic and an external approach. This previous surgery had included intranasal polypectomy (six on multiple occasions) and lateral rhinotomy (eight; one to three times). Recurrence occurred in one case (eight per cent) treated endoscopically and in five cases (21 per cent) treated by the combined approach. No case of malignant transformation was observed during the follow-up period.

In all 13 cases treated by endoscopic surgery alone the nasal cavity, anterior ethmoids and medial maxilla were involved. In two cases the tumour extended into the sphenoid through the natural ostium and in three cases tumour extended into the frontal nasal recess but without involvement of the sinus mucosa itself. In the two cases treated by a combined endoscopic and external fronto-ethmoidectomy, the frontal sinus mucosa was involved and in those cases treated by Caldwell-Luc, the maxillary sinus mucosa was extensively involved including the lateral wall and floor. In those cases treated by lateral rhinotomy and mid-facial degloving there was extensive disease involving both the maxilla and/or frontal sinus, one case of which was bilateral.

Discussion

The optimum management of inverted papilloma commences with the early diagnosis of the condition. Six patients had undergone previous polypectomy, in some cases over a number of years prior to the diagnosis being made. It is clear that unless clinicians have a low threshold of suspicion for the condition

TABLE II
RESULTS OF RADICAL EXTERNAL SURGERY IN THE LITERATURE

Author	n	F.U. (months)	Recurrence rate (%)
Myers <i>et al.</i> ¹¹	22	10.8	4
Dolgin <i>et al.</i> ¹²	42	>6	22–29
Waitz and Wigand ¹³	16	>12	18
Vrabec ¹⁴	101	9/12–25 yrs	2
McCary <i>et al.</i> ¹⁵	17	1–100	25
Lawson <i>et al.</i> ¹⁶	112	>12	14
Raveh <i>et al.</i> ¹⁷	18	?	22
Yoskovitch <i>et al.</i> ¹⁸	35	1–18 yrs	0

and send material for histological examination, the diagnosis may go unsuspected. Inverted papilloma may occur in association with benign polyposis which may mask the usual unilaterality of the condition. Although malignant transformation is a relatively rare occurrence it is also important that all tissue is carefully examined histopathologically, particularly to avoid the confusion between well-differentiated squamous cell carcinoma and its benign counterpart. CT scanning remains the imaging modality of choice^{8,9} characteristically showing a lesion arising within the middle meatus which dumb-bells into the adjacent sinuses, often associated with a heterogeneous opacification and sclerosis in adjacent bone. However, the extent of disease may be exaggerated by associated inflammation and/or retained secretions which can be clarified by MRI.

Surgery is the agreed primary therapeutic modality of choice and a range of surgical approaches has been described. It is clear that limited surgery such as conventional polypectomy is not surprisingly associated with 'recurrence' rates of up to 75 per cent.¹⁰ This has led to a greater reliance on more concerted attempts to completely remove the papilloma via external approaches (Table II) accompanied by commensurately lower recurrence rates of between zero and 29 per cent. Since the 1980s a number of authors have employed an endoscopic approach in appropriate cases, again reporting a similar range of recurrence zero to 27 per cent (Table III). When all the cases in 20 series reported between 1977 and 1998 are aggregated, a patient cohort of 1 287 may be reviewed (Table IV) and demonstrate comparable recurrence results from both radical external and endoscopic approaches. This is largely a reflection of patient selection based on extent of disease. In my own series, the majority of recurrences occurred in the external group which

TABLE III
RESULTS OF ENDOSCOPIC SINUS SURGERY FOR INVERTED PAPILLOMA
IN THE LITERATURE

Author	n	F.U. (months)	Recurrence rate (%)
Waitz and Wigand ¹³	35	>12	17
Stankiewicz and Gargis ¹⁹	15	26	20
McCary <i>et al.</i> ¹⁵	7	5–19	0
Buchwald <i>et al.</i> ²⁰	5	?	0
Kamel ²¹	17	>24	0
Raveh <i>et al.</i> ¹⁷	9	>24	22
Sham <i>et al.</i> ²²	22	>33	27

TABLE IV
OVERALL RECURRENCE RATES IN PUBLISHED SERIES BETWEEN 1977
AND 1998^{7,10–28} (n = 1287)

Conservative (INP, INE, C/L)	240/413	58%
Radical (LR, MFD)	110/764	14%
Endoscopic	20/110	18%

also included those individuals with the more extensive disease, many of whom had already undergone radical and often multiple surgery.

It is clear that when tumour invades the frontal sinus, lateral maxillary wall, naso-lacrimal region, orbit and/or skull base, the chances of inadequate excision are considerably increased and it is thus the extent of disease which primarily determines the optimum surgical approach. However, it may only be possible at operation to absolutely determine whether the papilloma has infiltrated the mucous membrane or simply 'dumb-belled' into the sinus with associated retention of secretion. In addition previous treatment, individual patient factors and surgical expertise must also be considered. Consequently there is no single right or wrong surgical solution but rather a range of procedures from which a choice may be made in any individual case. Indeed, it may be necessary to warn the patient that the final choice of procedure may be decided at the time of surgery and pre-operative discussion and consent should reflect this.

References

- 1 Kramer (1847) Quoted in Kramer R, Som ML. True papillomas of the nasal cavity. *Arch Otolaryngol* 1935;**22**:22–43
- 2 Ward N. Follicular tumour involving nasal bones, nasal processes of superior maxillary bone and septum of nose. Removal, death from pneumonia, autopsy. *Lancet* 1855;**ii**:460
- 3 Billroth T. Ueber dem Bau des Chleimpolyp. *Berlin Reimer* 1883
- 4 Ringetz N. Pathology of malignant tumours arising in the nasal and paranasal cavities and maxilla. *Acta Otolaryngol* 1938; (**suppl 27**):31–42
- 5 Lampertico P, Russell WO, MacComb WS. Squamous papilloma of upper respiratory epithelium. *Acta Pathol* 1963;**75**:293–302
- 6 Harrison DFN, Lund VJ. Papillomas of the nasal cavity and paranasal sinuses. In: Harrison DFN, Lund, VJ, eds. *Tumours of the Upper Jaw*. Edinburgh, London: Churchill Livingstone, 1993;73–80
- 7 Woodson GE, Robbins T, Michaels L. Inverted papilloma. Considerations in treatment. *Arch Otolaryngol* 1985;**111**:806–11
- 8 Lund VJ, Lloyd G. Radiological changes associated with inverted papilloma of the nose and paranasal sinuses. *Br J Radiol* 1984;**57**:455–61
- 9 Woodruff WW, Vrabec DP. Inverted papilloma of the nasal vault and paranasal sinuses: spectrum of CT findings. *Am J Rhinol* 1994;**162**:419–23
- 10 Calcaterra TC, Thompson JW, Paglia DE. Inverting papillomas of the nose and paranasal sinuses. *Laryngoscope* 1980;**90**:53–60
- 11 Myers EN, Fernau JL, Johnson JT, Tabet JC, Barnes L. Management of inverted papilloma. *Laryngoscope* 1990;**100**:481–90
- 12 Dolgin SR, Zaveri VD, Casiano RR, Maniglia AJ. Different options for treatment of inverting papilloma of the nose and paranasal sinuses: a report of 41 cases. *Laryngoscope* 1992;**102**:231–6

- 13 Waitz G, Wigand ME. Results of endoscopic sinus surgery for the treatment of inverted papillomas. *Laryngoscope* 1992;**102**:917–22
- 14 Vrabec DP. The inverted Schneiderian papilloma: a 25-year study. *Laryngoscope* 1994;**104**:582–605
- 15 McCary WS, Gross CW, Reibel JF, Cantrell RW. Preliminary report: endoscopic versus external surgery in the management of inverting papilloma. *Laryngoscope* 1994;**104**:415–9
- 16 Lawson W, Ho BT, Shaari CM, Biller HF. Inverted papilloma: a report of 112 cases. *Laryngoscope* 1995;**105**:282–8
- 17 Raveh E, Feinmesser R, Shpitzer T, Yaniv E, Segal K. Inverted papilloma of the nose and paranasal sinuses: a study of 56 cases and review of the literature. *Isr J Med Sci* 1996;**32**:1163–7
- 18 Yoskovitch A, Braverman I, Nachtigal D, Frenkiel S, Rochon L, Black MJ. Sinonasal Schneiderian papilloma. *J Otolaryngol* 1998;**27**:122–6
- 19 Stankiewicz JA, Girgis SJ. Endoscopic surgical treatment of nasal and paranasal sinus inverted papilloma. *Otolaryngol Head Neck Surg* 1993;**109**:988–95
- 20 Buchwald C, Franzmann M-B, Tos M. Sinonasal papillomas: a report of 82 cases in Copenhagen County, including a longitudinal epidemiological and clinical study. *Laryngoscope* 1995;**105**:72–9
- 21 Kamel RH. Transnasal endoscopic medial maxillectomy in inverted papilloma. *Laryngoscope* 1995;**105**:847–53
- 22 Sham CL, Woo JKS, van Hasselt CA. Endoscopic resection of inverted papilloma of the nose and paranasal sinuses. *J Laryngol Otol* 1998;**112**:758–64
- 23 Suh KW, Facer GW, Devine KD, Weiland LH, Zujko RD. Inverting papilloma of the nose and paranasal sinuses. *Laryngoscope* 1977;**87**:35–46
- 24 Kristensen S, Vorre P, Elbrønd O, Søggaard H. Nasal Schneiderian papillomas: a study of 83 cases. *Clin Otolaryngol* 1985;**10**:125–34
- 25 Segal K, Atar E, Mor C, Har-El G, Sidi J. Inverting papilloma of the nose and paranasal sinuses. *Laryngoscope* 1986;**96**:394–8
- 26 Weissler MC, Montgomery WW, Turner PA, Montgomery SK, Joseph MP. Inverted papilloma. *Ann Otol Rhinol Laryngol* 1986;**95**:215–21
- 27 Benninger MS, Lavertu P, Levine H, Tucker HM. Conservation surgery for inverted papillomas. *Head Neck* 1991;**13**:442–5
- 28 Outzen KE, Grøntvold A, Jørgensen K, Clausen PP, Ladefoged C. Inverted papilloma: incidence and late results of surgical treatment. *Rhinology* 1996;**34**:114–8

Address for correspondence:
Professor V. J. Lund,
Professor in Rhinology,
Institute of Laryngology and Otology,
University College London,
330 Gray's Inn Road,
London WC1X 8DA.