

Journal of Laryngology & Otology

<http://journals.cambridge.org/JLO>


Additional services for *Journal of Laryngology & Otology*:

Email alerts: [Click here](#)

Subscriptions: [Click here](#)

Commercial reprints: [Click here](#)

Terms of use : [Click here](#)



Optimum imaging for sinonasal malignancy

Glyn Lloyd, Valerie J. Lund, David Howard and Lloyd Savy

Journal of Laryngology & Otology / Volume 114 / Issue 07 / July 2000, pp 557 - 562
DOI: 10.1258/0022215001906174, Published online: 08 March 2006

Link to this article: http://journals.cambridge.org/abstract_S0022215100001651

How to cite this article:

Glyn Lloyd, Valerie J. Lund, David Howard and Lloyd Savy (2000). Optimum imaging for sinonasal malignancy. Journal of Laryngology & Otology, 114, pp 557-562 doi:10.1258/0022215001906174

Request Permissions : [Click here](#)

Radiology in Focus

Optimum imaging for sinonasal malignancy

GLYN LLOYD, D.M., F.R.C.R., F.R.C.OPHTH., VALERIE J. LUND, M.S., F.R.C.S., F.R.C.S.(ED.), DAVID HOWARD, F.R.C.S., F.R.C.S.(ED.), LLOYD SAVY, B.Sc., F.R.C.R.

Abstract

A combination of computed tomography (CT) and magnetic resonance imaging (MRI) is now established as the optimum assessment of sinonasal malignancy. CT and MRI are of particular value in assessing the skull base, orbit and pterygo-palatine and infratemporal fossae. Although MRI offers better differentiation of tumour from surrounding tissue and fluid, coronal CT is still required for the demonstration of bone erosion particularly in the region of the cribriform plate. Thus the extent of local tumour spread may be determined with a degree of accuracy in excess of 98 per cent. However, the final determinant of penetration of the dura and orbital periosteum requires per-operative frozen section assessment. A knowledge of the tissue characteristics and site of origin can be of value in distinguishing some of the commoner sinonasal malignancies such as squamous cell carcinoma, adenocarcinoma, adenoid cystic carcinoma, olfactory neuroblastoma and chondrosarcoma. Imaging, particularly MRI also plays an important role in the post-therapeutic follow-up of patients, indicating areas of residual or recurrent disease, defining suspicious areas for biopsy. Post-operative surveillance is best achieved with three planar T1-weighted MRI, with, and without, gadolinium and axial T2-weighted sequences. The subtraction of the T1 pre- and post gadolinium T1 sequences can be of particular value in delineating recurrence.

Key words: Magnetic resonance imaging; Tomography, X-ray computed; Paranasal sinus neoplasms

Introduction

In general, imaging has a threefold part to play in the management of sinonasal malignancy; firstly, at an early stage, the tumour may be inaccessible to clinical methods of examination and the initial diagnosis must be made by the radiologist and secondly, it is the best method of establishing the extent of the disease prior to treatment. In this respect CT and gadolinium-enhanced magnetic resonance (GdMR) are invaluable.¹⁻⁵ These techniques will show the best area for biopsy of the tumour, the presence of bone destruction, and the precise outlines of the mass both within the sinuses and in adjacent structures. Thirdly, imaging is of increasing importance in the post-operative surveillance of malignant sinus disease.

Materials and method

This review is based on an analysis of the imaging of 246 histologically proven malignant sinonasal tumours collected over a 20-year period, since the introduction of routine bi-planar head and neck CT in 1978, from a cohort of 515 malignant tumours.

Plain X-ray changes

The striking feature of plain X-ray changes is their unilateral nature with occlusion of one side of the nasal cavity and totally opaque sinuses on the same side. This is the result of a combination of direct tumour invasion and retained secretion. Typically, the nasal septum is bowed toward the normal side by the tumour mass and the contralateral sinuses are clear. The changes are most character-

istic of squamous cell carcinoma, the commonest sino-nasal malignancy. (Figure 1)

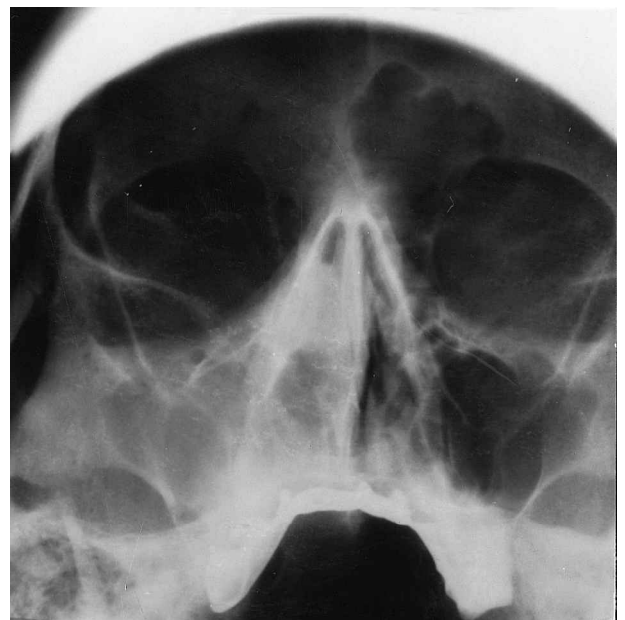


FIG. 1

Plain sinus X-ray (occipito-mental view) showing unilateral opacification of the maxillary sinus with occlusion of the adjacent nasal cavity and bowing of nasal septum.

TABLE I
IMAGING PROTOCOL FOR INVESTIGATION OF SINONASAL MALIGNANCY

<i>Pre-operative</i>	
CT scanning	
Direct coronal, axial	(one plane with and without contrast enhancement)
Filters and reconstruction algorithms should be suitable for both soft tissue and bone window settings	
MRI	
Coronal, axial and sagittal T1 (\pm gadolinium-DTPA)	Axial T2-weighted sequence
<i>Post-operative</i>	
MRI	
Coronal, axial and sagittal T1 pre- and post-gadolinium-DTPA with subtraction	Axial T2-weighted sequence

CT and MRI

Malignant sinus tumours are now optimally assessed by a combination of CT and GdMR; CT to show sites of bone destruction and GdMR to show soft tissue spread. (Table I). The CT protocol differs from that used for inflammatory disease and should be utilized whenever neoplasia is suspected. MRI allows soft tissue differentiation between tumour, inflammation, retention of mucus and fibrosis as confirmed by studies comparing histological findings at cranio-facial resection with pre-operative imaging. Using this protocol a correct correlation between CT and histology was found in 85.2 per cent of areas examined. The correlation of MRI with histological findings improves this figure to 94.1 per cent and the addition of gadolinium

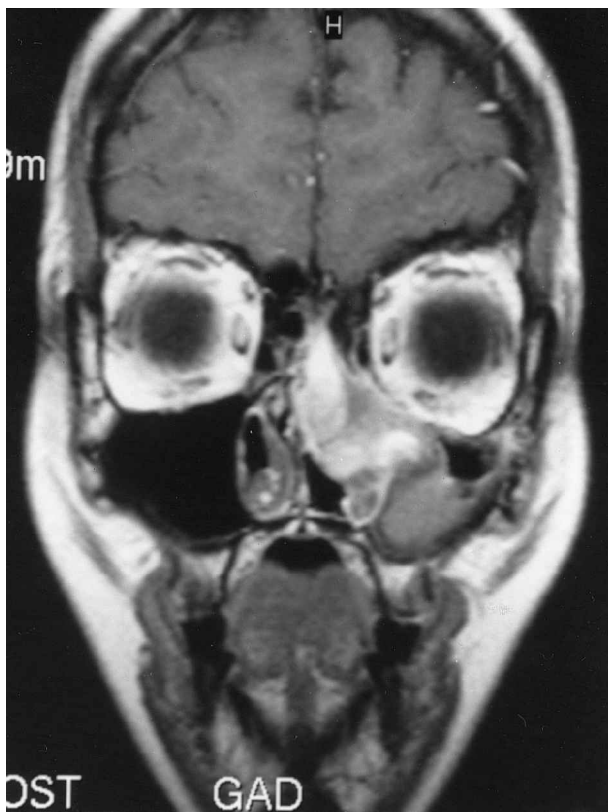


FIG. 2

T1-weighted gadolinium-enhanced MRI showing the differentiation between tumour, fluid and mucosal thickening in a case of malignant schwannoma.

DTPA increase the correlation to 98.4 per cent.⁵ However, the microscopic relationship of the tumour to orbital periosteum and dura cannot be resolved by imaging alone and must rely upon frozen section at the time of surgery.¹ The three plane multi-slice facility, using a head coil, gives total coverage of the head and neck so that both the primary tumour and any direct or metastatic cervical involvement can be recognized. Although the latter is a relatively infrequent accompaniment to sino-nasal malignancy occurring in fewer than 10 per cent of cases.

The combination of CT and MRI are of particular value in assessing several important anatomical sites:

(1) *Skull base.* Significant extension of disease through the cribriform plate into the anterior cranial fossa is best demonstrated by GdMR although early erosion is best seen on coronal CT. Tumours in this area can be shown on MRI by T2-weighted sequences which discriminate well between tumour and inflammation extra-cranially. However, T2 images have the disadvantage of poor discrimination between tumour and cerebral oedema. On the other hand the addition of gadolinium-DTPA to T1-weighted sequences will make this distinction clear and show the exact limits of the tumour; the oedema is not affected by the contrast medium. Similarly in the sinuses themselves, retained secretion is not affected by the gadolinium so that there is a clear distinction between tumour and fluid (Figure 2). Dural thickening and enhancement can be more difficult to interpret as this can occur as a reactive phenomenon adjacent to intracranial tumour extension but can also follow surgery or radiotherapy in the absence of residual or recurrent tumour.

(2) *Orbit.* Extension of disease into the orbit can be shown by either CT or MRI.^{6,7} Two varieties of orbital invasion can be demonstrated.

- (i) The more common type of invasion is seen in both benign and malignant sinus tumours. In this the orbital contents are displaced laterally without direct invasion, the peri-orbita acting as a barrier and resisting tumour infiltration.
- (ii) The second, less common type of orbital invasion is a direct infiltration of the retrobulbar structures by tumour so that the normal anatomical landmarks are obliterated. This represents a later stage of orbital tumour spread. In fact pre-contrast T1 sequences offer good demonstration of the tumour/fat interface. Gadolinium enhancement is helpful in the MR demonstration of orbital invasion but the contrast medium may enhance tumour signal to the same intensity as that of orbital fat, rendering the lesion less conspicuous. Fat suppression sequences must be performed to overcome this problem. The quality of fat suppression does vary from scanner to scanner and subtraction images can be useful. The non-enhancing of adipose tissue ensures almost total subtraction of the fat signal so that the extent of tumour within the orbit is optimally shown. (Figure 3a, b).

(3) *Pterygo-palatine and infratemporal fossae.* The significance of these areas is related to the confluence within them of a number of vascular and lymphatic channels connecting the face and the cranium; once the pterygo-palatine fossa is invaded, these allow easy tumour access to the middle cranial fossa, orbit, nose, nasopharynx and palate, indicating that the tumour is likely to be beyond the limits of complete resectability. CT has been the best method of demonstrating early pterygo-palatine fossa involvement, and was regarded as superior to magnetic resonance, largely because of the combination of soft tissue and bone imaging available. However, MRI is now as good as, if not better than, CT especially when there is more extensive invasion of the infratemporal fossa.

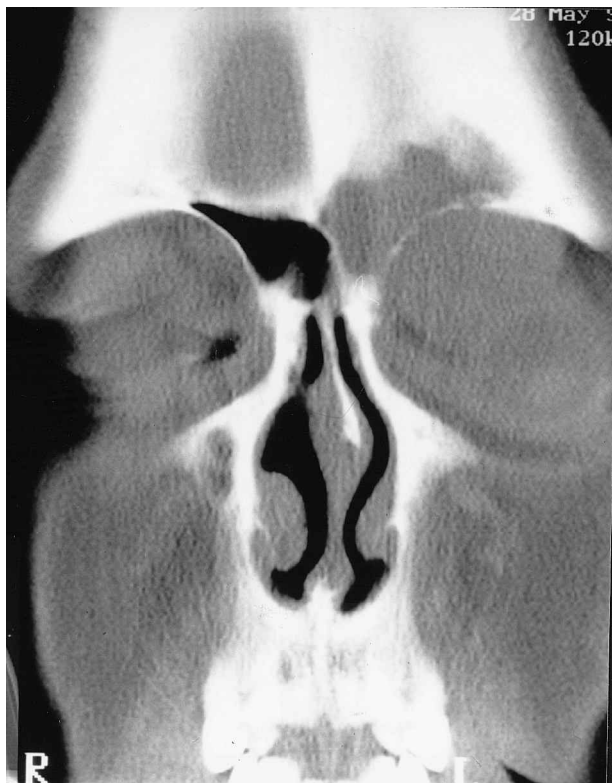

FIG. 3(a)

Coronal CT scan showing a small cell carcinoma of the upper medial quadrant of the orbit with opacification of the adjacent frontal sinus.

Post-operative surveillance

Regular post-operative surveillance by MRI is now routine following major surgery for sinus malignancy, whether there is clinical suspicion of recurrence or not. It is important to show early recurrence so that treatment by revision surgery and radiotherapy may be successful in preventing further extension or metastases. The frequency of the investigation and duration of the follow-up depends on the tumour type and patient availability but is generally performed every four to six months during the first two years and thereafter on a nine to 12 month basis.

Many tumour recurrences are diagnosed by clinical inspection particularly by endoscopy, but imaging is essential to visualize those areas that are inaccessible clinically. Again the cavity and extra-cranial areas can be shown well on T2-weighted scans but GdMR facilitates the demonstration of intracranial tumour recurrence after cranio-facial resection (Figures 4a and b) (Table I). In the subtraction process the magnetic resonance signal is removed from the final image so that the densities recorded are dependent only upon the enhancement of the tissue concerned, whether normal or pathological.^{8,9} Subtraction is most advantageous in situations where the anatomy is complex, as at the skull base, or in tumour recurrence where normal structures are distorted by previous surgery.

Tissue characteristics. The commoner histological varieties of malignant sino-nasal tumour may show some distinguishing features on CT and MR.

Most squamous cell carcinomas arise in the nose or maxillary antrum, but when first seen the tumours usually involve the nasal cavity, antrum and ethmoids. They tend to spread posteriorly invading the pterygo-palatine fossa at

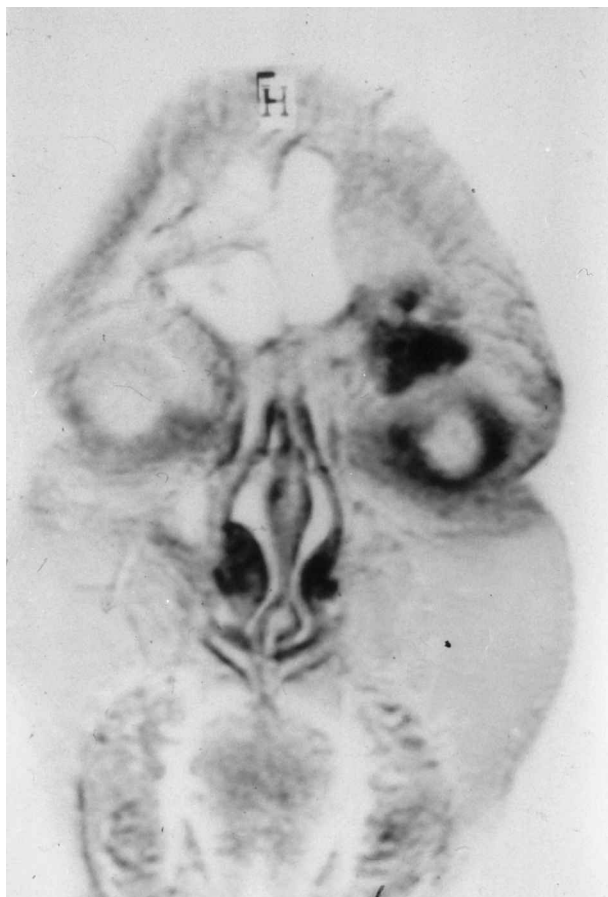


FIG. 3(b)

Subtraction GdMR in the same patient showing tumour enhancement within the orbit and no signal from the frontal sinus, showing that the opacification on CT was fluid.

an early stage: in the series under review 70 per cent showed CT evidence of this invasion at initial examination, which undoubtedly contributes to the poor prognosis of these tumours (32 per cent five-year survival) (Figure 5a, b).¹⁰

Adenocarcinoma may present a similar distribution, but a greater number (63 per cent) show a different location, being principally naso-ethmoidal, occupying the upper part of the nasal cavity and adjacent ethmoid cells. From this point of origin adenocarcinoma can gain early access to the cribriform plate area and the anterior cranial fossa, and the prognosis following cranio-facial surgery is directly related to the presence or absence of anterior fossa invasion which may be seen on the pre-operative scans (Figure 6).¹⁰ Extension readily occurs anteriorly into the glabellar region and posteriorly into the sphenothmoidal recess and nasopharynx – areas to which special attention must be paid on examining the imaging. Adenocarcinoma also, not infrequently, crossed the midline to the opposite ethmoid complex.

Adenoid cystic carcinoma is a malignant tumour derived from salivary-type seromucinous glands in the nose and paranasal sinuses. The majority of these tumours originate in the lower part of the nasal cavity and may involve both the hard and soft palate at an early stage. Some may present as a bulk tumour occupying an antro-ethmoidal location but many do not show as a large mass but tend to infiltrate soft tissue: they advance along tissue planes by

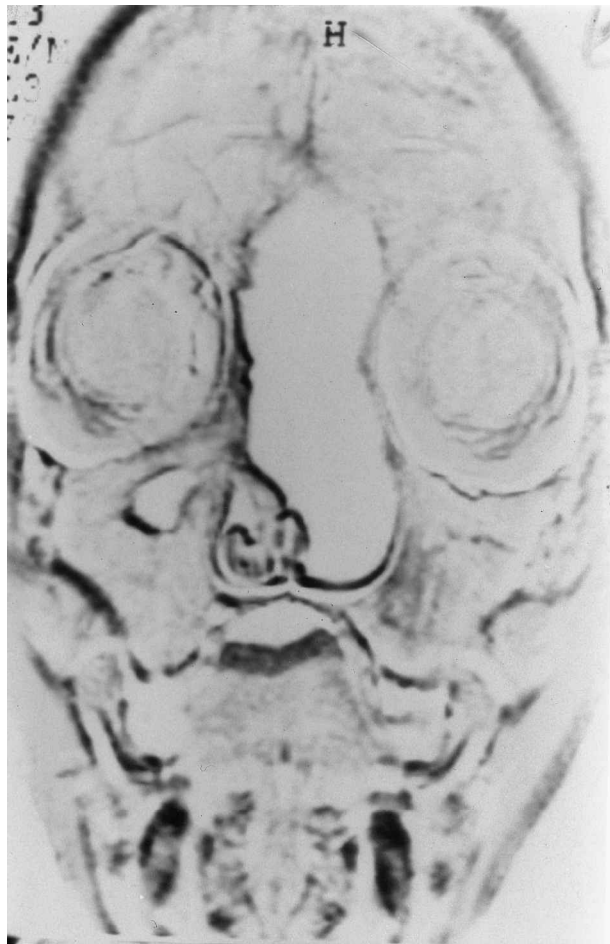


FIG. 4(a)

Subtraction GdMR showing normal post-operative craniofacial cavity with high signal from normal nasal mucosa.

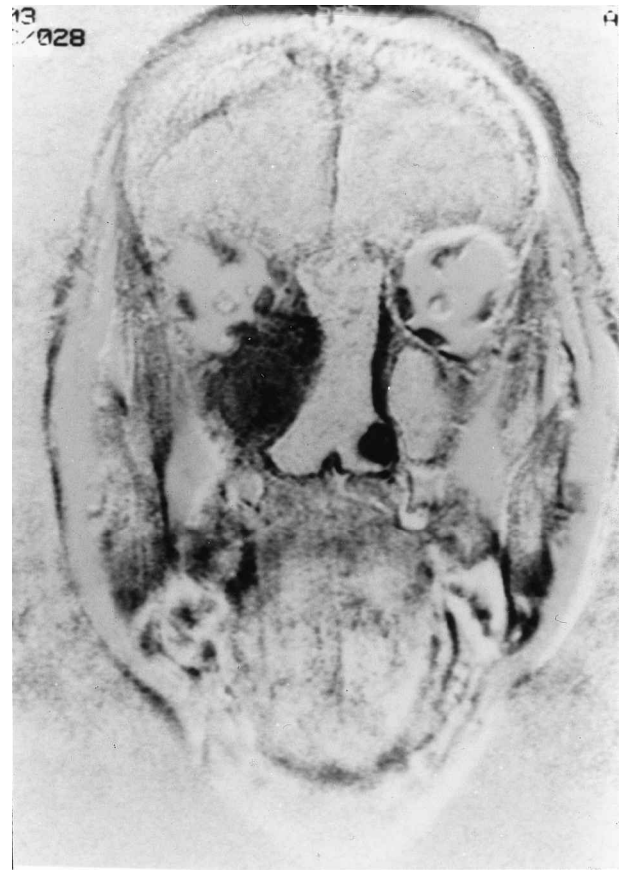

FIG. 4(b)

Subtraction GdMR showing post-operative craniofacial cavity with recurrent olfactory neuroblastoma in the maxillary sinus, adjacent to orbit.

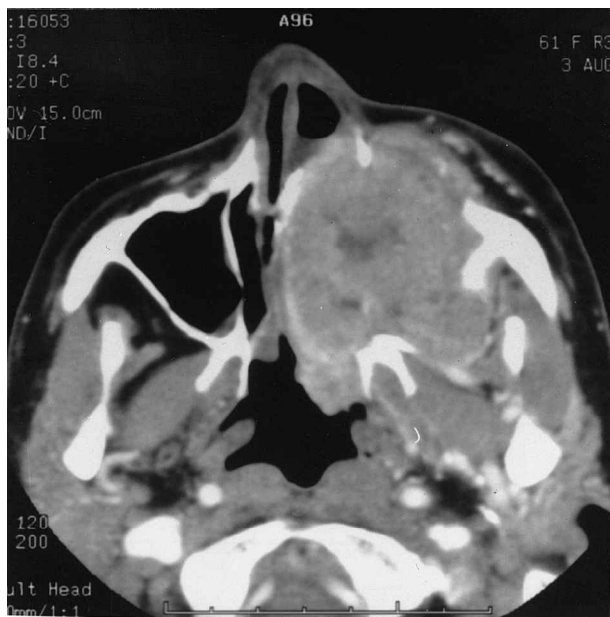


FIG. 5(a)

Axial CT scan showing squamous cell carcinoma of the maxillary sinus with expansion and erosion of the bone. Tumour extension is seen into the pterygoid region.

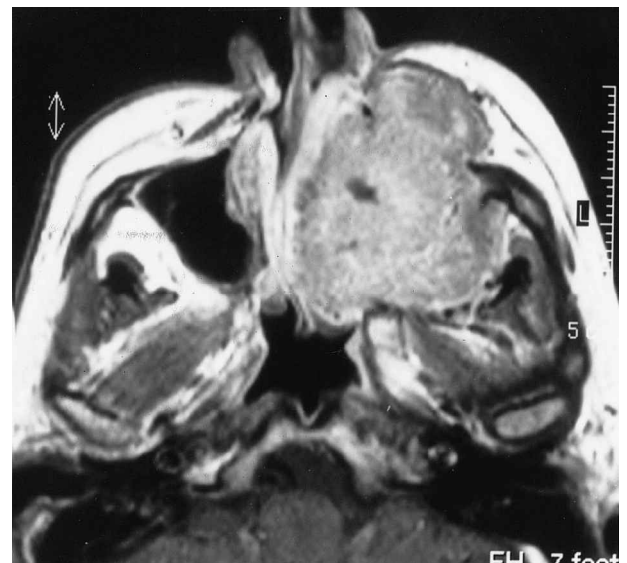

FIG. 5(b)

T1-weighted MR of same case.

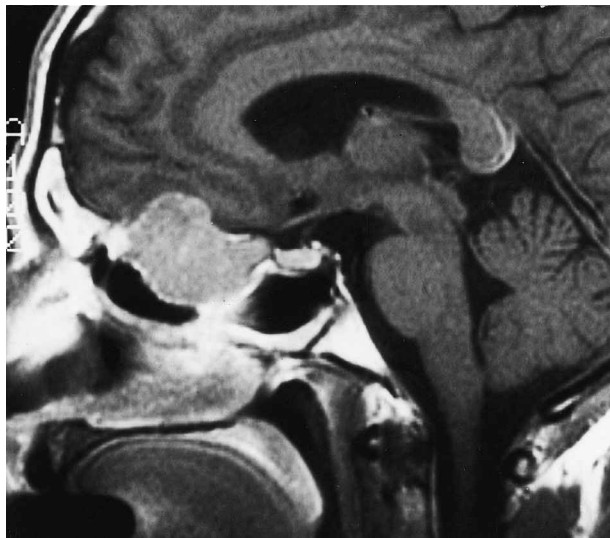


FIG. 6

Sagittal MRI (T1-weighted with gadolinium) showing mass of adenocarcinoma impinging on anterior cranial fossa with mucosal thickening in adjacent frontal and sphenoid sinuses.

perineural lymphatic spread which may be contiguous with the primary lesion or embolic. MRI can be helpful in demonstrating this.

In certain cases the tumour may represent a secondary deposit in the sinuses e.g. clear cell renal carcinoma when further imaging of the abdomen may be appropriate. Similarly some types of sinonasal tumour have a propensity for metastatic spread e.g. adenoid cystic carcinoma giving secondary deposits in the lungs and further imaging may be required as part of the pre-operative evaluation.

Olfactory neuroblastoma most usually arises from the olfactory epithelium in the nasal roof (although other locations can be found), and presents in the sub-cribriform plate area on CT and MRI. Erosion of the cribriform plate is an early feature and is best demonstrated by CT (Figure 7). These tumours are, on average, more vascular than the carcinomata although the degree of enhancement on MR

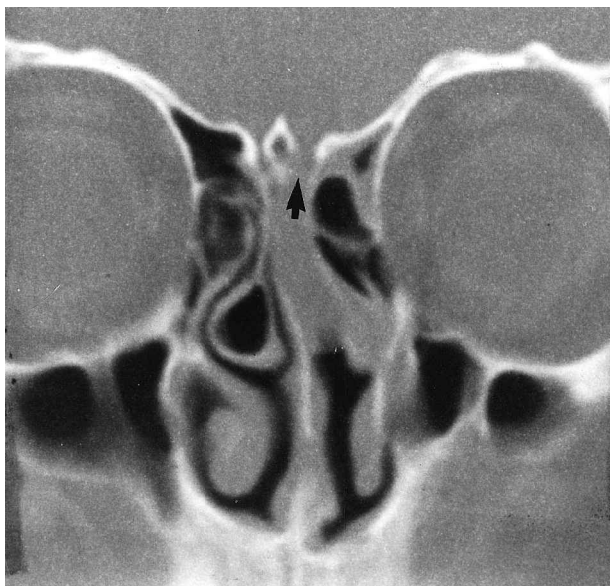


FIG. 7

Coronal CT showing early cribriform plate erosion (arrowed) associated with a small olfactory neuroblastoma.

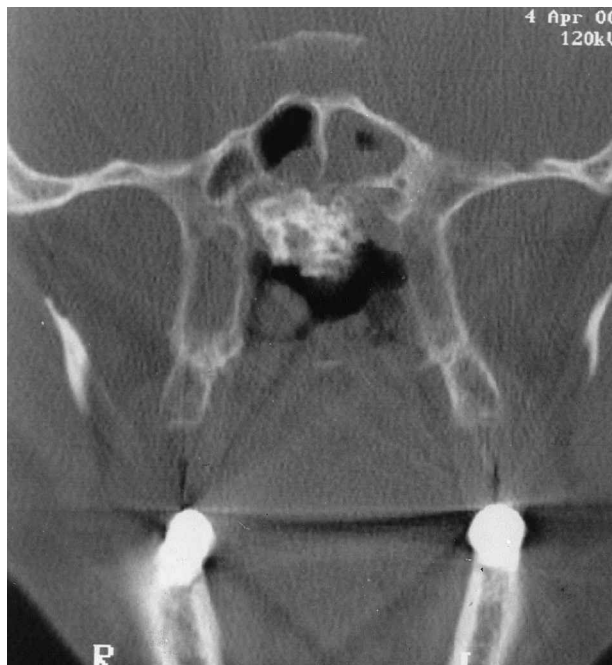

FIG. 8

Coronal CT showing chondrosarcoma of the perpendicular plate of ethmoid, vomer and face of sphenoid with characteristic calcification.

and CT may be similar. Histological analysis of craniofacial specimens has shown microscopic involvement of the olfactory bulbs and tract early in the disease.¹¹ As with adenocarcinoma, the prognosis is significantly worsened when the tumour is shown macroscopically to invade the anterior fossa or orbit on pre-operative imaging.

The commonest malignant sinonasal tumour of connective tissue origin is chondrosarcoma. This tumour has a high long-term survival rate but a high rate of recurrence requiring repeated cranio-facial resection.¹⁰ On CT they present as a lobulated mass expanding and destroying bone and typically contain areas of nodular or plaque-like calcification. The diagnostic feature on MRI is a differential enhancement of the mass of T1-weighted post-gadolinium sequences. The contrast enhancement is seen at the periphery of the tumour and the central chondromatous core fails to enhance. These changes are dependent on the vascularity of the tissues concerned and correlate exactly with the histopathology of resected specimens (Figure 8).¹²

References

- 1 Lund VJ, Howard DJ, Lloyd GAS. CT evaluation of paranasal sinus tumours for craniofacial resection. *Br J Radiol* 1983;**56**:439-46
- 2 Weber AL, Stanton AC. Malignant tumours of the paranasal sinuses: radiologic, clinical and histopathologic evaluation of 200 cases. *Head Neck Surg* 1984;**6**:761-76
- 3 Som PM, Lawson W, Biller HF, Lanzieri C, Sachdev VP, Rigamonti D. Ethmoid sinus disease: CT evaluation in 400 cases. Part III Craniofacial resection. *Radiology* 1986;**159**:605-9
- 4 Lloyd GAS, Lund VJ, Phelps PD, Howard DJ. Magnetic resonance imaging in the evaluation of nose and paranasal sinus disease. *Br J Radiol* 1987;**60**:957-68.
- 5 Lund VJ, Howard DJ, Lloyd GAS, Cheesman AD. Magnetic resonance imaging of paranasal sinus tumours for craniofacial resection. *Head Neck Surg* 1989;**11**:279-83

- 6 Hesselink JR, Weber AL. Pathways of orbital extension of extraorbital neoplasms. *J Comput Assist Tomogr* 1982;**6**:593-7
- 7 Lund VJ, Howard DJ, Cheesman AD. Proceedings 4th International Conference on Head and Neck Cancer. Head and Neck Cancer Proceedings. The Orbit. *Evaluation and Intra-operative Management* 1996;**4**:1020-7
- 8 Lloyd GAS, Barker PB. Subtraction magnetic resonance for tumours of the skull base and sinuses: a new imaging technique. *J Laryngol Otol* 1991;**105**:628-31
- 9 Lund VJ, Lloyd GAS, Howard DJ, Cheesman AD, Phelps PD. Enhanced magnetic resonance imaging and subtraction techniques in the postoperative evaluation of cranio-facial resection for sinonasal malignancy. *Laryngoscope* 1996;**106**:553-8
- 10 Lund VJ, Howard DJ, Wei WI, Cheesman AD. Cranio-facial resection for tumors of the nasal cavity and paranasal sinuses – a seventeen year experience. *Head Neck Surg* 1998;**20**:97-105
- 11 Harrison DFN. Surgical pathology of olfactory neuroblastoma. *Head Neck Surg* 1984;**7**:60-6.
- 12 Lloyd GAS, Phelps PD, Michaels L. The imaging characteristic of naso-sinus chondrosarcoma. *Clin Radiol* 1992;**6**:189-92

Address for correspondence:

Professor V. J. Lund,
Institute of Laryngology and Otology,
University College London,
330 Gray's Inn Road,
London WC1X 8DA, UK.

Fax: 44 (0) 20 7833 9480

Professor V. Lund takes responsibility for the integrity of the content of the paper.

Competing interests: None declared
