

Journal of Laryngology & Otology

<http://journals.cambridge.org/JLO>


Additional services for *Journal of Laryngology & Otology*:

Email alerts: [Click here](#)

Subscriptions: [Click here](#)

Commercial reprints: [Click here](#)

Terms of use : [Click here](#)



Optimum imaging for inverted papilloma

Lloyd Savy, Glyn Lloyd, Valerie Lund and David Howard

Journal of Laryngology & Otology / Volume 114 / Issue 11 / November 2000, pp 891 - 893
DOI: 10.1258/0022215001904284, Published online: 08 March 2006

Link to this article: http://journals.cambridge.org/abstract_S002221510000253X

How to cite this article:

Lloyd Savy, Glyn Lloyd, Valerie Lund and David Howard (2000). Optimum imaging for inverted papilloma. Journal of Laryngology & Otology, 114, pp 891-893 doi:10.1258/0022215001904284

Request Permissions : [Click here](#)

Optimum imaging for inverted papilloma

LLOYD SAVY, B.Sc., M.B., B.S., F.R.C.R., GLYN LLOYD, D.M., F.R.C.R., F.R.C.O.PHTH.,
VALERIE J. LUND, M.S., F.R.C.S., F.R.C.S.(ED.), DAVID HOWARD, F.R.C.S., F.R.C.S.(ED.)

Abstract

Inverted papilloma is the most common benign tumour of the nose and paranasal sinuses, and usually arises in the lateral wall of the nasal cavity and the middle meatus. The diagnosis is suggested on computed tomography (CT) when there is a mass continuous from the middle meatus into the adjacent maxillary antrum, through an expanded maxillary ostium. The mass may contain areas of high density or calcification, and there may be sclerosis of the wall of the affected sinus. The main advantage of magnetic resonance imaging (MRI) is in defining the extent of the tumour, and in differentiating it from adjacent inflammatory tissue, but there are no certain signal intensity or enhancement characteristics to help differentiate inverted papilloma from sinus malignancy. In the differential diagnosis, antro-choanal polyp, malignant sinus tumours and chronic rhinosinusitis and fungal disease need to be excluded. The combination of bone deformity and sclerosis with the typical antro-meatal mass suggests a slow-growing tumour such as inverted papilloma.

Key words: Magnetic Resonance Imaging; Tomography, X-ray Computed; Papilloma, Inverted

Introduction

Inverted papilloma is the most common benign tumour of the nose and paranasal sinuses.¹ Its usual site of origin is from the lateral wall of the nasal cavity in the middle meatus. The vast majority are unilateral and produce a nasal cavity mass with early spread into the maxillary antrum. Macroscopically, inverted papilloma often has the appearance of an ordinary or slightly fleshy lobulated nasal polyp, but histologically is characterized by an inversion of the surface epithelium into the underlying stroma. It is important clinically because of its tendency to recur following incomplete excision, and because of its association, albeit infrequent, with squamous cell carcinoma. The imaging appearances of this tumour are reviewed and the CT and MR findings presented in a series of 76 patients with histologically verified inverted papilloma.

Materials and method

Imaging was available for a retrospective analysis in 76 patients seen over a period of 20 years from 1980–2000. The average age was 51 years and the age range 20–82 years with a male/female ratio of 2.45.

Plain radiography

Plain radiographs can be entirely negative or more often the appearances are non-specific with opacification of one maxillary antrum indistinguishable from inflammatory sinus disease. The diagnosis of inverted papilloma may be suggested by the presence of a mass in the middle meatus with unilateral opacification of the antrum and ipsilateral paranasal sinuses. In common with malignant nasal tumours, the nasal septum may be bowed away from the side of the lesion.

Computed tomography (CT)

The characteristic feature on CT is that of a mass continuous from the middle meatus into the adjacent maxillary antrum through a widened maxillary ostium. This gives rise to a characteristic shape somewhat like the continent of Africa (Figure 1). The maxillary antrum is most commonly affected although the ethmoids, the frontal and occasionally the sphenoid sinus may be involved with, or without, antral involvement. Tumours with an atypical location are much more difficult to diagnose, but the presence of internal hyperdensity (Figures 2, 3) or irregular sclerosis and deformation of the sinus walls (Figure 4) may point to the diagnosis. CT does have the limitation that the boundaries of the tumour are difficult or impossible to distinguish from adjacent soft tissue density due to retained secretion in adjacent sinuses where drainage is obstructed by the tumour. There may indeed be a co-existent mucocele of an obstructed sinus which can itself present with orbital or intracranial complications. A lobulated margin of inverted papilloma has also been reported as a characteristic finding on CT.² In this series it was best demonstrated in the maxillary antrum when the tumour partially filled the sinus cavity (Figure 5).

Magnetic resonance imaging (MRI)

The main advantage of MRI over CT is in defining the extent of inverted papilloma rather than making the diagnosis (Figure 6). This is important for it is the extent of the disease which primarily determines the choice of surgical approach.³ T2-weighted MRI is very accurate in distinguishing papilloma (intermediate signal) from adjacent inflammatory change (very high signal). The papilloma usually shows homogeneous enhancement with intravenous gadolinium but Yousem *et al.*⁴ concluded

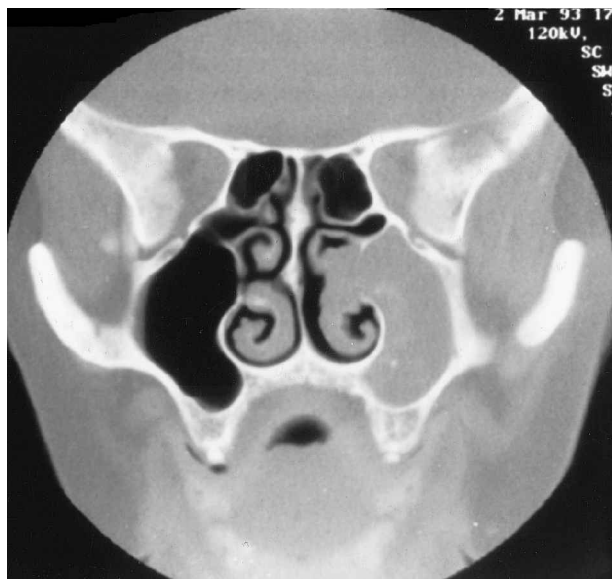

FIG. 1

Coronal CT showing typical appearance of inverted papilloma. There is a mass extending from the middle meatus into the antrum. Note small areas of high density or calcification within the antral component.

that there are no distinctive signal intensity or enhancement characteristics to help differentiate inverted papilloma from various sinus malignancies. In common with CT, MRI is unable to differentiate foci of co-existent squamous cell carcinoma from inverted papilloma, although it has been suggested that the malignant tumour enhances more homogeneously than the benign one.⁵ Frank destruction of sinus walls due to malignant change is less easy to recognize than by CT, but invasion of tumour into the orbit and nasopharynx is optimally shown by unenhanced T1, or enhanced T1 weighted sequences with fat suppression. Intracranial involvement by inverted

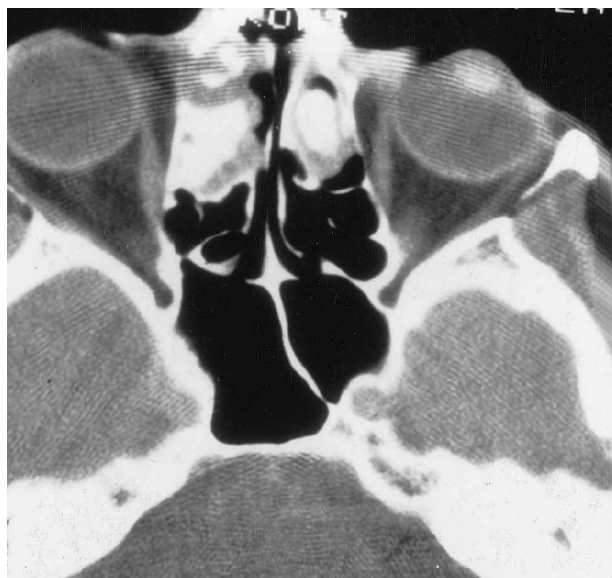

FIG. 2

Plaque-like densities in both right and left anterior ethmoid cells in inverted papilloma, shown on axial CT.

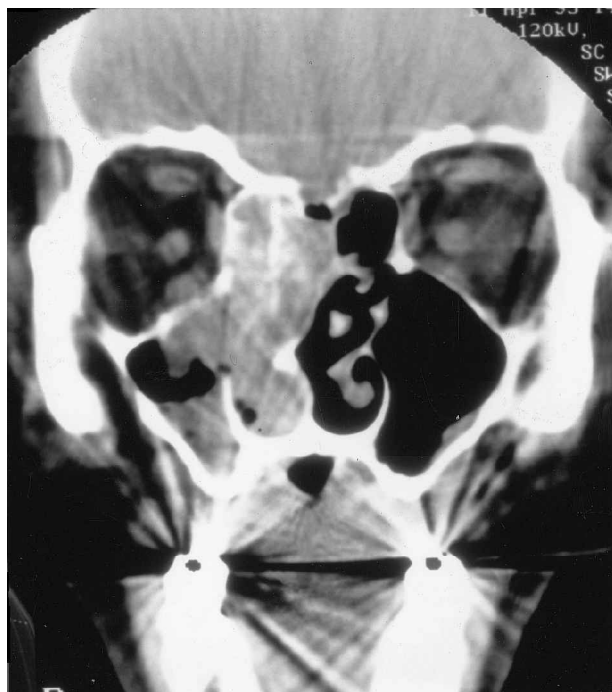


FIG. 3

A similar appearance to Figure 2. Coronal CT showing unilateral hyper-density in inverted papilloma.

papilloma is extremely rare but involvement with squamous cell carcinoma is more common and enhanced MRI is superior to CT in demonstrating and differentiating dural and pial infiltration when the anterior cranial fossa is invaded.

Differential diagnosis

When a nasal mass is shown with complete opacity of the ipsilateral maxillary antrum and widening of the sinus

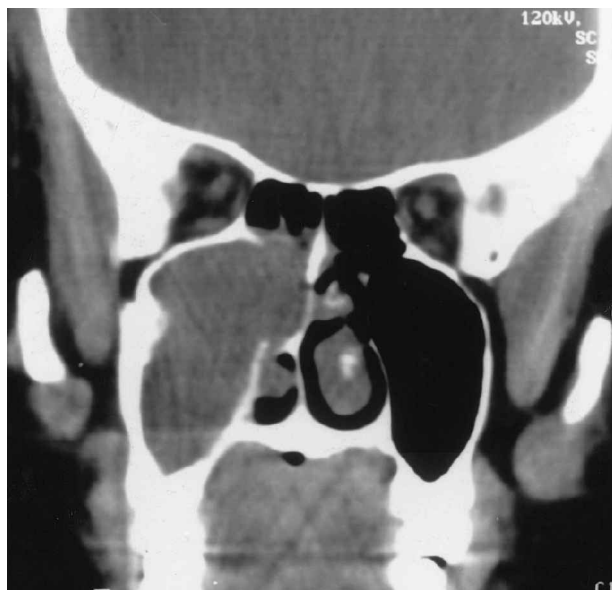

FIG. 4

Coronal CT scan of inverted papilloma showing sclerosing and deformity of the antral wall.

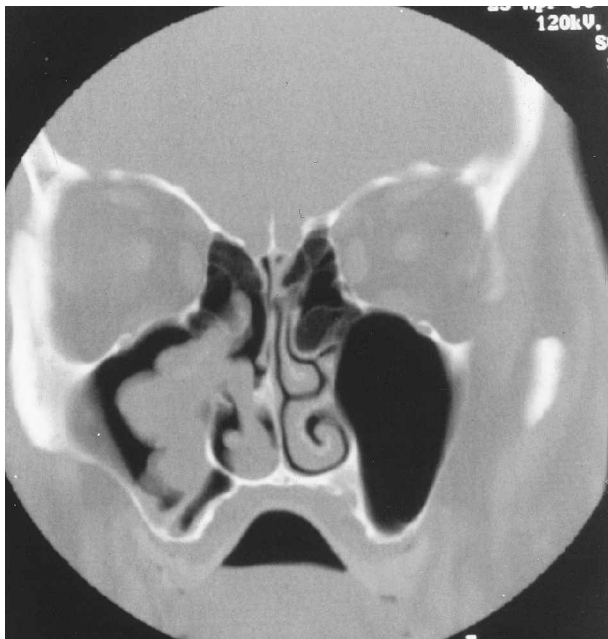


FIG. 5

Coronal CT scan showing the characteristic lobulated outline of inverted papilloma demonstrated in the maxillary antrum.

opening, an inverted papilloma or an antro-nasal polyp are the two most likely diagnoses. The mean age at presentation may be helpful in differentiating them, inverted papilloma occurring more commonly in patients over 40 years and antro-choanal polyp in a younger age group. At a stage in the development of squamous cell carcinoma and with other naso-sinus tumours, similar appearances may arise, although there is usually more widespread bone destruction on initial examination of patients with primary sinus malignancy. Fungus infection may also present as an antro-nasal mass and must be considered in the differential diagnosis. High attenuation on CT is a common feature of allergic fungal rhinosinusitis (AFRS) but is most often diffuse and unlike the linear, curvilinear or plaque-like calcification seen in inverted papilloma.⁶ Only one patient in the series under review showed diffuse high attenuation in the maxillary antrum and this was accompanied by increased density and deformity of the bony wall in contrast to the bone erosion typical of AFRS.⁷ Sclerosis of the sinus walls is a non-specific change, most frequently seen in chronic sinus infection. However, the new bone formation in these patients is distributed evenly along the sinus walls without deformation. The combination of bone deformity and sclerosis suggests a slow growing tumour such as inverted papilloma.

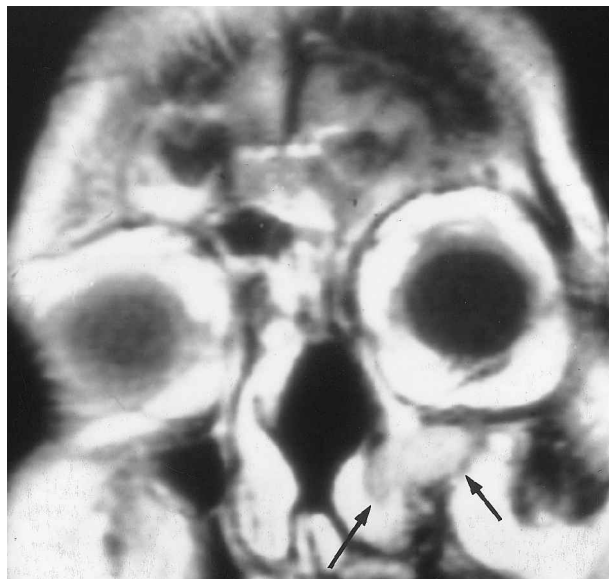


FIG. 6

Post-gadolinium T1-weighted MRI scan showing the extent of recurrent inverted papilloma, outlined against the strongly enhancing normal mucosa (arrows).

References

- 1 Harrison DFN, Lund VJ. *Tumours of the Upper Jaw*. Edinburgh, London: Churchill Livingstone, 1993
- 2 Dammann F, Peira P, Laniado M, Plimkert P, Lowenheim H, Claussen CD. Inverted papilloma of the nasal cavity and the paranasal sinuses. *Am J Roentgenol* 1999;**172**:543-6
- 3 Lund VJ. Optimum management of inverted papilloma. *J Laryngol Otol* 2000;**114**:194-7
- 4 Yousem DM, Fellows DW, Kennedy DW, Bolger WE, Haskings H, Zinreich SJ. Inverted papilloma: evaluation with MR imaging. *Radiology* 1992;**50**:472-5
- 5 Roobottom CA, Jewell FM, Kabala J. Primary and recurrent inverting papilloma: appearances with magnetic resonance imaging. *Clin Radiol* 1995;**50**:472-5
- 6 Lund VJ, Lloyd GAS. Radiological changes associated with inverted papilloma of the nose and paranasal sinuses. *Br J Radiol* 1984;**57**:455-61
- 7 Lund VJ, Lloyd G, Savy L, Howard D. Fungal rhinosinusitis. *J Laryngol Otol* 2000;**114**:76-80

Address for correspondence:
 Professor V. J. Lund,
 Institute of Laryngology and Otolaryngology,
 University College London,
 330 Gray's Inn Road,
 London WC1X 8DA, UK.

Fax: +44 (0)20 7 833 9480