

Intracranial volume measurement: A systematic review and comparison of different techniques

R.William.F. Breakey MBBS BSc MRCS, Paul G.M. Knoops MSc, Alessandro Borghi MEng PhD, Naiara Rodriguez-Florez MEng PhD, David J. Dunaway FDSRCS FRCS(Plast), Silvia Schievano MEng PhD, N.U. Owase Jeelani MBA MPhil(Medical Law) FRCS(Neuro. Surg.)

UCL Great Ormond Street Institute of Child Health, London, United Kingdom & Craniofacial Unit, Great Ormond Street Hospital for Children, NHS Trust, London, United Kingdom

Corresponding Author

William Breakey

30 Guilford Street, WC1N 1EH, London, UK

[020 7242 9789](tel:02072429789)

William.breakey@ucl.ac.uk

Author Contributions

RWFB, PGMK, NUOJ and SS designed the study, contributed to data acquisition, analysis and interpretation before drafting the manuscript. AB, NRF, RH and DJD critically revised the manuscript.

Acknowledgements

This research was supported by Great Ormond Street Hospital Children's Charity through the FaceValue programme grant (no. 508857). The views expressed in this publication are those of the author(s) and not necessarily those of the NHS, the National Institute for Health Research or the Department of Health.

Intracranial volume measurement: A systematic review and comparison of different techniques

R.William.F. Breakey MBBS BSc MRCS, Paul G.M. Knoops MSc, Alessandro Borghi MEng PhD, Naiara Rodriguez-Florez MEng PhD, David J. Dunaway FDSRCS FRCS(Plast), Silvia Schievano MEng PhD, N.U. Owase Jeelani MBA MPhil(Medical Law) FRCS(Neuro. Surg.)

UCL Great Ormond Street Institute of Child Health, London, United Kingdom & Craniofacial Unit, Great Ormond Street Hospital for Children, NHS Trust, London, United Kingdom

Corresponding Author

William Breakey

UCL Great Ormond Street Institute of Child Health

30 Guilford Street, WC1N 1EH, London, UK

[020 7242 9789](tel:02072429789)

William.breakey@ucl.ac.uk

Author Contributions

RWFB, PGMK, NUOJ and SS designed the study, contributed to data acquisition, analysis and interpretation before drafting the manuscript. AB, NRF, RH and DJD critically revised the manuscript.

Acknowledgements

This research was supported by Great Ormond Street Hospital Children's Charity through the FaceValue programme grant (no. 508857). This report incorporates independent research from the National Institute for Health Research Biomedical Research Centre Funding Scheme. The views expressed in this publication are those of the authors and not necessarily those of the NHS, the National Institute for Health Research or the Department of Health.

Abstract

The ability to calculate intracranial volume (ICV) from 3-dimensional imaging is a useful tool in a craniofacial team's armamentarium. ICV uses range from decision making to assessment. Various methods to calculate ICV exist including fully manual, semi-automatic and fully automatic techniques and they are used with varying frequency in craniofacial centres globally.

This study aimed to systematically analyse and compare ICV calculations across the three methods and provide information to allow the reader to utilise these processes in practice. 26 CT scans from Apert patients were used to compare ICV measurements calculated using the following techniques: fully manual segmentation with OsiriX (taken as the gold standard); semi-automatic segmentation using Simpleware Scan IP; and fully automatic segmentation using FSL neuroimaging software. In addition, to assess the effect that a reducing CT scan slice number had on ICV measurement, 13 scans were re-measured using half, quarter and an eighth of the slices of the full scan.

The manual and semi-automatic techniques had intraclass correlation coefficients (ICC) of 0.997, and 0.993 respectively. ICV measurements using the semi- and fully automatic techniques showed high linear correlation with manual techniques ($R^2=0.993$ and $R^2=0.995$). The coefficient of determination for full scan versus half, quarter and eighth scan were $R^2 = 0.98$, 0.96 , and 0.94 respectively.

Similar ICV results can be obtained using manual, semi-automatic or automatic techniques with decreasing amount of time required to perform each method. Command line code for the fully automatic method is provided.

Introduction

Computed tomography (CT) and magnetic resonance (MR) imaging allow for accurate measurement of intracranial volume (ICV) (1,2). This information can be used by craniofacial teams to analyse and formulate treatment strategies for patients, to better understand pathologies of intracranial pressure (ICP) disturbances and to quantify the operative change in volume achieved by craniofacial surgeries, such as vault expansion (3). ICV measurement is performed through a process of segmentation and image processing, which can be done manually or automatically on contiguous head image stacks. Manual segmentation involves outlining the intracranial area within each slice throughout the image stack, from the foramen magnum to the vertex. Semi-automatic techniques require thresholding of Hounsfield Units (HU) and region growing, whilst fully automatic techniques involve thresholding and brain extraction techniques to allow automatic calculation of ICV (4,5). Fully automatic techniques have been extensively investigated in MR studies (6) and only recently in CT imaging (5). Each technique has advantages and disadvantages and there are commercial and freeware options available for all. In the context of craniosynostosis, there is currently no standardised protocol for ICV measurements. A systematic literature search of material published by craniofacial centres worldwide showed that fully automatic methods of ICV measurement have not been adopted, with the majority of craniofacial units preferring semi-automatic techniques (Table 1).

The purpose of this study was to compare manual, semi-automatic and fully-automatic segmentation techniques for ICV measurement from CT images. The manual technique was assumed as the gold standard, presuming that the clinician provides expert outlining of the

intracranial cavity. A semi-automatic technique was tested, as it is the mainstay of most centres measuring ICV. Finally, a fully-automatic method was assessed considering its potential as a time saving and non-biased technique, which to our knowledge as of yet has not been applied to patients with craniosynostosis.

Methods

Systematic Review

A systematic literature search using the PubMed database was undertaken to delineate the various methods of intracranial volume measurement published from the various craniofacial centres worldwide. Search was restricted to those papers published between 1996 and 2016, using a search string of "Craniosynostoses"[Majr] AND "intracranial" AND "volume", which resulted in 86 papers.

Studies were required to: 1) have used an imaging modality that provided views of the intracranial vault; 2) use human subjects; 3) provide an explanation of their method of volume calculation; 4) measure the entire intracranial vault; and 5) provide actual 3D volume measurements, not mathematical estimations based on elliptical volumes.

Patient population and intracranial volume measurements

Pre- and post-operative CT images from 13 Apert patients (9 male, 4 female, average age at operation = 9.5 months range 3.6 – 16.1) who underwent spring assisted posterior vault expansion (PVE) at Great Ormond Street Hospital for Children, London, UK (7) between 2008 and 2014 and had full data sets were retrospectively considered for this study. This cohort was selected as Apert patients present complex skull bone distribution and, with the pre- and post-vault expansion data, a wide variation of head volumes was captured. In addition, in these patients, the full head volume, from foramen magnum to vertex, was included in the CT scan and the images did not present obstructive artefacts caused by the springs. The scans had a constant slice thickness of 1mm.

All measurements on the 26 scans were performed by the same operator using the following techniques:

- 1) Fully manual segmentation with the freely downloadable OsiriX software (OsiriX v4.1, Pixemo; Geneva, Switzerland), running on a MacBook with Mac OS X 10.6.8 (Apple Computer, Inc., Cupertino, CA, U.S.A).

DICOM (Digital Imaging and Communications in Medicine) images were loaded into OsiriX and windowed in the OsiriX derived bone window level and width (8). The inferior extreme of the foramen magnum was chosen as the most inferior plane between the clivus and the occipital bone (9). The bone-brain interface, identifiable by the tonal change in the images, was manually outlined in each of the contiguous CT axial sections using a digital pen (Wacom Bamboo, Kazo, Japan) and the OsiriX pencil tool to create the region of interest (ROI) on each slice, from foramen magnum to vertex. At the end of the segmentation process all ROI were grouped and the volume was computed by OsiriX as the sum of the contained voxels (8). (Figure 1)

- 2) Semi-automatic segmentation using the commercial software Simpleware Scan IP (Simpleware Ltd., Exeter, UK), running on 64-bit Operating System with Intel Xeon CPU E3-1270 and Windows 7 Enterprise, Service Pack 1 (Microsoft Corporation).

DICOM images were loaded into Simpleware and subsequently rotated and cropped to include foramen magnum to vertex. The image threshold was set at -55HU to 117HU for all scans, similar to others published in the literature (10); these parameters were found visually to provide the most useful soft tissue range for the first mask, highlighting the region of interest to be created. Intracranial contents were separated from the surrounding tissues using a region growing operation (known as 'flood fill' in

Simpleware); here the software fills in connected regions of the mask using a seed point and the given threshold. After this, the spill of the mask from the skull base foramina was assessed, and initially corrected through a series of open and close morphological operations. Any remaining spill that could not be solved using the morphological operations was removed manually by closing the remaining cranial defects. This produced a final mask that best filled the intracranial cavity across axial, sagittal and coronal views. The volume of this mask was calculated, based on mask statistics in Simpleware, using the voxel information within the mask. (Figure 1)

- 3) Fully automatic method with FSL neuroimaging software (Analysis Group, FMRIB, Oxford, UK), freely available, running on MacBook Pro 2 GHz Intel Core i5 with macOS Sierra 10.12.1 (Apple Computer, Inc., Cupertino, CA, U.S.A).

DICOM images were converted to the Neuroimaging Informatics Technology Initiative (NIfTI) format using ITK-SNAP (11). An example bash script for the initial FSL command-line (FSL_Muschelli) can be downloaded from http://bit.ly/CTBET_BASH (5). According to the description in Muschelli et al. (5), the following process was undertaken for each scan: images were thresholded using a range of 0 to 100HU and then smoothed using a 3 dimensional Gaussian Kernel ($\sigma = 1\text{mm}^3$). These settings have been shown to increase performance of the automatic measurement algorithm (5). Brain extraction technique (BET) was applied using a set fractional intensity (FI) parameter, which determines the edge of the extraction (12). FI values lie between 0 and 1 with smaller values providing larger volumes (13). Following BET, holes were filled using the 'fill holes' command, a mask was created and the volume measured. When using the automatic method, two main variables – the degree of Gaussian smoothing applied to the image and the FI at

which the brain is extracted – influence the result. These variables were assessed by altering the FI parameter in a step-wise manner from 0.01 to 0.99 with a constant smoothing setting of 1 and vice-versa altering the smoothing from 0.1 to 1 with the FI set at 0.01.(5) Through a refinement process, the the command line was changed (FSL_Altered) to use initial threshold levels of 5-100HU, include re-thresholding of the images at 5-100 HU after smoothing, and a different pipeline order (Figure 2). An example bash script for the FSL_Altered command-line can be downloaded from <http://bit.ly/2cCEBlu>

Observer reliability was assessed in all post-operative scans by calculating volumes three times when using the manual and semi-automatic techniques. The average values between these repeated measurements were used for the comparison between methods.

In addition, considering that in the past CT scanners often acquired information with larger slice thicknesses and that old CT scan repositories only hold a fraction of the full number of slices, the CT slice number of each post-operative scan was reduced in order to provide an indication of the number of slices required to obtain clinically accurate volume measurements. Thus, half, quarter, and an eighth of the original amount of slices were re-measured to calculate ICV using the semi-automatic technique.

An average time to perform the segmentation and extract ICV with each method was estimated as an important factor in assessing the quality of each technique.

Data analysis

Data analysis was performed using R statistical software (v. 3.2.5, R Foundation for Statistical Computing, Vienna, Austria). The coefficient of determination (R^2) and Bland-Altman plots were used to assess the relationships between manual, semi-automatic and fully automatic techniques (with the initial and altered scripts), and the influence of the numbers of CT slices. When assessing intra-observer reliability, the interclass correlation (ICC) was performed and root mean squared error (RMSE) and maximum error were calculated as percentages between each measurement and the average of three measurements.

Results

Systematic Review

Twenty-nine studies from 14 centres met the inclusion criteria for the analysis (Table 1): all but one utilised a semi-automatic method of ICV calculation. This was done through a mixture of proprietary, paid for and free software. One study used the fully manual method in OsiriX (14).

Intracranial volume measurements

All twenty six scans were measured using the manual and semi-automatic technique. The fully-automatic technique provided ICV measurement for only 12 scans using the first pipeline (FSL_Muschelli, Figure 2A), but managed to complete the analysis for all scans with the altered script (FSL_Altered, Figure 2B). Volume measurements for all patients across all techniques are shown in Table 2. The manual technique had an ICC of 0.997 (RMSE: 1.27%, maximum error: 3.82%). The semi-automatic technique had an ICC of 0.993 (RMSE: 2.02%, maximum error: 5.32%). Altering the FI and smoothing parameters in the fully automatic technique gave a volume range of 336.6–6673.4 cm³ and 1112.1–3629.2 cm³ respectively (Table 3).

All volume measurements, manual against semi-automatic (OsiriX against Simpleware) and manual against automatic (OsiriX against FSL_Muschelli) were found to show high linear correlation ($R^2=0.993$ and $R^2=0.995$ respectively) (Figure 3 A-B). This was also true for fully automatic method with the altered command line (OsiriX against FSL Altered)($R^2=0.978$) (Figure 3C). The limits of agreement were similar for Simpleware and FSL_Muschelli (Figure

4D-E): mean difference and 95% confidence intervals (CI) for Simpleware was 11.1 cm^3 (95%CI: $-42.5; 64.7 \text{ cm}^3$) and for FSL_Muschelli was -2.2 cm^3 (95%CI: $-51.5; 47.0 \text{ cm}^3$). However, for FSL Altered (Figure 4F), a larger positive bias was found with a mean difference of -82.0 cm^3 (95%CI: $-177.3; 13.2 \text{ cm}^3$).

In terms of time spent to perform the segmentation and extract ICV, the manual technique took around 40 minutes per scan, the semi-automatic technique, approximately 20 minutes, and the fully-automatic method 2 minutes.

The coefficient of determination for full scan versus half scan, full scan versus quarter scan and full scan versus eighth scan analysed with the semi-automatic method were $R^2 = 0.98$, 0.96 and 0.94 , respectively (Figure 4A-C). However, the limits of agreement increased with a decreasing number of slices (Figure 4D-F): mean difference and 95%CI for full versus half were -9.9 cm^3 (95%CI: $-77.3; 57.4 \text{ cm}^3$), full versus quarter 2.6 cm^3 (95%CI: $-81.5; 86.8 \text{ cm}^3$), and full versus eighth -5.8 cm^3 (95%CI: $-113.4; 101.9 \text{ cm}^3$).

Discussion

Accurate measurement of intracranial volume (ICV) is useful in many settings:

anthropometrically it can be used to provide normative data on skull vault volumes and in neurology it can be used in conjunction with measures of brain volume to assess disease

driven volumetric changes.(1,15) To the craniofacial surgeon it provides information for

devising management paradigms, for pre-operative planning and for post-operative

evaluation of surgical outcomes, allowing for quantifiable, objective measurements to be

made. The post-operative evaluation of outcomes poses several problems; many units

include ours do not have a standard post-operative CT scanning protocol and it would be

unethical to expose patients to radiation solely for evaluation. It is however a possibility that

a patient with craniosynostosis will require a further CT scan later in their patient timeline.

We are working towards building intracranial volume growth curves for syndromic

craniosynostoses, which will allow for post-operative CT scans, taken at random time points

to be normalised for allometric growth and used for operative evaluation. Suggested

alternatives to CT measured ICV are the occipito-frontal circumference (OFC) and the cranial

index (CI) as a predictor of ICV.(9,10) Of these two methods the OFC holds more promise.

Rijken and colleagues directly compared OFC and ICV in a variety of syndromic

craniosynostoses at a total of 84 time points and found there to be a significant correlation.

Therefore, suggesting use of OFC as a useful screening tool.(9) Conversely Leikola et al.

found CI to be a poor correlate for intracranial volume in scaphocephalic patients.(10) We

are working on a large series of ICV and OFC correlations to be published in due course.

Data driven evaluations are important in a time of rapid innovation of surgical techniques. In

the current study, manual, semi-automatic and fully-automatic techniques to calculate ICV in craniosynostotic Apert patients were systematically compared.

Since Gault's early work on the study of ICV from CT scans and then application of this technique to Apert syndrome by Gosain et al., many authors have investigated this objective measure.(16–18) The results presented in this study suggest that different methods available to the craniofacial investigator give broadly similar results. Despite the considered cohort was made up by complex Apert patients, each technique has been shown to manage volume extraction in both small paediatric skulls and enlarged post-operative skulls, which often contained bone holes due to the disease, and in some cases cranial vault springs due to the surgical vault expansion.

The use of different image post-processing techniques to manipulate and analyse CT data to provide ICV calculation in the setting of craniosynostosis has been shown here to give significantly similar results. The limits of agreement were similar for both manual and semi-automatic, and manual and fully automatic when using the Muschelli technique. When using the fully automatic method with the altered command line there was a positive bias, with uniformly higher values generated by the fully automatic method.

Manual and semi-automatic techniques provide varying degrees of user control whilst a fully automatic technique performs ICV calculation through command line instructions alone. There remains an inherent degree of human control in this technique, manifest through the values chosen for fractional intensity and Gaussian smoothing.

A fully manual technique provides the user with a high degree of control. Using a digital pen, the outline of the intracranial cavity can be accurately traced from foramen magnum to vertex. However, this technique is time costly, which may limit the size of the studies in which it can be used. It is noted that the OsiriX software is free to download and this technique should be reproducible in other craniofacial centres. This study was used to calculate the volume of the entire cranial vault. Due to the size of the measured space the manual method is time consuming. This technique may become more useful when measuring smaller objects such as intracerebral lesions or specific spaces such as cerebral ventricles or orbital volumes.

The semi-automated technique utilises thresholding and region growing to segment the intracranial contents from the skull. This technique, whilst not providing the same control as the fully automated method does offer other advantages. It is possible to manipulate the images in 3D and have a constantly updated 3D visual of the extraction. (Figure 1) Alongside the 3D visualisation of the intracranial vault extraction, it is possible to produce and view segmentations of the various components of the head in general. This allows for investigation of dead spaces, cerebrospinal fluid (CSF) spaces and other areas discernible on a CT scan. With practice, this technique is less time consuming than the fully manual technique. Whilst Simpleware Scan IP is commercial software, there are other programs freely available such as 3D Slicer (<http://slicer.org>) and ITK snap (<http://www.itksnap.org/>) that allow for similar operations to be performed on the images.

A fully automated technique is not a panacea. It requires a rudimentary knowledge of command line programming, and the user has less control over the results. In our first

attempt, fourteen of the twenty six scans failed to extract. This gave a failure rate of 53.8%, which compares unfavourably to Muschelli's failure rate of 5.2% (5). We hypothesise that this failure was in part caused by the presence of cranioplasty springs in some of the post-operative scans as, in nine of the failed scans, springs were still in situ. In the scans that were successful, there remained a scattering of holes in the mask, which were not filled by the fill holes command (figure 5). This led to marginally lower ICV values when compared to the manual method. The altered command line gave a 100% success rate, however the ICV values were uniformly larger than those from the manual and semi-automatic methods. This was due to the mask overlaying the skull in parts, leading to a larger mask and therefore a larger volume (Figure 5).

The fully automatic method has the advantage of being faster to use, the speed of which could be advantageous when programming entire cohorts to undergo the same pipeline at once. This would however require knowledge of the scripting process, not always available in every unit. In addition, this method removes user dependency, in that by running one pipeline of commands for every study image, unbiased results can be obtained. Obtaining uniformly larger volume results may not be problematic depending on the intended use of the tool. For example, when comparing pre- and post-operative volume change, or calculating ICV in a large cohort using the fully automatic method will give rapid, unbiased results.

The comparison of CT scans with full, half, quarter and an eighth number of slices analysed using the semi-automatic method has shown that the linear relationship between full and an eighth of the number of slices remains high, but that the limits of agreement increase

with a decreasing number of slices. We postulate this is due to the uniformity in calvarial shape and the averaging effect. The number of slices in the 'eighth category' ranged from x to x slices and our analysis shows these number or slices may be utilised to provide a meaningful result with good concordance to the 1mm slice thickness volumetric data.

Whilst correlations between measurements have been provided and show good agreement, we would recommend that where possible one technique is used throughout, to ensure the highest accuracy. This would be especially important when calculating the volumes of smaller spaces or objects.

Conclusion

When measuring intracranial volume (ICV) in craniosynostosis the most commonly used method reported in the literature is a semi-automatic one. Similar results can be obtained using manual, semi-automatic or automatic techniques with decreasing amount of time taken to perform each method. Command line instructions have been provided to perform automatic ICV calculations from CT data.

Conflict of Interest

None.

References

1. Kamdar MR, Gomez RA, Ascherman J a. Intracranial volumes in a large series of healthy children. *Plast Reconstr Surg* [Internet]. 2009;124(6):2072–5. Available from: <http://www.ncbi.nlm.nih.gov/pubmed/19952664>
2. Sgouros S, Hockley a D, Goldin JH, Wake MJ, Natarajan K. Intracranial volume change in craniosynostosis. *J Neurosurg*. 1999;91:617–25.
3. Abbott A, Netherway D, Niemann D, Clark B, Yamamoto M, Cole J, et al. CT Determined Intracranial Volume for a Normal Population. *Journal of craniofacial Surgery*. 2000. p. 211–23.
4. De Jong T, Rijken BFM, Lequin MH, Van Veelen MLC, Mathijssen IMJ. Brain and ventricular volume in patients with syndromic and complex craniosynostosis. *Child's Nerv Syst*. 2012;28(1):137–40.
5. Muschelli J, Ullman NL, Mould WA, Vespa P, Hanley DF, Crainiceanu CM. Validated automatic brain extraction of head CT images. *Neuroimage* [Internet]. Elsevier Inc.; 2015;114:379–85. Available from: <http://dx.doi.org/10.1016/j.neuroimage.2015.03.074>
6. Wang Y, Nie J, Yap PT, Li G, Shi F, Geng X, et al. Knowledge-guided robust MRI brain extraction for diverse large-scale neuroimaging studies on humans and non-human primates. *PLoS One*. 2014;9(1):1–23.
7. De Jong T, Van Veelen MLC, Mathijssen IMJ. Spring-assisted posterior vault expansion in multisuture craniosynostosis. *Child's Nerv Syst*. 2013;29:815–20.
8. Scolozzi P, Jaques B. Computer-aided volume measurement of posttraumatic orbits reconstructed with AO titanium mesh plates: accuracy and reliability. *Ophthal Plast Reconstr Surg* [Internet]. 2008;24(5):383–9. Available from:

<http://www.ncbi.nlm.nih.gov/pubmed/18806660>

9. Francisca B, Rijken M, Ottelander BK Den, Veelen MC Van, Lequin MH, Margreet I, et al. The occipitofrontal circumference: reliable prediction of the intracranial volume in children with syndromic and complex craniosynostosis. 2015;38(May):1–6.
10. Leikola J, Koljonen V, Heliövaara A, Hukki J, Koivikko M. Cephalic index correlates poorly with intracranial volume in non-syndromic scaphocephalic patients. *Child's Nerv Syst.* 2014;30(12):2097–102.
11. Yushkevich PA, Piven J, Hazlett HC, Smith RG, Ho S, Gee JC, et al. User-guided 3D active contour segmentation of anatomical structures: Significantly improved efficiency and reliability. *Neuroimage.* 2006;31(3):1116–28.
12. Rorden C, Bonilha L, Fridriksson J, Bender B, Karnath HO. Age-specific CT and MRI templates for spatial normalization. *Neuroimage.* 2012;61(4):957–65.
13. Smith SM. Fast robust automated brain extraction. *Hum Brain Mapp.* 2002;17(3):143–55.
14. Nowinski D, Di Rocco F, Renier D, Sainterose C, Leikola J, Arnaud E. Posterior cranial vault expansion in the treatment of craniosynostosis. Comparison of current techniques. *Child's Nerv Syst.* 2012;28:1537–44.
15. Dinomais M, Celle S, Duval GT, Roche F, Henni S, Bartha R, et al. Anatomic Correlation of the Mini-Mental State Examination: A Voxel-Based Morphometric Study in Older Adults. *PLoS One [Internet].* 2016;11(10):e0162889. Available from: <http://www.ncbi.nlm.nih.gov/pubmed/27741236>
16. Gault D, Brunelle F, Renier D, Marchac D. The calculation of intracranial volume using CT scans. *Childs Nerv Syst [Internet].* 1988;4(5):271–3. Available from: <http://www.ncbi.nlm.nih.gov/pubmed/3242796>

17. Gosain a K, McCarthy JG, Glatt P, Staffenberg D, Hoffmann RG. A study of intracranial volume in Apert syndrome. *Plastic and reconstructive surgery*. 1995. p. 284–95.
18. Anderson PJ, Netherway DJ, Abbott AH, Cox T, Roscioli T, David DJ. Analysis of intracranial volume in Apert syndrome genotypes. *Pediatr Neurosurg*. 2004;40(4):161–4.
19. Schulz M, Spors B, Haberl H, Thomale UW. Results of posterior cranial vault remodeling for plagiocephaly and brachycephaly by the meander technique. *Child's Nerv Syst*. 2014;30(9):1517–26.
20. Hill CA, Vaddi S, Moffitt A, Kane A, Marsh JL, J P, et al. Intracranial Volume and Whole Brain Volume in Infants With Unicoronal Craniosynostosis. *Cleft Palate Craniofac J*. 2011;48(4):394–8.
21. Derderian CA, Wink JD, McGrath JL, Collinsworth A, Bartlett SP, Taylor JA. Volumetric Changes in Cranial Vault Expansion. *Plast Reconstr Surg [Internet]*. 2015;135(6):1665–72. Available from: <http://www.ncbi.nlm.nih.gov/pubmed/25724062>
22. Heller JB, Heller MM, Knoll B, Gabbay JS, Duncan C, Persing J a. Intracranial volume and cephalic index outcomes for total calvarial reconstruction among nonsyndromic sagittal synostosis patients. *Plast Reconstr Surg*. 2008;121(1):187–95.
23. Fischer S, Maltese G, Tarnow P, Wikberg E, Bernhardt P, Tovetjärn R, et al. Intracranial volume is normal in infants with sagittal synostosis. *J Plast Surg Hand Surg*. 2015;49(1):62–4.
24. Ritvanen AG, De Oliveira ME, Koivikko MP, Hallila HO, Haaja JK, Koljonen VS, et al. Mesh-based method for measuring intracranial volume in patients with craniosynostosis. *Int J Comput Assist Radiol Surg*. 2013;8(5):703–9.
25. Deschamps-Braly J, Hettinger P, El Amm C, Denny AD. Volumetric analysis of cranial

vault distraction for cephalocranial disproportion. *Pediatr Neurosurg*.

2012;47(6):396–405.

26. Park DH, Chung J, Yoon SH. The role of distraction osteogenesis in children with secondary craniosynostosis after shunt operation in early infancy. *Pediatr Neurosurg*. 2010;45(6):437–45.

Legends

Figure 1. An example of the output of the three methodologies; OsiriX (A), Simpleware (B) and FSL (C).

Figure 2. An example of failed extraction using FSL_Muschelli pipeline in panel A (HU range = 0-100; $\sigma= 1$; FI = 0.01) and successful brain extraction using FSL_Altered in panels B(HU range = 5-100, $\sigma= 1$, FI = 0.35)

Figure 3. (A-C) Correlation of volume across different methodologies. Dashed line shows 1:1 correlation, solid line shows correlation between the two techniques **(D-F)** Bland Altman plots of comparisons. Dashed lines show 2SD from the mean, Solid line shows the mean

Figure 4. (A-C) Correlation of volume across slice number including full versus half scan, quarter scan and eighth scan. Dashed line shows 1:1 correlation, solid line shows correlation between the two techniques **(D-F)** Bland Altman plots showing decreasing agreement as slice number decreases. Dashed lines show 2SD from the mean, Solid line shows the mean

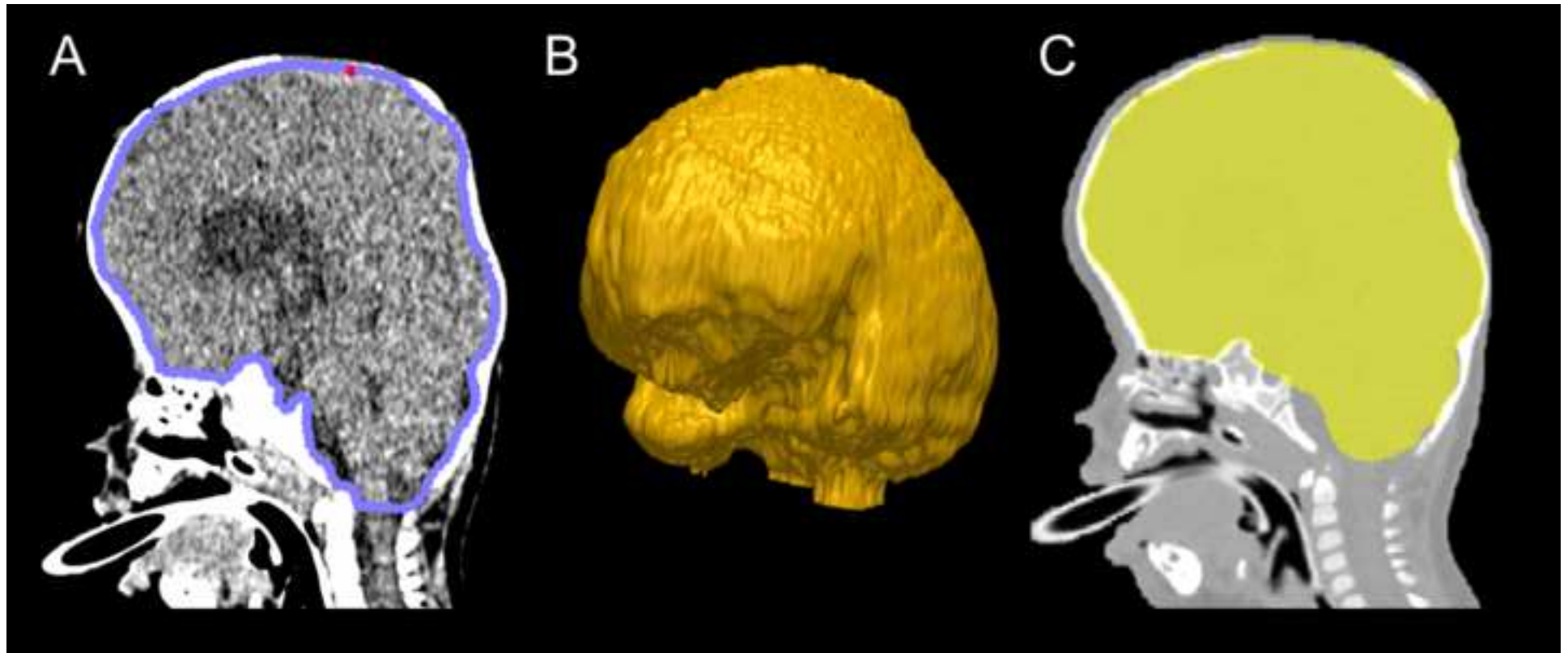
Figure 5. Example case showing FSL_Muschelli command line with a slight under estimation due to holes in the mask in panel A. Panel B shows an altered command line extraction (FSL Altered) in which there has been a slight over estimation in the volume. HU range = 0-100, 5-100; $\sigma= 1$; FI = 0.01, 0.35 respectively.

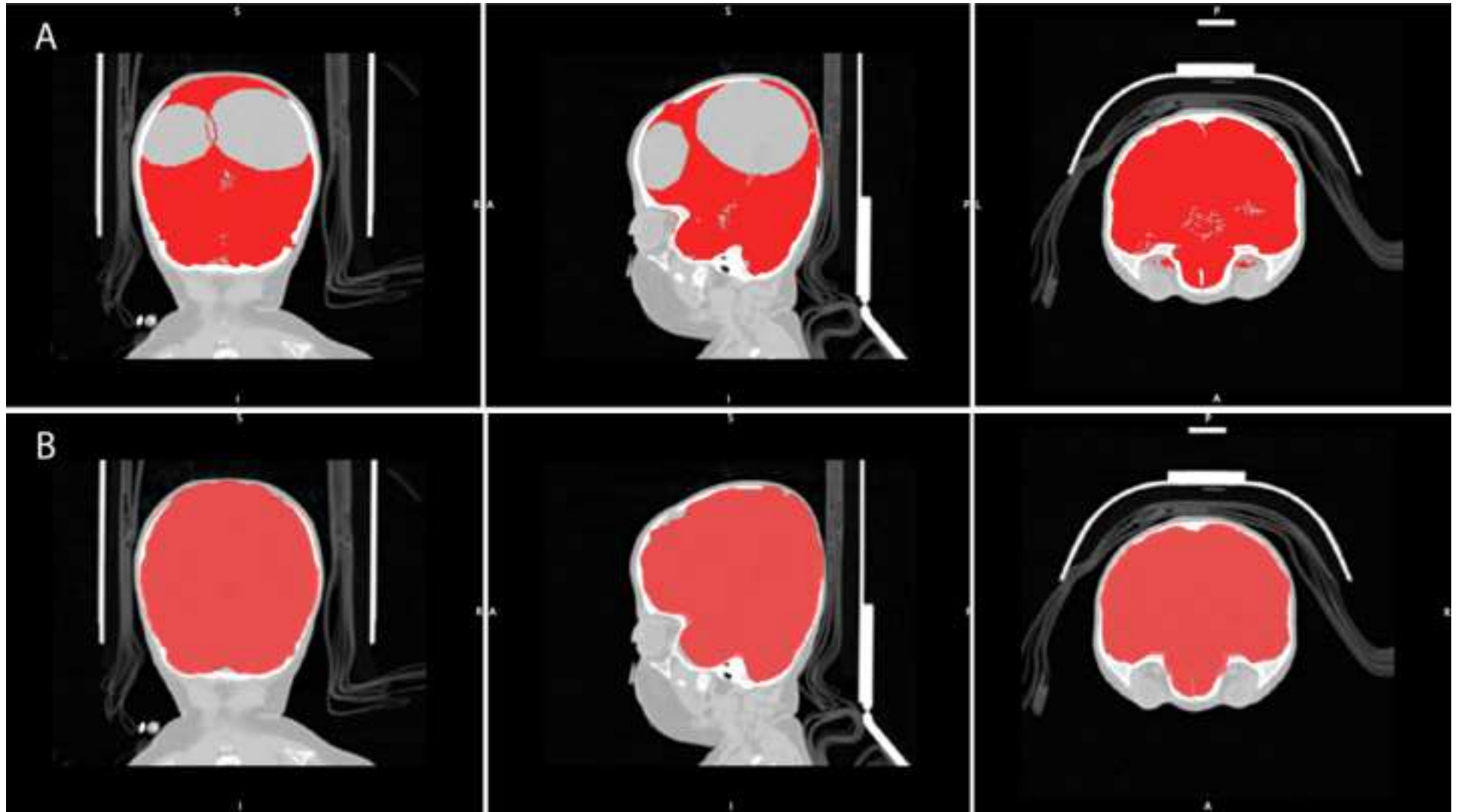
Tables

Table 1. Craniofacial centre and reported method (manual, semi-automatic or fully automatic) used to calculate intracranial volume (ICV) from magnetic resonance imaging or computed-tomography data.

Table 2. Calculated ICV (cm³) for all scans across all methodologies

Table 3. Differences in the measurement of intracranial volume (ICV) using the fully automatic technique with altered fractional intensity (FI) and Gaussian Smoothing (Smoothing) parameters.





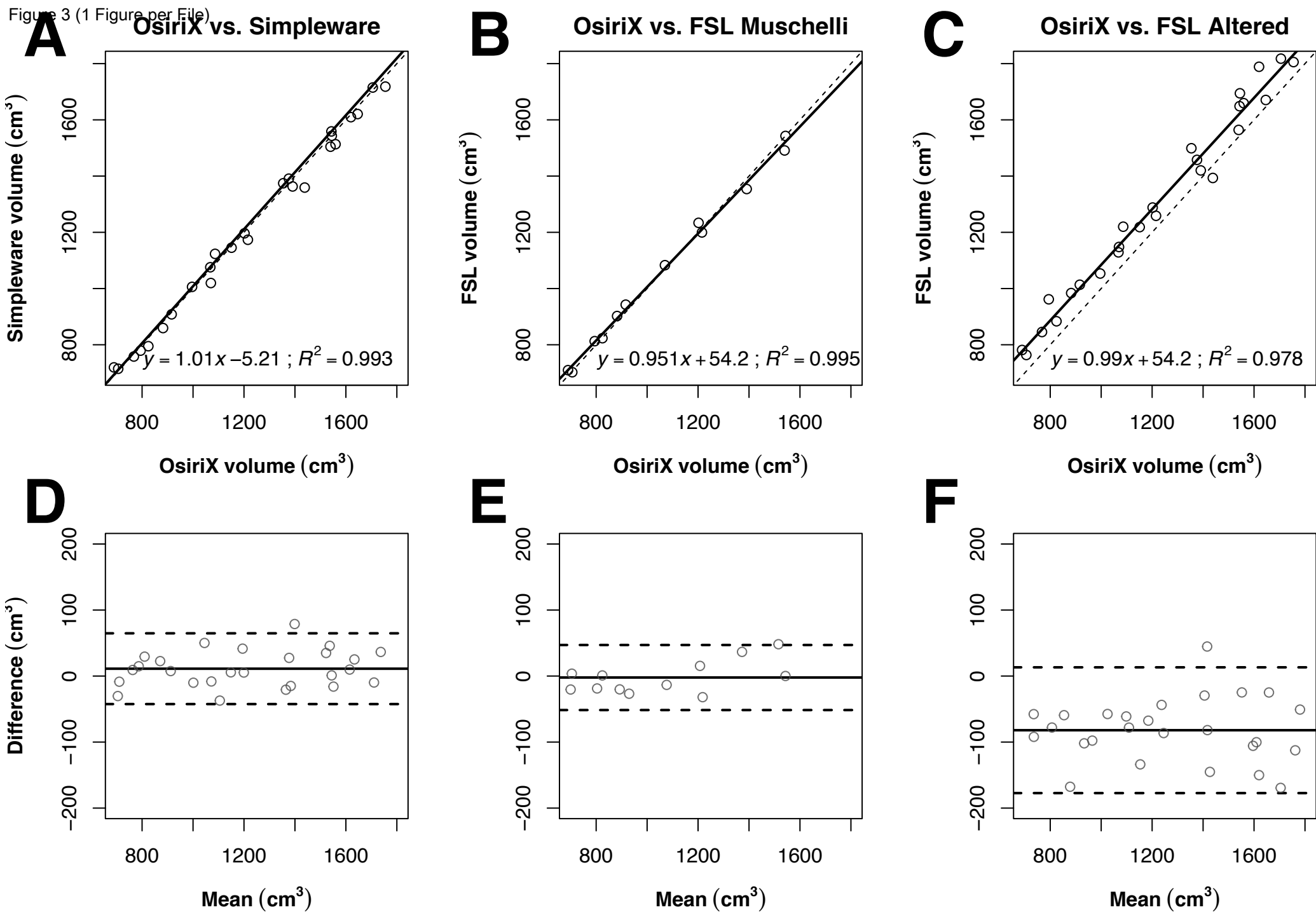
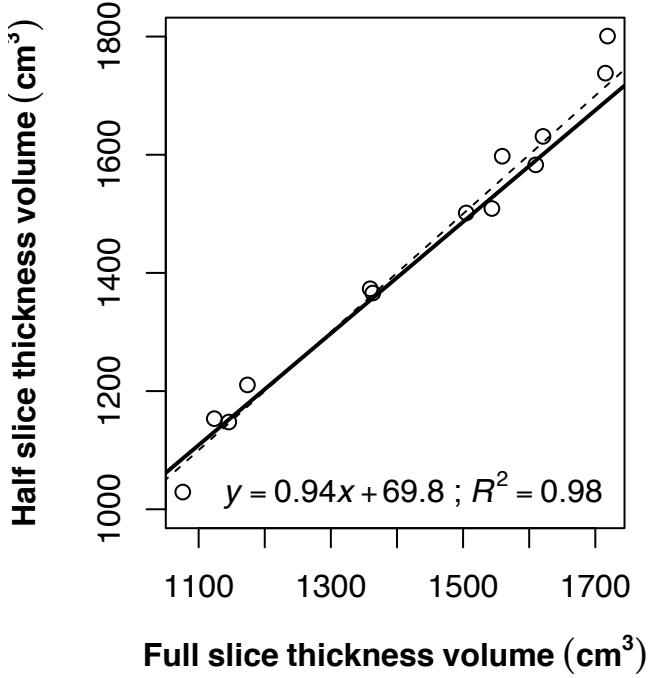
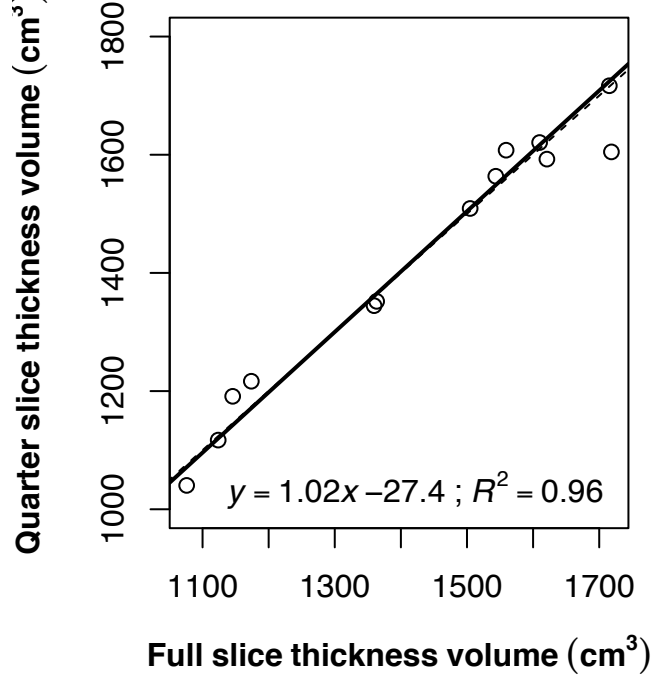


Figure 4 (1 Figure per File)

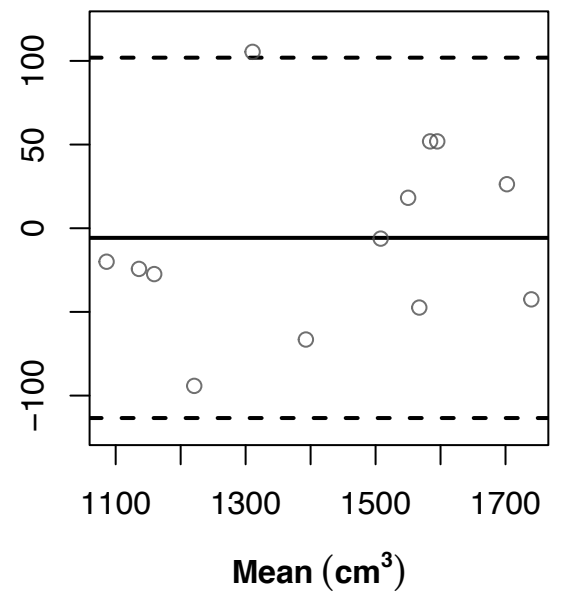
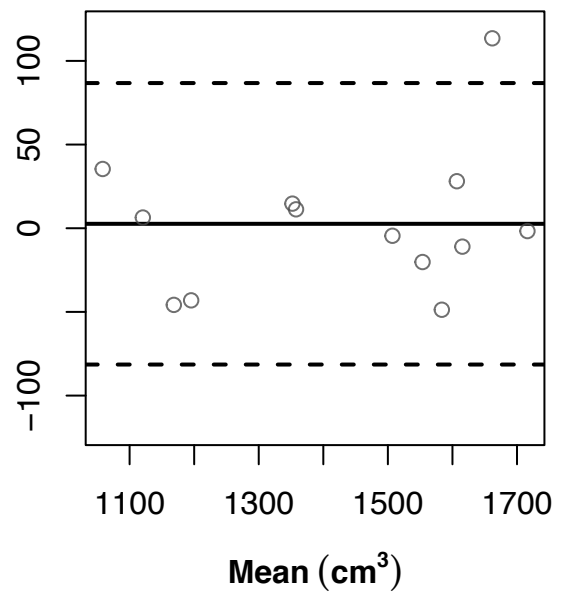
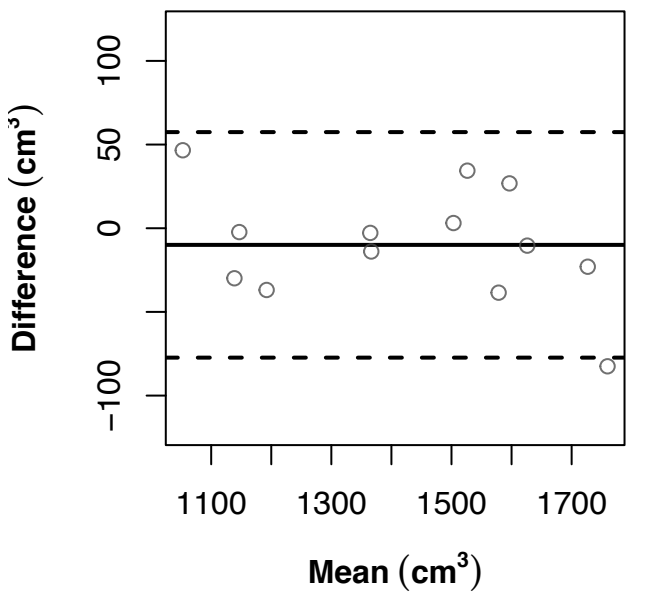
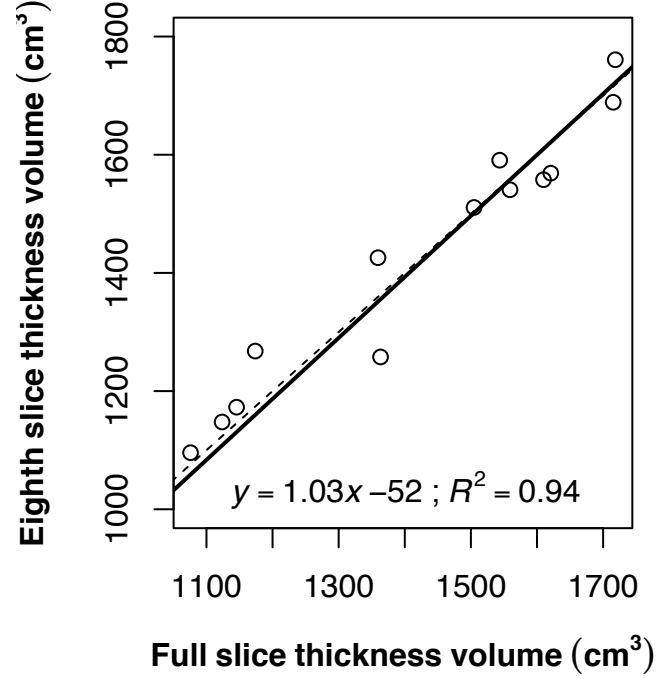
Full vs. half



Full vs. quarter



Full vs. eighth



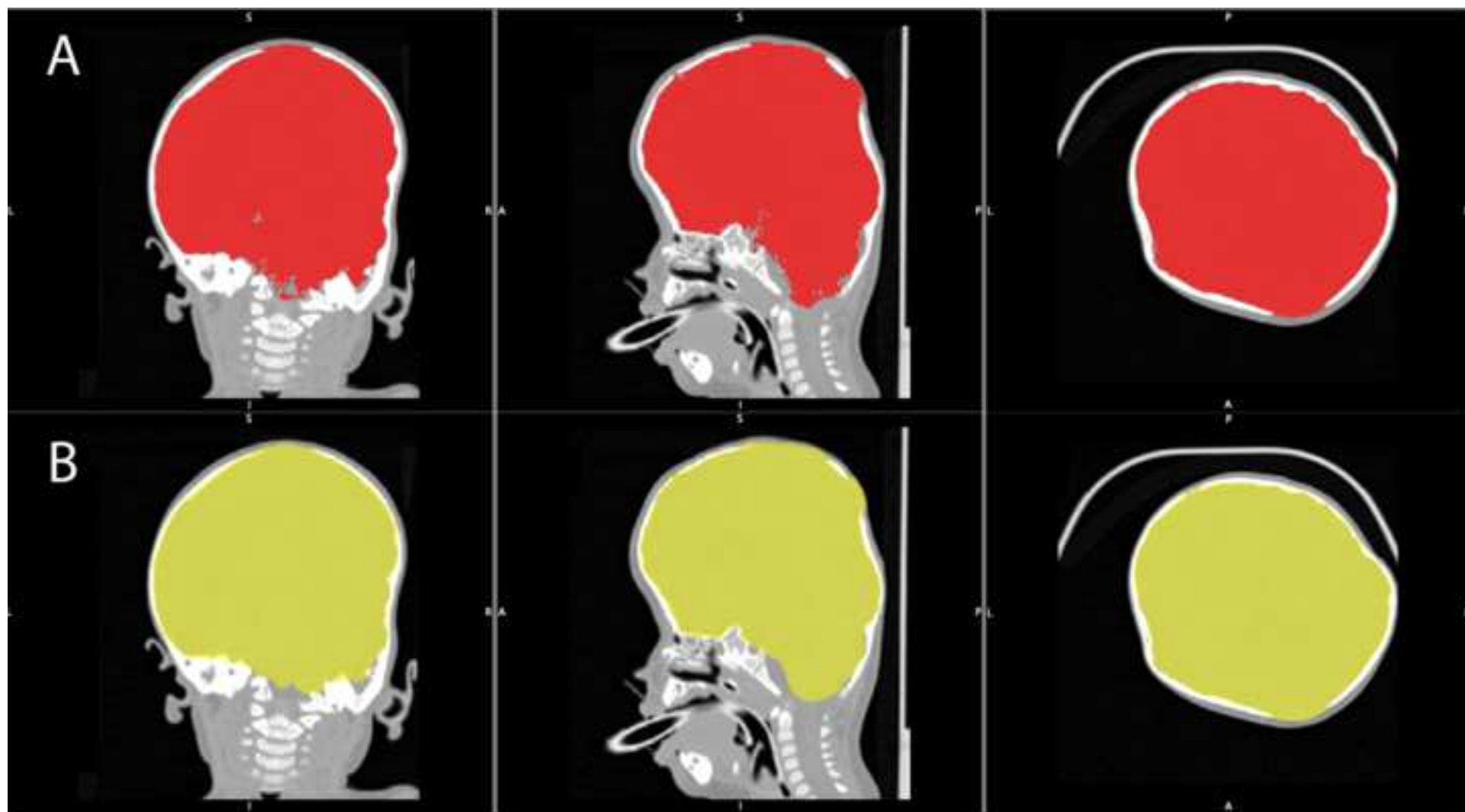


Table 1. Craniofacial centre and reported method (manual, semi-automatic or fully automatic) used to calculate intracranial volume (ICV) from magnetic resonance imaging or computed-tomography data.

Centre	Senior Author	Method	Program	Modality
Erasmus	Mathijssen. I (4)	Semi-automatic	Brainlab (BRAINLAB AG, Feldkirchen Germany)	MR
Berlin	Thomale. UW (20)	Semi-automatic	BrainLab (BRAINLAB AG, Feldkirchen Germany)	MR
Missouri	Aldridge. K (21)	Semi-automatic	Analyze 9.0 (AnalyzeDirect, Inc. KS, United States)	MR
CHOP	Taylor. J (22)	Semi-automatic	Mimics (Materialise, Leuven, Belgium)	CT
Australian Craniofacial Centre	David. D (3)	Semi-automatic	Proprietary	CT
Yale	Persing J.A (23)	Semi-automatic	Scion Image (Informer Technologies Inc.) / Image J (– National Institutes of Health)	CT
Gothenberg	Kolby. L (24)	Semi-automatic	MATLAB (MathWorks, MA, United States)	CT
Helsinki	Koivikko. M (10)	Semi-automatic	Volume Share 2 (– GE Healthcare)	CT
Helsinki	Paulasto-Krockel. M (25)	Semi-automatic	Proprietary	CT
Paris	Arnaud. E (14)	Manual	OsiriX (Pimexo, Bermex, Switzerland)	CT
Wisconsin	Denny. A.D (26)	Semi-automatic	Amira (FEI,)	CT
Seoul	Yoon.S.H (27)	Semi-automatic	Lucion (MEVISYS, Seoul, Korea)	CT

Columbia Med Centre Birmingham	Ascherman J.A (1)	Semi-automatic	Amira 3.0 (FEI,)	CT
Children's Hospital	Sgouros .S (2)	Semi-automatic	N/A	CT

Table 2. Calculated ICV (cm³) for all scans across all methodologies

Patient	OsiriX	Simpleware	FSL_Muschelli	FSL Altered
Pre-op				
1	1559.4	1513.6		1659.6
2	706.3	714.9	702.7	764.0
3	689.6	719.9	710	781.7
4	767.7	758.5		845.7
5.0	794.3	779.5	813.1	962.0
6.0	824.6	795.2	823.7	883.9
7.0	882.3	859.7	902.5	984.2
8.0	916.1	908.6	942.9	1013.9
9.0	996.2	1006.3		1053.7
10.0	1070.0	1019.9	1083.4	1148.1
11.0	1202.0	1196.7	1234	1288.4
12.0	1376.1	1391.1		1458.0
13.0	1354.1	1374.8		1499.3
Post-op				
1.0	1705.5	1715.3		1818.0
2.0	1543.2	1559.2	1543.1	1648.9
3.0	1086.5	1123.7		1220.3
4.0	1151.2	1145.6		1218.8
5.0	1619.7	1609.9		1789.1
6.0	1067.8	1076.0		1129.0
7.0	1215.3	1173.8	1199.9	1259.0
8.0	1544.6	1543.6		1694.7
9.0	1438.3	1359.5		1393.6
10.0	1390.9	1363.4	1354.3	1420.4
11.0	1539.7	1504.8	1491.5	1564.5
12.0	1646.1	1620.9		1671.0
13.0	1755.0	1718.5		1805.8

Table 3. Differences in the measurement of intracranial volume (ICV) using the fully automatic technique with altered fractional intensity (FI) and Gaussian Smoothing (Smoothing) parameters.

FI	ICV (CM³)	Smoothing	ICV (CM³)
0.01	1083.4	0.10	1112.1
0.05	1082.5	0.20	3629.2
0.10	1080.8	0.30	1069.2
0.15	1079.7	0.40	1068.7
0.20	1078.0	0.50	1083.4
0.25	1076.6	0.60	1083.4
0.35	1067.2	0.70	1083.5
0.50	6673.4	0.80	1083.7
0.75	1875.3	0.90	1083.6
0.99	366.6	1.00	1083.4