

BMJ Case Reports

Necrotizing granulomatous inflammation of the glans penis

Journal:	<i>BMJ Case Reports</i>
Manuscript ID	bcr-2016-216913.R1
Manuscript Type:	Rare disease
Date Submitted by the Author:	23-Jul-2016
Complete List of Authors:	Christodoulidou, Michelle; University College London Hospitals NHS Foundation Trust, Urology Bunker, Christopher; University College London Hospitals NHS Foundation Trust, Department of Dermatology Trevisan, Giorgia; University College London Hospitals NHS Foundation Trust Muneer, Asif; University College London Hospital, Urology
Keywords:	Dermatology, Urological surgery < Surgery

BMJ Case Reports

TITLE OF CASE

Necrotizing granulomatous inflammation of the glans penis

SUMMARY

We describe the case of a 73-year old male who presented with a 10-month history of an ulcerating lesion on the glans penis. Initially this was thought to be an invasive squamous cell carcinoma (SCC) but a biopsy showed histological features consistent with necrotizing granulomatous inflammation. Extensive serological, immunological and microbiological tests only showed a positive antinuclear (ANA) and perinuclear antineutrophil cytoplasmic antibodies (p-ANCA) indicating a possible autoimmune aetiology but an underlying systemic cause was not identified. Treatment with oral corticosteroids limited the inflammatory process but due to the gross destruction of the glans penis he still required a glansectomy and split-skin graft (SSG) reconstruction from which he recovered well.

Although this patient ultimately required surgery for this rare presentation, this case highlights the differential diagnosis of penile ulceration (that transcends neoplasia) and the importance of performing and interpreting penile biopsies before undertaking potentially mutilating definitive surgery.

BACKGROUND

Penile SCC is a rare cancer with reported incidence of 1 in 100 000 in most developed countries.[1] It can present as a fungating or ulcerating lesion on the foreskin or glans penis.[1] Other causes of penile ulceration include sexually acquired and non-sexually acquired infections, trauma and iatrogenic causes (e.g. injectable substance reaction such as paraffin or silicone), inflammatory disorders (such as lichen sclerosus and lichen planus, bullous dermatoses, sarcoid, vasculitis, pyoderma gangrenosum and drug eruptions) and neoplasms such as lymphoma, Kaposi's sarcoma and Langerhans cell histiocytosis. [2-10] Idiopathic inflammatory ulcerative lesions affecting the penis in isolation such as necrotizing granulomatous vasculitis or pyoderma gangrenosum are extremely rare and have been associated with systemic vasculitis and Crohn's disease.[11-23]

CASE PRESENTATION

A 73 year-old man presented with a 10-month history of a painful ulcerating lesion on the glans penis. He reported difficulty in voiding and urine was passing through a fistula formed by the ulceration of the lesion into the adjacent urethral meatus.

Eight months earlier he underwent a circumcision for presumed Zoon's balanitis as well as a biopsy of the ulcer. This biopsy only showed areas of inflammation. Although his circumcision scar healed well, there was still persistent and progressive ulceration at the site of the initial biopsy.

He had a past medical history of hypertension which was well controlled with ramipril and atenolol. He did not have any relevant family history.

On examination there was a necrotic, exudative ulcer on the ventral aspect of his glans penis with no palpable inguinal lymphadenopathy. (**Figure 1**)

BMJ Case Reports

DIFFERENTIAL DIAGNOSIS

In this case the differential diagnosis was felt to include penile SCC, pyoderma gangrenosum, atypical mycobacterial infection, syphilis, sarcoid, vasculitis and Crohn's disease. But the extended differential diagnosis considered all those entities listed above.

INVESTIGATIONS

The case was discussed at a regional penile cancer Multidisciplinary Team meeting (MDT) on several occasions with input from a specialist dermatologist. Computerised Tomography of the chest, abdomen and pelvis and Magnetic Resonance Imaging of the penis following Caverjet injection did not suggest an underlying malignancy, confirming an ulcerative lesion of the glans penis with no involvement of the corpus cavernosum. **(Figure 2)**

A biopsy performed under general anaesthesia showed a hyperplastic epithelium with reactive changes. The lamina propria consisted predominantly of granulation tissue and prominent necrotizing granulomatous inflammation as well as subepithelial band-like Zoonoid plasma cell inflammation, but with no evidence of atypia or malignancy. **(Figure 3 & 4)**

Additional stains for acid-fast bacilli, fungi and treponemal organisms were negative. Systemic investigations were normal including the white cell count and C-reactive protein. The erythrocyte sedimentation rate was mildly raised at 21 as well as the Immunoglobulin-A. Autoantibody screening showed positive ANA with a titre of 320, positive p-ANCA and swabs for bacteriology as well as syphilis serology were negative. Virology was negative for Herpes simplex virus (HSV), Cytomegalovirus, Human immunodeficiency virus (HIV) and Hepatitis B and C.

TREATMENT

Following MDT discussion he was treated empirically with oral prednisolone 30mg daily, oral antibiotics and oral antifungals.

Although the ulceration was arrested by systemic corticosteroid treatment there was no significant improvement of the glans penis. **(Figure 5)** As the glans penis had undergone ulceration and disfigurement, eventually a glansctomy followed by SSG reconstruction of the neoglans was performed in order to excise the diseased tissue for further tests, to provide a better cosmetic outcome and to allow voiding through a single urethral opening. **(Figure 6 & 7)**

Histological examination of the glansctomy specimen confirmed the previous findings. Special bacterial stains were negative as were the cultures for mycobacteria and fungi. The differential diagnosis of exclusion rested between focal granulomatous conditions such as sarcoidosis, Crohn's disease, vasculitis e.g. Wegener's and granulomatous pyoderma gangrenosum, so he was treated with on-going systemic steroids and oral antibiotics (to prevent secondary infection).

The patient recovered well from the procedure with no postoperative graft loss or wound infection and the neo-glans and donor site for the SSG had healed. Nine months following his glansctomy the steroids were finally stopped, the neo-glans appeared healthy and the patient remained well. **(Figure 8)** He did not report on any voiding difficulties such as urinary frequency, poor flow or spraying of the urinary stream and sexual function was recovered.

BMJ Case Reports

DISCUSSION

This case illustrates a rare presentation. The first issue is that of diagnosis; not all penile ulcers are cancers and screening tests for sexually transmitted diseases and a diagnostic biopsy are necessary in all suspicious penile lesions to exclude inflammatory and other benign conditions prior to radical treatment.

Benign isolated ulcerating lesions of the glans penis are rare and can be mistaken for a malignant condition such as SCC. [1] Here once a malignant lesion was excluded, the differential diagnoses of the necrotizing granulomatous inflammation was an infective or autoimmune cause or pyoderma gangrenosum.

The prior diagnosis of Zoon's plasma cell balanitis cannot be sustained by the history, signs and subsequent clinical events and histology. [2, 24, 25] Plasma cell balanitis was first described by Zoon in 1952. [2, 24, 25] It presents clinically with asymptomatic, well circumscribed symmetrical orange-red glazed patches and histologically shows a dense plasmacyte-rich subepidermal infiltrate. [2, 24, 25] In practice, Zoonoid inflammation is commonly seen in penile biopsies and can distract clinicians and histopathologists from the true underlying diagnosis, as is often the case with lichen sclerosus. [2, 24-26]

Necrotizing granulomatous inflammation of the glans has been associated with non-sexually transmitted infection with mycobacterium following Bacillus Calmette-Guérin installation for bladder cancer. [5-7] Tuberculosis of the penis is a rare pathology and diagnosis is established by the finding of granulomas histologically and mycobacteria following culture. [5-7] Lepromatous leprosy skin lesions of the penis are also related to acid-fast bacilli but are rarely isolated and usually present as multiple and widespread skin lesions. [8] Sexually acquired infections such as syphilis and HSV have been associated with ulcerative lesions of the glans penis and are more prevalent in patients with HIV or haematological malignancies. [2-4] However, extensive serological and tissue culturing for bacteria, fungi, mycobacteria, syphilis and sexually transmitted viruses did not identify an infective agent and no haematological malignancy was identified in our case.

Penile granulomata secondary to foreign body reaction following injection of paraffin oil and silicone are not uncommon in the literature. [2, 9, 10] These are used to augment the penis, however patients are rarely warned of adverse effects such as skin necrosis, penile deformity, granulomatous lymphoedema and the need for skin excision and grafting. [2, 9, 10] Nicorandil-induced skin ulceration including of the penis are well recognised complications, however there was no such history in our case. [27]

Extensive review of the literature revealed two cases similar to ours where autoimmune vasculitis was proposed as the underlying cause. [11-13] Congregado et al reported the case of a 68-year old male with localised granulomatous arteritis causing necrotizing granulomatous inflammation. [12] However, granulomatous arteritis usually affects the upper and lower respiratory tracts, the renal glomerulus and presents with ocular and skin lesions. [12] Another similar case is that of a 62-year old patient with Wegener's granulomatosis of the penis. [13] The histopathology revealed necrotizing granulomatous inflammation and vasculitis with c-ANCA levels of 320. This patient later presented with leg lesions that also showed granulomatous vasculitis. [13]

Pyoderma gangrenosum (PG) is an uncommon ulcerative skin disease of unknown cause. Fewer

BMJ Case Reports

than 20 cases have been reported affecting the penis. [11-22] PG can be associated with systemic diseases such as Crohn's disease, rheumatoid arthritis and haematological malignancies, but it also complicates trauma and surgical procedures. [11-15, 22] Crohn's disease is a chronic relapsing, granulomatous, and inflammatory bowel disorder. [11, 23] Variable extra-intestinal manifestations may occur, which include erythema nodosum, erythema multiforme and pyoderma gangrenosum.[24] However, penile ulcerative lesions associated with Crohn's are not usually necrotizing and steroid treatment or other immunosuppressive therapies are usually curative. [23]

Genital PG tends to occur without systemic complications and can mimic SCC. [11-22] The diagnosis of PG rests on clinical features and there are no pathognomonic histopathological characteristics. Histopathological features include oedema, neutrophil infiltration, engorgement and thrombosis of small- and medium-sized vessels and necrosis but this depends on the type of lesion, the stage of evolution and the site of the biopsy. [11, 15] Granulomatous inflammation is not a widely accepted associated finding in PG. [11, 15] However two cases reported by Park et al have been characterised clinically as pyoderma gangrenosum and they appear similar to our own case both clinically without evidence of systemic disease and histologically with granulomatous inflammation. [15] PG, as stated above, can complicate surgery. In our case, the ulcerating lesion was initially biopsied at the time of the patients' circumcision. The area failed to heal and evolved into a complex deep ulcer over a period of eight months. The clinical presentation and the lack of an infective or neoplastic cause for this patients' ulceration lead us to favour a diagnosis of post-surgical granulomatous PG in this case, however we are monitoring the patient long-term for both recurrence and systemic disease.

Benign causes of glans ulceration are rarely reported in the literature and once malignancy is excluded with a diagnostic biopsy, serological, autoimmune and infective screening should be performed prior to corticosteroid treatment. However, the outcomes following surgical reconstruction have been promising in this case, with the neoglans allowing better cosmesis and normal voiding.

The second issue of interest in this case relates to the clinical management. The importance of performing a biopsy or biopsies has been highlighted. However, surgical techniques used in the management of pre-malignant or malignant diseases of the penis such as wide local excision, glans resurfacing or glansectomy followed by reconstruction are also useful in cases where medical treatment fails to restore the normal architecture of the penis.

LEARNING POINTS

- Ulcerative lesions on the glans penis should be biopsied prior to surgical treatment to exclude squamous cell carcinoma.
- In cases of cryptic ulcerative lesions of the penis, a multidisciplinary approach to diagnosis and treatment is advisable given the broad differential diagnosis.
- Where medical treatment fails to improve penile structure and function, surgical excision and reconstruction are legitimate and successful interventions.

BMJ Case Reports

REFERENCES

1. Christodoulidou M, Sahdev V, Houssein S, Muneer A. Epidemiology of penile cancer. *Current Problems in Cancer* 2015; 39(3): 126-136.
2. Bunker CB, Porter WM. Dermatoses of the male genitalia. In: Griffiths C, Barker J, Bleiker T, Chalmers R, Creamer D. eds. *Rook's Textbook of Dermatology*. 9th ed. Oxford: Wiley-Blackwell; 2016. p. 111.1-41.
3. Dinotta F, De Pasquale R, Micali G. Secondary syphilis with exclusive peno-scrotal localization. *G Ital Dermatol Venereol* 2009; 144(6): 725-8.
4. Shim TN, Minhas S, Muneer A, Bunker CB. Atypical presentation of genital herpes simplex (HSV-2) in two patients with chronic lymphocytic leukemia. *Acta Derm Venereol* 2014; 94(2): 246-7.
5. Kureshi F, Kalaaji AN, Halvorson L et al Cutaneous complications of intravesical treatments for bladder cancer: Granulomatous inflammation of the penis following BCG therapy and penile gangrene following mitomycin therapy. *J Am Acad Dermatol* 2006; 55:328-31.
6. Lestre SI, Gameiro CD, Joao A, Lopes MJ. Granulomas of the penis: a rare complication of intravesical therapy with Bacillus Calmette-Guerin. *An Bras Dermatol* 2011; 86(4):759-62.
7. Venyo AK. Tuberculosis of the Penis: A review of the literature. *Scientifica* 2015; 2015:601624.
8. Mukhopadhyay AK. Primary involvement of penile skin in lepromatous leprosy. *Indian J Lepr* 2005; 77(4): 317-21.
9. Inn FX, Imran FH, Ali MF, Ih R, Z Z. Penile augmentation with resultant foreign material granuloma and sequaleae. *Malays J Med Sci* 2012; 19(4): 81-3.
10. Plaza T, Lautenschlager S. Penis swelling due to foreign body reaction after injection of silicone. *J Dtsch Dermatol Ges* 2010; 8(9): 689-91.
11. Ormerod AD, Hampton PJ. Pyoderma gangrenosum. In: Griffiths C, Barker J, Bleiker T, Chalmers R, Creamer D. eds. *Rook's Textbook of Dermatology*. 9th ed. Oxford: Wiley-Blackwell; 2016. P. 49.1-49.6.
12. Congregado RB, Medina López RA, Cruz Navarro N et al. Glands necrosis caused by necrotizing granulomatous arteritis. *Arch Esp Urol* 2002; 55(4):448-51.
13. Iwasaki J, Shwayder T, P6367: Wegener granulomatosis of the penis. *J Am Acad Dermatol* 2013; AB142
14. Farrell AM, Black MM, Bracka A, Bunker CB. Pyoderma gangrenosum of the penis. *Br J Dermatol* 1998; 138: 337-340.

BMJ Case Reports

15. Park H-J, Kim Y-C, Cinn Y-W et al. Granulomatous pyoderma gangrenosum: two unusual cases showing necrotizing granulomatous inflammation. *Clinical and Experimental Dermatology* 2000; 25:617-20.
16. Robinson AM, Chapple CR. Pyoderma gangrenosum of the penis: an interesting penile lesion. *BJU Int* 2003; 92 (S 3):e 62
17. Lally A, Hollowood K, Bunker CB, Turner R. Penile pyoderma gangrenosum treated with topical tacrolimus. *Arch Dermatol* 2005; 141 (9): 1175-6.
18. Gopi SS, Evand AT, Raza A, Byrne DJ. Superficial granulomatous pyoderma gangrenosum of the penis: a case report. *Scientific World J* 2007; 7:2426-9.
19. Parren LJ, Nellen RG, van Marion AM, Henquet CJ, Frank J, Poblete-Gutierrez P. Penile pyoderma gangrenosum: successful treatment with colchicine. *Int J Dermatol* 2008; 47 (S1):7-9.
20. Kim TH, Oh SY, Myung SC. Pyoderma gangrenosum of the penis. *J Korean Med Sci*. 2009; 24(6): 1200-2.
21. Pai VV, Kikkeri NN. Athanikar SB, Myageri A, Rai V. Pyoderma gangrenosum masquerading as Donovanosis. *J Dermatol* 2013; 40(10):840-3.
22. Satoh M, Yamamoto T. Genital pyoderma gangrenosum: Report of two cases and published work review of Japanese cases. *Journal of Dermatology* 2013; 40: 840–43. **23**
23. Lee Y, Lee YM, Kim MJ, Choe YH. Penile Crohn's disease resolved by infliximab. *J Crohns Colitis* 2013; 7(4):e146-9.
24. Murray JG, Fletcher MS, Yates-Bell AJ et al. Plasma cell balanitis of Zoon, *Br J Urol* 1996; 58: 689-91.
25. Rajiah K, Veetil SK, Kumar S et al. Study on various types of infections related to balanitis in circumcised or uncircumcised male and its causes, symptoms and management. *African Journal of Pharmacy and Pharmacology* 2012; 6(2):74-83.
26. Bunker CB, Shim TN. Male genital lichen sclerosus. *Indian J Dermatol* 2015; 60(2): 111-7.
27. Yap T, Philippou P, Petty M, Lam W, Corbishley C, Watkin N. Nicorandil-induced penile ulcerations: a case series. *BJU Int* 2011; 107(2): 268-71.

BMJ Case Reports

FIGURE CAPTIONS

Figure 1: Ulcerative lesion on the glans penis

Figure 2: T2-weighted axial MRI image of the penis showing glans ulceration (white arrow)

Figure 3: Haematoxylin and Eosin staining showing granulation-like tissue and granulomata (x40 magnification)

Figure 4: CD68 Immunostaining (x20 magnification)

Figure 5: Ulcerative lesion on the glans following conservative treatment

Figure 6: Removal of the glans and adjacent skin during glansectomy

Figure 7: Neoglans formation with central urethra and SSG

Figure 8: Appearance of the neoglans nine months following surgery

PATIENT'S PERSPECTIVE

N/A

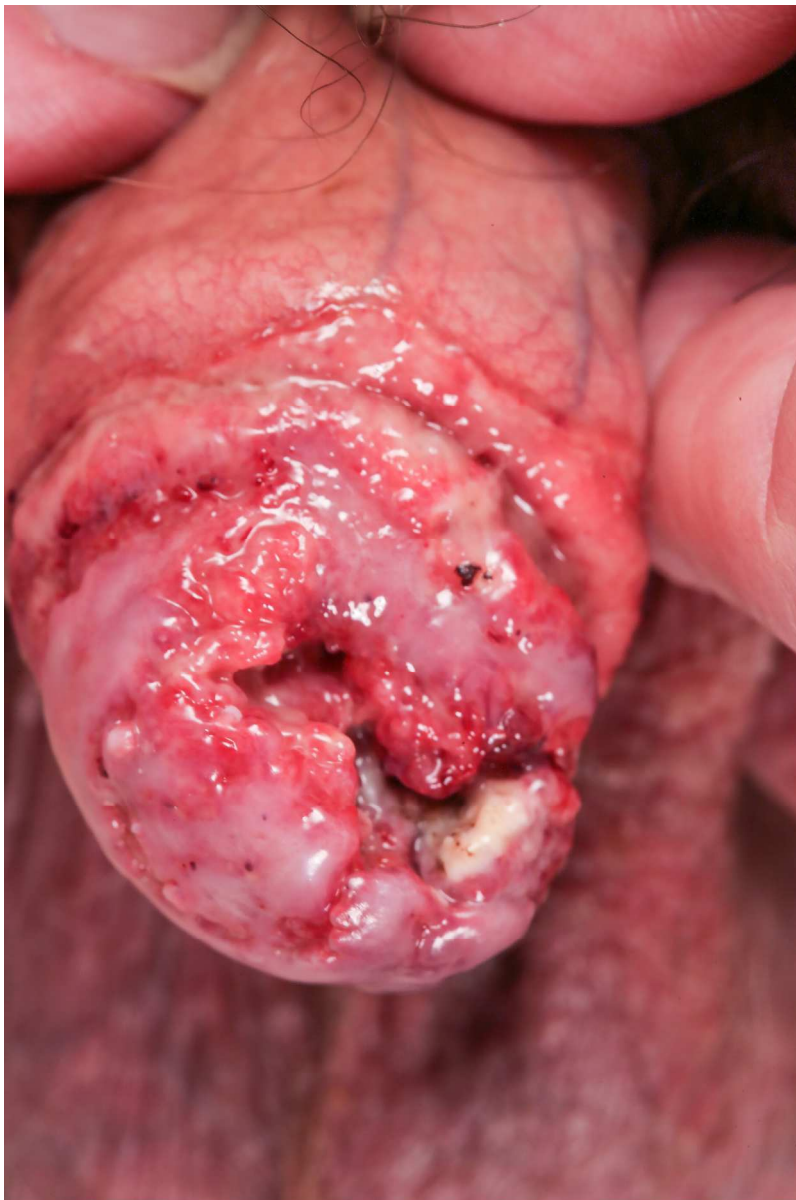
Copyright Statement

I, Michelle Christodoulidou, The Corresponding Author, has the right to assign on behalf of all authors and does assign on behalf of all authors, a full assignment of all intellectual property rights for all content within the submitted case report (other than as agreed with the BMJ Publishing Group Ltd) ("BMJ") in any media known now or created in the future, and permits this case report (if accepted) to be published on BMJ Case Reports and to be fully exploited within the remit of the assignment as set out in the assignment which has been read. <http://casereports.bmj.com/site/misc/copyright.pdf>.

Date: 23/07/2016

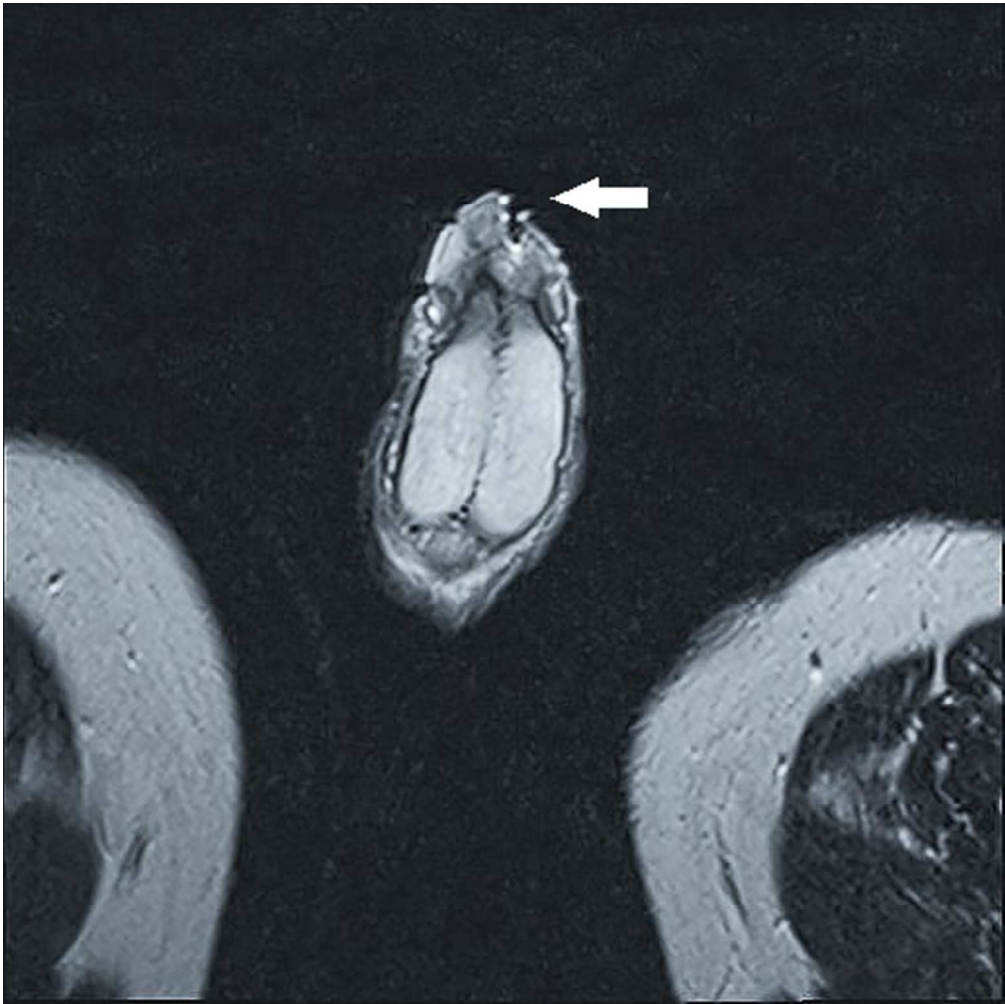
PLEASE SAVE YOUR TEMPLATE WITH THE FOLLOWING FORMAT:

Christodoulidou_July_2016.doc



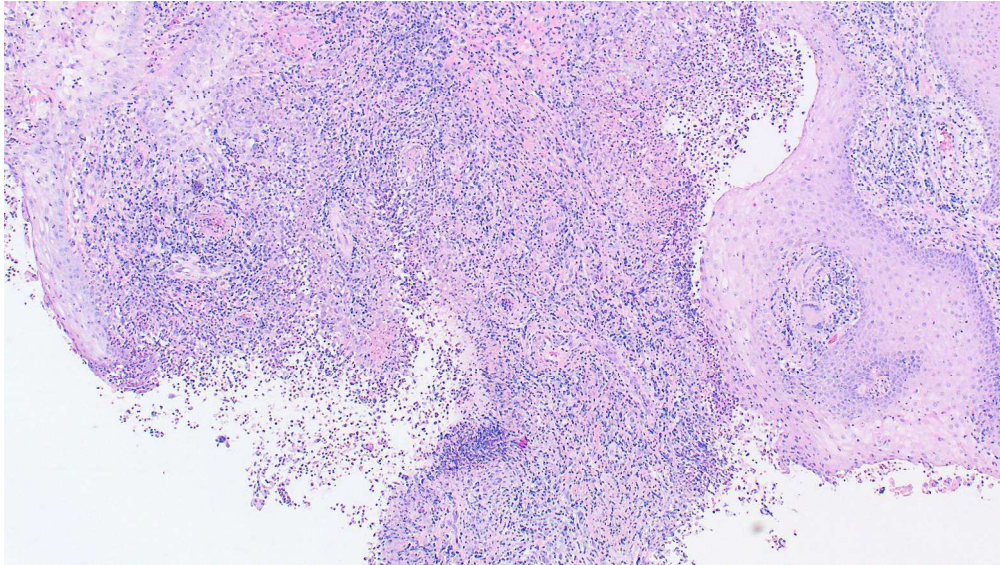
Ulcerative lesion on the glans penis

219x329mm (300 x 300 DPI)



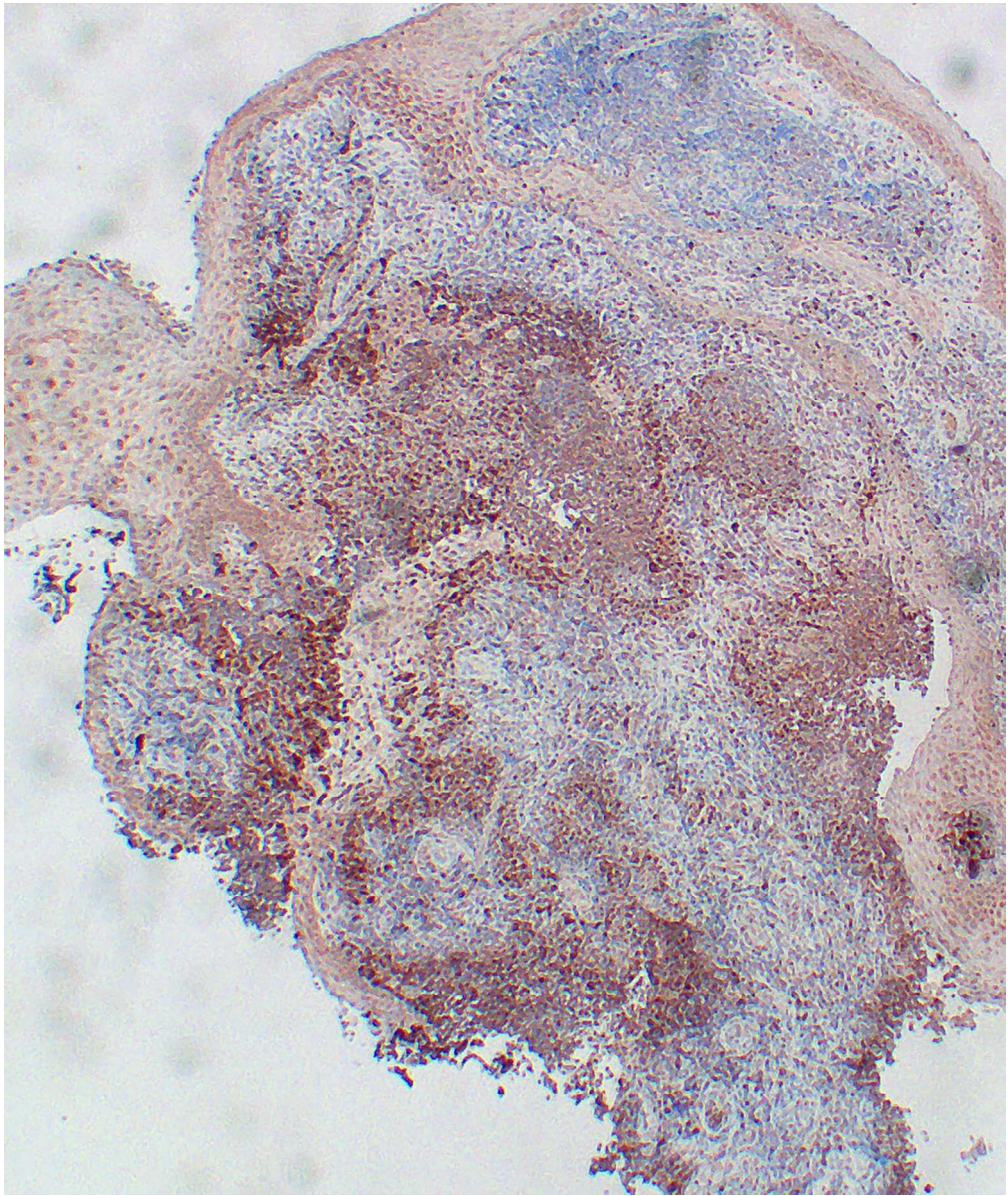
T2-weighted axial MRI image of the penis showing glans ulceration (white arrow)

43x43mm (300 x 300 DPI)



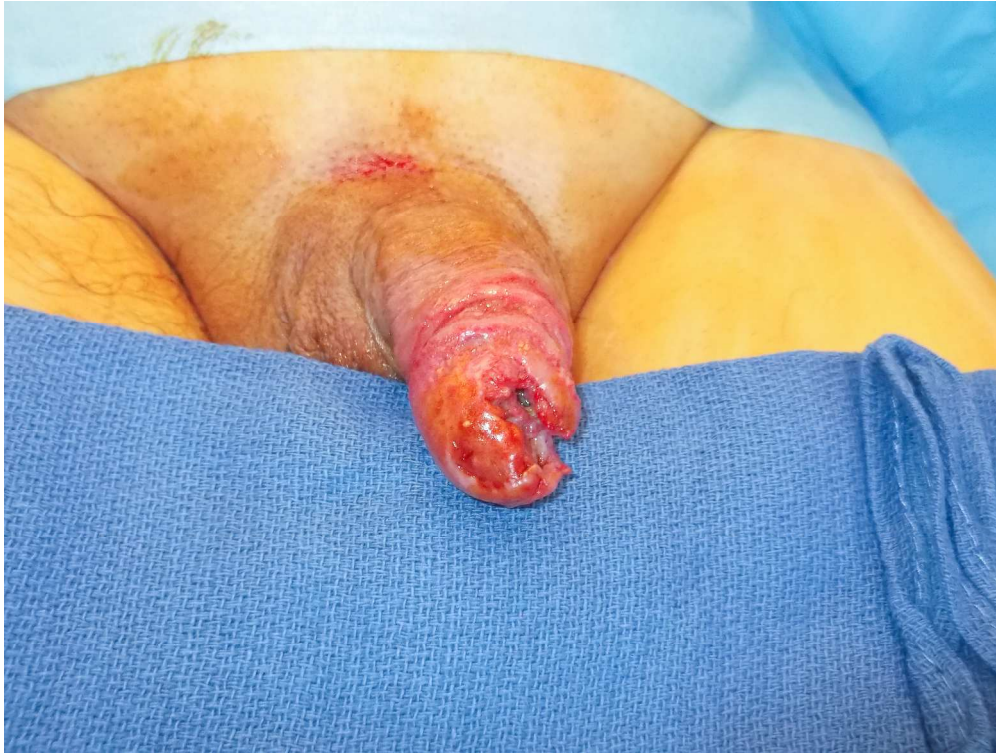Haematoxylin and Eosin staining showing granulation-like tissue and granulomata (x40 magnification)

162x91mm (300 x 300 DPI)



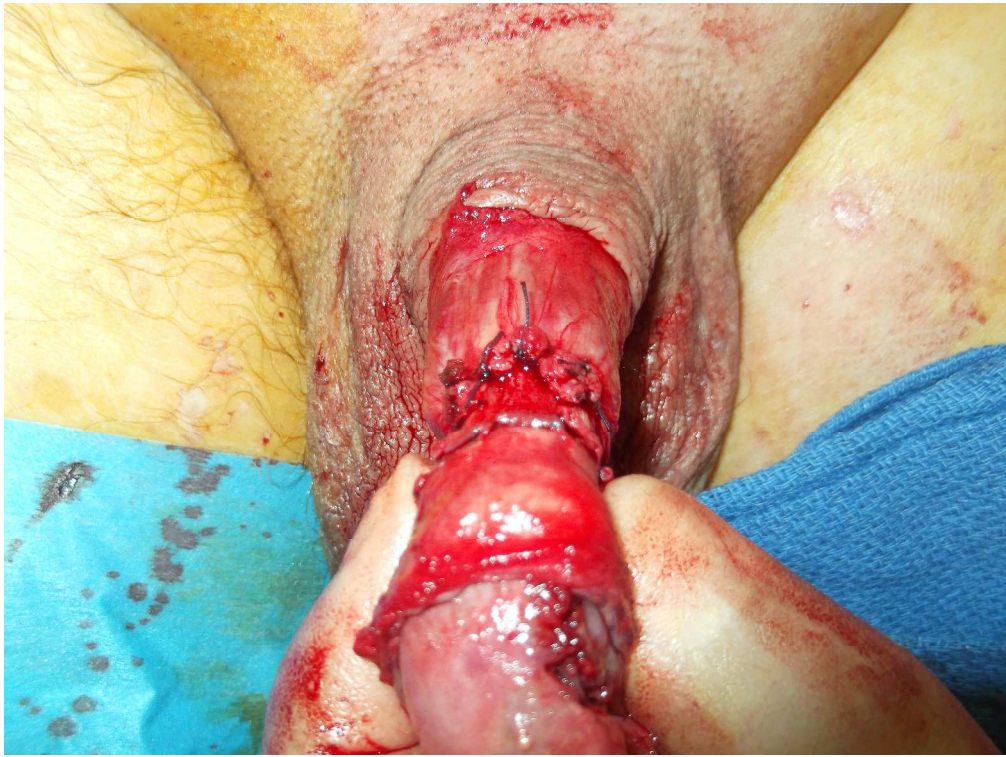CD68 Immunostaining (x20 magnification)

90x106mm (300 x 300 DPI)



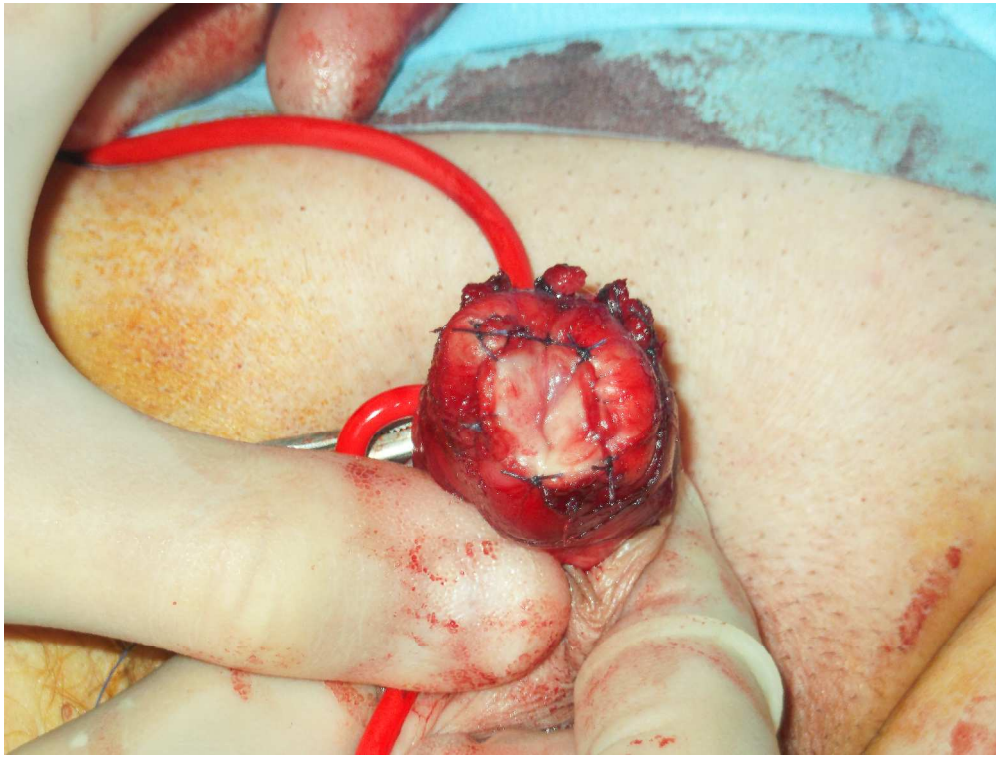
Ulcerative lesion on the glans following conservative treatment

363x272mm (300 x 300 DPI)



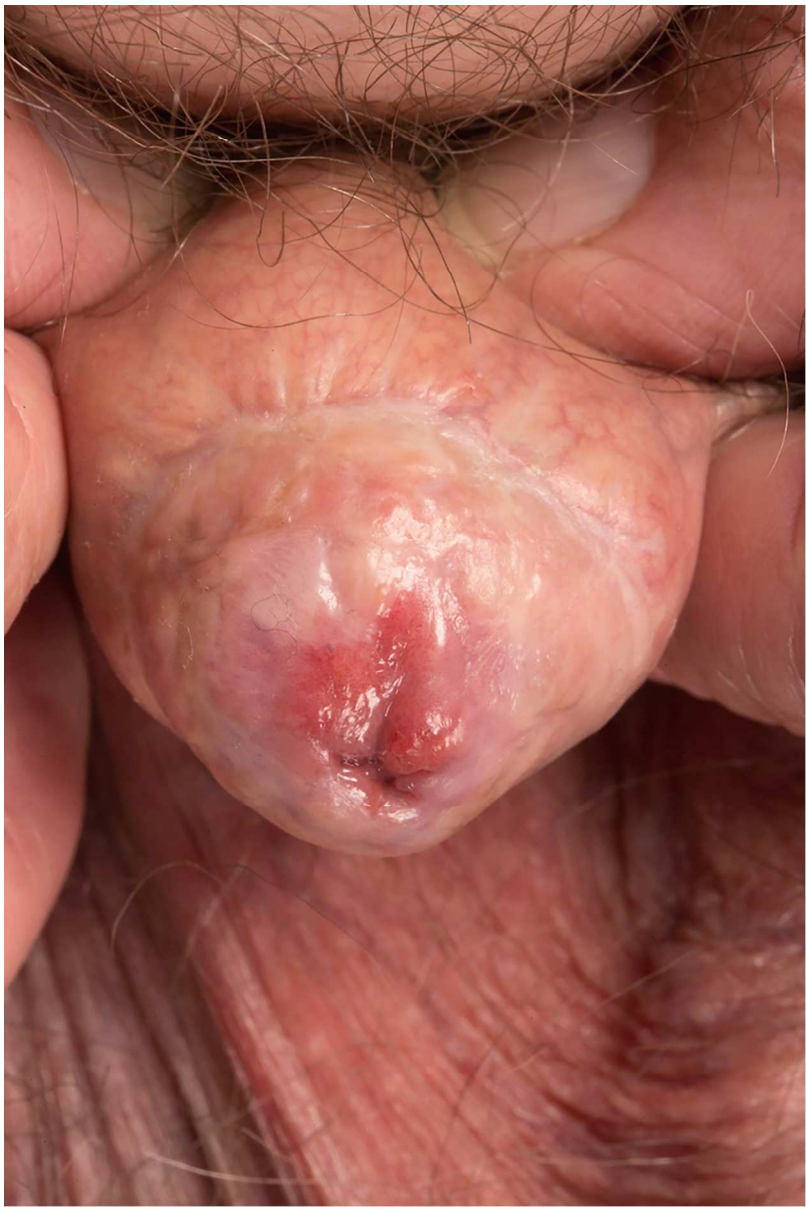Removal of the glans and adjacent skin during glansectomy

363x272mm (300 x 300 DPI)



Neoglans formation with central urethra and SSG

363x272mm (300 x 300 DPI)



Appearance of the neoglans nine months following surgery

90x134mm (300 x 300 DPI)