

# RADIO FREQUENCY ABLATION FOR PATIENTS WITH REFRACTORY SYMPTOMATIC ANAEMIA SECONDARY TO GASTRIC ANTRAL VASCULAR ECTASIA

## Authors:

Cormac Magee<sup>1,2</sup>, Gideon Lipman<sup>1,3</sup>, Durayd Alzoubaidi<sup>1,3</sup>, Martin Everson<sup>1,3</sup>, Rami Sweis<sup>1</sup>, Matthew Banks<sup>1</sup>, David Graham<sup>1</sup>, Charles Gordon<sup>4</sup> Laurence Lovat<sup>1,3</sup>, Charles Murray<sup>1</sup>, Rehan Haidry<sup>1,3</sup>

## Affiliations:

1 University College London Hospital, United Kingdom

2 Centre for Obesity Research, University College London, United Kingdom

3 Division of Surgery and Interventional Science, University College London, United Kingdom

4 Royal Bournemouth and Christchurch Hospital, United Kingdom

Correspondence to [r.haidry@ucl.ac.uk](mailto:r.haidry@ucl.ac.uk)

Conflict of interest statement: The authors declare no conflict of interest

Keywords: Gastrointestinal bleeding, Radio-Frequency ablation, Endoscopy, Gastric antral vascular ectasia

IRAS ID: 183819 REC Ref: 16/LO/0149 3<sup>rd</sup> February 2016 London – Central Research Ethics Committee.

ISRCTN Registry number 32186.

## Background:

Gastric antral vascular ectasia (GAVE) is a rare cause of gastrointestinal bleeding, often causing iron deficiency anaemia. Previous studies have looked at the management of this with Argon Plasma Coagulation, Laser Therapy and Endoscopic Band Ligation.

## Methods:

This was a single centre prospective study to evaluate the efficacy and safety of radio-frequency ablation (RFA) in patients with GAVE with persistent anaemia refractory to at least one session of first line endoscopic therapy. Patients were treated with a through the scope (TTS) radio-frequency catheter at two endoscopic sessions 6 weeks apart. The primary outcome was change in haemoglobin at 6 months post treatment. The secondary outcomes were reduction in blood or iron requirements, endoscopic surface area regression and complications.

## Results:

20 patients were treated. The mean change in haemoglobin at 6 months was +12.6g/L (95% CI 11.7-24.3 g/L), paired t-test  $p < 0.001$ . At 6 months 3/14 who had required blood transfusions had ongoing blood transfusions and 5/17 who had required iron had ongoing iron needs. Surface area regression was scored as 74+/-25% but no correlation was seen between this and other outcomes. 3/20 patients experienced pain which was managed with oral analgesia. Of the 14 patients who had reached 12 month follow up, 3 required retreatment (21%).

## Discussion:

This small study suggests that RFA is a safe and effective treatment for GAVE. Our study uses the TTS catheter compared to other studies, and demonstrates prolonged improvement in Hb and reduction in blood and iron requirements with a novel assessment of surface area regression.

## Registration:

The study was approved by the London Central Research Ethics Committee. IRAS ID: 183819 REC Ref: 16/LO/0149 3rd February 2016. ISRCTN Registry number 32186.

## **Introduction:**

Gastric antral vascular ectasia (GAVE) was first described in 1953 by Rider et al<sup>1</sup>. Later studies described its endoscopic appearances as “watermelon stomach” with “longitudinal rugal folds traversing the antrum and converging on the pylorus, each containing a visible convoluted column of vessels, the aggregate resembling the stripes on a watermelon.”<sup>2</sup> Although this is usually diagnosed by pathognomonic endoscopic appearances (Figure 1), confirmation by biopsies shows dilated, ectatic capillaries in mucosa and submucosa with microthrombi and minimal inflammation.<sup>3,4</sup>

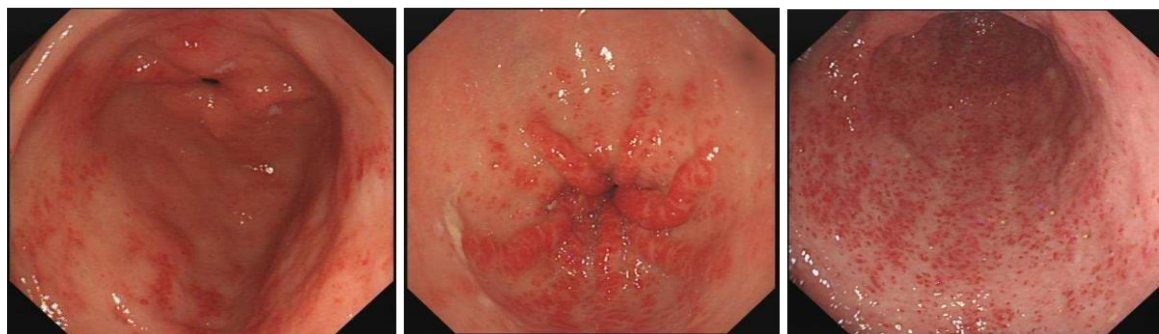

Figure 1: Examples of the characteristic endoscopic changes of GAVE at endoscopy

The majority of patients with GAVE have concomitant underlying systemic diseases including cirrhosis of the liver<sup>5</sup>, autoimmune diseases<sup>6</sup>, chronic kidney disease and hypothyroidism amongst others.<sup>7</sup> The underlying pathophysiology of GAVE is unclear with roles suggested for prostaglandin E2 levels<sup>8</sup>, cross-linking of antibodies to proteins in the gastric mucosa<sup>9</sup>, trauma of the gastric mucosa due to dysmotility<sup>10</sup> or such vasoactive substances as gastrin or 5HT-3<sup>11</sup>.

Patients with GAVE often develop iron deficiency anaemia and require treatments with blood transfusions and iron supplementation.<sup>12</sup> Along with the clinical problems of chronic anaemia, GAVE can impact on the patients' quality of life, requiring regular visits to hospitals. In addition, despite transfusions many patients remain anaemic which can impact on fatigue and exercise tolerance<sup>13</sup>.

The ideal management algorithm for GAVE is not clear. Treatment of the underlying disease is recommended. Medical therapies, including corticosteroids, tranexamic acid, thalidomide

and octreotide have been trialled and described in short case series or case reports or small clinical trials<sup>14,15,16,17</sup>.

Surgical treatment (antrectomy) can be definitive for GAVE by removing the affected mucosa<sup>18, 19</sup>. However particularly in those with such diseases as liver cirrhosis the mortality and morbidity associated with surgery can be high and therefore outweigh any potential benefit<sup>20</sup>.

Endoscopic therapy (ET) is therefore a mainstay of treatment in patients with GAVE and symptomatic anaemia. Endoscopic therapy mostly uses thermal modalities, aiming to achieve a widespread eradication of mucosal capillary ectasia network in the antrum, with subsequent re-epithelialization, without causing damage deeper than the superficial submucosa. Argon plasma coagulation (APC) is a thermoablative method where a high-frequency current is passed through argon gas to cause thermocoagulation. It is the preferred endoscopic treatment of GAVE on account of being easy to use, relatively safe and has an acceptable cost. However, it can often require multiple sessions, and discontinuation of transfusion dependence is currently achieved in only one third of the patients<sup>21</sup>. Endoscopic band ligation (EBL) has also been used to treat GAVE although again this can result in multiple sessions and can be painful for the patients.<sup>22,23</sup> Furthermore APC is not without complications including sepsis, hyperplastic polyps (which can also bleed) and gastric outlet obstruction<sup>24,25,26</sup>. Endoscopic LASER therapy with an Nd:YAG laser has also been used but is less available, has deeper tissue injury which can result in perforation and has a higher cost<sup>27</sup>.

Radio-frequency ablation (RFA) is the mainstay of endoscopic ablation treatment in such diseases as Barrett's oesophagus, using the Barrx HALO system (Medtronic, Dublin, Ireland).<sup>28</sup> This technique transmits high power energy for a short period of time to ablate superficial lesions. This leads to a uniform depth of ablation with low risk of ulceration, no need for gas insufflation (eg as is needed with APC treatment) and there are a range of catheters which can be used to achieve appropriate tissue contact. RFA has also been used to treat ectatic rectal vessels in the context of radiation proctitis.<sup>29</sup> RFA has been used in small numbers of patients for the treatment of GAVE, showing improvements in haemoglobin and reductions in transfusion requirements in patients refractory to APC without complications.<sup>30, 31</sup> Mucosal ablation can therefore likely provide a successful, safe method of treatment of GAVE associated with iron deficiency, particularly in those with disease refractory to first line treatments. We report the results of our prospective study of these patients.

### **Aim:**

A single centre prospective feasibility study to evaluate the efficacy and safety of RFA in patients with macroscopic GAVE with persistent anaemia refractory to first line endoscopic therapies.

## **Methods:**

### **Patient selection:**

Patients were recruited to this study prospectively from referrals to our specialist centre with confirmed GAVE. Formal written informed consent was taken from patients to join the study, and the study was approved by local and national ethics bodies. The study was approved by the London Central Research Ethics Committee. IRAS ID: 183819 REC Ref: 16/LO/0149 3rd February 2016. ISRCTN Registry number 32186. The study protocol conforms to the 1975 Declaration of Helsinki.

### **Inclusion criteria:**

Patient with the following criteria were screened for our study.

- Existing diagnosis of GAVE
- Persistent iron deficiency anaemia despite ongoing therapy with blood transfusions, intravenous or oral iron supplementation within the last 6 months
- At least 18 years of age
- Previous treatment for GAVE with either argon plasma coagulation, YAG laser or band ligation
- Visible GAVE at time of treatment endoscopy commensurate with anaemia
- Able to comply with study requirements and understand and sign the informed consent form

### **Exclusion criteria:**

- Active malignancy (malignancy diagnosed in past 5 years or ongoing treatment)
- Alternative cause for anaemia e.g. coeliac disease, colonic pathology or haematological disease (all patients underwent bidirectional endoscopy prior to inclusion).
- Pregnancy
- Anatomical abnormalities precluding treatment with radio-frequency ablation
- Any other reason that the investigator feels makes patient unsuitable for trial

### **RFA Treatment and investigation:**

Once informed written consent had been taken, details of transfusion/iron requirements and pre-treatment haemoglobin were recorded.

Treatment with RFA was carried out with focal RFA with a through-the-scope (TTS) catheter at 12J/cm<sup>2</sup> to all visible areas of GAVE under conscious sedation or propofol sedation by

experienced endoscopists. Prior to treatment 2% N-acetylcysteine (NAC) as a mucolytic and 1:10,000 adrenaline were applied through a dye-spray catheter. The latter acted as a topical vasoconstrictor to reduce contact bleeding with the catheter and improve visibility.

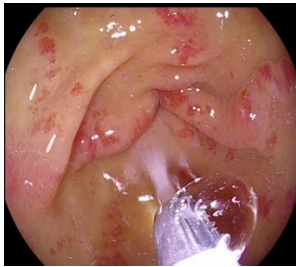

Fig 2a Application of N-acetylcysteine and adrenaline 1:10,000

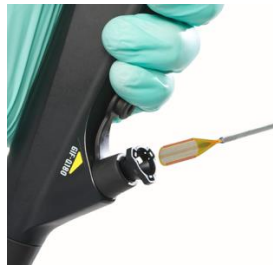

Fig 2b Insertion of TTS catheter



Fig 2c TTS catheter in endoscope

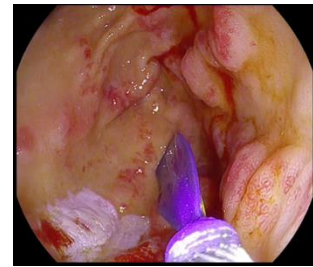


Fig 2d Application of RFA to visible GAVE

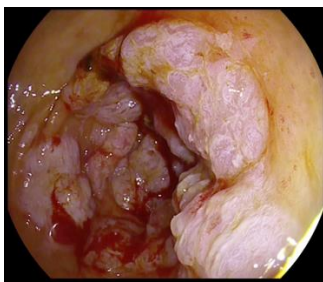


Fig 2e Image post treatment

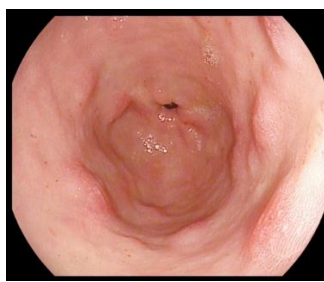

Fig 2f Follow up endoscopy

The device was apposed to the tissue to achieve good contact and 3 sequential applications at 12J/cm<sup>2</sup> were used (see figure 2a-f). Enhanced imaging was also used in some cases to highlight areas of visible GAVE (see figure 3). All patients received omeprazole (40mg BD), ranitidine (300mg OD) and sucralfate liquid (1g TDS) post endoscopy for 6 weeks as per our standard protocol for RFA in Barrett's oesophagus.

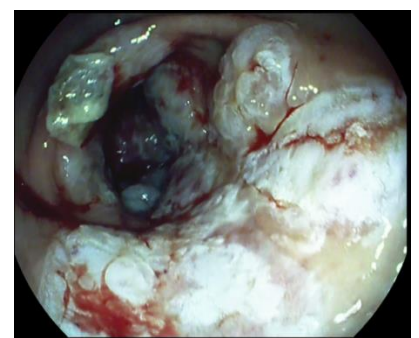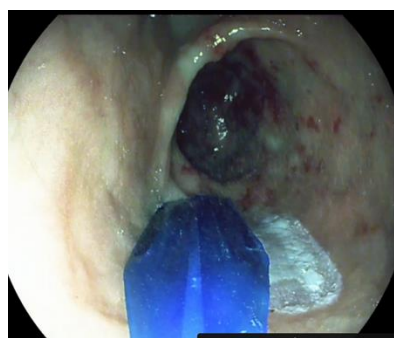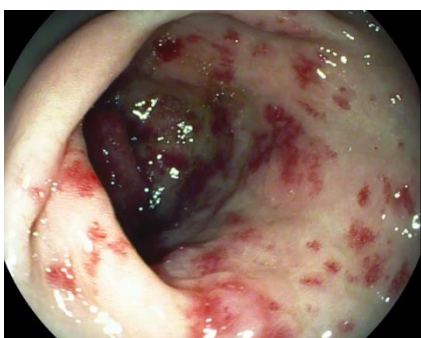


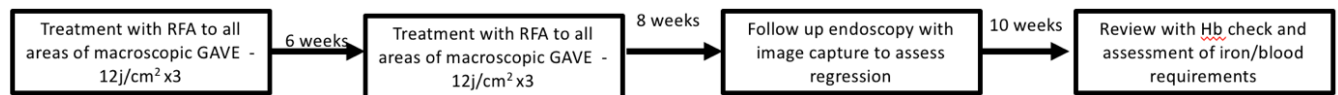Figure 3: The treatment of GAVE with RFA with enhanced imaging to identify areas of GAVE

Following the initial RFA procedure, all patients returned for a repeat endoscopy after 6 weeks. In those for whom there was macroscopic GAVE present at this endoscopy this was

treated with RFA as at the initial therapy. 8 weeks following this patients returned for a follow up endoscopy where images were captured of the gastric mucosa, and entered the follow up phase where haemoglobin and ongoing transfusion/iron requirements were recorded at 6 months following the first procedure.

Figure 4, flow chart demonstrating trial algorithm:



### Outcomes:

The primary outcome was a sustained increase in haemoglobin (Hb) 6 months after at least two sequential RFA treatments.

Secondary outcomes were a reduction in frequency of blood transfusions and/or iron (P.O. or I.V.) in the 6 months before and after RFA treatments. Endoscopic surface area (SA) regression of areas of GAVE at the follow up endoscopy were analysed by asking 2 expert endoscopists to estimate the overall percentage change in GAVE SA from index treatment by examining single endoscopic images of the stomach before and after the treatment sessions, and asked to score as 0%, 20%, 40%, 60%, 80% or 100% regression, in a manner similar to that previously published in assessment of regression for Barrett's oesophagus<sup>32</sup>. Where there was more than 30% disagreement a consensus meeting was held to score with review of the images. Follow up Hb and treatment success was correlated to the % regression at the follow up endoscopy.

### Statistical Methods:

The data were entered into an anonymised database and analysis was performed using SPSS (Statistical Package of the Social Sciences) 10.0.1 for Mac. The change in haemoglobin score values before and after treatment was compared using paired t-test for parametric variables. An  $\alpha$ -error of less than or equal to 0.05 was considered to be statistically significant.

### Results:

#### Patient demographics and characteristics:

22 patients were recruited into this feasibility study in our centre. 2 patients were excluded at first endoscopy due to absence of macroscopic GAVE.

The patient characteristics can be seen in Table 1:

Table 1: Patient characteristics

Age (years) median	69 (IQR 62-81)
Gender male	3 (15%)
Gender female	17 (85%)
Previously treated with APC	13 (65%)
Previously treated with YAG laser	4 (20%)
Previously treated with endoscopic band ligation	3 (15%)
Systemic sclerosis	5 (25%)
Liver cirrhosis	4 (20%)
Hypothyroidism	3 (15%)
Type 2 Diabetes	2 (10%)
Chronic kidney disease	1 (5%)
No associated diseases	5 (25%)
Oral iron supplementation pre-treatment	11 (55%)
Intravenous iron supplementation pre-treatment	6 (30%)
Blood transfusions pre-endoscopy	14 (70%)
Iron supplementation and blood transfusions	11 (55%)

Outcomes:

The primary outcome in our study was changes in haemoglobin following treatment with RFA. The mean pre-treatment haemoglobin was 95.1g/L (95% CI 87.4-102.6g/L). The mean post treatment haemoglobin at 6 months post RFA treatment protocol was 112g/L (95% CI 103.9 -120.1g/L). The mean change in haemoglobin was +12.6 g/L (95% CI 11.7 – 24.3g/L) (p<0.001) (paired t-test)). See Figure 4.



## Haemoglobin at 6 months following RFA treatment

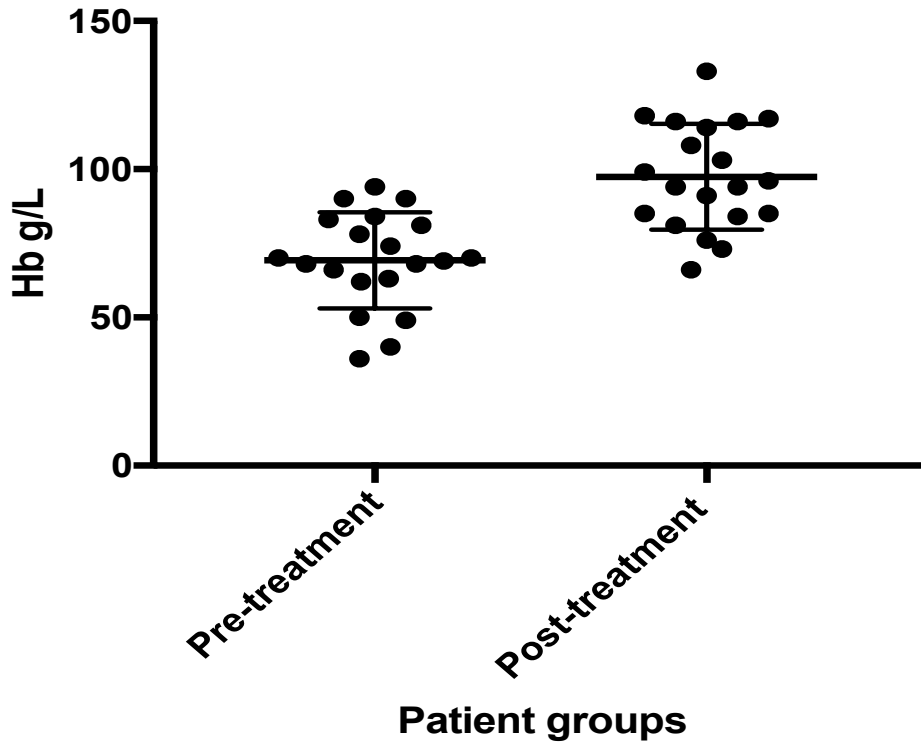


Figure 5: Change in haemoglobin at 6 months post RFA treatment

At 6 months post RFA only 3/14 (21%) of the patients who had required blood transfusions prior to the procedure had ongoing transfusions figure 5). 5/17 (29%) patients who were previously on iron had ongoing iron needs.

## Blood requirements at 6 months post treatment

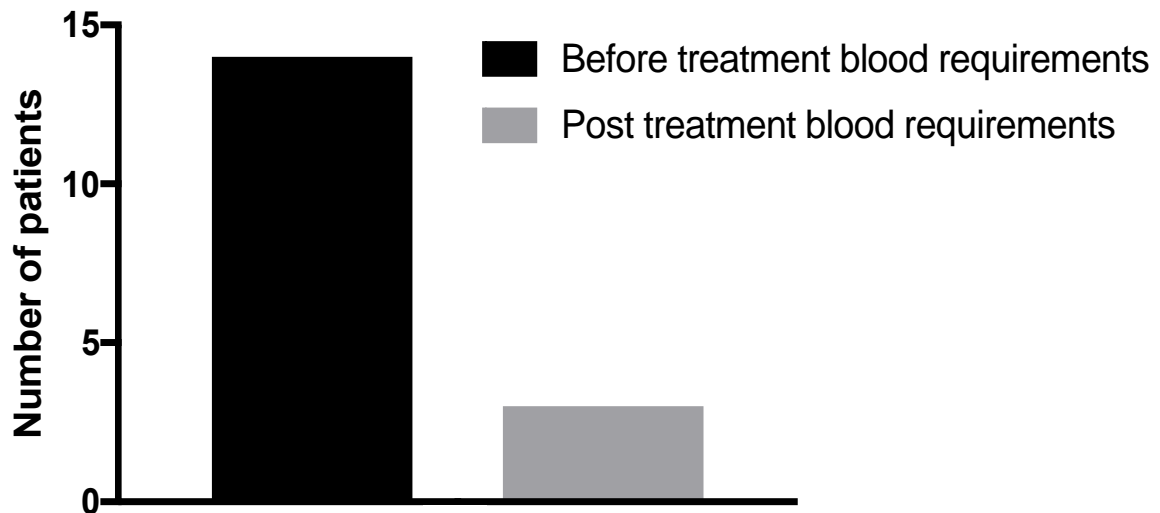


Figure 6: Change in blood requirements at 6 months

The mean surface area regression of GAVE when scored by 2 experienced upper GI endoscopists on still endoscopic images taken before and after treatment was 74% +/-25. No correlation was seen between higher surface area regression and Hb change, blood or iron requirements. Pearson Log rank p=NS. Figure 6 shows examples of the images used for regression analysis.

The median number of treatments needed in these patients was 2 (IQR 1-2).

The mean number of ablations needed per treatment was 106 +/-50.

### **Durability of anaemia reversal**

At 12 months post RFA, 3/14 (21%) patients had recurrence of anaemia with requirements for blood or intravenous iron. All 3 patients were then treated with RFA (outside of this study protocol). Patients with a lower haemoglobin pre-treatment appeared to be less likely to recur (p<0.05 Mann-Whitney U test). 2 patients were treated at 8 months and 1 at 10 months post initial RFA treatment.

### **Adverse events**

3/20 patients in our study experienced pain which was managed with oral pain medications (paracetamol or codeine). There were no complications of perforation, acute bleeding or stricture formation.

Before treatment:

After treatment:

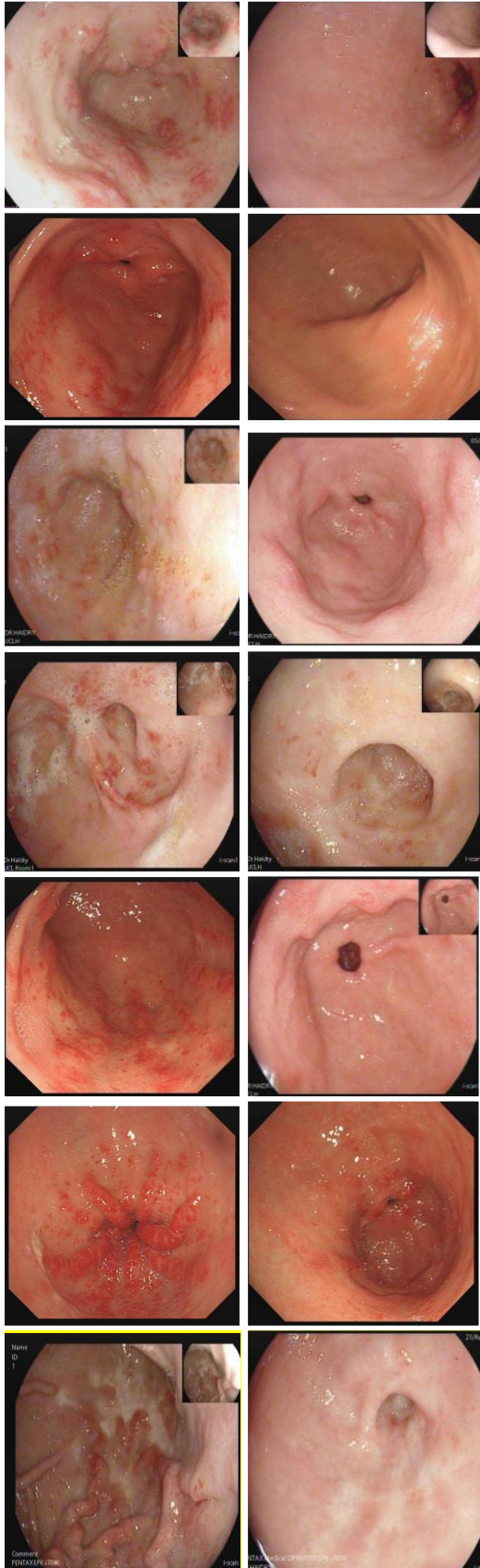


Figure 7: Images before and after treatment of GAVE with RFA

## **Discussion:**

This prospective feasibility study presents further evidence for the use of RFA in GAVE with symptomatic anaemia. In our group of 20 patients, all of whom had failed other endoscopic therapy for GAVE, remaining anaemic with blood and iron requirements, RFA over only 2 sessions was shown to produce a highly significant change in haemoglobin. There was a surprising negative correlation between pre-treatment haemoglobin and improvement in haemoglobin which may, tentatively suggest, that RFA for GAVE is most effective in patients with more severe anaemia although the study was not formally powered to address such questions. In addition, the number of patients requiring ongoing oral and intravenous iron supplementation was greatly reduced, as was the number of patients requiring blood transfusions. The number of treatments needed for this significant response was low compared to those reported in studies of other therapies<sup>25-27</sup> and our own clinical experience, meaning fewer visits to the endoscopy department for patients who often, due to other comorbidities, have multiple frequent hospital appointments. The treatment was well tolerated, with a small number of patients reporting pain which was controllable with oral analgesia. Many patients reported improved quality of life although this was not formally assessed. Improvement was seen across a broad range of clinical conditions associated with GAVE, with our group of patients involving more patients with systemic sclerosis than previous studies. Of those patients who had reached 12 month follow up, only 21% had recurrence of anaemia which required blood transfusion or recommencement of iron supplementation, and further treatment, demonstrating durability of the treatment.

Radiofrequency ablation has previously been studied in GAVE. An initial study by Gross et al found similar results in a small case series of 6 patients<sup>33</sup>. A further study by McGorisk et al<sup>30</sup> showed improvements in haemoglobin and reductions in transfusions in patients who had previously failed APC treatment using the HALO 90 catheter, while Jana et al<sup>34</sup> demonstrated reductions in transfusion requirements and improvements in haemoglobin in 7 patients who had failed APC treatment. All these studies reported acceptable safety profiles.

Our study includes patients with multiple different treatment modalities prior to intervention with RFA, including LASER and EBL in addition to APC. In addition, there were strict inclusion and exclusion criteria, especially the exclusion of other causes of anaemia through bidirectional endoscopy. In addition, we believe this to be the first to investigate changes in intravenous and oral iron requirements which we feel is important given the potential impact on quality of life from continuous oral iron supplementation or visits to the hospital for intravenous iron infusions. Surface area regression has been previously used in the assessment of Barrett's oesophagus<sup>32</sup>, but has not been used previously to assess therapeutic response in GAVE. Within the strict criteria of our trial, patients were permitted two treatment sessions before regression analysis. It may be that with further studies, it can be assessed whether surface area regression predicts clinical outcomes. This was not the case in

our study, although this may be due to insufficient numbers. Furthermore, our study used the TTS catheter while many of the previous studies used the HALO 90 catheter.

The TTS device is ideal for this treatment protocol as there is only one intubation of the oesophagus (rather than the second intubation with a gastroscope with a Halo Ultra catheter attached externally which expands the diameter of the device and in our experience from the treatment of Barrett's oesophagus can be uncomfortable for the patient). In addition, the improved flexibility and field of movement of the catheter allows treatment across the non-flat parts of the stomach. Another advantage of the TTS device is that there is not a need to reposition the catheter on the endoscope from the 6 o'clock to the 12 or 3 o'clock positions again reducing the need for further intubations of the oesophagus.

The 12J/cm<sup>2</sup>x3 protocol allows treatment of superficial disease with a uniform depth of ablation across a large area rapidly which is ideal for the treatment of such superficial diseases as GAVE without deeper treatment which may lead to more risk of ulceration and pain. This was chosen on the basis of dosimetry used in the treatment of Barrett's oesophagus and cleaning was not performed as we felt this might reduce the risk of bleeding. We plan, however, to investigate the use of higher energy protocols, particularly in those patients in whom the disease recurs.

The most frequently used alternative to RFA is APC. Trials have demonstrated the efficacy of this but, as with RFA, most of these are small single centre studies or retrospective analyses. In addition, many patients required frequent treatment sessions<sup>23</sup> and showed a significant level of recurrence of over 50% at one year<sup>21</sup>. Although RFA is more expensive at the time of endoscopy, we believe that a formal cost analysis of these patients may show savings due to reduced blood and iron infusions, reduced hospital stays and reduced number of treatments. This is the first study to show the feasibility of this treatment within the UK National Health Service.

The limitations of our study include the small number of patients as can be expected with a rare disease such as GAVE. In addition, this is a single centre study. Further work, which we are commencing, is needed to assess the cost effectiveness of RFA for GAVE which in turn could help design further studies including randomized studies comparing with APC or EBL across different centres, and the relative benefits of different RFA catheters, and different energy protocols.

---

<sup>1</sup> Rider JA, Klotz AP, Kirsner JB. Gastritis with veno-capillary ectasia as a source of massive gastric haemorrhage. *Gastroenterology*, 1953; 24:118-123

<sup>2</sup> Jabbari M, Cherry R, Lough JO et al. Gastric antral vascular ectasia: the watermelon stomach. *Gastroenterology*, 1984; 87:1165-1170

<sup>3</sup> Gilliam JH 3<sup>rd</sup>, Geisinger KR, Wu WC et al. Endoscopic biopsy is diagnostic in antral vascular ectasia. *Dig Dis Sci*, 1989; 34:885-888

<sup>4</sup> Naidy H, Huanq Q, Mashimo H. Gastric antral vascular ectasia: the evolution of therapeutic modalities. *Endosc Int Open*, 2014, 2:E67-73

<sup>5</sup> Ward EM, Raimondo M, Rosser BG et al. Prevalence and natural history of gastric antral vascular ectasia in patients undergoing orthotopic liver transplantation. *J Clin Gastroenterol* 2004;38:898-900

- 
- <sup>6</sup> Marie I, Ducrotte P, Antoinietti M, et al. Watermelon stomach in systemic sclerosis: its incidence and management. *Aliment Pharmacol Ther.* 2008;28:412–21.
- <sup>7</sup> Gretz JE, Achem SR. The watermelon stomach: clinical presentation, diagnosis and treatment. *Am J Gastroenterology*, 1998; 93(6):890-5
- <sup>8</sup> Saperas E, Perez Ayuso RM, Poca E et al. Increased gastric PGE2 biosynthesis in cirrhotic patients with gastric vascular ectasia. *Am J Gastroenterol*, 1990; 85:138-144.
- <sup>9</sup> Ceribelli A, Cavazaana I, Airo P et al. Anti-RNA polymerase III antibodies as a risk marker for early gastric antral vascular ectasia (GAVE) in systemic sclerosis, *J Rheumatol*; 2010: 37:1544
- <sup>10</sup> Sallam H, McNearney TA, Chen JD. Systematic review: pathophysiology and management of gastrointestinal dysmotility in systemic sclerosis (scleroderma). *Alimen Pharmacol Ther.*; 2006:23:691-712.
- <sup>11</sup> Lowes JR, Rode J. Neuroendocrine cell proliferations in gastric antral vascular ectasia. *Gastroenterology*; 1989; 97:207-212
- <sup>12</sup> Novitsky YW, Kercher KW, Czerniach DR et al. Watermelon stomach: pathophysiology, diagnosis and management. *J Gastrointest Surgery* 2003; 7:652-661
- <sup>13</sup> Selinger CP and Ang YS. Gastric Antral Vascular Ectasia (GAVE): An update on Clinical Presentation, Pathophysiology and Treatment, *Digestion*, 2008; 77:131-137
- <sup>14</sup> Fuccio L, Mussetto A, Laterza L et al. Diagnosis and management of gastric antral vascular ectasia. *World J Gastrointest Endosc* 2013; 51:6-13
- <sup>15</sup> Barbara G, De Giorgio R Salvioli B et al. Unsuccessful octreotide treatment of the watermelon stomach. *J Clin Gastroenterol* 1998; 26:345-346
- <sup>16</sup> McFarlane M, O'Flynn L, Ventre R et al. Emerging role of thalidomide in the treatment of gastrointestinal bleeding. *Frontline Gastroenterology* 2018; 9:98-104
- <sup>17</sup> Bhowmick BK. Watermelon stomach treated with oral corticosteroid. *J R Soc Med* 1993;86:52
- <sup>18</sup> Sherman V, Klassen Dr, Feldman LS et al. Laparoscopic antrectomy: a novel approach to treating watermelon stomach. *J Am Coll Surg* 2003; 197:864-867.
- <sup>19</sup> Kruger R, Ryan ME, Dickson KB, Nunez JF. Diffuse vascular ectasia of the gastric antrum, *Am J Gastroenterol* 1987; 82(5): 421-426
- <sup>20</sup> Spahr L, Villeneuve JP, Dufresne MP et al. Gastric antral vascular ectasia in cirrhotic patients: absence of relation with portal hypertension. *Gut* 1999; 44:739-742
- <sup>21</sup> Nakamura S, Mitunaga A, Konishi H et al. Long-term follow up of gastric antral vascular ectasia treated by argon plasma coagulation. *Dig Endosc* 2006. 18:128-133
- <sup>22</sup> Sato T, Yamakazi K, Akaike J. Endoscopic band ligation versus argon plasma coagulation for gastric antral vascular ectasia associated with liver diseases. *Dig Endoscopy* 2012; 24:237-242.
- <sup>23</sup> Elhendawy M, Mosaad S, Alkhalawany W et al. Randomised controlled study of endoscopic band ligation and argon plasma coagulation in the treatment of gastric antral and fundal vascular ectasia. *United European Gastroenterol J* 2016; 4(3):423-8.
- <sup>24</sup> Roman S, Saurin JC, Dumortier J et al. Tolerance and efficacy of argon plasma coagulation for controlling bleeding in patients with typical and atypical manifestations of watermelon stomach. *Endoscopy* 2003. 35:1024-1028
- <sup>25</sup> Farooq FT, Wong RC, Yang P et al. gastric outlet obstruction as a complication of argon plasma coagulation for watermelon stomach. *Gastrointest Endosc* 2007; 65: 1090-1092
- <sup>26</sup> Baudet JS, Salata H, Soler M et al. Hyperplastic gastric polyps after argon plasma coagulation treatment of gastric antral vascular ectasia (GAVE). *Endoscopy* 2007; 39: E320
- <sup>27</sup> Mathou NG, Lovat LB, Thorpe SM et al. Nb:YAG laser induces long-term remission in transfusion dependent patients with watermelon stomach. *Lasers Med Sci*, 2004; 18:213-218.
- <sup>28</sup> Haidry RJ, et al. Radiofrequency ablation and endoscopic mucosal resection for dysplastic Barrett's esophagus and early esophageal adenocarcinoma: outcomes of the UK National Halo RFA Registry. *Gastroenterology* 2013; 145: 87–95.
- <sup>29</sup> Zhou C, Adler DC, Becker L et al. Effective treatment of chronic radiation proctitis using radiofrequency ablation. *Therap Adv Gastroenterol* 2009; 2:149-156.
- <sup>30</sup> McGorisk T, Krishnan K, Keefer L, et al. Radiofrequency ablation for refractory gastric antral vascular ectasia (with video). *Gastrointest Endosc.* 2013;78(4):584-8
- <sup>31</sup> Dray X, Repici A, Gonzalez P et al. Radiofrequency ablation for the treatment of gastric antral vascular ectasia. *Endoscopy.* 2014;46(11):963-9
- <sup>32</sup> Belghazi K, Pouw RE, Koch AD et al. Self-sizing radiofrequency ablation balloon for eradication of Barrett's oesophagus: results of an international multicentre randomized trial comparing three different treatment regimens. *Gastrointest Endosc.* 2018; 86(6)SuppAB81
- <sup>33</sup> Gross SA, Al-Haddad M, Gill KR et al. Endoscopic mucosal ablation for the treatment of gastric antral vascular ectasia with the HALO90 system: a pilot study. *Gastrointest. Endosc.* 2008; 67(2):324-7

---

<sup>34</sup> Jana T, Thosani N, Fallon MB et al. Radiofrequency ablation for treatment of refractory gastric antral vascular ectasia (with video). *Endosc Int Open*. 2015; 3(2)E125-7