

1 **Immunotherapy-responsive childhood neurodegeneration with systemic and central nervous**
2 **system inflammation.**

3 Mario Sa¹, Yael Hacoheh¹, Lucy Alderson², WK 'Kling' Chong³, Glenn Anderson⁴, Thomas S Jacques^{4,5}, David
4 Neubauer⁶, Elzbieta Szczepanik⁷, Ming Lim^{8,9}, Marios Kaliakatsos¹

5

- 6 1. Paediatric Neurology, Great Ormond Street Hospital for Children, London, UK
7 2. Physiotherapy Department, Great Ormond street Hospital or Children, London, UK
8 3. Paediatric Neuroradiology, Great Ormond street Hospital or Children, London, UK
9 4. Department of Histopathology, Great Ormond Street for Children NHS Trust, London, UK
10 5. Developmental Biology and Cancer Program, UCL Great Ormond Street Institute of Child Health
11 6. Department of Child, Adolescent & Developmental Neurology, University Children's Hospital, Ljubljana,
12 Slovenia
13 7. Clinic of Neurology of Children and Adolescents, Institute of Mother and Child, Warsaw, Poland
14 8. Children's Neurosciences, Evelina London Children's Hospital @ Guy's and St Thomas' NHS
15 Foundation Trust, King's Health Partners Academic Health Science Centre, London, UK
16 9. Faculty of Life Sciences and Medicine, King's College London

17

18

19

20 Corresponding author: Dr Marios Kaliakatsos

21 Paediatric Neurology, Great Ormond Street Hospital for Children, London, UK.

22 Email: marios.kaliakatsos@gosh.nhs.uk

23

24

25 Running head: Immunotherapy responsive neurodegeneration

26 Word Count: 2013 Abstract: 139

27

28 Title: 98 characters

29 References: 11 Figure: 3 Video: 3 Table: 1

1 **Abstract**

2 Subacute neuroregression in association with raised neopterin and overexpression of interferon
3 stimulated genes (ISGs) could indicate a type 1 interferonopathy. Here we describe a novel
4 immunotherapy-responsive, clinico-immunological and imaging phenotype with evidence of innate
5 immune activation. Three children (patient 1: 22-month-old boy; patient 2: 5-year-old girl; patient 3: 4-
6 year-old girl) presented with asymmetric bilateral mixed dystonia and spasticity, regression in language
7 (expressive more than receptive) and bulbar symptoms with no evidence of seizures. Symptoms
8 evolved over several weeks to months. Brain MRI changes mimicked cerebral atrophy, initially
9 asymmetric. CSF revealed raised neopterins. Blood RNA assay showed abnormal overexpression of
10 ISGs and transient raised alanine aminotransferase (ALT). Importantly, all three children were treated
11 with intravenous methylprednisolone and immunoglobulin with significant and sustained improvement in
12 their motor and language function, and normalisation of imaging. Immune-mediated encephalitis can
13 masquerade as subacute neuroregression.

14

15

1 **Introduction**

2 Type I interferonopathies are a novel group of multiple monogenic autoinflammatory and autoimmune
3 disorders presenting with early-onset systemic and organ-specific disease and characterized by genetic
4 upregulation of the antiviral type I interferon axis with heterogeneous and expanding phenotypes. To
5 date 18 different causative genes have been identified¹. This was first described as the classical
6 phenotype of Aicardi-Goutières syndrome (AGS), a genetic leukoencephalopathy mimicking a
7 congenital infection and characterized by progressive cerebral atrophy, basal ganglia calcification and
8 lymphocytosis.

9

10 Interferons play an important role in the immune response against viral infections. The secretion of
11 these cytokines is normally induced by activation of recognition receptors of the innate immune system
12 after exposure to viral nucleic acids¹. Abnormalities in these test results can also occur in acquired
13 conditions such as autoimmune disorders and viral infections although not typically seen in antibody-
14 mediated encephalopathies^{2,3}. Until recently, it was difficult to directly measure type 1 interferon (IFN)
15 concentrations in biological samples. IFN activity is determined through IFN signature, meaning the
16 mRNA quantification of genes that are induced by IFN activity - interferon-stimulated genes (ISGs). A
17 neurological syndrome associated with raised neopterin and abnormal activation of ISGs could indicate
18 a type I interferonopathy.²

19

20 Here, we describe three children who presented with subacute motor and bulbar regression, mildly high
21 alanine aminotransferase (ALT), imaging appearances mimicking cerebral atrophy and an abnormal
22 ISGs who improved with immunotherapy suggestive of an acquired disorder. Written informed consent
23 for publication of the case description and the videos was obtained for all patients.

24

25 **Case 1:**

26 A previously well 22-month-old boy with a normal antenatal and developmental profile, presented with
27 fluctuating left sided hemiparesis. Five months later, following an intercurrent illness, he developed an
28 additional right-sided weakness and was unable to sit (Video 1). His speech regressed to 5 single
29 words only and he developed swallowing difficulties. There was no history of seizures, behavioural
30 deterioration or sleep problems. On examination, he had mixed dystonia and spasticity with increased
31 tone of all limbs, more marked in the lower limbs. There was sustained clonus on the left. He had
32 increased reflexes bilaterally (left more than right) with up-going plantars. There was mild facial
33 weakness on the left side but full range of ocular movements. Head circumference was normal. There

1 was no hepatosplenomegaly. Serial magnetic resonance imaging (MRI) of the brain demonstrated
2 progressive initially right hemispheric and subsequently evolving to global symmetric cerebral volume
3 loss (Figure 1-A). At 18 months from clinical presentation he was started on six weekly pulses
4 intravenous Methylprednisolone (IVMP, 30mg/kg/d), followed by six weekly IV Immunoglobulin (IVIG,
5 2g/kg). IVIG treatment is ongoing. This treatment resulted in improvement mainly in his fine motor and
6 non-verbal communication skills. Although less impressive, he showed improvement in his gross motor
7 skills and speech as well. He is now able to sit unsupported and is slowly gaining new vocabulary
8 (Video 1). Two years after treatment initiation brain MRI showed complete reversal of previous changes
9 and no other abnormalities. (Figure 1-B).

10
11
12 **Case 2:**

13 A previously well 5-year-old girl with a normal antenatal and developmental profile, presented with a
14 subacute onset over three months of left sided weakness, frequent falls and difficulties climbing stairs.
15 She was also unable to raise her left arm and had problems dressing and undressing. Her right side
16 was also affected and her handwriting deteriorated. Her speech deteriorated and she developed
17 swallowing difficulties with excessive drooling. There was no cognitive regression, sleep disturbance or
18 history of seizures. On examination, her speech was dysarthric. She had a mixture of spasticity and
19 dystonia with lower limbs more affected than upper limbs and left side more than right. Her tone was
20 increased bilaterally with sustained clonus on the left and upgoing plantars bilaterally. Head
21 circumference was normal. Brain MRI demonstrated generalized volume loss more marked in the right
22 cerebral hemisphere (Figure 1-C). Brain biopsy findings are summarised in Figure 2. At 12 months from
23 onset the patient was treated with four cycles of pulse IVMP (30mg/kg/d for 5 days) and IVIG (2g/kg)
24 three to four months apart. This resulted in significant improvement in her movement disorder and in all
25 domains of function (gross motor, fine motor and speech) (Video 2). Repeated imaging three years
26 after treatment showed normalisation of MRI appearances (Figure 1-D).

27
28 **Case 3:**

29 A previously well 4-year-old girl with mild gross motor developmental delay (walked independently at
30 the age of 21 months), presented with a progressive one-year history of frequent trips and falls,
31 difficulty climbing stairs, and progressive walking difficulty needing the aid of a wheelchair for outdoors
32 (Video 3). There was also five-month history of speech regression; initially slurred incomprehensible
33 words, followed by complete loss of expressive language. She had dysphagia with choking on solids
34 and liquids and drooling. Behavioural difficulties were also reported with frequent angry outbursts and

1 peer relationship problems. There was no history of seizures. On examination, her tone was increased
2 in the lower limbs with mixed spasticity and dystonia, right being worse than left and bilateral upgoing
3 plantars. She walked with a wide gait with both her knees hyperextended. There was drooling but no
4 cranial nerve abnormalities. Head circumference was below the 0.4th centile (no previous
5 measurements available for comparison). No hepatosplenomegaly was found. MRI brain showed mild
6 global cerebral volume loss mimicking atrophy (Figure 1-E). At 15 months from onset she had one
7 course of three days IVMP (30mg/kg/d), followed by IVIG (2g/kg) cycles, five courses over 20 months.
8 Marked improvement in her lower limb tone, with gain in both motor and expressive language skills,
9 was observed. A repeat MRI at 13 months after treatment initiation showed reversal of previous
10 changes (Figure 1-F). Currently, she is able to climb stairs unaided (Video 3), her speech is clear and
11 she can produce three to four word sentences.

12

13 Investigations, treatment and outcomes for all patients are summarized in Table 1.

14 All 3 patients were investigated for a range of infective, inflammatory and neurometabolic aetiologies,
15 none of which were identified. CSF in all patients showed no cells, normal protein and raised neopterin
16 at 355, 200 and 151nmol/L (normal range 7-65) respectively. Repeated CSF analysis showed
17 normalization of neopterins in patient 2 (29 nmol/L, 24 months after treatment) and reduction in patient
18 3 (93 nmol/L, 12 months after treatment). Patient 1 did not have CSF neopterins retested after
19 treatment initiation. Oligoclonal bands were negative. Blood RNA assay showed abnormal
20 overexpression of ISGs (Figure 3) and raised ALT (maximum 393U/L patient 2) in all patients. ISGs
21 were repeated in all three patients and have normalized in patients 1 and 2 but remain moderately
22 abnormal in patient 3 (Figure 3). ALT abnormalities eventually normalized in all patients. RNA
23 sequencing for viruses in brain biopsy was negative in patients 1 and 2. Liver and muscle biopsies in
24 patients 1 and 2 revealed no histochemical or enzymatic evidence of mitochondrial disorder. Patient 1
25 had a low complex IV (0.008; normal range: 0.014-0.034) on respiratory complex enzyme analysis, but
26 mitochondrial DNA sequencing and analysis for mitochondrial DNA deletion/rearrangements was
27 negative.

28

29 Genetic testing included whole exome sequencing for patients 1 and 2. This did not show any changes
30 in the genes known to be responsible for interferonopathies, nuclear genes associated mitochondrial
31 disorders, neurotransmitter disorders, early onset parkinsonism, dystonia associated disorders and
32 neurodegeneration with brain iron accumulation. Patient 3 underwent whole genome sequencing also
33 with no abnormalities identified so far (analysis not yet finalised). Testing for antibodies associated with

1 autoimmune encephalitis and serology screening for infections was negative. All patients had normal
2 electroencephalograms.

3
4 Patient's 2 brother presented at 11 months of age (3 months after his sister's presentation) with an
5 episode of vomiting and lethargy and was found to have raised ALT of 2000 U/L. The lethargy resolved
6 within 24 hours and he remained neurologically intact. He was also found to have elevated ISGs tested
7 acutely. Both his ALT and ISGs normalized after several months (Figure 3).

8 9 **Discussion:**

10 We describe three non-related previously well children who presented with a distinct clinical,
11 immunological and imaging phenotype. All patients presented with subacute deterioration in motor
12 function with a mixture of dystonia and spasticity, bulbar symptoms including dysphagia and excessive
13 drooling and regression of speech. None of the patients had seizures. Patients showed similar
14 biochemical profile with high serum ALT, raised CSF neopterin and abnormal overexpression of
15 interferon stimulated genes. Additionally, all the patients showed generalized changes mimicking
16 cerebral atrophy on brain MRI. This presentation could indicate a genetic type 1 interferonopathy, but
17 all patients were negative for the known genes. Importantly, they demonstrated a clear response to
18 immunotherapies with complete normalisation of the MRI appearances in all patients and normalization
19 of ISGs in patients 1 and 2. Patient 2 also showed normalization of CSF neopterin. Patient 3 still has
20 mildly abnormal ISGs and raised CSF neopterin and therefore she continues on IVIG treatment. The
21 increased ALT also normalized in all patients after a few months.

22
23 A notable difference between patient 1 and 2 is that brain biopsy in patient 1 showed only evidence of
24 gliosis whereas biopsy in patient 2 showed clear evidence of inflammation as well as tubuloreticular
25 inclusions. This may reflect different timings of biopsies from symptom onset. On the other hand, it has
26 been previously reported that in severe inflammatory brain disorders gliosis without evidence of
27 inflammation can be the only histopathologic finding.⁴ Tubuloreticular inclusions on ultrastructural
28 examination have been shown to be related to the presence of excessive interferon.⁵ In addition to
29 type 1 interferonopathies their presence has been linked to systemic lupus erythematosus and viral
30 infections. No evidence of these conditions was found in our patients. (REF) One cannot exclude the
31 possibility of a slow infectious encephalitis, from a potential unknown agent (viral or other). However,
32 the improvement with steroids makes this highly unlikely and deep RNA sequencing for viruses in brain
33 tissue was negative.

1 We believe that patient 1's abnormally low complex IV on respiratory complex analyses is either
2 secondary or spurious, as complex IV is the most sensitive of the assays to sample handling.
3 Furthermore, no other evidence of a mitochondrial disorder was found on biochemical or genetic
4 testing.

5
6 Rasmussen encephalitis presenting with slowly progressing hemiparesis without seizures has been
7 reported. However, the bilateral presentation seen in our cases makes this diagnosis unlikely⁶.

8 A diagnosis of an antibody mediated encephalitis could be considered. The authors believe that this is
9 also unlikely as no neuronal antibody has been identified and our patients' prolonged regression is not
10 typically seen in these disorders⁷. Nevertheless, the improvement in patient 3 with mainly only IVIG
11 leaves the possibility of an unidentified antibody mediated encephalitis open.

12
13 All patients were treated with pulse IVMP and IVIG and demonstrated a quick and substantial clinical
14 improvement in their motor function, bulbar symptoms and expressive language skills in the following
15 months after treatment. All 3 patients showed relentless deterioration for several months and
16 improvement was immediately noticed within days of treatment which makes the improvements
17 observed unlikely to be part of the natural history of this disorder. The mechanisms of action of both
18 IVIG and steroids may go beyond the known immunosuppressive and immunomodulative effect and
19 may also be beneficial in patients with primary genetic conditions⁸ and secondary inflammation⁹.

20
21 The milder systemic manifestation seen in the brother of patient 2 raised the possibility of an underlying
22 genetic disorder. Nevertheless, he has remained neurologically asymptomatic over the following years.
23 Several monogenic disorders mimicking acquired diseases have been described such as RANBP2¹⁰
24 and DARS⁸ and some may respond to immunotherapy. Although the phenotype of our patients is not in
25 keeping with these known disorders we cannot rule out a yet undiscovered monogenic disorder.
26 Alternatively, as previously reported in a child with AGS with acquired NMOSD¹¹, these patients could
27 have two different disorders with an underlying genetic predisposition and a second acquired insult.

28
29 We highlight the importance of evaluating children presenting with neurodegeneration of unknown
30 aetiology for CNS inflammation, assessing both innate and adaptive immunity biomarkers.

31 Immunotherapy should be considered in children presenting with this distinct phenotype of subacute
32 neuroregression, imaging appearances mimicking brain atrophy and evidence of innate immune
33 activation. This may reverse the course of the disease as exemplified by our cases.

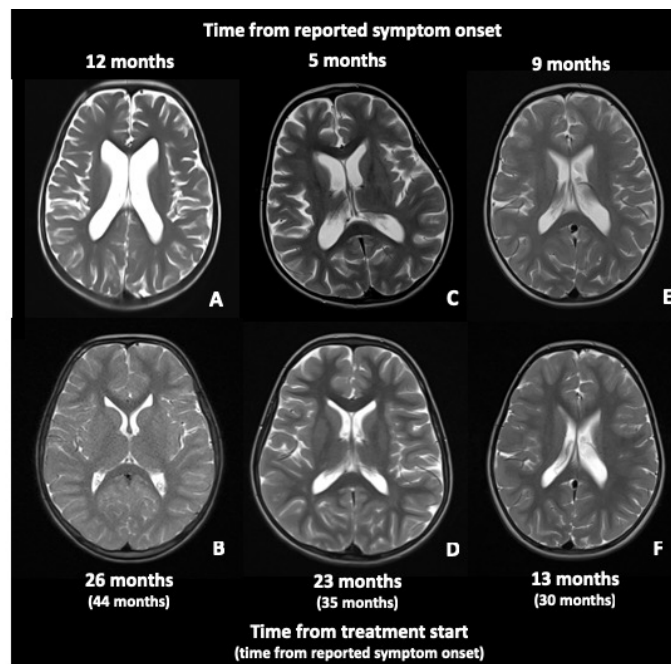
34

Acknowledgment

We are very grateful to the patients' families for providing the videos and consenting for us to report their cases. We are also grateful to: Dr Carlos DeSousa, Professor Yanick Crow and Dr Despina Eleftheriou for their thoughtful comments on the manuscript; Dr Gillian Rice for performing the ISG assays and for providing the relevant graphs; Dr Manju Kurian for performing whole exome sequencing in for patients 1 and 2. In addition, we would like to thank all the numerous allied health professionals caring for these children during their complex course of disease.

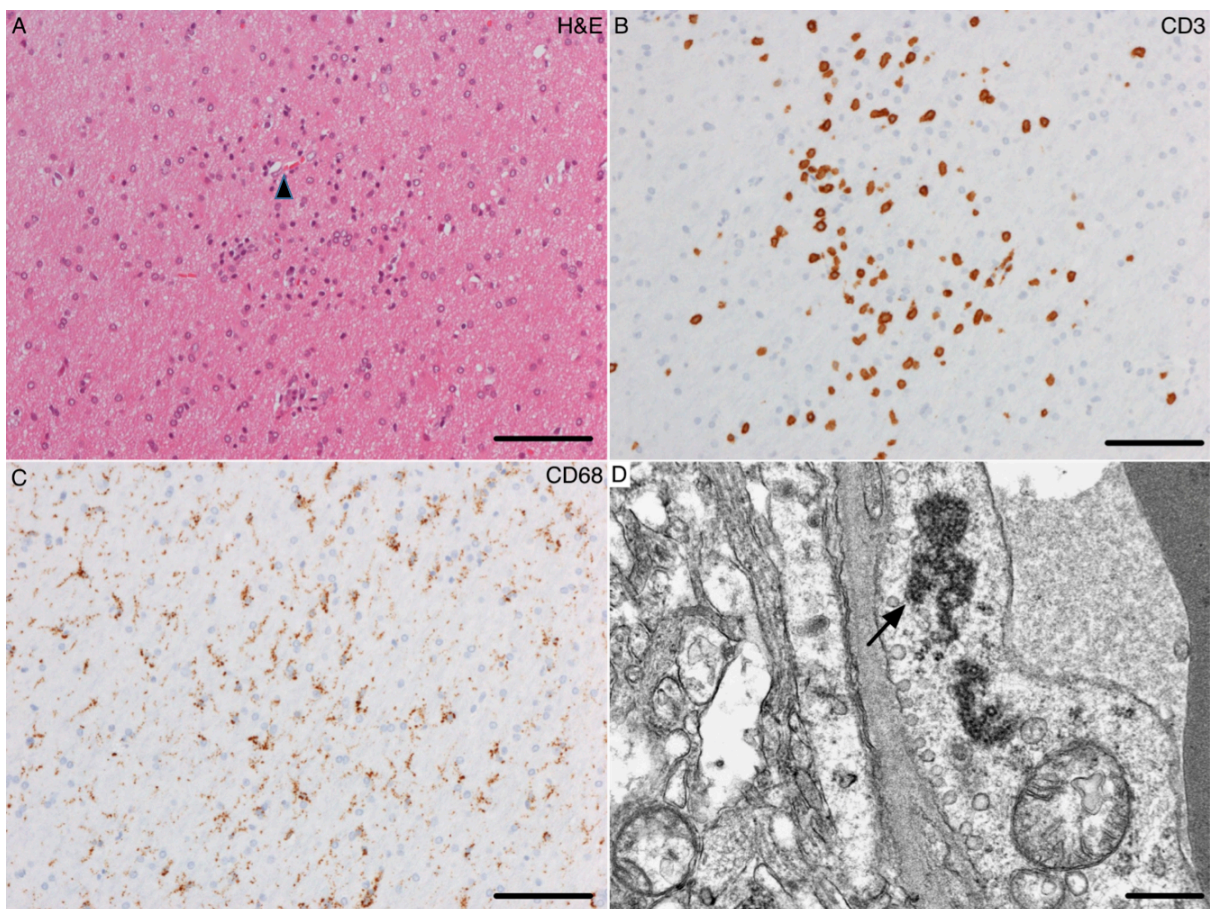
Figures

Figure 1



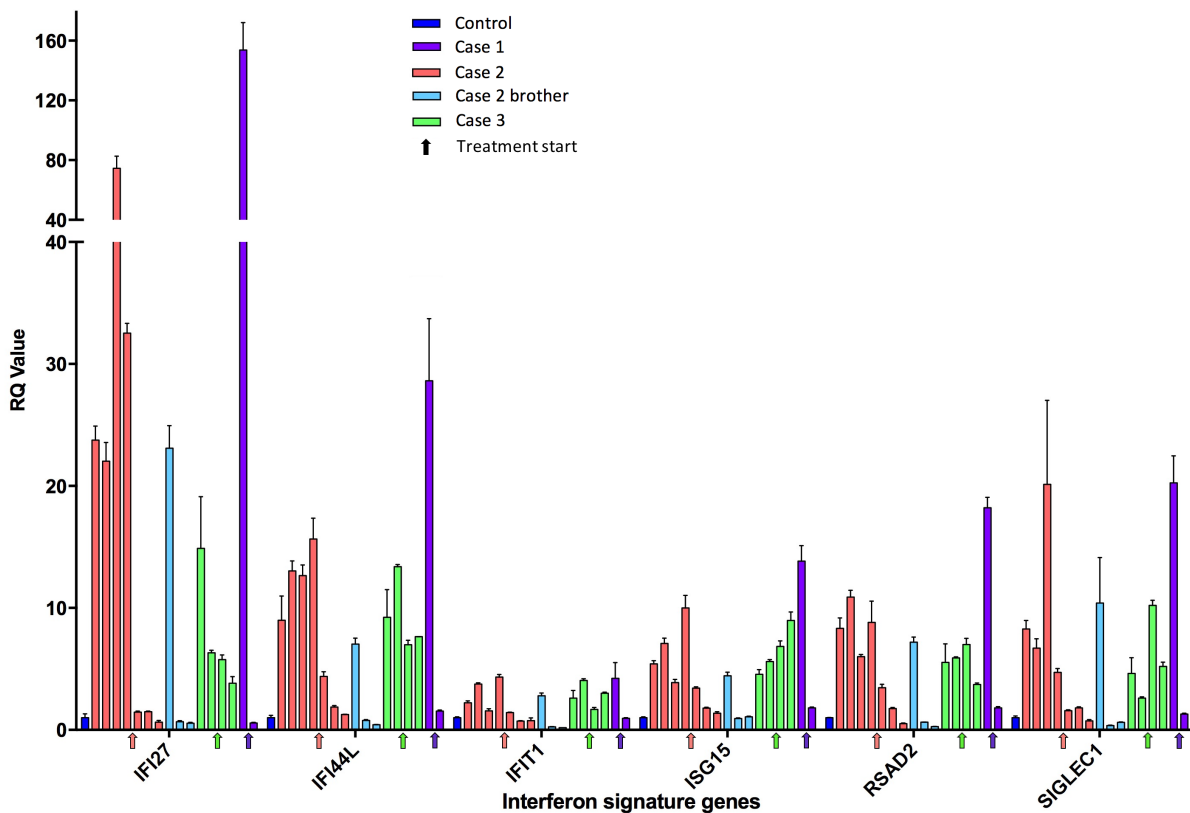
Brain MRI axial T2 images. A: Case 1 at 32 months (12 months after reported symptom onset): Bilateral ventricular and sulcal prominence evidencing volume loss. B: Case 1, 26 months after treatment: Complete reversal of previous changes. C: Case 2 at 5 years (5 months after reported symptom onset): Generalized volume loss more evident the right cerebral hemisphere. D: Case 2, 23 months after treatment: Significant reversal of the previously noted appearances of ventricular and sulcal prominence. E: Case 3 at 4 years (9 months after reported symptom onset): Slight reduction in the cerebral and cerebellar white matter bulk. F: Case 3, 13 months after treatment: Improvement of white matter bulk.

Figure 2



The figure shows the white matter from Case 2. There is a collection of chronic inflammatory cells (A-H&E), confirmed as a mixture of T-cells (B-CD3) and microglia (C-CD68) by immunohistochemistry. On ultrastructural examination by electron microscopy (D-EM), there were frequent tubuloreticular inclusions (arrow) in the endothelium. Scale bars: A, B & C 100nm D-500nm

Figure 3



Quantitative reverse transcription–polymerase chain reaction of a panel of six interferon stimulated genes (ISGs) in whole blood measured in the three patients and the brother of patient two compared with healthy control. The relative quantification (RQ) value is equal to $2^{-\Delta\Delta Ct}$, with $-\Delta\Delta Ct \pm SDs$ (ie, the normalized fold change relative to a calibrator).

Evidence of marked upregulation of type I interferon signaling was observed in all three patients and in patient's two brother. There was normalization of ISGs in patients 1 and 2 after treatment.

Age at sampling: Case 1, purple bars: 3 years and 3 months (pre-treatment); 4y8m (post-treatment).

Case 2, red bars: 5y3m; 5y4m; 5y5m; 5y9m (pre-treatment); 6y; 6y2m; 6y10m (post-treatment). Case 2's brother, light blue bars: 1y3m; 2y; 2y8m. Case 3, green bars: 4y7m; 5y (pre-treatment); 5y3m; 5y7m (post-treatment). Arrows under the X axis indicate treatment initiation.

Table

	Case 1	Case 2	Case 3
Brain MRI	Progressive right hemispheric evolving to global symmetric volume loss. Two years after treatment: complete reversal of changes.	Generalized cerebral volume loss more marked in the right cerebral hemisphere. Three years after treatment: reversal of MRI changes.	Mild reduction in the cerebral and cerebellar white matter bulk and some delay in maturation of myelin. One year after treatment: reversal of previous volume loss.
Brain histology	Patchy gliosis with good neuronal preservation and no significant inflammation.	Perivascular lymphocytes; focal collections of inflammatory cells in the white matter. Ultrastructural examination: frequent tubuloreticular inclusions in the endothelium.	---
Serum	ALT maximum: 90 U/L	ALT maximum: 393 U/L	ALT maximum: 37 U/L
CSF neopterin	240 and 355 nmol/L (7-65 nmol/L), not repeated after treatment	200 nmol/L (7-65 nmol/L), repeated 24 months after treatment: 29 nmol/L	151 nmol/L (7-65 nmol/L), repeated 12 months after treatment: 93 nmol/L
Genetics	Whole exome sequencing: no changes to the genes responsible for interferonopathies, mitochondrial disorders, neurotransmitter disorders, early onset parkinsonism, dystonia disorders and neurodegeneration with brain iron accumulation. No mutations found on gene panel sequencing <i>TREX1</i> , <i>ADAR1</i> , <i>RNASEH2A/B/C</i> , <i>IFIH1</i> , <i>SAMHD1</i> .	---	Whole genome sequencing ongoing: no changes identified so far.
Other investigations	All patients showed: no cells, normal proteins in CSF; oligoclonal bands negative in serum and CSF; testing for antibodies associated with autoimmune encephalitis and serology screening for infections negative; normal electroencephalograms.		
	Liver and muscle biopsies: normal, low complex IV in patient 1 (muscle), see text		---
Treatment	18 months from clinical presentation: - IV Methylprednisolone (30mg/kg), 6 weekly pulses followed by IV Immunoglobulin (2g/kg), monthly.	12 months from clinical presentation: - IV Methylprednisolone (30mg/kg, 5 days) and IV Immunoglobulin (2g/kg), 4 cycles, 3 months apart.	15 months from clinical presentation: - IV Methylprednisolone (30mg/kg, 3 days) only once, followed by IV Immunoglobulin (2g/kg), 5 cycles over 20 months, ongoing.
Outcome	Improvement mainly in fine motor, non-verbal communication. Also, gross motor skills and speech. Able to sit unsupported and gaining new vocabulary.	Significant improvement in movement disorder and in all domains of function: gross motor, fine motor and speech.	Improvement in lower limb tone, motor and expressive language skills. Now able to climb stairs unaided, produce three to four word sentences, behavior also normalised

Video 1 capture

Video 1: A video clip of the patient in Case 1 taken in four different time points. First clip at age two years and eleven months shows dystonic posturing of both upper limbs and difficulty to grasp objects. He also had some degree of axial hypotonia with curving of the spine. Second clip at age four years with obvious dystonic posturing and movements of all four limbs with both feet on equinovarus position. Third and fourth clip at age four years and a half after treatment shows him playing with toy and tablet computer with better upper limb posturing, grasp and fine motor skills.

Video 2 capture

Video 2: A video clip of the patient in Case 2 taken in two different time points. First clip at age six years and six months after treatment was started still presenting with abnormal gait pattern with increased tone and bilateral dragging her feet more marked on the left side (this was already improved compared to presentation). Second and third clips at age eight years walking up and down the stairs independently with an improved gait and riding a bicycle without any difficulties.

Video 3 capture:

Video 3: A video clip of the patient in Case 3 taken in four different time points. First clip at age four years mainly showing the complete loss of expressive speech. Second clip at age four years and six months shows a spastic/dystonic gait characterized by a wide base, hyperextended knees and feet posture into equinovarus. She was only able to walk independently for a few seconds. Third clip at age five years and eleven months shows some dystonic posturing while grasping but already with significant improvement compared to pre-treatment state. Fourth clip at age six years and four months shows her independent gait with internal rotation of both feet, more noticeable on the right side.

Reference

1. Rodero MP, Crow YJ. Type I interferon-mediated monogenic autoinflammation: The type I interferonopathies, a conceptual overview. *J Exp Med* 2016; **213**(12): 2527-38.
2. Rice GI, Forte GM, Szykiewicz M, et al. Assessment of interferon-related biomarkers in Aicardi-Goutieres syndrome associated with mutations in TREX1, RNASEH2A, RNASEH2B, RNASEH2C, SAMHD1, and ADAR: a case-control study. *Lancet Neurol* 2013; **12**(12): 1159-69.
3. Dale RC, Brilot F. Biomarkers of inflammatory and auto-immune central nervous system disorders. *Curr Opin Pediatr* 2010; **22**(6): 718-25.
4. van Baalen A, Hausler M, Boor R, et al. Febrile infection-related epilepsy syndrome (FIRES): a nonencephalitic encephalopathy in childhood. *Epilepsia* 2010; **51**(7): 1323-8.

5. Goutieres F, Aicardi J, Barth PG, Lebon P. Aicardi-Goutieres syndrome: an update and results of interferon-alpha studies. *Ann Neurol* 1998; **44**(6): 900-7.
6. Varadkar S, Bien CG, Kruse CA, et al. Rasmussen's encephalitis: clinical features, pathobiology, and treatment advances. *Lancet Neurol* 2014; **13**(2): 195-205.
7. Lim M, Hacoheh Y, Vincent A. Autoimmune encephalopathies. *Pediatr Clin North Am* 2015; **62**(3): 667-85.
8. Wolf NI, Toro C, Kister I, et al. DARS-associated leukoencephalopathy can mimic a steroid-responsive neuroinflammatory disorder. *Neurology* 2015; **84**(3): 226-30.
9. Kile S, Au W, Parise C, et al. IVIG treatment of mild cognitive impairment due to Alzheimer's disease: a randomised double-blinded exploratory study of the effect on brain atrophy, cognition and conversion to dementia. *J Neurol Neurosurg Psychiatry* 2017; **88**(2): 106-12.
10. Neilson DE. The interplay of infection and genetics in acute necrotizing encephalopathy. *Curr Opin Pediatr* 2010; **22**(6): 751-7.
11. Hacoheh Y, Zuberi S, Vincent A, Crow YJ, Cordeiro N. Neuromyelitis optica in a child with Aicardi-Goutieres syndrome. *Neurology* 2015.