

CASE REPORT

Familial absent uvula with velopharyngeal incompetence - a new syndrome?

Brian Sommerlad, FRCS¹, Rimante Seselgyte, MD², Melissa Lees, MD¹, Erwin Pauws, Ph.D³, Philip Stanier, Ph.D², Debbie Sell, Ph.D^{1, 4}

¹North Thames Cleft Centre, Great Ormond Street Hospital for Children NHS Foundation Trust, London and St Andrew's Centre, Broomfield Hospital, Chelmsford, Essex UK

²Genetics and Genomic Medicine, UCL GOS Institute of Child Health, London

³Developmental Biology and Cancer, UCL GOS Institute of Child Health, London

⁴Centre for Outcomes and Experience Research in Children's Health, Illness and Disability (ORCHID), Great Ormond Street Hospital for Children NHS Foundation Trust, London

Corresponding Author:

Brian Sommerlad

25 Doughty Mews, London WC1N 2PF, UK.

Tel: 00447860309133

Fax: 00441245421901

E-mail: brian@sommerlad.co.uk

Meeting presentation: A brief presentation was given at the meeting of the Craniofacial Society of Great Britain and Ireland on 4th April 2019

Running Title (8 words or less): Familial absent uvula with velopharyngeal incompetence

Statement acknowledging financial support: *Research at GOSH is supported by the NIHR. The views expressed are those of the authors and not necessarily those of the NHS, the NIHR or the Department of Health. This research was also supported by the NIHR Great Ormond Street Hospital Biomedical Research Centre. Dr Seselgyte's research grant is provided by CLEFT – "Bridging the Gap".*

ABSTRACT

We present a family with a previously undescribed abnormality of the palate and oropharynx which involved absence of the uvula and the anterior pillar of the fauces, rudimentary posterior pillar of the fauces and hypernasality. Eight family members over four generations are affected in a pattern consistent with autosomal dominant inheritance. A causal role for the *FOXF2* gene has been identified and previously reported. We describe the management of the proband, which involved attempting to lengthen the palate and to reposition the abnormally anteriorly directed velar musculature, along with speech therapy.

KEY WORDS: *familial; absent uvula; FOXF2; hypernasality; velopharyngeal incompetence; speech disorder.*

INTRODUCTION

Complete absence of the uvula appears to be a very uncommon congenital anomaly. In an examination of 2,258 neonates, only one was said to have an absent uvula (Jorgenson et al., 1982). Most apparently reported cases in the literature appear to refer to patients with submucous cleft palates or asymmetrical palate defects or to patients who may have had

surgery. Specifically, there are no descriptions of familial absent uvula associated with other abnormalities of the oropharynx that present with hypernasality.

CASE REPORT

History

A boy from Egypt, was referred to the first author at 3 years of age, with a history of occasional nasal regurgitation during breastfeeding in infancy, speech and language delay and hypernasality. At the age of 2 years, he could only say “mama”, “nonna” and “no”. He had commenced speech therapy at the age of 2 ½ years. Ventilation tubes were inserted soon afterwards. It was then recognized that he had hypernasality. His motor development was reportedly normal.

Examination of the patient

On examination, the patient (IV.5) demonstrated no obvious syndromic features apart from slight hooding of the upper eyelids *Figure 1*. On intraoral examination, he had an absent uvula and the posterior border of the soft palate appeared short and tight with poor velar movement on phonation of the vowel /a/. The anterior pillar of the fauces appeared to be absent and the posterior pillar was rudimentary as shown in *Figure 2*.

Family history

There was a history of eight affected family members in four generations, each having what was described as “absent uvulae” and hypernasality (*Figure 3*). Affected family members included the patient’s father and paternal grandmother. None of the family members had had surgical correction for hypernasal speech.

Examination of family members

The patient's father (III.3), paternal grandmother (II.2), grandmother's sister (II.3) and her daughter (III.6) (*Figure 3*) were also examined and their speech was recorded either in the UK or Egypt. They were not assessed by a specialist cleft speech and language therapist but all appeared to the cleft surgeon (BS) to be mildly hypernasal. The patient's grandmother's brother (II.6) lived in Sinai and was reported to have absent uvula and hypernasal speech. His daughter (III.8) also lived in Sinai and could not be examined, but sent palatal photographs and a speech video. None of these 5 family members had any obvious syndromic features. All regarded themselves as having nasal speech and all had an almost identical appearance of the soft palate with an absent uvula and a tight posterior border of the velum (*Figure 4*). The non-affected sibling (III.5) of III.6 was also examined. His speech was recorded and was not hypernasal. A study to identify the genetic basis of this phenotype is described elsewhere (Seselgyte et al, 2019).

Speech and language assessment and observations

The patient (IV.5) was seen at age 3.1 years by the specialist speech pathologist (DS). He was bilingual (Arabic and English). The assessment was conducted in English. His attention and listening skills were noted to be immature. In the main, he was using single words, with some two and occasional three-word utterances. He used nonverbal means to communicate including pointing, taking the adult to what he wanted, and gestures. He had receptive and expressive language delay with a greater deficit in his expressive language.

He presented with mild hypernasality, with accompanying nasal emission on targets /p, b/. There was variability in intraoral pressure, ranging from weak nasalized plosives to an absence of oral pressure e.g. /b/ > [m], /d/ > [ng]/. His sound system was characterized by several cleft speech characteristics: backing to velar for plosives and fricatives, glottal stops, glottal reinforcement and active nasal fricatives (Sell et al., 1999). He also had some unusual realisations, for example velar nasals for oral plosives, and syllabic nasals, where the vowel in

a syllable is replaced with a nasal consonant. Developmental immaturities included syllable elision, consonant harmony, and stopping. On a task of sound stimulability, it was possible to elicit /p, b, f/ and with facilitators /d, k, g/ suggesting potential for change with therapy even without surgery. He had a weak and breathy voice quality. He therefore presented with a severe speech disorder, with velopharyngeal incompetence as a feature.

Lateral videofluoroscopy

The velum appeared thin, and lift was poor (better with /a/ than with /i/). With many sounds, palate movement was produced by the tongue, but there was some active velar movement when the levator knee appeared to be somewhat anterior, notably on repetition of 'ba'. The palate never lifted to the plane of the hard palate and there was a consistent velopharyngeal gap with active movement as seen on the syllable 'ba'. The palate appeared short with only small adenoids above and at the plane of attempted closure. There was some slight movement of the posterior pharyngeal wall.

Management

It was decided to carry out a surgical exploration of the palate in the first instance, with the aim of retro-positioning the muscle insertions and improving velar function. Parents were warned that further surgery may be necessary.

Surgery was carried out under general anaesthetic when the patient was 3.4 years of age. The findings on examination of the palate (*Figure 5*) confirmed that there was no uvula and no anterior pillar of the fauces, with a rudimentary posterior pillar and a tight posterior border of the velum. The posterior nasal spine was broad but there was no significant notch. There was significant adenoid tissue.

On exploration of the velar musculature, the palatopharyngeus and levator muscles were directed somewhat anteriorly. They were retro-displaced and at the same time the palate lengthened by suturing the posterior pillars of fauces together and then releasing them postero-laterally at the junction with the tonsils. The levator muscles were of reasonable bulk and were sutured together in the midline as posteriorly as possible.

Follow-up

The patient was seen for reassessment by the specialist speech pathologist seven months after surgery, at age 4.0 years. In the interim period, he had received language therapy in Egypt twice a week by one therapist and therapy for the speech disorder thrice weekly by another. It was noted how he had made considerable progress in his language skills, now using 4 and sometimes 5-word sentences, according to his parents.

In his spontaneous speech, he was judged to have moderate hypernasality, but in words and syllables with the correct bilabial plosives, in the context of both high and low vowels, he had oral tone e.g. on words such as baby, bay, poppy, piper, paper. There was no longer accompanying nasal emission on targets such as /p, b/. The pattern of favoured placement of backed consonants to velar, with velar nasal fricatives and frequent syllabic nasals was still present. However, he was now inconsistently using targets /t, d/. There was still the developmental immaturity of consonant harmony, which needed to be taken into account in the vocabulary used in therapy. In terms of stimulability, a range of consonants not used in his sound system /f, n, s, sh, ge/ were elicited.

Follow-up videofluoroscopy showed improved palate mobility and lift to above the plane of the hard palate. The tongue was no longer involved in lifting the velum. The levator insertion, the point of maximum velar mobility, was very posterior. Firm closure to the posterior pharyngeal wall appeared to be achieved on this view (*Figure 6*).

In summary, the patient was judged to now have the structure to make considerable progress in establishing his sound system and resolving his unintelligibility problems. Parents were counselled that there may be some residual mild hypernasality, but this would only be known once the sound system difficulties had resolved.

At further review at age 5 and 7 years, his speech was within normal limits.

DISCUSSION

We have described the clinical findings and management of a three-generational family with absent uvulae and abnormal features of the oropharynx, associated with hypernasality, segregating in an autosomal dominant way. The presenting patient (IV.5) had a significant speech disorder and language delay associated with velopharyngeal incompetence, which led to a referral to a Cleft Lip and Palate team for management. The other family members had less severe hypernasality, and did not present with problems in their sound systems according to family report. They were not considered candidates for surgery. This may be in part be due to the more severe speech disorder in the patient, although may also reflect a lack of available services in Egypt in previous generations and society's acceptance of speech differences.

Velar surgery was performed on the patient when he was 3 years old. The operation involved lengthening the palate by suturing together the posterior pillars of the fauces and then releasing them inferiorly together with dissection and repositioning of the palate musculature – especially the levator (Sommerlad 2003; Sommerlad 2015). Follow-up seven months after surgery demonstrated significant improvement in speech, evidenced from the perceptual assessment, and velar function as demonstrated on lateral videofluoroscopy, and

he went on to completely resolve his speech difficulties supported by speech therapy intervention.

There are two interesting observations to be made. First, hypernasality was described as mild in degree preoperatively and moderate postoperatively, suggesting perhaps a lack of improvement with surgery. There was however important evidence of oral tone in the context of correct consonant production across both high and low vowels. This latter observation was very important in advising on the need for continuing therapy and likely success of the surgery. The apparent conflicting evidence of worsening hypernasality was a direct result of longer utterances postoperatively reflecting the resolving language delay observed at the initial appointment. Second, postoperative management recommended continuing therapy for the persistent articulation difficulties, not structurally related speech phenomena of hypernasality or nasal emission. Correcting the nasal fricatives and syllabic nasals resulted in habituating oral tone throughout speech, evidence for which was found at the postoperative assessment. He continued to be seen annually by the surgeon (BS). At the age of 5 and 7 years, his speech was recorded. There was complete speech resolution of the articulatory difficulties.

To our knowledge, absent uvula has not previously been reported as a familial occurrence. Nor has it been described with the other abnormalities of the oropharynx as described in all of the affected members in this family. The inheritance pattern is consistent with being autosomal dominant. Genetic and cytogenetic studies described in detail elsewhere (Seselgyte et al., 2019) show fully penetrant inheritance of a nonsynonymous, missense change in the gene *FOXF2*. This is closely associated with a nearby tandem duplication in 6p25.3. *Foxf2* has previously been established to play a crucial role in palate development in the mouse, with a gene knock out resulting in cleft palate (Wang et al., 2003). Expression of *Foxf2* in the mouse palate is restricted to the most posterior region at around the time of

palatal fusion (Nik et al., 2016). It is notable that mice inherently lack a uvula, but expression of *FOXF2* has recently been demonstrated in the developing human uvula (Seselgyte et al., 2019). It is not yet possible, in this family alone, to untangle the potential contributions or interactions of the tandem duplication from the *FOXF2* missense variant (Seselgyte et al., 2019). It will therefore be of great interest to identify further individuals or families with a similar phenotype in order to further investigate the genotype/phenotype correlation.

DECLARATION OF CONFLICTS OF INTEREST:

The Authors declare that there are no conflicts of interest.

REFERENCES:

Jorgenson RJ, Shapiro SD, Salinas CF, Levin LS. Intraoral findings and anomalies in neonates. *Pediatrics* 1982;69:577-582.

Nik AM, Johansson JA, Ghiami M, Reyahi A, Carlsson P. Foxf2 is required for secondary palate development and Tgfbeta signaling in palatal shelf mesenchyme. *Dev Biol* 2016;415:14-23.

Sell, D., Harding, A., & Grunwell, P. Revised GOS. SP. ASS (98): an assessment for speech disorders associated with cleft palate and/or velopharyngeal dysfunction. *Int J Lang Commun Disord* 1999;34:17-33.

Seselgyte R, Bryant D, Demetriou C, Ishida M, Peskett E, Moreno N, Morrogh D, Sell D, Lees M, Farrall M, Moore GE, Sommerlad B, Pauws E, Stanier P. Disruption of *FOXF2* as a likely cause of absent uvula in an Egyptian family. *J Dent Res* 2019; (in press).

Sommerlad BC. A technique for cleft palate repair. *Plast & Reconstr Surg* 2003;112:1542-1548.

Sommerlad BC. Cleft palate Repair with Minimal Hard Palate Dissection and Radical Muscle Reconstruction. Losee J & Kirschner R, eds *Comprehensive Cleft Care* 2nd Edition 2015 McGraw-Hill

Wang T, Tamakoshi T, Uezato T, Shu F, Kanzaki-Kato N, Fu Y, Koseki H, Yoshida N, Sugiyama T, Miura N. Forkhead transcription factor Foxf2 (LUN)-deficient mice exhibit abnormal development of secondary palate. *Dev Biol* 2003;259:83-94.

LEGENDS FOR FIGURES

Figure 1. The patient (IV.5) at 3 years and 4 months.

Figure 2. Oral view of the patient's (IV.5) palate. This image was recovered from a video still.

Figure 3. Family tree of the patient. The proband IV.5 is indicated with an arrow. The method of oral examination is indicated as:

§ seen in person, video recording, and photograph taken;

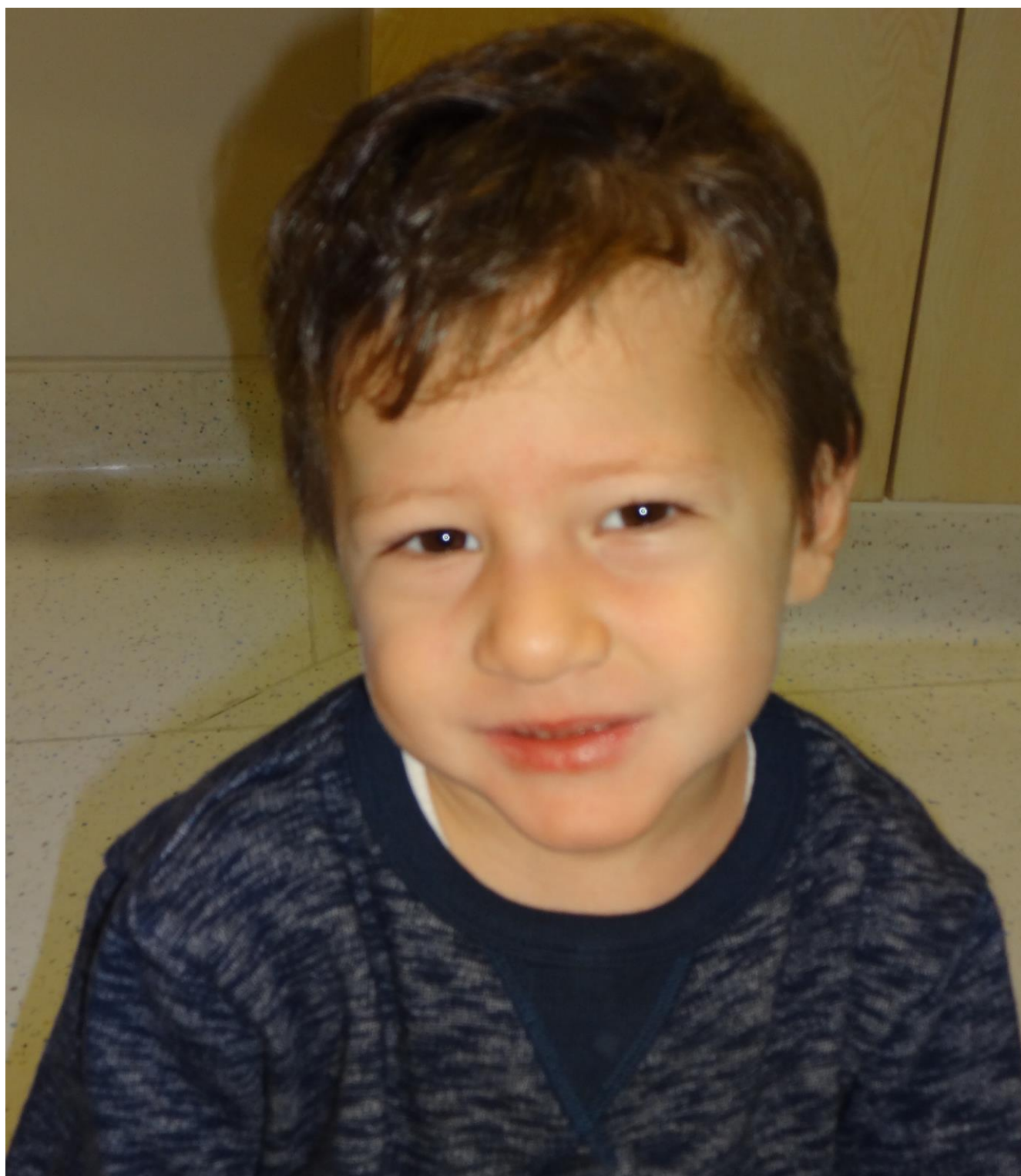viewed on video only, and photograph taken.

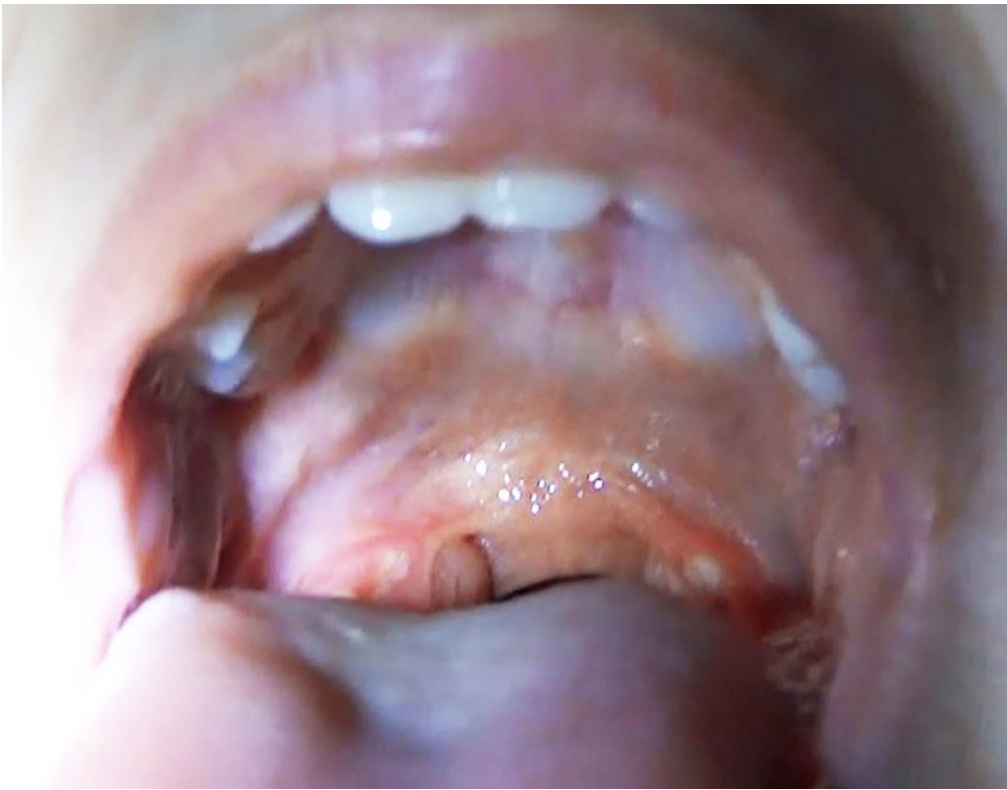* indicates DNA sample and participated in genetic studies.

Figure 4. Intra-oral views of 5 of the 6 living affected relatives of IV.5 with the two 2nd generation members (including his grandmother – II.2) above and the three 3rd generation members (including his father – III.3) below.

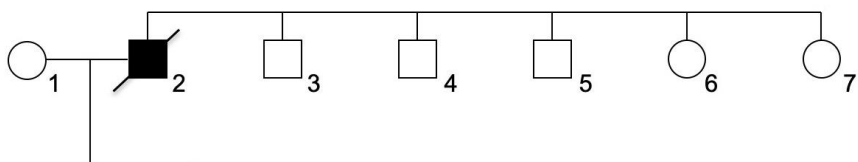
Figure 5. View of the palate before and during operation. Pre-operative (above). T = tonsil; SP = soft palate; HP = Hard palate. Velar muscles shown before retropositioning (below left) and after reconstruction (below right).

Figure 6. Stills taken from lateral videofluoroscopy. The patient is saying /i/. Pre-operative (left) and at 7 months after the operation (right).

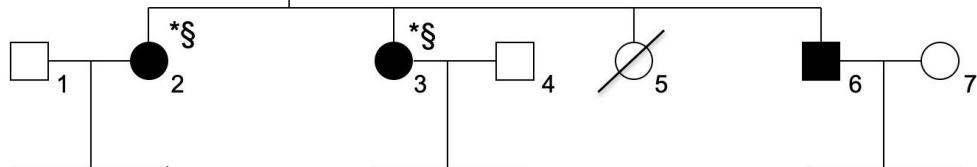




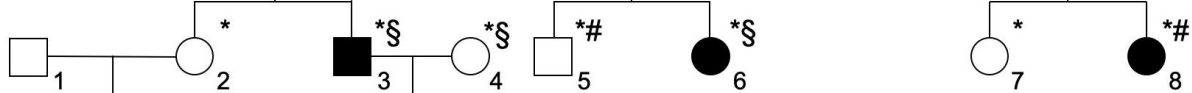
I



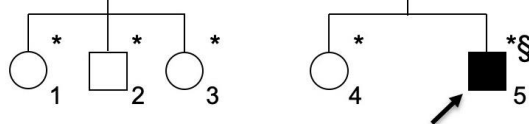
II



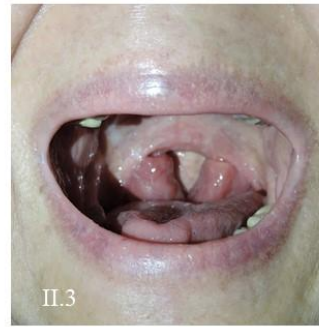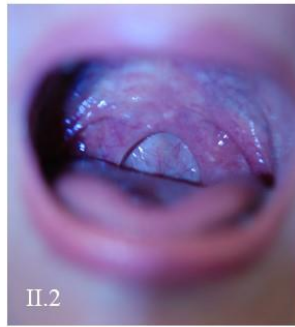III



IV



2nd generation



3rd generation



