

TITLE

IgM paraprotein-associated peripheral neuropathy: small volume CD20 positive B-cell clones may predict a monoclonal gammopathy of neurological significance and rituximab responsiveness

AUTHORS

Lucia Y Chen¹, Stephen Keddie^{2,3}, Michael P Lunn^{2,3}, Joshua Bomsztyk¹, Evan Vitsaras⁴, Rajeev Gupta⁵, Shirley D'Sa¹

AFFILIATIONS

¹Cancer Division, University College London Hospitals NHS Foundation Trust, London; ²MRC Centre for Neuromuscular Disease, National Hospital of Neurology and Neurosurgery and Department of Molecular Neuroscience, UCL Institute of Neurology, London; ³Neuroimmunology and CSF laboratory, UCL Institute of Neurology, National Hospital for Neurology and Neurosurgery, University College London Hospitals NHS Foundation Trust, London; ⁴Manual Blood Sciences, HSL Pathology, London; ⁵Stem Cell Group, UCL Cancer Institute, London

CORRESPONDING AUTHOR

Shirley D'Sa
Cancer Division
University College London Hospitals NHS Foundation Trust
3rd Floor West, 250 Euston Road, London, NW1 2PG
Email: s.d'a@nhs.net
Phone: 0203447101
Fax: 02034479911

WORD COUNT:

1500

FIGURE/TABLE COUNT

Figures: 1

Tables: 1

REFERENCE COUNT

15

ABSTRACT

IgM paraprotein-associated peripheral neuropathy in patients without overt evidence of lymphoma is a recognised clinical entity of unknown aetiology. Interrogating the bone marrow B-cell or plasma cell clones underlying paraproteinemic neuropathies may help our understanding of both pathogenesis and treatment options. In this retrospective observational analysis of patients with IgM paraprotein-associated PN from our tertiary Neurohaematology service, we identify five patients who have small pathological MYD88 and CD20 positive B-cell clones in their bone marrow using multi-parametric flow cytometry, all of whom have shown durable neurological response to rituximab treatment. We posit that multi-parametric flow cytometry may be instrumental in identifying the cellular source of the paraprotein in IgM paraprotein-associated PN and therefore in directing appropriate immunomodulatory therapy. Further understanding of these small pathological B-cell clones may also provide additional insight into mechanisms of Monoclonal Gammopathy of Clinical Significance overall.

INTRODUCTION

IgM paraprotein-associated peripheral neuropathy (PN) is a rare clinical entity associated with a spectrum of plasma cell dyscrasias ranging from monoclonal gammopathy of undetermined significance (MGUS) to Waldenström's macroglobulinaemia (WM). Approximately 30-50% of patients with IgM MGUS (Nobile-Orazio et al 1992) and up to 50% with WM experience PN (Levine et al 2006). Observational studies have shown that around 30% of patients with IgM paraprotein-associated PN have moderate disability, requiring assistance with daily activities 10 years after diagnosis and around 50% require walking aids (Niermeijer et al 2010).

Progressive PN alone is an indication for starting chemo-immunotherapy in patients with WM, who would have otherwise followed an expectant policy (Dimopoulos et al 2014). Patients with IgM MGUS, worsening PN and no overt WM or lymphoma may still receive immunomodulatory therapy, such as rituximab, if they have evidence of causal antibodies to a neural target, such as anti-myelin associated glycoprotein (MAG) antibodies (D'Sa et al 2017); around 40-50% of IgM paraprotein-associated neuropathies are related to a positive anti-MAG antibody (Chaudry et al 2017). Trials of rituximab therapy in anti-MAG neuropathy have shown variable outcomes (Lunn and Nobile-Orazio 2016), and few predictive factors of responsiveness to rituximab have been elucidated.

Existing treatments often aim to reduce the IgM paraprotein concentration or antibody load by targeting the underlying bone marrow clonal population. Currently, bone marrow examinations are only indicated for obvious malignant progression, therefore the cellular source of the pathological paraprotein is often unconfirmed although typically assumed to be either a monoclonal plasma cell or B-cell clone.

Delineating the precise cellular source may provide insight into the pathophysiology of IgM paraprotein-associated PN and therefore aid treatment. Recent studies have shown a high prevalence of the MYD88 L265P mutation in anti-MAG neuropathy (Vos et al 2017). Whilst the MYD88 mutation is known to be a driver mutation in WM, its significance in the pathogenesis of anti-MAG neuropathy in the absence of overt WM remains unclear.

We present a group of patients with IgM paraprotein-associated anti-MAG PN and no overt evidence of B-cell or plasma cell malignancy, who were found to have small volume CD20 and MYD88 L265P positive B-cell clones that may predict rituximab responsiveness.

PATIENTS AND METHODS

Between January 2015 and May 2018 we saw 66 different patients who had both IgM paraproteinaemia and neuropathy in our Neurohaematology tertiary referral clinic; of these, 20 had bone marrow examination with multi-parameter flow cytometry (MFC) (Figure 1).

MFC was added to our standard diagnostic algorithm for bone marrow examination in cases of suspected lymphoma. Two commercially sourced 10-colour antibody panels (DuraClone, Beckman Coulter) were designed for this purpose (i) CD3, CD4, CD5, CD8, CD10, CD19, CD20, CD23, CD25, CD45, FMC7, kappa, lambda and (ii) CD45, CD19, CD22, CD38, CD10, CD79b, CD13, CD34, kappa and lambda; the samples were run on Navios Flow Cytometers (Beckman Coulter). Red blood cells in whole bone marrow samples were lysed using a Q-Prep workstation. Nucleated cells were then washed in PBS three times before re-suspending in PBS and 22% bovine serum albumin. We established normal ranges using bone marrow samples from 34 patients who did not have haematological malignancies. Data analysis was with Kaluza software (Beckman Coulter).

RESULTS

A separate group of 5 patients with phenotypically abnormal B-cell clones accounting for <3% total bone marrow cellularity but without radiological or histological evidence for lymphoma was identified (Table 1). All were isotype-restricted and positive for CD19, CD20, CD79b, with variable expression of CD5, CD10 and CD23. Whilst our MFC panels were not specifically designed to detect plasma cells, no patient had increased or abnormal plasma cells in the marrow aspirate using this method or in the trephine biopsy by immunohistochemistry. All 5 patients tested positive for the MYD88 L265P mutation by quantitative PCR (sensitivity 0.5%). CXCR4 mutation analysis was available in 3 out of 5 patients and negative in all.

The median age of this group was 62 years (range 45 to 78 years; 3 M and 2 F). All patients presented with chronic progressive sensorimotor neuropathy, with median symptom duration of 4 years (range 2 to 13 years) and median Overall Neuropathy Limitations Scale (ONLS) (Graham and Hughes 2006) score of 3 (range 3 to 5) pre-treatment. This was similar when compared to a random sample of 10 patients with IgM paraprotein-associated PN who did not undergo bone marrow examination (median presenting ONLS score of 3, range 1 to 6). No patients in this group had received prior chemotherapy or immunotherapy.

All 5 patients had low-level IgM-kappa paraproteinaemia; the median pre-treatment IgM paraprotein level was 3 g/L (range 1.4 g/L to 6 g/L). Median pre-treatment haemoglobin (available for 4 patients) was 139 g/L (range 127 g/L to 151 g/L). Four of the 5 patients had cerebrospinal fluid

(CSF) analysis and median CSF protein was 0.66 mg/dL (range 0.5 mg/dL to 0.72 mg/dL); all had negative CSF cytology.

Three patients had 'strong positive' (>70000 Bühlmann titre Units (BTU, Bühlmann Laboratories AG, Switzerland)) anti-MAG antibody titres, and two had 'positive' anti-MAG antibody (7000-70000 BTU). All patients had neurophysiological features consistent with anti-MAG neuropathy.

Four out of 5 patients had previously failed treatment with steroids, intravenous immunoglobulin (IVIg) or both and went on to receive treatment with rituximab monotherapy (375mg/m² weekly for four weeks). The fifth patient was lost to follow-up. Response to treatment was measured clinically. Of the 4 patients who were treated, 1 patient had near-resolution of neuropathy, and was discharged from our service. One patient, who also had multiple comorbidities showed an improvement of ONLS score from 4 to 3. In 1 patient, 2 courses of 4-weekly rituximab halted progression of PN symptoms. Based on as-yet unpublished evidence that low dose rituximab maintains B-cell suppression, further 3-monthly low-doses of 100mg/m² rituximab were administered for 12 months and resulted in additional improvement. Another patient required a second course of 4-weekly rituximab after a 4-year interval because of a relapse of PN symptoms despite initial significant improvement of numbness and weakness in his feet. With a median follow-up of 25 months (range 18 to 107 months), none of these 4 patients is known to have developed WM, myeloma or any other lymphoproliferative disorder.

DISCUSSION

We describe a novel finding of anti-MAG paraproteinaemic neuropathy associated with small volume CD20 and MYD88 L265P positive B-cell clones in the bone marrow, in the absence of lymphoma or myeloma.

In our cohort, all clones detected via MFC were CD20 positive, and affected patients have shown durable neurological improvement following rituximab monotherapy. The response to anti-CD20 therapy supports the hypothesis that the abnormal B-cell clones we identified may be the cellular source of the IgM paraprotein in these patients and instrumental in the pathophysiology of neural damage. These small CD20-positive B-cell clones may cause clinical manifestations without massive clonal expansion, but through other immune-mediated mechanisms such as immunoglobulin deposition.

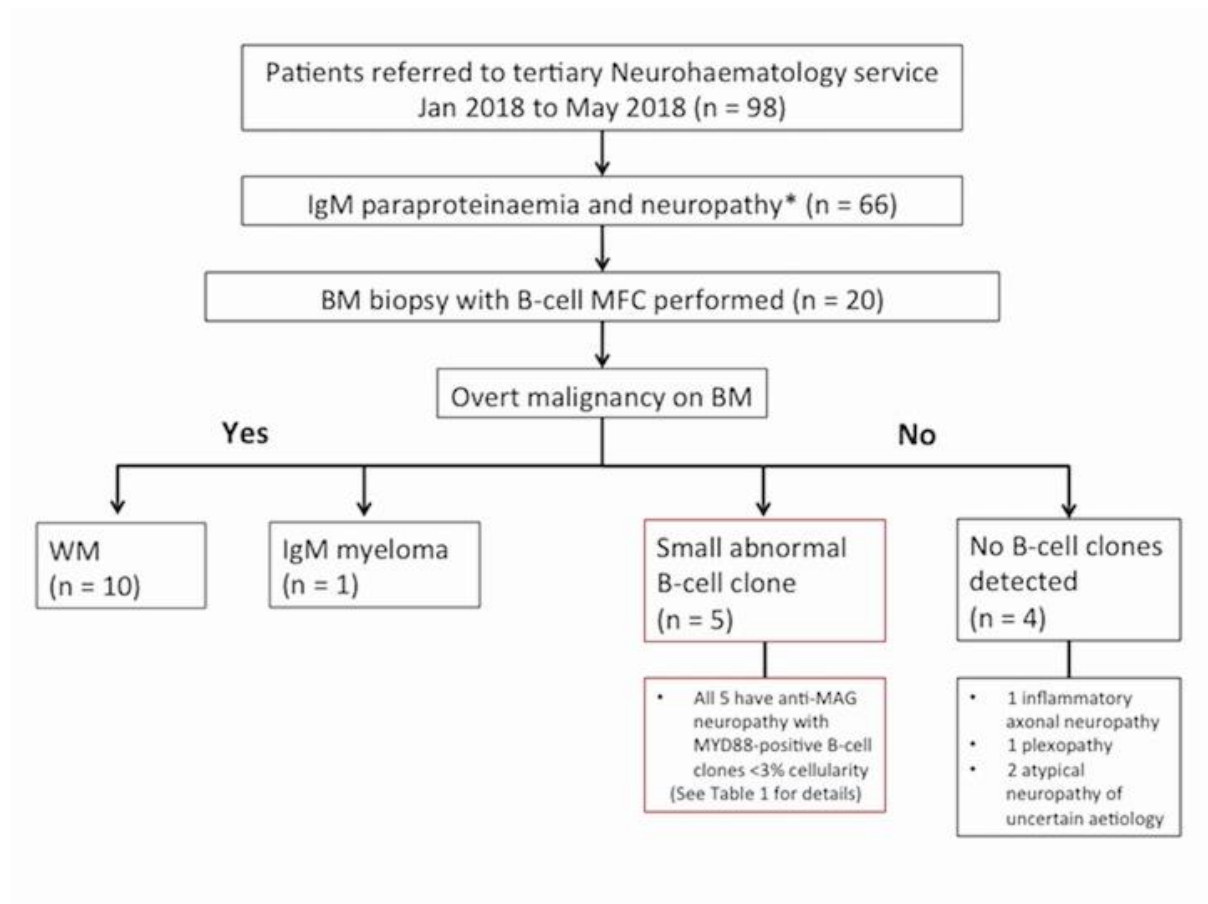
The MYD88 L265P mutation, present in around 50% of IgM MGUS patients, is known to carry a five-fold increased risk of progression to WM (Varettoni et al 2013). Current hypotheses propose that MYD88 L265P acts as a driver mutation to facilitate a 'multi-hit' phenomenon leading to progression

from IgM MGUS to WM (Treon and Hunter 2013). Despite the presence of the MYD88 L265P mutation in all 5 of our patients with abnormal small B-cell clones, none have shown malignant progression thus far. The significance of MYD88 positivity in our cohort is therefore unclear; although phenotypically similar to WM cells, the B-cell clones we describe are distinct from MGUS, appear to be less proliferative and may not seed extramedullary sites. It is possible that the MYD88 L265P mutation has a functional impact in these cells, leading to their persistence, but in the absence of additive mutations, evolution to full-blown lymphoma does not occur. Longer-term follow-up would be required to establish this hypothesis.

The Second International Workshop on Waldenström's macroglobulinaemia classification (Owen et al 2012) describes patients with symptomatic IgM monoclonal gammopathy and no overt evidence of lymphoma as "IgM-related disorders", a group clinically distinct from WM and IgM MGUS. Furthermore, the more recently described "monoclonal gammopathy of clinical significance" (MGCS) highlights the need for clinicians to actively seek out symptomatic MGUS to instigate relevant treatment (Ferland et al 2018). Svahn et al (2018) noted that IVIG was more often chosen over rituximab as first-line treatment for patients with MGUS-associated PN compared to those with 'malignant haemopathies'. By identifying CD20-positive clones, MFC may aid personalisation of treatment and avoid the use of potentially ineffective treatments such as IVIG.

To conclude, we posit that MFC may be useful in patients with IgM-related disorders and MGCS, such as IgM paraprotein-associated PN, to help identify those who may benefit from targeted immunomodulatory therapy. Serial use of MFC following treatment may also enable a more detailed assessment of response in this low burden setting, as the significance of anti-MAG antibody titres post-treatment remains controversial (Léger et al 2013). A comparison of the biology of these MYD88 L265P positive small B-cell clones with that of WM-derived B-cells may further inform our understanding of both conditions and aid their effective management.

Figure 1. Flow chart outlining our cohort of IgM paraprotein-associated peripheral neuropathy patients



BM: bone marrow; B-cell MFC: B-cell multi-parameter flow cytometry, designed to detect small lymphoma clones; WM: Waldenström’s macroglobulinaemia; *¹neuropathy inclusion: sensory neuropathy, sensorimotor neuropathy, radiculopathy, plexopathy; *²neuropathy exclusion: central nervous system manifestations, myopathy, parkinsonism, carpal tunnel syndrome.

Patient	Age/Sex	Previous therapy	Duration of neuropathy symptoms when referred (years)	Pre-treatment ONLS score	Paraprotein isotype	Pre-treatment SPEP (g/L)	MYD88 L265P	Anti-MAG antibodies	Flow cytometry (% Total cellularity)	Treatment	Response
1	45/ F	Steroids, IVIG	2	3	IgM-kappa	4	Positive	Strong positive	CD19+ CD10+ CD23+ CD20+ small B-cell clone (2.1%)	Lost to follow-up	
2	62/ F	IVIG	2	n/a	IgM-kappa	3	Positive	Positive *	CD19+ CD10+ CD20+ small B-cell clone (0.75%)	R (standard regimen) x 1	Post-treatment ONLS = 0
3	50/ M	None	4	4	IgM-kappa	6	Positive	Strong positive	CD19+ CD5+ CD79b+ CD20+ small B-cell clone (0.12%)	R (standard regimen) x 1	Post-treatment ONLS = 3
4	78/ M	IVIG	4	5	IgM-kappa	<3	Positive	Positive *	CD 19+ CD23+ CD20+ small	R (standard regimen) x	Slowed progression of

									B-cell clone (1.15%)	2, R (low-dose regimen) x 3	symptoms
5	62/ M	None	13	3	IgM-kappa	1.4	Positive	Strong positive	CD19+ CD79b+ slg+ CD20+ small B-cell clone (2.47%)	R (standard regimen) x 2	Post-treatment ONLS = 2

Table 1. Summary of patient characteristics, results and response following rituximab treatment

IVIG: intravenous immunoglobulin; SPEP: serum protein electrophoresis, anti-MAG antibodies: anti-myelin associated glycoprotein antibodies; ONLS: overall neuropathy limitations scale (neuropathy score ranging from no limitations of function at 0 and loss of all purposeful movements in the arms and legs at 12); n/a: not available; *: titre not available R: rituximab; R (standard regimen) x 1: 1 course of 4-weekly 375mg/m² R; R (low-dose regimen): R 100mg/m² three-monthly

ACKNOWLEDGEMENTS

Dr Keddie is funded by ABN/Guarantors of Brain Clinical Training Research Fellowship.

Dr Michael P Lunn is supported by the National Institute for Health Research, University College London Hospitals, Biomedical Research Centre.

This work was supported by the International Waldenström's Macroglobulinemia Foundation (IWMF) for funding of the UCLH Waldenstroms Biobank and Waldenström's Macroglobulinemia United Kingdom (WMUK) for funding for the Rory Morrison Registry for WM.

AUTHORSHIP

Contribution: LYC collected the data and wrote the paper. SD, RG, MPL designed the research and provided the patient data. RG and EV provided and analysed the flow cytometry data. SK, SD, RG, MPL, EV, RG edited the paper.

COMPETING INTERESTS

The authors have no competing interests.

REFERENCES

- Campagnolo M, Zambello R, Nobile-Orazio E, et al. IgM MGUS and Waldenstrom-associated anti-MAG neuropathies display similar response to rituximab therapy. *Journal of Neurology, Neurosurgery and Psychiatry*. 2017;88:1094–1097
- Chaudry HM, Mauermann ML, Rajkumar SV. Monoclonal Gammopathy-Associated Peripheral Neuropathy: Diagnosis and Management. *Mayo Clinic Proceedings*. 2017;92(5):838-850
- D'Sa S, Kersten MJ, Castillo JJ et al. Investigation and management of IgM and Waldenström associated peripheral neuropathies: recommendations from the IWWM-8 consensus panel. *British Journal of Haematology*. 2017;176:728–742
- Dimopoulos, M.A., Kastritis, E., Owen, R.G. Treatment recommendations for patients with Waldenström macroglobulinemia (WM) and related disorders: IWWM-7 consensus. *Blood*. 2014;124:1404–1411
- Fernand JP, Bridoux F, Dispenzieri A et al. Monoclonal gammopathy of clinical significance: a novel concept with therapeutic implications. *Blood*. 2018;132(14):1478-1485
- Graham RC, Hughes RA. A modified peripheral neuropathy scale: the Overall Neuropathy Limitations Scale. *Journal of Neurology Neurosurgery and Psychiatry*. 2006;77:973–6
- Léger JM, Viala K, Nicolas G et al. Placebo-controlled trial of rituximab in IgM anti-myelin-associated glycoprotein neuropathy. *Neurology*. 2013;80(24):2217-2225
- Levine T, Pestronk A, Florence J et al. Peripheral neuropathies in Waldenstrom's macroglobulinaemia. *Journal of Neurology, Neurosurgery and Psychiatry*. 2006;77:224–228.
- Lunn MPT and Nobile-Orazio E. Immunotherapy for IgM anti-myelin-associated glycoprotein-associated peripheral neuropathies. *Cochrane Database of Systematic Reviews*. 2016;10:CD002827

Niermeijer JMF, Fischer K, Eurelings M, Franssen H, Wokke JHJ, Notermans NC. Prognosis of polyneuropathy due to IgM monoclonal gammopathy: a prospective cohort study. *Neurology*. 2010;74:406-412

Nobile-Orazio E, Barbieri S, Baldini L, et al. Peripheral neuropathy in monoclonal gammopathy of undetermined significance: prevalence and immunopathogenetic studies. *Acta Neurol Scand*. 1992;85:383-390

Svahn J, Petiot P, Antoine JC et al. Anti-MAG antibodies in 202 patients: clinicopathological and therapeutic features. *Journal of Neurology, Neurosurgery and Psychiatry*. 2018;89:499-505

Treon SP and Hunter ZR. A new era for Waldenstrom macroglobulinaemia: MYD88 L265P. *Blood*. 2013;121:4434-4436

Varettoni M, Zibellini S, Arcaini L et al. MYD88 (L265P) mutation is an independent risk factor for progression in patients with IgM monoclonal gammopathy of undetermined significance. *Blood*. 2013;122:2284-2285

Vos JM, Notermans NC, D'Sa S, et al. High prevalence of the MYD88 L265P mutation in IgM anti-MAG paraprotein-associated peripheral neuropathy. *J Neurol Neurosurg Psychiatry* 2018;89:1007-1009