

## CASE REPORT

# Coombs-positive Paroxysmal Nocturnal Haemoglobinuria

Sabrina Kalam<sup>1,\*</sup>, Rupert Beale<sup>2</sup>, Derrallynn Hughes<sup>3</sup>,  
Austin Kulasekararaj<sup>4</sup> and Umasuthan Srirangalingam<sup>5</sup>

<sup>1</sup>Department of Neurology, Charing Cross Hospital, London, W6 8RF, UK, <sup>2</sup>Department of Nephrology, Royal Free Hospital, London NW3 2QG, UK, <sup>3</sup>Department of Haematology, Royal Free Hospital, London NW3 2QG, UK, <sup>4</sup>Department of Haematology, King's College Hospital, London SE5 9RS, UK, <sup>5</sup>Department of Endocrinology, University College London Hospital, London NW1 2BU, UK

\*Correspondence address. Charing Cross Hospital, London W6 8RF, UK. Tel: 07460118283; Email: sabrina.kalam@nhs.net

## Abstract

Autoimmune haemolytic anaemia (AIHA) and paroxysmal nocturnal haemoglobinuria (PNH) are two distinct causes of haemolytic anaemia. They have different mechanisms that underpin their pathogenesis and, therefore, require different treatment strategies. The direct antiglobulin test (DAT) or Coombs test is positive in cases of immune-mediated haemolytic anaemia and, thus, is positive in AIHA but negative in PNH. We report a case of a woman presenting with a haemolytic anaemia who was found to have concomitant evidence of AIHA and PNH. The case highlights the importance of carrying out a comprehensive haemolysis work-up in patients who present with haemolytic anaemia.

## INTRODUCTION

Haemolytic anaemia is defined as anaemia due to haemolysis of red blood cells (RBC) and its causes are subdivided into intracorpuscular or extracorpuscular aetiologies. The hallmark of the autoimmune haemolytic anaemia (AIHA) and paroxysmal nocturnal haemoglobinuria (PNH) is shortened red blood cell survival. Despite this, their pathophysiological mechanisms are distinct. AIHA results from an extracorpuscular defect in which the generation of autoantibodies against antigens on the surface of red blood cells leads to their premature destruction. PNH is a rare, acquired genetic condition caused by the non-malignant clonal expansion of haemopoietic stem cells with somatic mutation of phosphatidylinositol glycan class A (PIGA), which results in red cells being extremely sensitive to complement mediated lysis [1]. This results in a syndrome characterized by intravascular haemolysis, haemoglobinuria, thromboembolic episodes and

bone marrow failure. A spectrum of forms has been identified from haemolytic-type PNH through to an aplastic anaemia-PNH form (AA-PNH) [2]. We report the case of a woman who initially presented with an intravascular haemolytic anaemia and was subsequently found to have concomitant AIHA and PNH.

## CASE REPORT

A 65-year-old Caucasian female presented to the emergency department with a 3-day history of haematuria, exertional dyspnoea, abdominal pain, myalgia and profound fatigue. She reported profuse non-bloody diarrhoea the day before onset of symptoms, having eaten at a seafood restaurant. Her past medical and drug history are shown in Table 1. Upon clinical examination, she had marked conjunctival pallor, scleral icterus and marked tachypnoea with a respiratory rate of 24 breaths per

Received: August 24, 2017. Revised: April 22, 2018. Accepted: October 27, 2019

© The Author(s) 2020. Published by Oxford University Press.

This is an Open Access article distributed under the terms of the Creative Commons Attribution Non-Commercial License (<http://creativecommons.org/licenses/by-nc/4.0/>), which permits non-commercial re-use, distribution, and reproduction in any medium, provided the original work is properly cited. For commercial re-use, please contact [journals.permissions@oup.com](mailto:journals.permissions@oup.com)

**Table 1:** Past medical history, drug history and blood results

| Past medical history                       |                               | Medications   |       |       |                 |
|--|-------------------------------|---------------|-------|-------|-----------------|
| Chronic obstructive pulmonary disease      |                               | Levothyroxine |       |       |                 |
| Ovarian carcinoma (bilateral oophorectomy) |                               | Bumetanide    |       |       |                 |
| Epilepsy                                   |                               | Aspirin       |       |       |                 |
| Aortic valve replacement (porcine valve)   |                               | Phenytoin     |       |       |                 |
| Hypothyroidism                             |                               | Phenobarbital |       |       |                 |
| Fatty liver disease                        |                               |               |       |       |                 |
| Blood results                              |                               |               |       |       |                 |
|  | Units                         | Day 1         | Day 2 | Day 3 | Post-eculizumab |
| Hb   | (g/l)                         | 115           | 95    | 67    | 111             |
| WCC  | ( $\times 10^9/l$ )           | 10.88         | 13.05 | 10.16 | 7.24            |
| Platelets                                  | ( $\times 10^9/l$ )           | 339           | 408   | 315   | 312             |
| MCV  | (fl)                          | 88            | 84    | 84.9  | 100             |
| Reticulocyte count                         | %                             | 6.2           |       | 7.3%  | 3.1             |
| Urea                                       | (mmol/l)                      | 8.7           | 20.0  | 24.2  | 6.0             |
| Creatinine                                 | ( $\mu\text{mol/l}$ )         | 124           | 307   | 352   | 79              |
| eGFR                                       | (ml/min/1.73 m <sup>2</sup> ) | 39            | <15   | <15   | 63              |
| LDH (<240)                                 | (IU/l)                        | 989           | 1100  | -     | 209             |
| CK   | (IU/l)                        | 611           |       |       |                 |

**Table 2:** Autoimmune haemolytic anaemia

| Autoimmune haemolytic anaemia      |                                      |
|------------------------------------|--------------------------------------|
| Autoimmune haemolytic anaemia      |                                      |
| Group                              | A Rh D positive<br>C + c + E + e + K |
| Antibody report                    | No atypical antibodies detected      |
| DAT (short profile)                | Positive                             |
| Probable due to auto D and Auto E. |                                      |
| Anti-IgG                           | 3                                    |
| Anti C3b-C3d                       | 0                                    |
| DAT control                        | 0                                    |
| Flow cytometry                     |                                      |
| Acidified serum lysis              | Positive                             |
| Acidified serum lysis—%lysis       |                                      |
| CD55 (DAF)                         | 83%                                  |
| CD59 (MIRL)                        | 83%                                  |
| FLAER/CD24                         | 22% positive                         |
| PNH screen Interpretation          |                                      |

78% doubly negative FLAER/CD24 granulocytes detected. 17% RBC showing double negativity for CD55/59. Consistent with patient having PNH in both granulocyte and RBC populations

minute and oxygen saturation of 95% on room air. Left iliac fossa tenderness and voluntary guarding were noted on abdominal palpation and rectal examination was unremarkable.

Initial blood tests (Table 1) revealed a normocytic anaemia, raised reticulocyte counts and hyperbilirubinaemia, raising the possibility of a haemolytic process. Urinalysis demonstrated 3+ of both protein and blood, with microscopy (Table 2) demonstrating renal tubular cells and red cell casts. At presentation, she had an acute kidney injury (AKI) which subsequently worsened throughout the admission. ECG was normal and her chest x-ray showed small bilateral pleural effusions.

The differential diagnoses considered at this stage were gastrointestinal blood loss, haemolytic anaemia secondary to sepsis, haemolytic uraemic syndrome (HUS), infective endocarditis

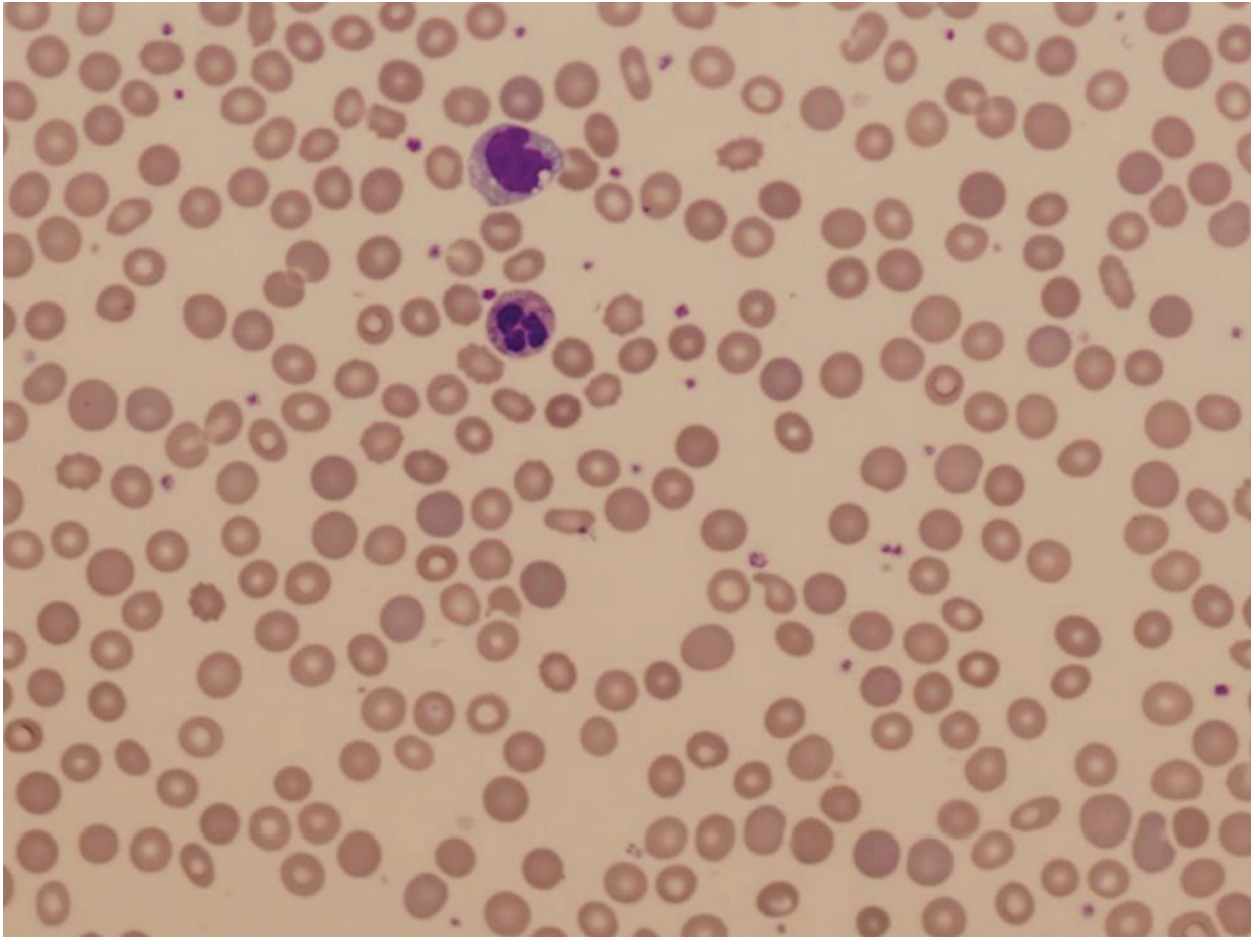
and malignancy. Initial management included IV fluids and fluid balance monitoring in the context of the AKI.

Subsequent blood tests were noted to haemolyse and her haemoglobin rapidly fell to 6 g/dl. No clotting samples could be processed. The peripheral blood smear revealed a few spherocytes, mild polychromasia, no fragments and toxic looking neutrophils (Fig. 1). The lack of red cell fragments and normal platelet count made HUS an unlikely differential. Transthoracic ECHO revealed a functioning porcine aortic valve without evidence of infective endocarditis and renal ultrasound showed normal kidneys.

A haemolysis screen noted a raised LDH, undetectable haptoglobin levels and a positive direct antiglobulin test (DAT) (3+ IgG), suggesting an autoimmune haemolytic anaemia (AIHA) (Table 2). Cold agglutinins and a viral screen were negative. A paroxysmal nocturnal haemoglobinuria (PNH) screen was requested given the possibility of haemoglobinuria (urinalysis positive for blood but absence of red cells on microscopy) and an intravascular source of the haemolysis. This identified marked clonal expansion of GPI-anchor deficient blood cells by flow cytometry, with 17% red cell clone and 78% monocyte and granulocyte clones. A bone marrow aspiration and trephine (BMT) showed no evidence of an underlying myelodysplastic syndrome or aplastic anaemia.

A diagnosis of concurrent AIHA and PNH, precipitated by a presumed acute gastrointestinal infection was formulated. The patient received packed red cell transfusions and was commenced on oral prednisolone (at a dose of 1 mg/kg) for AIHA. The patient was transferred to PNH National Service centre and subsequently commenced on eculizumab. She was also treated with thromboembolic prophylaxis (following resolution of the AKI) and was vaccinated against meningitis, due to increased risk conferred with eculizumab treatment.

She made a good recovery with eculizumab therapy and was under surveillance. At 3 years following her initial presentation, the PNH clone had persisted. Despite her good recovery and haematological stability, our patient died unexpectedly at 3 years following complications of her underlying (bio-prosthetic) valvular heart disease.



**Figure 1:** Blood film appearances showing polychromasia (large bluish red cells) and spherocytes (small round red cells with no central pallor).

## DISCUSSION

We report a rare case of concomitant AIHA and PNH. The patient presented with haemolysis and a positive DAT test, suggesting a diagnosis of AIHA. However the presence of persistent haemoglobinuria also raised the possibility of intravascular haemolysis and prompted a comprehensive haemolysis screen which included flow cytometric analysis, which confirmed an additional diagnosis of PNH.

In PNH, the complement regulatory proteins CD59 and CD55 are unable to attach to the cell membrane via GPI, rendering haemopoietic cells susceptible to complement mediated intravascular haemolysis and reduced bone-marrow production of white cells and platelets. The cell surface GPI deficiency in PNH is responsible for both the clonal expansion of these PIGA mutant cells, by allowing them to evade immune/apoptotic regulation, but is also the cause of the associated haemolysis [3]. Flow cytometry using antibodies against GPI to detect percentages of GPI deficient cells is the gold standard for diagnosis.

The flow cytometry in our patient identified the marked clonal expansion of GPI anchor deficient blood cells. The red cell clone was noted to be smaller (17%) than the granulocyte clone (78%). This is a result of a portion of the red cells being lost to haemolysis and highlights the importance of granulocytes, as they are not lysed like red cells and therefore provide a more accurate reflection of the true PNH clone size.

PNH is linked to aplastic anaemia (AA) and myelodysplastic syndrome (MDS) where cellular autoimmunity is directed against hematopoietic cells. CD55 and/or CD59 deficient cells are not specific to PNH and can be found in other autoimmune mediated haematological conditions including AA, MDS and AIHA [4]. PNH and AIHA occasionally occur concomitantly and it has been suggested that the inflammatory/thrombotic process in PNH may cause a conformational change on the erythrocyte surface, which triggers an immune antibody response. Alternatively, autoantibodies in AIHA may facilitate clonal expansion of the GPI deficient cell [5]. AIHA is characterized by extravascular haemolysis in contrast to the intravascular haemolysis of PNH. Additionally the presence of a positive DAT could have been incidental and not the primary reason for the patient's haemolysis, as our patient had a persistent PNH clone 3 years after diagnosis but her DAT became negative.

There has only been one other case report of possible coexisting AIHA and PNH reported in the literature [6]. This patient had presented with recurrent deep vein thrombosis and was diagnosed with AIHA. However, on flow cytometric red cell analysis, the authors found that they possessed PNH-like defects. Their patient was treated with steroids, antibiotics and an anti-thrombotic agent and made a good clinical recovery. Interestingly, they noted that the clinical recovery corresponded with improvement in the flow cytometry anomalies [6].

PNH has been historically managed with blood transfusions and iron and folate supplementation. Anticoagulation needs to be considered due to the thromboembolic risk, which is the principal cause of death in patients with PNH. If the diagnosis of PNH had been missed in our patient, it could have resulted in serious and even life threatening consequences from thromboembolic complications. Eculizumab, a humanized monoclonal antibody against terminal protein C5, inhibits complement activation and thus intravascular haemolysis. It has been shown to reduce intravascular haemolysis, stabilize haemoglobin, reduce transfusion dependence and improve quality of life in patients with PNH [5]. In the UK patients diagnosed with PNH are managed via the PNH National service. Poor outcomes are linked with the AA-PNH, older age and poor performance status [2].

This case highlights the possibility of a dual pathology in cases of haemolytic anaemia and the need to broaden investigations where clinical signs and symptoms diverge from a unifying diagnosis.

### CONFLICT OF INTEREST STATEMENT

None declared.

### CONSENT

Written consent not required as patient is deceased.

### FUNDING

Nil (not required).

### ETHICS

Verbal consent from family. Formal ethical approval not required.

### GUARANTOR

Dr U. Srilangalingam (usrirangalingam@nhs.net).

### Acknowledgements

We thank the patient for allowing us to write and publish this report.

### REFERENCES

1. Takeda J, Miyata T, Kawagoe K, Iida Y, Endo Y, Fujita T et al. Deficiency of the GPI anchor caused by a somatic mutation of the PIG-A gene in paroxysmal nocturnal hemoglobinuria. *Cell*. 1993;73:703–11.
2. Socie G, Schrezenmeier H, Muus P, Lisukov I, Roth A, Kulasekararaj A et al. Changing prognosis in Paroxysmal Nocturnal Haemoglobinuria disease subcategories; an analysis of International PNH Registry. *Intern Med J*. 2016.
3. Chen G, Zeng W, Maciejewski JP, Kcyvanfar K, Billings EM, Young NS. Differential gene expression in hematopoietic progenitors from paroxysmal nocturnal hemoglobinuria patients reveals an apoptosis/immune response in 'normal' phenotype cells. *Leukemia*. 2005;19:862–8.
4. Ruiz-Delgado GJ, Vazquez-Garza E, Mendez-Ramirez N, Gomez-Almaguer D. Abnormalities in the expression of CD55 and CD59 surface molecules on peripheral blood cells are not specific to paroxysmal nocturnal hemoglobinuria. *Hematology*. 2009;14:33–7.
5. Hillmen P, Young NS, Schubert J, Brodsky RA, Socie G, Muus P et al. The complement inhibitor eculizumab in paroxysmal nocturnal hemoglobinuria. *The New England journal of medicine*. 2006;355:1233–43.
6. zupańska B, Bogdanik I, Fabijanska-Mitek J, Pyl H. Autoimmune haemolytic anaemia with a paroxysmal nocturnal haemoglobinuria-like defect. *European Journal of Haematology* 2009;62:346–9.