

DR. JAMES WILLIAM DAY (Orcid ID : 0000-0002-6329-7636)

DR. THOMAS ANDREW FOX (Orcid ID : 0000-0002-1163-2295)

Article type : Letters

## **IL-1 blockade with anakinra in acute leukaemia patients with severe COVID-19 pneumonia appears safe and may result in clinical improvement**

**James W. Day<sup>1,2</sup>, Thomas A. Fox<sup>1,2</sup>, Richard Halsey<sup>1</sup>, Ben Carpenter<sup>1</sup> and Panagiotis D. Kottaridis<sup>1</sup>**

<sup>1</sup>Department of Haematology, University College London Hospitals NHS Foundation Trust, London, United Kingdom

<sup>2</sup>UCL Institute of Immunity and Transplantation, UCL, London, United Kingdom

This article has been accepted for publication and undergone full peer review but has not been through the copyediting, typesetting, pagination and proofreading process, which may lead to differences between this version and the [Version of Record](#). Please cite this article as [doi: 10.1111/bjh.16873](https://doi.org/10.1111/bjh.16873)

This article is protected by copyright. All rights reserved

**Corresponding author: James W. Day**

**Email: james.day@ucl.ac.uk**

**Mailing address: Flat 10 Wharf Mill apartments, Laburnum street, London, E2 8FT**

**Phone number: 07753101317**

## **Introduction**

As of 17th May, 2020 the number of patients infected by coronavirus disease 2019 (COVID-19) worldwide has exceeded 4.5 million (WHO 2020). A subgroup of patients with COVID-19 pneumonia develop a hyperinflammatory syndrome which has a similar cytokine release profile to secondary haemophagocytic lymphohistiocytosis (HLH) (Huang, *et al* 2020). Immunomodulatory drugs are hypothesised to abrogate the dysfunctional immune response in hyperinflammatory COVID-19 and are currently being investigated in clinical trials. IL-1 blockage with anakinra has been shown to be safe and is associated with clinical improvement in patients with hyperinflammatory COVID-19 (Cavalli, *et al* 2020).

Preliminary reports suggest that patients with an underlying malignancy have inferior outcomes from COVID-19 (Malard, *et al* 2020, Martin-Moro, *et al* 2020). Many haematology patients with COVID-19 will

not be able to access novel immunomodulatory agents through clinical trials due to threshold laboratory values or recent use of other biologic agents. Therefore, off-label use of accessible therapeutic agents that have demonstrated benefit should be considered in haematology patients with concomitant COVID-19. In this report we demonstrate that anakinra is safe in haematology patients and resulted in a clinical improvement in three patients with acute leukaemia and confirmed or suspected COVID-19 pneumonia with a life-threatening hyperinflammatory syndrome.

### **Patient One**

A 40-year-old male patient with newly diagnosed acute myeloid leukaemia (AML) was commenced on induction chemoimmunotherapy (daunorubicin 50mg/m<sup>2</sup>, cytarabine 100mg/m<sup>2</sup>, gemtuzumab ozogamicin 3mg/m<sup>2</sup>) (Table 1). On day 12 after starting treatment he became pyrexial and empirical antibiotics and antifungal agents were started. High-resolution computed tomography (HRCT) scan of the chest demonstrated ground glass opacities in the right upper lobe (Figure 1.A). A combined nose and throat swab for SARS-CoV-2 was negative but a diagnosis of presumed COVID-19 was made based on typical appearance on imaging and the absence of another identifiable cause. Due to increasing oxygen requirements, the patient was transferred to the intensive care unit (ICU). A diagnosis of HLH was considered after ferritin levels of 55,043µg/L were noted along with persistent pyrexia, refractory thrombocytopenia ( $5 \times 10^9/L$ ), raised triglycerides (5.7mmol/L) and a coagulopathy (International Normalized Ratio (INR) 2.4). The H Score was calculated as 195, which has a specificity of 86% for scores above 163. He was started on subcutaneous anakinra at a dose of 100mg three times a day (TDS), dexamethasone and IV immunoglobulin (IVIg). The following day his oxygen requirements reduced and he defervesced. The anakinra and corticosteroids were weaned, the serum ferritin level fell, and the patient was discharged 35 days after commencing chemotherapy.

### **Patient Two**

A 31-year-old male, newly diagnosed with AML, was admitted for induction therapy (daunorubicin 50mg/m<sup>2</sup>, cytarabine 100mg/m<sup>2</sup>, gemtuzumab ozogamicin 3mg/m<sup>2</sup>). On day 11 after starting chemotherapy he became pyrexial (38.4°C) and was therefore commenced on broad spectrum antibiotics. A repeat chest x-ray at this time showed features of bilateral airspace opacification. Combined nose and

throat swabs were negative for a respiratory virus panel by PCR; SARS-CoV-2 was not detected when tested retrospectively. On day 22, rigors, tachycardia and desaturation prompted transfer to ICU for high flow oxygen at a FiO<sub>2</sub> of 35%. On admission to ICU the serum ferritin was >100000µg/L, along with raised triglycerides (2.9mmol/L), a coagulopathy (INR 1.66) and a pancytopenia. The H-Score was calculated as 195 and he was started on subcutaneous anakinra 100mg TDS, dexamethasone and IVIg. Along with a reduction in temperature, the ferritin reduced to 35760µg/L four days after starting anakinra and the oxygen requirements began decreasing after five days. After seven days in ICU he was discharged back to the ward, where anakinra and steroids were progressively reduced. HRCT prior to discharge showed bilateral ground glass changes with patchy distribution and small areas of peribronchial consolidation, consistent with COVID-19 (Figure 1.B).

### **Patient Three**

A 36-year-old man with acute lymphoblastic leukaemia (ALL) presented with collapse and fever five days post completion of a second cycle of blinatumomab to eliminate minimal residual disease prior to allogeneic stem cell transplantation. Laboratory tests showed a lymphopenia ( $0.62 \times 10^9/L$ ) and a mild thrombocytopenia ( $121 \times 10^9/L$ ). Broad spectrum antibiotics were commenced. The patient desaturated two days later and combined nose and throat swabs sent for SARS-CoV-2 RT-PCR were found to be positive. A HRCT on day 11 showed widespread ground glass changes (Figure 1.C). The ferritin rose to 8961µg/L along with a significantly rising c-reactive protein, increasing oxygen requirements and persistent pyrexia. He became progressively pancytopenic, with high triglycerides (3mmol/L), a coagulopathy (INR 1.44) and an H-Score calculated as 204. Anakinra was started at 200mg intravenously twice a day. Initially, the ferritin continued to rise to a peak of 25,382µg/L and the platelets continued to fall. 10 days after starting anakinra the patient defervesced and oxygen requirements were sustainably reduced. Anakinra was weaned and the clinical picture continued to improve on the ward before discharge 31 days after admission.

### **Discussion**

We highlight that severe COVID-19 pneumonia can result in a life-threatening hyperinflammatory syndrome in haematology patients post chemo-immunotherapy. In these patients, IL-1 blockage with

anakinra was safe and resulted in clinical improvement. All three cases support the importance of screening for hyperinflammatory states in patients with COVID-19 and acute leukaemia and support the use of immunomodulatory agents for patients with this phenotype. At this stage of the pandemic, results of large randomized trials are not available and evidence-based treatment protocols have yet to be established. Emerging evidence suggests that immunomodulatory agents such as anakinra, may improve outcomes in hyperinflammatory COVID-19. We provide further evidence of the utility of this agent in the clinical context described and are the first to report its safe administration in patients with acute leukaemia affected by COVID-19.

## Acknowledgements

J.W.D wrote the paper along with T.A.F and B.C. R.H provided the radiological images. B.C and P.D.K were the consultants in charge of the patients and P.D.K proofread the paper.

None of the authors had relevant conflicts of interest.

## References

- Cavalli, G., De Luca, G., Campochiaro, C., Della-Torre, E., Ripa, M., Canetti, D., Oltolini, C., Castiglioni, B., Tassan Din, C., Boffini, N., Tomelleri, A., Farina, N., Ruggeri, A., Rovere-Querini, P., Di Lucca, G., Martinenghi, S., Scotti, R., Tresoldi, M., Ciceri, F., Landoni, G., Zangrillo, A., Scarpellini, P. & Dagna, L. (2020) Interleukin-1 blockade with high-dose anakinra in patients with COVID-19, acute respiratory distress syndrome, and hyperinflammation: a retrospective cohort study. *The Lancet Rheumatology*.
- Huang, C., Wang, Y., Li, X., Ren, L., Zhao, J., Hu, Y., Zhang, L., Fan, G., Xu, J., Gu, X., Cheng, Z., Yu, T., Xia, J., Wei, Y., Wu, W., Xie, X., Yin, W., Li, H., Liu, M., Xiao, Y., Gao, H., Guo, L., Xie, J., Wang, G., Jiang, R., Gao, Z., Jin, Q., Wang, J. & Cao, B. (2020) Clinical features of patients infected with 2019 novel coronavirus in Wuhan, China. *Lancet*, **395**, 497-506.
- Malard, F., Genthon, A., Brissot, E., van de Wyngaert, Z., Marjanovic, Z., Ikhlef, S., Banet, A., Lapusan, S., Sestilli, S., Corre, E., Paviglianiti, A., Adaeva, R., F, M.H.-B., Labopin, M., Legrand, O., Dulery, R. &

Mohty, M. (2020) COVID-19 outcomes in patients with hematologic disease. *Bone Marrow Transplant*.

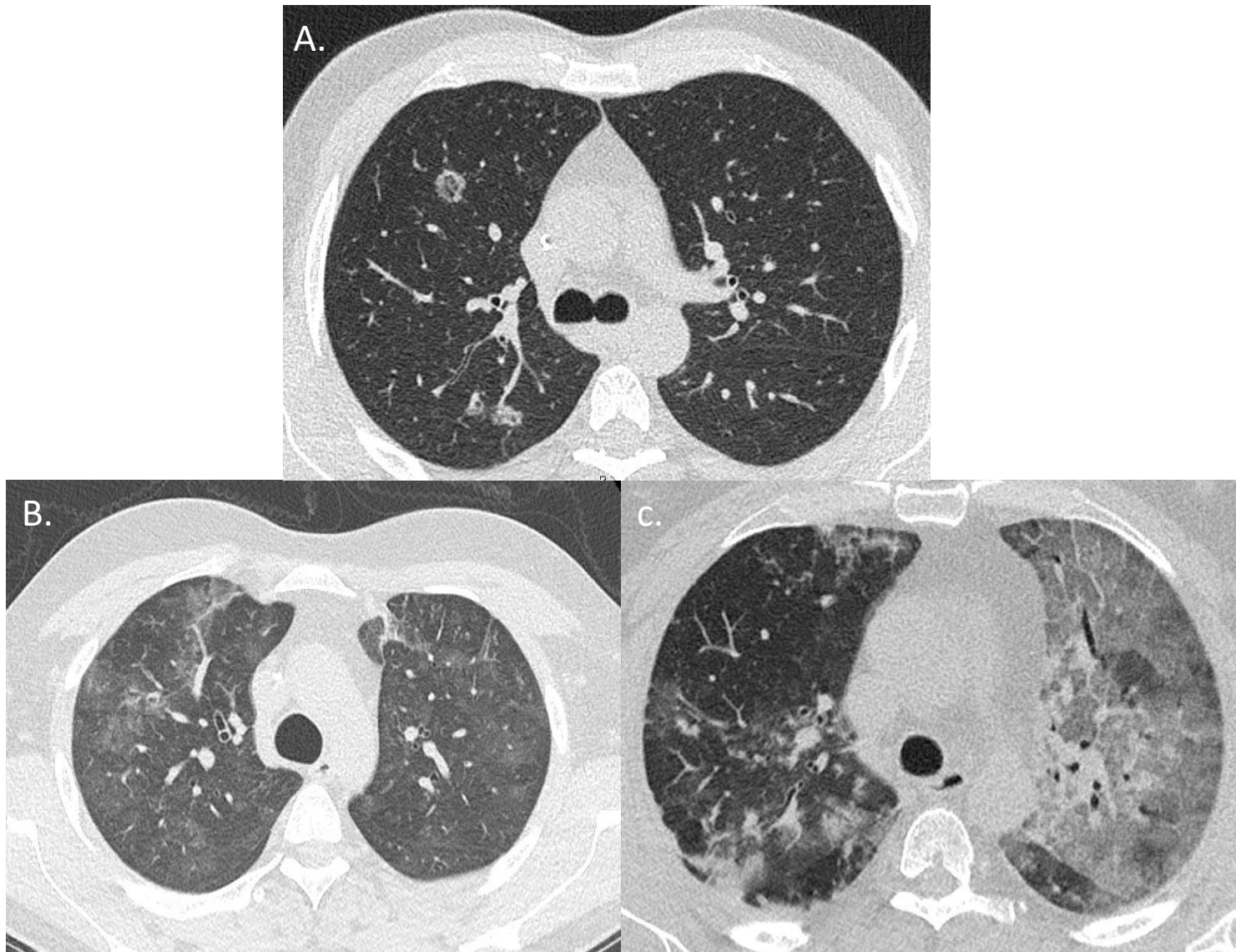
Martin-Moro, F., Marquet, J., Piris, M., Michael, B.M., Saez, A.J., Corona, M., Jimenez, C., Astibia, B., Garcia, I., Rodriguez, E., Garcia-Hoz, C., Fortun-Abete, J., Herrera, P. & Lopez-Jimenez, J. (2020) Survival study of hospitalized patients with concurrent Covid-19 and haematological malignancies. *Br J Haematol*.

WHO (2020) Coronavirus disease 2019 (COVID-19) Situation report -118. Vol. , [https://www.who.int/docs/default-source/coronaviruse/situation-reports/20200517-covid-19-sitrep-118.pdf?sfvrsn=21c0dafa\\_6](https://www.who.int/docs/default-source/coronaviruse/situation-reports/20200517-covid-19-sitrep-118.pdf?sfvrsn=21c0dafa_6).

**Table 1.** Baseline patient characteristics and length of stay

Patient No.	Sex	Ethnicity	Age	Haematological malignancy	Systemic anticancer treatment	Co-morbidities	Symptoms	No. of days post anakinra until ITU discharge	Total length of stay
1	Male	Caucasian	40	AML	Cycle 1 DA* and gemtuzumab	Nil	Cough, rhinorrhoea, sore throat, diarrhoea, fever, rash	3	37
2	Male	Caucasian	31	AML	Cycle 1 DA <sup>1</sup> and gemtuzumab	Nil	Cough, rash, fever, dyspnoea, diarrhoea	7	43
3	Male	Caucasian	36	ALL	Cycle 2 of Blinatumomab	Previous seizures	fevers	N/A	30

\* Daunorubicin and cytarabine



**Figure 1.** A) Patient 1 - Axial view, HRCT demonstrating three foci of parenchymal ground glass change surrounded by consolidation (the 'reverse halo' sign) in the right upper lobe. B) Patient 2 - Axial view, high resolution chest CT (HRCT), demonstrating bilateral, multifocal ground glass change. C) Patient 3 - Axial view, HRCT demonstrating widespread ground glass change most pronounced in the left upper lobe, predominantly subpleural and peribronchovascular consolidation and some interlobular septal thickening.