

BMJ Case Reports

TITLE OF CASE

Lipotransfer Provides Effective Soft Tissue Replacement for Acquired Partial Lipodystrophy

Jeon FHK¹, Griffin M^{1,2}, Frosdick C², Butler PEM^{1,2}

¹Division of Surgery and Interventional Science, University College London,

²Department of Plastic Surgery, Royal Free Hospital, London

SUMMARY

We present a 48 year-old female patient who presented with features consistent with acquired partial lipodystrophy (APL), also known as 'Barraquer-Simons syndrome'. It is a rare disease characterised by a gradual and progressive onset of lipoatrophy limited to the face, neck, upper limbs, thorax and abdomen and sparing the lower extremities. The resultant physical appearance can have significant psychosocial sequelae, further compounded by misdiagnosis and delay in recognition and management. Treatment is aimed at surgical correction of soft-tissue destruction. Autologous fat transfer is an established plastic and reconstructive procedure that is safe and minimally invasive, and can be used to reconstruct a variety of soft tissue defects, and has shown to be an effective treatment modality in patients with APL.

BACKGROUND

Acquired partial lipodystrophy (APL), also referred to as 'Barraquer-Simons syndrome' or 'progressive lipodystrophy', was first described by Mitchell in 1885,[1] followed by Barraquer in 1907 and Simons in 1911.[2-3] It is characterised by a gradual and progressive onset of lipoatrophy in a cephalocaudal distribution, affecting the face, neck, upper limbs, thorax and abdomen, limited to the upper half of the body. The lower extremities are either spared or can demonstrate increased fat accumulation.[4] Females are four times more likely to be affected than men.[5] Triggering factors such as viral infections, most commonly measles, and minor surgical procedures such as tooth extraction and tonsillectomy have been reported.[6] Typically there is no family history of lipodystrophy, and metabolic complications including insulin resistance are not usually implicated, or appear to be less severe when compared to other types of lipodystrophy.[6] A subset of patients develop membranoproliferative glomerulonephritis (MPGN), which is the defining prognostic factor in these patients, associated with the activation of the alternative complement pathway. This manifests as low circulating complement-component 3 (C3) levels and the presence of the C3-nephritic factor (C3NeF), a circulating auto-antibody that is thought to induce targeted adipose tissue destruction.[6-7] The resultant deformity poses a significant psychosocial burden,[8-9] and treatment is aimed at restoring aesthetic appearance through surgical correction.[9-10] We present a case study of a patient presenting with features consistent with APL, who was treated with autologous fat transfer to reconstruct the soft tissue destruction.

CASE PRESENTATION

A 48 year-old lady of Indian descent was referred to the Plastic and Reconstructive Surgery outpatients clinic. She presented with a longstanding history of progressive subcutaneous fat atrophy with an onset in her teenage years that had gradually worsened over the past few months, coinciding with the occurrence of multiple stressful life events. It principally affected her face where she was particularly concerned about the appearance of prominent dimple-like indentations in her cheeks, causing a loss of self-confidence and reluctance to be seen out in public. She had no family history of lipodystrophy. She was otherwise fit and well, enjoyed regular exercise in the gym, and was on no regular medications. She was a non-smoker, non-drinker with a BMI of 23. She lived with her husband and two children.

On examination there was a loss of fat affecting predominantly the face (Figure 1), upper limbs but sparing her forearms (Figure 2), her upper thorax and breasts down to the mid-abdominal level (Figure 3). The lower limbs were spared (Figure 4). In view of the history and cephalocaudal progression of disease, she was diagnosed with acquired partial lipodystrophy. She was referred to the renal team to screen for renal pathology, and was consented for autologous fat transfer to her face and later her breasts in simultaneous procedures.

INVESTIGATIONS *If relevant*

Screening laboratory tests including a full blood count, renal and liver function tests, inflammatory markers and thyroid function tests presented no abnormalities. A random glucose was normal (5.0mmol/L) and lipid profile including serum triglyceride and cholesterol levels were all within normal limits. Complement studies revealed a low serum level of C3 detected as 8 mg/dL (normal range 70-165 mg/dL) and a normal C4 level. In addition an elevated immunoglobulin G was found (20.7 g/L; normal range 7-16 g/L), but normal immunoglobulin A and M. Antinuclear antibody (ANA) was positive and a subsequent 6-test anti-extractable nuclear antigen (ENA) antibody screen was negative.

TREATMENT *If relevant*

Autologous fat transfer was performed according to the method described by Coleman.[11-12] Lipoaspirate was harvested using a 15 cm by 3mm disposable cannula connected to a 10cc Luer-Lock syringe, and centrifuged at 3000rpm for 3 minutes. The proximal portion of the lipoaspirate including free oil and blood was discarded. The remaining lipoaspirate was injected into the affected areas via small skin incisions using a blunt 9cm by 2mm cannula connected to 1cc Luer-Lock syringes. The patient underwent a total of four procedures over a period of three years. Fat was harvested from both thighs and an average of 23ml was injected into the face at each sitting. Fat was also injected into the breast in the latter two procedures with an average of 19ml per breast. Details of each procedure are presented in Table 1.

Date of Operation	Face	Breast	Donor Site
04/03/2015	Chin 1ml, Left cheek 12ml, Right cheek 14ml, Upper lip 1ml, Lower lip 1ml, forehead 2ml.	-	Both thighs
30/09/2015	Chin 2ml, Left cheek 12ml, Right cheek 14ml, Upper lip 2ml, Lower lip 2ml, Nasolabial folds 1ml each	-	Both thighs
07/09/2016	Left side 9ml, Right side 7.5ml	25ml each breast	Both thighs
07/03/2018	L side 5.3ml, Right side 5ml	13mls each breast	Both thighs

Table 1. Summary of autologous fat grafting procedures to the face and breast

OUTCOME AND FOLLOW-UP

Follow-up visits were arranged 3-6 months after each procedure. Apart from minor bruising in the donor sites as expected, the patient experienced no complications from the fat transfer procedures. At 6 months follow-up after the final procedure there was good fat retention in all areas and the patient was satisfied with the results (Figure 5-6). At 16 months follow-up the patient had experienced some fat resorption particularly affecting the cheeks and is subsequently on the waiting list for further fat transfer.

DISCUSSION *Include a very brief review of similar published cases*

Lipodystrophies are a heterogeneous group of acquired or inherited disorders characterised by selective loss or accumulation of subcutaneous fat. [4, 7] They can be associated with significant metabolic complications, often correlating with the extent of fat loss, demonstrating the substantial role of adipose tissue as an endocrine organ. [13] Lipodystrophies can be divided into partial or generalised, the latter further categorised as inherited or acquired. The diagnosis of APL is usually clinical, with essential diagnostic criteria described by Misra et al. [6] as a gradual onset of bilaterally symmetrical lipoatrophy in a cephalocaudal distribution, but sparing the lower extremities. Other criteria to support the diagnosis include clinical features, such as onset of symptoms at childhood or adolescence, lack of a family history and presence of autoimmune diseases. Laboratory supportive criteria include low levels of serum C3, presence of C3NeF, proteinuria and MPGN on renal biopsy. Our patient presented with the typical onset and distribution of disease, further supported by a low serum C3 level and elevated IgG level, most likely representing the presence of C3NeF, a polyclonal IgG. [14] C3NeF can induce lysis of adipocytes expressing factor D, a serum protease enzyme expressed in particular tissues, that produces the pattern of fat loss that is seen. [13] C3 hypocomplementaemia and the presence of C3NeF have been associated with MPGN, [15] which can progress to end stage renal disease in 40-50% of patients when present. [6] It is therefore of utmost importance to screen these patients early. Our patient also had a positive ANA test, but ENA screen was negative. This is reflected in the literature where a subset of patients were found with positive ANA without clinical evidence of autoimmune diseases. [6]

The distribution of fat atrophy affects the face, neck, upper limbs, and trunk, including the breast. Breast

fat was lost in all female patients in a case series.[6] The changes in physical appearance of these patients can have emotional and social sequelae.[9] As with our patient, there can be an impact in overall quality of life, and this is echoed other lipodystrophies affecting in particular the face, as in Parry-Romberg syndrome and HIV-associated lipodystrophy.[16-17] Further distress can be caused from misdiagnosis and delay in management. APL can be mistaken with anorexia nervosa[9] and there has been a case reported where facial oedema from severe nephrotic syndrome masked the characteristic appearance of facial lipoatrophy delaying diagnosis.[18]

Reconstructive methods to correct the soft tissue destruction range from cosmetic to surgical procedures. Injectable fillers such as poly-L-lactic acid[19] and hyaluronic fillers that last up to 24 months[20-21] can be used, though not offered in the case of our patient. Risk of foreign body response and impermanent results are a limitation. Alternative methods include dermal fat grafts[22] and free flaps including anterolateral thigh flaps,[23] temporal muscle flaps[24-25] and bilateral transverse rectus abdominis myocutaneous flaps.[26-27]. The latter offer long lasting results however the resultant bulky flaps that can cause ptosis, donor site morbidity and risk of complications to the recipient site including flap loss and compromised function.[27-28]

Autologous fat transfer is a safe and minimally invasive method that yields good aesthetic outcomes without functional compromise, whilst maintaining natural facial expressions and contour, and has become the established as a mode of facial soft tissue restoration.[29] It is gaining more popularity as a primary mode of breast augmentation or correction of breast asymmetry.[30-31] Moreover by harvesting from the lower limbs in these patients it serves to remove the excess fat deposition that can occur in conjunction in patients with APL. Our patient underwent four procedures in total to improve the appearance of both the face and breast to the patients satisfaction, however experienced some fat resorption in the cheek area after the last procedure. The main limitation to this procedure is fat resorption, which remains unpredictable and inevitable. Variable fat retention rates are attributed to a multifactorial process including method of fat harvest, processing and injection,[29] however procedures can be repeated safely and improvement in fat retention has been found with subsequent procedures.[32] Overcorrection with larger grafts is discouraged due to increased risk of fat necrosis and cyst formation.[29] Supplementation of fat grafts with adipose derived stem cells (ADSCs) and platelet-rich plasma (PRP) has considered to improve angiogenesis and increase fat survival however some studies report equivocal results and further work is required to establish this further [33].

The association between autoimmune disease and autologous fat transfer is yet to be explored. Parry Romberg syndrome, a rare disease considered to be of autoimmune origin and a variant of localized scleroderma, was found to be an independent negative predictor of fat retention,[34] however studies have also suggested that fat grafting in the active state of the disease served to inhibit or slow disease progression.[35]

LEARNING POINTS/TAKE HOME MESSAGES 3-5 bullet points

- Acquired partial lipodystrophy is a rare disorder that can have profound psychosocial impact and clinical sequelae if not recognized and managed appropriately.
- Screening and follow-up for development of renal disease is important.
- Autologous fat grafting is effective for soft tissue reconstruction in patients with acquired partial lipodystrophy who are appropriately educated about the procedure and its limitations.

REFERENCES

- [1] Mitchell SW. Singular case of absence of adipose tissue matter in the upper half of the body. *Am J Med Sci.* 1885;90:105 – 106.
- [2] Barraquer L. Histoire clinique d'un cas d'atrophie du tissu celluloa- dipeux. *Neurolog Zentralblatt.* 1907;26:1072.
- [3] Simons A. Lipodystrophia progressiva. *Zges Neurol Psychiat.* 1911; 5:29–38.
- [4] Oliveira J, Freitas P, Lau E, Carvalho D. Barraquer-Simons syndrome: A rare form of acquired lipodystrophy. *BMC Res Notes.* 2016;9:175-9
- [5] Ferrarini A, Milani D, Bottigelli M, Cagnoli G, Selicorni A. Two new cases of Barraquer–Simons syndrome. *Am J Med Genet.* 2004;126A(4):427–9
- [6] Misra A, Peethambaram A, Garg A. Clinical features and metabolic and autoimmune derangements in acquired partial lipodystrophy: report of 35 cases and review of the literature. *Medicine (Baltimore).* 2004;83:18–34.
- [7] Garg A. Lipodystrophies: genetic and acquired body fat disorders. *J Clin Endocrinol Metab.* 2011;96(11):3313–25.
- [8] Guaraldi G, Murri R, Orlando G, Giovanardi C, Squillace N, Vandelli M, et al. Severity of Lipodystrophy Is Associated with Decreased Health-Related Quality of Life. *AIDS Patient Care STDs.* 2008;22:577-585.
- [9] Heidemann L, Thomsen J, Sørensen J. Barraquer-Simons syndrome: A unique patient's perspective on diagnosis, disease progression and recontouring treatment. *BMJ Case Rep.* 2016;2016. pii: bcr2016216134
- [10] Capeau J, Magré J, Caron-Debarle M, Lagathu C, Antoine B, Béréziat V, et al. Human Lipodystrophies: Genetic and Acquired Diseases of Adipose Tissue. *Endocr Dev.* 2010;19:1-20.
- [11] Coleman SR. Structural fat grafts: the ideal filler? *Clin Plast Surg.* 2001;28:111–9.
- [12] Coleman SR. Structural fat grafting: more than a permanent filler. *Plast Reconstr Surg.* 2006;118(3 Suppl):108S–20S
- [13] Nolis T. Exploring the pathophysiology behind the more common genetic and acquired

lipodystrophies. *J Hum Genet.* 2013;59(1):16–23.

[14] Scott DM, Amos N, Sissons JG, Lachmann PJ, Peters DK. The immunoglobulin nature of nephritic factor (NeF). *Clin Exp Immunol.* 1978;32:12–24.

[15] Corvillo F, Akinci B. An overview of lipodystrophy and the role of the complement system. *Mol Immunol.* 2019;112:223–232.

[16] Palmero ML, Uziel Y, Laxer RM, Forrest CR, Pope E. En coup de sabre scleroderma and Parry-Romberg syndrome in adolescents: surgical options and patient-related outcomes. *J Rheumatol.* 2010;37:2174–2179

[17] Guaraldi G, Murri R, Orlando G, et al. Severity of lipodystrophy is associated with decreased health-related quality of life. *AIDS Patient Care STDS.* 2008;22:577–85.

[18] Hunter AM, Lawson AA, Thomson D. Partial lipodystrophy with nephrotic syndrome. *Postgrad Med J.* 1978;54:286–291.

[19] Zhang A, Moraites E, Goldfarb N, Liszewski W, Farah R. Acquired partial lipodystrophy treated with poly-L-lactic acid and hyaluronic acid fillers: A case report. *J Cosmet Laser Ther.* 2019;21(4):201–202.

[20] Afra TP, Vinay K, Razmi TM, Narang, T, Dogra S. Hyaluronic acid fillers for correcting midface volume deficit in Barraquer-Simons syndrome. *J Cosmet Dermatol.* 2019;

[21] Glaser DA, Kenkel JM, Paradkar-Mitragotri D, Murphy DK, Romagnano L, Drinkwater A. Duration of effect by injection volume and facial subregion for a volumizing hyaluronic acid filler in treating midface volume deficit. *Dermatol Surg.* 2015;41:942–949.

[22] Zafarulla MY. Lipodystrophy: a case report of partial lipodystrophy. *Br J Oral Maxillofac Surg.* 1985;23:53–57.

[23] Guelinckx PJ, Sinsel NK. Facial contour restoration in Barraquer-Simons syndrome using two free anterolateral thigh flaps. *Plast Reconstr Surg.* 2000;105:1730–1736.

[24] Serra JM, Ballesteros A, Mesa F, Bazan A, Paloma V, Sanz J. Use of the temporal muscle flap in Barraquer-Simon's progressive lipodystrophy. *Ann Plast Surg.* 1993;30:180–182.

[25] van der Wal KG, Mulder JW. Facial contour reconstruction in partial lipodystrophy using two temporalis muscle flaps. A case report. *Int J Oral Maxillofac Surg.* 1998;27:14–16.

[26] Coessens BC, Van Geertruyden JP. Simultaneous bilateral facial reconstruction of a Barraquer-Simons lipodystrophy with free TRAM flaps. *Plast Reconstr Surg.* 1995;95:911–915.

[27] Goossens S, Coessens B. Facial contour restoration in Barraquer-Simons syndrome using two free TRAM flaps: Presentation of two case reports and long-term follow-up. *Microsurgery.* 2002;22:211–218.

[28] Rodby KA, Kaptein YE, Roring J, Jacobs RJ, Kang V, Quinn K et al. Evaluating Autologous Lipofilling for Parry-Romberg Syndrome—Associated Defects: A Systematic Literature Review and Case Report. *Cleft Palate Craniofac J.* 2016;53(3):339–350.

[29] Simonacci F, Bertozzi N, Grieco MP, Grignaffini E, Raposio E. Procedure, applications, and outcomes

of autologous fat grafting. *Ann Med Surg.* 2017;20:49–60.

[30] Pu LL, Yoshimura K, Coleman SR. Future perspectives of fat grafting. *Clin Plast Surg.* 2015;42(3):389–394.

[31] Kling RE, Mehrara BJ, Pusic AL, Young VL, Hume KM, Crotty CA et al. Trends in autologous fat grafting to the breast: a national survey of the American Society of Plastic Surgeons. *Plast Reconstr Surg.* 2013;132(1):35–46.

[32] Denadai R, Buzzo CL, Raposo-Amaral, CA, Raposo-Amaral CE. Facial Contour Symmetry Outcomes after Site-Specific Facial Fat Compartment Augmentation with Fat Grafting in Facial Deformities. *Plast Reconstr Surg.* 2019;143(2):544–556.

[33] Vyas KS, Vasconez HC, Morrison S, Mogni B, Linton S, Hockensmith L et al. Fat Graft Enrichment Strategies: A Systematic Review. *Plast Reconstr Surg.* 2020;145(3):827-841.

[34] Denadai R, Raposo-Amaral CA, Pinho AS, Lameiro TM, Buzzo CL, Raposo-Amaral CE. Predictors of Autologous Free Fat Graft Retention in the Management of Craniofacial Contour Deformities. *Plast Reconstr Surg.* 2017;140(1):50e-61e.

[35] Hunstad JP, Shifrin DA, Kortesis BG. Successful Treatment of Parry-Romberg Syndrome With Autologous Fat Grafting: 14-Year Follow-up and Review. *Ann Plast Surg.* 2011;67(4):423-425.

FIGURE/VIDEO CAPTIONS

Figure 1. 48 year-old patient with clinical features of lipoatrophy involving the face

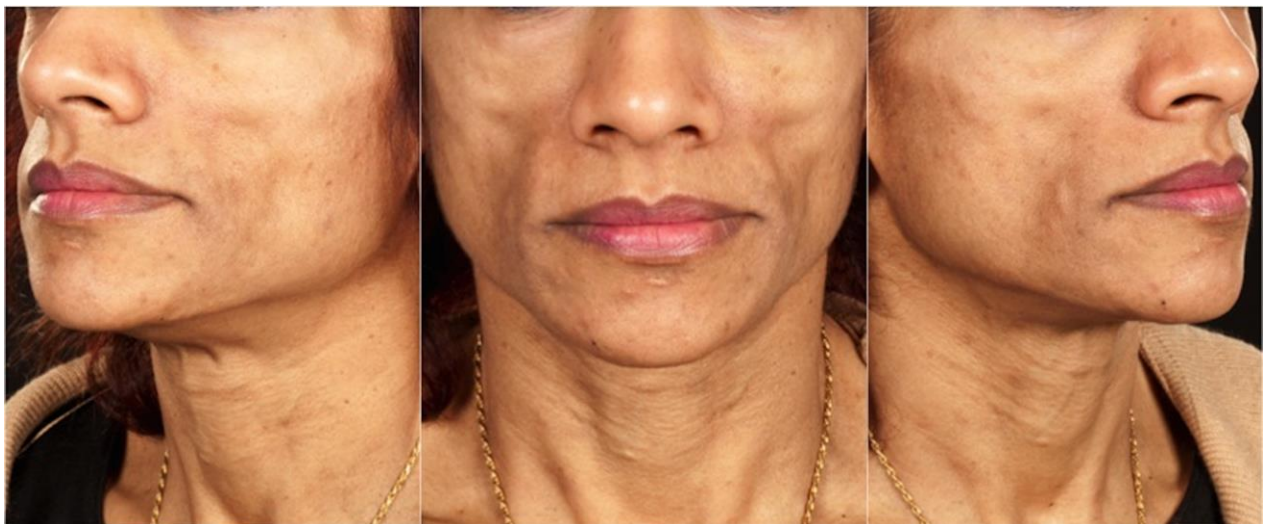

Figure 2. 48 year-old patient with clinical features of lipoatrophy involving proximal upper limbs but sparing the forearm

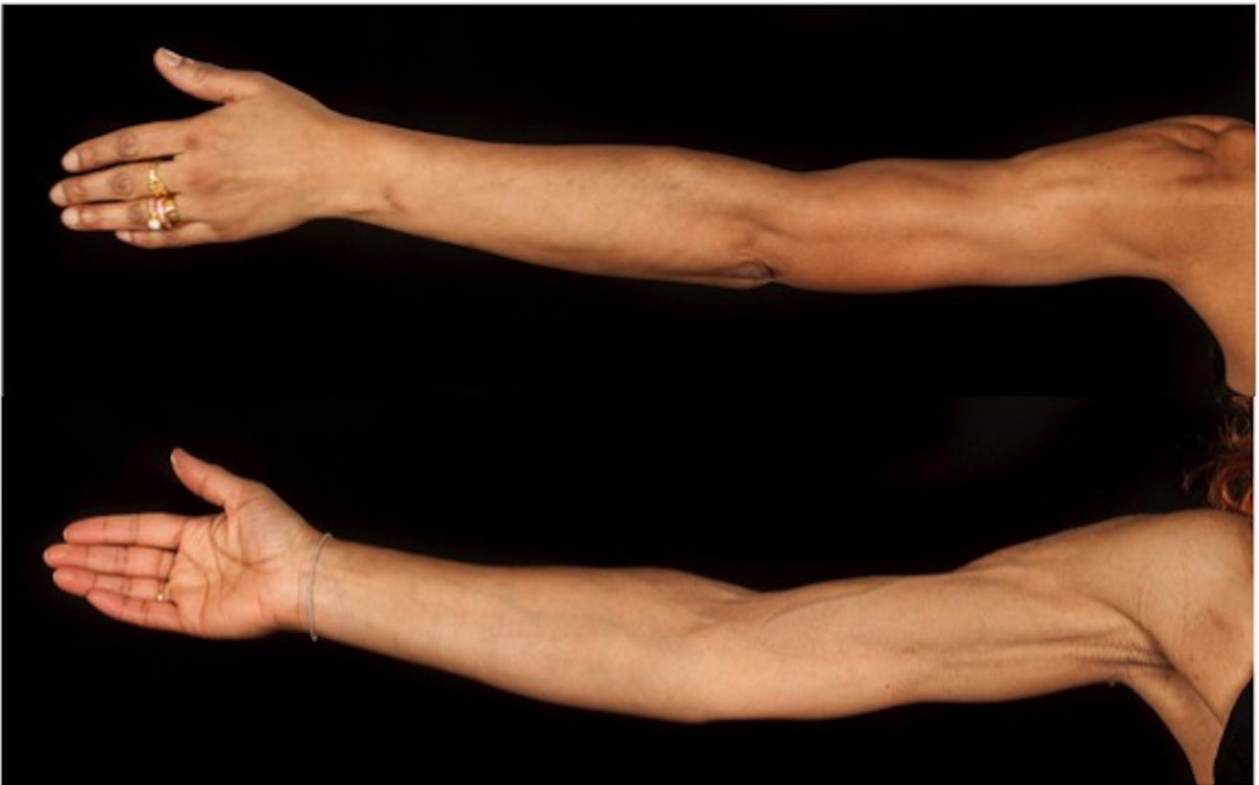


Figure 3. 48 year-old patient with clinical features of lipoatrophy involving the upper torso

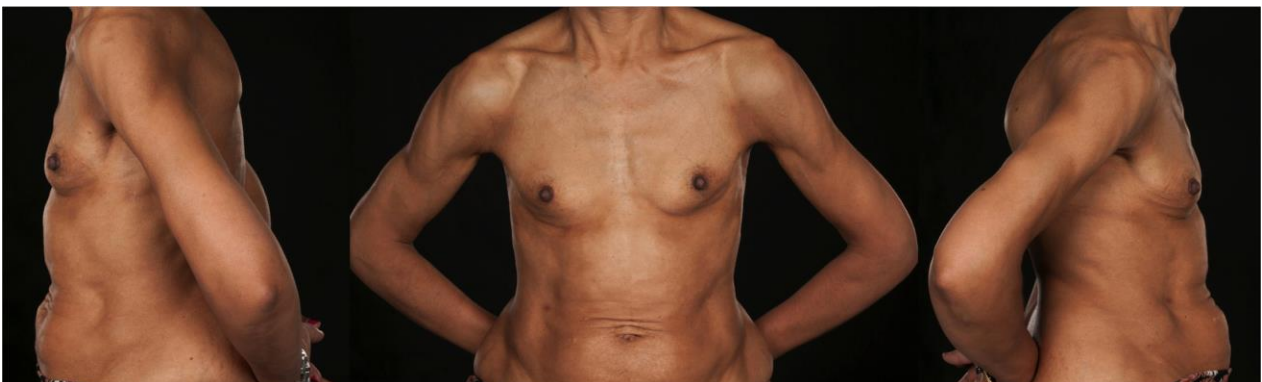


Figure 4. 48 year-old patient showing lower limbs are spared from lipoatrophy

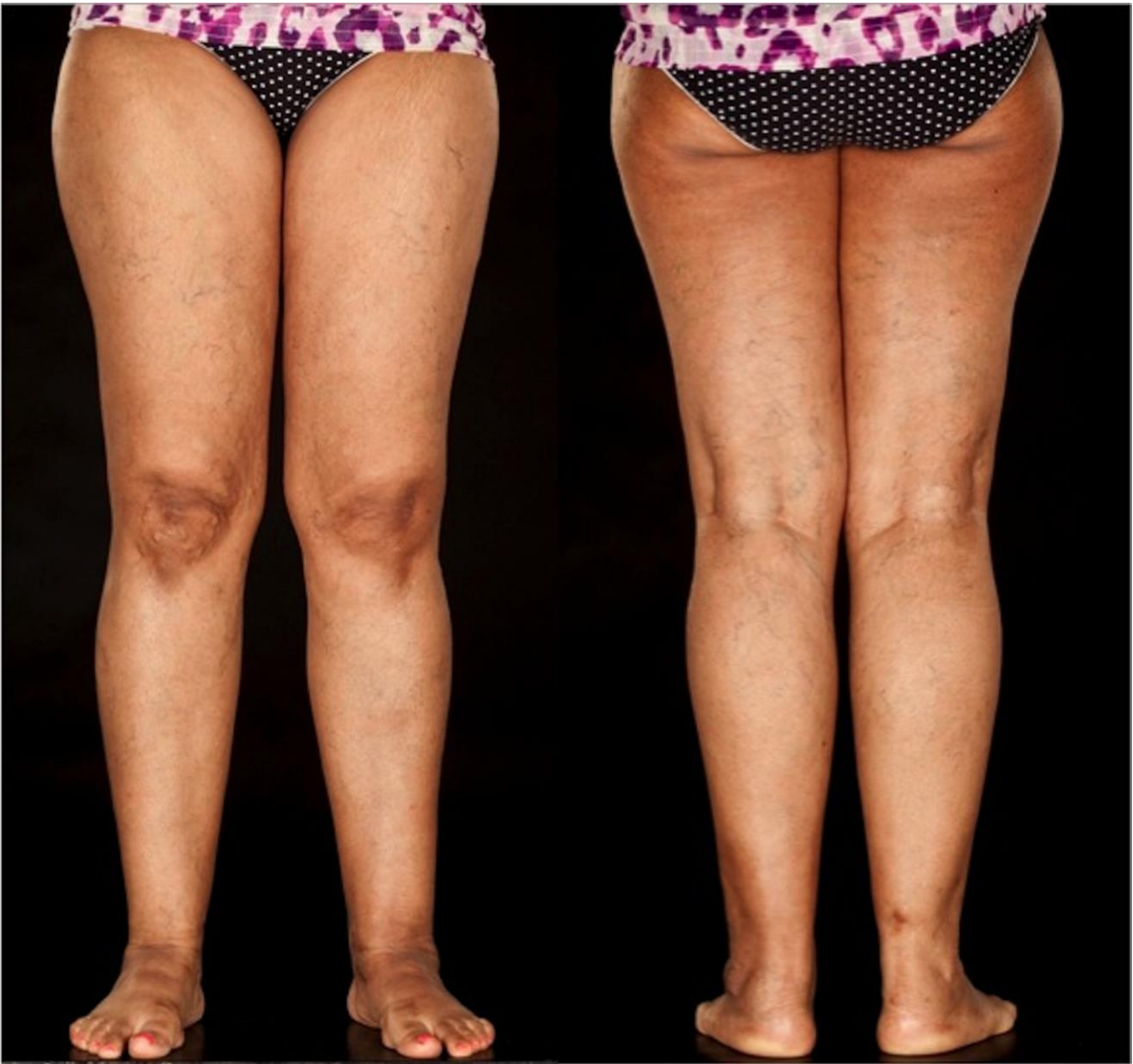

Figure 5. 4 months post-operative 4th fat transfer procedure to the face

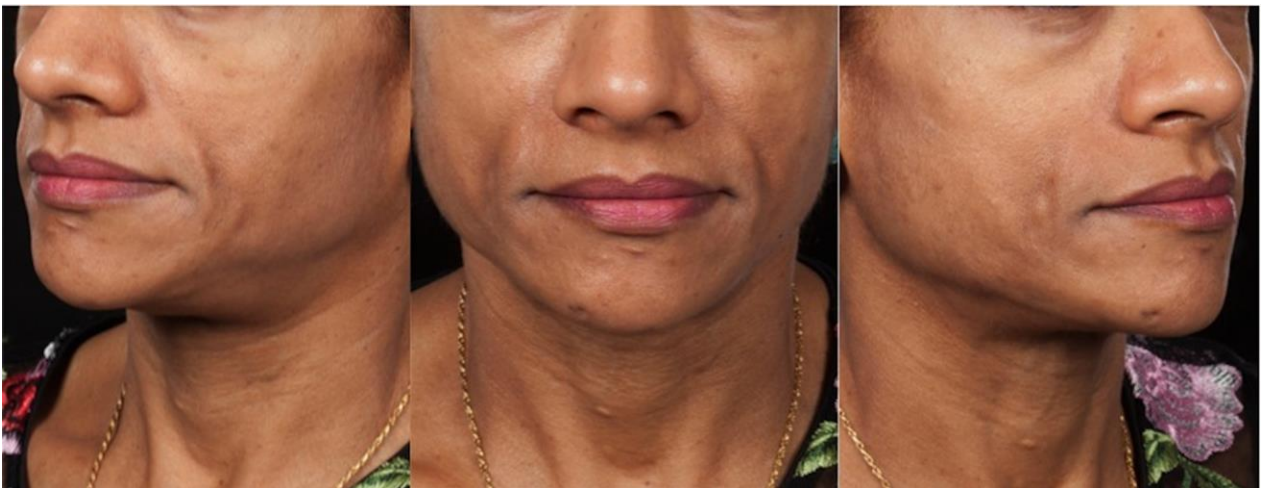
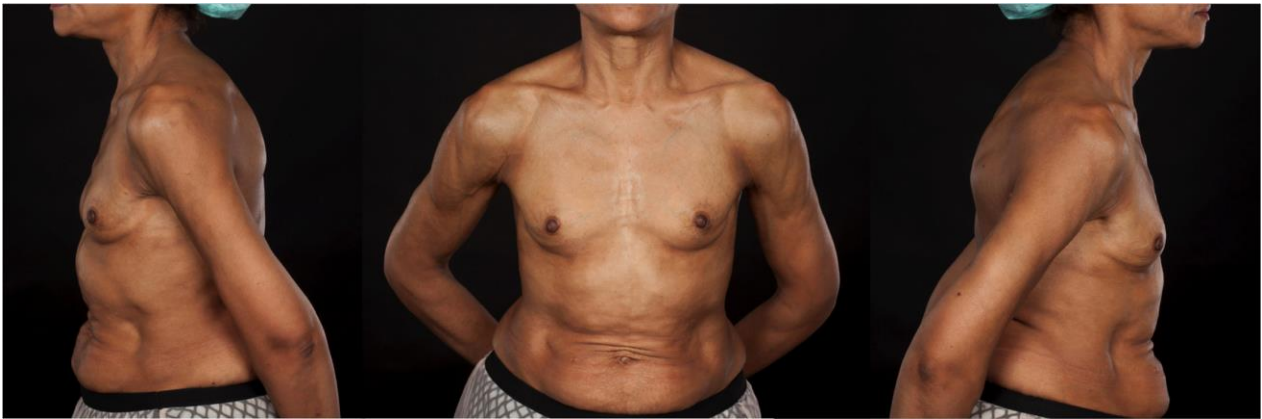
Figure 6. 4 months post-operative 2nd fat transfer procedure to both breasts



PATIENT'S PERSPECTIVE

In regards to my own perspective, I am eternally grateful to the team who have undertaken these procedures to 'rebuild' my face. It has allowed me to be confident in myself and become less hesitant to go out and socialise. I have noticed that during heavy stressful periods and where is anxiety and sadness, this also seemed to affect my face and upper body in a negative way.