

# Archives of Disease in Childhood

## A child in shock: carotid blowout syndrome

Journal:	<i>Archives of Disease in Childhood</i>
Manuscript ID	edpract-2019-317052.R2
Article Type:	Problem solving in clinical practice
Edition:	not in use
Date Submitted by the Author:	18-Jul-2019
Complete List of Authors:	Stilwell, Philippa Anna; University College London Hospital, General Paediatrics Robertson, Fergus; Great Ormond Street Hospital For Children NHS Foundation Trust Bhate, Sanjay; Great Ormond Street Hospital For Children NHS Foundation Trust Sutcliffe, Alastair; Institute of Child Health, General and Adolscnt Paediatric Unit
Keywords:	Accident & Emergency, Haematology, General Paediatrics, Neurosurgery

SCHOLARONE™  
Manuscripts

**A child in shock: carotid blowout syndrome**

Philippa Anna Stilwell<sup>a</sup>, MBChB, BSc, Fergus Robertson<sup>b</sup> MA, MBBS, MRCP, FRCR,  
Sanjay Bhat<sup>b</sup>, MDMRCPCH, Alastair Sutcliffe<sup>a,c</sup> MBChB, MD, PhD, FRCP, FRCPC, PG  
Dip CT

**Affiliations:** <sup>a</sup>University College London Hospital, London, England; and <sup>b</sup>Great Ormond Street Hospital for Children, London, England; and <sup>c</sup>Institute of Child Health, London, England

**Address correspondence to:** Philippa Anna Stilwell. Department of General Paediatrics, University College London Hospital, 235 Euston Road, Fitzrovia, London NW1 2BU. Email: philippa.stilwell@nhs.net. Telephone: 07745653657.

**Word count: 3375**

## Abstract

Paediatricians commonly encounter neck lumps during their routine clinical practice; vascular abnormalities, such as (pseudo)aneurysms, are a rare cause of these. Pseudoaneurysms of the carotid artery in children are usually the result of blunt or penetrating trauma, infection or vasculitis/connective tissue disorders. They can present with a variety of symptoms including neck pain, as a pulsatile neck mass or with compressive symptoms (for example, cranial nerve palsies or dyspnoea). Pseudoaneurysms carry a risk of rupture in which case they are fatal, unless immediate treatment is provided.

We report a 17 month old male child with idiopathic carotid artery blowout syndrome presenting with acute oropharyngeal haemorrhage leading to asystolic cardiac arrest. He was successfully resuscitated and emergency embolisation controlled the bleeding. Despite extensive left hemispheric infarct, he has survived and made a remarkable recovery.

Carotid artery blowout syndrome needs to be recognised as a potential cause of major haemorrhage in childhood. The purpose of this case report is to remind readers of the differential diagnosis and work-up of a child presenting with a neck lump, to highlight important aspects of the acute management of major haemorrhage and massive blood transfusion in paediatrics, to describe the aetiology, presentation and management of carotid artery pseudoaneurysm in children and to discuss long term rehabilitation in patients with consequent neurological sequelae (including the need for input from multiple specialty teams).

### Case part 1: antecedent events

A 17m old boy presented to the Emergency Department (ED) with a five day history of neck swelling and fever. He had previously seen the GP who had diagnosed him with mumps. The swelling had progressed, however, so his parents decided to seek further medical attention. On examination in ED, he had a 4 x 4cm fluctuant, non-pulsatile, neck swelling behind his left ear with overlying erythema. His inflammatory markers were raised (WCC 27 and CRP 167) and an ultrasound (without dopplers) confirmed lymphadenitis, with no evidence of suppurative change/necrosis, abscess formation or arterial abnormality. He was admitted to the ward for IV antibiotics, which were stepped down to oral therapy when he had clinically improved the following day.

### Commentary: neck lumps

#### *Aetiology*

Paediatricians commonly encounter neck lumps during their routine clinical practice. They are usually benign in nature, and may be congenital or of infectious origin – commonly, reactive lymphadenopathy, lymphadenitis or mycobacterial infections. Rarely, they may be due to vascular abnormalities or malignancy [1-5].

#### *Diagnostic work up – history and examination*

A systematic approach to neck lumps based on anatomy, the age of the patient as well as the history and clinical features should lead to fewer (unnecessary) investigations and a reduction in parental anxiety. Key features of the clinical history include the duration of symptoms, location of the lump(s), pattern of progression of the swelling, presence of tenderness, local and systemic signs/symptoms and recent exposures/travel. When examining neck lumps, clinicians should take particular attention to their location, size, number, mobility,

1  
2  
3 presence/absence of tenderness, and the features of the overlying skin. General examination  
4  
5 of the child is also essential to look for other features of, for example, malignancy or systemic  
6  
7 disease. Vascular abnormalities, such as (pseudo)aneurysms, tend to be pulsatile and may  
8  
9 have a bruit on auscultation; systemic examination may reveal evidence of trauma, a  
10  
11 connective tissue disorder or vasculitis (indicating the underlying aetiology of the  
12  
13 (pseudo)aneurysm). Clues to the diagnosis of a neck lump in a child, from the history and  
14  
15 examination, are summarised in Table 1.  
16  
17  
18  
19  
20  
21  
22  
23  
24  
25  
26  
27  
28  
29  
30  
31  
32  
33  
34  
35  
36  
37  
38  
39  
40  
41  
42  
43  
44  
45  
46  
47  
48  
49  
50  
51  
52  
53  
54  
55  
56  
57  
58  
59  
60

**Table 1: Diagnostic clues in the history and examination for paediatric neck lumps**

Diagnosis	Key features in history	Key findings on examination	
		Local	General
<b>Congenital</b>	Present since birth	Location: midline (e.g. thyroglossal duct cyst, dermoid cyst) versus. lateral (e.g. branchial arch cyst, cystic hygroma)	Systemically well
<b>Infectious</b>	Fevers Local pain Acute onset/rapidly enlarging Travel, TB contacts HIV risk factors Unimmunised (e.g. mumps) Cat scratch (e.g. cat scratch disease) Drinking unpasteurised milk (e.g. toxoplasmosis) Symptoms suggestive of a local infection (e.g. history of earache, upper respiratory tract infection)	Shotty enlarged lymph nodes (suggests reactive lymphadenopathy) Erythema and tenderness on palpation	Splenomegaly (e.g. EBV) Rash, non-purulent conjunctivitis, erythema of lips, extremity changes (e.g. Kawasaki's)
<b>Malignant</b>	Rapidly enlarging Enlarge during a course of antibiotic therapy B symptoms (fever, night sweats, weight loss) Persist for > 6 weeks Usually not painful	Hard, fixed, rubbery, irregular > 2cm Location: supraclavicular/posterior triangle node Midline thyroid mass	Pallor Hepato +/- splenomegaly (e.g. lymphoma) Generalised or multiple anatomic sites of lymphadenopathy Signs of pancytopenia (e.g. bruising)
<b>Vascular</b>	History of trauma, connective tissue disorder or vasculitis Pulsatile mass	Pulsatile Bruit Usually lateral	Features of a connective tissue disorder or vasculitis

### *Diagnostic work up - investigations*

Where further investigation of a neck lump is deemed necessary, the clinician should consider blood tests and/or serology/tumour markers where there is a suspected infective or malignant cause. Ultrasonography (US) tends to be the most common radiological investigation performed as it will differentiate a cystic lesion from a solid one and can help to characterise the neck lump further [6] by determining the size, consistency, shape, vascularity and location of the mass.

Ultrasound has been reported to have 95% sensitivity and 83% specificity in the differentiation between malignant and reactive lymph nodes [7]; malignancy (lymphoma) is more likely with an abnormally shaped, homogeneous, hypoechoic lymph node, compared with a heterogeneous lymph node that retains its normal architecture, with surrounding inflammation and central liquefaction (typical of inflamed/infected lymph nodes) [8].

Computed tomography (CT) and magnetic resonance imaging (MRI) can provide more detailed information about the anatomical location, lesion characteristics and surrounding structures [6].

Excisional biopsy is gold standard for histological investigation [9-10]. This is because excisional biopsy removes the entire lymph node and thus usually provides sufficient tissue to allow microscopic examination of all regions of the lymph node [11]. Although fine-needle aspiration biopsy (FNAB) has a well established role in the evaluation of an adult head and neck mass, it remains under-used in children [12]. The reason that it has not been adopted in paediatric practice is in part due to lack of experience in interpreting the cytomorphological features of malignant cells in children and due to concerns regarding the validity of cytology in evaluating lymph nodes in children [13]. A recent systematic review [5] found that overall, FNAB had a specificity of 92%-100% for diagnosing cancer and a sensitivity of 67%-100%.

1  
2  
3 A large study following this review evaluated 217 children biopsied in a tertiary centre and  
4  
5 found that the sensitivity of FNA was 92% with a specificity of 100% [14]. Two cases of  
6  
7 lymphoma were missed and misdiagnosed as reactive lymphadenitis. In short, FNAB  
8  
9 performs variably in excluding cancer.  
10  
11

### 12 13 **Case part 2: resuscitation** 14

15  
16 Three days following discharge, the young boy re-presented to the same ED as a London  
17  
18 Ambulance Service blue call, with bleeding from his mouth 'like an open tap'. On arrival, he  
19  
20 was in severe shock. His airway was patent but he was tachypnoeic with a respiratory rate of  
21  
22 36/min, and tachycardic with a heart rate of 177bpm. His blood pressure and oxygen  
23  
24 saturations were unrecordable. He was assessed using a structured 'Airway, breathing,  
25  
26 circulation, disability, exposure (ABCDE)' approach: the airway was secured shortly after his  
27  
28 arrival. There was difficulty obtaining intra-venous access (as he was so shut down  
29  
30 peripherally). Intra-osseous access was obtained (twice) but unfortunately failed to allow  
31  
32 fluid administration. Eventually, an intra-venous line was cited by the senior registrar,  
33  
34 allowing volume resuscitation to be initiated.  
35  
36  
37  
38  
39

40  
41 Despite this, he deteriorated and went into asystolic cardiac arrest within fifteen minutes of  
42  
43 arrival to the ED. He remained in asystolic arrest for sixteen minutes. The team resuscitated  
44  
45 him using Advanced Paediatric Life Support (APLS) algorithms. Throughout this time, the  
46  
47 bleeding from his mouth could not be controlled so a 'major haemorrhage' call was put out.  
48  
49 Over the course of the resuscitation, the child lost the equivalent of his entire circulating  
50  
51 blood volume and had an 'un-recordable' pH for at least sixty-two minutes. Multiple blood  
52  
53 products were administered, including packed red cells (1080ml), platelets, fresh frozen  
54  
55 plasma, fibrinogen and factor 7. He was also given desmopressin and anti-fibrinolytic therapy  
56  
57 (tranexamic acid), before being started on an adrenaline infusion.  
58  
59  
60



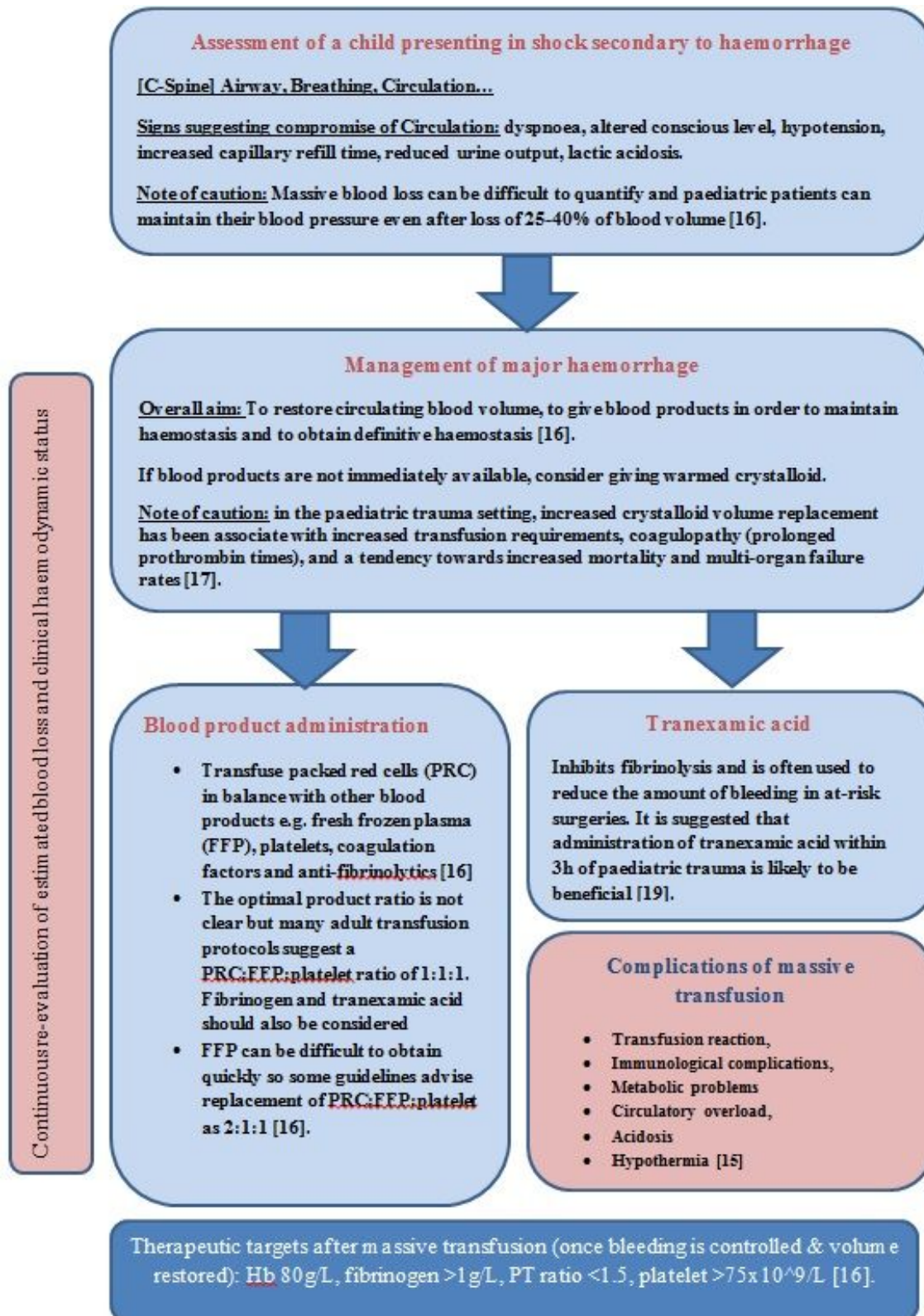
1  
2  
3 There were over twenty professionals involved in this child's resuscitation, including  
4  
5 specialists from a range of backgrounds: paediatrics, anaesthetics, intensive care, gastro-  
6  
7 enterology, ear, nose and throat (ENT) and maxillo-facial surgery.  
8  
9

### 10 11 **Commentary: paediatric massive transfusion**

#### 12 13 14 *Definition*

15  
16  
17 Massive transfusion in paediatrics has been defined by Diab et al. [15] as receiving a packed  
18  
19 red blood cell transfusion of 50% of total blood volume (TBV) in 3 hours or 100% of TBV in  
20  
21 24 hours or >10% of TBV per minute. Flowchart 1 summarises key factors to consider when  
22  
23 assessing and managing a child presenting in shock secondary to major haemorrhage.  
24  
25  
26  
27  
28  
29  
30  
31  
32  
33  
34  
35  
36  
37  
38  
39  
40  
41  
42  
43  
44  
45  
46  
47  
48  
49  
50  
51  
52  
53  
54  
55  
56  
57  
58  
59  
60

**Flowchart 1: Flowchart summarising key points to consider when assessing and managing a child presenting with major haemorrhage [Available as a word file in supplementary file 1].**



1  
2  
3  
4  
5  
6  
7  
8  
9  
10  
11  
12  
13  
14  
15  
16  
17  
18  
19  
20  
21  
22  
23  
24  
25  
26  
27  
28  
29  
30  
31  
32  
33  
34  
35  
36  
37  
38  
39  
40  
41  
42  
43  
44  
45  
46  
47  
48  
49  
50  
51  
52  
53  
54  
55  
56  
57  
58  
59  
60

Confidential: For Review Only

### *Major haemorrhage protocols*

Major haemorrhage protocols, such as that published by the paediatric Advanced Life Support Group (updated in 2016), have been developed to guide resuscitation, facilitate communication and prevent coagulopathy in paediatric major haemorrhage. The use of major haemorrhage protocols in adults has resulted in faster delivery of blood products, decreased rates of multi-organ failure and improved 30-day survival [20]. In paediatrics, use of major haemorrhage protocols has been shown to reduce time to transfusion [18]. It also has the potential to prevent excessive use of crystalloid, correct and prevent coagulopathy and minimise the complications of massive transfusion [17]. It must be noted that major haemorrhage protocols are not blood product prescriptions and that decision to administer blood products must remain the choice of the treating clinician, in accordance with the clinical situation.

### **Case part 3: initial diagnosis and outcome**

Following return of spontaneous circulation, the child underwent an emergency gastro-intestinal endoscopy whilst still in the resuscitation room in ED. Although a clot was found in the fundus of the stomach, no gastro-intestinal source of the bleeding was seen. The bleeding appeared to be coming from his oropharynx. The presumed bleeding point was packed using adrenaline-soaked gauze by the ENT surgeons, but this only partially controlled bleeding.

The child was therefore transferred to a tertiary centre, with a physician from the Children's Acute Ambulance Service (CATS) manually holding adrenaline-soaked gauze in the child's mouth throughout the ambulance journey. On arrival, the child underwent an emergency angiography, which revealed active extravasation from a pseudoaneurysm of the left cervical internal carotid artery (ICA) [figure 1A]. The extravasation was stopped with trans-arterial coil embolisation of the left ICA. The external carotid artery was deliberately maintained

1  
2  
3 patent to maintain maximal collateral potential to the distal carotid territory from its branches.  
4  
5 A final angiography demonstrated occluded left ICA flow [figure 1B]. Supplementary  
6  
7 injection of a liquid embolic into the coils mass, though considered, was rejected on the basis  
8  
9 of the additional risk of distal embolisation through the coil mass. There was no further  
10  
11 bleeding overnight. Computed tomography (CT) of the brain the following morning showed  
12  
13 extensive infarction in the left cerebral hemisphere [figure 2B] and recanalization of the  
14  
15 previously occluded left ICA [figure 2A] through (and distal to) the coil mass, although no  
16  
17 further extravasation. Catheter angiography also confirmed this situation and, having already  
18  
19 placed coils to the origin of the ICA, a balloon occlusion of the common carotid artery was  
20  
21 necessary to ensure permanent closure of the ruptured segment. This inevitably closed the  
22  
23 external carotid artery also. The procedure performed to re-occlude the vessel with a  
24  
25 detachable balloon placed proximally is shown in figure 3A. Final contralateral ICA contrast  
26  
27 injection demonstrated good cross-flow to the left hemisphere [figure 3B]. This reassured the  
28  
29 interventional radiologists that collaterals would be supporting the entire cranial circulation.  
30  
31  
32  
33  
34

### 35 36 **Commentary: pseudo-aneurysm**

37  
38  
39 A pseudoaneurysm occurs when there is a breach to the vessel wall, such that blood leaks  
40  
41 through the wall but is contained by the adventitia or surrounding perivascular soft tissue  
42  
43 [21]. This finding distinguishes it from a true aneurysm, in which the arterial wall is intact but  
44  
45 expanded [22-23].  
46  
47  
48

### 49 *Presentation*

50  
51  
52 Pseudoaneurysms of the neck arteries are rare in the paediatric age group – few reports are  
53  
54 found in the literature [24-31]. Children with carotid artery pseudoaneurysms can present  
55  
56 with a range of complaints, including a pulsatile neck mass [32] or thromboembolic episodes  
57  
58  
59  
60

1  
2  
3 [26]. A cervical mass can compress the upper airways leading to dyspnoea [33-34] or nerves  
4 leading to focal palsies [31], dysphagia or Horner's syndrome [4].  
5  
6  
7

8 Carotid artery (pseudo)aneurysms carry a risk of rupture (known as carotid blowout  
9 syndrome) and bleeding, which can be further contained by the neck tissues or rarely into the  
10 oropharyngeal tract [24, 35-36]. In the rare event of carotid artery blowout, bleeding can be  
11 fatal unless immediate treatment is instigated.  
12  
13  
14  
15  
16  
17

### 18 *Aetiology*

19  
20  
21  
22 Pseudoaneurysms of the carotid artery in children are usually the result of blunt or  
23 penetrating trauma [23], infection or vasculitis/connective tissue disorders [24-26]. This  
24 child's carotid artery rupture was initially suspected to be secondary to an invasive, infective  
25 lymphadenitis (given the antecedent history of lymphadenitis) but a repeat ultrasound of the  
26 neck at the tertiary centre did not reveal any enlarged or necrotic lymph nodes. Retrospective  
27 review of his initial ultrasound (when he presented with lymphadenitis) did not reveal any  
28 evidence of arterial abnormality. There was never any positive microbiology isolated, though  
29 a naso-pharyngeal aspirate was positive for adenovirus. Magnetic resonance imaging (MRI)  
30 of the cardiovascular system did not reveal any evidence of large vessel vasculitis and the  
31 coronary arteries looked normal. No clear pathogenic DNA connective tissue disorder  
32 variants were detected and a skin biopsy showed normal collagen. A full haematology work-  
33 up was also normal. This child's ICA pseudoaneurysm was most likely to be idiopathic,  
34 although the treating team still suspect an inflammatory contributing component.  
35  
36  
37  
38  
39  
40  
41  
42  
43  
44  
45  
46  
47  
48  
49  
50  
51

### 52 *Investigations*

53  
54  
55 The diagnosis of pseudoaneurysms can be made with doppler ultrasonography (US), CT  
56 Angiography (CTA), MRI and catheter angiography [24]. A pseudoaneurysm has a range of  
57  
58  
59  
60

1  
2  
3 ultrasound appearances dependent upon the state of thrombosis within it. If there is  
4  
5 extraluminal flow within the sac, the diagnosis can be easily made on colour doppler flow  
6  
7 imaging. However, if the sac is occluded with variably echogenic thrombotic material,  
8  
9 confusion with other neck masses is possible. Although doppler US can confirm a mass to be  
10  
11 of vascular origin and allow blood-flow assessment [37], CTA is the preferred modality since  
12  
13 it provides information about the structure and status of surrounding vessels (including  
14  
15 intracranial circulation) [31]. MRI and MR angiography may add value by helping to  
16  
17 visualise both the pseudoaneurysm and the surrounding tissue and also evaluate the distal  
18  
19 organ (i.e. the brain) [4]. Digital subtraction catheter angiography will define the anatomy of  
20  
21 the pseudoaneurysm and importantly assess for collateral circulation [25, 32] and can be  
22  
23 combined with endovascular treatment, as in our case.  
24  
25  
26  
27

### 28 *Management of pseudoaneurysm*

29  
30  
31  
32 The best treatment modality for pseudoaneurysm will depend on the morphology of the  
33  
34 pseudoaneurysm, its location, the age of the patient, physician preference, available  
35  
36 resources, and, most importantly, the status of collateral circulation to brain [10].  
37  
38  
39

40  
41 Conservative management with close long-term follow-up should be reserved for small,  
42  
43 stable pseudoaneurysms [35]; discussions should be had in each individual case to determine  
44  
45 whether an anti-thrombotic agent should be considered. Invasive management options  
46  
47 include endovascular repair [38] – constructive with covered stenting favourable in the  
48  
49 absence of infection or deconstructive by occluding the damaged vessel segment, if felt to be  
50  
51 adequate collaterals. Alternatively, surgical repair can be ligation of the carotid artery with or  
52  
53 without bypass procedure and/or arterial reconstruction [24, 30, 34, 36]. Perioperative stroke  
54  
55 and cranial nerve injuries are recognised serious complications from invasive carotid artery  
56  
57 repair [24, 39]. In our case, emergency carotid sacrifice was felt to be the only viable option  
58  
59  
60

1  
2  
3 in such an extreme situation in a small child. Parent vessel sacrifice is often preferred in  
4  
5 paediatric patients, due to generally reliable collateralisation of distal vascular territories and  
6  
7 also small vessel size, often considered too small to safely deliver conventional stents and  
8  
9 with additional requirement of antiplatelet therapy in the setting of haemorrhage. Surgical  
10  
11 arterial bypass is challenging particularly in haemodynamically unstable patients.  
12  
13

#### 14 **Case part 4: progress on intensive care and in the community**

15  
16  
17 Following the child's second procedure in the angiography suite, he went to intensive care  
18  
19 where he spent twenty days in total. He was paralysed, sedated and required inotropic support  
20  
21 and further blood products. He was intubated and ventilated for twelve days and cooled  
22  
23 therapeutically for six days.  
24  
25

26  
27  
28 Whilst recovering in intensive care, the child underwent decompressive hemi-craniotomy  
29  
30 (with bolt insertion) for management of cerebral oedema and midline shift - to prevent  
31  
32 herniation [figure 2C].  
33  
34

35  
36 Following extubation, the child had minimal right sided motor function. He received  
37  
38 intensive input from multiple therapy teams including physiotherapy, speech and language  
39  
40 and occupational therapy. Twelve months after the acute event, the child has shown  
41  
42 significant improvement in his right sided function with less right sided arm neglect. He is  
43  
44 able to lift his right hand but cannot use his fingers yet. He has started to take small unsteady  
45  
46 steps with support, and a few steps unsupported. There is a left-hand preference for feeding,  
47  
48 scribbling and playing. He demonstrates good comprehension and has passed his audiology  
49  
50 and vision checks. The speech and language team believe that he is making good progress  
51  
52 with his speech, although perhaps not as rapidly as a 'typically' developing child. He has  
53  
54 approximately twenty words in total and points to indicate his needs. He is sociable and  
55  
56 interactive.  
57  
58  
59  
60



1  
2  
3 This child also suffered from very poor sleep in the period following his intensive care  
4 admission and required melatonin. The family were also referred to a local psychologist to  
5  
6 provide post-traumatic support.  
7  
8  
9

## 10 **Commentary: childhood stroke and rehabilitation**

### 11 *Mechanism of left-sided infarct*

12  
13  
14  
15  
16  
17 There are multiple potential mechanisms underlying this child's stroke. These include an  
18 embolus from the carotid pseudoaneurysm [40-41] or a combination of the severe  
19  
20 hypotension and impaired flow in the left ICA during the haemorrhage and resuscitation  
21  
22 period. It is unclear the extent to which endovascular occlusion contributed to the extent of  
23  
24 the infarction, possibly relatively little, but it is clear that without adequate early control of  
25  
26 active extravasation from the carotid blow-out, the situation was not survivable.  
27  
28  
29  
30

### 31 *Impact of childhood stroke*

32  
33  
34  
35 A stroke during childhood disrupts the brain's development and affects emerging neural  
36  
37 networks. The clinical sequelae of paediatric stroke is highly variable and is influenced by  
38  
39 many factors, such as the characteristics of the lesion, the child's age, developmental level  
40  
41 and cognitive abilities. Long term neurological impairment, including motor, cognitive and  
42  
43 language deficits, have been reported in 50 to 60 per cent of children after childhood stroke  
44  
45 [42-43]. Childhood stroke can cause impairment in already established skills and disrupt the  
46  
47 development of emerging skills. The spectrum of difficulties experienced after either an  
48  
49 ischaemic or haemorrhagic stroke is broad, with reported deficits in all domains of the  
50  
51 International Classification of Functioning, Disability and Health (ICF) framework [44].  
52  
53  
54  
55  
56 The psychosocial impact of stroke on children has also been recognised; predictors of poor  
57  
58 outcome include older age at onset, acute neurological impairment, pre-stroke social  
59  
60

1  
2  
3 problems and poorer parental mental health status [45]. This suggests that support for whole  
4 families, as was offered in our case, may improve the child's long-term outcome. The Stroke  
5 Association have published a very useful factsheet on Childhood Stroke [46], which explains  
6 the causes, treatment, and impact strokes can have on children and family. The factsheet also  
7 lists other sources of help and support, such as the Stroke Association and the Children's  
8 Brain Injury Trust. Intact psychosocial function is critical to many aspects of long-term  
9 adjustment including mental health, quality of life, academic progress, employment and  
10 functioning within the community [45].  
11  
12  
13  
14  
15  
16  
17  
18  
19  
20  
21

### 22 *Rehabilitation*

23  
24  
25 A multi-disciplinary rehabilitation team (MDT) helps to ensure best possible neuro-motor  
26 recovery after a stroke in children [47]. The rehabilitation must be adapted to the child, his or  
27 her age, and the age at which the stroke occurred. The recently published RCPCH Childhood  
28 Stroke Guideline (2017) [48] makes evidence-based recommendations on planning discharge  
29 and rehabilitation after stroke. An assessment of a child's functions should be made within 72  
30 hours of the stroke (or as soon as the child is medically stable) [49]. Early liaison with  
31 community-based MDT members (medical, nursing and allied health professionals including  
32 education staff, occupational therapists, physiotherapists, orthoptists, psychologists, speech  
33 and language therapists) is encouraged, to start planning discharge and rehabilitation.  
34  
35  
36  
37  
38  
39  
40  
41  
42  
43  
44  
45

46 Baseline assessments should be undertaken before initiating any intervention. There is a lack  
47 of strong evidence to guide the optimal rehabilitation approach and long-term care of these  
48 children. An individualised approach is therefore indicated and priorities/needs may change  
49 as a child progresses through life [48-49].  
50  
51  
52  
53  
54  
55

56 Evidence from adult stroke suggests that intensive neuro-rehabilitation improves the rate of  
57 recovery and outcome within the first six months after stroke [50-51] but the optimal dosage  
58  
59  
60

1  
2  
3 and timing of specific therapies is an emerging area of research. Chen et al. [42] found that in  
4  
5 a mixed population of children with acquired brain injury who were admitted for  
6  
7 rehabilitation, larger improvements in self-care, mobility and cognition were found in those  
8  
9 who started at lower baselines and received more occupational therapy, physical therapy and  
10  
11 speech and language therapy. Although there are defined targets for the amount of time that  
12  
13 should be spent on rehabilitation (per day) in adults, in children, tolerance varies according to  
14  
15 various factors such as developmental age, fatigue and behaviour [48]. Motor interventions  
16  
17 should be focussed on functional goals and time since stroke should not be a barrier for the  
18  
19 consideration of intensive training [48].  
20  
21  
22

### 23 24 25 *Effect on staff morale*

26  
27  
28 The entire treating (resuscitation) team were informed of the patient's outcome by the team  
29  
30 leader. This was felt to have a positive effect on staff morale, especially considering the  
31  
32 gravity of the situation. The parents have since written a blog about their journey, which can  
33  
34 be found at: <https://monkey-on-the-road.com/>.  
35  
36  
37

### 38 **Conclusion**

39  
40  
41 The unusual presentation of carotid artery pseudo-aneurysm should serve to expand the  
42  
43 differential diagnosis for the paediatric clinician. Although carotid artery pseudoaneurysm is  
44  
45 an uncommon pathology in the paediatric population, it is essential for the paediatric clinician  
46  
47 to maintain a high index of suspicion, both in the presence and absence of trauma. Paediatric  
48  
49 clinicians should familiarise themselves with their local major haemorrhage protocol,  
50  
51 ensuring that paediatric specific guidance is in place. Securing the airway and maintaining  
52  
53 perfusion are key aspects of management of a child with haemorrhage who has become  
54  
55 haemodynamically unstable. We would also advocate for being cautious in making decisions  
56  
57 to cease resuscitation based purely on numbers: this child survived despite 16 minutes of  
58  
59  
60

1  
2  
3 asystolic arrest and 62 minutes of having an 'unrecordable' pH. His recovery is in keeping  
4  
5 with his neuroimaging at the time of his initial presentation. It is important to be mindful of  
6  
7 the psychological impact that witnessing haemorrhagic induced cardiac arrest can have on  
8  
9 parents and staff, and to be aware of the support services that are available. We hope that this  
10  
11 article will facilitate a better understanding of this topic and aid physicians in early  
12  
13 recognition and acute and long-term multi-disciplinary management of affected children and  
14  
15 their parents.  
16  
17  
18  
19

### 20 **Multiple choice questions**

21  
22 The most common aetiology of neck lumps in children are:

- 23  
24  
25 A: congenital and infectious  
26 B: malignancy  
27 C: vascular abnormalities  
28 D: trauma  
29

30 Answer: A

31  
32 In an unstable child suffering from major haemorrhage, the first priority is:

- 33  
34  
35 A: to stop the bleeding  
36 B: to secure the cervical spine and airway  
37 C: to obtain IV access and volume resuscitate  
38 D: to take a thorough history and examine the child  
39

40 Answer B

41  
42 Stroke in childhood can impact:

- 43  
44  
45 A: motor function only  
46 B: motor, cognitive and language development  
47 C: none of the above  
48 D: language development only  
49

50 Answer B

51  
52 Pseudoaneurysms in children are most commonly caused by:

- 53  
54  
55 A: trauma, infection or vasculitis/connective tissue disorders  
56 B: malignancy  
57 C: congenital abnormalities  
58 D: iatrogenic  
59  
60

1  
2  
3 Answer A  
4  
5  
6  
7  
8  
9  
10  
11  
12  
13  
14  
15  
16  
17  
18  
19  
20  
21  
22  
23  
24  
25  
26  
27  
28  
29  
30  
31  
32  
33  
34  
35  
36  
37  
38  
39  
40  
41  
42  
43  
44  
45  
46  
47  
48  
49  
50  
51  
52  
53  
54  
55  
56  
57  
58  
59  
60

Confidential: For Review Only

## References

1. Badawy MK. Pediatric neck masses. *Clinical Pediatric Emergency Medicine*. 2010; 11(2): 73–80.
2. Goins MR, Beasley MS. Pediatric neck masses. *Oral and Maxillofacial Surgery Clinics of North America*. 2012; 24(3): 457–468.
3. Friedman ER, John SD. Imaging of pediatric neck masses. *Radiologic Clinics of North America*. 2011; 49(4): 617–632.
4. Roger MTJ, Marcus F, Emmanuel F, et al. Pseudoaneurysm of the Common Carotid Artery in an Infant due to Swallowed Fish Bone. *Case Reports in Radiology*. 2015; 903150.
5. Locke R, Comfort R, Kubba H. When does an enlarged cervical lymph node in a child need excision? A systematic review. *International Journal Pediatric Otorhinolaryngology*. 2014; 78(3): 393-401.
6. King S. Lateral neck lumps: a systematic approach for the general paediatrician. *Journal of Paediatrics and Child Health*. 2017; 53(11): 1091-1095.
7. Unsal O, Soytaş P, Hascicek S, et al. Clinical approach to pediatric neck masses: retrospective analysis of 98 cases. *Northern Clinics of Istanbul*. 2017; 4(3): 225-232.
8. Meier JD, Grimmer JV. Evaluation and management of neck masses in children. *American Family Physician*. 2014; 89(5):353-358.
9. Dickson PV, Davidoff AM. Malignant neoplasms of the head and neck. *Seminars in Pediatric Surgery*. 2006; 15(2): 92– 8.
10. Ludwig BJ, Wang J, Nadgir RN, et al. Imaging of cervical lymphadenopathy in children and young adults. *American Journal of Roentgenology*. 2012; 199(5): 1105–13.

- 1  
2  
3 11. Farndon S, Behjati S, Jonas N, et al. How to use...lymph node biopsy in paediatrics.  
4  
5 Archives of Disease in Childhood: Education in Practice Edition. 2017; 0:1-5.  
6  
7
- 8 12. Huyett P, Monaco S, Choi S et al. Utility of Fine-Needle Aspiration Biopsy in the  
9  
10 Evaluation of Pediatric Head and Neck Masses. Otolaryngology – Head and Neck  
11  
12 Surgery. 2016; 154(5):928-935.  
13  
14
- 15 13. Shankar A, Daw S. Nodular lymphocyte predominant Hodgkin lymphoma in children  
16  
17 and adolescents – a comprehensive review of biology, clinical course and treatment  
18  
19 options. British Journal of Haematology. 2012; 159(3):288-98.  
20  
21
- 22 14. De Corti F, Cecchetto G, Vendraminelli R, et al. Fine-needle aspiration cytology in  
23  
24 children with supervivical lymphadenopathy. La Pediatria Medica e Chirurgica. 2014;  
25  
26 36(2):80-2.  
27  
28
- 29 15. Diab Y, Wong E, Luban N. Massive transfusion in children and neonates. British  
30  
31 Journal of Haematology. 2013; 161:15-6  
32
- 33 16. Blain S, Paterson N. Paediatric massive transfusion. British Journal of Anaesthesia  
34  
35 (Education). 2016; 16(8):269-275.  
36  
37
- 38 17. Spinella PC, Holcomb JB. Resuscitation and transfusion principles for traumatic  
39  
40 hemorrhagic shock. Blood reviews. 2009; 23(6):231-40.  
41  
42
- 43 18. Hendrickson JE, Shaz BH, Pereira G et al. Implementation of a pediatric trauma  
44  
45 massive transfusion protocol: one institution's experience. Transfusion.  
46  
47 2012;52(6):1228-36.  
48
- 49 19. Royal College of Paediatrics and Child Health. Evidence Statement. Major trauma  
50  
51 and the use of tranexamic acid in children. November 2012. Available at:  
52  
53 [https://www.rcem.ac.uk/docs/External%20Guidance/10k.%20Major%20trauma%20and%20the%20use%20of%20tranexamic%20acid%20in%20children%20Evidence%20statement%20\(RCPCH,%20Nov%202012\).pdf](https://www.rcem.ac.uk/docs/External%20Guidance/10k.%20Major%20trauma%20and%20the%20use%20of%20tranexamic%20acid%20in%20children%20Evidence%20statement%20(RCPCH,%20Nov%202012).pdf)  
54  
55  
56  
57  
58  
59  
60

- 1  
2  
3 20. Livingston MH, Singh S, Merritt NH. Massive transfusion in paediatric and  
4 adolescent trauma patients: incidence, patient profile, and outcomes prior to a massive  
5 transfusion protocol. *Injury*. 2014; 45(9): 1301-6.  
6  
7  
8  
9  
10 21. Kim HO, Bae Ji Y, Lee SH, et al. Cases of common carotid artery pseudoaneurysm  
11 treated by stent graft. *Case Reports in Otolaryngology*. 2012; 674827.  
12  
13  
14 22. Pearson SE, Choi SS. Pseudoaneurysm of the internal carotid artery: a case report and  
15 review of the literature. *Archives of Otolaryngology*. 2005; 131(5): 454–456.  
16  
17  
18 23. Nadig S, Barnwell S, Wax MK. Pseudoaneurysm of the external carotid artery -  
19 review of literature. *Head and Neck*. 2009; 31(1): 136–139.  
20  
21  
22  
23 24. Pourhassan S, Grottemeyer D, Fokou M, et al. Extracranial carotid arteries aneurysms  
24 in children. Single-center experiences in 4 patients and review of the literature.  
25 *Journal of Pediatric Surgery*. 2007; 42(11): 1961–1968.  
26  
27  
28 25. Beena NV, Kishore MS, Mahale A, et al. Pseudoaneurysm of internal carotid  
29 artery. *Indian Journal of Pediatrics*. 2007; 74(3): 307–309.  
30  
31  
32 26. Mahmoud M, Roshdi E, Benderbous D. Traumatic pseudoaneurysms of the common  
33 carotid and vertebral artery in a four-year-old child. *Interventional Neuroradiology*.  
34 2012; 18(3):348–352.  
35  
36  
37 27. Misra BK, Shaw JF. Haematemesis from distal extracranial carotid artery aneurysms.  
38 Case report and literature review. *Child's Nervous System*. 1986; 2(6): 329–332.  
39  
40  
41 28. Rajagopal KV, Lakhkar BN, Shetty D, et al. Spontaneous giant dissecting aneurysm  
42 of extracranial internal carotid artery. *Indian Journal Radiology and Imaging*. 2002;  
43 12(4): 517–520.  
44  
45  
46 29. Hart RG, Easton JD. Dissection of cervical and cerebral arteries. *Neurologic  
47 Clinics*. 1983; 1(1): 155–182.  
48  
49  
50  
51  
52  
53  
54  
55  
56  
57  
58  
59  
60



- 1  
2  
3 30. Singhal M, Gupta V, Singh P, et al. Iatrogenic life-threatening pseudoaneurysms of  
4 extracranial internal carotid artery after fine-needle aspiration of cervical lymph  
5 nodes: report of two cases in children. *CardioVascular and Interventional Radiology*.  
6 2009; 32(6): 1260–1263.  
7  
8  
9  
10  
11  
12 31. Zamiaty W, Kably MI, Kadiri R. A rare cause of recurrent laryngeal nerve palsy.  
13 *Journal de Radiologie*, 2005; 86(9): 1038–1039.  
14  
15  
16  
17 32. Windfuhr JP. Aneurysm of the internal carotid artery following soft tissue penetration  
18 injury. *International Journal of Pediatric Otorhinolaryngology*. 2001; 61 (2):155–159.  
19  
20  
21  
22 33. De Luccia N, da Silva ES, Aponchik M, Appolonio F, Benvenuti LA. Anévrysme  
23 congénital de l'artère carotide externe. *Annales de Chirurgie Vasculaire*. 2010; 24(3):  
24 457.e7–457.e10.  
25  
26  
27  
28  
29 34. Tannuri U, Mendes De Almeida N, Piske R, et al. Giant pseudoaneurysm of the  
30 internal carotid artery causing upper airway obstruction in a 10-month old infant  
31 treated y endovascular occlusion and surgical drainage. *Journal of Paediatric Surgery*.  
32 2003; 38(9): 1393-5.  
33  
34  
35  
36  
37  
38 35. Momiy J, Vasquez J. Iatrogenic vertebral artery pseudoaneurysm due to central  
39 venous catheterization. *Proceedings (Baylor University, Medical Center)*. 2011;  
40 24(2): 96–100.  
41  
42  
43  
44  
45 36. Tovi F, Leiberman A, Herizanu Y, et al. Pseudoaneurysm of the internal carotid artery  
46 secondary to tonsillectomy. *International Journal of Pediatric Otorhinolaryngology*.  
47 1987; 13(1): 69–75.  
48  
49  
50  
51  
52 37. Constantinides H, Passant C, Waddell AN. Mycotic pseudoaneurysm of common  
53 carotid artery mimicking parapharyngeal abscess. *Journal of Laryngology and*  
54 *Otology*. 2000; 114(10): 796-797.  
55  
56  
57  
58  
59  
60

- 1  
2  
3 38. Gralla J, Brekenfeld C, Schmidli J, et al. Internal carotid artery aneurysm with life-  
4 threatening hemorrhages in a pediatric patient: endovascular treatment options.  
5 Journal Endovascular Therapy. 2004; 11(6): 734-8.  
6  
7  
8  
9  
10 39. Garg K, Rockman CB, Lee V et al. Presentation and management of carotid artery  
11 aneurysms and pseudoaneurysms. Journal of Vascular Surgery. 2012; 55(6): 1618–  
12 1622.  
13  
14  
15  
16  
17 40. Wolfe SQ, Mueller-Kronast N, Aziz-Sultan MA et al. Extracranial carotid artery  
18 pseudoaneurysm presenting with embolic stroke in a pediatric patient. Case report.  
19 Journal of Neurosurgical Pediatrics. 2008;1(3):240-3  
20  
21  
22  
23  
24 41. Brinjikji W, Diehn FE, Lindsay CW, et al. Endovascular treatment of an infected  
25 pseudoaneurysm secondary to retropharyngeal abscess in a child. Interventional  
26 Neuroradiology. 2015;21(4):538-42.  
27  
28  
29  
30  
31 42. deVeber G, MacGregor D, Curtis R, et al. Neurologic outcome in survivors of  
32 childhood arterial ischemic stroke and sinovenous thrombosis. Journal of Child  
33 Neurology. 2000; 15(5): 316– 24.  
34  
35  
36  
37  
38 43. Mallick AA, Ganesan V, Kirkham FJ, et al. Outcome and recurrence 1 year after  
39 pediatric arterial ischemic stroke in a population-based cohort. Annals of Neurology.  
40 2016; 79:784– 93.  
41  
42  
43  
44  
45 44. World Health Organization. International Classification of Functioning, Disability and  
46 Health (ICF). Geneva: World Helath Organization; 2007.  
47  
48  
49  
50 45. Greenham M, Anderson V, Hearps S et al., Psychosocial function in the first year  
51 after childhood stroke. Developmental Medicine and Childhood Neurology. 2017;  
52 59(10): 1027-1033  
53  
54  
55  
56 46. Stroke Association. Childhood Stroke Factsheet. 2012. Available at:  
57 [https://www.stroke.org.uk/sites/default/files/childhood\\_stroke.pdf](https://www.stroke.org.uk/sites/default/files/childhood_stroke.pdf)  
58  
59  
60

- 1  
2  
3 47. Jouishomme C, Kehlhoffner P, Ros JC. Motor rehabilitation of a child after a stroke.  
4  
5 Soins Pédiatrie/Puericulture. 2017; 38(295): 24-27  
6  
7  
8 48. RCPCH Stroke Guideline. 2017. Available at: [https://www.rcpch.ac.uk/resources/stroke-](https://www.rcpch.ac.uk/resources/stroke-childhood-clinical-guideline-diagnosis-management-rehabilitation)  
9  
10 [childhood-clinical-guideline-diagnosis-management-rehabilitation](https://www.rcpch.ac.uk/resources/stroke-childhood-clinical-guideline-diagnosis-management-rehabilitation)  
11  
12 49. Gordon AL. 2014. Functioning and disability after stroke in children: using the ICF-  
13  
14 CY to classify health outcome and inform future clinical research priorities.  
15  
16 Developmental Medicine and Child Neurology. 2014; 56(5): 434-444.  
17  
18 50. Kwakkel G, van Peppen R, Wagenaar RC, et al. Effects of augmented exercise  
19  
20 therapy time after stroke: a meta-analysis. Stroke. 2004; 35(11): 2529-2539  
21  
22  
23 51. Lohse KR, Lang CE, Boyd LA. Is more better? Using metadata to explore dose-  
24  
25 response relationships in stroke rehabilitation. Stroke. 2014; 45(7): 2053-2058.  
26  
27  
28 52. Chen CC, Heinemann AW, Bode RK., et al. Impact of pediatric rehabilitation services  
29  
30 on children's functional outcomes. American Journal of Occupational Therapy 2004;  
31  
32 58(1): 44-53.  
33  
34  
35  
36  
37  
38  
39  
40  
41  
42  
43  
44  
45  
46  
47  
48  
49  
50  
51  
52  
53  
54  
55  
56  
57  
58  
59  
60

Review Only

1  
2  
3  
4 **Acknowledgements:** Nil  
5

6 **Conflict of Interest:** The authors have no potential conflicts of interest to disclose.  
7

8 **Funding Source:** No external funding for this manuscript.  
9

10 **Financial Disclosure:** The authors have no financial relationships relevant to this article to  
11 disclose.  
12

13 **Prior presentation of work:** The work has not been published elsewhere.  
14  
15  
16  
17  
18  
19  
20  
21  
22  
23  
24  
25  
26  
27  
28  
29  
30  
31  
32  
33  
34  
35  
36  
37  
38  
39  
40  
41  
42  
43  
44  
45  
46  
47  
48  
49  
50  
51  
52  
53  
54  
55  
56  
57  
58  
59  
60

Confidential: For Review Only

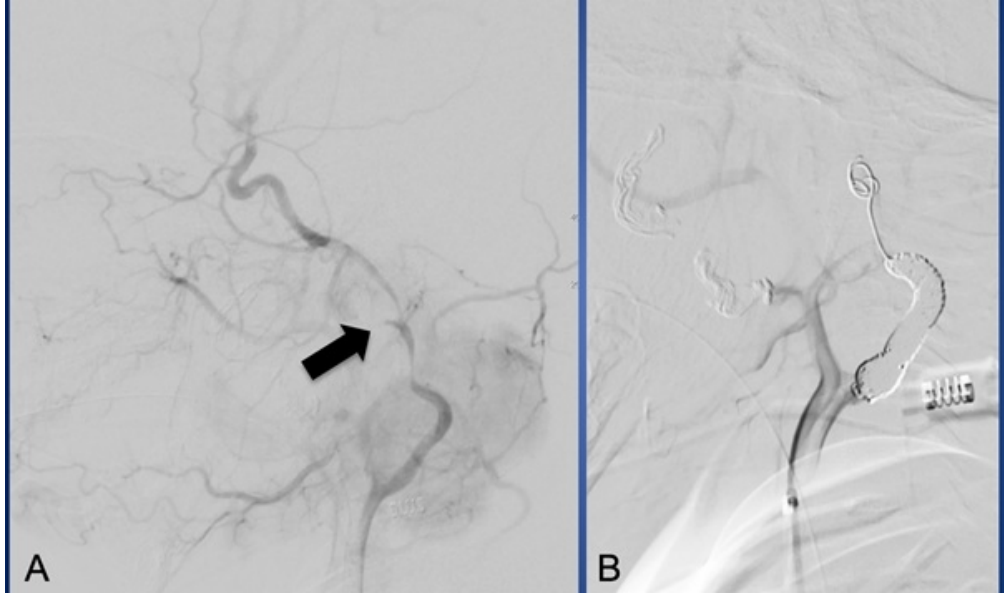
### Figure legends

**Figure 1:** Angiography of left carotid artery showing a rupture of the left cervical carotid artery (A) with active extravasation of contrast (arrow) and (B) with stasis post emergency coil embolisation.

**Figure 2:** (A) Coronal reconstruction of CT angiogram demonstrating perfusion of the cervical internal carotid artery through the coil mass (white arrow) (B) CT study showing progress to complete left middle cerebral artery territory infarction requiring decompressive floating craniotomy (C).

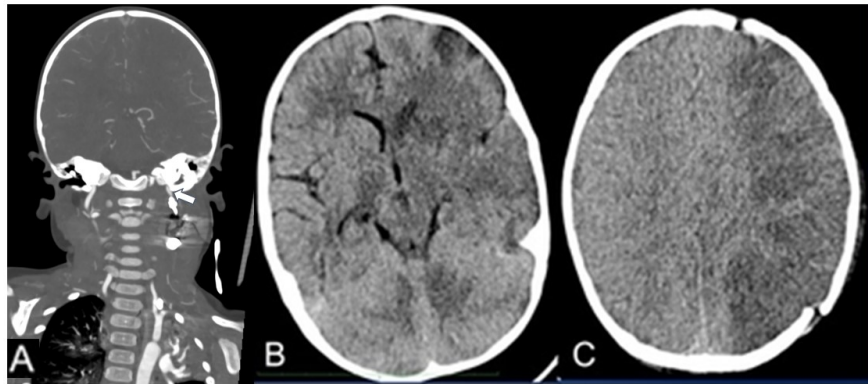
**Figure 3:** Repeat embolisation of left internal carotid artery with detachable balloon (A - black arrow) and frontal project of left vertebral contrast injection showing excellent filling of the left middle cerebral artery territory through large posterior communicating artery after left internal carotid artery sacrifice (B – black arrows).

1  
2  
3  
4  
5  
6  
7  
8  
9  
10  
11  
12  
13  
14  
15  
16  
17  
18  
19  
20  
21  
22  
23  
24  
25  
26  
27  
28  
29  
30  
31  
32  
33  
34  
35  
36  
37  
38  
39  
40  
41  
42  
43  
44  
45  
46  
47  
48  
49  
50  
51  
52  
53  
54  
55  
56  
57  
58  
59  
60



Angiography of left carotid artery showing a rupture of the left cervical carotid artery (A) with active extravasation of contrast (arrow) and (B) with stasis post emergency coil embolisation.

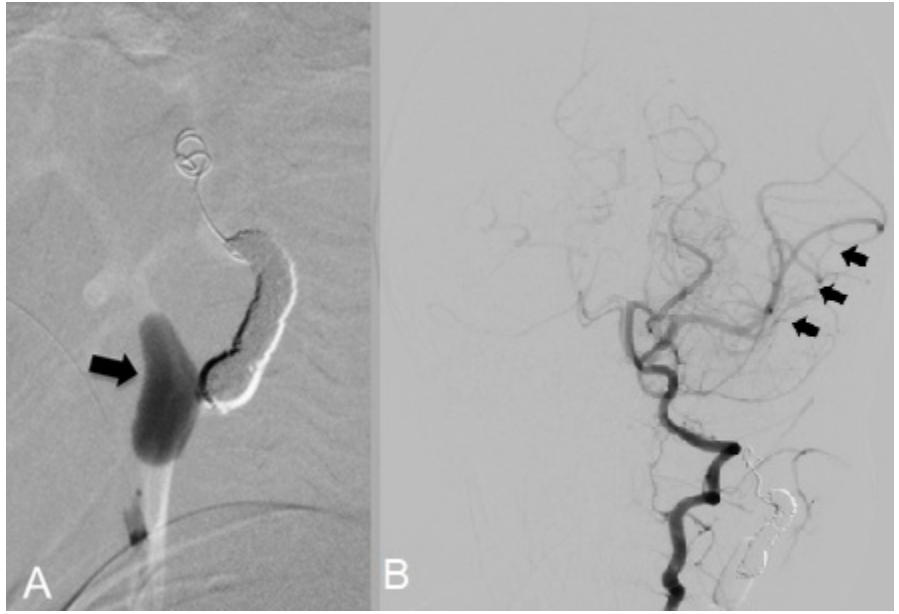
159x94mm (96 x 96 DPI)



(A) Coronal reconstruction of CT angiogram demonstrating perfusion of the cervical internal carotid artery through the coil mass (white arrow) (B) CT study showing progress to complete left middle cerebral artery territory infarction requiring decompressive floating craniotomy (C).

108x60mm (300 x 300 DPI)

1  
2  
3  
4  
5  
6  
7  
8  
9  
10  
11  
12  
13  
14  
15  
16  
17  
18  
19  
20  
21  
22  
23  
24  
25  
26  
27  
28  
29  
30  
31  
32  
33  
34  
35  
36  
37  
38  
39  
40  
41  
42  
43  
44  
45  
46  
47  
48  
49  
50  
51  
52  
53  
54  
55  
56  
57  
58  
59  
60



Repeat embolisation of left internal carotid artery with detachable balloon (A - black arrow) and frontal project of left vertebral contrast injection showing excellent filling of the left middle cerebral artery territory through large posterior communicating artery after left internal carotid artery sacrifice (B - black arrows).

37x25mm (300 x 300 DPI)



## Assessment of a child presenting in shock secondary to haemorrhage

### [C-Spine] Airway, Breathing, Circulation...

**Signs suggesting compromise of Circulation:** dyspnoea, altered conscious level, hypotension, increased capillary refill time, reduced urine output, lactic acidosis.

**Note of caution:** Massive blood loss can be difficult to quantify and paediatric patients can maintain their blood pressure even after loss of 25-40% of blood volume [16].

### Management of major haemorrhage

**Overall aim:** To restore circulating blood volume, to give blood products in order to maintain haemostasis and to obtain definitive haemostasis [16].

If blood products are not immediately available, consider giving warmed crystalloid.

**Note of caution:** in the paediatric trauma setting, increased crystalloid volume replacement has been associated with increased transfusion requirements, coagulopathy (prolonged prothrombin times), and a tendency towards increased mortality and multi-organ failure rates [17].

#### Blood product administration

- Transfuse packed red cells (PRC) in balance with other blood products e.g. fresh frozen plasma (FFP), platelets, coagulation factors, fibrinogen and anti-fibrinolytics [16]
- The optimal product ratio is not clear but many adult transfusion protocols suggest a PRC:FFP:platelet ratio of 1:1:1.
- FFP can be difficult to obtain quickly so some guidelines advise replacement of PRC:FFP:platelet as 2:1:1 [16].

#### Tranexamic acid

Inhibits fibrinolysis and is often used to reduce the amount of bleeding in at-risk surgeries. It is suggested that administration of tranexamic acid within 3h of paediatric trauma is likely to be beneficial [19].

#### Complications of massive transfusion

- Transfusion reaction,
- Immunological complications,
- Metabolic problems
- Circulatory overload,

Therapeutic targets after massive transfusion (once bleeding is controlled & volume restored): Hb 80g/L, fibrinogen >1g/L, PT ratio <1.5, platelet >75x10<sup>9</sup>/L [16].